

REVIEW ARTICLES

Regional anaesthesia for carotid endarterectomy

M. D. Stoneham*, D. Stamou and J. Mason

Nuffield Division of Anaesthetics, Level 2, Oxford University Hospitals NHS Trust, Headley Way, Oxford OX3 9DU, UK

* Corresponding author. E-mail: mark.stoneham@nda.ox.ac.uk

Editor's key points

- The authors review the use of regional anaesthesia in carotid endarterectomy.
- They note the reduced hospital stay, but the similar rate of stroke, compared with general anaesthesia.
- Methods of achieving regional anaesthesia are detailed, and the authors note the improvements in the equipment available.

Summary. Regional anaesthesia is a popular choice for patients undergoing carotid endarterectomy (CEA). Neurological function is easily assessed during carotid cross-clamping; haemodynamic control is predictable; and hospital stay is consistently shorter compared with general anaesthesia (GA). Despite these purported benefits, mortality and stroke rates associated with CEA remain around 5% for both regional anaesthesia and GA. Regional anaesthetic techniques for CEA have improved with improved methods of location of peripheral nerves including nerve stimulators and ultrasound together with a modification in the classification of cervical plexus blocks. There have also been improvements in local anaesthetic, sedative, and arterial pressure-controlling drugs in patients undergoing CEA, together with advances in the management of patients who develop neurological deficit after carotid cross-clamping. In the UK, published national guidelines now require the time between the patient's presenting neurological event and definitive treatment to 1 week or less. This has implications for the ability of vascular centres to provide specialized vascular anaesthetists familiar with regional anaesthetic techniques for CEA. Providing effective regional anaesthesia for CEA is an important component in the armamentarium of techniques for the vascular anaesthetist in 2014.

Keywords: carotid endarterectomy; outcome; regional anaesthesia

Regional anaesthesia for carotid endarterectomy (CEA) became commonplace in the UK in the 1990s, but significant changes in anaesthetic techniques have taken place since the last major review was published.¹ Regional anaesthetic techniques have evolved—in particular, the use of nerve stimulators and ultrasound to detect peripheral nerves. This review will focus on the whole process of regional anaesthesia for CEA, including: preoperative assessment and preparation, regional anaesthetic techniques, the choice of sedative and local anaesthetic (LA) drugs, the available evidence comparing regional and general anaesthetic (GA) techniques, perioperative arterial pressure management, and the treatment options for patients developing neurological deficits after carotid cross-clamping.

We searched the electronic databases; PubMed and National Library of Medicine from 1999 to 2013 using the phrases 'carotid endarterectomy', together with: 'epidemiology', 'pathophysiology', 'superficial cervical plexus block', 'deep cervical plexus block', 'intermediate cervical plexus block', 'single injection', 'multiple injection', 'monitoring', 'sedation', 'propofol', 'remifentanyl', 'clonidine', 'dexmedetomidine', 'analgesia', 'cross-clamping', 'blood pressure management', 'complications', 'hyperperfusion syndrome', 'cranial nerve injuries', 'stroke', 'shunting', and 'ultrasound guided regional anaesthesia'. We looked for articles, reviews, and case reports that described new techniques or developments in regional anaesthesia. We also searched the reference list of relevant

articles for further references. For this article, we did not consider animal studies.

Preoperative assessment

Preoperative hypertension is a risk factor for postoperative stroke and death,² so patients with uncontrolled hypertension require close attention to perioperative arterial pressure control. Specific figures for preoperative arterial pressure targets have not been defined from controlled trials, but a sensible target is that systolic and diastolic arterial pressures are ≤ 180 and ≤ 100 mm Hg, respectively.³

The 2012 National Guidelines for Stroke recommend that carotid intervention for recently symptomatic severe carotid stenosis should be regarded as an emergency procedure in patients who are neurologically stable, and should ideally be performed within 48 h of a transient ischaemic attack or minor stroke and definitely within 1 week,⁴ as the benefits of carotid surgery decrease rapidly after this. Implementation of these recommendations means that there is less time for preoperative patient preparation, including arterial pressure control, which could predispose to arterial pressure lability.

An estimation of the patient's 'normal' arterial pressure should be obtained from several sources including the clinic visit, the preoperative assessment clinic, and the anaesthetic room—this is the minimum arterial pressure accepted during



EDITOR'S CHOICE

the period of carotid cross-clamping.³ Arterial pressure should be measured in both arms using the correct techniques described by the British Hypertension Society.⁵

The patient's neurological status should be assessed before operation, and neurological deficit(s) documented, as differences detected in the postoperative period potentially require surgical re-exploration.⁶ It is worthwhile noting the patient's presenting neurological complaint, for example, amaurosis fugax, dysphasia, etc. If the patient develops a neurological deficit when the carotid cross-clamp is applied, they commonly present with the same symptoms that they first presented with (M.D.S., unpublished observations).

Anti-hypertensive medications should usually be continued except for angiotensin-converting enzyme inhibitors and angiotensin II receptor antagonists,⁷ but reductions in arterial pressure should be avoided in patients with neurological symptoms.³ β -Blockers protect against perioperative cardiac complications in patients with a history of myocardial ischaemia,⁸ but this is offset by an increased risk of stroke in higher dose regimes⁹ and in patients who become acutely anaemic (although acute anaemia is rare in patients undergoing CEA).¹⁰ The American College of Cardiology recommendations for perioperative β -block include continuation if already taking but not to start unless specifically indicated.¹¹ Metoprolol is associated with increased risk of stroke in patients undergoing non-cardiac surgery compared with other selective drugs such as atenolol or esmolol and should probably be avoided.¹² Statins should be continued as there is evidence of up to a 3% reduction in the incidence of stroke after CEA.¹³

Antiplatelet therapy has a theoretical, therapeutic benefit both at the thrombogenic endarterectomy site and in the coronary circulation in high-risk vascular patients. Aspirin is recommended for all vascular patients in the perioperative period,¹³ but the situation regarding clopidogrel is less clear. There is certainly evidence in patients undergoing CEA of the benefits of dual antiplatelet therapy (aspirin combined with low-dose clopidogrel) to reduce the rate of micro-embolization after operation,¹⁴ and a Cochrane review of randomized trials found significant protection against stroke in patients receiving clopidogrel.¹⁵

Neither the incidence of clinically important neck haematoma^{14 16} nor the morbidity rate from haemorrhagic complications increases in patients undergoing CEA taking clopidogrel with or without aspirin.¹⁷ Surgery may take longer;¹⁸ however, careful consideration should be given to the risks and benefits of performing regional anaesthesia in these patients.¹⁹ There is no evidence available in the literature on the safety of performing CEA under GA or regional anaesthesia techniques in patients receiving newer, faster onset and offset antiplatelet drugs such as ticagrelor or prasugrel or any other of the newer oral anticoagulants.²⁰

Regional anaesthetic techniques

Key anatomy

The cervical plexus is formed by the ventral rami of the first four cervical nerves (C1–4). The nerves pass laterally along the

corresponding transverse process immediately posterior to the vertebral artery and vein. The deep branches are entirely motor and supply the neck muscles. The superficial branches are sensory and supply the skin and subcutaneous tissues of the neck and posterior aspect of the head.

It is possible for the anaesthetist or the surgeon to anaesthetize the tissues layer by layer using large volumes of dilute LA along the line of incision, and thereafter at each dissection plane and finally into the carotid sheath. This represents the simplest and, by default, rescue technique for a less than adequate block or when procedures are to be done by anaesthetists less familiar with nerve blocks. However, most clinicians choose to utilize a formal regional anaesthetic technique.

Cervical epidural anaesthesia can provide suitable conditions for carotid surgery.²¹ An epidural catheter is sited at C6–7 and a dilute anaesthetic solution such as bupivacaine 0.25% injected. However, bilateral cervical and upper thoracic nerve roots are affected resulting in significant side-effects, including hypotension, bradycardia, and respiratory impairment. Other complications include conversion to GA, dural tap, epidural haematoma, and direct spinal cord damage. Although epidural anaesthesia is used infrequently in the UK, it may be useful for more extensive procedures, for example, carotid cross-overs and combined carotid–subclavian reconstructions.²¹ An epidural catheter may be 'topped up' for prolonged procedures, although this has also been described with deep cervical block.²²

Single injection posterior cervical paravertebral block at the C4 level using a nerve stimulator is another technique of blocking C2–4 dermatomes, which may reduce the risk of accidental vascular injury or injection.²³

Superficial cervical plexus block

The technique for this block has been described previously.^{1 24} Superficial block is performed superficial to the investing layer of deep cervical fascia.²⁵ Large volumes, for example, 20–30 ml of LA agents, are typically used. An oft-cited disadvantage of superficial compared with deep block is said to be that it does not provide neck muscle relaxation,²⁶ although this has not been shown to be important clinically.

Deep cervical plexus block

This block is performed as a single (C3 or C4–5)²⁷ or multiple injection technique (C2, C3, C4).²⁸ With the patient supine and the head turned towards the opposite side and slightly up, the cervical transverse processes are palpated behind sternocleidomastoid. After skin disinfection and intradermal infiltration with lidocaine, a 50 mm, 25 G block needle is introduced aiming slightly caudally and posteriorly until the cervical transverse process is encountered, usually 1–2 cm under the skin.

Single-injection blocks cause less pain during the block,²⁷ although the number of injections does not appear to affect overall block efficacy. Single injections may be associated with less systemic absorption of LA.²⁷ The deep block has been implicated with a higher risk of accidental involvement of deep structures, such as the carotid and vertebral arteries, the phrenic nerve, dura mater, and the sympathetic trunk.²⁴

Continuous deep block has been described and may be considered in high-risk cases in which the procedure may be prolonged. An 18 G Tuohy needle is directed towards the C3 transverse cervical process using 1 mA current. Once paraesthesia is encountered in the anterior region of the neck, a 20 G catheter is inserted and secured at 4 cm depth (catheter tip to skin distance).²²

Intermediate cervical plexus block refers to an injection of LA in the space between the superficial and deep cervical fascia²⁵ (although the existence of the deep fascia has been disputed).²⁹ Intermediate block should theoretically reduce complications of deep block such as intrathecal or intra-arterial injection, although there is no evidence supporting this. The technique is straightforward. A needle is inserted perpendicularly to the skin midpoint and posteriorly to the sternocleidomastoid to a depth of 15 mm, just below the superficial cervical fascia. This depth guide may not be valid in obese patients.³⁰ There may be a perception of 'loss of resistance'. The efficacy of superficial (subcutaneous) and intermediate cervical blocks appears similar.³¹

Combined superficial and deep cervical plexus block is commonly practiced and consists of a deep injection plus superficial or intermediate block.³² Superficial and combined blocks appear to be equally efficacious.^{24 32}

Nerve stimulators may be used to identify the deep cervical plexus. A short-bevelled, 50 mm block needle connected to a nerve stimulator is inserted perpendicular to the skin consecutively at C2, C3, and C4. A current of 0.5 mA may elicit neck muscle contractions; ipsilateral head twitch;²⁸ elevation and internal rotation of the scapula;²⁷ paraesthesia over the upper arm, shoulder,³³ neck; or paraesthesia radiating up to the ear. By identifying diaphragmatic muscle response, a nerve stimulator may avoid administration of the LA directly onto the phrenic nerve, thereby avoiding phrenic nerve palsy.³⁴

Additional nerve blocks have also been described to supplement cervical plexus block. Submandibular and referred dental pain commonly occur, which may not respond to administration of supplemental LA.³⁵ This pain may be ameliorated by anaesthetizing the mandibular division of the trigeminal nerve via the intraoral approach.³⁶ This may be useful in patients with short necks, where there is a high carotid bifurcation or where the atheromatous plaque extends cranially in the internal carotid artery.³⁷

Ultrasound-guided superficial cervical plexus block

Ultrasound can demonstrate the cutaneous branches of the superficial cervical plexus and their relation to the surrounding anatomy. The advantages over the landmark technique are the ability to visualize the spread of LA in the correct plane and to avoid inadvertent damage to, or accidental puncture of, neighbouring structures. However, ultrasound guidance has not been shown to improve the success of superficial cervical plexus blocks.³⁸

The superficial cervical plexus lies laterally to the posterior border of the sternocleidomastoid muscle. It can be visualized as a linear streak of hypoechoic nodules, which have a

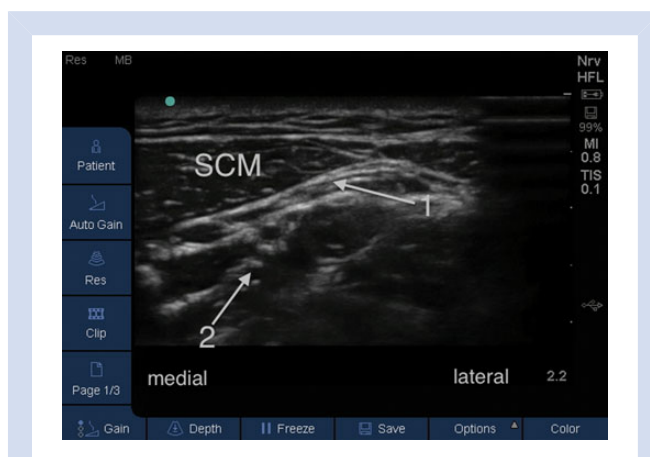


Fig 1 Ultrasound anatomy demonstrating the sternocleidomastoid muscle (SCM), interscalene groove between scalene muscles (arrow 2) and the superficial cervical plexus—hypoechoic nodules—under the lateral border of SCM (arrow 1). Moving the ultrasound probe medially, one would visualize the internal jugular vein and carotid artery.

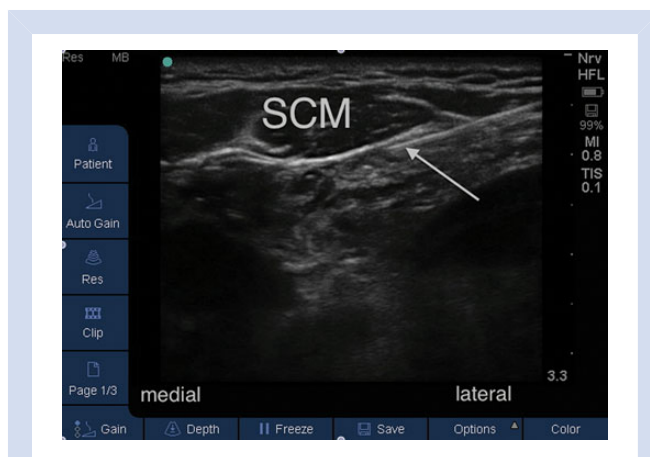


Fig 2 In-plane, longitudinal, ultrasound view with the arrow demonstrating the regional block needle advancing towards the superficial cervical plexus block underneath the lateral border of the sternocleidomastoid (SCM).

honeycomb appearance, below the prevertebral fascia and immediately above the interscalene groove (Fig. 1).

Using aseptic technique, a high-resolution linear transducer is placed transversely over the midpoint of the sternocleidomastoid muscle (usually at the level of the cricoid cartilage, where the external jugular vein crosses sternocleidomastoid). With an in-plane or out-of-plane technique, a 50 mm nerve block needle is advanced adjacent to the superficial cervical plexus in the plane deep to sternocleidomastoid, underneath the prevertebral fascia and immediately above the interscalene groove (Fig. 2). After negative aspiration, 10–15 ml of LA is placed in this fascial plane while visualizing the spread of the LA with ultrasound. High concentrations of LA agent are not required since the superficial cervical plexus comprises purely sensory nerves.³⁹

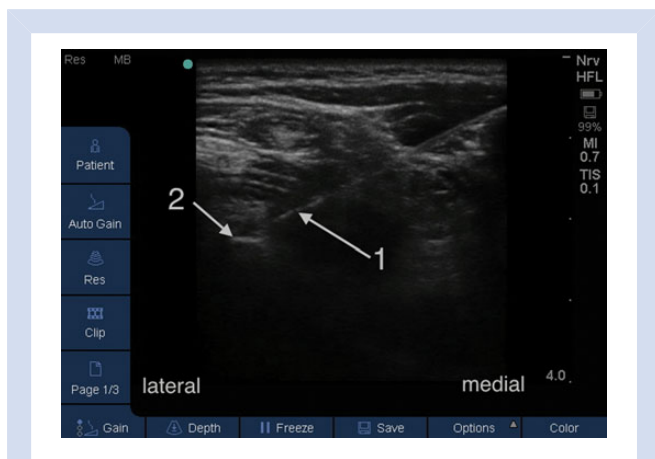


Fig 3 In-plane longitudinal ultrasound view of deep cervical plexus block showing regional block needle (arrow 1) advancing, from medially to laterally, to the C3 transverse process (arrow 2) for deep block. The transverse process appears as a hyperechoic line with posterior acoustic dropout.

Ultrasound-guided deep cervical plexus block

The transverse processes are easily visualized subcutaneously with ultrasound. The vertebral artery makes a prominent loop between C1 and C2, which may be visualized and is an accurate landmark for the transverse process of C2. The C2 spinal nerve lies inferior and posteriorly to the vertebral artery at this level. The vertebral artery is most susceptible to inadvertent puncture at this point but avoided by visualization with ultrasound.

The C3 and C4 spinal nerves exit in the gutters of the transverse processes and posterior to the vertebral artery. Vertebral artery injection with the needle positioned over the C3 and C4 transverse processes is virtually impossible. The neck is scanned from the mastoid process to Chassaignac’s tubercle allowing identification of the relevant anatomy. The transverse processes appear as a hyperechoic formation with posterior acoustic dropout on ultrasound, which is lost when the probe is moved further caudally. With strict asepsis under ultrasound guidance, a 50 mm nerve block needle is advanced until contact is made with the transverse process (Fig. 3). After negative aspiration, 5 ml of LA is injected, which may be repeated at each level.⁴⁰

Ultrasound-guided intermediate cervical plexus block

Fifteen to 20 ml of ropivacaine is deposited, with ultrasound guidance, in the fascial band between the sternocleidomastoid and levator scapulae muscle.⁴¹ This is effective when combined with a perivascular carotid sheath block using 3–5 ml 0.5% ropivacaine and requires little LA supplementation during carotid surgery.⁴²

Pharmacology of cervical plexus blocks

Most LA agents have been used for cervical plexus block. Ropivacaine and levobupivacaine are less potent than bupivacaine, but have a safer profile with regard to LA toxicity.⁴³ Ropivacaine has the advantage of offering longer postoperative pain relief

Table 1 Adjuncts for regional blocks used for CEA.

Drug	Effect
Fentanyl 50 µg ⁴⁶	Increased the quality and duration of the cervical block Decreased sedation requirements during CEA Delayed the timing for the first analgesic request after operation
Clonidine 50 µg ⁴⁷	Improved quality of block Speeds up onset of block
Epinephrine ⁴⁸	1:200 000 concentration decreased lidocaine blood concentrations by 20%

compared with mepivacaine⁴⁴ and causing less vasodilatation than levobupivacaine.⁴⁵ LA supplementation by the surgeon in the form of lidocaine 0.5% or 1% is commonly required. Adjuncts to LA agents which may be used to improve the block or reduce toxicity are shown in Table 1.

Assessment of the block

The loss of pinprick sensation in the distribution of the C2–4 dermatomes, together with complete sensory loss⁴⁶ or altered temperature sensation,⁴⁹ may be used to assess the effectiveness of the block—which should extend over the shoulder and down to the clavicle (C4 dermatome), and up to and including the neck up to the earlobe (C2). On occasions, the block may spread down to C5 and other lower cervical roots⁵⁰ after which the patient may complain of transient ipsilateral arm weakness, thus differentiating it from an intraoperative neurological event that would be contralateral.

Intraoperative management

Good communication at all times is important for patient reassurance and cooperation. The patient is positioned in a ‘deck-chair’ position with the head on a soft head-ring, extended (if tolerated), and rotated contralaterally. Patient comfort is vital to allow them to tolerate 2–3 h in this position. Other potential comfort measures include: the use of a non-heated mattress, padding and support under all pressure areas, a pillow placed under the patient’s knees, ensuring the patient’s bladder is emptied before the operation, and keeping surgical drapes off the patient’s face. Clear plastic drapes may be used to reduce the sensation of claustrophobia. Blood loss is rarely a problem, so fluids should be kept to a minimum to avoid the need to void intraoperatively. Water (e.g. from a 20 ml water for injection ampoule) may be administered to ‘wet the lips’ during the operation. Avoid allowing the patient to drink, however, as the combination of lying supine, the possibility of recurrent laryngeal nerve block, and residual sedation effects make accidental aspiration of water possible, resulting in choking, coughing, hypertension, and potential venous bleeding.

Oxygen is administered via a Hudson facemask continuously throughout the operation. Perioperative monitoring should be placed before sedation and performance of the regional

block. Respiratory monitoring consists of pulse oximetry, respiratory rate by thoracic impedance measurement, end-tidal respiratory gases sampled within the Hudson mask, and arterial blood gas analysis as required. Cardiac monitoring consists of electrocardiography (II and V5) and invasive and non-invasive arterial pressure monitoring. ST segment analysis may be useful.⁵¹

Arterial pressure should be recorded in both arms and the higher value used for invasive monitoring as there may be significant discrepancies between the arms of vascular patients. However, some clinicians choose to use the contralateral side to the operation for the arterial line due to the risk of intraoperative subclavian artery occlusion and thus loss of the arterial waveform.⁵² In patients with poor cardiac function or cardiac ischaemia, more invasive haemodynamic monitoring may be considered.

Carotid cross-clamping

The period of carotid cross-clamping may be up to or even longer than 1 h, although there is considerable variation. Cerebral perfusion is most at risk during this period. Under GA, augmentation of arterial pressure to maintain cerebral perfusion is used by some,⁵³ and augmentation of arterial pressure to 20% above baseline has been recently shown to reduce early postoperative cognitive dysfunction;⁵⁴ however, this can precipitate myocardial ischaemia so must be done cautiously.⁵⁵ Under GA, many surgeons choose to shunt all patients regardless of neurological state. In awake patients, shunting is usually only performed if a neurological deficit develops after cross-clamping. In such patients, two other treatment options are potentially available to avoid the need for carotid shunting. First, selective augmentation of the arterial pressure to normal, or up to 20% above normal, may reverse developing neurological ischaemia.⁵⁶

Secondly, the administration of high concentrations of oxygen has been shown clinically to reverse the developing neurological deficit⁵⁷ and to increase the ipsilateral cerebral oxygenation measured by cerebral oximetry during carotid cross-clamping.⁵⁸ Using these additional management strategies, the percentage of patients requiring carotid shunting is reduced to <10% in patients undergoing awake CEA.⁵⁹

An awake patient is the most reliable method for assessing neurology during carotid cross-clamping. Inadequate brain perfusion may present with loss or altered consciousness, confusion, agitation, dysphasia, seizures, and contralateral motor weakness.⁶⁰ In Oxford, the practice is as follows: the surgeon clamps the carotid artery for 2 min, while the anaesthetist actively looks for signs of cerebral ischaemia. If there is no neurological change, the operation proceeds, while frequent patient observation continues. However, if there are signs of cerebral ischaemia at this point, such as confusion, slurred speech, loss of consciousness, or contralateral motor weakness, the management manoeuvres described above are followed. If these interventions fail, the carotid cross-clamp is released, a shunt prepared, the carotid clamped once again, and a shunt inserted by the surgeon.

An alternative management strategy used by some surgeons, to reduce the likelihood of internal carotid embolism, is to leave the cross-clamp applied and if abnormal neurology develops, to insert a shunt straightaway. Assessment of the awake patient may be done by a variety of methods including: counting tests; questions requiring cognition to answer correctly (e.g. what day of the week is it?). A squeaky toy is used by some for assessment of motor power.

An awake patient can also notify the anaesthetist of cardiac symptoms such as angina before myocardial ischaemia can be detected on the ECG monitoring, thus allowing treatment and potential reversal of the condition.⁵⁶

Other neurological monitors have been used during patients undergoing awake CEA. Bispectral index (BIS) monitoring has been used to predict the need for shunt placement and although the negative predictive value was 96.8%, the positive predictive value was only 56.3%.⁶¹ Similarly, BIS monitoring during awake CEA has not been shown to be reliable in detecting cerebral ischaemia.⁶² On the other hand, depth of anaesthesia monitors such as the Patient State Analyzer (PSA 4000, Physiometric Inc., North Billerica, MA, USA) which use multi-channel analysis and can compare raw EEG from the left and right hemispheres have been successfully used to detect cerebral ischaemia during awake CEA.⁶³

Transcranial Doppler monitoring (TCD) is commonly used as a monitor of cerebral perfusion by monitoring middle cerebral artery blood flow during GA for CEA, but it has been used during awake carotid surgery to indicate developing cerebral ischaemia and to predict patients who may need shunting.^{64 65} In addition, TCD may be used to detect particulate and gaseous embolism intraoperatively and after operation⁶⁶ and to monitor the development of hyperperfusion syndrome after operation.^{67 68}

Sedation

Sedation is commonly administered to supplement the regional block during awake CEA, as inadequate analgesia or anxiety may increase the stress response and could precipitate adverse cardiovascular effects.⁶⁹ Judicious use of conscious sedation (communication maintained with the patient at all times) ensures patient comfort throughout the procedure while minimizing risks.

Several classes of sedative agents have been used including: opioids (remifentanyl, fentanyl), α -2 agonists (clonidine, dexmedetomidine), propofol, and, historically, butyrophenones (droperidol, haloperidol). The ideal sedative agent should reduce anxiety without causing respiratory depression, airway compromise, or haemodynamic instability, while the depth of sedation is altered rapidly.⁷⁰

Propofol target-controlled infusion produces effective, easily controlled sedation, easily titrated to an optimum level, while rapidly reducible to allow neurological monitoring during carotid cross-clamping.⁷⁰

α -2 agonists are ideal drugs as in addition to sedation, they reduce analgesic requirements and are hypotensive agents with cardioprotective properties. Clonidine (1 μ g kg^{-1} loading

dose plus $1 \mu\text{g kg}^{-1} \text{ h}^{-1}$ infusion) has been safely used in patients undergoing CEA without impairment of neurological monitoring, while decreasing the incidence of postoperative pain, hypertension, and neurological complications.⁷¹

Dexmedetomidine is licensed in the USA as a sedative. It produces easily rousable sedation with no respiratory depression, reduces opioid administration,⁷² and has a short half-life allowing rapid titration to effect.⁷³ Compared with other conventional sedatives, dexmedetomidine is associated with less intraoperative and immediate postoperative hypertension, fewer interventions for the treatment for hypertension,⁷⁴ and less pain after operation.⁷⁵ Suitable doses of dexmedetomidine for sedation during CEA are $0.2 \mu\text{g kg}^{-1}$ bolus followed by $0.2 \mu\text{g kg}^{-1} \text{ h}^{-1}$ infusion.⁷²

Remifentanyl is the preferred sedative agent of the authors. It causes hypoventilation and therefore may cause hypercarbia, but this effect is minimized if the dose is titrated to effect.⁶⁹ Remifentanyl at doses up to $3 \mu\text{g kg}^{-1} \text{ h}^{-1}$ produces a rapidly reversible and predictable sedo-analgesia while at the same time reducing LA supplementation.⁷⁶

Sedation must be minimal during cross-clamping to allow frequent neurological assessment. It is the authors' practice to turn off the remifentanyl sedation when the surgeon asks for heparin to be administered before cross-clamping, such that the patients are fully conscious when the period of carotid cross-clamping commences.

Haemodynamic management³

Patients who require perioperative pharmacological treatment for hypotension and hypertension have >1 yr morbidity and mortality.⁷⁷ The cardiovascular 'profiles' associated with carotid surgery performed under GA and regional anaesthesia differ considerably. Under GA, patients tend to be relatively hypotensive intraoperatively, commonly requiring vasopressor support.⁵³ After operation, GA patients tend to be hypertensive, due to emergence from anaesthesia and, perhaps, in pain. On the other hand, patients under regional anaesthesia are often relatively hypertensive intraoperatively, particularly during the cross-clamp period, but then relatively hypotensive after operation. These observations may be explained by cerebral autoregulation, which is probably still functioning in awake patients.

Arterial pressure during carotid cross-clamping should not be allowed to decrease below the patient's 'baseline' and should be kept at or up to 20% above this. However, after carotid artery unclamping, hypertension should be avoided to reduce the likelihood of hyperperfusion syndrome.⁷⁸ The choice of specific vasoactive drugs and reported thresholds for arterial pressure control depends on a variety of factors that include the patient's history, comorbidity, underlying heart rate, and drug history.

Metaraminol, ephedrine, and phenylephrine are commonly used in the UK to augment arterial pressure. A wide variety of drugs including hydralazine, glyceryl trinitrate (GTN), calcium channel antagonists, β -blockers (labetalol, esmolol, atenolol), and α -2 agonists, such as clonidine, may be used to treat perioperative hypertension. Metoprolol should probably be

avoided, due to pharmacogenetic variation in metabolism⁸ and the associated increased incidence of perioperative stroke.¹² Calcium channel blockers and vasodilators may be beneficial in patients with ischaemic heart disease. GTN can increase cerebral perfusion pressure, despite a decrease in mean arterial pressure⁷⁹ and nifedipine has caused precipitous decreases in arterial pressure^{80 81} and should be avoided in the acute management of hypertension in patients undergoing CEA.

Complications of regional anaesthesia

Seizures occurring during CEA can be life-threatening, because of possible airway compromise and cerebral ischaemia due to increased cerebral oxygen consumption.⁸² The cause of seizures during CEA is multifactorial and includes: LA overdose, direct injection of LA into the artery (either by the surgeon⁸² or by the anaesthetist,⁸³) or cerebral ischaemia. After operation, seizures may be a manifestation of hyperperfusion syndrome,⁷⁸ which generally requires aggressive anti-hypertensive treatment. Seizures occurring intraoperatively due to intravascular injection of LA may be short in duration, with rapid subsequent recovery⁸² and do not necessarily preclude safely completing the operation.

Cervical block complications

More complications have been reported in the literature from patients undergoing deep and combined deep and superficial cervical plexus block compared with superficial block alone. In a systematic review of complications reported from 69 papers describing a total of 7558 deep/combined blocks and 2533 superficial/intermediate blocks reported in the literature,⁸⁴ deep/combined block was associated with a higher complication rate compared with the superficial/intermediate block (odds ratio 2.13, $P=0.006$). The conversion rate to GA was also higher with patients receiving the deep/combined block (odds ratio 5.15, $P<0.0001$). Only two randomized controlled trials were included in the review and none of the studies specifically compared safety aspects of different cervical plexus blocks, so while this review illustrates the potential dangers of deep block, it would be imprudent to abandon the deep block without formal evidence of increased risk. In addition, performing regional blocks using ultrasound has been shown to be safer in terms of less LA toxicity⁸⁵ and higher success rates than nerve-stimulator-guided blocks,^{86 87} but this has not yet been shown for cervical plexus blocks.

Cardiovascular complications

Myocardial infarction is a major cause of perioperative and long-term mortality after CEA. Only nine out of 3523 (0.25%) patients in the GALA trial suffered myocardial infarction, with no difference between the GA and LA groups.⁸⁸ Cardiac complications are relatively common in arteriopathies presenting for any type of surgery, so the development of cardiac complications after administration of cervical plexus block may not necessarily imply a causal relationship.⁸⁹ Accidental surgical manipulation of the vagus nerve, which lies within the carotid sheath, can lead to profound

haemodynamic disturbance, including nausea and vomiting, bradycardia, hypotension, and even cardiovascular collapse. Treatment involves alerting the surgeons to their potential vagal stimulation, less retraction, and administration of anticholinergic drugs such as atropine.

Airway complications

Respiratory distress, secondary to diaphragmatic or vocal cord paralysis, may occur. Phrenic nerve block is common after deep cervical block occurring in up to half of the patients,⁹⁰ although this is commonly tolerated without major sequelae.⁹¹ However, in patients with unrecognized contralateral phrenic/recurrent laryngeal nerve damage, due to previous cardiac or neck surgery,⁴⁹ cervical plexus block may result in respiratory distress or obstruction.⁹² Preoperative examination of vocal cords in patients at risk of contralateral nerve damage has been recommended.⁴⁹

Airway compromise after CEA may be life-threatening. Airway oedema is demonstrable in all patients undergoing CEA⁹³ and may be due to local trauma and interference with venous and lymphatic drainage.⁹⁴ Haematoma formation (due to arteriotomy dehiscence or wound haematoma) further compresses the airway anatomy.

It may be possible to return the patient to theatre and open the wound with the LA block still working, thus avoiding the need for emergent control of the airway. However, when required, various airway techniques have been described including fiberoptic intubation, direct laryngoscopy using LA with or without mild sedation before induction of anaesthesia, laryngeal mask airway insertion, and tracheostomy.⁹⁵ Visualization of the glottis with a fiberoptic scope can itself be difficult due to venous congestion and distortion of the anatomy.⁹⁶ In cases of poor direct visualization of the glottis, either before or after induction, decompression of the airway by opening the surgical incision in recovery may facilitate intubation of the trachea, even if a previous fiberoptic intubation attempt has failed.⁹⁵ In the presence of acute neck swelling, changes in the voice such as hoarseness are considered harbingers of impending airway obstruction⁹⁶ and managed accordingly with appropriate anaesthetic and surgical levels of expertise. Any patient who has been reintubated for airway compromise or surgical evacuation of haematoma will usually require overnight elective ventilation to allow the airway oedema to settle.

Pain may be caused by inadequate regional anaesthesia, variable afferent sympathetic nerve supply to the carotid artery and sheath,⁹⁷ and may occur in patients with a high carotid bifurcation where the surgical field is supplied by cranial rather than spinal nerves. Supplementation of the block is easily achieved directly by judicious LA infiltration by the surgeon. The authors have used lidocaine spray (Xylocaine 10% Pump spray, AstraZeneca, Luton, UK), sprayed directly onto the carotid artery or sheath to effect immediate pain relief in particular for referred pain from the carotid sheath.

Intra-arterial injection of LA (despite negative aspiration test), subarachnoid injection (resulting in brain stem anaesthesia), and

anaesthesia of the recurrent laryngeal, vagus, hypoglossal, and phrenic nerve have all been described with deep cervical plexus block.

Conversion to GA is rarely required. An incidence of 2.5% is quoted⁹⁸ and may result from inadequate anaesthesia, patient agitation, poor patient compliance, severe respiratory compromise, or accidental intravascular injection. Deep/combined block has historically been more commonly associated with conversion to GA than superficial block.⁸⁴ If conversion to GA is required, this may usually be accomplished by administration of suitable analgesics (e.g. remifentanyl) and propofol followed by airway control with a laryngeal mask airway and subsequent ventilation if required. This may arguably be safer and a better plan than a rapid sequence induction due to difficulties with intubation and potential haemodynamic consequences of intubation.

Nerve injuries can occur as a result of the regional block or the surgery itself⁹⁹ and may be asymptomatic. The nerves at risk of injury are the marginal mandibular branch of the facial, laryngeal, accessory, hypoglossal, the sympathetic chain (Horner's syndrome), and the radial nerve. The cutaneous sensory nerves supplying the second, third, and fourth dermatomes can also be damaged.¹⁰⁰ Most cranial nerve injuries probably result from stretching, retraction, clamping, or imprudent use of diathermy,¹⁰¹ and resolve within 4 months. Dexamethasone has been shown to be effective at decreasing the incidence of temporary post-CEA cranial nerve dysfunction.¹⁰² Facial nerve block has also been described after superficial cervical plexus block¹⁰³ and must be distinguished from a cerebrovascular event.

Regional anaesthesia vs GA

Proponents of GA cite neurological protection afforded by thiopental and volatile anaesthetic agents;¹⁰⁴ absolute perioperative control of ventilation (allowing control of arterial carbon dioxide concentration and its effects on the cerebral vasculature);¹⁰⁵ and finally, the individual preferences of surgeon, anaesthetist, and patient.

The main advantage of regional anaesthesia is the ease of assessment of neurological status during carotid cross-clamping compared with the alternatives available under GA, such as TCD, somatosensory-evoked potentials, processed EEG, and near-infrared spectroscopy.⁶⁸ Other benefits of regional techniques include: immediate postoperative neurological assessment, greater cardiovascular stability, better postoperative analgesia, and shorter hospital stay¹⁰⁶ (with associated financial benefits).

The GALA trial (a randomized comparison of GA and LA for patients undergoing CEA) was devised to attempt to determine whether GA or regional anaesthesia was the safer technique.⁸⁸ GALA is the largest ever published comparison of two anaesthetic techniques. Over 8 yr, 3526 patients were recruited and randomized to receive GA or regional anaesthesia for CEA. A primary outcome (myocardial infarction, stroke, or

death within 30 days of surgery) occurred in 4.8% patients assigned to GA and 4.5% of those assigned to LA.

Despite the equivocal results of GALA, the debate as to which anaesthetic technique is associated with the best outcome has not abated.¹⁰⁷ GALA was criticized for being underpowered, despite the large number of patients recruited. Furthermore, GALA trial critics (mostly proponents of regional anaesthesia) cite the wide variability in trial methodology which allowed any GA technique to be compared with any regional anaesthesia technique; the slow recruitment and changing clinical practice over 8 yr; and the wide variability in practice between participating countries. On the other hand, proponents of GA have used GALA trial results to validate their practice.

Since the GALA trial, several other papers have been published showing further subtle differences between GA and regional anaesthesia for CEA. The GALA collaborators published a study showing that patients receiving GA had higher jugular venous concentrations of a marker of cerebral ischaemia (neuronal-specific enolase) compared with those patients receiving LA.¹⁰⁸

One possible explanation for the equivocal results of GALA is that the choice of anaesthetic technique used is less important than the vascular 'team' looking after the patient. Clinical staff who are used to working with each other use protocol-driven methods and techniques to achieve good clinical results.¹⁰⁹ There are large published case series attesting to the relative safety of both GA and regional anaesthetic techniques with 30 day mortality rates considerably less than the accepted 'normal' rates.^{110 111} These care series support this concept of a team approach to major vascular surgery.

Conclusions

Regional anaesthesia for carotid surgery has evolved over the last 15 yr with new regional techniques, novel methods of locating the cervical plexus, new drugs, and better management of the patient during the carotid cross-clamping. While regional anaesthesia has not been shown to be associated with better outcome than GA, there are differences in, including in haemodynamic stability, the ease of neurological monitoring and hospital stay. Our challenges for the future will include: management of the 'urgent carotid', optimizing arterial pressure control, and developing clinical protocols to avoid perioperative complications such that overall perioperative morbidity and mortality may be reduced.

Authors' contributions

M.D.S. had the idea for this review article and wrote the second and subsequent drafts. D.S. did the literature review and wrote a first draft. J.M. obtained the ultrasound images of the cervical plexus and wrote the section on ultrasound-guided cervical plexus blocks.

Declaration of interest

None declared.

Funding

No funding was required for this review article.

References

- 1 Stoneham MD, Knighton JD. Regional anaesthesia for carotid endarterectomy. *Br J Anaesth* 1999; **82**: 910–9
- 2 Bond R, Narayan SK, Rothwell PM, Warlow CP, Group ECSTC. Clinical and radiographic risk factors for operative stroke and death in the European carotid surgery trial. *Eur J Vasc Endovasc Surg* 2002; **23**: 108–16
- 3 Stoneham MD, Thompson JP. Arterial pressure management and carotid endarterectomy. *Br J Anaesth* 2009; **102**: 442–52
- 4 Intercollegiate Stroke Working Party. *National Clinical Guidelines for Stroke*. London, 2012. Available from <https://www.rcplondon.ac.uk/resources/stroke-guidelines> (accessed 23 July 2014)
- 5 British Hypertension Society. Hypertension: clinical management of primary hypertension in adults, 2011. Available from <http://www.bhsoc.org/latest-guidelines/sub-page-11/> (accessed 23 July 2014)
- 6 Hans SS. Results of carotid re-exploration for post-carotid endarterectomy thrombosis. *J Cardiovasc Surg (Torino)* 2007; **48**: 587–91
- 7 Comfere T, Sprung J, Kumar MM, et al. Angiotensin system inhibitors in a general surgical population. *Anesth Analg* 2005; **100**: 636–44
- 8 Flynn BC, Vernick WJ, Ellis JE. β -Blockade in the perioperative management of the patient with cardiac disease undergoing non-cardiac surgery. *Br J Anaesth* 2011; **107**(Suppl. 1): i3–15
- 9 Devereaux PJ, Yang H, Yusuf S, et al. Effects of extended-release metoprolol succinate in patients undergoing non-cardiac surgery (POISE trial): a randomised controlled trial. *Lancet* 2008; **371**: 1839–47
- 10 Beattie WS, Wijeyesundera DN, Karkouti K, et al. Acute surgical anemia influences the cardioprotective effects of beta-blockade: a single-center, propensity-matched cohort study. *Anesthesiology* 2010; **112**: 25–33
- 11 Fleischmann KE, Beckman JA, Buller CE, et al. 2009 ACCF/AHA focused update on perioperative beta blockade. *J Am Coll Cardiol* 2009; **54**: 2102–28
- 12 Mashour GA, Sharifpour M, Freundlich RE, et al. Perioperative metoprolol and risk of stroke after noncardiac surgery. *Anesthesiology* 2013; **119**: 1340–6
- 13 Durham CA, Ehlert BA, Agle SC, et al. Role of statin therapy and angiotensin blockade in patients with asymptomatic moderate carotid artery stenosis. *Ann Vasc Surg* 2012; **26**: 344–52
- 14 Payne DA, Twigg MW, Hayes PD, Naylor AR. Antiplatelet agents and risk factors for bleeding postcarotid endarterectomy. *Ann Vasc Surg* 2010; **24**: 900–7

- 15 Engelter S, Lyrer P. Antiplatelet therapy for preventing stroke and other vascular events after carotid endarterectomy. *Stroke* 2004; **35**: 1227–8
- 16 Stoner MC, Defreitas DJ. Process of care for carotid endarterectomy: perioperative medical management. *J Vasc Surg* 2010; **52**: 223–31
- 17 Wait SD, Abla AA, Killory BD, Starke RM, Spetzler RF, Nakaji P. Safety of carotid endarterectomy while on clopidogrel (Plavix). Clinical article. *J Neurosurg* 2010; **113**: 908–12
- 18 Chechik O, Goldstein Y, Behrbalk E, Kaufman E, Rabinovich Y. Blood loss and complications following carotid endarterectomy in patients treated with clopidogrel. *Vascular* 2012; **20**: 193–7
- 19 Hall R, Mazer CD. Antiplatelet drugs: a review of their pharmacology and management in the perioperative period. *Anesth Analg* 2011; **112**: 292–318
- 20 Benzon HT, Avram MJ, Green D, Bonow RO. New oral anticoagulants and regional anaesthesia. *Br J Anaesth* 2013; **111**(Suppl. 1): i96–113
- 21 Michalek P, David I, Adamec M, Janousek L. Cervical epidural anesthesia for combined neck and upper extremity procedure: a pilot study. *Anesth Analg* 2004; **99**: 1833–6
- 22 Jones HG, Stoneham MD. Continuous cervical plexus block for carotid body tumour excision in a patient with Eisenmenger's syndrome. *Anaesthesia* 2006; **61**: 1214–8
- 23 Boezaart AP, Nosovitch MA. Carotid endarterectomy using single injection posterior cervical paravertebral block. *Anesth Analg* 2005; **101**: 1885–6
- 24 de Sousa AA, Filho MA, Faglione W, Carvalho GT. Superficial vs combined cervical plexus block for carotid endarterectomy: a prospective, randomized study. *Surg Neurol* 2005; **63**(Suppl. 1): S22–5
- 25 Telford RJ, Stoneham MD. Correct nomenclature of superficial cervical plexus blocks. *Br J Anaesth* 2004; **92**: 775, author reply 775–6
- 26 Masters RD, Castresana EJ, Castresana MR. Superficial and deep cervical plexus block: technical considerations. *AANA J* 1995; **63**: 235–43
- 27 Merle JC, Mazoit JX, Desgranges P, et al. A comparison of two techniques for cervical plexus blockade: evaluation of efficacy and systemic toxicity. *Anesth Analg* 1999; **89**: 1366–70
- 28 Gratz I, Deal E, Larijani GE, Domskey R, Goldberg ME. The number of injections does not influence absorption of bupivacaine after cervical plexus block for carotid endarterectomy. *J Clin Anesth* 2005; **17**: 263–6
- 29 Pandit JJ, Dorje P, Satya-Krishna R. Investing layer of the cervical fascia of the neck may not exist. *Anesthesiology* 2006; **104**: 1344
- 30 Barone M, Diemunsch P, Baldassarre E, et al. Carotid endarterectomy with intermediate cervical plexus block. *Tex Heart Inst J* 2010; **37**: 297–300
- 31 Ramachandran SK, Picton P, Shanks A, Dorje P, Pandit JJ. Comparison of intermediate vs subcutaneous cervical plexus block for carotid endarterectomy. *Br J Anaesth* 2011; **107**: 157–63
- 32 Pandit JJ, Bree S, Dillon P, Elcock D, McLaren ID, Crider B. A comparison of superficial versus combined (superficial and deep) cervical plexus block for carotid endarterectomy: a prospective, randomized study. *Anesth Analg* 2000; **91**: 781–6
- 33 Mehta Y, Juneja R. Regional analgesia for carotid artery endarterectomy by Winnie's single-injection technique using a nerve detector. *J Cardiothorac Vasc Anesth* 1992; **6**: 772–3
- 34 Zeiden A, Hayek F. Nerve stimulator-guided cervical plexus block for carotid endarterectomy. *Anaesthesia* 2007; **62**: 299–300
- 35 Madi-Jebara S, Yazigi A, Haddad F, Hayek G. Severe dental pain during carotid endarterectomy under cervical plexus block. *J Cardiothorac Vasc Anesth* 2001; **15**: 356–7
- 36 Bourke DL, Thomas P. Mandibular nerve block in addition to cervical plexus block for carotid endarterectomy. *Anesth Analg* 1998; **87**: 1034–6
- 37 Krovvidi H, Thomas W, Danks J. Supplementary intraoral inferior alveolar block improves the quality of regional anesthesia during carotid endarterectomy: experience with 100 cases. *J Clin Anesth* 2008; **20**: 406
- 38 Tran dQ, Dugani S, Finlayson RJ. A randomized comparison between ultrasound-guided and landmark-based superficial cervical plexus block. *Reg Anesth Pain Med* 2010; **35**: 539–43
- 39 Narouze S. Sonoanatomy of the cervical spinal nerve roots: implications for brachial plexus block. *Reg Anesth Pain Med* 2009; **34**: 616
- 40 Sandeman DJ, Griffiths MJ, Lennox AF. Ultrasound guided deep cervical plexus block. *Anaesth Intensive Care* 2006; **34**: 240–4
- 41 Perisanidis C, Saranteas T, Kostopanagioutou G. Ultrasound-guided combined intermediate and deep cervical plexus nerve block for regional anaesthesia in oral and maxillofacial surgery. *Dentomaxillofac Radiol* 2013; **42**: 29945724
- 42 Rössel T, Kersting S, Heller AR, Koch T. Combination of high-resolution ultrasound-guided perivascular regional anesthesia of the internal carotid artery and intermediate cervical plexus block for carotid surgery. *Ultrasound Med Biol* 2013; **39**: 981–6
- 43 Foster RH, Markham A. Levobupivacaine: a review of its pharmacology and use as a local anaesthetic. *Drugs* 2000; **59**: 551–79
- 44 Leoni A, Magrin S, Mascotto G, et al. Cervical plexus anesthesia for carotid endarterectomy: comparison of ropivacaine and mepivacaine. *Can J Anaesth* 2000; **47**: 185–7
- 45 Cristalli A, Arlati S, Bettinelli L, Bracconaro G, Marconi G, Zerbi S. Regional anesthesia for carotid endarterectomy: a comparison between ropivacaine and levobupivacaine. *Minerva Anestesiol* 2009; **75**: 231–7

- 46 Sindjelic RP, Vlajkovic GP, Davidovic LB, Markovic DZ, Markovic MD. The addition of fentanyl to local anesthetics affects the quality and duration of cervical plexus block: a randomized, controlled trial. *Anesth Analg* 2010; **111**: 234–7
- 47 Danelli G, Nuzzi M, Salcuni PF, et al. Does clonidine 50 microg improve cervical plexus block obtained with ropivacaine 150 mg for carotid endarterectomy? A randomized, double-blinded study. *J Clin Anesth* 2006; **18**: 585–8
- 48 Dawson AR, Dysart RH, Amerena JV, et al. Arterial lignocaine concentrations following cervical plexus blockade for carotid endarterectomy. *Anaesth Intensive Care* 1991; **19**: 197–200
- 49 Weiss A, Isselhorst C, Gahlen J, et al. Acute respiratory failure after deep cervical plexus block for carotid endarterectomy as a result of bilateral recurrent laryngeal nerve paralysis. *Acta Anaesthesiol Scand* 2005; **49**: 715–9
- 50 Dhonneur G, Saidi NE, Merle JC, Asfazadourian H, Ndoko SK, Bloc S. Demonstration of the spread of injectate with deep cervical plexus block: a case series. *Reg Anesth Pain Med* 2007; **32**: 116–9
- 51 Landesberg G, Erel J, Anner H, et al. Perioperative myocardial ischemia in carotid endarterectomy under cervical plexus block and prophylactic nitroglycerin infusion. *J Cardiothorac Vasc Anesth* 1993; **7**: 259–65
- 52 Connell OO, Lynch T, Motherway C. An added benefit of bilateral blood pressure monitoring during carotid endarterectomy. *Anaesthesia* 2007; **62**: 971
- 53 Umbrain V, Keeris J, D'Haese J, et al. Isoflurane, desflurane and sevoflurane for carotid endarterectomy. *Anaesthesia* 2000; **55**: 1052–7
- 54 Heyer EJ, Mergeche JL, Anastasian ZH, Kim M, Mallon KA, Connolly ES. Arterial blood pressure management during carotid endarterectomy and early cognitive dysfunction. *Neurosurgery* 2014; **74**: 245–51
- 55 Smith JS, Roizen MF, Cahalan MK, et al. Does anesthetic technique make a difference? Augmentation of systolic blood pressure during carotid endarterectomy: effects of phenylephrine versus light anesthesia and of isoflurane versus halothane on the incidence of myocardial ischemia. *Anesthesiology* 1988; **69**: 846–53
- 56 Stoneham MD, Warner O. Blood pressure manipulation during awake carotid surgery to reverse neurological deficit after carotid cross-clamping. *Br J Anaesth* 2001; **87**: 641–4
- 57 Stoneham MD, Martin T. Increased oxygen administration during awake carotid surgery can reverse neurological deficit following carotid cross-clamping. *Br J Anaesth* 2005; **94**: 582–5
- 58 Stoneham MD, Lodi O, de Beer TC, Sear JW. Increased oxygen administration improves cerebral oxygenation in patients undergoing awake carotid surgery. *Anesth Analg* 2008; **107**: 1670–5
- 59 Sideso E, Walton J, Handa A. General or local anesthesia for carotid endarterectomy—the ‘real-world’ experience. *Angiology* 2011; **62**: 609–13
- 60 Guay J. Regional anesthesia for carotid surgery. *Curr Opin Anaesthesiol* 2008; **21**: 638–44
- 61 Estruch-Pérez MJ, Ausina-Aguilar A, Barberá-Alacreu M, Sánchez-Morillo J, Solaz-Roldán C, Morales-Suárez-Varela MM. Bispectral index changes in carotid surgery. *Ann Vasc Surg* 2010; **24**: 393–9
- 62 Deogaonkar A, Vivar R, Bullock RE, Price K, Chambers I, Mendelow AD. Bispectral index monitoring may not reliably indicate cerebral ischaemia during awake carotid endarterectomy. *Br J Anaesth* 2005; **94**: 800–4
- 63 Culp WC, Kinsky MP, Rios JA, Mendelow AD. Bispectral index monitoring may not reliably indicate cerebral ischaemia during awake carotid endarterectomy. *Br J Anaesth* 2005; **95**: 559–60
- 64 Guay J, Kopp S. Cerebral monitors versus regional anesthesia to detect cerebral ischemia in patients undergoing carotid endarterectomy: a meta-analysis. *Can J Anaesth* 2013; **60**: 266–79
- 65 Pugliese F, Ruberto F, Tosi A, et al. Regional cerebral saturation versus transcranial Doppler during carotid endarterectomy under regional anaesthesia. *Eur J Anaesthesiol* 2009; **26**: 643–7
- 66 van Zuilen EV, Moll FL, Vermeulen FE, Mauser HW, van Gijn J, Ackerstaff RG. Detection of cerebral microemboli by means of transcranial Doppler monitoring before and after carotid endarterectomy. *Stroke* 1995; **26**: 210–3
- 67 Pennekamp CW, Tromp SC, Ackerstaff RG, et al. Prediction of cerebral hyperperfusion after carotid endarterectomy with transcranial Doppler. *Eur J Vasc Endovasc Surg* 2012; **43**: 371–6
- 68 Pennekamp CW, Moll FL, de Borst GJ. The potential benefits and the role of cerebral monitoring in carotid endarterectomy. *Curr Opin Anaesthesiol* 2011; **24**: 693–7
- 69 Krenn H, Deusch E, Jellinek H, Oczenski W, Fitzgerald RD. Remifentanyl or propofol for sedation during carotid endarterectomy under cervical plexus block. *Br J Anaesth* 2002; **89**: 637–40
- 70 Barringer C, Williams JM, McCrerrick A, Earnshaw JJ. Regional anaesthesia and propofol sedation for carotid endarterectomy. *ANZ J Surg* 2005; **75**: 546–9
- 71 Schneemilch CE, Bachmann H, Ulrich A, Elwert R, Halloul Z, Hachenberg T. Clonidine decreases stress response in patients undergoing carotid endarterectomy under regional anesthesia: a prospective, randomized, double-blinded, placebo-controlled study. *Anesth Analg* 2006; **103**: 297–302
- 72 Sidorowicz M, Owczuk R, Kwiecińska B, Wujtewicz MA, Wojciechowski J, Wujtewicz M. Dexmedetomidine sedation for carotid endarterectomy. *Anestezjol Intens Ter* 2009; **41**: 78–83
- 73 Coursin DB, Maccioli GA. Dexmedetomidine. *Curr Opin Crit Care* 2001; **7**: 221–6

- 74 Bekker AY, Basile J, Gold M, et al. Dexmedetomidine for awake carotid endarterectomy: efficacy, hemodynamic profile, and side effects. *J Neurosurg Anesthesiol* 2004; **16**: 126–35
- 75 McCutcheon CA, Orme RM, Scott DA, Davies MJ, McGlade DP. A comparison of dexmedetomidine versus conventional therapy for sedation and hemodynamic control during carotid endarterectomy performed under regional anesthesia. *Anesth Analg* 2006; **102**: 668–75
- 76 Stoneham MD. Anaesthesia for carotid artery disease. In: Moores CNA, ed. *Core Topics of Vascular Anaesthesia*. Cambridge: Cambridge University Press, 2012; 170–81
- 77 Tan TW, Eslami MH, Kalish JA, et al. The need for treatment of hemodynamic instability following carotid endarterectomy is associated with increased perioperative and 1-year morbidity and mortality. *J Vasc Surg* 2014; **59**: 16–24
- 78 Bouri S, Thapar A, Shalhoub J, et al. Hypertension and the post-carotid endarterectomy cerebral hyperperfusion syndrome. *Eur J Vasc Endovasc Surg* 2011; **41**: 229–37
- 79 Moppett IK, Sherman RW, Wild MJ, Latter JA, Mahajan RP. Effects of norepinephrine and glyceryl trinitrate on cerebral haemodynamics: transcranial Doppler study in healthy volunteers. *Br J Anaesth* 2008; **100**: 240–4
- 80 Fami MJ, Ho NT, Mason CM. Another report of adverse reactions to immediate-release nifedipine. *Pharmacotherapy* 1998; **18**: 1133–5
- 81 Yanturali S, Akay S, Ayrik C, Cevik AA. Adverse events associated with aggressive treatment of increased blood pressure. *Int J Clin Pract* 2004; **58**: 517–9
- 82 Stoneham MD, Bree SE. Epileptic seizure during awake carotid endarterectomy. *Anesth Analg* 1999; **89**: 885–6
- 83 Carling T, Donovan P, Rinder C, Udelsman R. Minimally invasive parathyroidectomy using cervical block: reasons for conversion to general anesthesia. *Arch Surg* 2006; **141**: 401–4
- 84 Pandit JJ, Satya-Krishna R, Gratton P. Superficial or deep cervical plexus block for carotid endarterectomy: a systematic review of complications. *Br J Anaesth* 2007; **99**: 159–69
- 85 Barrington MJ, Kluger R. Ultrasound guidance reduces the risk of local anesthetic systemic toxicity following peripheral nerve blockade. *Reg Anesth Pain Med* 2013; **38**: 289–97
- 86 Schnabel A, Meyer-Frießem CH, Zahn PK, Pogatzki-Zahn EM. Ultrasound compared with nerve stimulation guidance for peripheral nerve catheter placement: a meta-analysis of randomized controlled trials. *Br J Anaesth* 2013; **111**: 564–72
- 87 Abrahams MS, Aziz MF, Fu RF, Horn JL. Ultrasound guidance compared with electrical neurostimulation for peripheral nerve block: a systematic review and meta-analysis of randomized controlled trials. *Br J Anaesth* 2009; **102**: 408–17
- 88 Lewis SC, Warlow CP, Bodenham AR, et al. General anaesthesia versus local anaesthesia for carotid surgery (GALA): a multicentre, randomised controlled trial. *Lancet* 2008; **372**: 2132–42
- 89 Carling A, Simmonds M. Complications from regional anaesthesia for carotid endarterectomy. *Br J Anaesth* 2000; **84**: 797–800
- 90 Emery G, Handley G, Davies MJ, Mooney PH. Incidence of phrenic nerve block and hypercapnia in patients undergoing carotid endarterectomy under cervical plexus block. *Anaesth Intensive Care* 1998; **26**: 377–81
- 91 Sala-Blanch X, Lázaro JR, Correa J, Gómez-Fernandez M. Phrenic nerve block caused by interscalene brachial plexus block: effects of digital pressure and a low volume of local anesthetic. *Reg Anesth Pain Med* 1999; **24**: 231–5
- 92 Stoneham MD, Wakefield TW. Acute respiratory distress after deep cervical plexus block. *J Cardiothorac Vasc Anesth* 1998; **12**: 197–8
- 93 Carmichael FJ, McGuire GP, Wong DT, Crofts S, Sharma S, Montanera W. Computed tomographic analysis of airway dimensions after carotid endarterectomy. *Anesth Analg* 1996; **83**: 12–7
- 94 Kwok AO, Silbert BS, Allen KJ, Bray PJ, Vidovich J. Bilateral vocal cord palsy during carotid endarterectomy under cervical plexus block. *Anesth Analg* 2006; **102**: 376–7
- 95 Shakespeare WA, Lanier WL, Perkins WJ, Pasternak JJ. Airway management in patients who develop neck hematomas after carotid endarterectomy. *Anesth Analg* 2010; **110**: 588–93
- 96 Munro FJ, Makin AP, Reid J. Airway problems after carotid endarterectomy. *Br J Anaesth* 1996; **76**: 156–9
- 97 Einav S, Landesberg G, Prud D, Anner H, Berlatzky Y. A case of nerves. *Reg Anesth* 1996; **21**: 168–70
- 98 Davies MJ, Silbert BS, Scott DA, Cook RJ, Mooney PH, Blyth C. Superficial and deep cervical plexus block for carotid artery surgery: a prospective study of 1000 blocks. *Reg Anesth* 1997; **22**: 442–6
- 99 Downs AR, Jessen M, Lye CR. Peripheral nerve injuries during carotid endarterectomy. *Can J Surg* 1987; **30**: 22–4
- 100 Cunningham EJ, Bond R, Mayberg MR, Warlow CP, Rothwell PM. Risk of persistent cranial nerve injury after carotid endarterectomy. *J Neurosurg* 2004; **101**: 445–8
- 101 Beasley WD, Gibbons CP. Cranial nerve injuries and the retrojugular approach in carotid endarterectomy. *Ann R Coll Surg Engl* 2008; **90**: 685–8
- 102 Regina G, Angiletta D, Impedovo G, De Robertis G, Fiorella M, Carratu' MR. Dexamethasone minimizes the risk of cranial nerve injury during CEA. *J Vasc Surg* 2009; **49**: 99–102
- 103 Hayek G, Yazigi A, Jebara S, Haddad F, Rokeibi N. Facial nerve paralysis during cervical plexus block for carotid artery endarterectomy. *J Cardiothorac Vasc Anesth* 2003; **17**: 782–3
- 104 Head BP, Patel P. Anesthetics and brain protection. *Curr Opin Anaesthesiol* 2007; **20**: 395–9

- 105 Picton P, Chambers J, Shanks A, Dorje P. The influence of inspired oxygen fraction and end-tidal carbon dioxide on post-cross-clamp cerebral oxygenation during carotid endarterectomy under general anesthesia. *Anesth Analg* 2010; **110**: 581–7
- 106 Schechter MA, Shortell CK, Scarborough JE. Regional versus general anesthesia for carotid endarterectomy: the American College of Surgeons National Surgical Quality Improvement Program perspective. *Surgery* 2012; **152**: 309–14
- 107 Guay J. The GALA trial: answers it gives, answers it does not. *Lancet* 2008; **372**: 2092–3
- 108 Wijeyaratne SM, Collins MA, Barth JH, Gough MJ. Jugular venous neurone specific enolase (NSE) increases following carotid endarterectomy under general, but not local, anaesthesia. *Eur J Vasc Endovasc Surg* 2009; **38**: 262–6
- 109 Ramakrishna H, Reidy C, Riha H, et al. The year in cardiothoracic and vascular anesthesia: selected highlights from 2012. *J Cardiothorac Vasc Anesth* 2013; **27**: 86–91
- 110 Markovic D, Vlajkovic G, Sindjelic R, Ladjevic N, Kalezic N. Cervical plexus block versus general anesthesia in carotid surgery: single center experience. *Arch Med Sci* 2012; **8**: 1035–40
- 111 Naylor AR, Sayers RD, McCarthy MJ, et al. Closing the loop: a 21-year audit of strategies for preventing stroke and death following carotid endarterectomy. *Eur J Vasc Endovasc Surg* 2013; **46**: 161–70

Handling editor: J. G. Hardman