

## FULL-LENGTH ORIGINAL RESEARCH

# Regional neocortical thinning in mesial temporal lobe epilepsy

\*†Carrie R. McDonald, †‡Donald J. Hagler, Jr., †‡Mazyar E. Ahmadi, §Evelyn Tecoma, §Vicente Iragui, †Lusineh Gharapetian, †‡§Anders M. Dale, and \*†‡§Eric Halgren

\*Department of Psychiatry, †Multimodal Imaging Laboratory, ‡Department of Radiology, and §Department of Neurosciences, University of California, San Diego, CA, U.S.A.

### SUMMARY

**Purpose:** To determine the nature and extent of regional cortical thinning in patients with mesial temporal lobe epilepsy (MTLE).

**Methods:** High-resolution volumetric MRIs were obtained on 21 patients with MTLE and 21 controls. Mean cortical thickness was measured within regions of interest and point-by-point across the neocortex using cortical reconstruction and parcellation software.

**Results:** Bilateral thinning was observed within frontal and lateral temporal regions in MTLE patients relative to controls. The most striking finding was bilateral cortical thinning in the precentral gyrus and immediately adjacent paracentral region and pars opercularis of the inferior frontal gyrus, extending to the orbital region. Within the temporal lobe, bilateral thinning was observed in Heschl's

gyrus only. Ipsilateral only thinning was observed in the superior and middle temporal gyri, as well as in the medial orbital cortex. Greater asymmetries in cortical thickness were observed in medial temporal cortex in patients relative to controls. Individual subject analyses revealed that this asymmetry reflected significant ipsilateral thinning of medial temporal cortex in 33% of patients, whereas it reflected ipsilateral thickening in 20% of MTLEs.

**Discussion:** Patients with MTLE show widespread, bilateral pathology in neocortical regions that is not appreciated on standard imaging. Future studies are needed that elucidate the clinical implications of neocortical thinning in MTLE.

**KEY WORDS:** Cortical thickness, Seizure disorders, Volumetric MRI, Cortical parcellation, Temporal lobe epilepsy (TLE).

Pathological changes to the hippocampus and other medial temporal lobe structures are well documented in patients with medial temporal lobe epilepsy (MTLE) (Dreifuss et al., 2001; Szabo et al., 2006). However, recent improvements in structural imaging have allowed for the detection of subtle abnormalities within neocortical regions in MTLE that are not revealed by standard MRI (Lee et al., 1998; Hermann et al., 2003; Oyegbile et al., 2004). In particular, studies using voxel-based morphometry (VBM) have demonstrated reductions in total and lobar gray matter density in patients with MTLE (Bernasconi et al., 2004; Oyegbile et al., 2006), and studies based on manual tracings have shown volumetric changes within

medial temporal cortex (Bernasconi et al., 2001; Jutila et al., 2001). Furthermore, PET studies have demonstrated interictal hypometabolism in temporal, frontal, and parietal cortex (Henry et al., 1993), and histopathological studies have confirmed areas of microdysgenesis in medial and lateral temporal neocortex of patients with MTLE (Hardiman et al., 1988; Eriksson et al., 2005). These studies demonstrate widespread brain pathology in patients with MTLE and support accumulating evidence that MTLE is not a disease limited to hippocampal pathology, but rather a disease affecting temporal and extratemporal neocortical regions.

To date, only a handful of studies have examined the quantitative and qualitative features of pathology across the entire neocortex of patients with MTLE (Cook et al., 1995; Lee et al., 1998; Oyegbile et al., 2004; Lin et al., 2007; Ronan et al., 2007). Oyegbile et al. (2004) reported changes in global gyral curvature, but they did not find reductions in mean cortical thickness. However, in their study, cortical thickness estimates were obtained by

Accepted January 4, 2008; Online Early publication xxxxxx.  
Address correspondence to Carrie R. McDonald, Multimodal Imaging Laboratory, 9500 Gilman Drive, La Jolla, CA 92093-0841, U.S.A. E-mail: camcdonald@ucsd.edu

averaging across the entire cortical surface, rather than within specific regions or point-by-point along the cortical ribbon. Therefore, the presence of regional changes in cortical thickness in their patients could not be established. To our knowledge, Lin et al. (2007) are the only investigators to have measured regional changes in cortical thickness in patients with MTLE. They reported up to 30% bilateral reductions in cortical thickness in multiple frontal, temporal, and occipital lobe regions in patients with MTLE relative to controls. In addition, they found that longer disease duration was associated with cortical thinning in superior frontal, parietal, and parahippocampal regions, suggesting that chronic MTLE is characterized by neocortical changes that are both progressive and region-specific.

These preliminary investigations provide evidence that (1) specific pathological changes are present in the neocortex of patients with MTLE that may include reductions in cortical thickness, and (2) neocortical thinning may result from cumulative years of seizure activity experienced by patients with MTLE. In addition, Lin et al. demonstrated that neocortical changes may be bilateral and region-specific. Thus, global measures of thickness may lack sensitivity and obscure group differences when areas of local thinning are averaged together with areas of normal cortical depth and architecture. One limitation of Lin et al.'s method for detecting regional changes is that it required manual tracings of sulci and gyri by trained image analysts. Such manual delineations are labor-intensive and require neuroanatomical expertise. Therefore, these methods are generally limited to use at major research institutions, but difficult to implement in mainstream clinical settings. Furthermore, manual techniques can be inaccurate if the MRI section is not strictly perpendicular to the local curvature in all planes, making thickness measurements problematic (Fischl & Dale, 2000).

In the present study, we evaluate *in vivo* cortical thickness across the entire cortical surface in patients with MTLE and age- and gender-matched healthy controls using a semiautomated approach that has been validated against manual tracings made on postmortem tissue (Rosas et al., 2002). Using this approach, the entire cortical surface is reconstructed in a topologically correct manner, enabling rigorous determination of the surface normal at each location, a prerequisite for principled cortical thickness measures. Cortical thickness was selected for analysis because it has proven to be useful in clarifying the nature of cortical pathology in patients with MTLE (Lin et al., 2007; Ronan et al., 2007) and other neurological diseases (Fischl & Dale, 2000; Rosas et al., 2002; Sailer et al., 2003). In addition, cortical thinning has been associated with important clinical features, including increased cognitive morbidity in Alzheimer's disease (Du et al., 2007) and disability in multiple sclerosis (Sailer et al., 2003), and may have similar clinical correlates in patients with MTLE.

## MATERIALS AND METHODS

### Participants

Participants in this investigation were 21 patients with MTLE (ages 21–54) and 21 age- and gender-matched healthy controls (ages 21–52). All patients were recruited from the University of California, San Diego, Epilepsy Center and were considered for enrollment if they were diagnosed with MTLE by a board-certified neurologist with expertise in epileptology, and were either undergoing or had previously completed preoperative evaluation for epilepsy surgery. Patients were classified according to video-EEG telemetry, seizure semiology, and neuroimaging results. In all 21 patients with MTLE, the diagnosis was based on the presence of ictal and interictal medial temporal-lobe epileptiform activity as monitored by video-EEG telemetry. In the majority of patients, scalp recordings were supplemented with sphenoidal electrodes. When necessary, patients underwent monitoring with five-contact foramen ovale electrodes to confirm mesial temporal onset. Diagnoses were supported in 16 of 21 patients by the presence of hippocampal atrophy and increased signal on T<sub>2</sub>-weighted images, consistent with mesial temporal sclerosis (MTS). In no case was there evidence of dual pathology on MRI. The remaining five patients showed no evidence of MTS based on visual inspection by a neuroradiologist. However, MRI volumetry demonstrated unilateral hippocampal volume loss (i.e., greater than 1.5 standard deviations below the mean volume of the controls) in 18 of the 21 patients. The remaining three patients showed strong evidence of unilateral mesial temporal lobe onset with foramen ovale electrode recordings (Velasco et al., 2006). Subjects with either an epileptic focus or radiological evidence of pathology outside the temporal regions were excluded. The sample of MTLE patients consisted of eleven patients with unilateral right MTLE and ten with unilateral left MTLE. Two patients with left MTLE were left-handed, as assessed by the Edinburgh Handedness Inventory (Oldfield, 1971). The study was approved by the Institutional Review Board (IRB) and each subject's consent was obtained in accordance with the ethical standards promulgated in the Declaration of Helsinki.

Twenty-one healthy participants were recruited through open advertisement. The control group consisted of 11 females and 10 males with no known history of neurological disorder, loss of consciousness, or serious medical or psychiatric condition. Two of the controls were left-handed. Table 1 displays demographic characteristics for the control and patient groups.

An independent *t*-test revealed no significant difference between the groups in age ( $t[40] = 1.4$ ;  $p > 0.05$ ). However, controls attained a higher level of education than patients with MTLE ( $t[40] = 4.7$ ;  $p < 0.05$ ). Due to the nonnormal distribution of the seizure-related variables, nonparametric tests were used to evaluate group

**Table 1. Demographic characteristics and epilepsy features of the MTLE and Control groups (standard deviations are in parentheses)**

	MTLE (N = 21)	Controls (N = 21)
Age (years)	37.3 (10.0)	33.0 (10.2)
Education	13.2* (2.2)	16.5 (2.3)
Gender (females/males)	11/10	11/10
Age at seizure onset (years)	14.3 (11.5)	—
Duration of illness (years)	23.0 (14.6)	—
Seizure frequency (per month)	6.7 (7.4)	—

\*Group mean is statistically different from that of controls at  $p < 0.05$ .

differences between patients with right versus left MTLE. Mann–Whitney U tests revealed no significant group differences between the right and left MTLE patients in illness duration ( $U = 1.7$ ,  $p > 0.05$ ), age of seizure onset ( $U = 1.3$ ,  $p > 0.05$ ), number of anticonvulsant medications ( $U = 1.89$ ,  $p > 0.05$ ), or seizure frequency ( $U = -1.0$ ,  $p > 0.05$ ).

## Procedure

### *MRI scanning and image processing*

Imaging was performed at the UCSD Radiology Imaging Laboratory on a General Electric 1.5T EXCITE HD scanner with an 8-channel phased-array head coil (General Electric, Waukesha, WI, U.S.A.). Image acquisitions included a conventional 3-plane localizer, GE calibration scan, and a  $T_1$ -weighted volume acquisition pulse sequence ( $TE = 3.8$  ms,  $TR = 10.7$  ms,  $TI = 1$  s, flip angle = 8 deg, bandwidth = 31.25 Hz/pixel, field of view (FOV) = 25.6 cm, matrix =  $256 \times 256$ , slice thickness = 1.0 mm). Acquisition parameters were optimized for increased gray/white matter image contrast. The imaging protocol was identical for all subjects studied. The image files in DICOM format were transferred to a Linux workstation for morphometric analysis. The two  $T_1$ -weighted images were rigid body registered to each other and re-oriented into a common space, roughly similar to alignment based on the AC-PC line. Images were corrected for nonlinear warping caused by nonuniform fields created by the gradient coils. Image intensities were corrected for spatial sensitivity inhomogeneities in the 8-channel head coil by normalizing with the ratio of a body coil scan to a head coil scan (using GE's standard calibration scan). Image intensities were further normalized and made uniform with the FreeSurfer (3.0.5) software package (<http://surfer.nmr.mgh.harvard.edu>).

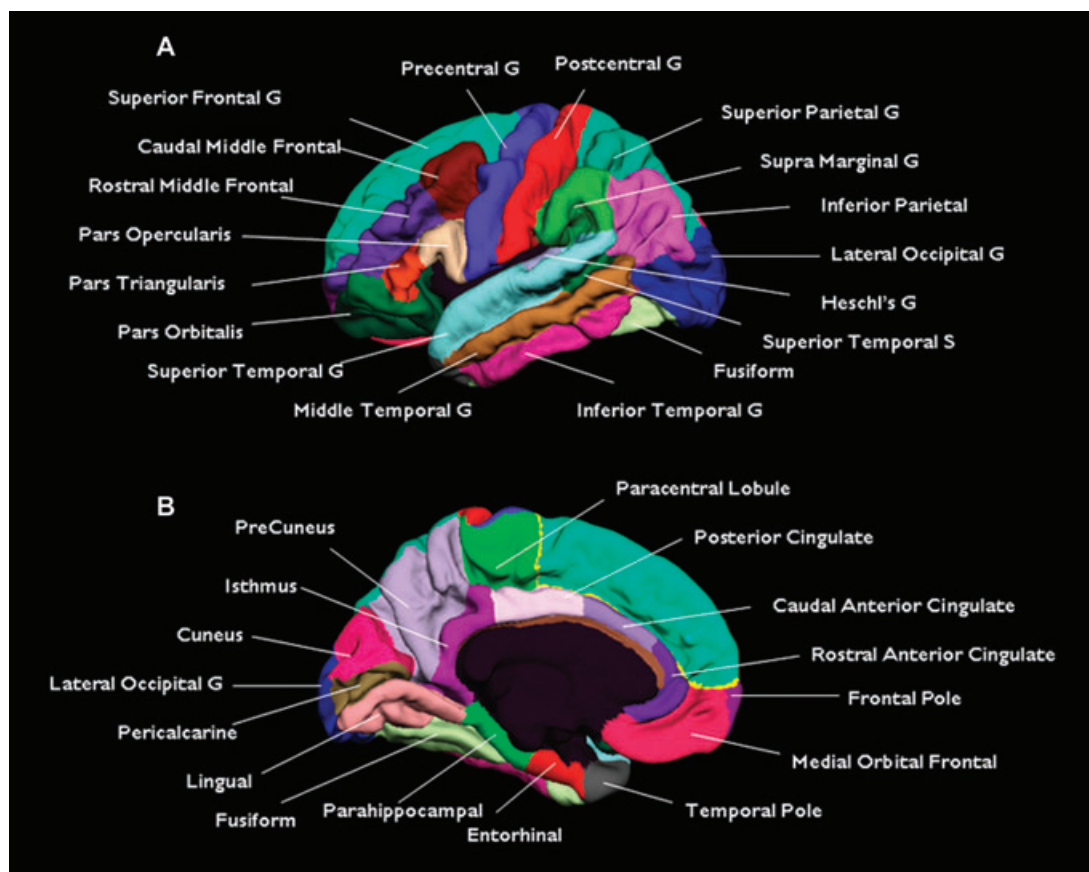
### *Surface reconstruction and parcellation*

The volumetric MRI scan was used to construct models of each subject's cortical surface using an automated procedure that involves (1) segmentation of the white matter, (2) tessellation of the gray/white matter boundary, (3) inflation of the folded surface tessellation, and (4) automatic correction of topological defects. These steps are described in detail elsewhere (Dale et al., 1999; Fischl et al., 1999, 2001). From this reconstructed surface, measures of cortical thickness were obtained using the procedure described by Fischl & Dale (2000). First, an estimate of the gray/white matter boundary was constructed by classifying all white matter voxels in the MRI volume. Then, the white matter surface was refined in order to obtain submillimeter accuracy in delineating the gray/white matter junction. The surface was then deformed outward to locate the pial surface (Dale et al., 1999). Estimates of cortical thickness were made by measuring (1) the shortest distance from each point on the white matter surface to the pial surface, and (2) the shortest distance from each point on the pial surface to the white matter surface. Cortical thickness at each vertex was computed as the average of the two values. Thickness measures were mapped to the inflated surface of each brain reconstruction, allowing the optimal visualization in both sulcal and gyral regions across the entire neocortex without being obscured by cortical folding. Sulcal and gyral features across individual subjects were aligned by morphing each subject's brain to an average spherical representation that allows for accurate matching of cortical locations among participants, while minimizing metric distortion. To improve the signal to noise ratio, data were then smoothed on the tessellated surface using a 10 mm full width half max Gaussian kernel.

Cortical thickness estimates were computed for gyral-based regions of interest (ROIs), lobar ROIs, and point by point across the cortical mantle. The gyral-based ROIs used in this study were derived from an automated labeling system that subdivides the cerebral cortex on volumetric MRI into 34 neuroanatomical regions per hemisphere (4 medial temporal, 5 lateral temporal, 11 frontal, 5 parietal, 4 occipital, and 5 cingulate; See Fig. 1). This method has been validated against manual tracings in healthy controls and is part of the publicly available FreeSurfer package. A detailed description of the development and validation of this labeling system is provided elsewhere (Desikan et al., 2006). Mean thickness for each gyral-based ROI was calculated by averaging the mean cortical thickness measurements at each vertex within a given ROI. Mean thickness for each lobar ROI was calculated as the weighted average of the thickness within each gyral-based ROI (mean regional thickness  $\times$  number of vertices for that region/total number of vertices).

### *Statistical analysis*

First, group differences between controls and patients with MTLE were analyzed using multivariate analysis



**Figure 1.**

Gyral-based regions of interest derived from an automated labeling system (Desikan et al., 2006). Labels are shown in color on the left lateral (**A**) and medial (**B**) pial surface. Key: G, gyrus; S, sulcus.

*Epilepsia* © ILAE

of variance (MANOVA) on mean thickness within the six lobar ROIs (frontal, medial temporal, lateral temporal, parietal, cingulate, and occipital). Follow-up analyses were performed within subregions when group differences were found for the lobe. Second, MANOVAs were performed to examine group differences in mean thickness for each region ipsilateral and contralateral to the seizure focus, as well as for the mean asymmetry within each region. In order to minimize the likelihood of Type I errors, an alpha level of 0.01 was adopted for all sub-region analyses in this study. Third, individual subject analyses were performed using linear, step-wise discriminant function analysis. Finally, linear regression was performed to determine the contribution of disease-related factors (i.e., duration of seizures, hippocampal atrophy, age of seizure onset, seizure frequency, and number of anticonvulsant medications) to cortical thickness in regions where patients showed significant thinning relative to controls.

## RESULTS

### Group differences in cortical thickness

#### *Group differences in cortical regions of interest*

A MANOVA on mean cortical thickness across the six cortical regions was significant (Wilks' Lambda;  $F[6, 35] = 2.57, p < 0.05$ ). Follow-up ANOVAs revealed that patients with MTLE showed cortical thinning in frontal ( $F[1, 41] = 7.09, p < 0.01$ ) and lateral temporal ( $F[1, 41] = 10.00, p < 0.005$ ) lobe regions relative to controls (see Table 2). No significant differences emerged between medial temporal, parietal, cingulate, or occipital lobe regions (all  $p$ -values  $> 0.05$ ). Univariate analysis within lateral temporal subregions revealed bilateral reductions in Heschl's gyrus in patients with MTLE. Within frontal regions, bilateral reductions were observed within paracentral, precentral, and pars opercularis cortex. In the left hemisphere only, cortical thinning was observed in the superior temporal gyrus, superior temporal sulcus, and medial



**Table 2. Regional cortical thickness (mm) in patients with MTLE and healthy controls**

Regions	Controls (N = 21)	MTLE (N = 21)
<b>Frontal</b>		
Average thickness	2.57 (0.125)	2.45 (0.152)**
Range	2.28–2.87	2.08–2.69
Percent asymmetry	1.51 (0.62)	1.16 (0.83)
Ipsilateral z-score <sup>a</sup>	—	−0.96 (1.20)**
Contralateral z-score	—	−0.86 (1.22)*
<b>Medial temporal</b>		
Average thickness	2.78 (0.105)	2.72 (0.172)
Range	2.54–2.97	2.32–2.84
Percent asymmetry	2.44 (1.72)	5.43 (2.06)*
Ipsilateral z-score	—	−0.62 (1.89)
Contralateral z-score	—	−0.40 (1.62)
<b>Lateral temporal</b>		
Average thickness	2.82 (0.094)	2.72 (0.109)**
Range	2.68–3.09	2.47–2.92
Percent asymmetry	2.05 (1.03)	2.08 (2.26)
Ipsilateral z-score	—	−1.16 (1.15)***
Contralateral z-score	—	−0.97 (1.36)**
<b>Parietal</b>		
Average thickness	2.25 (0.125)	2.18 (0.149)
Range	2.01–2.50	1.76–2.42
Percent asymmetry	1.88 (1.38)	2.40 (2.01)
Ipsilateral z-score	—	−0.65 (1.24)
Contralateral z-score	—	−0.57 (1.20)
<b>Occipital</b>		
Average thickness	1.84 (0.103)	1.82 (0.110)
Range	1.56–1.99	1.61–2.03
Percent asymmetry	2.46 (1.36)	2.30 (2.08)
Ipsilateral z-score	—	−0.15 (1.21)
Contralateral z-score	—	−0.18 (0.98)
<b>Cingulate</b>		
Average thickness	2.54 (0.125)	2.47 (0.142)
Range	2.32–2.94	2.14–2.64
Percent asymmetry	2.75 (2.48)	4.50 (4.10)
Ipsilateral z-score	—	−0.55 (1.42)
Contralateral z-score	—	−0.68 (1.12)

<sup>a</sup>Ipsilateral/contralateral scores are reported as z-scores derived from the control mean.  
 \*Mean is significantly different from controls at \* $p < 0.05$ ;  
 \*\* $p < 0.01$ ; \*\*\* $p < 0.001$ .

orbital cortex in patients with MTLE relative to controls. Within the right hemisphere only, cortical thinning was observed in the middle temporal gyrus and lateral orbitofrontal cortex (all  $p$ -values  $< 0.01$ ).

The ROI analyses were supplemented with point-by-point measures of thickness across the cortical surface. Mean difference maps were generated by aligning and then averaging across participants in spherical space (see Fig. 2) to demonstrate the mean cortical thickness differences (mm) between patients and controls at each point on the cortex. Consistent with the ROI analysis, these maps revealed bilateral cortical thinning in MTLE that is diffuse, but most prominent in frontal and lateral temporal cortex, especially in precentral and paracentral cortex. In addition,

these surface maps reveal areas of cortical thinning in parietal regions (i.e., inferior parietal lobule and postcentral gyrus) that were not significant in the ROI analysis at the lobar level.

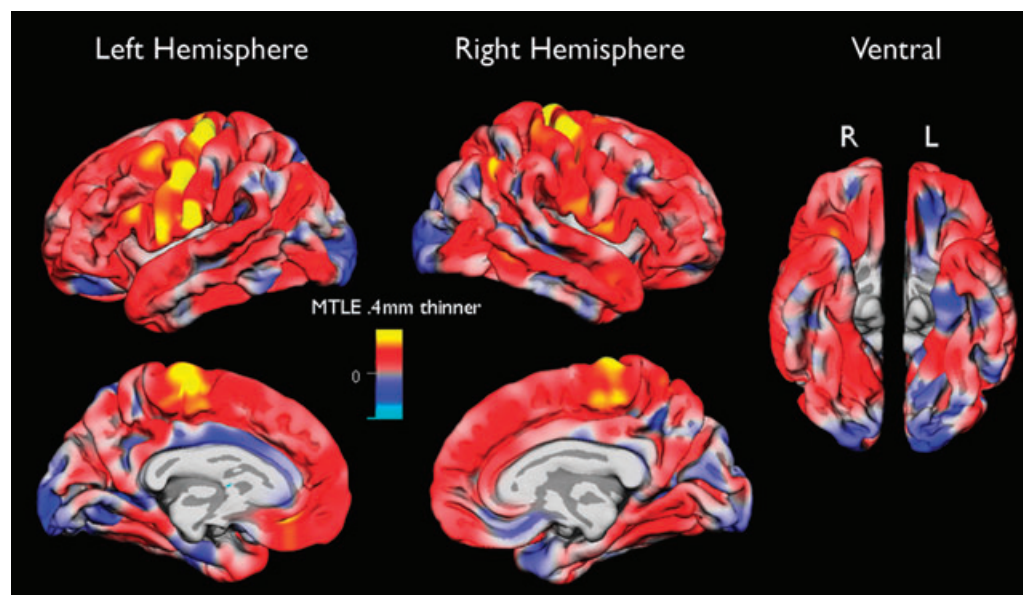
#### *Group differences in ipsilateral and contralateral cortical thickness*

To increase statistical power, data were pooled across hemispheres (ipsilateral and contralateral) to investigate whether or not the side of the seizure focus differentially affected patterns of cortical thickness. A MANOVA on the ipsilateral regions was highly significant ( $F[6, 35] = 3.42$ ,  $p < 0.005$ ). Univariate analysis revealed that patients with MTLE showed ipsilateral reductions within lateral temporal ( $F[1, 41] = 12.11$ ,  $p < 0.001$ ) and frontal ( $F[1, 41] = 7.81$ ,  $p < 0.001$ ) regions relative to controls. There was also a trend for patients with MTLE to have greater reductions in ipsilateral parietal cortex ( $F[1, 41] = 3.61$ ,  $p = 0.065$ ). Within the lateral temporal cortex, ipsilateral reductions were observed within superior and middle temporal gyri, as well as Heschl's gyrus in patients with MTLE relative to controls. Within frontal cortex, ipsilateral reductions were found within precentral, paracentral, medial orbital, and pars opercularis in MTLE compared to controls. The overall MANOVA on contralateral cortical thickness did not reach significance when all six regions were considered together ( $F[6, 35] = 2.75$ ,  $p = 0.085$ ). However, univariate analyses were performed to investigate the overall trend that emerged in the multivariate analysis. Significant, but less robust, reductions were found in contralateral lateral temporal ( $F[1, 41] = 7.00$ ,  $p < 0.01$ ) and frontal ( $F[1, 41] = 6.30$ ,  $p < 0.05$ ) regions. Within lateral temporal regions, contralateral reductions were observed within Heschl's gyrus only. Within frontal cortex, contralateral reductions were also observed in precentral, paracentral, and pars opercularis cortex. Figs. 3 and 4 show standardized scores (z-scores) derived from the mean of the controls for each ipsilateral and contralateral frontal and temporal lobe region in patients with MTLE.

MANOVA on the mean asymmetry across cortical regions was also significant ( $F[6, 35] = 3.14$ ,  $p < 0.01$ ) and revealed an asymmetry in medial temporal cortex ( $F[1, 41] = 4.72$ ,  $p < 0.05$ ), with patients showing a greater asymmetry than controls. However, univariate analyses did not reveal asymmetries within any specific subregion after correcting for multiple comparisons (i.e.,  $p < 0.01$ ).

#### **Discriminant function analysis**

In order to determine whether or not regional thinning could differentiate patients with MTLE from controls at the individual subject level, a linear, step-wise discriminant function analysis was performed. This approach considers the parameters that were selected in each previous step in order to obtain the best discrimination equation. A "leave-one-out" procedure was used to cross-validate the



**Figure 2.**

Mean thickness maps. The folded surface reconstruction (pial surface) demonstrates mean thickness differences (mm) between the Control and MTLE groups. The entire dynamic range of thinning is shown from yellow (areas of greatest thinning in MTLE) to blue (areas of thickening in MTLE). Full yellow corresponds to  $>0.4$  mm of thinning in the MTLE group.

*Epilepsia* © ILAE

model. In this procedure, each case in the analysis is classified by the functions derived from all cases other than that case. This procedure is optimal for applying the function to a new sample of cases and reducing the likelihood of any one case significantly biasing the model. Including each of the six lobar ROIs in the analysis, lateral temporal cortical thickness emerged as the only significant predictor ( $\chi^2 [1] = 8.8, p < 0.01$ ), successfully classifying 74% of both groups in the original and cross-validated samples (74% sensitivity and 74% specificity). These data suggest that lateral temporal cortical thinning differentiated MTLEs from controls at the individual subject level, and that approximately three-fourths of our patient sample showed significant thinning of the temporal neocortex relative to controls.

#### Disease-related predictors of reductions in neocortical thickness

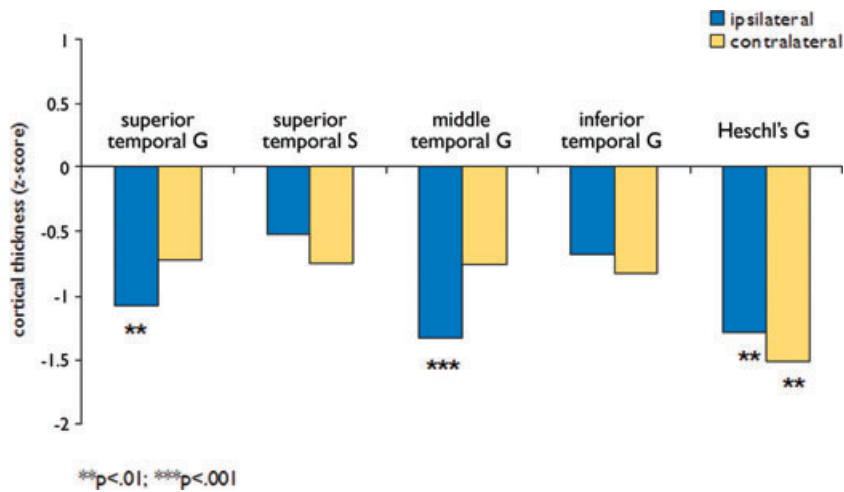
Linear regression was performed to determine if key disease-related variables (i.e., hippocampal volume, age of seizure onset, disease duration in years, number of anti-convulsant medications, or seizure frequency) predicted reductions in cortical thickness or increased cortical asymmetries in patients with MTLE relative to controls, after controlling for the effects of age. Results revealed that increased disease duration predicted reductions in right parietal thickness ( $b = -0.44, p < 0.05$ ). Analysis of right parietal subregions revealed that longer disease duration

was associated with reduction in the right inferior parietal lobule ( $b = -0.57, p < 0.01$ ) in MTLE patients relative to controls. No other disease-related variables emerged as significant predictors of regional cortical thinning in patients with MTLE.

## DISCUSSION

There is accumulating evidence that MTLE is a disease process that results in pathological changes to neocortical regions that are not detected using standard imaging techniques (Lee et al., 1998). These changes include reductions in cortical thickness that may be ipsilateral or bilateral to the seizure focus, as well as regional or diffuse. We conducted this study in order to determine the nature of cortical changes in patients with MTLE via an in vivo analysis of cortical thickness, and to investigate whether or not cortical thinning in MTLE was associated with any disease-specific characteristics. These goals were accomplished using semiautomated cortical reconstruction software that provides thickness measurements within gyral-based ROIs and point-by-point across the cortical surface.

The major finding in this investigation was the presence of bilateral reductions in cortical thickness within frontal and lateral temporal lobe regions, including Heschl's gyrus, frontal operculum, precentral, paracentral, and orbitofrontal regions in patients with MTLE compared to controls. However, cortical thinning was more robust



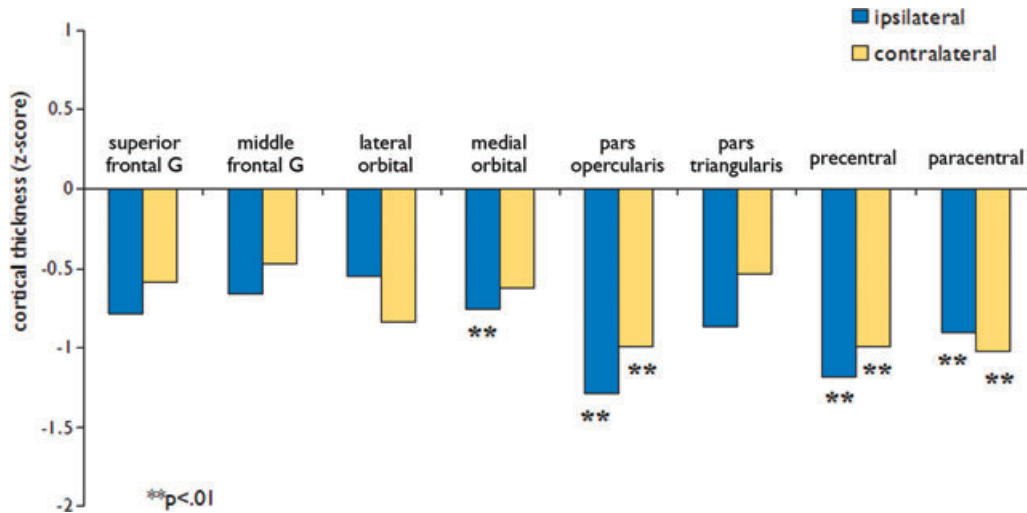
**Figure 3.**

Cortical thickness in ipsilateral and contralateral temporal lobe regions in patients with MTL. Bars represent standardized z-scores derived from the mean of the Control group. Key: G, gyrus; S, sulcus.

*Epilepsia* © ILAE

ipsilateral to the seizure focus, and this was especially the case within lateral temporal cortex. These data are concordant with previous research based on manual tracings demonstrating neocortical changes in patients with MTL in the temporal and frontal lobes bilaterally (Bonilha et al., 2007; Lin et al., 2007). Our findings are also commensurate with existing evidence that MTL is characterized by ictal and interictal disruptions within limbic-neocortical networks both neighboring and distant from the seizure focus (Van Paesschen et al., 2003; Tae et al., 2005). Cor-

tical thinning of neighboring areas (i.e., ipsilateral temporal) is supported by histological evidence of pathology in resected tissue (Nishio et al., 2000; Bothwell et al., 2001). In fact, recent studies have demonstrated that up to 48% of patients with MTL have microscopic structural abnormalities, including microdysgenesis and gliosis, within lateral temporal cortex. These abnormalities are assumed to be secondary to abnormal neuronal migration during development and atrophy from persistent seizures (Eriksson et al., 2005). Whether or not such pathology



**Figure 4.**

Cortical thickness in ipsilateral and contralateral frontal lobe regions in patients with MTL. Bars represent standardized z-scores derived from the mean of the Control group. Key: G, gyrus; S, sulcus.

*Epilepsia* © ILAE

contributes to the epileptogenesis of MTLE is yet to be established. Neocortical changes within more distant regions, including orbitofrontal and dorsolateral frontal cortex, has also been reported in previous investigations and attributed to the effects of chronic, epileptiform discharges propagating from the hippocampus to key areas within the frontal lobes (Keller et al., 2002a). Although the etiology of these changes has not been fully established, it is clear that frontal and lateral temporal lobe pathology is present in a sizable number of patients with MTLE. The current data reinforce the notion that refractory MTLE is a disease of both subcortical and cortical pathology and extend the literature by delineating the specific nature (i.e., cortical thinning) and distribution of cortical pathology in MTLE.

An unexpected and striking finding was the prominence of bilateral thinning in sensorimotor regions in patients with MTLE. Thinning within sensorimotor cortex in MTLE was recently reported by Lin et al. (2007) and is supported by a few VBM studies demonstrating decreased gray matter density in pre- and postcentral cortex (Keller et al., 2002b; Bonilha et al., 2006). Although the reasons for prominent thinning within these regions in our MTLE patients is unclear, previous studies have found an association between gray matter loss in the motor cortex and disease duration in MTLE (Bonilha et al., 2006). In addition, studies of patients with other movement disorders have established a relationship between sensorimotor thinning and both disease duration (Rosas et al., 2002) and increasing disability (Sailer et al., 2003). Furthermore, cerebral perfusion studies have revealed interictal hypoperfusion and ictal hyperperfusion in the precentral and paracentral cortex of patients with MTLE, indicating both structural and functional impairment to these regions (Van Paesschen et al., 2003; Tae et al., 2005). Given the presence of motor phenomena during many seizure types, it is conceivable that pathological changes would occur within these regions over time. Although we did not find a significant relationship between disease duration and sensorimotor thinning in our study, our data provide strong support that sensorimotor regions are structurally affected in MTLE, and that this effect is bilateral in nature.

Aside from structural differences between patients and controls, structural asymmetry within patients is of considerable value in the diagnosis of patients with MTLE. We found a significant asymmetry in medial temporal lobe thickness in patients with MTLE compared to controls. Despite this asymmetry, we did not find significant thinning within medial temporal lobe regions in patients relative to controls at the group level. It is of note that gray matter reductions in medial temporal lobe regions have been reported in some studies (Bernasconi et al., 2001; Jutila et al., 2001), whereas thickening has been reported in others (Keller et al., 2002a). Therefore, individual variability within this region may have eliminated any effect at the

group level. A post hoc analysis of individual patients revealed that 33% of the patients showed significant cortical thinning in the ipsilateral medial temporal lobe (defined by a  $z$ -score greater than 1.5 standard deviations below the mean of the controls), whereas 20% showed cortical thickening. By comparison, no patients showed thickening of ipsilateral or contralateral lateral temporal lobe regions. These data suggest greater variability within medial relative to lateral temporal cortex in patients with MTLE and indicate that perhaps the asymmetry within medial temporal lobe regions is a better indicator of pathology than the absolute level of thinning.

Although the clinical implications of regional cortical thinning in MTLE are not well established, previous research has linked reductions in cortical thickness to increased cognitive morbidity (Du et al., 2007) and disability (Sailer et al., 2003) in patients with other neurological diseases. In addition, VBM studies in patients with MTLE suggest that regional reductions in gray matter concentration are associated with poor seizure outcome and cognitive status. In particular, Keller et al. (2007) used VBM to study gray matter differences in left MTLE patients with good versus poor surgical outcomes. They found that compared to patients who were seizure-free, the preoperative MRIs of patients with persistent seizures showed reduced gray matter concentration in medial temporal and bilateral orbitofrontal cortex. In another recent study, Bonilha et al. (2007) demonstrated an association between bilateral orbitofrontal gray matter reductions and poor memory functioning. Other studies have revealed that widespread neocortical volume loss in MTLE is associated with global neuropsychological impairment (Baxendale et al., 1999; Hermann et al., 2003; Oyegbile et al., 2006). These studies provide evidence that subtle changes within neocortical regions may be an additional risk factor for poor cognitive status and seizure outcome in patients who otherwise appear to have focal disease and to be good surgical candidates. One limitation of VBM methods is that they may lack sensitivity at the individual subject level (Mehta et al., 2003). Our method for detecting regional cortical thinning showed sensitivity and specificity at the individual subject level and may offer a clinical advantage by delineating the degree and distribution of neocortical pathology in individual patients. Whether or not knowledge of neocortical thinning contributes to the preoperative evaluation of patients with MTLE requires further clarification of its relationship to clinical outcomes.

In this investigation, we provide data showing a distribution of cortical thinning in MTLE that is highly similar to that reported in a previous study based on manual tracings (Lin et al., 2007). However, one key difference is that the degree of cortical thinning found in our patients at the group level is quite modest (5–15%) compared to the reductions reported by Lin et al. (up to 30%). We propose several possible explanations for these differences.



First, Lin et al. only included patients with histologically confirmed MTS, who may have a greater overall burden of disease on MRI than those patients who are MTS-negative. The more modest reductions in cortical thinning found in our study may reflect the fact that we included patients with and without MTS. To test this hypothesis, we conducted a post hoc analysis that included only patients with visually detected MTS on MRI. This analysis resulted in negligible changes in the magnitude of regional cortical thinning. Rather, when only MTS-positive patients were included in the analysis, significant group differences also emerged in parietal cortex ( $F[1,36] = 4.5$ ,  $p < 0.04$ ). Therefore, neocortical changes in MTS-positive patients were characterized by a wider distribution of cortical thinning rather than increased regional thinning. Based on this analysis, we conclude that the presence/absence of MTS-positive patients is unlikely to account for the magnitude of the group differences between the studies. Another possible difference is that the control participants in Lin et al.'s study appear to have been somewhat younger (age range: 18–26) than their MTLE patients (age range: 18–48). Given that changes in cortical thickness have been identified by the third decade of life (Salat et al., 2004), it is possible that increased age contributed to group differences in cortical thickness in addition to the effects of the epilepsy disease process itself. Third, there are a number of instrument-related factors that have been shown to affect cortical thickness measurements based on MRI (Han et al., 2006). Therefore, it is possible that differences in the acquisition protocols, data processing, or postprocessing contributed to discrepancies between our results and those of Lin and colleagues. It is noteworthy that all participants in our study were scanned on the same scanner and with the same protocol and method of data processing. This consistency is important to the internal validity of our study in assessing differences between groups. However, the external validity of the study requires that our findings generalize to other centers and scanners. A large, multi-site study to determine the generalizability of our findings is underway.

Despite the theoretical and clinical value of our results, several limitations of the current study should be addressed. First, our patient sample was relatively small. As a result, our study may have been underpowered to detect subtle neocortical changes between groups in some regions that have been reported previously (i.e., anterior and medial temporal). Second, there are instrumentation-related limitations to our study that should be addressed. The precision of MRI-based measurements of cortical thickness is constrained by the contrast to noise ratio of the MRI image. In particular, gray to white matter contrast is known to vary across the cortex, and is particularly reduced in highly myelinated areas, including primary sensory cortices (Fischl & Dale, 2000). This issue deserves attention due to the prominent thinning noted within sensorimotor regions

both in our study and in previous investigations. However, it is of note that our finding of structural pathology within these regions is supported by a wealth of data demonstrating functional disturbances within sensorimotor regions in MTLE (Van Paesschen et al., 2003). Furthermore, in order to reduce the likelihood of such variations in image contrast, two structural volumes were acquired and averaged for all 42 participants in the study. Therefore, we believe that our findings represent true cortical thinning in MTLE rather than a methodological artifact. Finally, it is possible that diagnostic accuracy would increase even further by combining surface-based data on thickness with data from other structural and functional imaging techniques, including diffusion tensor imaging. Combining these structural measures would elucidate the degree to which regional cortical and white matter deterioration are associated or reflect distinct underlying degenerative processes in MTLE.

## CONCLUSION

We describe bilateral reductions in cortical thickness in patients with MTLE relative to healthy controls that are most pronounced in central, frontal, and lateral temporal regions. In addition, we demonstrate the ability of automated surface reconstruction and cortical parcellation software for detecting cortical thinning in specific regions at both the group and individual subject level. The degree to which these neocortical changes in MTLE provide meaningful data with regard to clinical outcome requires further investigation.

## ACKNOWLEDGMENTS

The project described was supported by Grant Number K23NS056091 from the National Institute of Neurological Disorders and Stroke. The content is solely the responsibility of the authors and does not necessarily represent the official views of the National Institute of Neurological Disorders and Stroke or the National Institute of Health. We also greatly acknowledge support from GE Healthcare.

Conflict of interest: We confirm that we have read the Journal's position on issues involved in ethical publication and affirm that this report is consistent with those guidelines. Eric Halgren has equity interest in CorTechs Labs, Inc, and also serves on its Board of Directors. Anders M. Dale is a founder and holds equity in CorTechs Labs, Inc and also serves on the Scientific Advisory Board. The terms of this arrangement have been reviewed and approved by the University of California, San Diego in accordance with its conflict of interest policies.

## REFERENCES

- Baxendale SA, Sisodiya SM, Thompson PJ, Free SL, Kitchen ND, Stevens JM, Harkness WF, Fish DR, Shorvon SD. (1999) Disproportion in the distribution of gray and white matter: neuropsychological correlates. *Neurology* 52:248–252.
- Bernasconi N, Bernasconi A, Caramanos Z, Dubeau F, Richardson J, Andermann F, Arnold DL. (2001) Entorhinal cortex atrophy in epilepsy patients exhibiting normal hippocampal volumes. *Neurology* 56:1335–1339.
- Bernasconi N, Duchesne S, Janke A, Lerch J, Collins DL, Bernasconi A. (2004) Whole-brain voxel-based statistical analysis of gray matter and white matter in temporal lobe epilepsy. *Neuroimage* 23:717–723.

- Bonilha L, Rorden C, Appenzeller S, Coan AC, Cendes F, Li LM. (2006) Gray matter atrophy associated with duration of temporal lobe epilepsy. *Neuroimage* 32:1070–1079.
- Bonilha L, Alessio A, Rorden C, Baylis G, Damasceno BP, Min LL, Cendes F. (2007) Extrahippocampal gray matter atrophy and memory impairment in patients with medial temporal lobe epilepsy. *Hum Brain Mapp* 28:1376–1390.
- Bothwell S, Meredith GE, Phillips J, Staunton H, Doherty C, Grigorenko E, Glazier S, Deadwyler SA, O'donovan CA, Farrell M. (2001) Neuronal hypertrophy in the neocortex of patients with temporal lobe epilepsy. *J Neurosci* 21:4789–4800.
- Cook MJ, Free SL, Manford MR, Fish DR, Shorvon SD, Stevens JM. (1995) Fractal description of cerebral cortical patterns in frontal lobe epilepsy. *Eur Neurol* 35:327–335.
- Dale AM, Fischl B, Sereno MI. (1999) Cortical surface-based analysis. I. Segmentation and surface reconstruction. *Neuroimage* 9:179–194.
- Desikan RS, Segonne F, Fischl B, Quinn BT, Dickerson BC, Blacker D, Buckner RL, Dale AM, Maguire RP, Hyman BT, Albert MS, Killiany RJ. (2006) An automated labeling system for subdividing the human cerebral cortex on MRI scans into gyral based regions of interest. *Neuroimage* 31:968–980.
- Dreifuss S, Vingerhoets FJ, Lazeyras F, Andino SG, Spinelli L, Delavelle J, Seeck M. (2001) Volumetric measurements of subcortical nuclei in patients with temporal lobe epilepsy. *Neurology* 57:1636–1641.
- Du AT, Schuff N, Kramer JH, Rosen HJ, Gorno-Tempini ML, Rankin K, Miller BL, Weiner MW. (2007) Different regional patterns of cortical thinning in Alzheimer's disease and frontotemporal dementia. *Brain* 130:1159–1166.
- Eriksson SH, Nordborg C, Rydenhag B, Malmgren K. (2005) Parenchymal lesions in pharmacoresistant temporal lobe epilepsy: dual and multiple pathology. *Acta Neurol Scand* 112:151–156.
- Fischl B, Sereno MI, Dale AM. (1999) Cortical surface-based analysis. II: Inflation, flattening, and a surface-based coordinate system. *Neuroimage* 9:195–207.
- Fischl B, Dale AM. (2000) Measuring the thickness of the human cerebral cortex from magnetic resonance images. *Proc Natl Acad Sci U S A* 97:11050–11055.
- Fischl B, Liu A, Dale AM. (2001) Automated manifold surgery: constructing geometrically accurate and topologically correct models of the human cerebral cortex. *IEEE Trans Med Imaging* 20:70–80.
- Han X, Jovicich J, Salat D, van der Kouwe A, Quinn B, Czanner S, Busa E, Pacheco J, Albert M, Killiany R, Maguire P, Rosas D, Makris N, Dale A, Dickerson B, Fischl B. (2006) Reliability of MRI-derived measurements of human cerebral cortical thickness: the effects of field strength, scanner upgrade and manufacturer. *Neuroimage* 32:180–194.
- Hardiman O, Burke T, Phillips J, Murphy S, O'Moore B, Staunton H, Farrell MA. (1988) Microdysgenesis in resected temporal neocortex: incidence and clinical significance in focal epilepsy. *Neurology* 38:1041–1047.
- Henry TR, Engel J Jr, Mazziotta JC. (1993) Clinical evaluation of interictal fluorine-18-fluorodeoxyglucose PET in partial epilepsy. *J Nucl Med* 34:1892–1898.
- Hermann B, Seidenberg M, Bell B, Rutecki P, Sheth RD, Wendt G, O'Leary D, Magnotta V. (2003) Extratemporal quantitative MR volumetrics and neuropsychological status in temporal lobe epilepsy. *J Int Neuropsychol Soc* 9:353–362.
- Jutila L, Ylinen A, Partanen K, Alafuzoff I, Mervaala E, Partanen J, Vapalahti M, Vainio P, Pitkanen A. (2001) MR volumetry of the entorhinal, perirhinal, and temporopolar cortices in drug-refractory temporal lobe epilepsy. *AJNR Am J Neuroradiol* 22:1490–1501.x
- Keller SS, Mackay CE, Barrick TR, Wiesmann UC, Howard MA, Roberts N. (2002a) Voxel-based morphometric comparison of hippocampal and extrahippocampal abnormalities in patients with left and right hippocampal atrophy. *Neuroimage* 16:23–31.
- Keller SS, Wiesmann UC, Mackay CE, Denby CE, Webb J, Roberts N. (2002b) Voxel based morphometry of grey matter abnormalities in patients with medically intractable temporal lobe epilepsy: effects of side of seizure onset and epilepsy duration. *J Neurol Neurosurg Psychiatry* 73:648–655.
- Lee JW, Andermann F, Dubeau F, Bernasconi A, Macdonald D, Evans A, Reutens DC. (1998) Morphometric analysis of the temporal lobe in temporal lobe epilepsy. *Epilepsia* 39:727–736.
- Lin JJ, Salamon N, Lee AD, Dutton RA, Geaga JA, Hayashi KM, Luders E, Toga AW, Engel J Jr, Thompson PM. (2007) Reduced Neocortical Thickness and Complexity Mapped in Mesial Temporal Lobe Epilepsy with Hippocampal Sclerosis. *Cereb Cortex* 17:2007–2018.
- Mehta S, Grabowski TJ, Trivedi Y, Damasio H. (2003) Evaluation of voxel-based morphometry for focal lesion detection in individuals. *Neuroimage* 20:1438–1454.
- Nishio S, Morioka T, Hisada K, Fukui M. (2000) Temporal lobe epilepsy: a clinicopathological study with special reference to temporal neocortical changes. *Neurosurg Rev* 23:84–89.
- Oldfield RC. (1971) The assessment and analysis of handedness: the Edinburgh inventory. *Neuropsychologia* 9:97–113.
- Oyegbile T, Hansen R, Magnotta V, O'Leary D, Bell B, Seidenberg M, Hermann BP. (2004) Quantitative measurement of cortical surface features in localization-related temporal lobe epilepsy. *Neuropsychology* 18:729–737.
- Oyegbile TO, Bhattacharya A, Seidenberg M, Hermann BP. (2006) Quantitative MRI biomarkers of cognitive morbidity in temporal lobe epilepsy. *Epilepsia* 47:143–152.
- Ronan L, Murphy K, Delanty N, Doherty C, Maguire S, Scanlon C, Fitzsimons M. (2007) Cerebral cortical gyrfication: a preliminary investigation in temporal lobe epilepsy. *Epilepsia* 48:211–219.
- Rosas HD, Liu AK, Hersch S, Glessner M, Ferrante RJ, Salat DH, van der Kouwe A, Jenkins BG, Dale AM, Fischl B. (2002) Regional and progressive thinning of the cortical ribbon in Huntington's disease. *Neurology* 58:695–701.
- Sailer M, Fischl B, Salat D, Tempelmann C, Schonfeld MA, Busa E, Bodammer N, Heinze HJ, Dale A. (2003) Focal thinning of the cerebral cortex in multiple sclerosis. *Brain* 126:1734–1744.
- Salat DH, Buckner RL, Snyder AZ, Greve DN, Desikan RS, Busa E, Morris JC, Dale AM, Fischl B. (2004) Thinning of the cerebral cortex in aging. *Cereb Cortex* 14:721–730.
- Szabo CA, Lancaster JL, Lee S, Xiong JH, Cook C, Mayes BN, Fox PT. (2006) MR imaging volumetry of subcortical structures and cerebellar hemispheres in temporal lobe epilepsy. *AJNR Am J Neuroradiol* 27:2155–2160.
- Tae WS, Joo EY, Kim JH, Han SJ, Suh YL, Kim BT, Hong SC, Hong SB. (2005) Cerebral perfusion changes in mesial temporal lobe epilepsy: SPM analysis of ictal and interictal SPECT. *Neuroimage* 24:101–110.
- Van Paesschen W, Dupont P, van Driel G, van Billoen H, Maes A. (2003) SPECT perfusion changes during complex partial seizures in patients with hippocampal sclerosis. *Brain* 126:1103–1111.
- Velasco TR, Sakamoto AC, Alexandre V Jr, Walz R, Dalmagro CL, Bianchin MM, Araujo D, Santos AC, Leite JP, Assirati JA, Carlotti C Jr. (2006) Foramen ovale electrodes can identify a focal seizure onset when surface EEG fails in mesial temporal lobe epilepsy. *Epilepsia* 47:1300–1307.