

## Remnant Pacemaker Lead Tips after Lead Extractions in Pacemaker Infections

Daehoon Kim, MD, Yong-Soo Baek, MD, Misol Lee, MD, Jae-Sun Uhm, MD, Hui-Nam Pak, MD, Moon-Hyoung Lee, MD, and Boyoung Joung, MD

*Division of Cardiology, Severance Cardiovascular Hospital, Yonsei University College of Medicine, Seoul, Korea*

Complete hardware removal is recommended in the case of patients with cardiovascular implantable electronic device (CIED) infections. However, the complete extraction of chronically implanted leads is not always achieved. The outcomes and optimal management of CIED infections with retained material after lead extractions have not been elucidated. In this case report, we present five patients with CIED infections with remnant lead tips even after lead extractions. Two patients had localized pocket infections, and were managed with antibiotics for a period of more than two weeks. The other three patients had infective endocarditis, and were managed with antibiotics for a period of more than four weeks. In one patient, the lead tip migrated to the right pulmonary artery, but did not produce any symptoms or complications. Only one of five patients experienced a resurgence of an infection. **(Korean Circ J 2016;46(4):569-573)**

**KEY WORDS:** Cardiac pacemaker, artificial; Infection; Device removal.

### Introduction

Cardiovascular implantable electronic devices (CIED) are extensively employed for arrhythmia and congestive heart failure.<sup>1)</sup> Simultaneously, there has been an associated increase in rate of CIED infections.<sup>2)</sup> CIED infections, frequently complicated by formation of vegetations on the intracardiac aspect of the leads and adjoining structures, including valvular leaflets, are associated with significant morbidity and mortality.<sup>3-4)</sup> In every single patient with CIED infections, complete device and lead removal with antimicrobial therapy is recommended.<sup>5)</sup> However, the extraction of chronically implanted transvenous lead systems remains a complex

procedure and is associated with considerable morbidity and mortality.<sup>6)</sup> Sometimes, there is fragmentation of leads which leads to failure of extraction of all of pacing leads.<sup>7)</sup> The fate of remnant lead materials is still controversial. A study<sup>8)</sup> suggested that the extraction of an entire lead might not be necessary, if the lead could be totally separated from an infected pocket. Meanwhile, several studies reported that the intracardiac portion of a lead might be colonized even in cases limited to localized pocket infections.<sup>9-11)</sup> In addition to the aspect of CIED infections, remnant lead fragments may cause mechanical complications such as embolization into the pulmonary arterial bed.<sup>7)12)</sup> This report describes cases of five patients with remnant lead tips after lead extraction for CIED infections and managed only by administration of antibiotics. This study was approved by the Institutional Review Board of Yonsei University Hospital.

### Case

Among 86 patients, who underwent lead removals for CIED infections between January 2000 to June 2015, a transvenous and a surgical lead removal was performed in 84 (98%) and two (2%) patients, respectively. Five patients had remnant lead tips (Fig. 1). The clinical features of these five patients are described below.

**Received:** September 6, 2015

**Revision Received:** October 23, 2015

**Accepted:** November 5, 2015

**Correspondence:** Boyoung Joung, MD, Division of Cardiology, Severance Cardiovascular Hospital, Yonsei University College of Medicine, 50-1 Yonsei-ro, Seodaemun-gu, Seoul 03722, Korea  
Tel: 82-2-2228-8460, Fax: 82-2-393-2041  
E-mail: cby6908@yuhs.ac

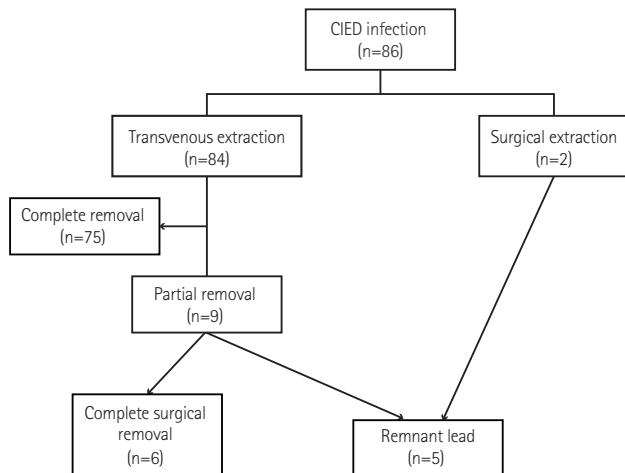
• The authors have no financial conflicts of interest.

This is an Open Access article distributed under the terms of the Creative Commons Attribution Non-Commercial License (<http://creativecommons.org/licenses/by-nc/3.0>) which permits unrestricted non-commercial use, distribution, and reproduction in any medium, provided the original work is properly cited.

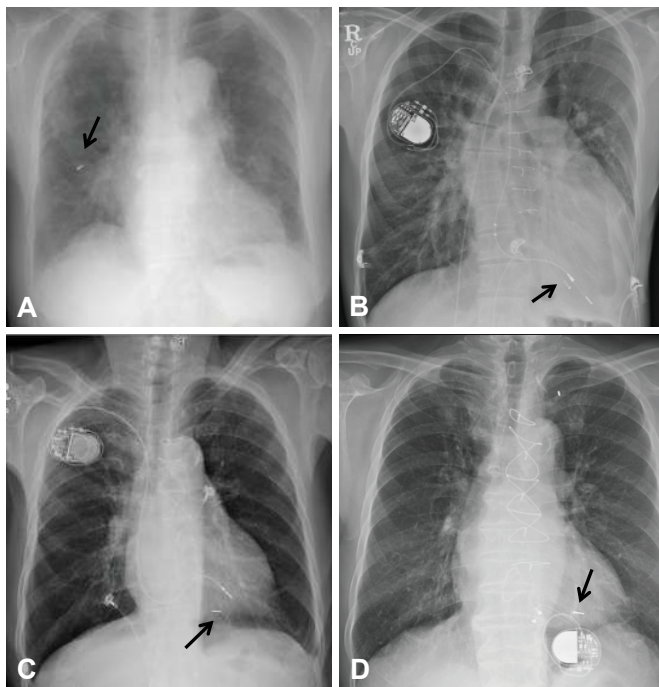
## Patients with localized pocket infections

### Case 1

A 93-year-old female was admitted for skin erosion at the site of the generator pocket (Patient 1 in Table 1-1). The patient



**Fig. 1.** Diagram representing the patients. CIED: cardiovascular implantable electronic device.



**Fig. 2.** Chest radiographs of four patients. (A) Embolization of the remnant lead tip (arrow) after lead extraction in Patient 1. (B) The remaining lead tip (arrow) after lead extraction in Patient 2. (C) The remnant lead tip (arrow) after lead extraction in Patient 3. A new pacemaker was implanted on the contralateral side. (D) The remnant lead tip (arrow) after lead extraction in Patient 4. A new epicardial pacemaker was implanted.

had undergone a permanent dual chamber (DDD) pacemaker implantation 10 years back for symptomatic sick sinus syndrome.

There was no evidence of a systemic infection. The patient underwent a transvenous lead removal initially using the direct traction and traction/counter-traction method with a locking stylet. The lead tip separated from the right ventricle (RV) lead during the extraction procedure (Patient 1 in Table 1-2). Two weeks after the extraction, the remnant RV lead tip embolized into the right middle pulmonary artery (Fig. 2A). There was no evidence of a pulmonary infarction or infection. During a 4-year follow up study, no adverse events were reported.

### Case 2

A 43-year-old male was referred for the left-sided generator exposure (Patient 2 in Table 1-1). The patient had Eisenmenger syndrome and right heart failure. The patient had undergone a DDD pacemaker implantation 31 years back for complete atrioventricular block, via the left subclavian vein. Due to a lead fracture of left sided DDD pacemaker, an atrial synchronous, ventricular demand (VDD) pacemaker was newly implanted via the right subclavian vein 10 years back. He was treated with oral antibiotics at the referring hospital for a week.

We tried a transvenous lead extraction of the DDD pacemaker. The left sided RV lead was separated at the middle part, and almost 10 cm of the RV lead was still present. To remove the remaining lead, transfemoral traction with a snare was used (Patient 2 in Table 1-2). However, we failed to remove the tip of the RV lead (Fig. 2B). Because of the unstable condition due to severe pulmonary hypertension, the procedure was terminated. The patient did not show any further evidence of infection and we decided to maintain the right sided VDD pacemaker. During 23-months of follow up, the patient has shown no evidence of infection or complications.

## Patients with systemic infections

### Case 3

A 77-year-old male was admitted for fever (Patient 3 in Table 1-1). The patient had undergone a DDD pacemaker implantation 18 years back for complete atrioventricular block. Transthoracic echocardiogram (TTE) revealed multiple vegetations (2.0 cm maximum) attached to the RV lead. The patient initially underwent a surgical lead extraction, considering large vegetations. The RV lead was not completely removed because of severe adhesion to the leaflet and chordae of the tricuspid valve. The proximal part of remaining RV lead in the left subclavian vein was removed by a transvenous approach (Patient 3 in Table 1-2). However, the tip of RV lead was left behind (Fig. 2C). A new pacemaker was implanted

via the right subclavian vein 14 days after the device removal (18 days after the blood cultures were confirmed to be negative). During 26-months of follow up, the patient has shown no evidence of infection or complications.

Case 4

A 69-year-old male was admitted for fever and chills (Patient 4 in Table 1-1). The patient had undergone a VDD pacemaker implantation 8 years back for symptomatic tachy-brady syndrome. TTE revealed vegetation (0.9x0.6 cm) attached to the right atrium (RA) lead and severe tricuspid

regurgitation (TR). The patient had to undergo a surgical lead extraction for simultaneous surgical correction of severe TR. The VDD lead was not completely removed because of severe adhesion to the chordae of the tricuspid valve. The proximal part of remaining VDD lead in the left subclavian vein was removed by a transvenous approach via the left subclavian vein (Patient 4 in Table 1-2). However, the VDD lead tip was still left behind (Fig. 2D). A pacemaker was implanted epicardially at the time of the initial surgical removal. There was no evidence of any resurgence of the infection after the completion of the antibiotic therapy, at the 36-months follow up.

Table 1-1. Baseline characteristics and clinical manifestation

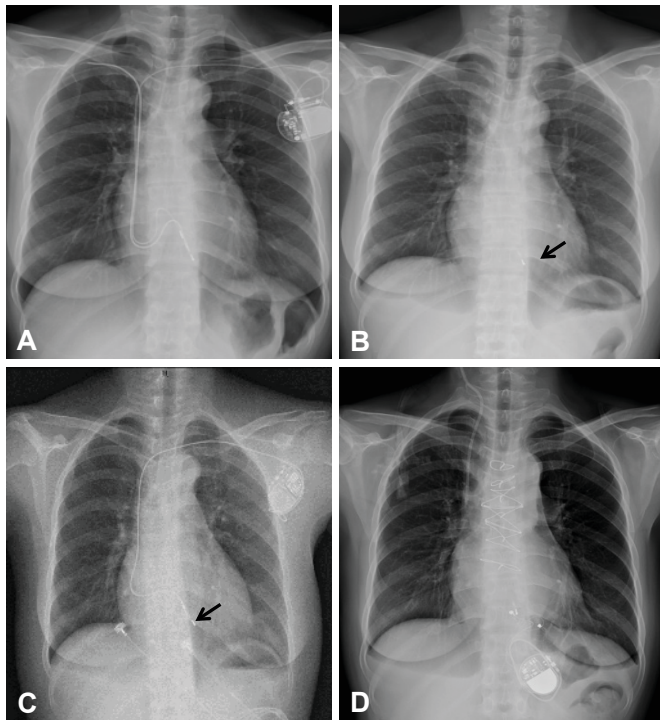
Patients	Sex	Age (years)	Type of device	Indication for the device	Lead type	Duration (years)	Type of infection	Organism	Echocardiography findings
1	Female	93	PPM (DDD)	SSS	A-screw, V-tined	10	Localized Pocket infection	Staphylococcus, coagulase negative (wound culture)	None remarkable
2	Male	43	PPM (DDD)	CAVB	A-screw (left), V-screw (left) VDD (right)	31 (left), 10 (right)	Localized Pocket infection	No organisms grown	None remarkable
3	Male	77	PPM (DDD)	CAVB	A-tined, V-tined	18	Systemic infection	MSSA (blood, wound culture)	Multiple vegetations (2.0 cm maximum) on the RV lead
4	Male	69	PPM (VDD)	TBS	VDD lead	8	Systemic infection	No organisms grown	Vegetation (0.9x0.6 cm) on the RA lead
5	Female	54	PPM (VVI)	CAVB	V-tined (left), V-tined (right)	11 (left) 22 (right)	Systemic infection	No organisms grown	Multiple vegetations (2.3 cm, 1.5 cm, 0.6 cm) on TV and IAS on the RA side

PPM: permanent pacemaker, DDD: dual chamber pacing, SSS: sick sinus syndrome, CAVB: complete atrioventricular block, VDD: atrial synchronous, ventricular demand pacing, TBS: tachy-brady syndrome, VVI: ventricular demand pacing, MSSA: methicillin-susceptible Staphylococcus aureus, RV: right ventricle, RA: right atrium, TV: tricuspid valve, IAS: interatrial septum

Table 1-2. Treatment and follow-up

Patients	Extraction Method	Retained lead: site	Antibiotics	Duration of the antibiotic treatment (IV/total days)	Day of the reimplantation (days after extraction)	FU (months)
1	DT/CT with a locking stylet	V lead tip: TV annulus	TEI → PO CFX	14/29	-	48
2	DT/CT with a locking stylet: Transfemoral traction with a snare kit	V lead tip: RV apex	VAN → PO AMP/SUL	8/14	- (maintain the right sided VDD lead)	23
3	Surgical removal: DT/CT with a locking stylet*	V lead tip: RV apex	VAN-GEN-RIF → NAF	43/43	14	26
4	Surgical removal: DT/CT with a locking stylet*	V lead tip: RV	TEI-LFX → PO AMP/SUL	29/36	0	36
5	DT/CT with a locking stylet: Transfemoral traction with a snare kit	V lead tip: RV apex	VAN-RIF → ARB	41/41	85	5

\*These 2 patients underwent surgery for the lead removal initially: but the atrial and ventricular leads could not be removed: and decision was made to perform a secondary lead removal via a transvenous approach. IV: intravenous, FU: follow up, DT: direct traction, CT: counter traction, V: ventricle, TV: tricuspid valve, RV: right ventricle, TEI: teicoplanin, PO: per os, CFX: cefixime, VAN: vancomycin, AMP/SUL: ampicillin/sulbactam, GEN: gentamycin, RIF: rifampin, NAF: nafcillin, LFX: levofloxacin, ARB: arbekacin



**Fig. 3.** Chest radiographs of patient 5. (A) The lead of the right sided pacemaker (generator removed previously): and the left sided VVI pacemaker. (B) The remnant lead tip (arrow) after lead extraction. (C) The remnant lead tip (arrow) and the VVI pacemaker implanted three months after lead extraction. (D) The newly implanted epicardial pacemaker after surgical removal. VVI: ventricular demand pacing.

### Case 5

A 54-year-old female was admitted due to continuous fever for a month (Patient 5 in Table 1-1). The patient had undergone a ventricular demand pacing (VVI) pacemaker implantation for complete atrioventricular block via the right subclavian vein 22 years back. Eleven years after initial implantation, the right-sided generator was removed for the generator exposure and a new VVI pacemaker was implanted via the left subclavian vein (Fig. 3A). At the time of admission, transesophageal echocardiogram (TEE) showed multiple and large (2.3 cm maximum) vegetations attached to the pacemaker leads, septum, and tricuspid valve. We tried to remove the pacemaker leads by the traction/countertraction method with a locking stylet. The left sided pacemaker lead was completely removed. The ventricular lead of the right sided pacemaker was fractured and removed by a transfemoral traction method with the aid of a snare kit (Patient 5 in Table 1-2). Unfortunately, the ventricular lead tip fragmented off and was left behind in the RV apex (Fig. 3B). A new VVI pacemaker was implanted three months after the lead extraction (Fig. 3C). A month after the new pacemaker implantation, the patient was admitted for fever. TEE showed presence of a new vegetation attached to the newly

implanted lead. The vegetation and the lead were removed by open heart surgery, and an epicardial pacemaker was newly implanted (Fig. 3D).

### Discussion

Because of the concerns over colonization and the higher risk of recurrence, the mainstay of CIED infection management has been established as the complete removal of the entire implanted device system in patients with device-related endocarditis, and also with only localized pocket infections.<sup>13-15</sup> Although the extraction procedure has matured into a defined art, the physicians still fail to remove all the components of an implanted system by the transvenous approach and even by the surgical approach. In patients with pocket infections, Love et al.<sup>9</sup> reported that extraction of an entire lead might not be necessary if the lead could be totally separated from an infected pocket. Also, a case of curing the infection through antibiotic administration alone has been reported.<sup>16</sup> However, the outcomes and optimal management of device-related endocarditis with retained material have not been elucidated. We experienced cases of two locally infected patients and three endocarditis patients with retained lead fragments after the device removal. All the remaining parts of their devices were RV lead tips. Considering that most CIED infections are due to staphylococcal species and some of the species would be methicillin resistant, vancomycin (Patients 2, 3, and 5) and teicoplanin (Patients 1 and 4), were administered to the patients as initial empirical antibiotics until the culture results were revealed. In the patients whose infections were limited to the pocket site (Patients 1 and 2); we continued the antibiotic treatment for over seven days with parenteral agents and for a total of 14 days. In patients with systemic infections, we continued the parenteral antibiotic therapy for at least 4 weeks. Neither locally infected patients nor systemically infected patients experienced any relapse of the infection during a median of 26-month follow up (range 5-48 months). For the CIED infection, in cases with remaining fragmented lead tips, we suggest that a conservative management with a sufficiently long, proper antibiotic treatment can be considered.

Only 1 out of 5 patients (Patient 1) had complications caused due to retaining material in our series. Development of pulmonary embolization of the remnant lead tip occurred, but there was no evidence of infection or pulmonary infarction, and the patient did not undergo any additional treatment during 48-months of follow-up.

Three patients (Patients 3, 4, and 5) underwent new pacemaker reimplantations and all those patients had systemic infections initially. Two patients showed no relapse of infections or other

complications after the reimplantation, suggesting that the remaining lead fragments were not an absolute contraindication for the implantation of a new intracardiac device. However, Patient 5 had relapsing fever a month after implantation of a new pacemaker. The patient had to undergo open heart surgery for complete removal of the remnant lead.

In conclusion, in the case of patients with remnant lead tips after a hardware removal for a CIED infection and with device-related endocarditis, conservative treatment with antibiotics without the retrieval of material can be a safe and effective way. One of five patients with retained lead tips in our series experienced pulmonary embolism, but neither there was an evidence of an infection nor occurrence of pulmonary infarction. Only one of five patients experienced resurgence of an infection.

## Acknowledgments

This study was supported in part by research grants from the Basic Science Research Program through the National Research Foundation of Korea funded by the Ministry of Education, Science and Technology (2012-0007604, 2012-045367), and a grant from the Korean Healthcare technology R&D project funded by Ministry of Health & Welfare (A121668).

## References

- Masoudi FA, Ponirakis A, Yeh RW, et al. Cardiovascular care facts: a report from the national cardiovascular data registry: 2011. *J Am Coll Cardiol* 2013;62:1931-47.
- Greenspon AJ, Patel JD, Lau E, et al. 16-year trends in the infection burden for pacemakers and implantable cardioverter-defibrillators in the United States 1993 to 2008. *J Am Coll Cardiol* 2011;58:1001-6.
- Victor F, De Place C, Camus C, et al. Pacemaker lead infection: echocardiographic features, management, and outcome. *Heart* 1999;81:82-7.
- Athan E, Chu VH, Tattevin P, et al. Clinical characteristics and outcome of infective endocarditis involving implantable cardiac devices. *JAMA* 2012;307:1727-35.
- Baddour LM, Epstein AE, Erickson CC, et al. Update on cardiovascular implantable electronic device infections and their management: a scientific statement from the American Heart Association. *Circulation* 2010;121:458-77.
- Wilkoff BL, Love CJ, Byrd CL, et al. Transvenous lead extraction: Heart Rhythm Society expert consensus on facilities, training, indications, and patient management: this document was endorsed by the American Heart Association (AHA). *Heart Rhythm* 2009;6:1085-104.
- Byrd CL, Wilkoff BL, Love CJ, Sellers TD, Reiser C. Clinical study of the laser sheath for lead extraction: the total experience in the United States. *Pacing Clin Electrophysiol* 2002;25:804-8.
- Love CJ, Wilkoff BL, Byrd CL, et al. Recommendations for extraction of chronically implanted transvenous pacing and defibrillator leads: indications, facilities, training. North American Society of Pacing and Electrophysiology Lead Extraction Conference Faculty. *Pacing Clin Electrophysiol* 2000;23(4 Pt 1):544-51.
- Darouiche RO. Treatment of infections associated with surgical implants. *N Engl J Med* 2004;350:1422-9.
- Klug D, Wallet F, Kacet S, Courcol RJ. Detailed bacteriologic tests to identify the origin of transvenous pacing system infections indicate a high prevalence of multiple organisms. *Am Heart J* 2005;149:322-8.
- Klug D, Wallet F, Lacroix D, et al. Local symptoms at the site of pacemaker implantation indicate latent systemic infection. *Heart* 2004;90:882-6.
- Robinson T, Oliver J, Sheridan P, Sahu J, Bowes R. Fragmentation and embolization of pacemaker leads as a complication of lead extraction. *Europace* 2010;12:754-5.
- Baddour LM, Bettmann MA, Bolger AF, et al. Nonvalvular cardiovascular device-related infections. *Circulation* 2003;108:2015-31.
- Chua JD, Wilkoff BL, Lee I, Juratli N, Longworth DL, Gordon SM. Diagnosis and management of infections involving implantable electrophysiologic cardiac devices. *Ann Intern Med* 2000;133:604-8.
- Sohail MR, Uslan DZ, Khan AH, et al. Management and outcome of permanent pacemaker and implantable cardioverter-defibrillator infections. *J Am Coll Cardiol* 2007;49:1851-9.
- Turkishier V, Priel I, Dan M. Successful management of an infected implantable cardioverter defibrillator with oral antibiotics and without removal of the device. *Pacing Clin Electrophysiol* 1997;20(9 Pt 1):2268-70.