

---

## REVIEW

# *Renal biopsy for medical renal disease: indications and contraindications*

Jathin Bandari, MD, Thomas W. Fuller, MD, Robert M. Turner II, MD,  
Louis A. D'Agostino, MD

Department of Urology, University of Pittsburgh Medical Center, Pittsburgh, Pennsylvania, USA

---

BANDARI J, FULLER TW, TURNER II RM, D'AGOSTINO LA. Renal biopsy for medical renal disease: indications and contraindications. *Can J Urol* 2016;23(1):8121-8126.

**Introduction:** Percutaneous renal biopsy (PRB) is a safe and effective modality for sampling kidney tissue. In limited circumstances, alternative methods for kidney biopsy may be indicated. Historical contraindications for PRB such as bleeding diathesis, morbid obesity and solitary kidney have been called into question in the literature. We present a review of the literature on PRB and the risks and benefits associated with alternatives.

**Materials and methods:** A review of the literature was performed through MEDLINE and PubMed. A total of 726 articles exist under the query, "percutaneous renal biopsy." Large series describing indications, contraindications, procedural methods, and complications were extracted. To further investigate the risks of percutaneous renal biopsy on solitary kidneys, the literature on percutaneous

nephrolithotomy (PCNL) and biopsy of transplant kidneys were queried. Summaries of the data were compiled and synthesized in the body of the text.

**Results:** Percutaneous renal biopsy is safe and effective in the majority of kidney units for the evaluation of medical renal disease. Rates of bleeding range from 0.3%-7.4%, and nephrectomy rates are exceedingly low (0.1%-0.5%). Bleeding rates in open and laparoscopic approaches are comparable and range from 0%-7.0%, with major complications ranging from 0%-6.1%.

**Conclusions:** The successes of percutaneous methods have called into question traditional contraindications such as solitary kidney, bleeding diathesis, and morbid obesity. In limited cases, alternative methods may be appropriate. We present a review of the literature for the various approaches and their associated complication rates.

**Key Words:** percutaneous renal biopsy, open renal biopsy, laparoscopic renal biopsy, transjugular renal biopsy

---

## Introduction

Since its introduction in 1951, percutaneous renal biopsy has become an integral part of the clinical practice in nephrology and subsequently revolutionized the management of kidney disease.<sup>1</sup> Information garnered from histologic examination of renal tissue may be useful in the diagnosis, prognostic assessment, and therapy guidance of renal disease. Despite the value of tissue diagnosis, not all patients are candidates for percutaneous biopsy. Historically, absolute contraindications have included solitary kidney or bleeding diathesis, prompting referral to urologists for consideration of alternative means of renal biopsy. Classically described contraindications are increasingly being

challenged with improvements in the technique and safety of percutaneous biopsy. We review biopsy techniques including open and laparoscopic surgical approaches and modern relative and absolute contraindications.

## Indications for renal biopsy

Indications for renal biopsy vary amongst nephrologists. Common precipitants for renal biopsy include idiopathic nephritic and nephrotic syndromes, diagnosis of unknown primary lesions, and the evaluation of small renal masses.<sup>2</sup> In contrast to the variation in indications, there is consensus regarding clinical scenarios in which renal biopsy is not indicated, including the evaluation of non-nephrotic proteinuria and isolated glomerular hematuria. Renal biopsy is also unnecessary in cases of slowly progressive renal failure with a known etiology such as diabetes mellitus, hypertension or acute renal failure with an obvious antecedent event such as hypotension.<sup>3</sup>

---

Accepted for publication October 2015

Address correspondence to Dr. Jathin Bandari, 3471 Fifth Avenue, Suite 700, Pittsburgh, PA 15213 USA

Widespread use of renal biopsy for small renal masses has been limited by the perception that there is a high risk of tumor seeding in the percutaneous tract, bleeding complications when biopsying a hypervascular tumor, and a historically low diagnostic certainty with low negative predictive value. Multiple series of percutaneous renal mass biopsies have recently been published providing growing clinical experience to more accurately define the usefulness, yield, and clinical utility of small renal mass biopsies.<sup>4-7</sup>

## Contraindications

Absolute contraindications to percutaneous renal biopsy have historically included uncontrolled severe hypertension, inability to cooperate with biopsy, solitary kidney, and uncontrollable bleeding diathesis. Relative contraindications include severe azotemia, renal anatomical abnormalities, anticoagulation, pregnancy, and urinary tract infections.<sup>8</sup> It is rare that hypertension cannot be controlled to an extent where biopsy cannot be pursued, and a patient unable to comply can have biopsy performed under sedation or general anesthesia.

### *Solitary kidney*

Traditionally, biopsy of a solitary kidney has been avoided out of concern that post-biopsy hemorrhage could result in the need for nephrectomy. Studies performed on patients with solitary kidneys are limited; however, those performed on carefully selected cohorts have been successful.<sup>9</sup> In this study, nine patients were deemed "low risk" for hemorrhage, meeting the criteria of adequate control of blood pressure (< 170/90 mm Hg), normal platelet count, prothrombin time, partial thromboplastin time, hematocrit greater than 30%, and a normal-sized solitary kidney. Eight of the nine biopsies retrieved adequate tissue sampling, and only one patient developed transient gross hematuria. There were no other complications reported. While open renal biopsy has been advocated in solitary kidneys due to the purported benefit of direct hemostasis, the low rate of bleeding complications and nephrectomy in patients with bilateral kidneys undergoing percutaneous biopsy suggests that this concern is overstated. In a review of 19,459 percutaneous renal biopsies from 1951-1990 an overall complication rate of 2.1% to 10.8% was reported.<sup>10</sup> Nephrectomy was only required on 13 occasions (0.06%). In a more recent meta-analysis of 34 studies, including 8941 biopsies performed in the era of ultrasound-guidance and automated biopsy devices, only one nephrectomy was required for life-

threatening hemorrhage. In the same study only 0.9% of patients required blood transfusion.<sup>11</sup>

Urologic experience with percutaneous nephrolithotomy (PCNL) suggests that percutaneous access and even subsequent dilation are safe in patients with a solitary kidney.<sup>12-14</sup> The Clinical Research Office of Endourological Studies (CROES) database evaluated 5803 patients undergoing PCNL, of whom 189 (3.3%) had solitary kidneys.<sup>15</sup> Though bleeding rates were similar in the solitary kidney group versus those with two kidneys (10.2% versus 7.7%), patients with solitary kidneys received twice as many transfusions. This may be due to physician variability in management of patients with solitary kidneys undergoing PCNL or compensatory hypertrophy of the solitary kidney resulting in increased severity of bleeding.<sup>16</sup>

Long term functional outcomes after PCNL in solitary kidneys have been excellent. At 3 year follow up, a study of 200 patients with solitary kidneys undergoing PCNL showed an improvement in creatinine to 1.83 from baseline of 2.0.<sup>17</sup> Thirty-one percent of patients showed improved eGFR, 53.5% had stationary eGFR, and 15.5% showed deterioration. Only one patient developed end-stage renal disease requiring hemodialysis. Importantly, nephrostomy tracts do not appear to have an effect on long term function of kidneys on <sup>99m</sup>Tc-Dimercaptosuccinic Acid (DMSA) scans in either single-functioning or double-functioning kidney systems after PCNL.<sup>18,19</sup>

Percutaneous renal biopsy is routinely performed in transplanted allografts for evaluation of graft dysfunction. Wilczek published a series of 1129 biopsy specimens between 1974 and 1988. Only 0.7% of patients required transfusion.<sup>20</sup> Biopsies within the medulla were associated with an increased risk of bleeding. This study was performed without radiographic aid, and modern techniques have served to mitigate this risk. A recent series evaluating 282 renal transplant surveillance biopsies similarly reported no major complications, including hemorrhage or need for allograft nephrectomy.<sup>21</sup>

Despite these reassuring data, undertaking a solitary kidney biopsy remains an important decision that should be made only after carefully thinking about whether the renal biopsy is likely to have important therapeutic implications. In the cohort of patients that do have complications, management can be considerably more difficult than in those with two native kidneys.<sup>22</sup> For example, arterial complications such as arteriovenous fistula, arteriocalyceal fistula, aneurysm, pseudoaneurysm or perinephric hematoma may require contrasted CT scan in the early arterial phase for diagnosis. Superselective renal angiography remains

the gold standard for treatment of uncontrolled bleeding and the physician should consider the effects of contrast on a solitary kidney when these complications do occur.

### *Bleeding diathesis*

Bleeding is a relatively common complication of renal biopsy ranging from transient gross hematuria (1%-10%) and self-limited perinephric hematoma (10%-90%) to major bleeding requiring transfusion (0.3%-7.4%) and possible nephrectomy (0.1%-0.5%).<sup>11,23</sup> Multiple factors, both procedural and patient specific, have been identified that increase a patient's risk of bleeding complications. Patient specific variables that increase the risk of post-biopsy bleeding include elevated serum creatinine (> 2 mg/dL), hypertension (> 140 systolic, > 90 diastolic), female gender, low prebiopsy hemoglobin (< 12 gm/dL) and biopsy for acute kidney injury.<sup>11,24,25</sup> Potentially modifiable procedural risks decrease hemorrhagic complications include the use of a 16- or 18-gauge needle instead of 14-gauge and the use of real-time ultrasound with an automated biopsy device.<sup>11</sup>

Patients with clotting disorders, thrombocytopenia, and those on anticoagulants or antiplatelets are inherently at higher risk of bleeding complications after percutaneous renal biopsy. Prior to biopsy patients should universally be evaluated with a thorough history of personal and family bleeding disorders. Laboratory evaluation should include hemoglobin and hematocrit, prothrombin time (PT), and partial thromboplastin time (PTT). Bleeding time has not been shown to be predictive and is not recommended.<sup>26</sup>

Thrombocytopenia < 50,000/microL is a standard cut off for transfusion prior to surgical intervention. Many nephrologists have suggested 100,000/microL is a more appropriate cut off for percutaneous renal biopsy considering platelet dysfunction with uremia and the inability to provide direct hemostasis. Efforts have been made to correct the effect of uremia on platelets. Whereas, estrogen, cryoprecipitate (containing fibrinogen, von Willebrand factor, and factors VIII/XIII), and erythropoietin have been shown to improve uremic bleeding, desmopressin (DDAVP) is the most commonly used agent. It rapidly corrects platelet dysfunction in uremia by releasing factor VIII. Despite the theoretical advantage, DDAVP and other pharmacologic correction have not been shown to significantly improve bleeding outcomes after percutaneous renal biopsy but may be warranted in high risk patients with significantly diminished glomerular filtration rates (GFRs).<sup>23</sup>

Antiplatelets ideally should be stopped 5 to 7 days prior to biopsy and not restarted for 48 hours after

the procedure but this decision must be balanced against the risk of cessation especially in the setting of new coronary stents or individuals at high risk of acute coronary syndrome. Prospective studies have identified an increased risk of minor complication (31% versus 12%) with continuing antiplatelet therapy but not of major complications. A large meta-analysis of 34 studies failed to show an increased transfusion rate when performing biopsy in the setting of active antiplatelet therapy.<sup>11,23,27,28</sup>

Ideally, fully anticoagulated patients should be instructed to hold anticoagulation in order to normalize their coagulation factors. Cessation of anticoagulation must be weighed against the possibility of thrombosis specific to their underlying need for anticoagulation (atrial fibrillation, mechanical valve, etc.). Bridging regimens may include the use of IV heparin or subcutaneous low molecular weight heparin. In the case of warfarin the international normalized ration (INR) should return to < 1.5 prior to biopsy. Heparin should be held 6 hours pre-procedurally to ensure a normalized PTT and 24 hours post-procedurally.<sup>24</sup> In the event anticoagulation cannot be temporarily stopped and biopsy is mandatory open surgical biopsy may be considered.<sup>3</sup>

### *Obesity*

Though there are no direct studies directly measuring complication rates in the obese patient, it is largely assumed that poor ultrasound visualization would result in higher bleeding risk.<sup>29</sup> This has resulted in alternative methods for tissue sampling, such as open, laparoscopic, and transjugular approaches. It has been proposed that placing the patient in the lateral decubitus position could mitigate the need for such alternatives.<sup>30</sup> Further investigation is needed in this specific patient population.

## Alternatives to percutaneous renal biopsy

### *Open renal biopsy*

The classical approach to open renal biopsy was first described in 1923, and later modified with progressively smaller subcostal incisions.<sup>31</sup> While generally regarded as a safe procedure, open renal biopsy is often performed in patients with significant comorbidities, and as such, is associated with significant postoperative morbidity. Patil et al retrospectively reviewed the outcomes of uremic patients who underwent open renal biopsy and reported high rates of pulmonary complications (15%), need for perioperative transfusion (15%), and postoperative wound infection (6%).<sup>32,33</sup> A contemporary series evaluating 115 patients with significant comorbidities

TABLE 1. Series of open and laparoscopic renal biopsies and their associated complications

Study	N	Approach	Major (%)	Minor (%)	EBL (cc)	Transfusion (%)	Intraoperative (%)
Stec et al <sup>33</sup>	115	Open	6.1	27.0	N/A	7.0	5.2
Finan et al <sup>45</sup>	50	Open	0.0	4.0	< 50	0.0	0.0
Nomoto et al <sup>46</sup>	934	Open	0.0	1.1	N/A	0.0	0.0
Gonick & Grau <sup>47</sup>	202	Open	2.0	0.0	N/A	1.0	2.0
Micali et al <sup>36</sup>	14	Single site laparoscopic	0.0	0.0	< 50	0.0	0.0
Repetto et al <sup>38</sup>	40	Laparoscopic	2.5	7.5	N/A	0.0	0.0
Gaur et al <sup>48</sup>	17	Laparoscopic	0.0	5.9	N/A	0.0	5.9
Shetye et al <sup>39</sup>	74	Laparoscopic	1.4	18.9	67	0.0	4.0

who underwent open biopsies between 1991 and 2006 reported an overall complication rate of 31.3%, of which there was 1 (0.8%) mortality, 7 (6.1%) major complications, and 31 (27%) minor complications. The transfusion rate was 7%. Though this study did not separate data for open incisions and laparoscopic incisions, the majority of cases (87%) were open.<sup>33</sup>

### Laparoscopic renal biopsy

Laparoscopic renal biopsy (LRB) was first described in human subjects in 1991 by Squadrito and Coletta.<sup>34</sup> The initial descriptions utilized three laparoscopic ports, however the procedure may also be performed with two-site and single-site approach.<sup>35,36</sup> The decision of which kidney to biopsy may vary. A right-handed surgeon may be more comfortable approaching the right kidney, whereas the lower positioning of the left kidney may provide more working-room and better angles. After exposure of a 2 cm<sup>2</sup> area of the lower pole, an 18G Trucut needle or laparoscopic biopsy forceps are generally used to obtain tissue. Hemostasis may be achieved with bipolar cautery or argon laser. The surgeon may place oxidized cellulose, fibrin glues, matrix hemostatic sealant, or other surgical adhesives over the biopsy site(s).

Retroperitoneal laparoendoscopic single-site surgery (LESS) has been described in an ongoing attempt to reduce morbidity and scarring associated with laparoscopic surgery. Early studies have demonstrated the feasibility of LESS in a variety of urological procedures.<sup>37</sup> Initial attempts at single-site renal biopsies were limited by poor visualization due to a single trocar, with later success achieved with the advent of the single-site multiple-port trocars.<sup>37</sup> In the single-site approach, access is generally obtained through a 10-mm transverse incision between the iliac crest and the tip of the 12<sup>th</sup> rib in the posterior axillary line. Micali

et al describe a 100% success rate in obtaining tissue specimen, with no complications and minimal blood loss.<sup>36</sup> Mean operative time was 53 minutes.

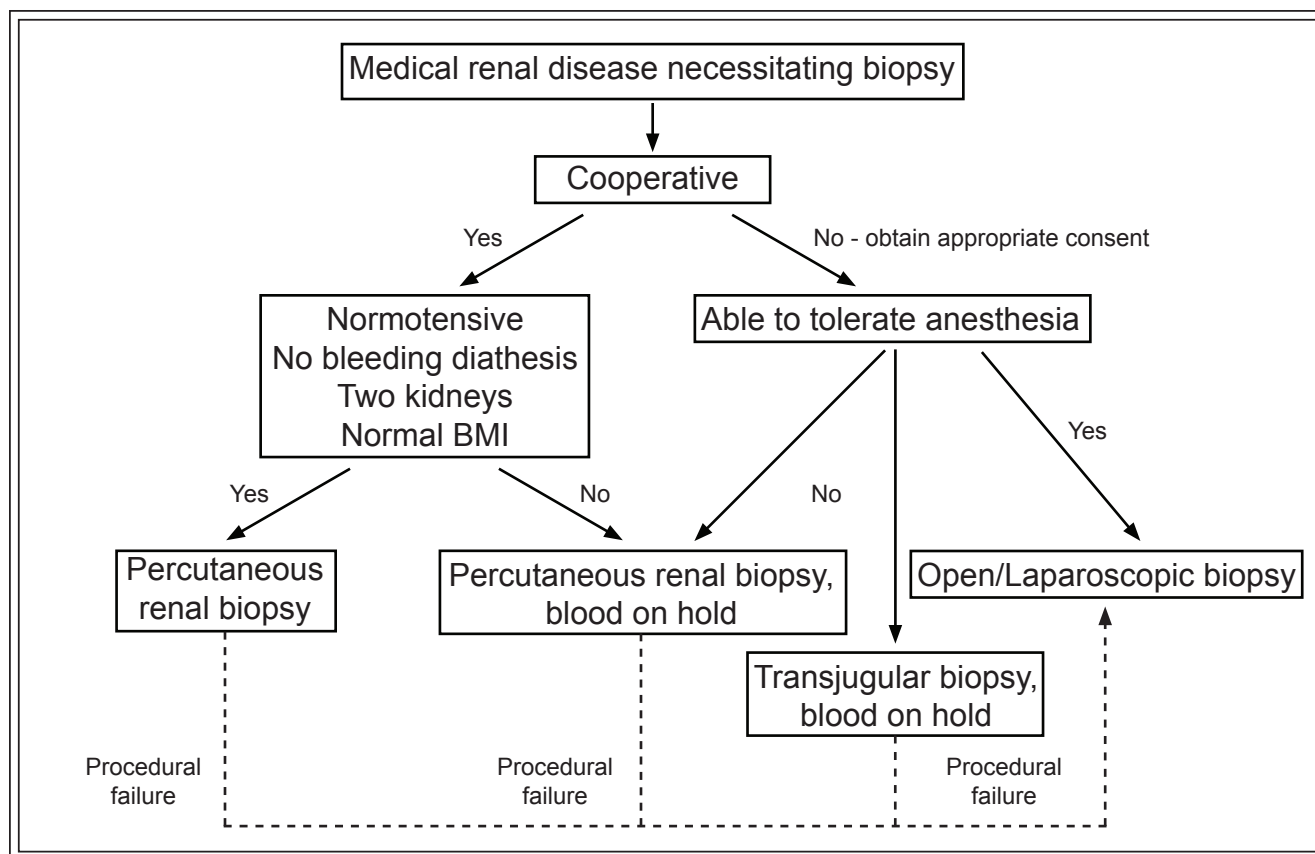
Repetto described a modified “ready-to-laparo” technique in carefully selected thin patients with superficial kidneys.<sup>38</sup> Dissection begins with a 10-mm incision at the tip of the 11<sup>th</sup> or 12<sup>th</sup> rib and blunt dissection through the muscular layers. If Gerota’s fascia is identified, trocar placement is deferred, and the lower pole is exposed through blunt dissection alone. Biopsy through this single incision without the need for laparoscopic access and insufflation was successful in 3 of 40 (7.5%) cases.

The largest series evaluating the safety of laparoscopic renal biopsy reviewed 74 patients, of whom 10 had complications (13.5%): 3 with bleeding (4%), 1 with bowel injury (1.3%), 2 with inability to obtain specimen (2.7%), 1 with DVT (1.3%), 1 with pulmonary edema (1.3%), 1 with hyperkalemia (1.3%), and 1 death due to perforated duodenal ulcer secondary to chronic steroids for lupus nephritis (1.3%).<sup>39</sup> A subsequent study evaluating 40 patients reported a higher bleeding rate (7.5%), one of which required angioembolization, Table 1.<sup>38</sup>

### Transjugular renal biopsy

Transjugular renal biopsy offers an attractive safe and reliable alternative to percutaneous renal biopsy in high risk patients and does not require general anesthesia. Transvenous sampling is theoretically safer because the needle is passed through the vein wall directly into the renal parenchyma. Therefore, any bleeding should drain directly back into the vein, thereby limiting extravascular blood loss. Access is typically obtained via the right internal jugular vein, and biopsy of the right kidney is preferred. While left renal biopsy is feasible, it





**Figure 1.** Proposed algorithm for approaching renal biopsies.

is technically more difficult due to the horizontal course of the longer left renal vein. A lower pole renal vein is preferred due to the optimal angle for coagulation.

The diagnostic yield of transjugular renal biopsy is 92%-96%.<sup>40</sup> The volume of tissue and number of glomeruli obtained are comparable to the percutaneous technique, though some have reported instances of insufficient yield for immunofluorescence or electron microscopy.<sup>41,42</sup> Side-cut biopsy systems have been shown to provide greater tissue yield per pass than aspiration needles.<sup>43</sup>

The rates of complications observed with transjugular kidney biopsy are likely influenced by patient selection. Perinephric hematoma is common, occurring in up to 52% of patients, though this is comparable to rate of perinephric hematoma following percutaneous biopsy.<sup>40</sup> Capsular perforation noted on post-biopsy venography is common but has been shown to be clinically occult and inconsequential.<sup>40,44</sup> Despite this, some interventionalists proceed with routine elective coil embolization of biopsy tracts in the setting of capsular perforation.<sup>42</sup> Transfusion requirements, unrelated to the biopsy procedure or its complication itself, are common in the group of patients selected

for transjugular renal biopsy.<sup>40</sup> Major bleeding events, such as hemodynamically significant bleeding or symptomatic calyceal bleeding are rare, but occasionally require subsequent angioembolization. Nephrectomy for control of severe bleeding following transjugular renal biopsy has not been reported.

## Conclusions

Percutaneous renal biopsy offers valuable diagnostic and prognostic information in appropriately selected patients. Bleeding diathesis and solitary kidney were classically considered absolute contraindications; however, growing evidence supports the safety of percutaneous biopsy in patients with a solitary kidney. Obesity may compromise the quality of sonographic imaging and increase the risk of biopsy, though further study is needed in this patient population. The authors have proposed an algorithm for the approach to renal biopsies, Figure 1. Risk of complications can be limited by correcting underlying coagulopathy when present. In limited cases, alternatives such as open, laparoscopic, and transjugular biopsies provide excellent tissue sampling. □

## References

1. Iversen P, Brun C. Aspiration biopsy of the kidney. *Am J Med* 1951;11(3):324-330.
2. Fuiano G, Mazza G, Comi N et al. Current indications for renal biopsy: a questionnaire-based survey. *Am J Kidney Dis* 2000; 35(3):448-457.
3. Madaio MP. Renal biopsy. *Kidney Int* 1990;38(3):529-543.
4. Volpe A, Finelli A, Gill IS et al. Rationale for percutaneous biopsy and histologic characterisation of renal tumours. *Eur Urol* 2012;62(3):491-504.
5. Gill IS, Aron M, Gervais DA, Jewett MA. Clinical practice. Small renal mass. *N Engl J Med* 2010;362(7):624-634.
6. Klatte T. The contemporary role of renal tumor biopsy. *Eur Urol* 2012;62(3):505-506.
7. Mally AD, Gayed B, Averch T, Davies B. The current role of percutaneous biopsy of renal masses. *Can J Urol* 2012;19(3):6243-6249.
8. Clinical competence in percutaneous renal biopsy. Health and Public Policy Committee. American College of Physicians. *Ann Intern Med* 1988;108(2):301-303.
9. Mendelssohn DC, Cole EH. Outcomes of percutaneous kidney biopsy, including those of solitary native kidneys. *Am J Kidney Dis* 1995;26(4):580-585.
10. Schow DA, Vinson RK, Morrissette PM. Percutaneous renal biopsy of the solitary kidney: a contraindication? *J Urol* 1992;147(5): 1235-1237.
11. Corapi KM, Chen JL, Balk EM, Gordon CE. Bleeding complications of native kidney biopsy: a systematic review and meta-analysis. *Am J Kidney Dis* 2012;60(1):62-73.
12. Chandhoke PS, Albalá DM, Clayman RV. Long-term comparison of renal function in patients with solitary kidneys and/or moderate renal insufficiency undergoing extracorporeal shock wave lithotripsy or percutaneous nephrolithotomy. *J Urol* 1992;147(5): 1226-1230.
13. Jones DJ, Kellett MJ, Wickham JE. Percutaneous nephrolithotomy and the solitary kidney. *J Urol* 1991;145(3):477-479; discussion 9-80.
14. Wong KA, Sahai A, Patel A, Thomas K, Bultitude M, Glass J. Is percutaneous nephrolithotomy in solitary kidneys safe? *Urology* 2013;82(5):1013-1016.
15. Bucuras V, Gopalakrishnam G, Wolf JS, Jr et al. The Clinical Research Office of the Endourological Society Percutaneous Nephrolithotomy Global Study: nephrolithotomy in 189 patients with solitary kidneys. *J Endourol* 2012;26(4):336-341.
16. El-Nahas AR, Shokeir AA, El-Assmy AM et al. Post-percutaneous nephrolithotomy extensive hemorrhage: a study of risk factors. *J Urol* 2007;177(2):576-579.
17. El-Tabey NA, El-Nahas AR, Eraky I et al. Long-term functional outcome of percutaneous nephrolithotomy in solitary kidney. *Urology* 2014;83(5):1011-1015.
18. Unsal A, Koca G, Resorlu B, Bayindir M, Korkmaz M. Effect of percutaneous nephrolithotomy and tract dilatation methods on renal function: assessment by quantitative single-photon emission computed tomography of technetium-99m-dimercaptosuccinic acid uptake by the kidneys. *J Endourol* 2010;24(9):1497-1502.
19. Basiri A, Shabaninia S, Mir A, Soltani MH. The safety and efficacy of percutaneous nephrolithotomy for management of large renal stones in single- versus double-functioning kidney patients. *J Endourol* 2012;26(3):235-238.
20. Wilczek HE. Percutaneous needle biopsy of the renal allograft. A clinical safety evaluation of 1129 biopsies. *Transplantation* 1990; 50(5):790-797.
21. Laute M, Vanholder R, Voet D et al. Safety and sample adequacy of renal transplant surveillance biopsies. *Acta Clin Belg* 2013;68(3): 161-165.
22. Wong KA, Sahai A, Patel A, Thomas K, Bultitude M, Glass J. Is percutaneous nephrolithotomy in solitary kidneys safe? *Urology* 2013;82(5):1013-1016.
23. Brachemi S, Bollee G. Renal biopsy practice: What is the gold standard? *World J Nephrol* 2014;3(4):287-294.
24. Whittier WL. Complications of the percutaneous kidney biopsy. *Adv Chronic Kidney Dis* 2012;19(3):179-187.
25. Manno C, Strippoli GF, Arnesano L et al. Predictors of bleeding complications in percutaneous ultrasound-guided renal biopsy. *Kidney Int* 2004;66(4):1570-1577.
26. Stiles KP, Hill C, LeBrun CJ, Reinmuth B, Yuan CM, Abbott KC. The impact of bleeding times on major complication rates after percutaneous real-time ultrasound-guided renal biopsies. *J Nephrol* 2001;14(4):275-279.
27. Stiles KP, Yuan CM, Chung EM, Lyon RD, Lane JD, Abbott KC. Renal biopsy in high-risk patients with medical diseases of the kidney. *Am J Kidney Dis* 2000;36(2):419-433.
28. Wolff AT, Hohenstein C. Gastric perforation after mouth-to-mouth ventilation: a case report. *Eur J Anaesthesiol* 2015;32(2):138-139.
29. Fine DM, Arepally A, Hofmann LV, Mankowitz SG, Atta MG. Diagnostic utility and safety of transjugular kidney biopsy in the obese patient. *Nephrol Dial Transplant* 2004;19(7):1798-1802.
30. Dugo M, Brisotto E, Vitturi N et al. [Renal biopsy in the lateral position in high risk patients: an opportunity to take advantage of]. *G Ital Nefrol* 2015;32(1):12.
31. Gwyn NB. Biopsies and the completion of certain surgical procedures. *CMAJ* 1923;13(11):820-823.
32. Patil J, Bailey GL, Mahoney EF. Open-renal biopsy in uremic patient. *Urology* 1974;3(3):293-296.
33. Stec AA, Stratton KL, Kaufman MR et al. Open renal biopsy: comorbidities and complications in a contemporary series. *BJU Int* 2010;106(1):102-106.
34. Squadrito JF Jr, Coletta AV. Laparoscopic renal exploration and biopsy. *J Laparoendosc Surg* 1991;1(4):235-239.
35. Gimenez LF, Micali S, Chen RN, Moore RG, Kavoussi LR, Scheel PJ Jr. Laparoscopic renal biopsy. *Kidney Int* 1998;54(2):525-529.
36. Micali S, Zordani A, Galli R et al. Retroperitoneoscopic single site renal biopsy surgery: right indications for the right technique. *BMC Urol* 2014;14:80.
37. Micali S, Isgro G, De Stefani S, Pini G, Sighinolfi MC, Bianchi G. Retroperitoneal laparoendoscopic single-site surgery: preliminary experience in kidney and ureteral indications. *Eur Urol* 2011;59(1):164-167.
38. Repetto L, Oderda M, Soria F et al. Retroperitoneal laparoscopic kidney biopsy: technical tips for a minimally invasive approach. *J Endourol* 2011;25(10):1639-1642.
39. Shetye KR, Kavoussi LR, Ramakumar S, Fugita OE, Jarrett TW. Laparoscopic renal biopsy: a 9-year experience. *BJU Int* 2003;91(9):817-820.
40. Misra S, Gyamlani G, Swaminathan S et al. Safety and diagnostic yield of transjugular renal biopsy. *J Vasc Interv Radiol* 2008;19(4):546-551.
41. Sam R, Ing TS. Transjugular renal biopsy: when to do it and when not to? *Int J Artif Organs* 2001;24(9):595-597.
42. Thompson BC, Kingdon E, Johnston M et al. Transjugular kidney biopsy. *Am J Kidney Dis* 2004;43(4):651-662.
43. Marchetto BE, Meglin AJ, Chiricosta FM, Temo JA, Duhan JL. Transvenous renal biopsy in an ex vivo swine kidney model: a comparison of five devices. *J Vasc Interv Radiol* 1997;8(5):831-834.
44. Cluzel P, Martinez F, Bellin MF et al. Transjugular versus percutaneous renal biopsy for the diagnosis of parenchymal disease: comparison of sampling effectiveness and complications. *Radiology* 2000;215(3):689-693.
45. Finan BF, Brewer TE, Hughes RD, Wellons JA. Modified open renal biopsy. An experience with fifty consecutive cases. *Am J Nephrol* 1989;9(4):300-302.
46. Nomoto Y, Tomino Y, Endoh M et al. Modified open renal biopsy: results in 934 patients. *Nephron* 1987;45(3):224-228.
47. Gonick P, Grau J. Open renal biopsy technique: results in 202 patients. *Urology* 1978;11(6):568-571.
48. Gaur DD, Agarwal DK, Khochikar MV, Purohit KC. Laparoscopic renal biopsy via retroperitoneal approach. *J Urol* 1994;151(4):925-926.