

**RENO-, HEPATO- AND SPLENOMEGALY  
OF COMMON CARP FINGERLINGS (*CYPRINUS CARPIO* L.)  
DISEASED IN SWIMBLADDER INFLAMMATION CAUSED  
BY *SPHAEROSPORA RENICOLA* DYKOVÁ ET LOM, 1982**

A. AL-SAMMAN<sup>1</sup>, K. MOLNÁR<sup>2\*</sup>, Cs. SZÉKELY<sup>2</sup> and J. REICZIGEL<sup>3</sup>

<sup>1</sup>Faculty of Veterinary Medicine, Al-Baath University, Hama, Syria; <sup>2</sup>Veterinary Medical Research Institute, Hungarian Academy of Sciences, H-1581 Budapest, P.O. Box 18, Hungary; <sup>3</sup>Department of Biomathematics and Informatics, Faculty of Veterinary Science, Szent István University, Budapest, Hungary

(Received December 16, 2002; accepted April 1, 2003)

The weight of internal organs (swimbladder, kidney, liver, spleen) in relation to the body weight was studied in common carp fingerlings divided into three groups on the basis of swimbladder appearance and microscopic examination of the kidney. The fish had been collected from different Hungarian fish farms at the time when swimbladder inflammation (SBI) usually occurs (in July and August). The first group comprised fish with severe signs of SBI and massive renal sphaerosporosis, the second group consisted of fish with milder swimbladder changes and/or kidney infection by a low number of *Sphaerospora renicola*, while the third group was constituted by infection-free common carp fry. Statistical analysis of swimbladder, kidney, liver and spleen weight in relation to the body weight revealed that in the infected groups the internal organs were substantially enlarged. This suggests that in common carp fry with SBI the swimbladder changes are accompanied by reno-, hepato- and splenomegaly.

**Key words:** Swimbladder inflammation, common carp, *Sphaerospora renicola*, Myxosporea, renomegaly, hepatomegaly, splenomegaly

Swimbladder inflammation (SBI) caused by the developmental stages of *Sphaerospora renicola* Dyková and Lom (1982) is a common and seasonal disease among common carp fingerlings reared in the Hungarian pond farms. Infection of the carp kidney with *Sphaerospora* spores was first described in Europe by Molnár (1980a), who identified the species with *S. angulata* Fujita, 1912 recorded in Japan. After a detailed study of the spores from carp kidney in Czechoslovakia, Dyková and Lom (1982) rejected Molnár's identification and described the parasite as a new species under the name *S. renicola*.

---

\*Corresponding author: Dr. Kálmán Molnár; E-mail: kalman@vmri.hu; Fax: +36 (1) 252-2455

The parasitic aetiology of SBI was first suggested by Molnár (1980*b*), who expressed the opinion that the parasite stages found in the blood by Csaba (1976) and the stages proliferating by internal cleavage and detected by Kovács-Gayer et al. (1982) and Körting (1982) in the swimbladder wall corresponded to early stages of *S. angulata*. Csaba et al. (1984) provided further data to support this hypothesis and proved the parasitic aetiology of SBI, a disease formerly thought to be of viral origin. They concluded that the blood stages found by Csaba (1976) and described in detail by Lom et al. (1983) corresponded to the early stages of *S. renicola*, while those detected by Kovács-Gayer et al. (1982) and Körting (1982) represented the late extrasporogonic stages of the same parasite. The seasonal occurrence, the dynamics and the pathogenic effects of *S. renicola* were studied in detail by Grupcheva et al. (1985), Odening (1987), Odening et al. (1988, 1989) and Dyková and Lom (1988). Most of these studies were focused on the morphology and development of the blood parasitic stages and little attention was paid to the pathological importance of sporogonic stages located in the renal tubules. Apart from the short description of pathological changes in the kidney by Molnár (1980*a*), Dyková and Lom (1982) and Körting and Hermanns (1984), only Dyková and Lom (1988) have studied the pathology of renal sporogonic stages in detail. In addition to a slight enlargement of the trunk kidney, the last mentioned authors recorded dystrophic changes such as atrophy and necrosis of the tubular epithelium. The most relevant data on the enlargement of inner organs due to this infection were furnished by Kudryashova and Naumova (1978) who incorrectly identified the *Sphaerospora renicola* blood stages as *Haemogregarina cyprini*. These authors remarked that the relative weights of the spleen, heart, kidney and swimbladder in infected fishes were more than twice higher than the relative organ weights of uninfected specimens.

The objective of this work was to study, by regular fish dissections, differences in the weight of kidney, spleen, liver and swimbladder between infection-free common carp fingerlings and those with SBI and/or infected by renal stages of *Sphaerospora*.

### Materials and methods

The survey was conducted on a material consisting of 6- to 10-week-old common carp fingerlings from fish farms, in the period between 1 July and 10 August 2002. This is the period when, according to experience of several years, the following types of infection occur: (1) The first swimbladder changes can be observed and the first pseudoplasmodia appear in the kidney. (2) A certain proportion of common carp fry in the infected ponds show signs of acute SBI. (3) In the late phase of infection mostly regenerated swimbladders are seen, but some unreleased spores can still be found in the renal tubules.

The examined fish weighed 3 to 48 g and had been harvested from 10 ponds of three carp farms. Those ponds were selected for detailed study in which preliminary examinations had revealed that at least 30% of the fry showed the signs of SBI. A total of 189 specimens of common carp fingerlings were dissected. Each fingerling was weighed before dissection. After opening the abdominal cavity the fish were gutted and their internal organs (spleen, liver, kidney and swimbladder) were separated and weighed on a digital precision balance. After weighing the internal organs, first the swimbladder was examined for signs of SBI (transparency, haemorrhages, thickening of the wall, etc.). Pieces from the kidney were squashed under a coverslip and the renal tubules were examined by microscopy at 400-fold magnification for the presence of *S. renicola* plasmodia and spores.

Fish were divided into three groups on the basis of the dissection findings. The first group comprised fish that showed distinct signs of SBI (haemorrhages and thickening of the swimbladder wall, and plasmodia and spores filling at least one fourth of the renal tubules). Fingerlings assigned to the second group represented incipient and chronic cases, when the swimbladder showed only mild changes of SBI (dilated capillaries, minor haemorrhages, slight thickening and opacity of the regenerated swimbladder wall and traces of previous haemorrhages) and only few pseudoplasmodia or spores were found in the renal tubules. The third group comprised common carp fingerlings with an intact, transparent swimbladder wall and infection-free kidneys.

As the weight of organs markedly depends on the body weight, their relative weights, expressed as a percentage of the body weight, were used in the analysis. For the comparison of the three groups analysis of variance and Dunnett's test were used (Dunnett, 1955). In the latter test the two infected groups were compared with the third, uninfected group.

## Results

Carp fingerlings proved to be free of infection in two of the ponds selected for the survey. In two other ponds the level of infection was low and, therefore, fish from these ponds were not subjected to detailed studies. In the remaining six ponds the prevalence of infection exceeded 30%.

In the first days of July clouding of the otherwise transparent swimbladder wall, dilation of the capillaries running in it, and appearance of small haemorrhages on the surface of the relatively thin swimbladder wall were observed. By mid-July the *Sphaerospora*-infected fish had become easily distinguishable from the infection-free fish on the basis of the swimbladder signs. While infection-free fish had a thin-walled, air-filled and transparent swimbladder (Figs 1a and 1b), in the majority of the infected fish both sacs of the swimbladder were shrunken and

deformed, had thickened walls with extensive haemorrhages as signs of SBI (Figs 1c and 1d). The presence of *S. renicola* pseudoplasmodia and spores (Fig. 2) in the kidney was closely correlated with the swimbladder changes. Sporogonic stages of sphaerospores were detectable in the convoluted tubules of the kidney in all of the fish showing signs of acute SBI, and a few spores could consistently be detected in the renal tubules of fish that showed barely perceptible signs of a passed-off SBI. At the time when the first swimbladder changes appeared, there were no spores yet in the renal tubules, which were filled by pseudoplasmodia (Fig. 3). As the disease progressed, the renal tubules of fish with a thickened swimbladder wall became dilated and filled by large numbers of pseudoplasmodia and spores (Fig. 4). At the end of the investigations, in August the acute signs of SBI could no longer be observed. In fingerlings dissected in that period a passed-off inflammation was indicated by the opalescent, slightly thickened swimbladder wall with haemosiderin spots suggestive of previous haemorrhages and the presence of a few spores in the renal tubules. Swimbladder changes were no longer seen in 17 out of 43 fingerlings with chronic sphaerosporosis in which only low numbers of *S. renicola* spores were present in the renal tubules.

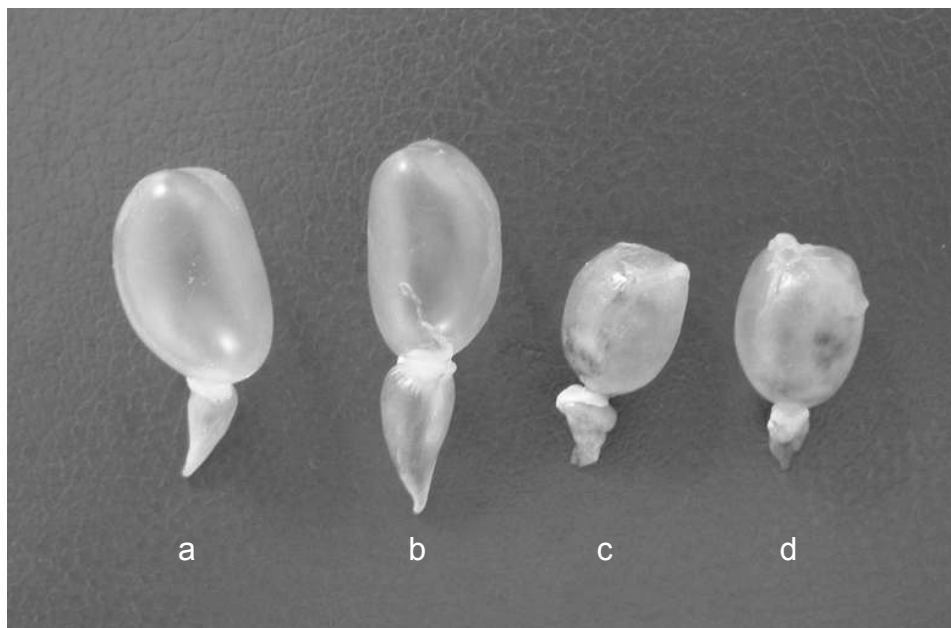


Fig. 1. Swimbladders from uninfected common carp and from common carp infected by *Sphaerospora renicola* developmental stages. The wall of the uninfected swimbladders (a and b) is thin and transparent, while the swimbladder of fish showing signs of SBI (c and d) is deformed and has thickened wall with haemorrhagic areas. Natural size

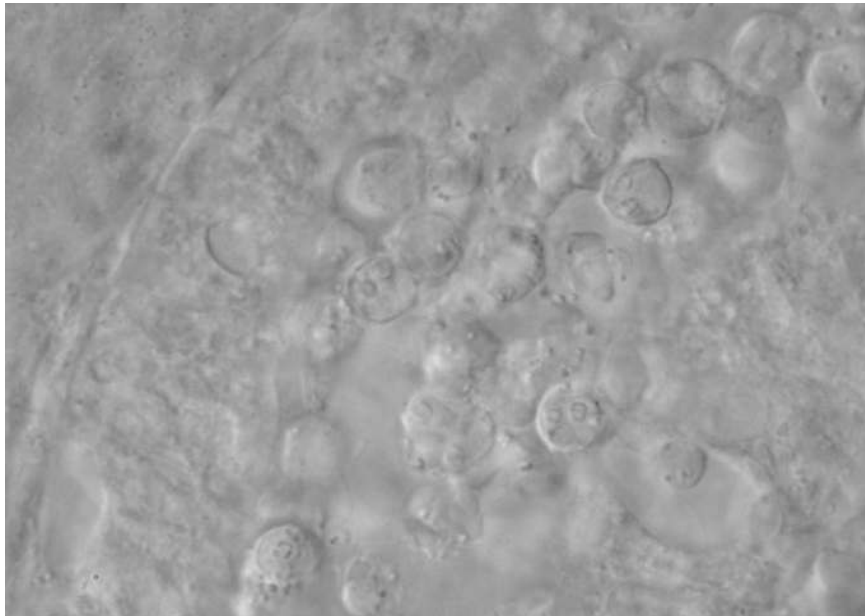


Fig. 2. Fish with severe signs of swimbladder inflammation always harbour masses of *Sphaerospora renicola* spores in the renal tubules. Haematoxylin and eosin (H.-E.),  $\times 800$

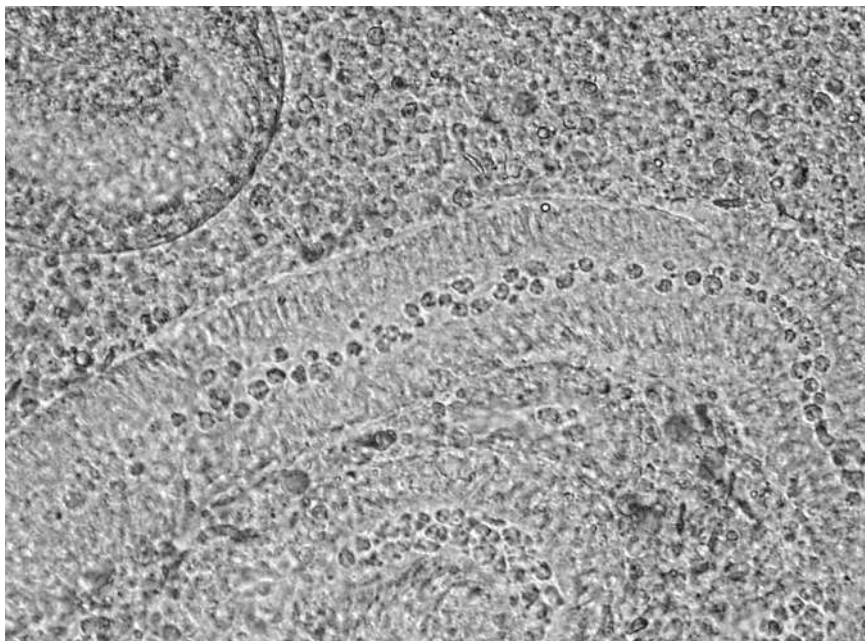


Fig. 3. Early stage of *Sphaerospora renicola* infection in the kidney of common carp. Some of the tubules contain young pseudoplasmodia. H.-E.,  $\times 150$

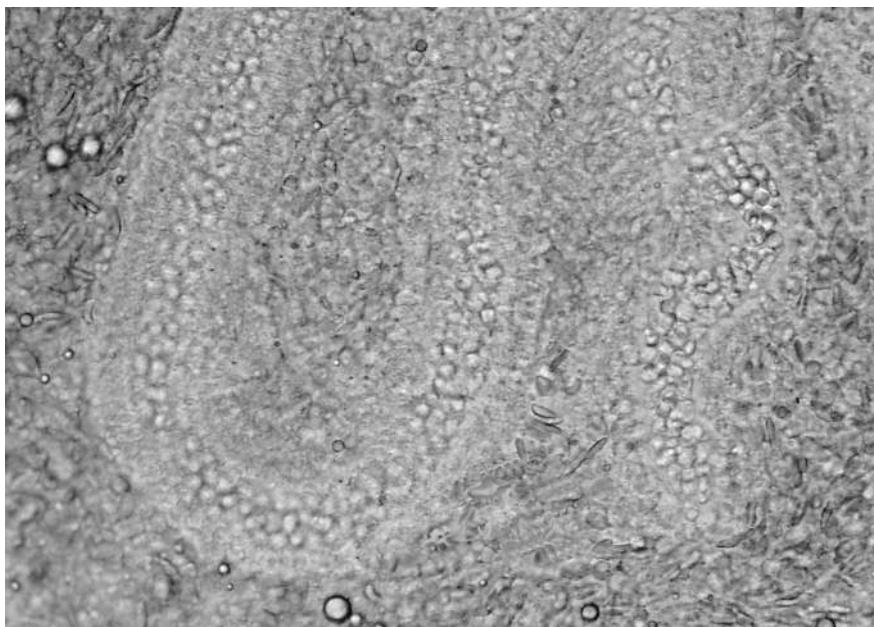


Fig. 4. Massive renal infection associated with acute swimbladder signs. The renal tubules are filled by large numbers of *Sphaerospora renicola* pseudoplasmodia and spores. H.-E.,  $\times 150$

Enlargement of the kidney was observed in all sphaerospore-infected common carp fingerlings showing signs of SBI. As compared to the kidney weight/body weight ratio measured in the infection-free group, the difference in the weight of the kidney in relation to the body weight was larger in the more severely infected and smaller in the less severely infected fish group. Similar differences were detected in the weight of other internal organs in relation to the body weight. This difference was the most striking in the swimbladder weight/body weight ratio, but it was statistically significant for the other organs as well (Table 1).

**Table 1**

Weight of organs expressed as a percentage of the body weight in the three groups

	Group 1 (n = 66)	Group 2 (n = 43)	Group 3 (n = 80)
Kidney	2.03 $\pm$ 0.55 (p < 0.001)	1.62 $\pm$ 0.51 (p < 0.001)	1.21 $\pm$ 0.37
Liver	3.23 $\pm$ 0.59 (p < 0.001)	3.09 $\pm$ 0.84 (p = 0.004)	2.66 $\pm$ 0.74
Swimbladder	1.05 $\pm$ 0.54 (p < 0.001)	0.63 $\pm$ 0.32 (p = 0.038)	0.46 $\pm$ 0.17
Spleen	0.85 $\pm$ 0.32 (p < 0.001)	0.66 $\pm$ 0.29 (p = 0.002)	0.48 $\pm$ 0.25

Group 1: severe infection; Group 2: infection of medium degree; Group 3: free of infection. The *p* values are derived from the comparison of the given group with the infection-free group (Dunnett's test)

### Discussion

The findings of this study support the observations according to which *S. renicola* pseudoplasmodia and spores appear in the kidney simultaneously with the development of swimbladder changes (Molnár, 1980b; Csaba et al., 1984; Körting and Hermanns, 1984; Dyková and Lom, 1988; Odening et al., 1989).

The results of this study also clearly demonstrate that, in addition to swimbladder changes being the primary features of the disease and exophthalmia caused by swelling of the choroidal rete mirabile (Molnár, 1993), enlargement of the kidney, spleen and liver also plays a role in the pathological process. Statistical analysis of infections of different severity revealed that the weight of internal organs (swimbladder, kidney, liver, spleen) of both the fish group showing severe swimbladder changes and massive infection of the kidney and the group showing milder swimbladder changes and a low-level renal infection differed significantly from the weight of the same organs of infection-free fish. In the infected fish, the weight increase of the visibly enlarged swimbladder was always accompanied by an externally less conspicuous volume and weight increase of the kidney, liver and spleen. Although the eyeball was not weighed in this study, external signs indicate that the weight of the eyeball increases considerably in the infected fish, which is indicated by exophthalmia observed in fish showing severe signs of infection. The weight increase of the swimbladder is clearly attributable to the *Sphaerospora* K-stages accumulated in that organ, the blood stagnant in capillaries blocked by parasite stages, and the exudate infiltrating the tissues. The weight increase of the kidney, on the other hand, probably results from the mass of pseudoplasmodia and spores filling the convoluted tubules, and the dysfunction resulting from obstruction of the convoluted tubules plays only a secondary role. The smaller increase observed in the weight of the liver and spleen can primarily be explained by the general blood congestion resulting from the general damage of these organs, and C-stages always detectable in the capillaries of infected fish and the less frequently detectable K-stages are likely to play a less important role.

Despite the fact that renomegaly is well detectable, the kidney enlargement caused by *S. renicola* is not consistent with the changes observed in proliferative kidney disease of trout. While *S. renicola* spores and pseudoplasmodia cause damage to the host organism primarily by occupying space within the renal tubules, the PKX pseudoplasmodia of *Tetraspora bryozoides* causing proliferative kidney disease grow in the renal interstitium and the proteins released by disintegrating mother cells exert a continuous antigen effect on the humoral and cellular defence mechanisms of the host (Clifton-Hadley et al., 1987; Feist et al., 2002).

In the present survey, we could not detect severe disease associated with high mortality comparable to that reported by Szokolczai (1967), Arshanica (1969), Csaba et al. (1984), Körting et al. (1984) and Odening (1987) in common

carp fry. It can no longer be determined whether in the 1960s and 1970s this condition occurred in a more severe form because the parasite was introduced to a susceptible European common carp stock at that time, or whether the chances of parasite colonisation increased as a result of purely economy-oriented efforts to produce the highest possible number of fingerlings on unit pond area.

### Acknowledgements

The authors thank Ms. Orsolya Rácz and Ms. Györgyi Pataki for their help in the laboratory work. The study was rendered possible by a grant from the Hungarian Scientific Research Fund (project no. T 029200) and by the programme entitled 'Quality development of the biological and technological bases of the Hungarian fishing sector', 4/039/2001.

### References

- Arshanica, N. M. (1969): Data on the epizootiology, diagnosis and prophylaxis of swimbladder disease of the common carp (in Russian). *Izvestiia of GosNIORCh* **10**, 80–82.
- Clifton-Hadley, R. S., Bucke, D. and Richards, R. S. (1987): A study of the sequential clinical and pathological changes during proliferative kidney disease in rainbow trout, *Salmo gairdneri* Richardson. *J. Fish Dis.* **10**, 335–352.
- Csaba, Gy. (1976): An unidentifiable extracellular sporozoan parasite from the blood of the carp. *Parasitol. Hung.* **9**, 21–24.
- Csaba, Gy., Kovács-Gayer, E., Békési, L., Bucsek, M., Szokolczai, J. and Molnár, K. (1984): Studies into the possible protozoan aetiology of swimbladder inflammation in carp fry. *J. Fish Dis.* **7**, 39–56.
- Dunnett, C. W. (1955): A multiple comparison procedure for comparing several treatments with a control. *J. Am. Stat. Assoc.* **50**, 1096–1211.
- Dyková, I. and Lom, J. (1982): *Sphaerospora renicola* n. sp., a myxosporean from carp kidney, and its pathogenicity. *Z. Parasitenkd.* **68**, 259–268.
- Dyková, I. and Lom, J. (1988): Review of pathogenic myxosporeans in intensive culture of carp (*Cyprinus carpio*) in Europe. *Folia Parasitol.* **35**, 289–307.
- Feist, S. W., Peeler, E. J., Gardiner, R., Smith, E. and Longshaw, M. (2002): Proliferative kidney disease and renal myxosporidiosis in juvenile salmonids from rivers in England and Wales. *J. Fish Dis.* **25**, 451–458.
- Grupcheva, G., Dyková, I. and Lom, J. (1985): Seasonal fluctuation in the prevalence of *Sphaerospora renicola* and myxosporean bloodstream stages in carp fingerlings in Bulgaria. *Folia Parasitol. (Praha)* **32**, 193–203.
- Kovács-Gayer, E., Csaba, Gy., Békési, L., Bucsek, M., Szokolczai, J. and Molnár, K. (1982): Studies on the protozoan etiology of swimbladder inflammation in common carp fry. *Bull. Eur. Ass. Fish Pathol.* **2**, 22–24.
- Körting, W. (1982): Protozoan parasites associated with swimbladder inflammation (SBI) in young carp. *Bull. Eur. Assoc. Fish Pathol.* **2**, 25–28.
- Körting, W. and Hermanns, W. (1984): Myxosporidien-Infektionen in der Niere des Karpfens (*Cyprinus carpio* L.) aus niedersächsischen Teichwirtschaften. *Berl. Münch. Tierärztl. Wschr.* **97**, 255–259.
- Körting, W., Hoffmann, R., Neukirch, M. and Fuhrmann, H. (1984): Myxosporidien-bedingte Schwimmblasenentzündung bei Karpfenbrut. *Berl. Münch. Tierärztl. Wschr.* **97**, 99–104.



- Kudryashova, J. V. and Naumova, A. M. (1978): Influence of *Haemogregarina* on the carp. *Veterinariya* **4**, 76–78.
- Lom, J., Dyková, I. and Pavlasková, M. (1983): 'Unidentified' mobile protozoans from the blood of carp and some unsolved problems of myxosporean life cycles. *J. Protozool.* **30**, 497–508.
- Molnár, K. (1980a): Renal sphaerosporosis in the common carp *Cyprinus carpio* L. *J. Fish Dis.* **3**, 11–19.
- Molnár, K. (1980b): 'Sphaerosporosis', a new kidney disease of the common carp. *Fish Dis.* Third COPRAQ Session. Springer-Verlag, Berlin, Heidelberg, New York. pp. 157–164.
- Molnár, K. (1993): The occurrence of *Sphaerospora renicola* K-stages in the choroidal rete mirabile of the common carp. *Folia Parasitol.* **40**, 175–180.
- Odening, K. (1987): *Sphaerospora renicola* (Myxosporidia), der Erreger der protozoären Schwimmblasenentzündung des Jungkarpfens (renicola-Sphaerosporose). *Angew. Parasitol.* **28** (Merkbl.), 1–16.
- Odening, K., Walter, G. and Bockhardt, I. (1988): Zur jahreszeitlichen Dynamik von *Sphaerospora renicola* (Myxosporidia) beim Karpfen (Osteichthys). *Angew. Parasitol.* **29**, 65–80.
- Odening, K., Walter, G. and Bockhardt, I. (1989): Zum Infektionsgeschehen bei *Sphaerospora renicola* (Myxosporidia). *Angew. Parasitol.* **30**, 131–140.
- Szokolczai, J. (1967): Untersuchungen der Schwimmblasenentzündung bei Karpfen anhand von zwei Fällen in Ungarn. *Z. Fisherei* **15**, 139–151.