

## Systematic Review

## Repair of Horizontal Meniscus Tears: A Systematic Review

Peter R. Kurzweil, M.D., Nancy M. Lynch, M.D., Sheldon Coleman, M.D., and Brian Kearney, Ph.D.

**Purpose:** Despite the well-documented advantages of meniscal repair over meniscectomy, horizontal cleavage tears (HCTs) are often not repaired. Reported reasons include difficulty performing the repair, potential suture failure due to mechanical stresses, and poor healing rates. In addition, many surgeons have the perception that debriding the tear until the superior and inferior laminae are stable results in a good clinical outcome. Furthermore, many of the tears occur in patients who are older than the generally accepted indicated age for repair and may also have a degenerative component, making them potentially less likely to benefit from repair. This review was performed to evaluate the published outcomes of HCT repairs and test the hypothesis that surgically repaired HCTs have an unacceptably low rate of success. **Methods:** A systematic search of the PubMed and Embase databases was performed in December 2013 to identify studies in which meniscal HCTs were repaired. Inclusion criteria for the analysis were English language, reference to a patient with an HCT repaired by any method, and a report of at least 1 postoperative outcome. For the purposes of this review, a failed outcome was defined as the need for reoperation. **Results:** More than 16,000 abstracts were returned in the search. From these abstracts, we identified 210 articles for further review, of which 9 met the inclusion criteria. A total of 98 repairs of horizontal tears were evaluated in these studies. By use of reoperation as the criterion for treatment failure, 77 of the repairs were successful, for an overall success rate of 77.8%. **Conclusions:** The literature does not support the hypothesis that surgically repaired HCTs have an unacceptably low rate of success. Rather, our results show that existing studies of repaired HCTs show a comparable success rate to repairs of other types of meniscal tears. **Level of Evidence:** Level IV, systematic review of Level IV studies.

Meniscal tears are a common orthopaedic diagnosis, accounting for more than 400,000 ambulatory surgical visits each year in the United States alone.<sup>1</sup> Even in asymptomatic knees, the rates of meniscal tears detected by magnetic resonance imaging are high, especially in older patients. For example, in 1

large study of almost 1,000 asymptomatic adults, 19% of women and 33% of men aged older than 50 years had evidence of a meniscal tear on magnetic resonance imaging.<sup>2</sup>

Meniscal tears can have either traumatic or degenerative causes.<sup>3</sup> In younger patients, traumatic tears frequently occur during sports injuries. These tears often result in pain localized to the joint line.<sup>3,4</sup> In contrast, degenerative tears, which are typically associated with aging and osteoarthritis, often occur without an inciting episode, and the resultant symptoms of activity-related pain or rest pain<sup>3</sup> may be more reflective of a generalized arthritic process.

Standard treatment options for symptomatic meniscal tears that have failed nonoperative measures include meniscectomy and repair. The preferred approach has changed dramatically over the past 30 years.<sup>5</sup> Once thought to be an unnecessary vestigial appendage, the meniscus has been shown to play key roles in load transmission<sup>6,7</sup> and shock absorption,<sup>8</sup> especially in younger active patients. The meniscus is also involved in joint lubrication,<sup>9</sup> anteroposterior joint stability,<sup>10</sup> and proprioception.<sup>11</sup> With a better understanding of meniscal biology and function, coupled with improved

*From the Southern California Center for Sports Medicine (P.R.K.), Long Beach, California; Advisorthopædics (N.M.L.), Belmont, California; Private Practice (S.C.), Los Angeles, California; and Private Practice (B.K.), Oakland, California, U.S.A.*

*The authors report the following potential conflict of interest or source of funding: P.R.K. receives support from Ceterix Orthopaedics. N.M.L. receives support from the following: paid consultant for Ceterix for clinical trial design and protocol development for systematic review. Expenses paid by Ceterix for meeting travel for purpose of consulting. Smith & Nephew. Chief Medical Officer of Histogenics. S.C. receives support from Ceterix Orthopaedics. Payment received for reviewing the manuscript. Payment for conducting a literature search. B.K. receives support from Ceterix Orthopaedics. Paid by Ceterix Orthopaedics to write the manuscript.*

*Received April 18, 2014; accepted May 22, 2014.*

*Address correspondence to Peter R. Kurzweil, M.D., Southern California Center for Sports Medicine, 2760 Atlantic Ave, Long Beach, CA 90806, U.S.A. E-mail: [pkurzweil@aol.com](mailto:pkurzweil@aol.com)*

*© 2014 by the Arthroscopy Association of North America  
0749-8063/14320/\$36.00*

*<http://dx.doi.org/10.1016/j.arthro.2014.05.038>*

techniques and tools that facilitate meniscal repair, treatment has evolved toward meniscal preservation. Partial meniscectomy has largely taken the place of total meniscectomy, and the indications for meniscal repair have expanded.<sup>5</sup>

Horizontal cleavage tears (HCTs) extend from the inner free margin of the meniscus into the intrameniscal substance, dividing the meniscus into superior and inferior laminae.<sup>12</sup> HCTs are most often treated by partial meniscectomy and are not commonly repaired.<sup>13</sup> Reported reasons include difficulty performing the repair,<sup>14-16</sup> potential suture failure due to differential shear stresses between the superior and inferior laminae,<sup>17</sup> and poor healing rates.<sup>16,18</sup> HCTs also typically extend significantly into the avascular zone, which may affect their ability to heal.<sup>19</sup> In many meniscal repair studies evaluated in this systematic review, investigators excluded horizontal tears from treatment consideration without explanation, presumably because the commonly held beliefs that HCTs do not need repair or fail to heal if repaired require no discussion.

In our initial literature searches, little clinical support was found for the contention that repaired HCTs do not heal or heal at rates significantly lower than those for other types of meniscal tears. Consequently, the search was expanded to a systematic review to evaluate the published outcomes of HCT repair. The purpose was to test the hypothesis that surgically repaired HCTs have an unacceptably low rate of success.

## Methods

A search of the PubMed and Embase databases was performed in December 2013 to identify studies in which meniscal HCTs were repaired. The search terms were “horizontal cleavage” OR “avascular zone” OR “menisci, tibial” AND “repair” OR “arthroscopy.”

Abstracts identified by the search were evaluated by 2 investigators. The literature search strategy is shown in Figure 1. The title and abstract reviews were performed simultaneously. If the title indicated that the study covered human subjects, was in English, and included the results of meniscal repairs, then the abstract was read. Full-text versions of articles were obtained for studies when we concluded that information contained in the title or abstract warranted further investigation for possible inclusion in the systematic review. Inclusion criteria were English language, reference to a patient with an HCT repaired by any method, and a report of at least 1 outcome for at least 1 repair at any time postoperatively. No limitations were placed on the date of publication. A failed outcome was defined as the need for reoperation.

If the results were reported for a variety of tear types, only those articles that specifically reported the results for the HCT repairs were included in the final tally. When separate studies reported results from overlapping case series, only the larger study was included in the

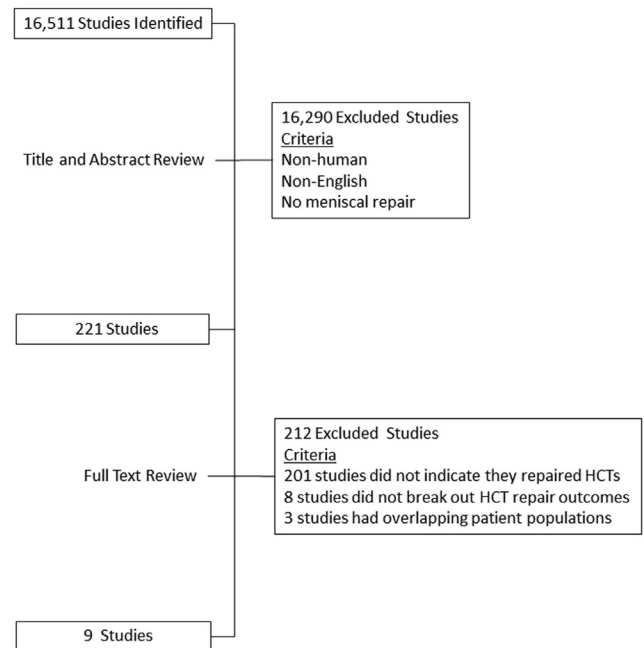


Fig 1. Literature search strategy and results.

final analysis to ensure that the results for any case were counted only once. Studies that reported on intra-substance meniscal lesions were excluded if the lesions were incomplete without connection to the surface or the bed of the meniscus.

## Results

More than 16,000 abstracts were identified in the search, and 221 articles were retrieved for further review, of which 9 studies met the inclusion criteria.<sup>20-28</sup> Table 1 provides a summary for each study including the number of HCT repairs, follow-up period, and success rates. The number of HCTs repaired ranged from 1 to 47 in any given study, with follow-up periods ranging from 11 to 70 months.<sup>20-28</sup>

Overall, the results from 98 horizontal repairs were reported in these 9 studies, usually as part of larger retrospective analyses across a wide range of meniscal tears. Patient populations, repair techniques, and lengths of follow-up varied among the studies. The way authors defined success also varied. Reported outcomes included clinical examination findings and a variety of subjective patient surveys. One outcome that was included in all 9 studies and could be commonly accepted as failure was the need for reoperation. Conversely, one might consider success based on lack of the need for reoperation. This was reported for a total of 77 repairs (78.6%).<sup>20-28</sup>

The study with the largest number of horizontal repairs was reported by Tengrootenhuysen et al.<sup>27</sup> from Bruges, Belgium. This retrospective review included 119 meniscal repairs, of which 47 were repairs of HCTs.

**Table 1.** Studies Reporting Outcomes of Repaired Meniscal HCTs

Study	Study Type	Period in Which Repairs Were Performed	Patient Age (All Patients) (yr)	HCTs	Type of Repair	Mean Length of Follow-up (All Patients) (mo)	HCT Treatment Success (No Reoperation)	Notes
Accadbled et al. <sup>20</sup>	Retrospective case series	1999-2002	8-16 (mean, 13)	2	1 inside out 1 FasT-Fix	37	2 of 2	Both repairs were successful by IKDC criteria. The FasT-Fix repair was not successful by MRI.
Kamimura and Kimura <sup>21</sup>	Retrospective case series	Not reported	Not reported	9	FasT-Fix + fibrin clot	12	9 of 9	All patients in the study had degenerative menisci with HCTs.
Kraus et al. <sup>22</sup>	Retrospective case series	2003-2005	17 (single HCT patient)	1	All inside	28	0 of 1	No data were available about reoperation. Treatment failure was determined by postoperative Tegner and Lysholm scores.
Krych et al. <sup>23</sup>	Retrospective case series	1990-2005	10-19 (mean, 16)	2	1 inside out 1 with bioabsorbable arrows	70	1 of 2	The inside-out repair was successful.
Pujol et al. <sup>24</sup>	Retrospective case series	1998-2006	16-44 (median, 25)	21	All open	40	17 of 21	
Rubman et al. <sup>25</sup>	Retrospective case series	1982-1995	9-53 (mean, 28)	14	Inside out	42	10 of 14	Type of tear was not statistically correlated with reoperation rates.
Scott et al. <sup>26</sup>	Prospective case series	1980-1983	9-53 (mean, 22)	1	Inside out	23	1 of 1	Incompletely healed but no reoperation was required.
Tengrootenhuysen et al. <sup>27</sup>	Retrospective case series	1994-2002	11-47 (median, 23)	47	Biofix arrows Inside out Combined (arrows plus inside out)	70	36 of 47	Horizontal tear was not a contributor to failure by multivariate analysis. All 11 failures were confirmed by repeat arthroscopy. Repair technique was a significant contributor with arrow and combined techniques showing poorer outcomes.
Tenuta and Arciero <sup>28</sup>	Retrospective case series	1987-1991	16-34 (mean, 22)	1	Inside out	11	1 of 1	Incompletely healed at second look but asymptomatic.

IKDC, International Knee Documentation Committee; MRI, magnetic resonance imaging.

Three methods of repair were used: inside-out repair, all-inside repair with Biofix arrows (Linvatec, Largo, FL), or a hybrid method combining inside-out repair with arrows. The mean follow-up period from the time of repair was 70 months. Criteria for successful repair of the meniscus included all of the following: absence of knee pain or, if present, mild pain that was not activity limiting; absence of symptoms suggestive of a meniscal tear, such as locking, catching, giving way, or significant swelling; a negative McMurray test; and no subsequent surgical procedures on the repaired meniscus. Patients ranged in age from 11 to 47 years, with a median age of 23 years. Patient baseline characteristics, the types of repairs used, and the length of follow-up were not reported for the HCT repairs separately from the general study population.<sup>27</sup>

The study had a number of interesting results. First, the overall success rate for horizontal repairs was 76% (36 of 47). The success rates for repairs of vertical and bucket-handle tears were 68% and 84%, respectively. Repair technique was a significant contributor to treatment failure. Tears repaired with arrow and hybrid techniques had lower rates of treatment success than inside-out repairs. A horizontal tear was not a contributor to treatment failure by multivariate analysis, and no significant differences in success rates based on tear type were identified.

In the study, posteroanterior weight-bearing Rosenberg radiographs were obtained, and the radiographs were reviewed for signs of degenerative changes and compared with the preoperative images.<sup>27</sup> The radiologic changes were graded to determine the severity of osteoarthritis. In this analysis across the overall study population, significantly more osteoarthritic changes were observed in the group with failed meniscal repairs.

Concern about the healing potential of degenerative tissue is 1 of the reasons cited for not performing repairs of horizontal tears. Most of the studies identified in this review were in younger patients or in patients whose demographic characteristics were not specified by tear type.<sup>20-28</sup> One of the 9 HCT studies specifically addressed repair of degenerative tears.<sup>21</sup> This study, by Kamimura and Kimura,<sup>21</sup> included 9 tears with meniscal degeneration, although the ages of the patients and the definition of degeneration were not reported. Vertical sutures were placed on each meniscus using FasT-Fix (Smith & Nephew Endoscopy, Andover, MA), and an exogenous fibrin clot was inserted within the cleft of the tear before the sutures were tightened. At second-look arthroscopy performed 12 months after surgery, the suture knots for all 9 repairs were covered with scar tissue, no changes in the appearance of the weight-bearing articular cartilage were apparent, and a vascular layer was present on the repaired meniscus. In addition, all patients (100%) showed improvements in their functional scores and quality of life.<sup>21</sup>

Additional concerns about the healing potential of HCTs have been raised because horizontal tears often extend into the avascular region of the meniscus.<sup>19</sup> Of the 9 studies reviewed, 1 specifically evaluated arthroscopic repair of meniscal tears that extended into the central-third region of the meniscus or had a rim width of 4 mm or greater. Of the 14 repairs made to horizontal tears, 10 were successful and 4 required reoperation because of tibiofemoral joint symptoms identified at follow-up examination.<sup>25</sup>

Table 2 lists the conclusions of each of the 9 studies. Overall, the authors of the articles emphasized the importance of meniscal repair over meniscectomy for appropriate patients.<sup>20-28</sup>

## Discussion

This systematic review was performed to test the hypothesis that surgically repaired HCTs have an unacceptably low rate of success. The question is important because the unmet need is large. HCTs are common, not only among middle-aged and older adults<sup>2</sup> but even among younger patients with trauma-induced meniscal tears.<sup>29-31</sup> Prevalence estimates vary by study population, but HCTs were present in 12% to 32% of patients with meniscal tears in 3 large series that included approximately 12,000 patients.<sup>29-31</sup>

Not only are HCTs common, they are commonly treated with meniscectomy, with its well-established limitations and long-term complications. Both total meniscectomy and partial meniscectomy have been shown to cause poor long-term knee function that deteriorates over time.<sup>32-40</sup> Numerous studies have shown that after meniscectomy, the tibiofemoral contact area is reduced by approximately 50% whereas contact forces increase 2 to 3 times.<sup>6,7,32,41-44</sup> A biomechanical study of horizontal meniscal tears showed that single-lamina resection reduced contact area by 59%, increased mean pressure by 55%, and increased peak pressure by 19%. Double-lamina resection did not significantly change these values, suggesting that sparing 1 leaf offers no benefit compared with resecting both.<sup>45</sup>

The long-term personal and even professional impact of meniscectomy can be significant. For example, in a case-controlled study of professional athletes who played in the National Football League in the United States, a history of meniscectomy significantly reduced the length of a player's career in years and games played.<sup>46</sup>

More recently, a number of Level I studies have brought into question the short-term benefit of partial meniscectomy. Sihvonen et al.<sup>47</sup> conducted a multicenter, randomized, double-blind, sham-controlled trial in 145 patients with knee symptoms consistent with a degenerative medial meniscus tear and no knee osteoarthritis. Katz and Losina<sup>48</sup> compared partial meniscectomy versus physical therapy in 351 patients with a

**Table 2.** Study Conclusions

Study	Conclusions
Accadbled et al. <sup>20</sup>	"We think meniscal repair is appropriate in young patients, as meniscectomy would result in the loss of function and premature joint arthrosis. Patients should be informed of the risk of failure. The evaluation of long-term results is necessary."
Kamimura and Kimura <sup>21</sup>	"The meniscal repair procedure described here offers an alternative approach to treat a degenerative meniscus with a horizontal cleavage tear, the repair of which has been limited until now."
Kraus et al. <sup>22</sup>	"All meniscal tears in the skeletally immature patient are amenable to repair. All recurrent meniscal tears in our patients were located in the pars intermedia; the poorer blood supply in this region may give a higher risk of re-rupture. Simultaneous ACL reconstruction appears to benefit the results of meniscal repair."
Krych et al. <sup>23</sup>	"Clinically successful repair of an isolated meniscal tear in patients 18 years or younger was variable depending on tear type, with complex tears and rim width 3 mm or greater being negative prognostic factors."
Pujol et al. <sup>24</sup>	"Open meniscal repair of complex horizontal tears extending into the avascular zone was effective at midterm follow-up in young and active patients. The meniscus was preserved in 80% of cases. Functional results deteriorated in those older than 30 years. This entity should be differentiated from degenerative meniscal tears that often occur in patients over 50, which may be associated with osteoarthritis."
Rubman et al. <sup>25</sup>	"Partial meniscectomy for complex tear patterns or tears that extend into the avascular zone require removal of a large portion of the meniscus and may render it nonfunctional. If meniscal repair is performed, the short-term data in our study show that at 2 years after surgery, a majority of the patients will be asymptomatic. The long-term function of these menisci needs to be determined in future studies."
Scott et al. <sup>26</sup>	"There is well-documented evidence that meniscectomy is not a benign procedure. Partial meniscectomy, while decreasing short-term morbidity, may have just as pronounced long-term sequelae as does total meniscectomy. Meniscal repair is a logical alternative to restore the normal kinematics of the knee."
Tengrootenhuysen et al. <sup>27</sup>	"This retrospective study shows the clinical and radiological importance of meniscal repair. Successful results in this study were associated with younger age and earlier repair using inside-out technique. Furthermore, increased success was seen in meniscal repairs performed in association with ACL reconstruction."
Tenuta and Arciero <sup>28</sup>	"Based on our results, the 'ideal' patient profile for meniscal repair is a patient less than 30 years of age, with a tear within 3 mm of the meniscosynovial junction, repaired in conjunction with an ACL reconstruction, and done relatively early after injury."

ACL, anterior cruciate ligament.

meniscal tear and evidence of mild to moderate osteoarthritis on imaging. In both studies the 12-month outcomes for partial meniscectomy were not significantly different from those for the less invasive alternative studied.<sup>47,48</sup>

Given the limitations of total and partial meniscectomy, repair would be a preferable option for many patients if surgeons can achieve acceptable rates of success. The published studies reviewed for this analysis support the position that one should consider repair of HCTs. The evidence suggests that most repaired HCTs have good clinical outcomes, with success rates possibly comparable with rates published for other commonly repaired meniscus tear patterns.

In addition to the studies reviewed in this analysis, other studies that failed to meet our inclusion criteria also provide support for repairing HCTs. Biedert<sup>49</sup> studied repair of intrasubstance meniscal lesions (not complete cleavage tears) and reported a 90% success rate for 10 lesions. In other studies, HCTs represented a large percentage of tear types in a series with high overall success rates, but the HCT repair results were not reported separately. For example, Konan and Haddad<sup>50</sup> reported an 85.9% success rate for 312 repairs of meniscal tears, of which 66 were horizontal tears. Kalliakmanis et al.<sup>51</sup> reported a 92.4% success rate for 99 meniscal repairs (including 32 HCTs) performed with FasT-Fix implants, an 87% success rate for 99 meniscal

tears (including 19 HCTs) using the T-Fix implants (Acufex Microsurgical, Mansfield, MA), and an 86.5% success rate for 92 meniscal repairs (including 23 HCTs) performed with RapidLoc implants (DePuy Mitek, Raynham, MA). In each of these series, horizontal tears represented a large percentage of tear types and presumably contributed to the high overall success rates.

### Limitations

This systematic review has several weaknesses. We identified few studies with outcomes data after repair of meniscal HCTs. All but 1 of the studies were retrospective reviews of case series. None were prospective and controlled. Most of the studies did not include imaging or second-look arthroscopy follow-up. The common metric of success in these studies, freedom from reoperation, may not capture all treatment failures, nor do positive clinical results by this metric provide sufficient proof that these tears are capable of healing.

Meniscal repairs for vertical longitudinal tears have lower failure rates, better activity levels, and better long-term patient-reported outcomes than meniscectomy.<sup>4</sup> However, a paucity of literature specifically addressing the clinical results of repairing meniscal HCTs clearly exists. Given the potential to reduce morbidity associated with meniscal pathology, well-designed prospective studies of horizontal repairs should be performed.

## Conclusions

The literature does not support the hypothesis that surgically repaired HCTs have an unacceptably low rate of success. Rather, our results show that existing studies of repaired HCTs show a comparable success rate to repairs of other types of meniscal tears.

## Acknowledgment

We gratefully acknowledge John McCutcheon and Chris Pfaff for their assistance in planning the study and reviewing the manuscript.

## References

- Cullen KA, Hall MJ, Golosinskiy A. Ambulatory surgery in the United States, 2006. *Natl Health Stat Report* 2009;1-25.
- Englund M, Guermazi A, Gale D, et al. Incidental meniscal findings on knee MRI in middle-aged and elderly persons. *N Engl J Med* 2008;359:1108-1115.
- Maak TG, Fabricant PD, Wickiewicz TL. Indications for meniscus repair. *Clin Sports Med* 2012;31:1-14.
- Xu C, Zhao J. A meta-analysis comparing meniscal repair with meniscectomy in the treatment of meniscal tears: The more meniscus, the better outcome? *Knee Surg Sports Traumatol Arthrosc* in press, available online 14 May, 2013. doi:10.1007/s00167-013-2528-6.
- Vidal AF. The save the meniscus society: Commentary on an article by Jeffrey J. Nepple, MD, et al.: "Meniscal repair outcomes at greater than five years. A systematic literature review and meta-analysis." *J Bone Joint Surg Am* 2012;94:e186.
- Baratz ME, Fu FH, Mengato R. Meniscal tears: The effect of meniscectomy and of repair on intraarticular contact areas and stress in the human knee. A preliminary report. *Am J Sports Med* 1986;14:270-275.
- Fukubayashi T, Kurosawa H. The contact area and pressure distribution pattern of the knee. A study of normal and osteoarthrotic knee joints. *Acta Orthop Scand* 1980;51:871-879.
- Voloshin AS, Wosk J. Shock absorption of meniscectomized and painful knees: A comparative in vivo study. *J Biomed Eng* 1983;5:157-161.
- Mow VC, Ratcliffe A, Chern KY, Kelly MA. Structure and function relationships of the menisci of the knee. In: Mow VC, Arnoczky S, Jackson DW, eds. *Knee meniscus: Basic and clinical foundations*. New York: Raven, 1992;37-57.
- Walker PS, Erkman MJ. The role of the menisci in force transmission across the knee. *Clin Orthop Relat Res* 1975;109:184-192.
- Wilson AS, Legg PG, McNeur JC. Studies on the innervation of the medial meniscus in the human knee joint. *Anat Rec* 1969;165:485-491.
- Verdonk P, Vererfve P. Traumatic lesions: Stable knee, ACL knee. In: Beaufils P, Verdonk R, eds. *The meniscus*. New York: Springer, 2010;45-50.
- Seil R, Pape D. Meniscal repair: Biomechanics. In: Beaufils P, Verdonk R, eds. *The meniscus*. New York: Springer, 2010;107-117.
- Boyd KT, Myers PT. Meniscus preservation; rationale, repair techniques and results. *The Knee* 2003;10:1-11.
- Jouve F, Ovadia H, Pujol N, Beaufils P. Meniscal repair: Technique. In: Beaufils P, Verdonk R, eds. *The meniscus*. New York: Springer, 2010;119-128.
- Magnussen RA, Mather RC, Taylor DC. Arthroscopy-assisted inside-out and outside-in meniscus repair. In: Scott WN, ed. *Insall & Scott surgery of the knee*. Ed 5. Philadelphia, PA: Churchill Livingstone, 2012;275-282.
- Starke C, Kopf S, Petersen W, Becker R. Meniscal repair. *Arthroscopy* 2009;25:1033-1044.
- Noyes FR, Barber-Westin SD. Meniscus tears: Diagnosis, repair techniques, and clinical outcomes. In: Noyes FR, ed. *Noyes' knee disorders: Surgery, rehabilitation, clinical outcomes*. Philadelphia, PA: Saunders, 2010;733-771.
- Arnoczky SP, Warren RF. Microvasculature of the human meniscus. *Am J Sports Med* 1982;10:90-95.
- Accadbled F, Cassard X, Sales de Gauzy J, Cahuzac JP. Meniscal tears in children and adolescents: Results of operative treatment. *J Pediatr Orthop B* 2007;16:56-60.
- Kamimura T, Kimura M. Repair of horizontal meniscal cleavage tears with exogenous fibrin clots. *Knee Surg Sports Traumatol Arthrosc* 2011;19:1154-1157.
- Kraus T, Heidari N, Svehlik M, Schneider F, Sperl M, Linhart W. Outcome of repaired unstable meniscal tears in children and adolescents. *Acta Orthop* 2012;83:261-266.
- Krych AJ, McIntosh AL, Voll AE, Stuart MJ, Dahm DL. Arthroscopic repair of isolated meniscal tears in patients 18 years and younger. *Am J Sports Med* 2008;36:1283-1289.
- Pujol N, Bohu Y, Boisrenoult P, Macdes A, Beaufils P. Clinical outcomes of open meniscal repair of horizontal meniscal tears in young patients. *Knee Surg Sports Traumatol Arthrosc* 2013;21:1530-1533.
- Rubman MH, Noyes FR, Barber-Westin SD. Arthroscopic repair of meniscal tears that extend into the avascular zone. A review of 198 single and complex tears. *Am J Sports Med* 1998;26:87-95.
- Scott GA, Jolly BL, Henning CE. Combined posterior incision and arthroscopic intra-articular repair of the meniscus. An examination of factors affecting healing. *J Bone Joint Surg Am* 1986;68:847-861.
- Tengrootenhuysen M, Meermans G, Pittoors K, van Riet R, Victor J. Long-term outcome after meniscal repair. *Knee Surg Sports Traumatol Arthrosc* 2011;19:236-241.
- Tenuta JJ, Arciero RA. Arthroscopic evaluation of meniscal repairs. Factors that effect healing. *Am J Sports Med* 1994;22:797-802.
- Binfield PM, Maffulli N, King JB. Patterns of meniscal tears associated with anterior cruciate ligament lesions in athletes. *Injury* 1993;24:557-561.
- Poehling GG, Ruch DS, Chabon SJ. The landscape of meniscal injuries. *Clin Sports Med* 1990;9:539-549.
- Metcalfe MH, Barrett GR. Prospective evaluation of 1485 meniscal tear patterns in patients with stable knees. *Am J Sports Med* 2004;32:675-680.
- Barber-Westin SD, Noyes FR. Clinical healing rates of meniscus repairs of tears in the central-third (red-white) zone. *Arthroscopy* 2014;30:134-146.
- Andersson-Molina H, Karlsson H, Rockborn P. Arthroscopic partial and total meniscectomy. *Arthroscopy* 2002;18:183-189.

34. Roos EM, Ostenberg A, Roos H, Ekdahl C, Lohmander LS. Long-term outcome of meniscectomy: Symptoms, function, and performance tests in patients with or without radiographic osteoarthritis compared to matched controls. *Osteoarthritis Cartilage* 2001;9:316-324.
35. Scheller G, Sobau C, Bulow JU. Arthroscopic partial lateral meniscectomy in an otherwise normal knee: Clinical, functional, and radiographic results of a long-term follow-up study. *Arthroscopy* 2001;17:946-952.
36. Mills PM, Wang Y, Cicuttini FM, et al. Tibio-femoral cartilage defects 3-5 years following arthroscopic partial medial meniscectomy. *Osteoarthritis Cartilage* 2008;16:1526-1531.
37. Jorgensen U, Sonne-Holm S, Lauridsen F, Rosenklint A. Long-term follow-up of meniscectomy in athletes. A prospective longitudinal study. *J Bone Joint Surg Br* 1987;69:80-83.
38. Wroble RR, Henderson RC, Campion ER, el-Khoury GY, Albright JP. Meniscectomy in children and adolescents. A long-term follow-up study. *Clin Orthop Relat Res* 1992;180-189.
39. McNicholas MJ, Rowley DI, McGurty D, et al. Total meniscectomy in adolescence. A thirty-year follow-up. *J Bone Joint Surg Br* 2000;82:217-221.
40. Medlar RC, Mandiberg JJ, Lyne ED. Meniscectomies in children. Report of long-term results (mean, 8.3 years) of 26 children. *Am J Sports Med* 1980;8:87-92.
41. Kurosawa H, Fukubayashi T, Nakajima H. Load-bearing mode of the knee joint: Physical behavior of the knee joint with or without menisci. *Clin Orthop Relat Res* 1980;149:283-290.
42. Verma NN, Kolb E, Cole BJ, et al. The effects of medial meniscal transplantation techniques on intra-articular contact pressures. *J Knee Surg* 2008;21:20-26.
43. McDermott ID, Lie DT, Edwards A, Bull AM, Amis AA. The effects of lateral meniscal allograft transplantation techniques on tibio-femoral contact pressures. *Knee Surg Sports Traumatol Arthrosc* 2008;16:553-560.
44. Lee SJ, Aadalen KJ, Malaviya P, et al. Tibiofemoral contact mechanics after serial medial meniscectomies in the human cadaveric knee. *Am J Sports Med* 2006;34:1334-1344.
45. Haemer JM, Wang MJ, Carter DR, Giori NJ. Benefit of single-leaf resection for horizontal meniscus tear. *Clin Orthop Relat Res* 2007;457:194-202.
46. Brophy RH, Gill CS, Lyman S, Barnes RP, Rodeo SA, Warren RF. Effect of anterior cruciate ligament reconstruction and meniscectomy on length of career in National Football League athletes: A case control study. *Am J Sports Med* 2009;37:2102-2107.
47. Sihvonen R, Paavola M, Malmivaara A, et al. Arthroscopic partial meniscectomy versus sham surgery for a degenerative meniscal tear. *N Engl J Med* 2013;369:2515-2524.
48. Katz JN, Losina E. Surgery versus physical therapy for meniscal tear and osteoarthritis. *N Engl J Med* 2013;369:677-678.
49. Biedert RM. Treatment of intrasubstance meniscal lesions: A randomized prospective study of four different methods. *Knee Surg Sports Traumatol Arthrosc* 2000;8:104-108.
50. Konan S, Haddad FS. Outcomes of meniscal preservation using all-inside meniscus repair devices. *Clin Orthop Relat Res* 2010;468:1209-1213.
51. Kalliakmanis A, Zourntos S, Bousgas D, Nikolaou P. Comparison of arthroscopic meniscal repair results using 3 different meniscal repair devices in anterior cruciate ligament reconstruction patients. *Arthroscopy* 2008;24:810-816.