

Replantation of an avulsed tooth: a case report

Abstract

A 15 year old boy reported to the Department of Paedodontics and Preventive Dentistry with trauma to upper front region of jaw. On examination, it was noted that 21 and 22 were missing. Patient's parent had preserved 21. The patient was a known case of cryptogenic epilepsy. The case report is about replantation of 21 and replacement of 22 with a removable partial denture.

Keywords: avulsion, replantation, maxillary central incisor

Volume 7 Issue 6 - 2017

Pooja Balgi, Manohar Poojari, Sanmati Pol,
Shilpa Shetty, Farhin Katge

Terna Dental College, India

Correspondence: Pooja Balgi, Post Graduate Student, Terna Dental College, India, Tel 8983225095, Email balgipooja@gmail.com

Received: July 06, 2017 | **Published:** August 09, 2017

Abbreviations: IOPA, intra oral periapical radiograph; PDL, periodontal ligament; APF, acidulated phosphate fluoride

Introduction

Tooth avulsion implies total displacement of the tooth out of its socket. It is a relatively infrequent phenomenon and ranges between 0.5% and 3%. The age range most commonly affected is from 7 to 9 years. This is mainly attributed to the fact that periodontium and bone are very resilient and roots are not completely formed at this age. The maxillary central incisor is the most commonly avulsed tooth.¹ It is often associated with fracture of the alveolar socket and injuries to lips. The factors which determine healing following replantation are the length of extra-alveolar time and storage media. Ankylosis is the most frequent PDL healing complication and the most difficult to diagnose.² The type of storage media also influences the pulpal and periodontal healing post replantation.³

Case presentation

A 15-year old boy presented to the department of Paedodontics and Preventive Dentistry with trauma to maxillary anterior region. While obtaining his medical history, it was found that the patient was a known case of cryptogenic epilepsy and was undergoing treatment for the same. He had sustained an injury to his upper front teeth following an epileptic attack 2 hours before presentation. The patient was assessed for other neurological abnormalities and physical injuries incurred due to trauma. He was conscious and well oriented to time, place and person during examination. On extraoral examination, the upper lip appeared swollen and lacerated on the inner side. Intraoral examination revealed missing maxillary left central (21) and lateral incisor (22) (Figure 1). The anterior maxilla was examined for fracture and any other abnormality. The patient's mother had preserved 21 which she carried to the clinic. An IOPA was advised to rule out intrusion of 22 and to check for any alveolar fracture (Figure 2). An OPG was not advised immediately as the timing of replantation of 21 was crucial. The potential risks associated with replantation in epileptic patients were explained to the parents. After obtaining informed consent from the parents, it was decided to replant 21. The avulsed tooth was inspected for fracture and debris. The crown portion was intact and the root was completely formed. The tooth was carried dry in a handkerchief for more than an hour.

It was washed in saline and the root surface was scrapped with a No. 11 blade to remove the PDL remnants and debris (Figures 3&4). An IOPA of 21 was taken to determine the morphology of canal before beginning with the endodontic procedure. Access opening was done and pulp was extirpated. Following this, another IOPA was taken to determine the working length (Figures 6&7). The cleaning of canal was done with EDTA, saline and povidone iodine (Figures 8&9). Rotary ProTaper file system was used to shape the canal (Figures 8&9). The tooth was treated with 1.23% Acidulated Phosphate Fluoride for 20 mins (Figure 10). The canal was irrigated with saline to remove excess fluoride and obturated using 6% gutta percha cones (Figure 11). The access opening was sealed with light cure composite material. Local anesthesia was administered. Intraorally, the socket of 21 was inspected for loose bony fragments that would interfere with healing (Figure 12). The socket was gently irrigated with saline and povidone iodine without disturbing the coagulum. The tooth was placed back in the socket with light digital pressure (Figure 13). It was secured in place with the help of light cure composite splint. The composite material approximated 11 and 21 together on their mesial surfaces (Figure 14). The composite splint was maintained for 2 weeks. 0.5 ml anti-tetanus booster was administered and oral antibiotics were prescribed for 5 days. Radiographs were taken during 21 days, 3 months and 6 months follow-up (Figures 15–17). The periodontal ligament space and periapical region appeared intact throughout the follow up period. A removable partial denture was fabricated and delivered to replace 22 (Figure 18).¹⁻³

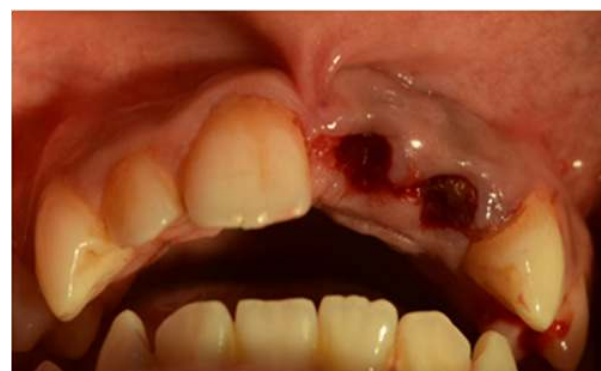

Figure 1 Preoperative intraoral photograph – avulsed 21, 22.

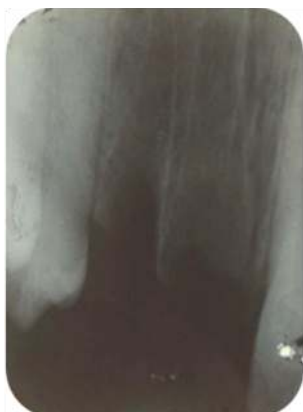

Figure 2 Preoperative intraoral radiograph avulsed 21, 22.



Figure 3 Avulsed tooth in saline.

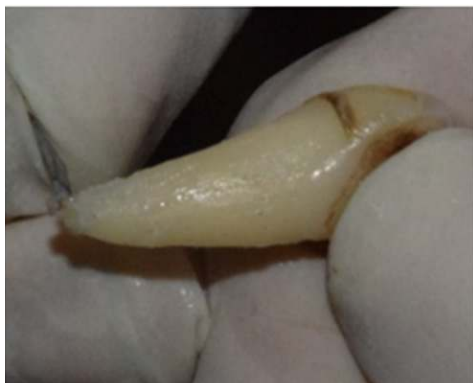

Figure 4 PDL remnants removed with scalpel.

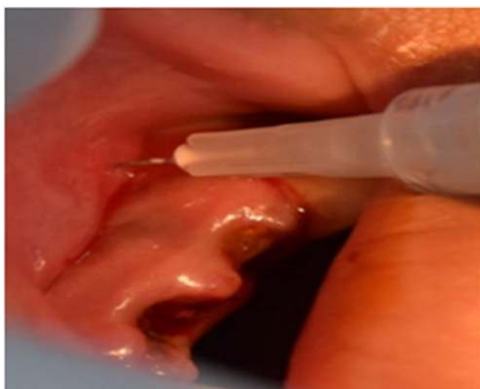

Figure 5 Local anesthesia administered.

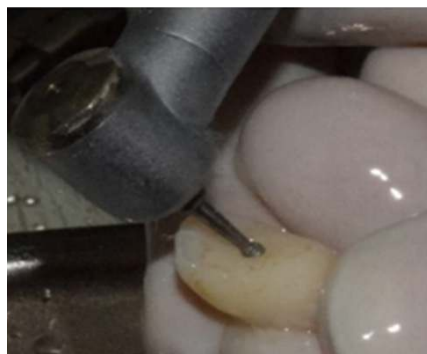


Figure 6 Access opening done with BR-41.

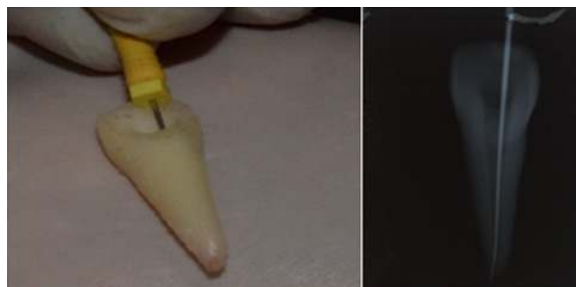


Figure 7 Working length radiograph taken.



Figure 8 Cleaning and shaping of the canal done with EDTA and Rotary Protaper file S1.

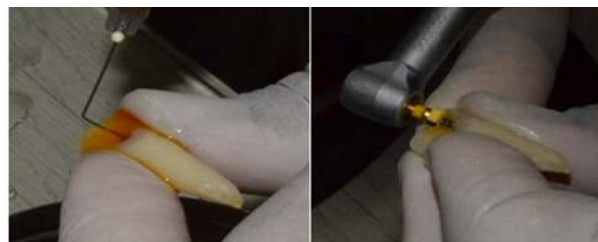

Figure 9 Chemomechanical preparation done with povidone iodine till Rotary ProTaper file F1.



Figure 10 Tooth placed in 1.23% Acidulated phosphate fluoride for 20 min and rinsed with saline.

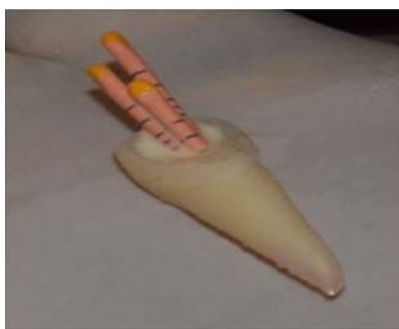

Figure 11 Obturation done with 6% gutta percha cones.

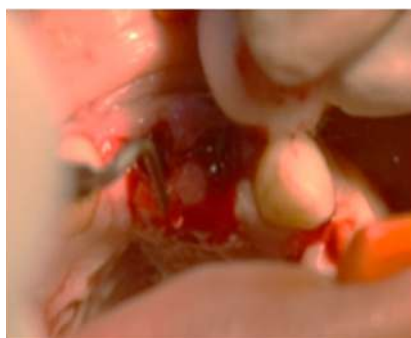

Figure 12 Alveolar socket debrided.

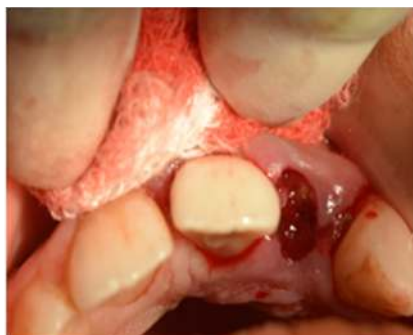

Figure 13 21 replanted in socket.

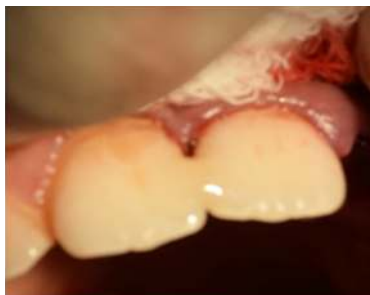
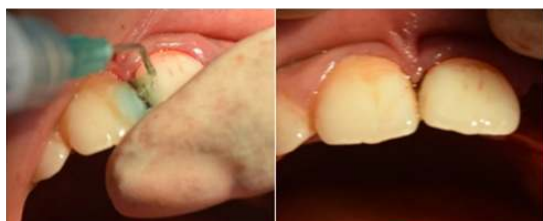
Figure 14 Acid etch composite splint.

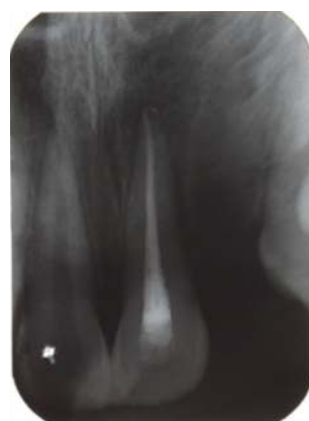

Figure 15 Radiograph taken during follow-up after 21 days.

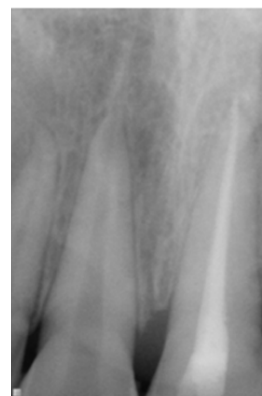
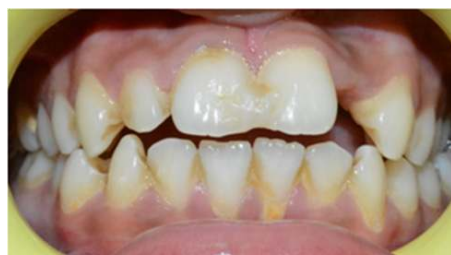
Figure 16 Intra oral photographs of 3 months follow up.

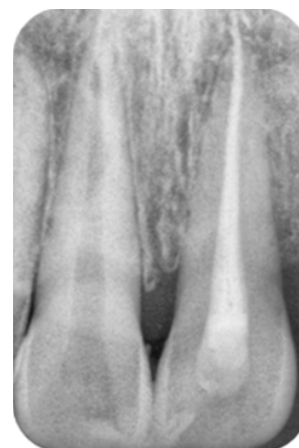


Figure 17 Tooth placed in 1.23% Acidulated phosphate fluoride for 20 min and rinsed with saline.

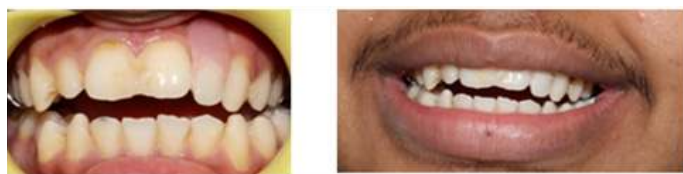

Figure 18 Removable Partial Denture inserted to replace 22.

Discussion

Replacement of an avulsed tooth has been performed in controlled epileptic patients in the past.^{4,5} Immediate replantation strongly contributes to favourable healing of the PDL. In this case, the avulsed tooth was kept in a dry environment for 2 hours. The pulp and periodontal ligament sustain extensive damage and their fate is mainly determined by the extra-oral time and circumstances in which the tooth was preserved.¹ Prolonged extraoral dry storage time is seen to be associated with inflammatory root resorption. The numbers of vital cells are also reduced with an increase in extraoral dry storage time. In an experiment conducted by Andreasen, no viable cells were seen on the root surface after an extraoral period of 2 hours.³ The influence of the storage time appears to be mediated by necrosis of PDL cells. According to a study by Andresen, the thickness of PDL tissue layer also depends upon dry storage. A thick PDL layer tolerates a dry period better, before the layer close to the cementum is destroyed.⁶ With regards to the dry storage time, the pulpal healing was seen to be better than PDL healing. It has been claimed from several in vitro experiments, that the hypotonic nature of saliva can damage periodontal ligament cells.⁷⁻⁹ The physiologic medium used in this report was saline. It was decided to treat the tooth endodontically as the goal was not immediate replantation considering the prolonged extra oral time of the tooth. The chances of retention and prevention of replacement resorption are improved when endodontic treatment is carried out on an avulsed tooth before replantation.¹⁰ The root surface of the avulsed tooth was washed with saline and scrapped with a scalpel to get rid of the PDL remnants. Few authors suggest the use of scaler, curette, pumice prophylaxis, diamond bur, sand paper disk for removal of necrotic PDL cells.¹¹⁻¹⁴ It was later treated with 1.23% APF gel for 15 minutes. Other resorption inhibiting substances that can be used to treat root surface prior to replantation are tetracycline, stannous fluoride, hypochloric acid, calcium hydroxide, alcohol, diphosphonates.¹² However, there is no demonstration of long term resorption inhibition apart from sodium fluoride. Fluoride treatment is advocated in case of delayed tooth replantation assuming that demineralized dentin surface would be more prone to fluoride incorporation and might become more resistant to resorption. It converts the hydroxyapatite on the bone tissues, cementum and dentin, into fluorapatite.¹⁵ Fluoride has also been hypothesized to specifically inhibit clastic cells.¹⁶

It has been manifested that application of acid or alkaline solutions for root surface treatment has not yielded good results. However, utilizing alkaline substances, followed by use of acidic solutions seem to provide more favorable results.¹⁷ Splinting technique should allow physiologic movement of teeth during healing as this reduces the incidence of ankylosis.¹⁸ In a study conducted by Andresen, the duration of splinting was more crucial than the type of splint on PDL healing. Splinting for 6 weeks or more resulted in less desirable prognosis.⁶ In this case, the tooth was splinted with composite resin for 2 weeks. An arch wire was not used so as to avoid undesirable

consequences should the patient witness another epileptic attack. The possible consequences in this case are inflammatory resorption and replacement resorption which may be evident 2-6 months later. There is considerable reduction in the risk of inflammatory resorption if it is not detected within 2 years.¹⁹ At the subsequent visits, it is prudent to take new radiographs to reveal the condition of the PDL space, periapical region and level of alveolar crest. Clinically, gingival healing or level of attachment must be examined to recognize any pathology related to the attachment apparatus. The main objective of replantation of 21 was to preserve the alveolar bone height in the young patient. It also preserves the arch length and ensures esthetics. The latter one was the chief concern of this adolescent patient. Likewise, it prevents psychologic trauma associated with missing anterior tooth. Owing to this, a RPD was fabricated to replace 22. The patient in this case report was an adolescent. A more definite prosthesis such as an implant will be planned after the growth period is complete. The follow up period being short in this case is not justified to determine the long term prognosis of the avulsed tooth. It is therefore, important to have an extensive follow up period to determine and intervene undesirable consequences, once revealed.

Funding

None.

Acknowledgments

None.

Conflicts of interest

Author declares that there is no conflict of interest.

References

1. Andreasen JO, Andreasen FM. Textbook and color atlas of traumatic injuries to the teeth. 4th ed, Europe: Blackwell Publishing Company, Denmark; 2007. p. 1-444.
2. Andersson L, Malmgren B. The problem of dentoalveolar ankylosis and subsequent replacement resorption in the growing patient. *Aust Endod J.* 1999;25(2):57-61.
3. Andreasen JO. Effect of extra-alveolar period and storage media upon periodontal and pulpal healing after reimplantation of mature permanent incisors in monkeys. *Int J Oral Surg.* 1981;10(1):43-53.
4. Duggal MS, Toumba KJ, Russell JL, et al. Replantation of avulsed permanent teeth with avital periodontal ligaments: case report. *Endodont Dent Traumatol.* 1994;10(6):282-285.
5. Shetty RM, Goyal A, Reddy H, et al. Frog appliance- An innovative treatment option for the replacement of missing teeth in an epileptic child. *J Clin Diagn Res.* 2015;9(5):ZD11-ZD12.
6. Andreasen JO, Borum MK, Jacobsen HE, et al. Replantation of 400 avulsed permanent incisors- Factors related to periodontal ligament healing. *Endod Dent Traumatol.* 1995;11(2):76-89.
7. Blomloe E, Otteskog P. Viability of human periodontal ligament cells after storage in milk or saliva. *European Journal of Oral Sciences.* 1980;88(5):436-440.
8. Layug ML, Barrett EJ, Kenny DJ. Interim storage of avulsed permanent teeth. *J Can Dent Assoc.* 1998;64(5):357-363.
9. Blomlof L. Milk and saliva as possible storage media for traumatically exarticulated teeth prior to replantation. *Swed Dent J.* 1981;8:1-26.

10. Ize-Iyamu IN, Saheeb B. Reimplantation of avulsed dry permanent teeth after three days: A report of two cases. *Niger J Clin Pract.* 2013;16(1):119–122.
11. Sardana D, Goyal A, Gauba K. Delayed replantation of avulsed tooth with 15-hours extra-oral time: 3-year follow-up. *Singapore Dent J.* 2014;35:71–76.
12. Kenny DJ, Barrett EJ, Johnson DH, et al. Clinical management of avulsed permanent incisors using Emdogain: initial report of an investigation. *J Can Dent Assoc.* 2000;66(1):21.
13. Selvig KA, Bjorvatn K, Claffey N. Effect of stannous fluoride and tetracycline on repair after delayed replantation of root-planed teeth in dogs. *Acta Odontol Scand.* 1990;48(2):107–112.
14. Ripamonti U, Petit JC. Patterns of healing on replanted baboon incisors coated with an allogeneic fibrin-fibronectin protein concentrate. *J Periodontal Res.* 1989;24(5):335–342.
15. Bjorvatn K, Massler M. Effect of fluorides on root resorption in replanted rat molars. *Acta Odontol Scand.* 1971;29(1):17–29.
16. Panzarini SR, Gulinelli JL, Poi WR, et al. Treatment of root surface in delayed tooth replantation: A review of literature. *Dent Traumatol.* 2008;24(3):277–282.
17. Panzarini SR, Carvalho AC, Poi WR, et al. Use of vitamin C in delayed tooth replantation. *Brazilian dental journal.* 2005;16(1):17–22.
18. Finucane D, Kinirons MJ. External inflammatory and replacement resorption of luxated, and avulsed replanted permanent incisors: A review and case presentation. *Dent Traumatol.* 2003;19(3):170–174.
19. Puri S, Tripathi S, Pandya M, et al. Reimplantation of avulsed teeth after dry storage for one week. *Int J Clin Den Sci.* 2011;2(3):18–22.