

REPORT OF THIRTEEN CASES OF MUCORMYCOSIS

M. MOGHADDAMI, Ph.D.,* M. MOHRAZ, M.D.,** AND
M.R. SHIDFAR, Ph.D.*

From the *Department of Parasitology and Medical Mycology, School of Public Health, and the
**Department of Infectious Disease, Imam Khomeini Medical Center, Tehran University of Medical
Sciences, Tehran, Islamic Republic of Iran.

ABSTRACT

Thirteen cases of mucormycosis in ten diabetics, one leukemic, and one burned patient, and one in an apparently normal person are reported. The presenting form included rhinocerebral in 11 and cutaneous in two cases. The diagnosis was established by KOH preparation and biopsy and it was confirmed with culture. *Rhizopus sp.* was the causative agent in 11 and *Mucor sp.* in one case. Amphotericin B was administered in 10 patients as soon as the diagnosis of mucormycosis was made. Of these, four patients survived.
MJIRI, Vol. 7, No. 3, 175-178, 1993.

INTRODUCTION

Mucormycosis is an opportunistic fungal infection caused by members of the order *Mucorales*. It usually affects patients with predisposing disease such as uncontrolled diabetes mellitus, lymphoma, malnutrition, severe burns, and immunosuppressive therapy.¹⁻³ Recently, several cases are reported in healthy individuals.^{4,12} The main clinical forms of the disease are rhinocerebral, pulmonary, disseminated, cutaneous and gastrointestinal.^{2,11,12} The rhinocerebral form of zygomycosis is the most common and often fatal. This form is typically observed in insulin-dependent diabetes mellitus with ketoacidosis.^{1,13} Widespread cutaneous mucormycosis has been described in patients with burns.²

The diagnosis is achieved by demonstrating broad, non-septate hyphae with right-angle branching in a tissue biopsy specimen.¹² Successful treatment consists of early diagnosis, systemic antifungal therapy with amphotericin B, surgical debridement, and control of the underlying disease.^{12,14,15}

In this paper we present 13 cases of mucormycosis in patients with and without underlying disease during the past nine years.

MATERIAL AND METHODS

The specimen for mycological study included nasal,

sinus, and eye discharges, also necrotic and biopsy materials were obtained from the palate, nose, and skin lesions. Microscopic examination of the discharges were performed by KOH wet mount and Giemsa staining.

The tissue sections were stained by Hematoxylin and Eosin (H and E) and periodic acid schiff (PAS) stains. Discharges or ground tissues were cultured on Sabouraud dextrose agar, and Sabouraud dextrose agar with Chloramphenicol 50 mg/mL (Difco). Microscopic features of the isolates were studied by slide culture preparation.

RESULTS

During nine years from 1984 to 1993, thirteen cases of mucormycosis were diagnosed by histology and mycological methods. The details of the cases are given in Table I. Patients ranged in age from 10 to 70 years. Seven of them were male and six were female. Eleven patients had rhinocerebral mucormycosis (RCM) (Fig. 1). Diabetes mellitus was present in ten and acute lymphocytic leukemia (ALL) in one patient. The blood glucose level was between 300-760 mg/100 mL in diabetic patients. In 10 patients direct and histopathological examinations were positive (Figs. 2,3), in nine of which *Rhizopus sp.* was isolated in culture (Fig. 4). In one case direct examination of the nasal discharges and biopsy of maxillary sinus was negative but the colonies of *Rhizopus sp.* were isolated in heavy and pure growth from biopsy specimen of left maxillary sinus

Mucormycosis

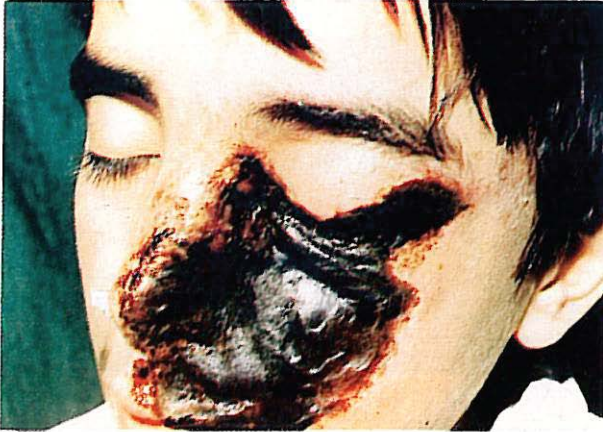

Fig. 1. Rhinocerebral mucormycosis in a diabetic patient.

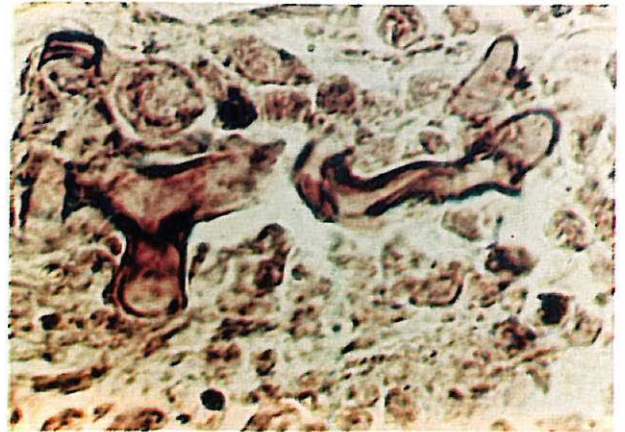

Fig. 3. Ribbon-like hyphae in tissue (PAS \times 1000).

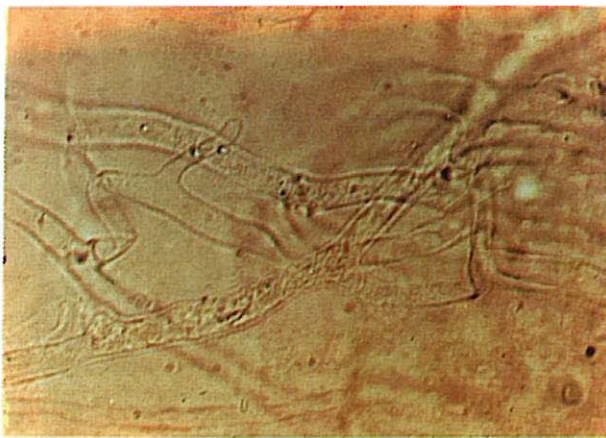

Fig. 2. Direct microscopy of nasal discharges prepared in potassium hydroxide solution, showed broad and branching hyphae (\times 400).

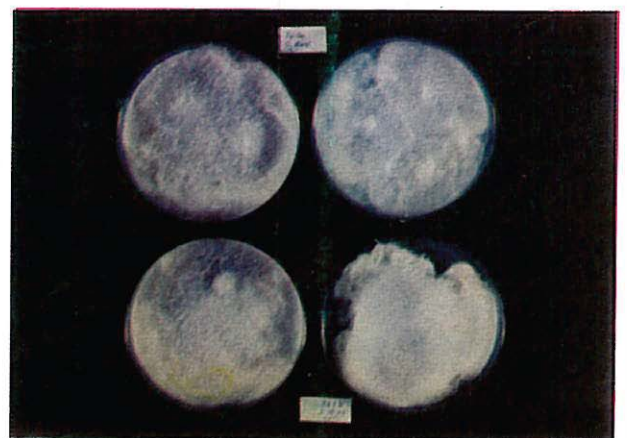


Fig. 4. Colonies of *Rhizopus* sp. on Sabouraud dextrose agar and brain heart infusion agar at both 30° and 37°C.

on Sabouraud dextrose agar. Four of the patients survived by treatment with amphotericin B and debridement and the others died.

In two patients cutaneous mucormycosis was observed. One was in a 13-year-old girl who had burns measuring 40% total body surface (both lower extremities). Biopsy of the burn wound performed 20 days post-burn revealed large non-septate hyphae on tissue sections which was later identified as *Mucor* sp. on culture. In this case the fungi were eradicated by debridement before it could invade the viable subcutaneous tissues. In another case multiple nodular lesions were noticed in a healthy 10-year-old boy. Physical examination at the time of admission showed no abnormality except a nodule on the left side of his thyroid which was suggested to be a cold abscess and was surgically removed. After operation several painful, hard nodules appeared on his left thigh, right leg, and left ankle. A couple of days later the nodules softened and fistulized. Laboratory examination revealed no abnormal features. Discharges of the skin lesions and also the biopsy

of the thigh lesion were negative for fungi. He died suddenly before diagnosis was made.

DISCUSSION

Rhinocerebral mucormycosis is often a fatal condition and is characterized by an aggressive necrotizing infection spreading from the nose to the paranasal area, orbit and hence to the central nervous system.¹⁶ The infection begins less commonly in the palate or pharynx.¹⁷ The organism spreads by direct extension or by invading blood vessels and may present as proptosis or visual loss. If the carotid artery is involved, the prognosis for survival would be poor.¹ This form of the disease is usually observed in patients with insulin-dependent diabetes mellitus with ketoacidosis, leukemia or patients who receive immunosuppressive therapy.^{13,17} Systemic or local acidosis may interfere with phagocyte mobilization and function, this may favour infection by the mucorales.¹³ Similarly, the

Table I. Characteristics of mycologically positive cases of mucormycosis

Case No.	Age (years)	Sex	Residential area	Type of infection	Underlying disease	Direct examination	Causative agent
1	70	M	Tehran	Rhinocerebral	Diabetes mellitus	Positive	<i>Rhizopus sp.</i>
2	33	F	Naishabour	Rhinocerebral	Diabetes mellitus	Positive	<i>Rhizopus sp.</i>
3	60	F	Neka	Rhinocerebral	Diabetes mellitus	Positive	Negative
4	37	M	Ahvaz	Rhinocerebral	Diabetes mellitus	Positive	<i>Rhizopus sp.</i>
5	22	M	Tehran	Rhinocerebral	Diabetes mellitus	Positive	<i>Rhizopus sp.</i>
6	16	F	Ghom	Rhinocerebral	Diabetes mellitus	Positive	<i>Rhizopus sp.</i>
7	15	M	Arak	Rhinocerebral	Diabetes mellitus	Positive	<i>Rhizopus sp.</i>
8	29	F	Tehran	Rhinocerebral	Diabetes mellitus	Negative	<i>Rhizopus sp.</i>
9	31	M	Tehran	Rhinocerebral	Diabetes mellitus	Positive	<i>Rhizopus sp.</i>
10	31	F	Zanjan	Rhinocerebral	Diabetes mellitus	Positive	<i>Rhizopus sp.</i>
11	11	M	Kerman	Rhinocerebral	ALL	Positive	<i>Rhizopus sp.</i>
12		F	Tehran	Cutaneous	Burn	Positive	<i>Mucor sp.</i>
13	10	M	Tehran	Cutaneous	—	Positive	<i>Rhizopus sp.</i>

fungus obstructs blood vessels, causing a decrease in tissue oxygenation, which leads to more acidosis. This condition allows the fungal organisms to proliferate and to damage more vessels.¹⁴

Mucormycosis should be suspected in cases of active sinusitis, epistaxis, ecchymosis and dehydration in immunosuppressed patients.¹⁸ Also it should be noticed that the rapid progression of signs and devastating visual loss suggest mucormycosis.¹ In the present study of 11 cases of rhinocerebral mucormycosis (RCM), 10 occurred in diabetics and one in a leukemic patient. Accurate and rapid diagnosis of mucormycosis and/or histopathological examination of biopsy material is best undertaken to establish the causative agent of infection.^{3,19} Amphotericin B therapy combined with aggressive surgical debridement have been the primary modes of treatment.¹⁴ Of the studied patients, most cases (84.6%) were positive both in direct examination and culture. Four patients with rhinocerebral mucormycosis survived by treatment with amphotericin B and debridement but all of them lost vision. The others died before diagnosis or after a short period of initiation of treatment. In two patients the symptoms were inadvertently overlooked so early diagnosis was delayed. They underwent different antibiotic therapies with the supposed diagnosis of bacterial infection. In another case, amphotericin B was not available so the patient died before treatment could be started. If the diagnosis had been made early and treatment was administered immediately after the diagnosis of RCM was made, some of them might have survived. On the other hand, the mortality rate of our patients are similar to those reported by Ochi et al. and Chetchotisakd et al. which

despite antifungal therapy with amphotericin B and debridement, had mortality rates of 82% and 72.2%, respectively.^{20,21} More than 80% of the culturally proven human and animal cases are caused by *Rhizopus*, *Rhizomucor*, and *Absidia* spp.^{10,22} Also it was shown that regardless of the source of the thermotolerant species of *Rhizopus*, most isolates of *Rhizopus* were consistently more pathogenic than isolates of *Absidia corymbifera* or *Rhizomucor pusillus*.²³ Of 13 reported cases of mucormycosis, 11 were caused by *Rhizopus* sp.

Mucormycosis of the skin is rare and diagnosis is often delayed.¹⁹ The Mucorales such as *Mucor* or *Rhizopus* initially colonize the surface of the burn wound, then extend into viable subcutaneous fat and invade the vessels, producing thrombosis and tissue necrosis.²⁴ A awareness of the clinical appearance of the lesion is essential for early diagnosis in order to facilitate early treatment which may favorably affect the prognosis.¹¹ It is necessary to obtain skin biopsy early when a suspicious lesion exists in the compromised patients.²⁵

The cutaneous infection is characterised by infarction of the skin with black necrotic debris,¹¹ which were successfully treated with debridement alone or in combination with amphotericin B administration.²⁶ Of the two presented cutaneous mucormycoses one was observed in a burned patient, in which the fungi were eradicated by debridement. The causative agent was *Mucor* sp. Another case of cutaneous mucormycosis was seen in a patient having neither diabetes nor any other predisposing disease. It is assumed that he was infected either by elasticized adhesive tape in the post-surgical dressing or from the surgical wound. He was treated

Mucormycosis

with different antibiotics with the assumption of bacterial infection but his situation was not improved. The diagnosis was made too late so he died before initiation of the treatment.

ACKNOWLEDGEMENT

We would like to thank Dr. Shafiei and Dr. Ghavamzadeh for their sincere help.

REFERENCES

1. Galetta SL, Wulc AE, Goldberg HI, Nichols CW, Glaser JS: Rhinocerebral mucormycosis: management and survival after carotid occlusion. *Ann Neurol* 28(1): 103-7, 1990.
2. Koren G, Polacheck I, Kaplan H: Invasive mucormycosis in a non-immunocompromised patient. *J Infection* 12: 165-7, 1986.
3. Norden G, Bjorck S, Persson H, Svalander C, Li X, Edebo L: Cure of zygomycosis caused by a lipase-producing *Rhizopus rhizopodiformis* strain in a renal transplant patient. *Scand J Infect Dis*. 23: 377-82, 1991.
4. Povedano-Rodriguez V, Mellado-Rubio R, Cantillo-Banos E, Lopez-Villarejo P: Rhinocerebral mucormycosis. *An-Otorrinolaringol-Ibero-Am*. 18(2): 139-46, 1991.
5. Prevoo RL, Starink TM, De-Haan P: Primary cutaneous mucormycosis in a healthy young girl. Report of a case caused by *Mucor heimalis*. *J Am Acad Dermatol*. 24(5 Pt 2): 882-5, 1991.
6. De-Biscop J, Mondie JM, Venries-De-La-Guillaumie B, Peri G: Mucormycosis in an apparently normal host. Case study and literature review. *J Craniomaxillofac Surg*. 19(6): 275-8, 1991.
7. Bhattacharyya AK, Deshpande AR, Nayak SR, Kirtane MV, Vora IM: Rhinocerebral mucormycosis: an unusual case presentation. *J Laryngol Otol* 106(1): 48-9, 1992.
8. Akpunonu BE, Ansel G, Kaurich JD, Savolaine ER, Campbell EW, Myles JL: Zygomycosis mimicking paranasal. *Am J Trop Med Hyg* 45(3): 390-8, 1991.
9. Majid AA, Yui NW: Granulomatous pulmonary zygomycosis in a patient without underlying illness. Computed tomographic appearances and treatment by pneumonectomy. *Chest* 100(2): 560-1, 1991.
10. Wang JJ, Satoh H, Takahashi H, Hasegawa A: A case of cutaneous mucormycosis in Shanghai, China. *Mycosis*. 33(6): 311-5, 1990.
11. Record NB, Ginder DR: Pulmonary phycomycosis without obvious predisposing factors. *JAMA* 235(12): 1256-7, 1976.
12. Harris: hospital perspective. *Ala Med* 60(1-2), 38, 40-1, 1990.
13. Melro M, Kaimen MI, Tiraboschi N, Botargues M, Radisic M: Rhinosinuso-orbital mucormycosis. *Medicine B Aires* 51(1): 53-5, 1991.
14. Couch L, Theilen F, Mader J: Rhinocerebral mucormycosis with cerebral extension successfully treated with adjunctive hyperbaric oxygen therapy. *Arch Otolaryngol Head Neck Surg* 114-791-4, 1988.
15. Gans R, Strack VS, Laorman D, Stilma JS, Thijs LG: Fatal rhinocerebral mucormycosis and diabetic ketoacidosis. *Neth. J Med* 34(1-2): 29-34, 1989.
16. Fisher EW, Toma A, Fisher PH, Cheesman AD: Rhinocerebral mucormycosis: use of liposomal amphotericin B. *J Laryngol Otol* 105(7): 575-7, 1991.
17. Rippon JW: Zygomycosis. In: *Medical Mycology. The Pathogenic Fungi and the Pathogenic Actinomycetes*. Philadelphia: W.B. Saunders, 681-713, 1988.
18. El-Ani AS, Dhar AV: Disseminated mucormycosis in a case of metastatic carcinoma. *Am J Pathol* 77(1): 110-5, 1982.
19. Kerr PG, Turner H, Pavidson A, Bennett C, Maslen M: Zygomycosis requiring amputation of the hand: an isolated case in a patient receiving haemodialysis. *Med J Australia* 148: 258-9, 1988.
20. Ochi JW, Harris JP, Feldman JI, Press GA: Rhinocerebral mucormycosis: results of aggressive surgical debridement and amphotericin B. *Laryngoscope* 98(12): 1339-42, 1988.
21. Chetchotisakd P, Boonma P, Sookpranee M, Pairojkul C: Rhinocerebral mucormycosis: a report of eleven cases. *Southeast Asian J Trop Med Public Health* 22(2): 268-73, 1991.
22. England AC, Weinstein M, Ellner J, Ajello L: Two cases of rhinocerebral mucormycosis with common epidemiologic and environmental features. *Am Rev Respir Dis* 124: 497-8, 1981.
23. Reinhardt DJ, Licata I, Kaplan W, Ajello L, Chandler FW, Ellis JJ: Experimental cerebral zygomycosis in alloxan-diabetic rabbits: variation in virulence among zygomycetes. *Sabouraudia* 19: 245-55, 1981.
24. Moghaddami M, Emami M: Study of fungal infection in burn patients. *Acta Medica Iranica*. 29(1-2): 61-7, 1987.
25. Sheldon DL, Johnson WC: Cutaneous mucormycosis. *JAMA*. 241(10): 1032-4, 1979.
26. Tanphaichitr VS, Chairprasert A, Suvatte V, Thasnakorn P: Subcutaneous mucormycosis caused by *Saksenea vasiformis* in a thalassemic child: first case report in Thailand. *Mycoses* 33(6): 303-9, 1990.