

Reproducibility of Retinal Mapping Using Optical Coherence Tomography

Pascale Massin, MD; Eric Vicaut, MD, PhD; Belkacem Haouchine, MD; Ali Erginay, MD; Michel Paques, MD; Alain Gaudric, MD

Objective: To assess the reproducibility of retinal thickness measurement using commercially available mapping software of optical coherence tomography (OCT).

Methods: Six radial scans, 6 mm long and centered on the fixation point, were performed on 10 eyes of 10 healthy volunteers and 10 eyes of 10 diabetic patients with clinically significant macular edema. Retinal thickness was measured automatically using the mapping software of OCT in the 9 macular Early Treatment Diabetic Retinopathy Study areas and in a central area 500 μm in diameter. Measurement reproducibility was tested by means of 3 series of scans performed by 2 different observers on 2 different days. Results were assessed by their repeatability and intraclass correlation coefficients (ICCs).

Results: In healthy subjects, intraobserver, interobserver, and intervisit reproducibility of retinal thickness measurements were excellent, with a repeatability coefficient of less than 7 μm and ICCs of greater than 0.89. In diabetic patients, the repeatability coefficient was less than 21 μm in all areas of the macula except one, with an ICC of greater than 0.98. Relative variations in measurements were small in both healthy and diabetic subjects, with reproducibilities of $\pm 5\%$ and $\pm 6\%$, respectively.

Conclusion: Retinal mapping software of OCT allows reproducible measurement of retinal thickness in both healthy subjects and diabetic patients with macular edema.

Arch Ophthalmol. 2001;119:1135-1142

MANY RETINAL diseases affect retinal thickness, the main disease being macular edema. Diabetic macular edema is defined by retinal thickening involving or threatening the center of the macula. The methods available for assessing macular thickness at present are slitlamp biomicroscopy and stereoscopic photography. However, both are qualitative, and both are insensitive to small changes in retinal thickness. Consequently, new methods of measuring retinal thickness have been developed.¹⁻⁵ Optical coherence tomography (OCT) is a technique based on low-coherence interferometry that provides optical cross-sectional images of the eye.^{4,5} It allows measurement of retinal thickness from the tomograms by means of computer image-processing techniques. Since the commercialization of OCT equipment, several software programs have become available. The A-5 software release for the Humphrey optical coherence tomography scanner (A-5 software); (Humphrey Instruments, Inc, San Leandro, Calif) can display a 2-dimensional color-coded map of retinal thick-

ness of the posterior pole and give the average retinal thickness of 9 different areas of it.⁶ Good reproducibility of retinal thickness measurements from a single scan or from a circular scan around the optic disc using OCT prototype systems or commercially available equipment has been reported.⁷⁻⁹ However, to our knowledge, no reproducibility study with mapping software has been published. The purpose of this study was to assess the reproducibility of retinal thickness measurements in healthy subjects and diabetic patients with visual impairment due to macular edema, using the A5 mapping software of OCT, to test their relevance to clinical practice.

RESULTS

The means and SDs of the measurements performed at each session in each area of the macula (A1-A10) and at its center are given in **Table 1** and **Table 2**. The means and SDs of the differences between the retinal thickness measurements made under different conditions (change of observer or visit) in healthy and diabetic subjects and the ICCs are shown in Tables 1 and 2 and **Table 3**.

From the Department of Ophthalmology, Hôpital Lariboisière, Assistance Publique-Hôpitaux de Paris (Drs Massin, Haouchine, Erginay, Paques, and Gaudric), and Laboratoire d'Etude de la Microcirculation, Hôpital Fernand Widal (Dr Vicaut), Université Paris, Paris, France. The authors have no proprietary interest in this study.

SUBJECTS AND METHODS

SUBJECTS

The reproducibility of retinal thickness measurement was assessed in 10 eyes (4 right and 6 left) of 10 healthy volunteers (6 men and 4 women, aged 24 to 52 years [mean age, 35 years]). The study protocol was approved by the Ethics Committee of the Hospital Saint-Louis, Paris, France, and all volunteers signed a consent form. Before OCT examination, visual acuity was measured, with the pupils dilated by using 1 drop each of 2.5% phenylephrine hydrochloride and 0.5% tropicamide. Biomicroscopic funduscopy was performed to ensure that the fundus was healthy. In all cases, visual acuity was 20/25 or better, and refraction was within 2 diopters of emmetropia.

Retinal thickness reproducibility was also assessed in 10 eyes (5 left and 5 right) of 10 diabetic patients with retinal thickening involving the center of the macula, ie, clinically significant macular edema as defined by the Early Treatment Diabetic Retinopathy Study (ETDRS),¹⁰ and impaired visual acuity. Visual acuity was less than 20/40 in all cases (range, 20/125-20/40; median, 20/100). This group included 6 men and 4 women with a mean age of 61 years (range, 34-82 years). Five patients had type 2 diabetes and 5, type 1 diabetes; mean duration, 15 years. Five patients had nonproliferative diabetic retinopathy, and 5, proliferative diabetic retinopathy treated with panretinal photocoagulation. Four had undergone focal laser photocoagulation for macular edema. Hard exudates were present in 3 patients.

OPTICAL COHERENCE TOMOGRAPHY

Optical coherence tomography was performed using commercially available equipment (Humphrey Instruments, Inc) derived from the prototype described by Hee and coworkers.⁵ The principle of OCT is based on low-coherence interferometry. The light source is a superluminescent diode operating at 840 nm, which provides a probe beam of low-coherence light on the retina. Cross-sectional tomographic images (B-scans) are constructed by integrating 100

axial measurements (A-scans) obtained in 1 second while scanning the probe beam across the retina. Lateral resolution is limited by the separation between 2 adjacent scans on the retina; this separation was 60 μm for the 6-mm scans used in this study. The longitudinal definition is about 13 μm . The images are displayed in false color. Bright colors (red to white) correspond to high reflectivity; dim colors (blue to black), minimal reflectivity.

Retinal thickness was measured automatically using the A-5 software. For each A-scan, the anterior and posterior boundaries of the retina are identified by a thresholding algorithm that searches for the point on each A-scan at which the reflectivities exceed a certain threshold (**Figure 1**). Linear interpolation is performed to remove any gaps in the boundaries resulting from shadowing due to blood vessels or exudates. Retinal thickness is calculated as the distance between the vitreoretinal interface and the anterior boundary of the red reflective layer corresponding to the retinal pigment epithelium (RPE) and choriocapillaris.

To measure macular thickness, we used the retinal mapping program of the A-5 software.⁶ Six OCT scans 6 mm long were obtained in a radial spoke pattern centered on the patient's fixation point, through a dilated pupil (**Figure 2A**). Scanning was performed using an internal fixation beam. Each of the 6 tomograms contained 100 equally spaced axial profiles of optical reflectivity. Thus, retinal thickness was measured at a total of 600 points along these 6 intersecting lines, with 6 of these measurements located in the central fovea. Retinal thickness was displayed first as a 2-dimensional color-coded map, with brighter colors indicating areas of increased retinal thickness (**Figure 3** and **Figure 4**). Then, for quantitative evaluation, the macula was divided into 9 ETDRS areas,¹⁰ including a central disc with a diameter of 1000 μm and an inner and outer ring, each divided into 4 quadrants, with diameters of 3000 and 6000 μm , respectively (Figure 2B). The average thickness of each of the 9 areas (A1-A9) was calculated. The number of measured points differs from one region to another. If there are 100 values measured per scan length of 6 mm, the number of points measured in each ETDRS region can be calculated and reported for comparison per surface area

Whichever observer or visit was considered, mean retinal thickness values in healthy subjects were very similar (Table 1). Reproducibility was good, because whichever change was considered, the repeatability coefficient was less than 7 μm for all macular areas except 2, and at worst it was 14 μm (ie, at the center or in A10). These values for healthy subjects, based on retinal thickness measurements performed by the same examiner on the same day or 2 different days, displayed only small relative variations in all the ETDRS areas, and the reproducibility of retinal thickness measurements was $\pm 5\%$. In addition, ICCs were always greater than or equal to 0.89 (Table 3). The intraobserver, interobserver, and intervisit measurements were highly reproducible. No significant difference was found for any of the areas studied, whether the measures were recorded by different observers or during different visits.

The intrasession reproducibility of the measurements in healthy subjects was high. The mean coefficient of variation was less than 1.5% for all ETDRS areas, as seen in the following tabulation:

Macular Area	Mean (\pm SD) Coefficient of Variation, %
A-1	1.3 \pm 0.7
A-2	0.7 \pm 0.3
A-3	0.7 \pm 0.3
A-4	0.6 \pm 0.6
A-5	0.7 \pm 0.3
A-6	0.8 \pm 0.6
A-7	0.7 \pm 0.4
A-8	0.7 \pm 0.4
A-9	0.9 \pm 0.3
A-10	2.5 \pm 1.5
Center	3.3 \pm 1.9

Mean absolute changes in 2 measures of retinal thickness, made at 2 different examinations, were significantly larger in diabetic than in healthy subjects. However, both measures were still very close. Indeed, reproducibility was also very good in this group, since the repeatability coefficient was less than 21 μm in all areas of the macula except A6, for which it was 27 μm . As the average retinal thicknesses measured in the dia-

unit. The thickness of the central area A1 with a diameter of 1 mm is the average of 100 measurements, ie, 127 measurements per square millimeter. The thickness of each middle area (A2-A5) is the average of 50 measurements; each outer area (A6-A9), 75 measurements. The mean thickness corresponds to 32 and 14 measurements, respectively, per square millimeter. The reproducibility of the measurements was tested in the 9 ETDRS regions of the macula.

However, an area with a diameter of 1000 μm is too large to account for the thickness of the foveolar region, which corresponds to an area about 350 μm in diameter. Therefore, we also measured the average thickness of a central macular region (A10) with a diameter of 500 μm , and tested the reproducibility of this measurement. In addition, the central foveolar thickness was calculated as the average of the 6 measurements performed at the intersection of the 6 radial scans.

STUDY PROTOCOL

Three series of 6 scans were performed on 1 eye of each healthy subject during the same session by 2 trained examiners. The first series, consisting of 6 consecutive radial scans, was performed by examiner 1 (B.H.). The patient then sat back from the machine for at least 5 minutes before being repositioned. The second series of scans was then performed by examiner 2 (A.E.). After another rest period, a third series was performed, again by examiner 1 (B.H.). To assess intervisit reproducibility, an additional series of 6 scans was performed 1 week later by examiner 1 (B.H.). For each scan, images were optimized to obtain the highest intensity and definition of the inner and outer bands by altering the intensity of the incident light.

In the healthy subjects, the following 3 reproducibility variables were assessed: intraobserver reproducibility, by comparing the results of the 2 examinations performed during the same day by the same examiner; interobserver reproducibility, by comparing the results of the 2 examinations performed during the same day by 2 different examiners; and intervisit reproducibility, by comparing the results of the 2 examinations performed at a 1-week interval by the same examiner.

In the diabetic patients, because macular edema may vary from one visit to another, and because our initial data showed that interobserver reproducibility was good, we tested only intraobserver reproducibility. To assess intraobserver reproducibility, 2 series of 6 scans were performed on each diabetic patient during the same session by the same examiner, and the results for each series were compared.

STATISTICAL ANALYSIS

For healthy subjects and diabetic patients, the mean and SD of the retinal thickness measurements made in each area of the macula and at its center were first calculated for each observer and visit. Reproducibility of retinal thickness measurements was assessed by the repeatability and intraclass correlation coefficients (ICCs).

The reproducibility of the measurements made in the same subject was described by the mean and SD of the difference between measurements made under different conditions (change of observer or visit). This allowed calculation of the repeatability coefficient adopted by the British Standards Institution as 2 SDs of the difference between measurements in the same subject.¹¹ In addition, intraobserver, interobserver, and intervisit reproducibility were estimated using the ICC determined on the basis of an analysis of variance for mixed models corresponding to each situation, and calculated as proposed by Bartko and Carpenter¹² by the following equation:

$$ICC = \frac{(\text{Within Variance} - \text{Between Variance})}{(\text{Within Variance} + \text{Between Variance})}$$

where within and between variance refer to within- and between-subject variance, respectively. The ICC is commonly used to measure reliability. A higher ICC indicates better reproducibility of the method.

In addition, for healthy subjects, the coefficient of variation of the measurements obtained for the same subject during each visit was calculated for each area and averaged among the 10 subjects studied.

All tests were performed using commercially available software (Biomedical Data Package; University of California-Los Angeles).

betic patients for the peripheral and central areas were, respectively, 149% and 233% of the corresponding thicknesses measured in the healthy subjects, the relative variations in the measurements were very small and their reproducibility was $\pm 6\%$. In addition, the ICCs calculated for this group were always larger than 0.98. Reproducibility of retinal thickness measurements in diabetic patients with macular exudates did not differ from that of the other diabetic patients.

COMMENT

The aim of this study was to assess the reproducibility of retinal thickness measurement using commercially available mapping software of OCT. Optical coherence tomography has already provided useful information about intraretinal structures in different vitreomacular diseases.¹³⁻¹⁵ In addition, it allows retinal thickness to be calculated as the distance between the anterior and posterior highly reflective boundaries of the retina, which

are located by means of a thresholding algorithm. The anterior boundary corresponds to the internal limiting membrane and is well defined because of the contrast between the nonreflective vitreous and the backscattering of the retina. The posterior boundary is located as the first signal posterior to the low-scattering photoreceptor layer and probably corresponds to the anterior edge of the RPE-choriocapillaris complex. Previous studies undertaken to correlate OCT images with histological features reported a close correlation between the OCT bands and specific retinal layers.^{16,17} Although Chauhan and Marshall¹⁸ showed that the inner band of the high OCT signal is not specific to the retinal nerve fiber layer, the 2 most consistent sources of high reflectivity are the surface of the retina and the RPE, and Chauhan and Marshall concluded that OCT allows accurate measurement of the total retina. Whatever these 2 boundaries precisely correspond to, their most important property for clinical relevance is that they must be recognizable with good reproducibility. Several studies have been per-

formed to evaluate the reproducibility of retinal thickness measurements, using a prototype or commercially available OCT equipment.^{7,8} In these studies, a single scan 3 mm long was repeatedly performed at the same location through the fovea. In the study by Baumann et al,⁷ good reproducibility was obtained for locations farther than 500 μm from the patient's fixation (coefficient of variation, <10%). However, reproducibility was not as good for locations within 500 μm of fixation (coefficient of variation, >10%). In the study by Koozekanani et al,⁸ retinal thickness was calculated for a 1-mm section located 750 μm from the fovea in normal retina, outside the foveal depression, where changes in retinal thickness are small. In this location, the reproducibility of retinal thickness measurement was good, with a mean ($\pm\text{SD}$) intrasession coefficient of variation of $1.2\% \pm 0.7\%$.

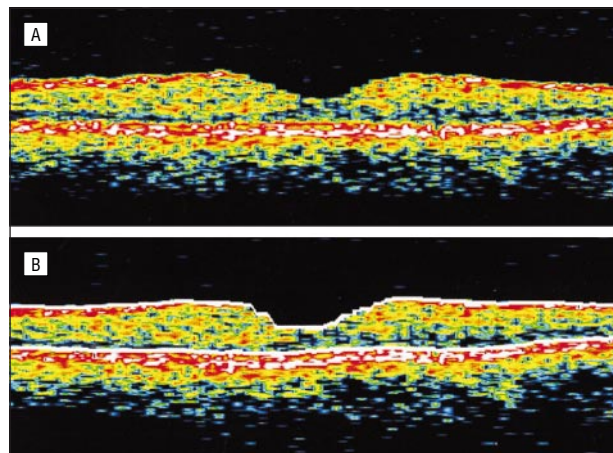


Figure 1. Measurement of retinal thickness from a single scan by means of the optical coherence tomography (OCT) algorithm. A, Cross-sectional OCT scan through a healthy macula. B, The anterior and posterior borders of the retina (white lines) are identified by the OCT algorithm. Retinal thickness is automatically measured as the distance between the 2 borders.

Therefore, both studies demonstrated that the OCT algorithm is able to recognize the 2 high-signal boundaries of the retina with good reproducibility and is therefore a valid tool for retinal thickness measurements.

Because a single scan through the macula provides an incomplete clinical assessment of macular thickness, Hee et al⁶ developed a topographic mapping protocol that allows 2-dimensional mapping of the macula and is included in the OCT A-5 software. This protocol consists of 6 radial tomograms obtained in a spoke pattern centered on the fovea, and it has the advantage of concentrating measurements in the central fovea. Quantitative evaluation of retinal thickness in the macula is displayed using the ETDRS grid for macular edema assessment.¹⁰ The retinal thickness for each ETDRS area is calculated as the average of several measurements performed along the 6-mm scans. Because all OCT images in the radial pattern intersected in the center, Hee and coworkers¹⁵ considered the SD of the 6 central values as an estimate of the measurement reproducibility for a given patient and found that the average reproducibility of central foveal thickness measurements was 11 μm in healthy subjects and about 20 μm in diabetic patients. However, as this mapping protocol is designed for longitudinal monitoring of the macular edema, with examinations performed on different days by different examiners, the intrasession, intersession, and interobserver reproducibility of retinal thickness measurement in all ETDRS areas must be rigorously evaluated.

Retinal mapping is performed from 6 consecutive radial scans centered on the patient's fixation point. Thus, the reproducibility of the measurements may alter if the central points of these scans do not coincide because of unstable patient fixation. Internal or external fixation beams may be used with OCT. We chose to use internal beam fixation, because it has been shown to provide better reproducibility.⁹

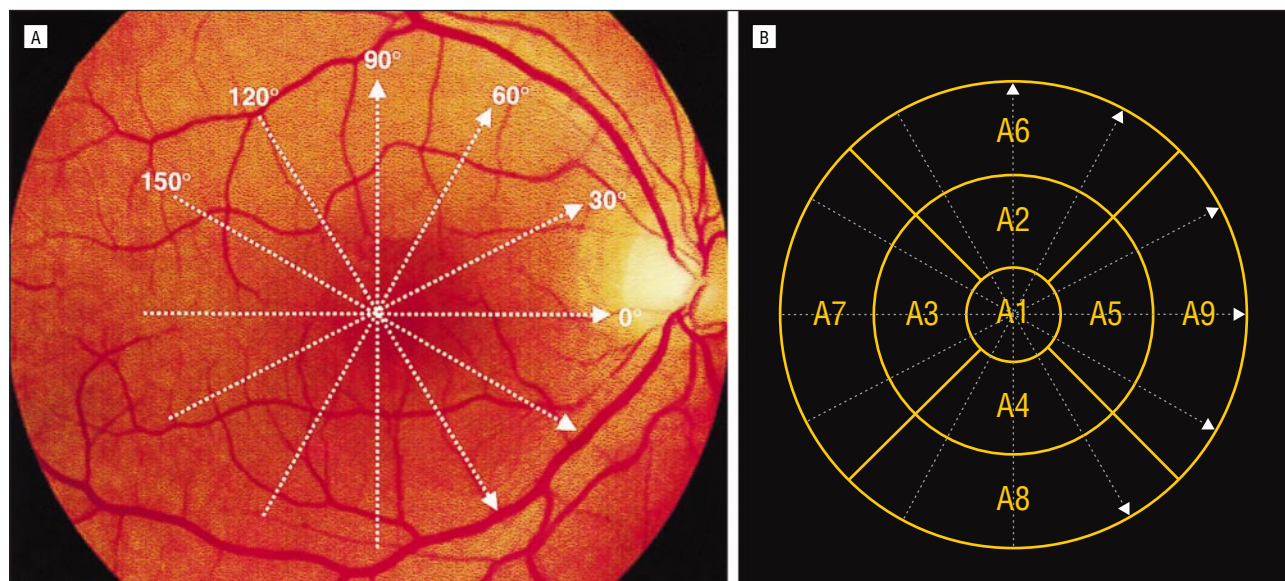


Figure 2. Retinal mapping protocol. A, Radial spoke pattern of 6 scans 6 mm long, centered on the patient's fixation point. B, Early Treatment Diabetic Retinopathy Study areas of the macula in a right eye. A1 indicates the central zone, 1000 μm in diameter; A2 to A5, superior, temporal, inferior, and nasal zones of a disc, 3000 μm in diameter; and A6 to A9, superior, temporal, inferior, and nasal zones of a disc, 6000 μm in diameter, centered on the center of the macula.

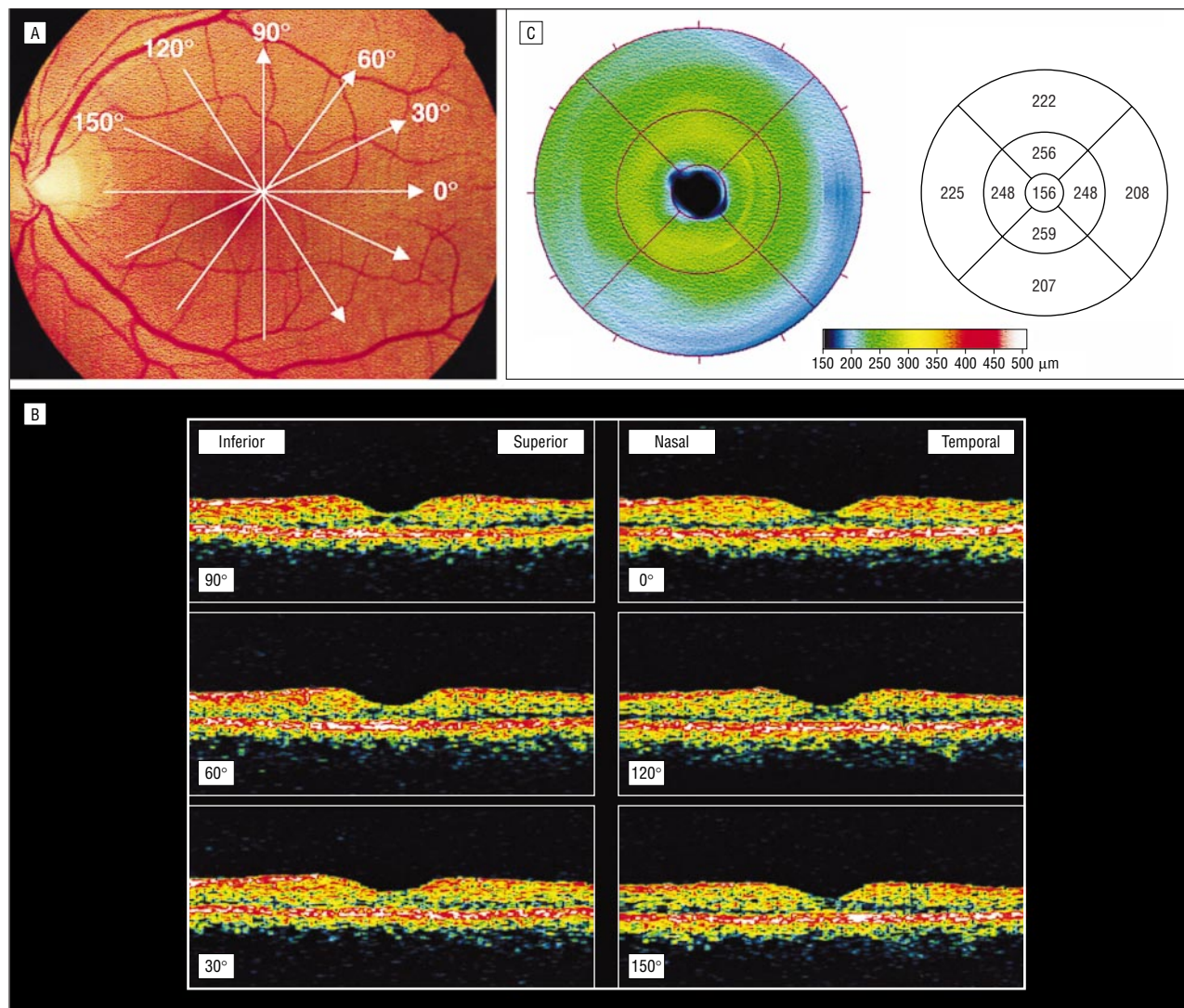


Figure 3. Macular mapping in a healthy subject (left eye). A, Radial spoke pattern of 6 scans 6 mm long, centered on the patient's fixation point. B, Cross-sectional optical coherence tomograms obtained from the 6 radial scans. C, Macular thickness is displayed as a 2-D false-color map (left), with brighter colors (red and white) indicating areas of increased retinal thickness. Macular thickness is numerically reported as an average (mean \pm SD) in each of the 9 Early Treatment Diabetic Retinopathy Study areas (right).

The impact of unstable fixation is likely to be greater in the foveal than in the peripheral areas of the posterior pole. Indeed, because of the shape of the foveal depression and the large variations in retinal thickness along the foveal slope, small changes in scan placement due to eye motion could cause variations in retinal thickness measurements. Thus, in 2 studies, these measurements varied greatly within 500 μm of the foveal center when calculated from a single scan.^{7,8} In our study using retinal mapping, intravisit and intervisit reproducibility were good in the healthy volunteers, and retinal thickness measurements with OCT were highly reproducible in the central macular area 1 mm in diameter, with a repeatability coefficient of less than 8 μm and an ICC of greater than 0.97. The large number of points measured in the central area with the mapping protocol may compensate for the theoretically greater variability due to the changes in retinal thickness occurring in this area.

We also tested the reproducibility of the measurements performed in a central area of the macula 500 μm

in diameter (A10), which is more representative of the foveolar area than an area 1000 μm in diameter, ie, the reproducibility of the mean of 50 A-scan measurements instead of 100. One might expect the assessment of retinal thickness in a smaller zone to be less reproducible, because it integrates fewer values. However, our results showed that the reproducibility of the measurements in this central area remained good, and the ICC coefficient was high in all cases. Consequently, measurement of retinal thickness in a central area with a diameter of 500 μm seems relevant for clinical practice. The variability of the measurements performed in the central point of the macula, although acceptable, was greater than that of the measurements for the other areas, a result that was expected because the retinal thickness of the center was assessed as the mean of only 6 measurements.

In the middle and outer ETDRS regions, intravisit and intervisit reproducibility were good in the healthy volunteers, as shown by the repeatability coefficient and ICC, despite the smaller number of points measured.

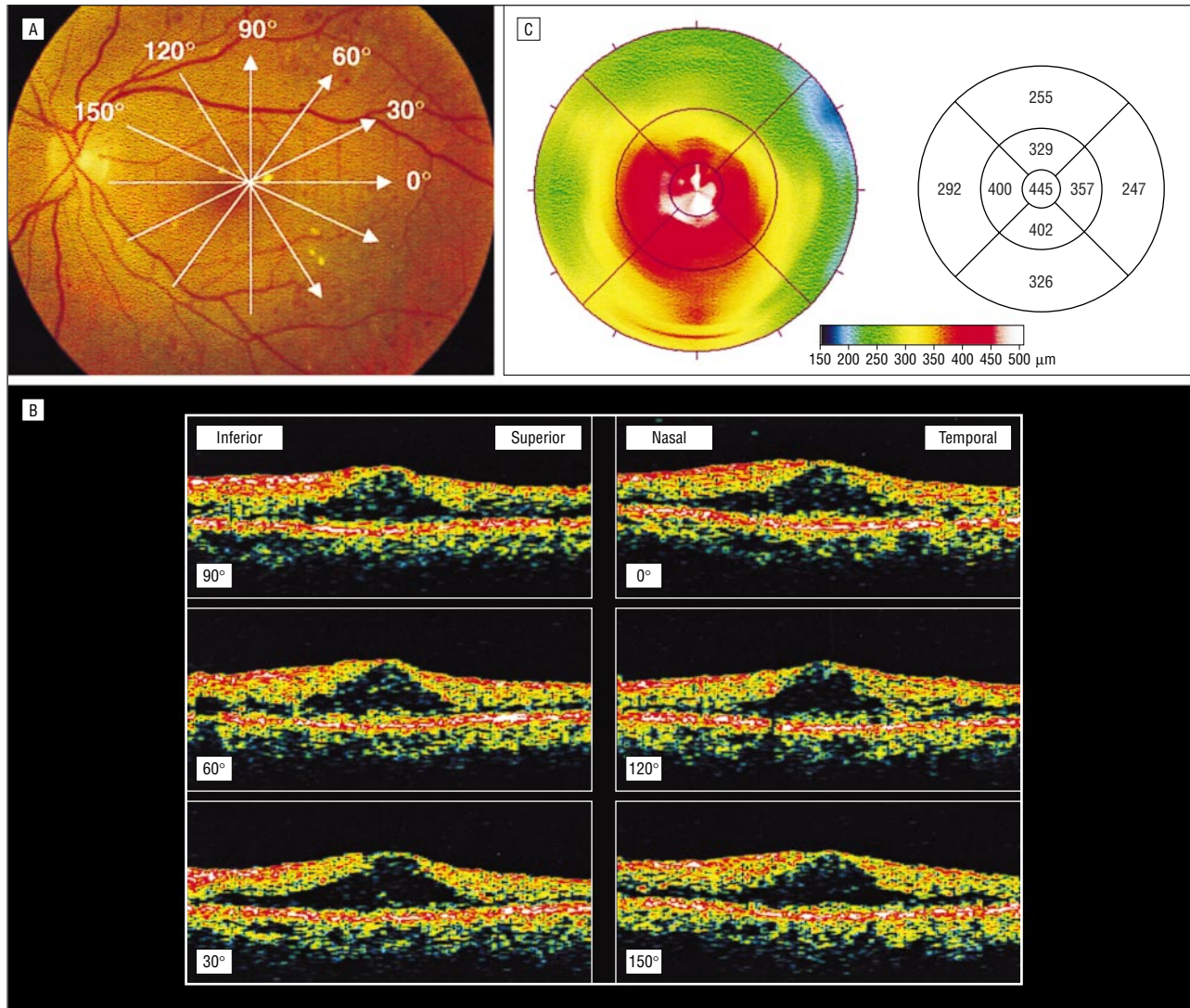


Figure 4. Macular mapping in a diabetic patient with clinically significant macular edema (left eye). A, Radial spoke pattern of 6 scans 6 mm long, centered on the patient's fixation point. B, Cross-sectional optical coherence tomographic (OCT) scans obtained from the 6 radial scans, showing retinal thickening and loss of the foveal depression. C, An OCT topographic map shows increased macular thickness throughout the macula, especially in the central area.

Table 1. Retinal Thickness Measured in Healthy Subjects*

Macular Area	Mean ± SD Measurements, μm						
	R1	R2	R3	R4	Δ (1-2)	Δ (1-3)	Δ (1-4)
A1	178 ± 17	177 ± 17	179 ± 19	177 ± 16	0.8 ± 2.0	-1.1 ± 4.7	1.2 ± 3.3
A2	252 ± 13	253 ± 12	252 ± 12	252 ± 9	-0.8 ± 2.9	-0.3 ± 1.9	0.4 ± 4.5
A3	241 ± 15	240 ± 14	240 ± 14	240 ± 13	0.9 ± 2.7	0.4 ± 2.7	0.6 ± 3.2
A4	253 ± 9	253 ± 9	252 ± 9	253 ± 9	-0.7 ± 3.5	0.2 ± 3.2	-0.3 ± 4.4
A5	253 ± 13	254 ± 12	252 ± 12	253 ± 12	-1.1 ± 1.6	0.5 ± 3.2	-0.6 ± 2.3
A6	217 ± 9	218 ± 11	218 ± 10	216 ± 11	-0.6 ± 2.6	-1.4 ± 3.2	0.8 ± 4.5
A7	207 ± 11	207 ± 11	206 ± 11	207 ± 11	0.2 ± 2	0.7 ± 2.5	0.2 ± 2.7
A8	214 ± 11	213 ± 12	213 ± 10	214 ± 12	0.7 ± 1.4	1.0 ± 2.4	-0.6 ± 4.7
A9	232 ± 14	233 ± 12	232 ± 13	233 ± 14	-0.5 ± 3.2	0.6 ± 3.0	-1.3 ± 3.5
A10	152 ± 15	153 ± 13	156 ± 18	152 ± 14	-1.0 ± 2.5	-4.6 ± 6.8	-0.4 ± 3.8
Central foveolar	145 ± 13	146 ± 14	149 ± 17	147 ± 13	-0.5 ± 6.7	-4.0 ± 6.4	-1.3 ± 5.6

*Macular areas are described in the "Optical Coherence Tomography" subsection of the "Subjects and Methods" section. R1 indicates the first series of measurements by examiner 1 (B.H.) during the first visit; R2, the second series of measurements by examiner 1 (B.H.) during the first visit; R3, the measurements by examiner 2 (A.E.) during the first visit; R4, the measurements by examiner 1 (B.H.) during the second visit; Δ (1-2), differences between the retinal thickness measurements by examiner 1 during the first visit (intraobserver variability); Δ (1-3), differences between the retinal thickness measurements by examiners 1 and 2 during the first visit (interobserver variability); and Δ (1-4), differences between the retinal thickness measurements by examiner 1 (B.H.) on 2 different days (intervisit variability).

Table 2. Retinal Thickness Measured in Diabetic Patients With Macular Edema*

Macular Area	Mean ± SD Measurements, μm		
	R1	R2	Δ (1-2)
A1	418 ± 87	413 ± 85	4.8 ± 6.67
A2	389 ± 76	390 ± 78	-0.7 ± 8.4
A3	393 ± 97	391 ± 94	2.0 ± 8.9
A4	371 ± 99	371 ± 96	0.3 ± 9.6
A5	401 ± 91	396 ± 89	4.6 ± 7.7
A6	305 ± 69	306 ± 66	-0.5 ± 13.6
A7	306 ± 89	302 ± 85	4.4 ± 8.3
A8	300 ± 83	298 ± 79	2.3 ± 8.1
A9	322 ± 79	321 ± 80	1.9 ± 7.4
A10	417 ± 95	413 ± 91	3.1 ± 10.1
Central foveolar	418 ± 97	413 ± 94	5.0 ± 10.6

*Macular areas are described in the "Optical Coherence Tomography" subsection of the "Subjects and Methods" section. Abbreviations are given in the footnote to Table 1.

Nevertheless, one must expect lower sensitivity for the detection of small areas of retinal thickening in the outer regions because of the small number of points measured per square millimeters.

We also tested the reproducibility of retinal thickness measurements in 10 diabetic patients with macular edema and impaired visual acuity, whose unstable fixation might have impaired measurement reliability. However, as the repeatability coefficient of the measurements performed on the same day by the same examiner was less than 20 μm in the inner ETDRS areas (ie, reproducibility was ±6%), these measurements were also valid for the diabetic patients. Although measurement variability increased slightly in the outer regions, it remained small. In addition, the ICCs calculated for this group, which were always larger than 0.98, demonstrated the great reliability of the measurements. This good reproducibility of retinal thickness measurements in diabetic patients may be partly due to the thickening and flattening of the macula with loss of the foveal depression caused by macular edema, which compensates for the patient's possibly poor fixation. Greater variability may be present in diabetic patients after the resolution of macular edema if visual acuity remains poor.

Another factor that may adversely affect retinal thickness measurements is the inability of different observers to obtain the same image quality. Thus, the signal intensity of OCT images may vary with the control setting. Trained observers usually manipulate light power and sometimes polarization to obtain the best image, ie, maximal intensity of the inner band. Total retinal thickness is measured by OCT software as the distance between the inner borders of the inner and outer red bands of high reflectivity, suggesting that the reproducibility of retinal thickness measurements may be observer dependent. However, in our study, interobserver reproducibility was excellent, as repeatability coefficients ranged from 4 to 13 μm in the different areas of the macula, and ICCs, from 0.93 to 0.99. In addition, Chauhan and Marshall¹⁸ showed that changes in signal intensity do not interfere with total retinal thickness measurement, even when polarization is set to provide the minimum inner-band signal intensity. This

Table 3. Intraclass Correlation Coefficients for Retinal Thickness Measurements in Healthy and Diabetic Subjects*

Macular Area	Reliability			
	ICC 1-2	ICC 1-3	ICC 1-4	ICC DB
A1	0.97	0.99	0.98	0.99
A2	0.99	0.97	0.92	0.99
A3	0.98	0.98	0.98	0.99
A4	0.94	0.93	0.89	0.99
A5	0.97	0.99	0.98	0.99
A6	0.94	0.97	0.91	0.98
A7	0.97	0.98	0.97	0.99
A8	0.97	0.99	0.93	0.99
A9	0.98	0.97	0.97	0.99
A10	0.89	0.98	0.97	0.99
Central foveolar	0.89	0.89	0.91	0.99

*Macular areas are described in the "Optical Coherence Tomography" subsection of the "Subjects and Methods" section. ICC 1-2 indicates intraobserver reliability in healthy subjects; ICC 1-3, interobserver reliability in healthy subjects; ICC 1-4, intervisit reliability in healthy subjects; and ICC DB, intraobserver reliability in diabetic patients. All ICCs were significantly different from 0 ($P < .001$).

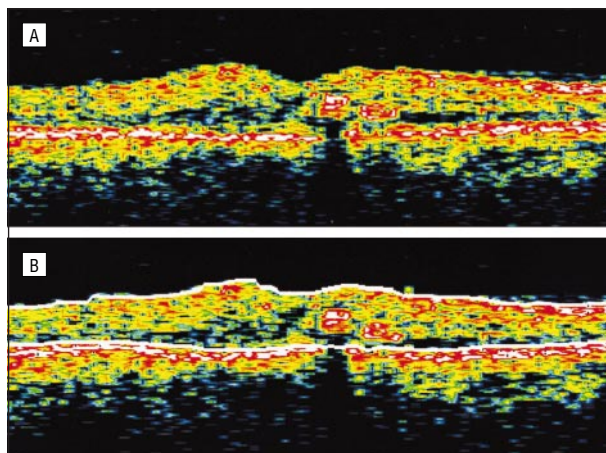


Figure 5. Cross-sectional optical coherence tomography (OCT) scan showing increased macular thickness and a small hard exudate due to diabetic macular edema. A, The intraretinal exudate appears as a focal area of high backscattering that shadows the backscattering from the choroid and pigment epithelium below. B, In OCT software, linear interpolation removes the gap in the posterior boundary resulting from shadowing due to an exudate. The 2 boundaries are correctly recognized by the OCT algorithm.

suggests that reliable retinal thickness measurements can be obtained even by untrained observers.

Finally, under pathologic conditions such as diabetic maculopathy, some lesions may provoke artifacts in retinal thickness measurements. Retinal exudates appear as focal areas of high backscattering that shadow the backscattering from the choroid and RPE below. However, in A-5 software, linear interpolation is performed to remove any gaps in the boundaries resulting from shadowing due to exudates (Figure 5). Thus, 3 of our 10 diabetic patients exhibited small retinal exudates, and in all 3, the 2 boundaries were correctly recognized, and reproducibility did not differ from that of the other patients. However, in case of larger exudates, linear interpolation may not work, and high exudate reflectivity may be recognized as the posterior boundary of the retina, lead-

ing to artifactual measurement of retinal thickness. In such cases, software that allows correction of the boundaries could be a useful addition to the OCT system.

Other factors that may negatively affect reproducibility are pupillary myosis, cataract, and changes in refraction. Our study was performed on dilated eyes. We did not study the effect of pupil size on reproducibility, but Baumann et al⁷ and Koozekanani et al⁸ showed good reproducibility of macular thickness measurement with OCT on undilated eyes. Changes in axial length or refraction may affect measurements in the transverse direction of the eye (ie, along the direction of the scan line) but have no effect on measurements in the axial direction.⁸ Finally, a nuclear cataract does not seem to affect retinal thickness measurement,⁹ although the presence of dense subcapsular opacity may impair the ability to perform OCT examination.

CONCLUSION

Retinal mapping software of OCT is a highly sensitive tool that allows reproducible measurements of retinal thickness in healthy subjects and diabetic patients with macular edema, with reproducibility of $\pm 5\%$ and $\pm 6\%$, respectively. We showed that for clinical practice, a central area 500 μm in diameter gives a reliable assessment of central macular thickness. Therefore, OCT may be used in clinical practice for longitudinal objective monitoring of macular edema and for assessment of treatment efficacy.

Accepted for publication January 10, 2001.

Supported by grant TBM 97040 from the Délégation à la Recherche Clinique de l'Assistance Publique-Hôpitaux de Paris, Paris, France.

Corresponding author: Pascale Massin, MD, Department of Ophthalmology, Hôpital Lariboisière, 2 rue Ambroise Paré, 75475 Paris CEDEX 10, France (e-mail: p.massin@lrh.ap-hop-paris.fr).

REFERENCES

1. Zeimer RC, Mori MT, Khoobehi B. Feasibility test of a new method to measure retinal thickness noninvasively. *Invest Ophthalmol Vis Sci.* 1989;30:2099-2105.
2. Shahidi M, Ogura Y, Blair NP, Rusin MM, Zeimer R. Retinal thickness analysis for quantitative assessment of diabetic macular edema. *Arch Ophthalmol.* 1991; 109:1115-1119.
3. Zeimer RC, Shahidi M, Mori MT, et al. A new method for rapid mapping of the retinal thickness at the posterior pole. *Invest Ophthalmol Vis Sci.* 1996;37:1994-2001.
4. Huang D, Swanson CA, Lin CP, et al. Optical coherence tomography. *Science.* 1991;254:1178-1181.
5. Hee MR, Izatt JA, Swanson EA, et al. Optical coherence tomography of the human retina. *Arch Ophthalmol.* 1995;113:325-332.
6. Hee MR, Puliafito CA, Duker JS, et al. Topography of diabetic macular edema with optical coherence tomography. *Ophthalmology.* 1998;105:360-370.
7. Baumann M, Gentile RC, Liebman JM, Ritch R. Reproducibility of retinal thickness measurements in normal eyes using optical coherence tomography. *Ophthalmic Surg Lasers.* 1998;29:280-285.
8. Koozekanani D, Roberts C, Katz SE, Herderick EE. Intersession repeatability of macular thickness measurements with the Humphrey 2000 OCT. *Invest Ophthalmol Vis Sci.* 2000;41:1486-1491.
9. Schuman JS, Pedut-Kloizman T, Hertzmark E, et al. Reproducibility of nerve fiber layer thickness measurements using optical coherence tomography. *Ophthalmology.* 1996;103:1889-1898.
10. Early Treatment Diabetic Retinopathy Study Research Group. Photocoagulation for diabetic macular edema: Early Treatment Diabetic Retinopathy Study report number 1. *Arch Ophthalmol.* 1985;103:1796-1806.
11. British Standards Institution. *Precision of Test Methods, I: Guide for the Determination and Reproducibility for a Standard Test Method.* London, England: British Standards Institution; 1979. Publication BS5497, part 1.
12. Bartko JJ, Carpenter WT. On the methods and theory of reliability. *J Nerv Ment Dis.* 1976;163:307-317.
13. Puliafito CA, Hee MR, Lin CP, et al. Imaging of macular diseases with optical coherence tomography. *Ophthalmology.* 1995;102:217-229.
14. Coker JG, Duker JS. Macular disease and optical coherence tomography. *Curr Opin Ophthalmol.* 1996;7:33-38.
15. Hee MR, Puliafito CA, Wong C, et al. Quantitative assessment of macular edema with optical coherence tomography. *Arch Ophthalmol.* 1995;113:1019-1029.
16. Toth CA, Narayan DG, Boppart SA, et al. A comparison of retinal morphology viewed by optical coherence tomography and by light microscopy. *Arch Ophthalmol.* 1997;115:1425-1428.
17. Huang Y, Cideciyan AV, Papastergiou GI, et al. Relation of optical coherence tomography to microanatomy in normal and rd chickens. *Invest Ophthalmol Vis Sci.* 1998;39:2405-2416.
18. Chauhan DS, Marshall J. The interpretation of optical coherence tomography images of the retina. *Invest Ophthalmol Vis Sci.* 1999;40:2332-2342.

From the Archives of the ARCHIVES

A look at the past . . .

Dr P. Watson-Williams said that recently much investigation had taken place to find a satisfactory substitute for cocaine. The toxicity of cocaine and its abuse by the narcomaniac had brought the matter much into the public eye. Mr R. Foster Moore pointed out that those local anesthetics were used in different ways by the various specialities. Speaking as an ophthalmic surgeon for infiltration anaesthesia he was entirely satisfied with novocaine 2 per cent, but for intraocular operations cocaine so far led the field.

Reference: Doyne PG. Discussion on the comparative value of cocaine substitutes. *Arch Ophthalmol.* 1925;54:86-87.