

Response Assessment in Neuro-Oncology working group and European Association for Neuro-Oncology recommendations for the clinical use of PET imaging in gliomas

Nathalie L. Albert, Michael Weller, Bogdana Suchorska, Norbert Galldiks, Riccardo Soffietti, Michelle M. Kim, Christian la Fougère, Whitney Pope, Ian Law, Javier Arbizu, Marc C. Chamberlain, Michael Vogelbaum, Ben M. Ellingson, and Joerg C. Tonn

Department of Nuclear Medicine, Ludwig-Maximilians-University Munich, Munich, Germany (N.L.A.); Department of Neurology, University Hospital Zurich, Zurich, Switzerland (M.W.); Department of Neurosurgery, Ludwig-Maximilians-University Munich, Munich, Germany (B.S., J.C.T.); Institute of Neuroscience and Medicine, Research Center Juelich, Juelich, Germany (N.G.); Department of Neurology, University of Cologne, Cologne, Germany (N.G.); Department of Neuro-Oncology, University of Turin, Turin, Italy (R.S.); Department of Radiation Oncology, University of Michigan, Ann Arbor, Michigan (M.M.K.); Division of Nuclear Medicine and Clinical Molecular Imaging, Department of Radiology, University of Tübingen, Tübingen, Germany (C.L.F.); Radiological Sciences, University of California Los Angeles, Los Angeles, California (W.P.); Department of Clinical Physiology, Nuclear Medicine and PET, Rigshospitalet, University of Copenhagen, Copenhagen, Denmark (I.L.); Department of Nuclear Medicine, Clínica Universidad de Navarra, University of Navarra, Pamplona, Spain (J.A.); Department of Neurology, University of Washington, Seattle, Washington (M.C.); Department of Neurological Surgery, Brain Tumor and Neuro-Oncology Center, Cleveland Clinic, Cleveland, Ohio (M.A.V.); Department of Radiology, David Geffen School of Medicine, University of California Los Angeles, Los Angeles, California (B.M.E.)

Corresponding Author: Jörg-Christian Tonn, MD, Department of Neurosurgery, Ludwig-Maximilians-University Munich, Marchioninstr. 15, 81377 Munich, Germany (joerg.christian.tonn@med.uni-muenchen.de).

This guideline provides recommendations for the use of PET imaging in gliomas. The review examines established clinical benefit in glioma patients of PET using glucose (^{18}F -FDG) and amino acid tracers (^{11}C -MET, ^{18}F -FET, and ^{18}F -FDOPA). An increasing number of studies have been published on PET imaging in the setting of diagnosis, biopsy, and resection as well radiotherapy planning, treatment monitoring, and response assessment. Recommendations are based on evidence generated from studies which validated PET findings by histology or clinical course. This guideline emphasizes the clinical value of PET imaging with superiority of amino acid PET over glucose PET and provides a framework for the use of PET to assist in the management of patients with gliomas.

Keywords: amino acid PET, glioma, guideline, PET imaging, recommendations.

Gliomas are the second most common primary brain tumors, with an incidence of 4–5/100 000 individuals. Gliomas are the second leading cause of cancer mortality in adults under the age of 35, the fourth leading cause in those under the age of 54, and result in death in approximately 13 770 individuals per year in the United States.¹ Median survival of glioblastoma, the most aggressive variant, is 16 months in patients treated with maximum safe resection, radiotherapy, and concurrent and adjuvant temozolomide in clinical trial populations.^{2–4}

MRI is the mainstay of imaging of gliomas to monitor both treatment and response. T1-weighted MRI without and with contrast medium, T2-weighted as well as fluid-attenuated inversion recovery (FLAIR) MRI sequences are used for anatomic imaging. However, many brain tumors (particularly World

Health Organization [WHO] grade II and a significant number of WHO grade III gliomas) do not enhance with contrast-agent administration, reducing the ability of contrast imaging to accurately quantify tumor burden. The challenge to accurately determine brain tumor response by MRI both in daily practice and in clinical trials has led to the introduction of updated guidelines by the Response Assessment in Neuro-Oncology (RANO) working group.⁵

Functional molecular imaging such as positron emission tomography (PET) uses various tracers to visualize biological processes such as cell proliferation, membrane biosynthesis, glucose consumption, and uptake of amino acid analogs.⁶ Hence, PET provides additional insight beyond MRI into the biology and treatment response of gliomas which may be used for

Received 15 January 2016; accepted 14 March 2016

© The Author(s) 2016. Published by Oxford University Press on behalf of the Society for Neuro-Oncology. All rights reserved. For permissions, please e-mail: journals.permissions@oup.com.

noninvasive grading, differential diagnosis, delineation of tumor extent, surgical and radiotherapy treatment planning, posttreatment surveillance, and prognostication.

Analogous to the RANO effort regarding MRI use in gliomas, an initiative was undertaken by a group of clinicians and nuclear medicine physicians to similarly define standards of molecular imaging for gliomas using PET with respect to interpretation and validation as well as to define its role in clinical practice. In this paper, evidence-based recommendations are proposed for the use of PET imaging in the clinical management of glioma patients. Accordingly, the review discusses tracers which image glucose metabolism— ^{18}F -2-fluoro-2-deoxy-D-glucose (^{18}F -FDG)—and amino acid transport ([^{11}C -methyl]-methionine (^{11}C -MET), O-(2-[^{18}F]-fluoroethyl)-L-tyrosine (^{18}F -FET) and 3,4-dihydroxy-6-[^{18}F]-fluoro-L-phenylalanine (^{18}F -FDOPA)), since these compounds have already entered clinical practice.

The current guidelines aim to serve medical professionals of all disciplines involved in the diagnosis and care of patients with gliomas. A separate procedural guideline focusing on the standardization of technical aspects of PET imaging for glioma will be the subject of another paper prepared by the EANM (European Association of Nuclear Medicine)/EANO (European Association of Neuro-Oncology)/RANO groups.

Levels of Validation and Clinical Evidence Search Strategy and Selection Criteria

The information retrieved from a PubMed search of the published literature with the combination of the search terms “glioma,” “glioblastoma,” “brain tumor,” “PET,” “FDG,” “FET,” “MET,” and “DOPA” until September 2015 as well as from articles identified through searches of the authors’ own files was evaluated by the working group with respect to the level of evidence and the grade of validation of the PET studies examined.

Any study that correlated the PET findings with histopathology was considered to represent the highest degree of validation. Next, correlation with MRI (when applicable, according to RANO criteria) and with the patient’s clinical course was used for the second level of validation. Only papers constituting levels 1–3 evidence according to the Oxford Centre for Evidence-based Medicine (OCEBM Levels of Evidence Working Group: “The Oxford 2011 Levels of Evidence”) were included.

General Recommendations

Recommendations for clinical use and diagnostic performance of differing PET tracers compared with MRI are presented in Tables 1 and 2 and in Fig. 1.

Specific Recommendations

Primary Diagnosis/Differential Diagnosis

^{18}F -FDG PET may provide useful information for distinguishing WHO grade III/IV gliomas from other malignant brain tumors, but its specificity is limited. Importantly, maximum standardized uptake values (SUV_{max}) were significantly higher in primary CNS lymphomas than in glioblastoma.^{7,8} However, corticosteroid medication may reduce uptake.

The differential diagnosis by ^{18}F -FDG PET between WHO grades III/IV gliomas and brain metastases is limited, since considerable overlap of SUV_{max} exists between these tumor types.⁷ ^{18}F -FDG PET also has limited specificity for distinguishing glioma from other nonneoplastic lesions, such as brain abscesses, demyelinating tumefactive (“tumor-like”) lesions, fungal infections, and neurosarcoidosis⁹ due to increased ^{18}F -FDG metabolism in inflammatory tissue.

Amino acid PET is useful for the noninvasive differentiation of tumor and nontumoral processes, as tumors have significantly higher uptake than nonneoplastic tissue.^{10,11} However, moderately increased uptake can also be seen in acute inflammatory lesions such as active multiple sclerosis and brain abscesses.^{12,13} Conversely, lack of ^{18}F -FET uptake does not exclude a glioma, as approximately one-third of WHO grade II gliomas and most dys-embryoplastic neuroepithelial tumors (WHO grade I) are ^{18}F -FET negative.¹⁴ However, among WHO grades III and IV gliomas, the vast majority (>95%) show increased uptake,^{11,12,15} with a resultant high sensitivity for the detection of these tumors. A recent meta-analysis revealed that for brain tumor diagnosis, ^{18}F -FET PET performed much better than ^{18}F -FDG PET and consequently would be the preferred PET tracer when assessing patients with a newly diagnosed brain tumor.¹⁶ Furthermore, numerous studies validated by histology have demonstrated higher diagnostic accuracy of additional amino acid PET compared with anatomic MRI alone for the differentiation of gliomas from nonneoplastic lesions.^{11,12,17–19}

- In cases of diagnostic uncertainty, amino acid PET improves sensitivity, specificity, and accuracy and is markedly superior to ^{18}F -FDG PET in differentiating between glioma and nonneoplastic tissue.

Tumor Grading

The value of ^{18}F -FDG PET for grading of gliomas is hampered by the poor tumor-to-background contrast due to physiologically increased glucose uptake of cortical and subcortical (basal ganglia, thalamus) structures in brain and high variation of uptake and overlap of uptake values between tumors of different WHO grades, especially in oligodendroglial tumors.^{20,21} However, WHO grades III and IV gliomas generally have higher ^{18}F -FDG values than WHO grade II gliomas, which often appear as a hypometabolic lesion, particularly when compared with the uptake in the cortex.¹⁶

Characteristically, **amino acid** uptake is higher in gliomas of WHO grades III/IV compared with WHO grade II gliomas. However, uptake intensities may vary, and tumor-to-brain ratios show a considerable overlap between different WHO grades as well as histological subtypes.^{11,12,22–24} For ^{18}F -FET, accuracy for tumor grading can be markedly improved by evaluating *dynamic* (kinetic) PET data, which typically show steadily increasing time-activity curves in WHO grade II gliomas, as opposed to an early activity peak around 10–20 min after injection, followed by a decrease of ^{18}F -FET uptake in WHO grades III/IV gliomas.^{22,25} This is particularly valuable in the clinical setting of patients with MRI non-contrast-enhancing gliomas suspected of harboring a WHO grade II glioma. In approximately 40% of such cases, an anaplastic focus is demonstrated.^{14,26} In these patients, kinetic analysis provides a higher sensitivity and specificity for the detection of WHO grades III/IV gliomas (95%).¹⁴ This method

Table 1. Diagnostic performance of different amino acid tracers compared with conventional and advanced MRI

Clinical Problem	MET	FET	FDOPA
Differentiation of glioma from nonneoplastic lesions	Numerous studies, ¹⁹ higher diagnostic accuracy than MRI alone	Higher diagnostic accuracy than MRI alone ^{11,12,18}	Not available for the initial diagnosis
Glioma grading (including detection of anaplastic foci)	Higher diagnostic accuracy than MRI, but still limited accuracy due to high overlap between WHO grades ^{19,96}	Higher diagnostic accuracy than MRI, in particular for <i>dynamic</i> PET ^{14,26,93} High accuracy by combination of dynamic FET-PET and diffusion MRI ⁹⁷	No studies available comparing directly PET with MRI; in the pure PET studies, conflicting results reporting high ^{38,98} and low ^{28,99} performance
Delineation of glioma extent	Metabolically active tumor larger than contrast enhancement in LGG and HGG at diagnosis and recurrence ^{100,101} Delineates metabolically active tumor in non-enhancing anaplastic glioma ^{32,102}	In newly diagnosed glioblastoma, metabolically active tumor larger than CE pre- and postoperatively ^{46,103} In WHO grades II/IV gliomas metabolically active tumor larger than rCBV ¹⁰⁴	In glioma, metabolically active tumor larger than rCBV, ¹⁰⁵ ADC, ¹⁰⁶ and contrast enhancement ^{34,36}
Differentiation of glioma recurrence from treatment-induced changes (eg, pseudoprogression, radionecrosis)	Higher diagnostic accuracy than MRI ⁶⁶	Higher diagnostic accuracy than MRI ^{74,81,107}	Higher diagnostic accuracy than MRI ^{17,37,79,108}
Assessment of treatment response (including pseudoresponse)	Superior to MRI; metabolic response to TMZ predictive for survival ⁷⁰	Superior to MRI; metabolic responses to TMZ, ⁸³ RT, ^{69,71} and BEV ^{76,78} occurred earlier and/or were associated with improved survival	Superior to MRI; metabolic response to BEV ⁷⁷ occurred earlier and was predictive of improved survival
Assessment of prognosis in gliomas	In contrast to pretreatment CE volumes, metabolically active tumor volumes are prognostic in HGG ^{86,95}	Metabolically active tumor volume is prognostic in WHO grade IV glioma. ⁴⁶ Higher prognostic value of time-activity curves in <i>dynamic</i> PET than MRI within WHO grade II and WHO grades III/IV glioma. ^{15,91,92} FET uptake in combination with specific MRI findings is prognostic ⁹⁴ for WHO grade II glioma	Superior to MRI in WHO grade II glioma; maximum uptake is an independent predictor of progression ¹⁰⁹

Abbreviations: LGG, low-grade glioma; HGG, high-grade glioma; CE, contrast enhancement; rCBV, relative cerebral blood volume; ADC, apparent diffusion coefficient; TMZ, temozolomide; RT, radiotherapy; BEV, bevacizumab.

of kinetic analysis does not work for ¹¹C-MET²⁴; and for ¹⁸F-FDOPA, data are still controversial.^{27,28}

- Although ¹⁸F-FDG and amino acid uptake are usually higher in WHO grades III/IV gliomas than in WHO grade II gliomas, tumor grading is limited due to significant overlap in uptake values.
- Dynamic analysis of ¹⁸F-FET PET uptake further improves differential diagnosis between WHO grade II and WHO grades III/IV gliomas.

Delineation of Glioma Extent

Multiple histopathological and postmortem series demonstrate the limitations of conventional MRI in defining the extent of glioma.^{29,30} Moreover, the usefulness of ¹⁸F-FDG PET in tumor delineation, given high uptake in normal brain cortex and low

uptake in WHO grade II gliomas, is particularly limited for cortical or pericortical tumors, even when dual-timepoint images are performed.³¹ In contrast, amino acid PET imaging more accurately identifies infiltrating regions of tumor extending beyond the MRI contrast-enhancing lesion and often distinguishes among tumor, nontumoral edema, and normal brain.³² In addition, amino acid PET provides functional and metabolic information about the tumor and may identify tumor regions with different biological and clinical behavior. In both WHO grade II and WHO grades III/IV gliomas, amino acid PET complements conventional MRI by providing additional information about tumor extent and biology.

WHO grades III/IV glioma

Both the uptake and image contrast between tumor and normal tissue of **amino acid tracers** such as ¹¹C-MET and ¹⁸F-FET

Table 2. Overview of histologically validated amino acid PET studies in gliomas

Clinical Problem	MET	FET	FDOPA
Differentiation of neoplastic from nonneoplastic lesions	Stereotactic biopsy ¹¹⁰ Hot-spot guided resection ¹¹¹	Stereotactic biopsy and hot-spot guided resection ¹¹	n.a.
Differentiation between WHO grades II and WHO grades III/IV glioma	In a subset of patients stereotactic biopsy ¹¹²	Stereotactic biopsy ^{14,22,25}	In a subset of patients stereotactic biopsy and hot-spot guided resection ³⁸
Delineation of glioma extent	Stereotactic biopsy ^{39,43,113,114} Hot-spot guided resection ^{101,115}	Stereotactic biopsy ^{41,116} Stereotactic biopsy and hot-spot guided resection ¹¹⁷	In a subset of patients hot-spot guided resection ³⁶
Differentiation of glioma recurrence from treatment-induced changes (eg, radionecrosis)	Stereotactic biopsy ¹¹⁸	Stereotactic biopsy ¹¹⁹ Stereotactic biopsy and hot-spot guided resection ^{81,120}	In a subset of patients stereotactic biopsy ^{17,108}
Detection of malignant tumor parts in MRI findings suggestive for WHO grade II glioma	Stereotactic biopsy and hot-spot guided resection ⁹⁶	Stereotactic biopsy ²⁶ Stereotactic biopsy and hot-spot guided resection ⁹³	n.a.
Assessment of prognosis in untreated gliomas	Histological confirmation of glioma only ⁹⁵ (local comparison not necessary)	Histological confirmation of glioma only ^{15,91} (local comparison not necessary)	Histological confirmation of glioma only ¹⁰⁹ (local comparison not necessary)

Abbreviation: n.a., not available.

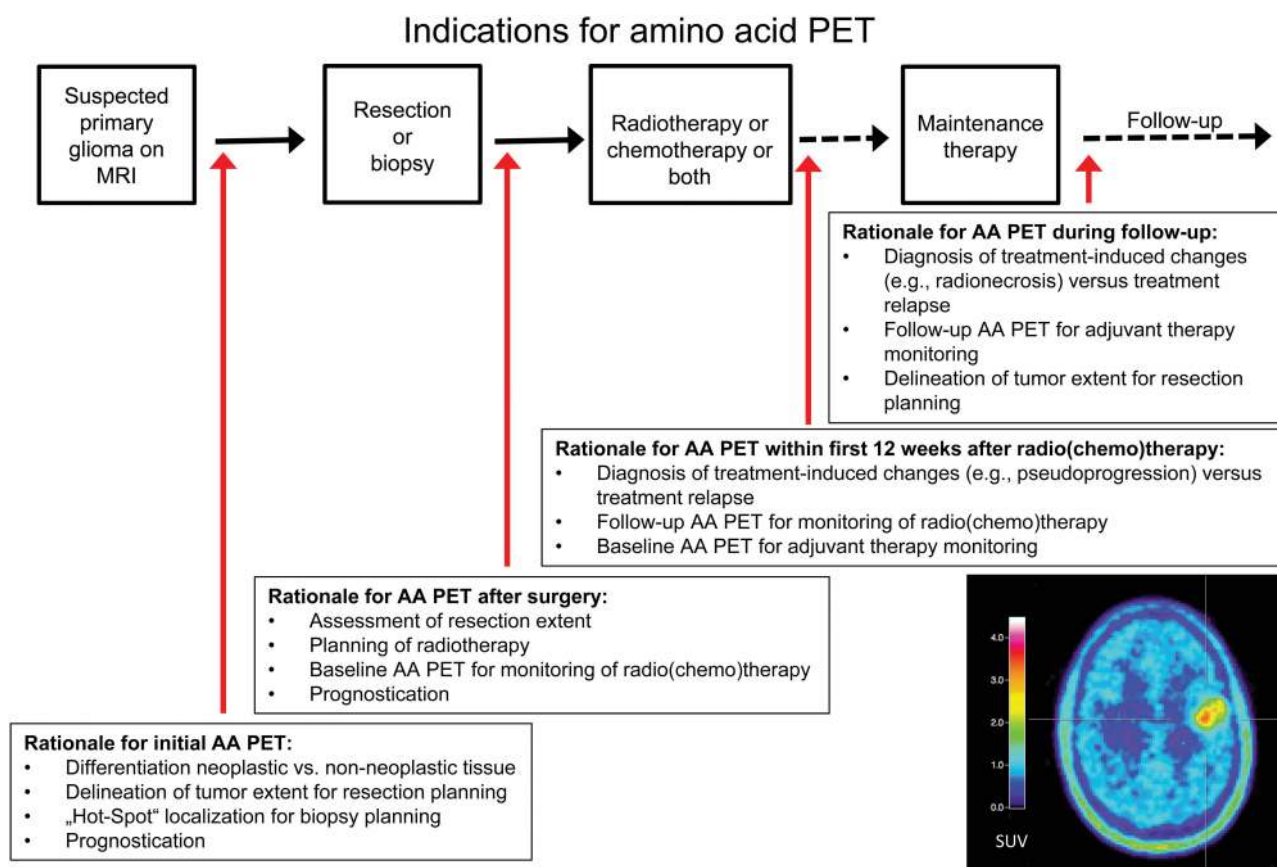


Fig. 1. Overview of indications for amino acid PET.

are similar.³³ PET-based tumor volumes have been shown to extend beyond the contrast-enhancing volume on conventional MRI by 2–3.5 cm for different tracers.^{34–37} In addition, amino acid PET identifies tumor extent within nonspecific regions of T2/FLAIR signal abnormality.^{34,36}

WHO grade II glioma

Most WHO grade II gliomas are nonenhancing with infiltrating tumor borders that are difficult to delineate by conventional MRI. Several studies have demonstrated the usefulness of **amino acid** PET in defining tumor extent. This has been demonstrated in histology-validated series for ¹¹C-MET, ¹⁸F-FET, and ¹⁸F-FDOPA PET.^{17,38–41}

- ¹⁸F-FDG is not suitable for glioma volume delineation.
- Delineation of tumor borders by amino acid PET is superior to standard MRI both in contrast-enhancing as well as non-contrast-enhancing gliomas.

Value for Treatment Planning: Biopsy and Resection

Implementation of PET into biopsy and resection planning is advantageous, as PET better delineates tumor extent compared with standard MRI and additionally identifies intratumoral heterogeneity, including malignant foci in non-contrast-enhancing gliomas.

Numerous studies have investigated the benefit of incorporating ¹⁸F-FDG or **amino acid** PET into biopsy target planning. The identification of malignant foci (“hot spots”) in MRI heterogeneous gliomas is essential for biopsy planning to ensure that the biologically most aggressive portion of the tumor, which determines the patient’s prognosis as well as treatment, is not undersampled.^{26,42} There are several reports that illustrate the advantages of amino acid PET-based resection planning, of considerable importance whenever functional, eloquent areas may be involved,^{26,34,43} and which demonstrate a higher probability of detecting more highly malignant areas within an MRI heterogeneous glioma as well as decreased risk of incomplete resection.^{44,45,46}

- Integration of amino acid PET into surgical planning allows better delineation of the extent of resection beyond margins visible with standard MRI. This is of considerable importance whenever functional eloquent areas of brain are involved.
- For biopsy planning, amino acid PET is particularly helpful in identifying malignant foci within non-contrast-enhancing gliomas.

Value for Treatment Planning: Radiation

Beyond MRI-based morphologic gross tumor volume delineation, a biological tumor volume may be defined by radiotracer uptake on amino acid PET that identifies tumor beyond the extent visible with standard MRI.⁴⁷ In addition, the biologic and metabolic information provided by PET may identify subregions of tumor at higher risk of recurrence, which can be included in the radiation boost volume. The ability to better define tumor extent and biology may be used to improve the therapeutic ratio of radiation treatment. The current recommendations focus on the role of PET for radiation planning of WHO grades

III/IV gliomas, as the role of PET imaging in irradiation of WHO grade II gliomas is not well established.

Small, prospective studies systematically comparing contrast MRI tumor volume (the “standard” radiation boost target) and ¹⁸F-FDG uptake abnormality generally demonstrate a smaller region of ¹⁸F-FDG uptake contained within the MRI abnormality, with only occasional extension outside of the MRI target.^{48,49} Although small studies have demonstrated the feasibility of radiation boost planning using ¹⁸F-FDG PET, its utility is limited by the low contrast between tumor and normal cortex.⁴⁸

Studies analyzing patterns of failure following conventional chemoradiotherapy based on standard MRI-defined tumor volumes suggest that **amino acid** PET-defined tumor volumes may yield a more appropriate radiation target volume.^{50–52} In these small studies, a proportionate increase in marginal or noncentral tumor recurrences were seen when regions of ¹¹C-MET and ¹⁸F-FET abnormality were not adequately covered by high-dose radiation. Prospective, single-arm studies evaluating the use of amino acid PET for radiation treatment planning of recurrent WHO grades III/IV glioma suggest the feasibility of this approach, and most studies suggest an improvement in outcome compared with radiation planning based on conventional MRI alone.^{53,54} However, the inclusion of amino acid PET-based tumor volumes in standard-dose radiation therapy and reirradiation protocols continue to demonstrate a predominance of in-field tumor recurrences, highlighting the need for more effective therapies.^{53–56}

- Amino acid PET may improve the delineation of a biological tumor volume beyond conventional MRI and identify aggressive tumor subregions that may be targeted by radiation therapy.
- While ¹⁸F-FDG PET is of limited utility in radiation treatment planning of WHO grades III/IV gliomas, radiation planning using amino acid PET appears feasible, with preliminary evidence of potential benefit.

Follow-up: Treatment Response, Progression, Pseudoprogression, and Radionecrosis

To date, standard, structural MRI is the most important diagnostic tool for assessing treatment effects in patients with gliomas.⁴ The extent of contrast enhancement on MRI is usually considered an indicator of treatment response (eg, Macdonald criteria, RANO criteria),^{5,57} although its reliability in distinguishing tumor tissue from treatment effects, which can include blood–brain barrier breakdown, is limited.⁵⁸ For example, transient blood–brain barrier alteration with contrast enhancement—such as after radiotherapy with or without concomitant temozolomide—can mimic tumor progression and is termed “pseudoprogression.”^{59,60} In addition, since the introduction of anti-angiogenic agents such as bevacizumab, the phenomenon of pseudoresponse complicates the assessment of treatment response using standard MRI alone.^{59,61}

WHO grades III/IV glioma

Few ¹⁸F-FDG PET studies have measured the glucose metabolic rate following either radiotherapy, chemotherapy, or both: decrease of ¹⁸F-FDG uptake correlates with treatment

response.^{62–64} ¹⁸F-FDG PET has been found to be of only moderate additional value to MRI for differentiation between malignant glioma recurrence and radionecrosis, especially due to low specificity.^{65,66,67,68} However, there are several limitations: most studies were retrospective, jointly assessed gliomas of all WHO grades, used differing treatments, had varying assessment strategies, and utilized varying ¹⁸F-FDG thresholds of tumor to normal brain for image interpretation.

The feasibility and usefulness of **amino acid** PET such as ¹¹C-MET, ¹⁸F-FET, or ¹⁸F-FDOPA PET for treatment assessment after chemoradiotherapy, stereotactic brachytherapy, chemotherapy, and other experimental approaches have been demonstrated in several studies, primarily in WHO grades III/IV gliomas. Current amino acid PET data suggest that a reduction of amino acid uptake and/or a decrease of the metabolically active tumor volume is a sign of treatment response associated with long-term outcome.^{69–73} Amino acid PET using ¹⁸F-FET may facilitate the diagnosis of pseudoprogression in glioblastoma patients within the first 12 weeks following completion of chemoradiotherapy.⁷⁴

Furthermore, several studies suggest that treatment response and outcome in bevacizumab therapy can be assessed by amino acid PET using ¹⁸F-FET and ¹⁸F-FDOPA better than by MRI.^{75–78}

Amino acid PET is useful for the differentiation between treatment-related changes and true progression with high sensitivity and specificity.^{37,79,80} A combination of static and dynamic ¹⁸F-FET PET parameters identified correctly progressive or recurrent glioma with higher accuracy (93%) than conventional MRI.⁸¹

WHO grade II glioma

In contrast to patients with WHO grades III/IV gliomas, the experience with **amino acid PET** for monitoring after treatment in patients with WHO grade II gliomas is limited, with only a few studies available in the literature.^{82,83} As these tumors are usually negative on **¹⁸F-FDG PET**, the latter is not suitable for response evaluation.

- Analysis of ¹⁸F-FDG uptake does not reliably distinguish between recurrence and radionecrosis.
- A decrease in amino acid uptake and/or volume is associated with treatment response across gliomas of WHO grades III/IV.
- Amino acid PET improves the assessment of pseudoprogression, radionecrosis, and pseudoresponse.

Prognostication

The prognostic value of **¹⁸F-FDG** uptake in gliomas has been suggested by several studies.^{84–87} Additionally, pretreatment ¹⁸F-FDG PET has been reported to correlate with survival in patients with newly diagnosed glioblastoma⁸⁸ or recurrent high-grade gliomas receiving bevacizumab.⁸⁹

The prognostic value of **amino acid** PET has been increasingly explored.^{15,90–92} At diagnosis, *dynamic* ¹⁸F-FET PET identified highly aggressive astrocytomas within the same WHO grade—for instance, WHO grade II gliomas with decreasing time-activity curves manifested earlier tumor progression, malignant transformation, as well as shorter survival.^{91,93} Similarly *dynamic*

¹⁸F-FET PET identified anaplastic astrocytomas with a very early decrease of time-activity curves—and consequently short time-to-peak—as having a comparably poor outcome.¹⁵

To date, the association of glioma ¹⁸F-FET uptake with survival has remained controversial. Some groups have reported a better outcome of patients with absent or only low tumoral amino acid uptake.^{86,90,94} In contrast, a larger study of ¹⁸F-FET-negative glioma patients did not reveal an association with improved outcome, as neither time to transformation, which was proven upon histological evaluation, nor overall survival differed from that of FET-positive glioma patients.¹⁵

A prospective multicenter trial investigating the role of pretreatment ¹⁸F-FET PET in newly diagnosed glioblastoma found biological tumor volume prior to chemoradiotherapy to be highly prognostic for outcome.⁴⁶ This is in accordance with results of previous studies investigating amino acid PET in malignant glioma prior to therapy.^{69,95}

- Uptake of ¹⁸F-FDG and amino acid tracer is associated with outcome in WHO grades III/IV glioma both in a pretreatment setting and following therapy.
- Biological tumor volume in amino acid PET is associated with survival following therapy in glioblastoma.
- Dynamic analysis of ¹⁸F-FET uptake provides prognostic information within all grades of glioma prior to treatment.

Current Limitations

While ¹⁸F-FDG is used at all PET sites, only a few centers offer amino acid PET so far. However, due to the ¹⁸F labeling of FET and FDOPA, the radiotracer can be delivered in the same way as ¹⁸F-FDG, facilitating the availability of amino acid PET. Only for ¹¹C-MET is an on-site cyclotron required. The major obstacle for the widespread use of amino acid PET in glioma patients is to date the limited reimbursement by health insurance companies/institutions, despite the fact that current data clearly favor amino acid over ¹⁸F-FDG PET.

Across all tracers, numerous studies differed in terms of methodology, which limits comparability of data and might eventually jeopardize acceptance in the clinical setting. However, this guideline collected convincing support that PET imaging is of additional value beyond MRI in glioma management.

Outlook Perspective

Future clinical studies should consider the use of amino acid PET as an imaging modality for gliomas complementary to MRI. Standardized technical guidelines for PET imaging procedures and recommendations by the EANM/EANO/RANO group will be published separately.

Funding

This work has not been funded.

Conflict of interests statement. M.W. has received research grants from Acceleron, Actelion, Alpinia Institute, Bayer, Isarna, MSD, Merck & Co, Novocure, PIQUR, and Roche and honoraria for lectures or advisory board participation or consulting from Celldex, Immunocellular

Therapeutics, Isarna, Magforce, MSD, Merck & Co, Northwest Biotherapeutics, Novocure, Pfizer, Roche, and Teva. M.M.K. has received research funding from EpicentRx, Inc. C.I.F. has received personal fees from Bayer and GE Healthcare, advisory board fees from Bayer, Endocyte, and GE Healthcare, grants from GE Healthcare, Pierre Fabre, and Siemens Healthcare. W.P. is consultant for Celldex Therapeutics, Imaging End-points, LLC, and Tocagen. J.A. has received financial research support from Siemens and Avid-Lilly and honoraria as a speaker or advisory board member from Bayer, Advanced Accelerator Applications, Lilly, Piramal, and General Electric. M.A.V. is an officer with intellectual property, equity, and royalty interests at Infuseon Therapeutics, is a member of DSMB Neuralstem, and is a consultant for Pharmaco-Kinesis. B.M.E. is a consultant for MedQIA, LLC and is a consultant for and has received grants from or participated on the advisory board of Siemens Healthcare, Roche/Genentech, Agios Pharmaceuticals, Bristol-Meyers Squibb, and Merck. J.C.T. is a consultant/advisory board member for Merck Serono, Roche, and Celldex. He received speakers bureau honoraria from Merck Serono, Roche, Brainlab, and Siemens. N.L.A., B.S., N.G., R.S., I.L., and M.C. report no conflicts of interest.

References

- Ostrom QT, Gittleman H, Liao P, et al. CBTRUS statistical report: primary brain and central nervous system tumors diagnosed in the United States in 2007–2011. *Neuro Oncol.* 2014;16(Suppl 4):iv1–iv63.
- Stupp R, Mason WP, van den Bent MJ, et al. Radiotherapy plus concomitant and adjuvant temozolomide for glioblastoma. *N Engl J Med.* 2005;352(10):987–996.
- Chinot OL, Wick W, Mason W, et al. Bevacizumab plus radiotherapy-temozolomide for newly diagnosed glioblastoma. *N Engl J Med.* 2014;370(8):709–722.
- Weller M, van den Bent M, Hopkins K, et al. EANO guideline for the diagnosis and treatment of anaplastic gliomas and glioblastoma. *Lancet Oncol.* 2014;15(9): e395–e403.
- Wen PY, Macdonald DR, Reardon DA, et al. Updated response assessment criteria for high-grade gliomas: Response Assessment in Neuro-Oncology working group. *J Clin Oncol.* 2010;28(11):1963–1972.
- la Fougere C, Suchorska B, Bartenstein P, et al. Molecular imaging of gliomas with PET: opportunities and limitations. *Neuro Oncol.* 2011;13(8):806–819.
- Kosaka N, Tsuchida T, Uematsu H, et al. 18F-FDG PET of common enhancing malignant brain tumors. *AJR Am J Roentgenol.* 2008;190(6):W365–W369.
- Yamashita K, Yoshiura T, Hiwatashi A, et al. Differentiating primary CNS lymphoma from glioblastoma multiforme: assessment using arterial spin labeling, diffusion-weighted imaging, and (1)(8)F-fluorodeoxyglucose positron emission tomography. *Neuroradiology.* 2013;55(2):135–143.
- Omuro AM, Leite CC, Mokhtari K, et al. Pitfalls in the diagnosis of brain tumours. *Lancet Neurol.* 2006;5(11):937–948.
- Chung JK, Kim YK, Kim SK, et al. Usefulness of 11C-methionine PET in the evaluation of brain lesions that are hypo- or isometabolic on 18F-FDG PET. *Eur J Nucl Med Mol Imaging.* 2002;29(2):176–182.
- Rapp M, Heinzel A, Galldiks N, et al. Diagnostic performance of 18F-FET PET in newly diagnosed cerebral lesions suggestive of glioma. *J Nucl Med.* 2013;54(2):229–235.
- Hutterer M, Nowosielski M, Putzer D, et al. [18F]-fluoroethyl-L-tyrosine PET: a valuable diagnostic tool in neuro-oncology, but not all that glitters is glioma. *Neuro Oncol.* 2013;15(3): 341–351.
- Floeth FW, Pauleit D, Sabel M, et al. 18F-FET PET differentiation of ring-enhancing brain lesions. *J Nucl Med.* 2006;47(5): 776–782.
- Jansen NL, Graute V, Armbruster L, et al. MRI-suspected low-grade glioma: is there a need to perform dynamic FET PET? *Eur J Nucl Med Mol Imaging.* 2012;39(6):1021–1029.
- Jansen NL, Suchorska B, Wenter V, et al. Prognostic significance of dynamic 18F-FET PET in newly diagnosed astrocytic high-grade glioma. *J Nucl Med.* 2015;56(1):9–15.
- Dunet V, Pomoni A, Hottinger A, et al. Performance of 18F-FET versus 18F-FDG-PET for the diagnosis and grading of brain tumors: systematic review and meta-analysis. *Neuro Oncol.* 2016;18(3):426–434.
- Karunanithi S, Sharma P, Kumar A, et al. Comparative diagnostic accuracy of contrast-enhanced MRI and (18)F-FDOPA PET-CT in recurrent glioma. *Eur Radiol.* 2013;23(9):2628–2635.
- Dunet V, Rossier C, Buck A, et al. Performance of 18F-fluoro-ethyl-tyrosine (18F-FET) PET for the differential diagnosis of primary brain tumor: a systematic review and Metaanalysis. *J Nucl Med.* 2012;53(2):207–214.
- Glaudemans AW, Enting RH, Heesters MA, et al. Value of 11C-methionine PET in imaging brain tumours and metastases. *Eur J Nucl Med Mol Imaging.* 2013;40(4):615–635.
- Giammarile F, Cinotti LE, Jouve A, et al. High and low grade oligodendrogliomas (ODG): correlation of amino-acid and glucose uptakes using PET and histological classifications. *J Neurooncol.* 2004;68(3):263–274.
- Manabe O, Hattori N, Yamaguchi S, et al. Oligodendroglial component complicates the prediction of tumour grading with metabolic imaging. *Eur J Nucl Med Mol Imaging.* 2015;42(6): 896–904.
- Popperl G, Kreth FW, Mehrkens JH, et al. FET PET for the evaluation of untreated gliomas: correlation of FET uptake and uptake kinetics with tumour grading. *Eur J Nucl Med Mol Imaging.* 2007;34(12):1933–1942.
- Jansen NL, Schwartz C, Graute V, et al. Prediction of oligodendroglial histology and LOH 1p/19q using dynamic [(18)F]FET-PET imaging in intracranial WHO grade II and III gliomas. *Neuro Oncol.* 2012;14(12):1473–1480.
- Moulin-Romsee G, D'Hondt E, de Groot T, et al. Non-invasive grading of brain tumours using dynamic amino acid PET imaging: does it work for 11C-methionine? *Eur J Nucl Med Mol Imaging.* 2007;34(12):2082–2087.
- Lohmann P, Herzog H, Rota Kops E, et al. Dual-time-point O-(2-[(18)F]fluoroethyl)-L-tyrosine PET for grading of cerebral gliomas. *Eur Radiol.* 2015;25(10):3017–3024.
- Kunz M, Thon N, Eigenbrod S, et al. Hot spots in dynamic (18)FET-PET delineate malignant tumor parts within suspected WHO grade II gliomas. *Neuro Oncol.* 2011;13(3):307–316.
- Schiepers C, Chen W, Cloughesy T, et al. 18F-FDOPA kinetics in brain tumors. *J Nucl Med.* 2007;48(10):1651–1661.
- Kratochwil C, Combs SE, Leotta K, et al. Intra-individual comparison of (1)(8)F-FET and (1)(8)F-DOPA in PET imaging of recurrent brain tumors. *Neuro Oncol.* 2014;16(3):434–440.
- Watanabe M, Tanaka R, Takeda N. Magnetic resonance imaging and histopathology of cerebral gliomas. *Neuroradiology.* 1992; 34(6):463–469.

30. Johnson PC, Hunt SJ, Drayer BP. Human cerebral gliomas: correlation of postmortem MR imaging and neuropathologic findings. *Radiology*. 1989;170(1 Pt 1):211–217.
31. Prieto E, Marti-Climent JM, Dominguez-Prado I, et al. Voxel-based analysis of dual-time-point 18F-FDG PET images for brain tumor identification and delineation. *J Nucl Med*. 2011;52(6):865–872.
32. Arbizu J, Tejada S, Marti-Climent JM, et al. Quantitative volumetric analysis of gliomas with sequential MRI and (1)(1)C-methionine PET assessment: patterns of integration in therapy planning. *Eur J Nucl Med Mol Imaging*. 2012;39(5):771–781.
33. Weber WA, Wester HJ, Grosu AL, et al. O-(2-[18F]fluoroethyl)-L-tyrosine and L-[methyl-11C]methionine uptake in brain tumours: initial results of a comparative study. *Eur J Nucl Med*. 2000;27(5):542–549.
34. Pafundi DH, Laack NN, Youland RS, et al. Biopsy validation of 18F-DOPA PET and biodistribution in gliomas for neurosurgical planning and radiotherapy target delineation: results of a prospective pilot study. *Neuro Oncol*. 2013;15(8):1058–1067.
35. Becherer A, Karanikas G, Szabo M, et al. Brain tumour imaging with PET: a comparison between [18F]fluorodopa and [11C]methionine. *Eur J Nucl Med Mol Imaging*. 2003;30(11):1561–1567.
36. Ledezma CJ, Chen W, Sai V, et al. 18F-FDOPA PET/MRI fusion in patients with primary/recurrent gliomas: initial experience. *Eur J Radiol*. 2009;71(2):242–248.
37. Chen W, Silverman DH, Delaloye S, et al. 18F-FDOPA PET imaging of brain tumors: comparison study with 18F-FDG PET and evaluation of diagnostic accuracy. *J Nucl Med*. 2006;47(6):904–911.
38. Fueger BJ, Czernin J, Cloughesy T, et al. Correlation of 6-18F-fluoro-L-dopa PET uptake with proliferation and tumor grade in newly diagnosed and recurrent gliomas. *J Nucl Med*. 2010;51(10):1532–1538.
39. Kracht LW, Miletic H, Busch S, et al. Delineation of brain tumor extent with [11C]L-methionine positron emission tomography: local comparison with stereotactic histopathology. *Clin Cancer Res*. 2004;10(21):7163–7170.
40. Tripathi M, Sharma R, D'Souza M, et al. Comparative evaluation of F-18 FDOPA, F-18 FDG, and F-18 FLT-PET/CT for metabolic imaging of low grade gliomas. *Clin Nucl Med*. 2009;34(12):878–883.
41. Pauleit D, Floeth F, Hamacher K, et al. O-(2-[18F]fluoroethyl)-L-tyrosine PET combined with MRI improves the diagnostic assessment of cerebral gliomas. *Brain*. 2005;128(Pt 3):678–687.
42. Pirotte B, Goldman S, Brucher JM, et al. PET in stereotactic conditions increases the diagnostic yield of brain biopsy. *Stereotact Funct Neurosurg*. 1994;63(1–4):144–149.
43. Pirotte B, Goldman S, Massager N, et al. Comparison of 18F-FDG and 11C-methionine for PET-guided stereotactic brain biopsy of gliomas. *J Nucl Med*. 2004;45(8):1293–1298.
44. Tanaka Y, Nariai T, Momose T, et al. Glioma surgery using a multimodal navigation system with integrated metabolic images. *J Neurosurg*. 2009;110(1):163–172.
45. Ewelt C, Floeth FW, Felsberg J, et al. Finding the anaplastic focus in diffuse gliomas: the value of Gd-DTPA enhanced MRI, FET-PET, and intraoperative, ALA-derived tissue fluorescence. *Clin Neurol Neurosurg*. 2011;113(7):541–547.
46. Suchorska B, Jansen NL, Linn J, et al. Biological tumor volume in 18FET-PET before radiochemotherapy correlates with survival in GBM. *Neurology*. 2015;84(7):710–719.
47. Grosu AL, Weber WA, Riedel E, et al. L-(methyl-11C) methionine positron emission tomography for target delineation in resected high-grade gliomas before radiotherapy. *Int J Radiat Oncol Biol Phys*. 2005;63(1):64–74.
48. Tralins KS, Douglas JG, Stelzer KJ, et al. Volumetric analysis of 18F-FDG PET in glioblastoma multiforme: prognostic information and possible role in definition of target volumes in radiation dose escalation. *J Nucl Med*. 2002;43(12):1667–1673.
49. Gross MW, Weber WA, Feldmann HJ, et al. The value of F-18-fluorodeoxyglucose PET for the 3-D radiation treatment planning of malignant gliomas. *Int J Radiat Oncol Biol Phys*. 1998;41(5):989–995.
50. Lee IH, Piert M, Gomez-Hassan D, et al. Association of 11C-methionine PET uptake with site of failure after concurrent temozolomide and radiation for primary glioblastoma multiforme. *Int J Radiat Oncol Biol Phys*. 2009;73(2):479–485.
51. Niyazi M, Schnell O, Suchorska B, et al. FET-PET assessed recurrence pattern after radio-chemotherapy in newly diagnosed patients with glioblastoma is influenced by MGMT methylation status. *Radiother Oncol*. 2012;104(1):78–82.
52. Mahasittiwat P, Mizoe JE, Hasegawa A, et al. L-[METHYL-(11)C] methionine positron emission tomography for target delineation in malignant gliomas: impact on results of carbon ion radiotherapy. *Int J Radiat Oncol Biol Phys*. 2008;70(2):515–522.
53. Grosu AL, Weber WA, Franz M, et al. Reirradiation of recurrent high-grade gliomas using amino acid PET (SPECT)/CT/MRI image fusion to determine gross tumor volume for stereotactic fractionated radiotherapy. *Int J Radiat Oncol Biol Phys*. 2005;63(2):511–519.
54. Miwa K, Matsuo M, Ogawa S, et al. Re-irradiation of recurrent glioblastoma multiforme using 11C-methionine PET/CT/MRI image fusion for hypofractionated stereotactic radiotherapy by intensity modulated radiation therapy. *Radiat Oncol*. 2014;9:181.
55. Weber DC, Casanova N, Zilli T, et al. Recurrence pattern after [(18)F]fluoroethyltyrosine-positron emission tomography-guided radiotherapy for high-grade glioma: a prospective study. *Radiother Oncol*. 2009;93(3):586–592.
56. Piroth MD, Pinkawa M, Holy R, et al. Integrated boost IMRT with FET-PET-adapted local dose escalation in glioblastomas. Results of a prospective phase II study. *Strahlenther Onkol*. 2012;188(4):334–339.
57. Macdonald DR, Cascino TL, Schold SC Jr., et al. Response criteria for phase II studies of supratentorial malignant glioma. *J Clin Oncol*. 1990;8:1277–1280.
58. Kumar AJ, Leeds NE, Fuller GN, et al. Malignant gliomas: MR imaging spectrum of radiation therapy- and chemotherapy-induced necrosis of the brain after treatment. *Radiology*. 2000;217:377–384.
59. Brandsma D, Stalpers L, Taal W, et al. Clinical features, mechanisms, and management of pseudoprogression in malignant gliomas. *Lancet Oncol*. 2008;9:453–461.
60. Radbruch A, Fladt J, Kickingeder P, et al. Pseudoprogression in patients with glioblastoma: clinical relevance despite low incidence. *Neuro Oncol*. 2015;17(1):151–159.
61. Brandsma D, van den Bent MJ. Pseudoprogression and pseudoreponse in the treatment of gliomas. *Curr Opin Neurol*. 2009;22(6):633–638.

62. Spence AM, Muzi M, Graham MM, et al. 2-[(18)F]Fluoro-2-deoxyglucose and glucose uptake in malignant gliomas before and after radiotherapy: correlation with outcome. *Clin Cancer Res.* 2002;8(4):971–979.
63. Rozental JM, Levine RL, Mehta MP, et al. Early changes in tumor metabolism after treatment: the effects of stereotactic radiotherapy. *Int J Radiat Oncol Biol Phys.* 1991;20(5):1053–1060.
64. Charnley N, West CM, Barnett CM, et al. Early change in glucose metabolic rate measured using FDG-PET in patients with high-grade glioma predicts response to temozolomide but not temozolomide plus radiotherapy. *Int J Radiat Oncol Biol Phys.* 2006;66(2):331–338.
65. Caroline I, Rosenthal MA. Imaging modalities in high-grade gliomas: pseudoprogression, recurrence, or necrosis? *J Clin Neurosci.* 2012;19(5):633–637.
66. Nishashi T, Dahabreh IJ, Terasawa T. Diagnostic accuracy of PET for recurrent glioma diagnosis: a meta-analysis. *AJNR Am J Neuroradiol.* 2013;34(5):944–950. S1–11.
67. Van Laere K, Ceysens S, Van Calenbergh F, et al. Direct comparison of 18F-FDG and 11C-methionine PET in suspected recurrence of glioma: sensitivity, inter-observer variability and prognostic value. *Eur J Nucl Med Mol Imaging.* 2005;32(1):39–51.
68. Chao ST, Suh JH, Raja S, et al. The sensitivity and specificity of FDG PET in distinguishing recurrent brain tumor from radionecrosis in patients treated with stereotactic radiosurgery. *Int J Cancer.* 2001;96(3):191–197.
69. Galldiks N, Langen K, Holy R, et al. Assessment of treatment response in patients with glioblastoma using [18F]fluoroethyl-L-tyrosine PET in comparison to MRI. *J Nucl Med.* 2012;53:1048–1057.
70. Galldiks N, Kracht LW, Burghaus L, et al. Use of 11C-methionine PET to monitor the effects of temozolomide chemotherapy in malignant gliomas. *Eur J Nucl Med Mol Imaging.* 2006;33(5):516–524.
71. Jansen NL, Suchorska B, Schwarz SB, et al. [18F]fluoroethyltyrosine-positron emission tomography-based therapy monitoring after stereotactic iodine-125 brachytherapy in patients with recurrent high-grade glioma. *Mol Imaging.* 2013;12:137–147.
72. Pöpperl G, Goldbrunner R, Gildehaus FJ, et al. O-(2-[18F]fluoroethyl)-L-tyrosine PET for monitoring the effects of convection-enhanced delivery of paclitaxel in patients with recurrent glioblastoma. *Eur J Nucl Med Mol Imaging.* 2005;32:1018–1025.
73. Pöpperl G, Götz C, Rachinger W, et al. Serial O-(2-[(18)F]fluoroethyl)-L-tyrosine PET for monitoring the effects of intracavitary radioimmunotherapy in patients with malignant glioma. *Eur J Nucl Med Mol Imaging.* 2006;33:792–800.
74. Galldiks N, Dunkl V, Stoffels G, et al. Diagnosis of pseudoprogression in patients with glioblastoma using O-(2-[18F]fluoroethyl)-L-tyrosine PET. *Eur J Nucl Med Mol Imaging.* 2015;42(5):685–695.
75. Harris RJ, Cloughesy TF, Pope WB, et al. 18F-FDOPA and 18F-FLT positron emission tomography parametric response maps predict response in recurrent malignant gliomas treated with bevacizumab. *Neuro Oncol.* 2012;14(8):1079–1089.
76. Galldiks N, Rapp M, Stoffels G, et al. Response assessment of bevacizumab in patients with recurrent malignant glioma using [18F]fluoroethyl-L-tyrosine PET in comparison to MRI. *Eur J Nucl Med Mol Imaging.* 2013;40:22–33.
77. Schwarzenberg J, Czernin J, Cloughesy TF, et al. Treatment response evaluation using 18F-FDOPA PET in patients with recurrent malignant glioma on bevacizumab therapy. *Clin Cancer Res.* 2014;20:3550–3559.
78. Hutterer M, Nowosielski M, Putzer D, et al. O-(2-18F-fluoroethyl)-L-tyrosine PET predicts failure of antiangiogenic treatment in patients with recurrent high-grade glioma. *J Nucl Med.* 2011;52(6):856–864.
79. Herrmann K, Czernin J, Cloughesy T, et al. Comparison of visual and semiquantitative analysis of 18F-FDOPA-PET/CT for recurrence detection in glioblastoma patients. *Neuro Oncol.* 2014;16(4):603–609.
80. Walter F, Cloughesy T, Walter MA, et al. Impact of 3,4-dihydroxy-6-18F-fluoro-L-phenylalanine PET/CT on managing patients with brain tumors: the referring physician's perspective. *J Nucl Med.* 2012;53(3):393–398.
81. Galldiks N, Stoffels G, Filss C, et al. The use of dynamic O-(2-18F-fluoroethyl)-L-tyrosine PET in the diagnosis of patients with progressive and recurrent glioma. *Neuro Oncol.* 2015;17(9):1293–1300.
82. Voges J, Herholz K, Holzer T, et al. 11C-methionine and 18F-2-fluorodeoxyglucose positron emission tomography: a tool for diagnosis of cerebral glioma and monitoring after brachytherapy with 125I seeds. *Stereotact Funct Neurosurg.* 1997;69(1–4 Pt 2):129–135.
83. Wyss M, Hofer S, Bruehlmeier M, et al. Early metabolic responses in temozolomide treated low-grade glioma patients. *J Neurooncol.* 2009;95(1):87–93.
84. Patronas NJ, Di Chiro G, Kufta C, et al. Prediction of survival in glioma patients by means of positron emission tomography. *J Neurosurg.* 1985;62(6):816–822.
85. De Witte O, Lefranc F, Levivier M, et al. FDG-PET as a prognostic factor in high-grade astrocytoma. *J Neurooncol.* 2000;49(2):157–163.
86. Singhal T, Narayanan TK, Jacobs MP, et al. 11C-methionine PET for grading and prognostication in gliomas: a comparison study with 18F-FDG PET and contrast enhancement on MRI. *J Nucl Med.* 2012;53(11):1709–1715.
87. Colavolpe C, Metellus P, Mancini J, et al. Independent prognostic value of pre-treatment 18-FDG-PET in high-grade gliomas. *J Neurooncol.* 2012;107(3):527–535.
88. Omuro A, Beal K, Gutin P, et al. Phase II study of bevacizumab, temozolomide, and hypofractionated stereotactic radiotherapy for newly diagnosed glioblastoma. *Clin Cancer Res.* 2014;20(19):5023–5031.
89. Colavolpe C, Chinot O, Metellus P, et al. FDG-PET predicts survival in recurrent high-grade gliomas treated with bevacizumab and irinotecan. *Neuro Oncol.* 2012;14(5):649–657.
90. Floeth FW, Sabel M, Stoffels G, et al. Prognostic value of 18F-fluoroethyl-L-tyrosine PET and MRI in small nonspecific incidental brain lesions. *J Nucl Med.* 2008;49(5):730–737.
91. Jansen NL, Suchorska B, Wenter V, et al. Dynamic 18F-FET PET in newly diagnosed astrocytic low-grade glioma identifies high-risk patients. *J Nucl Med.* 2014;55(2):198–203.
92. Thon N, Kunz M, Lemke L, et al. Dynamic F-FET PET in suspected WHO grade II gliomas defines distinct biological subgroups with different clinical courses. *Int J Cancer.* 2015;136(9):2132–2145.
93. Galldiks N, Stoffels G, Ruge MI, et al. Role of O-(2-18F-fluoroethyl)-L-tyrosine PET as a diagnostic tool for detection of malignant progression in patients with low-grade glioma. *J Nucl Med.* 2013;54(12):2046–2054.

94. Floeth FW, Pauleit D, Sabel M, et al. Prognostic value of O-(2-18F-fluoroethyl)-L-tyrosine PET and MRI in low-grade glioma. *J Nucl Med.* 2007;48(4):519–527.
95. Galldiks N, Dunkl V, Kracht LW, et al. Volumetry of [(11)C]-methionine positron emission tomographic uptake as a prognostic marker before treatment of patients with malignant glioma. *Mol Imaging.* 2012;11(6):516–527.
96. Ullrich RT, Kracht L, Brunn A, et al. Methyl-L-11C-methionine PET as a diagnostic marker for malignant progression in patients with glioma. *J Nucl Med.* 2009;50(12):1962–1968.
97. Dunet V, Maeder P, Nicod-Lalonde M, et al. Combination of MRI and dynamic FET PET for initial glioma grading. *Nuklearmedizin.* 2014;53(4):155–161.
98. Nioche C, Soret M, Gontier E, et al. Evaluation of quantitative criteria for glioma grading with static and dynamic 18F-FDopa PET/CT. *Clin Nucl Med.* 2013;38(2):81–87.
99. Chen W, Cloughesy T, Kamdar N, et al. Imaging proliferation in brain tumors with 18F-FLT PET: comparison with 18F-FDG. *J Nucl Med.* 2005;46(6):945–952.
100. Galldiks N, Ullrich R, Schroeter M, et al. Volumetry of [(11)C]-methionine PET uptake and MRI contrast enhancement in patients with recurrent glioblastoma multiforme. *Eur J Nucl Med Mol Imaging.* 2010;37(1):84–92.
101. Pirotte B, Goldman S, Dewitte O, et al. Integrated positron emission tomography and magnetic resonance imaging-guided resection of brain tumors: a report of 103 consecutive procedures. *J Neurosurg.* 2006;104(2):238–253.
102. Galldiks N, Kracht LW, Dunkl V, et al. Imaging of non- or very subtle contrast-enhancing malignant gliomas with [(11)C]-methionine positron emission tomography. *Mol Imaging.* 2011;10(6):453–459.
103. Piroth MD, Holy R, Pinkawa M, et al. Prognostic impact of postoperative, pre-irradiation (18)F-fluoroethyl-L-tyrosine uptake in glioblastoma patients treated with radiochemotherapy. *Radiother Oncol.* 2011;99(2):218–224.
104. Filss CP, Galldiks N, Stoffels G, et al. Comparison of 18F-FET PET and perfusion-weighted MR imaging: a PET/MR imaging hybrid study in patients with brain tumors. *J Nucl Med.* 2014;55(4):540–545.
105. Cicone F, Filss CP, Minniti G, et al. Volumetric assessment of recurrent or progressive gliomas: comparison between F-DOPA PET and perfusion-weighted MRI. *Eur J Nucl Med Mol Imaging.* 2015;42(6):905–915.
106. Rose S, Fay M, Thomas P, et al. Correlation of MRI-derived apparent diffusion coefficients in newly diagnosed gliomas with [18F]-fluoro-L-dopa PET: what are we really measuring with minimum ADC? *AJNR Am J Neuroradiol.* 2013;34(4):758–764.
107. Popperl G, Gotz C, Rachinger W, et al. Value of O-(2-[18F]fluoroethyl)-L-tyrosine PET for the diagnosis of recurrent glioma. *Eur J Nucl Med Mol Imaging.* 2004;31(11):1464–1470.
108. Karunanithi S, Sharma P, Kumar A, et al. 18F-FDOPA PET/CT for detection of recurrence in patients with glioma: prospective comparison with 18F-FDG PET/CT. *Eur J Nucl Med Mol Imaging.* 2013;40(7):1025–1035.
109. Villani V, Carapella CM, Chiaravalloti A, et al. The Role of PET [18F]FDOPA in Evaluating Low-grade Glioma. *Anticancer Res.* 2015;35(9):5117–5122.
110. Massager N, David P, Goldman S, et al. Combined magnetic resonance imaging- and positron emission tomography-guided stereotactic biopsy in brainstem mass lesions: diagnostic yield in a series of 30 patients. *J Neurosurg.* 2000;93(6):951–957.
111. Braun V, Dempf S, Weller R, et al. Cranial neuronavigation with direct integration of (11)C methionine positron emission tomography (PET) data—results of a pilot study in 32 surgical cases. *Acta Neurochir.* 2002;144(8):777–782.
112. Sadeghi N, Salmon I, Tang BN, et al. Correlation between dynamic susceptibility contrast perfusion MRI and methionine metabolism in brain gliomas: preliminary results. *J Magn Reson Imaging.* 2006;24(5):989–994.
113. Goldman S, Levivier M, Pirotte B, et al. Regional methionine and glucose uptake in high-grade gliomas: a comparative study on PET-guided stereotactic biopsy. *J Nucl Med.* 1997;38(9):1459–1462.
114. Pirotte BJ, Lubansu A, Massager N, et al. Results of positron emission tomography guidance and reassessment of the utility of and indications for stereotactic biopsy in children with infiltrative brainstem tumors. *J Neurosurg.* 2007;107(5 Suppl):392–399.
115. Pirotte BJ, Levivier M, Goldman S, et al. Positron emission tomography-guided volumetric resection of supratentorial high-grade gliomas: a survival analysis in 66 consecutive patients. *Neurosurgery.* 2009;64(3):471–481.
116. Stockhammer F, Plotkin M, Amthauer H, et al. Correlation of F-18-fluoro-ethyl-tyrosin uptake with vascular and cell density in non-contrast-enhancing gliomas. *J Neurooncol.* 2008;88(2):205–210.
117. Misch M, Guggemos A, Driever PH, et al. (18)F-FET-PET guided surgical biopsy and resection in children and adolescence with brain tumors. *Childs Nerv Syst.* 2015;31(2):261–267.
118. Tsuyuguchi N, Takami T, Sunada I, et al. Methionine positron emission tomography for differentiation of recurrent brain tumor and radiation necrosis after stereotactic radiosurgery—in malignant glioma. *Ann Nucl Med.* 2004;18(4):291–296.
119. Mehrkens JH, Popperl G, Rachinger W, et al. The positive predictive value of O-(2-[18F]fluoroethyl)-L-tyrosine (FET) PET in the diagnosis of a glioma recurrence after multimodal treatment. *J Neurooncol.* 2008;88(1):27–35.
120. Rachinger W, Goetz C, Popperl G, et al. Positron emission tomography with O-(2-[18F]fluoroethyl)-L-tyrosine versus magnetic resonance imaging in the diagnosis of recurrent gliomas. *Neurosurgery.* 2005;57(3):505–511.