

Julia Lewandowska

**Retinal damage in ocular contusions:
a prospective bicentric study**

Dissertation

Tutors:

Professor Krystyna Pecold

Professor Jean-François Charlin

Study realized in co-direction

**in Department of Ophthalmology at Poznań University of Medical Sciences
and Department of Ophthalmology at University of Rennes**

Poznań 2010

ACKNOWLEDGEMENT

I wish to express my sincere gratitude
to Professor Krystyna Pecold
and Professor Jean-François Charlin,
my thesis tutors
and to all who helped me to realize this study.

CONTENTS

| | |
|--|-----------|
| LIST OF ABBREVIATIONS | 6 |
| SUMMARY | 7 |
| STRESZCZENIE..... | 10 |
| RESUME..... | 22 |
| 1.0. INTRODUCTION..... | 34 |
| 2.0. RETINA | 36 |
| 2.1. Retinal cells..... | 36 |
| 2.1.1. Retinal pigment epithelium (RPE)..... | 36 |
| 2.1.2. Photoreceptors..... | 36 |
| 2.1.3. Bipolar cells..... | 37 |
| 2.1.4. Ganglion cells..... | 37 |
| 2.1.5. Horizontal and amacrine cells..... | 38 |
| 2.1.6. Müller's cells..... | 38 |
| 2.2. Histology | 38 |
| 2.3. Topography | 39 |
| 2.3.1. Posterior pole topography | 39 |
| 2.3.2. Retinal periphery topography | 39 |
| 2.4. Vitreoretinal adhesions and tractions..... | 40 |
| 2.5. Retinal vascularisation..... | 41 |
| 2.5.1. Arterial system..... | 41 |
| 2.5.2. Venous system..... | 42 |
| 3.0. EYE FUNDUS EXAMINATION AND IMAGING METHODS.. | 43 |
| 3.1. Ophthalmoscopy..... | 43 |
| 3.2. Biomicroscopy | 47 |
| 3.3. Eye fundus photography..... | 49 |
| 3.4. Modalities of eye fundus examination methods..... | 50 |
| 3.5. Fluorescein angiography | 50 |
| 3.6. Ultrasonography..... | 52 |

| | |
|--|-----------|
| 3.7. Optical coherence tomography (OCT) | 53 |
| 4.0. OCULAR TRAUMA | 54 |
| 4.1. Ocular Trauma Score (OTS)..... | 54 |
| 4.2. Birmingham Eye Trauma Terminology System (BETTS) | 55 |
| 4.2.1. Type of injury | 55 |
| 4.2.1.1. Open-globe injuries | 55 |
| 4.2.1.2. Closed-globe injuries | 55 |
| 4.2.2. Grade..... | 56 |
| 4.2.3. Relative afferent pupil defect | 56 |
| 4.2.4. Zone | 56 |
| 4.3. Ocular contusions..... | 57 |
| 5.0. RETINAL CONTUSIONS | 58 |
| 5.1. Pathophysiology | 58 |
| 5.1.1. Cup-contrecoup theory | 58 |
| 5.1.2. Pathogenesis of peripheral damage..... | 58 |
| 5.1.3. Pathogenesis of posterior pole damage..... | 59 |
| 5.2. Diagnosis of retinal contusions..... | 60 |
| 5.2.1. Symptoms | 60 |
| 5.2.1.1. Immediate..... | 60 |
| 5.2.1.2. Retarded | 60 |
| 5.2.2. Classification..... | 60 |
| 5.2.2.1. Depending on contusion mechanism | 60 |
| 5.2.2.2. Depending of contusion damage location | 61 |
| 5.2.3. Mechanism and clinical appearance of well-defined entities of traumatic posterior segment abnormalities | 62 |
| 5.2.3.1. from direct eye injury..... | 62 |
| 5.2.3.1.1. Commotio retinae (Retinal concussion / Retinal contusion)..... | 62 |
| 5.2.3.1.2. Choroidal rupture..... | 63 |
| 5.2.3.1.3. Retinal breaks and posttraumatic retinal detachment | 65 |
| 5.2.3.1.4. Optic nerve avulsion (Anterior indirect traumatic optic neuropathy) | 69 |
| 5.2.3.1.5. Traumatic chorioretinal rupture (scleropetaria)..... | 70 |
| 5.2.3.1.6. Vitreous base avulsion | 71 |
| 5.2.3.2. retinal contusions from remote injuries (orbit and head) | 71 |
| 5.2.3.2.1. Whiplash retinopathy | 71 |
| 5.2.3.2.2. Terson's syndrome..... | 72 |
| 5.2.3.3. from remote injuries..... | 73 |
| 5.2.3.3.1. Purtscher's retinopathy | 73 |
| 5.2.3.3.2. Valsalva retinopathy (Venous retinopathy)..... | 74 |
| 5.2.3.3.3. Fat embolism syndrome (FES)..... | 76 |
| 5.2.3.3.4. Shaken baby syndrome..... | 76 |
| 5.3. Retinal contusions treatment..... | 77 |
| 5.3.1. Medical treatment | 77 |
| 5.3.2. Prophylaxis of retinal detachment..... | 77 |
| 5.3.2.1. Laser photocoagulation | 77 |
| 5.3.2.2. Cryotherapy | 78 |

| | |
|--|------------|
| 5.3.2.3. Causes of prophylaxis failure..... | 79 |
| 5.3.3. Other laser treatment..... | 79 |
| 5.3.4. Surgical treatment..... | 79 |
| 5.3.4.1. External surgery (Scleral buckling)..... | 79 |
| 5.3.4.1.1. Local explants..... | 79 |
| 5.3.4.1.2. Encirclement..... | 80 |
| 5.3.4.1.3. Subretinal fluid drainage (SFD)..... | 80 |
| 5.3.4.1.4. Causes of external surgery failure..... | 80 |
| 5.3.4.2. Vitrectomy..... | 80 |
| 5.3.4.2.1. Tamponading agents..... | 81 |
| 5.3.4.2.2. Postoperative complications..... | 82 |
| | |
| 6.0. OUR STUDY..... | 83 |
| 6.1. Aim and type of the study..... | 83 |
| 6.2. Patients and methods..... | 83 |
| 6.2.1. Inclusion criteria..... | 83 |
| 6.2.2. Exclusion criteria..... | 83 |
| 6.3. Methods..... | 83 |
| 6.3.1. Initial examination..... | 83 |
| 6.3.1.1. Interview..... | 83 |
| 6.3.1.2. Examination..... | 84 |
| 6.3.1.3. Imaging examinations..... | 84 |
| 6.3.1.4. Classification after initial examination..... | 84 |
| 6.3.2. Follow-up examinations..... | 85 |
| 6.3.3. Treatment..... | 85 |
| 6.3.4. Data analysis..... | 85 |
| 6.3.4.1. Clinical analysis..... | 85 |
| 6.3.4.2. Statistical methods..... | 85 |
| 6.4. Results..... | 86 |
| | |
| 7.0. DISCUSSION..... | 118 |
| 7.1. Study value..... | 118 |
| 7.2. Study limitations..... | 118 |
| 7.3. Comparison of study results with results of literature..... | 119 |
| | |
| 8.0 CONCLUSIONS..... | 125 |
| | |
| BIBLIOGRAPHY..... | 126 |

LIST OF ABBREVIATIONS

AT. – ambulatory treatment
BCVA – best corrected visual acuity
BETTS – Birmingham Eye Trauma Terminology System
CF – count fingers
CHU – Centre Hospitalier Universitaire
CRAO – central retinal artery occlusion
DD – disc diameter
ETDRS – Early Treatment Diabetic Retinopathy Study
F – females
FA – fluorescein angiography
FAZ – foveal avascular zone
FES – fat embolism syndrome
HM – hand movements
Hospit. – hospitalization
ILM – internal limiting membrane
IOP – intraocular pressure
LP – light perception
M – males
MAVC – meilleure acuité visuelle corrigée
MAR – minimum angle of resolution
NLP – no light perception
OCT – optical coherence tomography
OLM – outer limiting membrane
OTS – Ocular Trauma Score
Ppv – pars plana vitrectomy
PVD – posterior vitreous detachment
PVR – Proliferative Vitreoretinopathy
RPE – retinal pigment epithelium
SFD – subretinal fluid drainage
USEIR – United States Eye Injury Registry
VA – visual acuity
VEP – visual evoked potentials

SUMMARY

Introduction and purpose

Ocular contusions are closed-globe injuries resulting from blunt forces (BETTS) and occur during chock, shaking or compression. These forces may damage the globe directly or indirectly following orbital, cranial or remote injury. Damage of eye posterior segment are at high risk of permanent visual consequences. Retrospective analysis of ocular trauma characteristics, especially demographic and economic ones were frequent. Less frequent, retinal contusions studies were mostly retrospective and focused on the particular clinical form or activity result.

In the literature, there is no prospective study which analyze all retinal consequences of ocular contusions in the context of etiology, evolution and prognosis.

The organization of follow-up visits for patients with different types of retinal blunt post-traumatic damage is to be considered a distinct issue.

In the context of potential severe consequences of retinal contusions, possible prevention and in some cases, prognosis amelioration by early diagnosis and treatment, the determination of risk population, occupations and damage characteristics appears to be fundamental.

The aim of this prospective study, realized in cooperation between Poznań Medical University and University of Rennes 1, was to evaluate epidemiology, etiology, initial characteristics and 12 month evolution of closed-globe blunt retinal injuries in 35 eyes of patients from Poznań and Rennes. We hoped that results of this study would give helpful indications concerning prevention, prognosis and adapted follow-up proposed to patients with retinal contusion damage.

Patients and methods

34 patients with diagnosis of retinal damage following ocular contusion dated of 5 days or less were included into the study. 19 patients (20 eyes) were diagnosed at the Eye Emergency of Poznań District Hospital on 14-month period and 15 patients (15 eyes) at the one of Pontchaillou Hospital of Rennes on 10-month period. A prospective observational study included data providing from interview, clinical examination and imaging at initial presentation and during one-year follow-up. Depending on initial examination, groups of patients were distinguished according to:

1. initial best corrected visual acuity (BCVA)
2. damage extent
3. recruitment center.

Clinical and statistical analysis was performed.

Results

25 males (74%) and 9 females (26%) at age from 7 to 58 years were included. Mean age was $32,7 \pm 14,4$ years. The number of man over 40 was significantly higher in Poznań ($p < 0,05$). Everyday activities accounted for 68 % of cases in Poznań, whereas sport for 40 % in Rennes, $p < 0,05$. The most frequent damage on initial examination was commotio retinae (91%). It was isolated in 34% of cases. The rest was accompanied by: choroidal ruptures, RPE damage, retinal and vitreous hemorrhages, papillar and retinal edema, vitreous base avulsion and macular hematoma. Initial BCVA was $< 5/10$ in 49 % of cases in both centers ($p > 0,05$). In Rennes damage localized both centrally and peripheraly dominated (60 %) and BCVA was significantly lower in this group comparing with the corresponding group in Poznań. 44 % of patients were hospitalized immediately after the presentation, the time of hospitalization was longer in Poznań (6,75 versus 3 days, $p < 0,05$). On first month follow-up retinal breaks were diagnosed in three patients in Poznań (retinal dialysis, multiple one quadrant tears, retinal hole). Four patients in Rennes were found to have respectively: operculated tear, retinal elevation, retinal detachment without break and macular hole in the first posttraumatic month. In 5 from total 35 eyes peripheral retinal laser was performed. Six eyes required retinal surgery. One-year central retina sequellae of blunt eye injury were present in 12 of 35 eyes (34%) in both centers and included: pigmented maculopathy, macular atrophy, epimacular membranes, indirect choroidal ruptures, ruptures of Bruch's membrane, late macular hole and optic neuropathy. One-year peripheral sequellae of blunt eye injury included: direct choroidal ruptures, choroido-retinal rupture (sclopetaria), posttraumatic retinoschisis and posttraumatic retinopathy and were found in ten eyes (29%).

In both centers BCVA increased significantly one year after the trauma. It was of 0,5 or better in 83 % of patients. However 49 % had permanent eye fundus damage.

Conclusions

Results of this study show that retinal contusive damage, as other eye trauma, dominate in men. The number of male patients over 40 seems to be higher in Poznań.

Everyday activities appear to be the most common cause of retinal contusions in Poznań, whereas sport in Rennes.

Comotio retinae is the most frequent closed-globe blunt traumatic damage diagnosed at initial examination but it seems to be the unique type of lesion only in one third of cases. In Rennes retinal contusive damage seems to be more severe regarding BCVA and lesions extent. The presence of retinal damage should be ruled out after each ocular contusion. Careful retinal periphery re-examination in the first month after the injury should be performed in all cases of initial retinal damage.

The presence of central retinal post-traumatic sequellae impose more frequent, prolonged follow-up and repeated imaging examinations because of the risk of retarded complications.

Initial post-traumatic visual acuity and damage extent have a prognostic value and related to the possibility of retinal visualization may help to adapt a follow-up strategy.

The information on ocular trauma risks and use of eye protection during sport, leisure and domestic activities should be enhanced to reduce the incidence and severity of ocular trauma.

STRESZCZENIE

USZKODZENIA SIATKÓWKI W URAZACH NIEPRZENIKAJĄCYCH GAŁKI OCZNEJ: BADANIE PROSPEKTYWNE DWUŚRODKOWE

I. Wprowadzenie

Urazy oczu stanowią jedną z głównych przyczyn pogorszenia widzenia w krajach rozwiniętych. Zgodnie z obecnie przyjętą klasyfikacją urazów mechanicznych (BETTS) stłuczenie gałki ocznej jest definiowane jako uraz nieprzenikający tępy, tzn. spowodowany przekształceniem energii mechanicznej podczas uderzenia, wstrząśnięcia lub ucisku. Uszkodzenia w gałce ocznej mogą być skutkiem urazu bezpośredniego lub pośredniego poprzez uraz oczodołu, głowy lub struktur oddalonych. Zmiany pourazowe zlokalizowane w tylnym odcinku oka niosą ryzyko trwałego upośledzenia widzenia.

Dotychczasowe doniesienia na temat uszkodzeń siatkówki powstałych na skutek urazów nieprzenikających są nieliczne, najczęściej retrospektywne i zazwyczaj ograniczone do określonych aspektów urazów, przypadków konkretnej formy klinicznej lub spowodowanych określonym czynnikiem sprawczym.

W dostępnym piśmiennictwie brak jest prospektywnej oceny stłuczeń gałki ocznej manifestujących się w odcinku tylnym, pod kątem etiopatogenezy, przebiegu i rokowania. nierozwiązanym problemem pozostaje organizacja badań kontrolnych u pacjentów z uszkodzeniami siatkówki na skutek urazu nieprzenikającego.

W kontekście potencjalnych poważnych powikłań, możliwej prewencji oraz polepszenia rokowania w niektórych formach poprzez wczesną diagnozę i odpowiednie leczenie, istotnym zdaje się określenie grupy narażonej na wystąpienie tępych nieprzenikających uszkodzeń siatkówki, czynności sprzyjających tym urazom oraz cech zmian o podwyższonym ryzyku trwałych uszkodzeń.

Celem niniejszej pracy, realizowanej w ramach współpracy między Uniwersytetem Medycznym w Poznaniu i Uniwersytetem w Rennes, była ocena epidemiologii, etiologii, stopnia oraz rocznej ewolucji uszkodzeń siatkówki powstałych na skutek stłuczenia gałki ocznej u pacjentów

zdiagnozowanych w czasie ostrego dyżuru okulistycznego Szpitala Wojewódzkiego w Poznaniu i Szpitala Uniwersyteckiego w Rennes.

Oczekiwaliśmy, że wyniki badania pozwolą na uzyskanie praktycznych wskazówek odnośnie rokowania i postępowania kontrolnego u pacjentów, u których zdiagnozowano świeże zmiany siatkówki na skutek tępego nieprzenikającego urazu gałki ocznej.

Po przedstawieniu budowy siatkówki człowieka, metod badania tylnego odcinka gałki ocznej oraz klasyfikacji urazów mechanicznych, dokonano przeglądu przedstawianych w literaturze uszkodzeń siatkówki powstałych na skutek urazów tępych nieprzenikających. Następnie prezentowane i dyskutowane są wyniki badania własnego.

II. Siatkówka

W rozdziale, w oparciu o literaturę, przedstawiono ogólną charakterystykę komórek siatkówki. Opisano komórki nabłonka barwnikowego (RPE), zwłaszcza w kontekście ich roli w utrzymywaniu integralności przestrzeni podsiatkówkowej i udziału w metabolizmie fotoreceptorów. Przedstawiono funkcje i cechy różnicujące komórki fotoreceptorowe siatkówki człowieka: pręciki i czopki. W budowie fotoreceptorów zwrócono uwagę na cechy członu zewnętrznego, zawierającego barwnik wrażliwy na światło, wewnętrznego oraz części tworzącej synapsę. Opisano kolejne siatkówkowe neurony drogi wzrokowej (komórki dwubiegunowe i zwojowe), neurony asocjacyjne (komórki horyzontalne i amakrynowe) oraz komórki glejowe Müllera, rozciągające się od błony granicznej zewnętrznej do błony granicznej wewnętrznej i stanowiące rusztowanie dla wszystkich elementów siatkówki. Przedstawiono budowę histologiczną siatkówki na podstawie badań w mikroskopie świetlnym (10 warstw) oraz topografię. Zdefiniowano rejony bieguna tylnego (plamkę, dołek i dołeczek) oraz obwodu siatkówki aż do rąbka zębatego. Zwrócono uwagę na markery anatomiczne obwodowej części dna oka. Następnie przedstawiono zagadnienie połączeń szkliskowo-siatkówkowych (fizjologicznych i patologicznych) oraz trakcji (statycznych i dynamicznych). Opisano unaczynienie tętnicze i żylnie siatkówki. Podkreślono fakt odżywiania warstw zewnętrznych siatkówki przez choriokapilary, a warstw wewnętrznych przez tętnicę środkową siatkówki.

III. Metody badania i obrazowania dna oka

W rozdziale przybliżono historię rozwoju metod badania dna oka począwszy od oftalmoskopu bezpośredniego do optycznej koherentnej tomografii (OCT).

Wynalezienie oftalmoskopu przez Helmholtza i jego wprowadzenie do użytku w 1851 r. zrewolucjonizowało diagnostykę i leczenie chorób oczu. Kolejne modyfikacje zaowocowały udoskonaleniem oftalmoskopii bezpośredniej oraz pojawieniem się oftalmoskopii pośredniej, z której wyewoluowała stereo-oftalmoskopia. Przedstawiono charakterystykę poszczególnych metod oftalmoskopowych, uwzględniając zasadę działania, wady i zalety.

Pojawienie się lampy szczelinowej i rozwój soczewek dodatkowych doprowadziły do upowszechnienia biomikroskopii tylnego odcinka gałki ocznej, umożliwiającej uzyskanie przekroju optycznego oraz dokonanie dokładnej oceny przestrzennej oglądanych struktur.

W rozdziale dokonano charakterystyki soczewek stosowanych w biomikroskopii tylnego odcinka: wypukłych i wklęsłych oraz kontaktowych i bezkontaktowych. Następnie przedstawiono zasady fotografowania dna oka oraz zalety badania w świetle monochromatycznym. Scharakteryzowano metodę angiografii fluoresceinowej, uwzględniając podstawy badania, obraz prawidłowego oraz patologicznego angiogramu. Przedstawiono zastosowanie ultrasonografii oraz OCT w diagnostyce tylnego odcinka gałki ocznej wraz z możliwościami prezentacji obrazu w tych metodach.

IV. Urazy gałki ocznej

W rozdziale przedstawiono skalę OTS oceny urazów gałki ocznej. Na podstawie obecności określonych cech bezpośrednio po urazie, wyznacza ona prawdopodobieństwo kategorii ostrości wzroku sześć miesięcy później. Scharakteryzowano także obecnie obowiązującą klasyfikację urazów mechanicznych gałki ocznej według Birmingham Eye Trauma Terminology (BETT). Klasyfikacja dzieli urazy gałki ocznej na te, w których doszło do przerwania ciągłości ściany (open- globe) i te, w których integralność ściany została zachowana- nieprzenikające (closed – globe). Uwzględnia dla każdej z dwóch kategorii:

1. typ urazu:

- z przerwaniem ciągłości ściany: pęknięcie gałki, perforację, penetrację oraz obecność ciała obcego wewnątrzgałkowego;

- bez przerywania ciągłości ściany gałki ocznej (nieprzenikający): ranę warstwową, ciało obce powierzchniowe oraz stłuczenie.
2. stopień według najlepszej skorygowanej ostrości wzroku w badaniu pourazowym
 3. defekt drogi dośrodkowej w reakcji źrenicy na światło
 4. strefę dotkniętą urazem.

Zgodnie z powyższą klasyfikacją stłuczenie definiowane jest jako uszkodzenie spowodowane przekształceniem energii mechanicznej podczas urazu tępego nieprzenikającego: uderzenia, wstrząśnięcia lub ucisku. Uszkodzenia w gałce ocznej mogą być skutkiem urazu bezpośredniego lub pośredniego poprzez uraz oczodołu, głowy lub struktur oddalonych. Wymieniono zmiany będące skutkiem urazu nieprzenikającego w odcinku przednim gałki ocznej. Zasygnalizowano, że uszkodzenia bezpośrednie w odcinku tylnym mogą umiejscawiać się w miejscu zadziałania czynnika sprawczego jak i w strefie przeciwległej.

V. Stłuczenia siatkówki

Patofizjologia

Rozdział otwiera przedstawienie patofizjologii stłuczeń gałki ocznej.

Teoria cup- contrecoup wysunięta w 1963 r. przez Woltera zakładała powstawanie zmian bezpośrednio w miejscu zadziałania siły oraz w miejscu przeciwległym.

Badania eksperymentalne, przeprowadzone przez Weidenthala i Schepensa wykazały predyspozycję rejonu podstawy ciała szklistego i rąbka zębatego do powstawania zmian pourazowych. Obserwowano największe narażenie na zmiany pourazowe kwadrantów skroniowo-dolnych, najmniej chronionych przez oczodół.

Delori, Pomerantzeff i Cox kontynuowali badania nad uszkodzeniami pourazowymi na obwodzie dna oka. Wyodrębnili cztery etapy w sekwencji zdarzeń po urazie tępym gałki ocznej:

1. skrócenie przednio-tylnego wymiaru gałki ocznej na skutek działającej siły,
2. dekompresja gałki ocznej ze wzrostem obwodu w okolicy równikowej do 111 % wartości przedurazowej
3. wydłużenie gałki ocznej do 112 % długości przed urazem
4. oscylacje całej gałki ocznej.

Badanie potwierdziło największe odkształcenia w rejonie podstawy ciała szklanego oraz rąbka zębatego siatkówki.

Badaniem centralnych zmian pourazowych zajęli się Pruett, Weiter i Goldstein. Obserwowali stożkową deformację bieguna tylnego, tłumaczącą powstawanie pęknięć błony Brucha koncentrycznie w stosunku do tarczy nerwu wzrokowego.

Diagnostyka

W podrozdziale dotyczącym diagnostyki stłuczeń siatkówki zwrócono uwagę na ich częstą bezobjawowość. Natychmiastowe objawy subiektywne mogą towarzyszyć uszkodzeniom nerwu wzrokowego, fotoreceptorów dołkowych lub nabłonka barwnikowego w tym obszarze, krwotokom siatkówkowym, podsiatkówkowym lub przedsiatkówkowym zajmującym obszar dołka lub krwotokowi do ciała szklanego rzutującemu się na ten region. Opóźnione objawy pourazowe często wiążą się z wystąpieniem powikłań: makulopatii (atrofia, błony nasiatkówkowe, otwór w plamce) lub neuropatii. Wystąpienie fotopsji może sugerować trakcję siatkówkowo- szklaną w miejscach patologicznych połączeń szklanek- siatkówkowych na skutek pourazowego odłączenia tylnego ciała szklanego. Natomiast pojawienie się ubytku w polu widzenia postrzeganego jako zasłona, sugeruje odwarstwienie siatkówki.

W rozdziale przedstawiono klasyfikację stłuczeń siatkówki na podstawie mechanizmu powstania, wyróżniając:

bezpośrednie (mechanizm cup i contre-coup):

- wstrząśnienie siatkówki
- pęknięcie naczyniówki
- otwory siatkówki
- awulsję nerwu wzrokowego
- przedarcie naczyniówkowo- siatkówkowe (sclopetaria)
- oderwanie podstawy ciała szklanego

oraz **pośrednie**:

spowodowane urazem oczodołu oraz głowy

- retinopatia typu whiplash
- przedarcie naczyniówkowo- siatkówkowe (sclopetaria)
- zespół Tersona

spowodowane urazem okolic oddalonych od gałki ocznej

- retinopatia Purtschera
- retinopatia Valsalvy
- zespół zatorów tłuszczowych
- zespół dziecka potrząsanego.

Sklassyfikowano także powyższe uszkodzenia uwzględniając ich lokalizację w obrębie bieguna tylnego lub obwodu siatkówki. Na podstawie dostępnej literatury scharakteryzowano szczegółowo powyższe jednostki kliniczne uszkodzeń siatkówki na skutek stłuczenia gałki ocznej w aspekcie mechanizmu powstania, obrazu dna oka, badań obrazowych (angiografii fluoresceinowej, OCT oraz ultrasonografii), podziału oraz ewolucji.

Leczenie

Poruszono problem braku leków o udowodnionej skuteczności w leczeniu zmian pourazowych siatkówki. Zwrócono uwagę na możliwość samoistnego cofania się zmian krwotocznych oraz zamykania otworów w plamce. W aspekcie profilaktyki odwarstwienia siatkówki przedstawiono podstawy stosowania oraz wskazania do fotokoagulacji siatkówki laserem argonowym oraz zastosowania krioaplikacji. Zasygnalizowano użycie laserów w innych zmianach pourazowych. Przedstawiono metody chirurgicznego leczenia pourazowego odwarstwienia siatkówki: chirurgię zewnątrzgałkową (klasyczną) oraz witrektomię. Dla każdej z metod przedstawiono podstawy stosowania, wskazania oraz przyczyny niepowodzenia.

VI. Badanie własne

Cel pracy

Celem pracy była ocena epidemiologii, etiologii, stopnia, ewolucji i następstw uszkodzeń siatkówki powstałych na skutek stłuczenia gałki ocznej u pacjentów zdiagnozowanych w czasie ostrego dyżuru okulistycznego Szpitala Wojewódzkiego w Poznaniu i Szpitala Uniwersyteckiego w Rennes oraz uzyskanie wskazówek praktycznych odnośnie rokowania i zasad kontroli u tych pacjentów.

Pacjenci i metody

Grupę badaną stanowiło 34 pacjentów z uszkodzeniami siatkówki na skutek stłuczenia gałki ocznej zaistniałego w okresie do 5 dni przed zgłoszeniem się pacjenta na ostry dyżur okulistyczny. 19 pacjentów (20 oczu) zdiagnozowano na ostrym dyżurze okulistycznym Szpitala Wojewódzkiego w Poznaniu w łącznym okresie 14 miesięcy, 15 pacjentów (15 oczu) na ostrym dyżurze okulistycznym Szpitala Uniwersyteckiego w Rennes w okresie 10 miesięcy. Grupę objęto badaniem prospektywnym. Uwzględniono dane pochodzące z: wywiadu, badania okulistycznego i badań dodatkowych przeprowadzanych podczas badania wstępnego i badań kontrolnych w ciągu roku po urazie.

Pacjentów podzielono na grupy według danych z badania wstępnego:

1. najlepszej skorygowanej ostrości wzroku
2. lokalizacji uszkodzeń
3. ośrodka rekrutacji.

Otrzymane wyniki poddano analizie klinicznej oraz statystycznej.

Analizę statystyczną przeprowadzono za pomocą programów: Statistica 9 i StatXact 8. W przypadku parametrów odbiegających od rozkładu normalnego, przedstawiono ich mediany, kwartyle oraz wartości minimalne i maksymalne. Do analizy danych jakościowych wykorzystano testy statystyczne przeznaczone dla grup o małej liczebności: test dokładny Fishera oraz test Fishera-Freemana-Haltona. Do analizy danych ilościowych zastosowano testy t-Studenta oraz nieparametryczne testy Mann-Whitney'a i Wilcoxon. Wartość $p < 0,05$ uznano za istotną statystycznie. W celu analizy statystycznej dokonano konwersji ostrości wzroku ze skali dziesiętnej na skalę logarytmiczną.

Wyniki

Do badania włączono 25 mężczyzn (74%) i 9 kobiet (26%) w wieku od 7 do 58 lat. Średni wiek pacjentów wynosił $32,7 \pm 14,4$ lat. Liczba mężczyzn powyżej 40 r. ż była istotnie wyższa wśród włączonych do badania w Poznaniu ($p < 0,05$). Tabela 6.1 podsumowuje cechy demograficzne badanej grupy, natomiast Ryc. 1 przedstawia strukturę wiekową pacjentów w obu ośrodkach. Główną przyczyną urazu w Poznaniu były czynności codzienne (68%), a w Rennes sport (40 %), $p < 0,05$. Graficzne podsumowanie przyczyn urazu powodującego stłuczenie siatkówki przedstawiają Ryc. 2 i 3. Zbiorcze zestawienie wszystkich okoliczności urazu zawiera Tabela 6.2.

Tabela 6.3 przedstawia miejsce pierwszego zgłoszenia się pacjenta, a Tabela 6.4 czas od urazu do pełnego badania okulistycznego. Najczęstszym typem uszkodzeń w badaniu wstępnym były wstrząśnienia siatkówki (91%). W 66 % przypadków towarzyszyły im inne zmiany: pęknięcia naczyńki, uszkodzenia nabłonka barwnikowego siatkówki, krwotoki siatkówkowe i/lub do ciała szklonego, obrzęk tarczy nerwu wzrokowego i siatkówki, oderwanie podstawy ciała szklonego i krwotok w plamce. Szczegółowe dane na temat uszkodzeń siatkówki stwierdzonych w badaniu wstępnym, przyczyny urazu, towarzyszących uszkodzeń w odcinku przednim, ostrości wzroku po urazie oraz rodzaju początkowego leczenia w obu ośrodkach zawarte są w tabelach 6.5 i 6.6. Tabela 6.7 podsumowuje lokalizację pourazowych zmian siatkówkowych. W Rennes dominowały uszkodzenia zlokalizowane zarówno w biegunie tylnym, jak i na obwodzie siatkówki (60%), a ostrość wzroku w tej grupie była znacząco niższa niż w odpowiadającej grupie w Poznaniu. Tabela 6.8 zawiera dane na temat ostrości wzroku w badaniu wstępnym w obu ośrodkach. Natychmiastowej hospitalizacji poddano 44 % pacjentów. Wynik był porównywany w Poznaniu i w Rennes ($p>0,05$). Czas trwania hospitalizacji był dłuższy w Poznaniu ($p<0,05$). W Tabeli 6.9 przedstawiono podsumowanie wskazań w przypadkach natychmiastowej hospitalizacji. We wszystkich oczach leczenie miejscowe było dostosowane indywidualnie według ogólnie przyjętych zasad (przeciwbakteryjne, przeciwzapalne, obniżające ciśnienie wewnątrzgałkowe). U 13 z 34 pacjentów zastosowano ogólnie glikokortykosteroidy: 9 z 19 pacjentów w Poznaniu (47%) i 4 z 15 w Rennes (27%). Schemat badań kontrolnych uwzględniał pourazową ostrość wzroku oraz rozległość zmian siatkówkowych. Wyniki badań z rocznego okresu obserwacji przedstawiono w tabelach według ośrodka rekrutacji oraz rozległości zmian w badaniu wstępnym. Zamieszczono zdjęcia dna oka oraz badań obrazowych dla wybranych przypadków z każdej grupy.

Tabela 6.10 podsumowuje dane z badań kontrolnych u pacjentów ze zmianami zarówno centralnymi jak i obwodowymi zdiagnozowanymi w Poznaniu.

Przedstawiono zdjęcia dna oka, OCT oraz angiografię fluoresceinową u pacjentów po urazach petardą (przypadek 1), podczas gry w paintball (przypadek 9), na skutek uderzenia korkiem od szampana (przypadek 14).

W Tabeli 6.11 zamieszczono podsumowanie rocznych badań kontrolnych u pacjentów ze zmianami centralnymi i obwodowymi, zdiagnozowanych w Rennes. Przedstawiono zdjęcia

dna oka oraz badań dodatkowych po urazach: podczas gry w paintball (przypadek 1 i 2), linką holowniczą (przypadek 5) oraz piłką nożną (przypadek 6).

Wyniki badań u pacjentów ze zmianami wyłącznie centralnymi w badaniu wstępnym w obu ośrodkach zawierają kolejno tabele 6.12 i 6.13. Przedstawiono dokumentację obrazową u pacjentów z Poznania: po urazie piłą tarczową (przypadek 2), po uderzeniu smyczą elastyczną (przypadek 7) oraz po zderzeniu z chrabąszczem (przypadek 11).

Tabela 6.14 przedstawia wyniki badań u pacjentów ze zmianami obwodowymi zdiagnozowanymi w ośrodku poznańskim. Przedstawiono zdjęcia dna oka u pacjenta po urazie kawałkiem drewna (przypadek 18). Wyniki badań tej grupy pacjentów z Rennes zawiera Tabela 6.15. Zamieszczono zdjęcia dna oka pacjenta po urazie gałęzią (przypadek 15).

Podczas badań kontrolnych w pierwszym miesiącu po urazie zdiagnozowano otwory siatkówki u trzech pacjentów w ośrodku poznańskim (oderwanie od rąbka, mnogie przedarcia w jednym kwadrancie, otwór siatkówki). U czterech pacjentów w Rennes w ciągu miesiąca od urazu stwierdzono kolejno: otwór z wieczkiem, uniesienie siatkówki obwodowej bez otworu, odwarstwienie siatkówki bez otworu oraz otwór w plamce.

Laseroterapię siatkówki wykonano w 5 oczach, a zabiegi chirurgiczne siatkówki w 6 z 35 oczu włączonych do badania (Tabela 6.16). Po roku od urazu uszkodzenia siatkówki w biegunie tylnym były obecne w 12 z 35 oczu (34%) i obejmowały: zmiany barwnikowe w plamce, atrofię plamki, błony nasiatkówkowe, pęknięcia naczyńki, pęknięcia błony Brucha, późny otwór w plamce oraz neuropatię nerwu wzrokowego. Uszkodzenia siatkówki obwodowej były obecne w 10 oczach (29% wszystkich włączonych do badania) i obejmowały pęknięcia naczyńki, przedarcia siatkówkowo-naczyńkowe (sclopetaria), pourazowe retinoschisis oraz obszary pourazowej retinopatii.

W obu ośrodkach średnia ostrość wzroku po roku od urazu była istotnie wyższa od ostrości wzroku w badaniu wstępnym ($p < 0,05$). Statystycznie istotne polepszenie ostrości wzroku obserwowano w grupie z ostrością początkową $< 0,5$. 83 % ogółu pacjentów miało po roku od urazu ostrość wzroku 0,5 lub wyższą (Tabela 6.17). Trwałe pourazowe zmiany siatkówki obserwowano w 49 % ogółu przypadków (Tabela 6.18).

VII. Dyskusja

Wartość badania

Podkreślono prospektywny charakter badania oraz uwzględnienie wszystkich typów stłuczeń siatkówki. Zwrócono uwagę na dokumentację fotograficzną i obrazową pourazowych uszkodzeń oraz fakt przeprowadzania badań kontrolnych pacjentów przez jednego i tego samego lekarza. Zaznaczono, iż ośrodki rekrutacji pacjentów analizowanych w badaniu różnią się systemem organizacji doraźnej pomocy okulistycznej: w Poznaniu okulista dostępny jest 24 godziny na dobę, w Rennes dyżuruje od godziny 9 do 17, poza tymi godzinami konsultuje na wezwanie.

Ograniczenia badania

Uwzględniono niewielką liczebność badanych grup i związane z tym trudności badań statystycznych. Podkreślono jednakże objęcie badaniem wyselekcjonowanej grupy pacjentów. Zwrócono uwagę na niski udział w badaniu pacjentów ze zmianami siatkówki na skutek urazów wielonarządowych, spowodowany zazwyczaj ciężkim ogólnym stanem pacjentów. Także udział przypadków pediatrycznych, w związku ze specyfiką okulistycznej pomocy doraźnej dla dzieci, wydaje się być zaniżony.

Porównanie z dostępną literaturą

W rozdziale podkreślono zgodność wyników epidemiologicznych uzyskanych u pacjentów ze stłuczeniami siatkówki z dostępnymi danymi z literatury dotyczącej ogólnie urazów gałki ocznej. Zwrócono uwagę na większy udział w Poznaniu mężczyzn po 40 r.ż. oraz znaczące różnice w okolicznościach urazów w obu ośrodkach, związane najprawdopodobniej z różnicami w stylu życia w dwóch krajach. Przytoczono badania dotyczące wszystkich typów urazów gałki ocznej, gdzie sport odpowiadał w większości za urazy nieprzenikające, ciężkie. Poruszono problem kulturowych uwarunkowań uprawiania sportu oraz rosnącej popularności nowych dyscyplin sportowych i para-sportowych jak: squash, paintball, halowa piłka nożna. W kontekście wyników badania własnego oraz wcześniejszych doniesień, zwrócono uwagę na konieczność odpowiedniej informacji pacjentów na temat ryzyka urazu oczu oraz odpowiedniej ochrony.

Zwrócono uwagę na stosowaną w ośrodku w Rennes wstępną selekcję pacjentów przed konsultacją okulistyczną. Związany był z tym dłuższy czas od momentu urazu do badania okulistycznego. Jednakże na podstawie wcześniejszych doniesień oraz własnych obserwacji, jeśli badanie ma miejsce w ciągu pierwszych dni po urazie, dokładny czas do zgłoszenia się pacjenta,

nie wpływa znacząco na postępowanie lecznicze w odniesieniu do zmian urazowych siatkówki. Podkreślono znaczenie badania wstępnego z oceną ostrości wzroku i rozległości zmian. Szczególną uwagę zwrócono na fakt, iż zmianom na dnie oka mogą towarzyszyć jedynie niewielkie uszkodzenia aparatu ochronnego gałki ocznej lub odcinka przedniego.

Podkreślono brak konsensusu, co do ogólnego leczenia pacjentów ze stłuczeniami siatkówki oraz znaczenie indywidualizacji leczenia i bazowania na własnych doświadczeniach ośrodków.

Uwzględniono problem pourazowych otworów oraz odwarstwienia siatkówki. Badania eksperymentalne wykazały, że otwory siatkówki powstają w momencie urazu. Jednakże dane z literatury podają iż, tylko 18 % pourazowych odwarstwień siatkówki diagnozowanych jest w pierwszym miesiącu po urazie. Przyczyny należy upatrywać w ignorowaniu urazu przez pacjenta, niemożności uwidocznienia obwodu dna oka w badaniu wstępnym z powodu zaburzeń przejerności lub dyskomfortu pacjenta oraz zgłaszania się pacjentów dopiero po wystąpieniu objawów odwarstwienia siatkówki. Wcześniejsze badania podkreślały potrzebę badań kontrolnych u pacjentów po urazach gałki ocznej. Jednakże tylko w kilku przypadkach kontrolni pacjenci zostali uwzględnieni, a w każdym przypadku dotyczył określonych postaci klinicznych stłuczeń siatkówki (odwarstwienia siatkówki, zmian na dnie oka towarzyszących obecności krwi w komorze przedniej). Autorzy zwracali także uwagę na trudności w przeprowadzaniu badań kontrolnych ze względu na młody wiek pacjentów, ich dużą mobilność oraz częsty brak objawów okulistycznych.

W badaniu własnym przyjęto schemat badań kontrolnych uwzględniający pourazową ostrość wzroku oraz rozległość uszkodzeń. W każdym przypadku częstość wizyt była również dostosowywana indywidualnie. Wszystkie otwory siatkówki grożące potencjalnie jej odwarstwieniem, zdiagnozowano w pierwszym miesiącu po urazie. W ciągu roku po urazie nie zdiagnozowano żadnych nowych otworów siatkówki obwodowej. Obserwowano natomiast ewolucję zmian na dnie oka oraz u części pacjentów trwałe następstwa urazów siatkówki.

VIII. Wnioski

1. Wyniki badania wskazują, że na wystąpienie stłuczeń siatkówki najbardziej narażeni są mężczyźni. Liczba mężczyzn po 40 r.ż była wyższa w Poznaniu niż w Rennes. Czynności

codzienne stanowiły najczęstszą przyczynę urazów siatkówki w stłuczeniach gałki ocznej w Poznaniu, a sport w Rennes.

2. Wstrząśnienie siatkówki było najczęściej diagnozowaną zmianą w badaniu wstępnym, jednakże tylko w jednej trzeciej przypadków, było to uszkodzenie izolowane. Zmiany pourazowe diagnozowane w Rennes były cięższe pod względem pourazowego obniżenia ostrości wzroku oraz rozległości.
3. Obecność uszkodzeń siatkówki należy brać pod uwagę po każdym nieprzenikającym urazie gałki ocznej. Dokładna kontrola obwodu dna oka powinna być przeprowadzona w pierwszym miesiącu po każdym stłuczeniu gałki z uszkodzeniem siatkówki.
4. Większa częstotliwość, a także długofalowość kontroli i powtarzanie badań obrazowych, są wskazane w przypadku zmian pourazowych o lokalizacji centralnej.
5. Wstępna pourazowa ostrość wzroku i lokalizacja uszkodzeń mają znaczenie rokownicze, a w połączeniu z możliwościami wizualizacji dna oka mogą pomóc w przyjęciu odpowiedniej strategii postępowania.

Informacje na temat ryzyka uszkodzenia gałki ocznej, odpowiedniej ochrony oczu podczas codziennych czynności, uprawiania sportu czy rozrywek są konieczne celem zmniejszenia częstości oraz następstw urazów gałki ocznej.

RESUME

LESIONS RETINIENNES D'ORIGINE CONTUSIVE: ETUDE PROSPECTIVE BICENTRIQUE

I. Introduction

Le traumatisme oculaire est une des causes majeures de baisse d'acuité visuelle dans les pays développés.

Selon la classification contemporaine des traumatismes mécaniques (BETTS), les contusions oculaires sont définies comme des traumatismes à globe fermé résultant de la transmission d'énergie mécanique au cours d'un choc, d'un coup ou d'une compression. Elles peuvent être directes ou indirectes suivant le traumatisme de l'orbite, de la tête ou des structures éloignées. L'atteinte du segment postérieur du globe oculaire est à risque majeure des conséquences visuelles permanentes.

Peu nombreuses et dans la majorité des cas retrospectives, les études antérieures sur les lésions rétiniennes produites suite aux contusions du globe oculaire, sont limitées aux formes cliniques spécifiques ou manifestations résultant d'une activité précise.

Dans la littérature, il n'existe pas d'évaluation prospective des contusions rétiniennes dans le cadre d'étiopathogénie, d'évolution et du pronostic. De plus, il n'y a pas de consensus concernant le suivi de ces patients.

Dans le contexte de conséquences potentiellement graves, de prévention possible et d'amélioration du pronostic dans certains types de lésions par le diagnostic précoce et traitement adapté, il est de fondamental de définir la population, les occupations et les caractéristiques des lésions à risque.

Cette étude, réalisée dans le cadre de coopération entre l'Université de Médecine de Poznań et l'Université de Rennes 1, a eu pour but d'évaluer épidémiologie, étiologie, caractéristiques cliniques initiales et évolution sur 12 mois des contusions rétiniennes chez des patients diagnostiqués aux urgences ophtalmologiques de l'Hôpital Départemental de Poznań et de l'Hôpital Pontchaillou du Centre Hospitalier Universitaire de Rennes. Nous espérons ainsi

d'obtenir des indications pratiques au sujet du pronostic et du suivi chez des patients atteints des lésions rétiniennes d'origine contusive.

Après un rappel sur l'organisation de la rétine humaine, des méthodes diagnostiques du segment postérieur de l'oeil et des classifications des traumatismes oculaires, nous proposons une revue de la littérature sur les différentes lésions rétiniennes contusives.

Nous analyserons et discuterons ensuite les résultats de notre étude personnelle.

II. Rétine

Dans ce chapitre, à partir de la littérature, les caractéristiques des cellules de la rétine humaine sont présentées. Les cellules de l'épithélium pigmentaire de la rétine ont été décrites surtout dans le contexte de leur rôle dans le maintien de l'intégrité de l'espace sous-rétinienne et dans le métabolisme des photorécepteurs. Les fonctions et les caractéristiques différentielles des photorécepteurs humains: bâtonnets et cônes, ont été présentées. Dans la structure des photorécepteurs, le segment externe contenant le pigment visuel, ainsi que le segment interne et terminaison synaptique ont été analysés. Les neurones suivant les photorécepteurs dans la voie visuelle (cellules bipolaires et ganglionnaires), ainsi que les neurones associatifs (cellules horizontales et amacrines) et cellules gliales de Müller, passant de la membrane limitante externe jusque l'interne et formant le squelette pour tout les autres éléments de la rétine, ont été décrits. La structure histologique de la rétine dans le microscope lumineux (10 couches) et topographie rétinienne ont été présentées. Les régions du pôle postérieur comprenant: macula, fovéa et fovéola et de la périphérie rétinienne jusque l'ora serrata ont été définis. Les marqueurs anatomiques de la périphérie rétinienne ont été soulignés. Ensuite le sujet des adhérences vitréo-rétiniennes (physiologique et pathologiques) ainsi que des tractions (statique et dynamique) a été traité. En terminant, la vascularisation artérielle et veineuse de la rétine a été présentée. Le fait de nutrition des couches externes par les choriocapillaires et des couches interne par l'artère centrale de la rétine a été exposé.

III. Méthodes d'examen et d'imagerie du segment postérieur de l'oeil

L'histoire de développement des méthodes d'examen du fond d'oeil à partir d'ophtalmoscope direct jusqu'à la tomographie en cohérence optique (OCT) a été abordée dans ce chapitre.

L'invention de l'ophtalmoscope par Helmholtz et son introduction à l'usage en 1851 ont révolutionné le diagnostic et le traitement des maladies des yeux. Les modifications suivantes ont abouti à l'affinement d'ophtalmoscopie directe et à l'introduction d'ophtalmoscopie indirecte, à partir de laquelle la stéréo-ophtalmoscopie a évolué. Les caractéristiques des méthodes ci-dessus, comprenant le principe d'utilisation, ainsi que les avantages et les inconvénients, ont été présentées. L'apparition de la lampe à fente et le développement des lentilles additionnelles ont entraîné la popularisation de la biomicroscopie du segment postérieur du globe oculaire, faisant possible la coupe optique de l'image et l'évaluation en profondeur des structures regardées.

Dans ce chapitre, les caractéristiques des lentilles convexes et concaves, contact et non-contact, utilisées au cours de la biomicroscopie du segment postérieur ont été présentées. La présentation des principes de la photographie du fond d'oeil et des avantages d'examen dans lumière monochromatique ont suivies. La caractéristique d'angiographie fluorescéinique comprenant principes d'examen, l'aspect d'angiogramme physiologique et pathologique a été donnée. Nous avons présenté l'utilisation d'ultrasonographie et d'OCT dans le diagnostic du segment postérieur d'oeil ainsi que les possibilités de présentation d'image dans ces deux méthodes.

IV. Traumatisme oculaire

Les principes du score d'OTS des traumatismes oculaires ont été exposés. D'après la présence des caractéristiques précises immédiatement après le trauma, il donne la probabilité de catégorie d'acuité visuelle six mois plus tard. La présentation de classification actuelle des traumatismes mécaniques Birmingham Eye Trauma Terminology (BETT) a suivie. Elle divise des traumatismes en deux classes: à globe ouvert et à globe fermé. Elle donne pour chacune des catégories:

1. type de traumatisme:

- à globe ouvert: rupture du globe oculaire, plaie perforante, plaie pénétrante, corps étranger intraoculaire;
- à globe fermé: plaie laméllaire, corps étranger superficiel, contusion oculaire.

2. grade selon la meilleure acuité visuelle corrigée à l'examen en post-traumatique

3. déficit de voie afférente de la réaction pupillaire à la lumière

4. zone touchée.

Selon la classification ci-dessus, contusion oculaire est définie comme traumatisme due à une transformation d'énergie mécanique au cours d'un choc, d'un coup ou d'une compression. Lésions rétiniennes peuvent être directes ou indirectes suivant le traumatisme de l'orbite, de la tête ou des structures éloignées.

Les conséquences traumatiques de contusion oculaire dans le segment antérieur ont été mentionnées. On a signalé que les altérations dans le segment postérieur, suivant le traumatisme direct de l'oeil, peuvent être localisées au lieu du choc ainsi que dans l'endroit opposé à celui-ci.

V. Lésions rétiniennes d'origine contusive

Patophysiologie

La présentation de pathophysiologie des contusions du globe oculaire ouvre ce chapitre.

Le théorie du coup- contrecoup proposée en 1963 par Wolter parle de création des lésions post-traumatiques dans le lieu du choc ainsi que dans l'endroit opposé à celui-ci.

Les expérimentations faites par Weidenthal et Schepens ont démontré la prédisposition du région de la base du vitré et d'ora serrata au traumatismes. La fréquence élevée de ces lésions dans les quadrants temporaux inférieurs a été observée et expliquée par l'exposition la plus grande due à l'anatomie de l'orbite.

Delori, Pomerantzeff et Cox ont continué les études sur les conséquences des traumatismes sur la périphérie du fond d 'oeil. Ils ont distingué quatre étapes dans la séquence d'événement après la contusion du globe:

5. raccourcissement d'axe antéro- postérieure du globe oculaire suite à l'impact
6. décompression du globe avec expansion équatoriale à 111 % de valeur initiale
7. allongement du globe à 112 % de valeur initiale
8. oscillations du globe oculaire.

L'étude a démontré les plus grandes forces dans la région de la base du vitré et d'ora serrata. Les lésions post-traumatiques centrales ont été le sujet des expérimentations de Pruett, Weiter et Goldstein. Ils ont observé une déformation conoïdale du pôle postérieur, expliquant la formation des ruptures de la membrane de Bruch concentriquement à la tête du nerf optique.

Diagnostic

Dans ce sous-chapitre la souvente absence de symptômes des contusions rétiniennes a été soulignée. Les symptômes immédiats sont liés à altération du nerf optique, des photorécepteurs fovéales, ou de l'épithélium pigmentaire de la rétine de cette région, des hémorragies rétiniennes, pré-ou sous-rétiniennes localisées dans l'aire de fovéa ou à l'hémorragie vitrénne masquant cette zone. Les symptômes retardés sont souvent liés aux complications: maculopathie (atrophie, membranes épitréiniennes, trou maculaire) ou neuropathie. La sensation de photopsie suggère une traction vitréo-rétinienne dans les zones d'adhérences pathologique vitréo-rétiniennes suite au décollement post-traumatique du vitré. Le déficit du champs visuel sous le signe du voile devant l'oeil est caractéristique du décollement de la rétine.

La classification des lésions contusives de la rétine selon le mécanisme de formation a été présentée, distinguant :

traumatismes directs (le coup et le contre-coup)

- commotio retinae
- rupture de la choroïde
- déchiscences rétiniennes
- avulsion du nerf optique
- rupture choroïdo- rétinienne (sclopetaria)
- avulsion de la base du vitré

traumatismes indirects

par traumatisme de l'orbite et de la tête

- rétinopathie de whiplash
- rupture choroïdo- rétinienne (sclopetaria)
- syndrome de Terson

par traumatisme des organes éloignés

- rétinopathie de Purtscher
- rétinopathie de Valsalva
- syndrome des embolies graisseuse
- syndrome de l'enfant secoué.

En plus, les lésions mentionnées ci-dessus ont été classées selon leur localisation dans le pôle postérieur ou dans la périphérie rétinienne. Toutes ces altérations post-traumatiques contusives de la rétine ont été caractérisées d'après une revue de la littérature dans le contexte du mécanisme, d'aspect du fond d'oeil, d'imagerie (angiographie à la fluoresceine, OCT, ultrasonographie), de classification et d'évolution.

Traitement

Le fait qu'actuellement aucun traitement médical n'a démontré son efficacité dans la prise en charge des lésions rétiniennes post-traumatique a été souligné. La possibilité de résorption spontanée des hémorragies ou de fermeture d'un trou maculaire a été mentionnée. Les principes et indications au traitement préventif par laser argon et cryoapplication des lésions rétiniennes ont été présentés. L'utilisation des lasers dans autres problèmes post-traumatiques a été signalée. Ensuite, l'auteur a caractérisé les méthodes chirurgicales du traitement de décollement de la rétine d'origine traumatique: la chirurgie externe (classique) et la vitrectomie. La présentation des principes, d'indications et causes d'échec pour chacune de ces méthodes a suivie.

VI. Etude personnelle

L'objectif

Cette étude a eu pour but d'évaluer épidémiologie, étiologie, caractéristiques cliniques initiales et évolution sur 12 mois des contusions rétiniennes chez des patients diagnostiqués aux urgences ophtalmologiques de l'Hôpital Départemental de Poznań et de l'Hôpital Pontchaillou du Centre Hospitalier Universitaire de Rennes. Nous espérons ainsi d'obtenir des indications pratiques au sujet du pronostic et du suivi chez les patients atteints des lésions rétiniennes d'origine contusive.

Patients et méthodes

34 patients diagnostiqués d'avoir des lésions rétiniennes suite à une contusion oculaire survenue au maximum 5 jours avant la présentation aux urgences ont été inclus. Il s'agissait de 19 patients (20 yeux) vus sur une période de 14 mois aux urgences ophtalmologiques de l'Hôpital Départemental de Poznań et de 15 patients (15 yeux) recrutés sur une période de 10 mois au CHU Pontchaillou de Rennes. Données d'interrogatoire, d'examen clinique et d'imagerie ont été recueillies à l'examen initial et au cours de suivi sur un an pour cette étude prospective

et observationnelle. Selon les résultats de l'examen initial, les groupes des patients ont été distingués selon :

1. la meilleure acuité visuelle corrigée (MAVC)
2. extension des lésions
3. centre du recrutement.

Analyse clinique et statistique avec le logiciel Statistica 9 et StatXact 8 a été conduite. Pour la distribution des données différant de la normale, les médians, quartiles, minimum et maximum ont été présentés. L'analyse des données qualitatives a été conduite en utilisant les tests dédiés aux groupes de faible effectif: test exact de Fisher et test de Fisher-Freeman-Halton. Les données quantitatives ont été traitées avec test t-Student et tests non- paramétriques de Mann-Whitney et Wilcoxon. La valeur de $p < 0,05$ a été considérée comme statistiquement significative. Pour l'analyse statistique les valeurs d'acuité visuelle ont été converties de l'échelle décimale en logarithmique.

Résultats

25 hommes (74%) et 9 femmes (26%) à l'âge de 7 à 58 ans ont été inclus. L'âge moyen était de $32,7 \pm 14,4$ ans. Le nombre des hommes au dessus de 40 ans était plus élevé à Poznań ($p < 0,05$). La description démographique du groupe analysé est donnée dans le Tableau 6.1 et la répartition des patients en fonction de leur âge dans les deux centres dans la Fig. 1. Les activités quotidiennes ont été une cause de traumatisme en 68 % des cas à Poznań, pendant que le sport en 40 % à Rennes, $p < 0,05$. La répartition graphique des patients dans les groupes d'activité au cours de traumatisme contusif est donnée dans les Fig. 2 et 3. Le Tableau 6.2 contient toutes les causes de traumatismes avec les manifestations oculaires. Le lieu de la première consultation du patient est présenté dans le Tableau 6.3 et le temps du traumatisme à la consultation ophtalmologique dans le Tableau 6.4.

La lésion la plus fréquente à l'examen initial, c'était commotio retinae (91%). En 66 % elle était accompagnée par: ruptures choroïdiennes, lésions de l'épithélium pigmentaire de la rétine, hémorragies rétinienne et vitréennes, l'œdème papillaire et rétinienne, avulsion de la base du vitré, hématome maculaire.

Les Tableaux 6.5 et 6.6 présentent les données précises sur les lésions diagnostiquées à l'examen initial, les raisons du traumatisme, les altérations concomitantes dans le segment antérieur, MAVC à l'examen initial et mode du traitement initial. La répartition des patients dans les groupes d'extension des lésions post-traumatiques rétiniennes est présentée dans le Tableau 6.7.

Les lésions simultanées du pôle postérieur et de la périphérie rétiniennes ont été une localisation dominante (60 %) à Rennes et MAVC dans ce groupe était inférieure à celle du groupe correspondant à Poznań ($p < 0,05$). Tableau 6.8 contient les données sur MAVC dans les deux centres. 44 % des patients dans les deux centres ont été hospitalisés à l'issue de leur présentation aux urgences. Le résultat était comparable dans les deux centres. La durée de l'hospitalisation était plus importante à Poznań ($p < 0,05$). Les indications à l'hospitalisation immédiate sont données dans le Tableau 6.9. Dans tous les cas le traitement topique était individualisé selon les principes généraux (antibactérienne, anti-inflammatoire, baissant la pression intraoculaire). Chez 13 des 34 patients le traitement général avec les glicocorticostéroïdes a été introduit: 9 de 19 patients de Poznań (47%) et 4 de 15 de Rennes (27%).

Le schéma du suivi prenait en compte la MAVC à l'examen initial ainsi que l'extension des lésions rétiniennes. Les résultats du suivi pendant un an après le traumatisme ont été présentés dans les tableaux selon le centre de recrutement et l'extension des lésions rétiniennes à l'examen initial. Les photographies du fond d'oeil ainsi que les résultats d'imagerie pour des patients provenant de chaque groupe ont été publiés.

Le Tableau 6.10 présente les données des examen du suivi des patients avec les lésions centrales et périphériques diagnostiquées à Poznań.

Les photographies du fond d'oeil, les images d'OCT et d'angiographie fluorescéinique des patients après le traumatisme avec le pétard (cas 1), au cours du paintball (cas 9), par bouchon du champagne (cas 14) ont suivies.

Les données du suivi d'un an des patients avec lésions rétiniennes centrales et périphériques diagnostiqués à Rennes ont été présenté dans le Tableau 11. Les examens d'imagerie ont été analysés chez des patients traumatisés au cours du paintball (cas 1 et 2), par tendeur (cas 5) et par football (cas 6).

Les résultats obtenus pour des patients avec les lésions uniquement centrales ont été accueillis dans les Tableaux 6.12 et 6.13. La documentation iconographiques des patients après le traumatisme avec une scie (cas 2), laisse pour le chein (cas 7) et collision avec un hanneton (cas 11). Concernant des patients avec des lésions périphériques à Poznań, les données du suivi ont été présentées dans le Tableau 6.14 et la documentation photographique du fond d'oeil après le traumatisme avec un fragment du bois (cas 18) a suivie. Les résultats pour ce groupe à Rennes sont contenus dans le Tableau 6.15. Les photographies du fond d'oeil après le traumatisme par une branche ont été présentées (cas 15).

Au cours des examens de contrôle du premier mois en post-traumatique, les déchiscences rétiniennes ont été diagnostiquées chez trois patients à Poznań (une dialyse à l'ora, des déchirures multiples sur un quadrant, un trou rétinien). Au cours du premier mois une déchirure operculée, une élévation de la rétine, un décollement de la rétine sans déchiscences et un trou maculaire ont été retrouvés chez quatre patients à Rennes. Le traitement au laser des lésions rétiniennes périphériques a été pratiqué sur 5 de 35 yeux. 6 yeux ont bénéficié d'un traitement chirurgical de la rétine (Tableau 16).

Les séquelles rétiniennes au pôle postérieur ont été présentes en 12 des 35 yeux (34%) un an après le traumatisme et comprenaient: maculopathie pigmentée, atrophie maculaire, membranes épitréiniennes, ruptures choroïdiennes indirectes, ruptures de la membrane de Bruch, trou maculaire d'apparition retardé et neuropathie optique. Suivantes lésions périphériques ont été retrouvées à un an dans les 10 yeux (29% du total): ruptures choroïdiennes directes, ruptures choroïdo-rétiniennes (sclopetaria), rétinosischisis post-traumatique et rétinopathie post-traumatique.

Une augmentation significative de la MAVC à un an a été observée dans notre série. 83 % des patients ont eu la MAVC de 0,5 ou plus (Tableau 6.17). 49 % présentaient des lésions permanentes au fond d'oeil (Tableau 6.18).

VII. Discussion

Valeur d'étude

Le façon prospective de l'étude, ainsi que la prise en compte de toutes les formes des lésions contusives ont été soulignés. Nous pensons que la documentation photographiques et d'imagerie

et le fait du suivi des patients par le même médecin sont aussi les points forts de ce travail. Les différences dans le système d'organisation des urgences ophtalmologiques dans les deux centres analysés ont été signalées: à Poznań ophtalmologiste est disponible sur place 24 heures par 24 et à Rennes de 9 h à 17 h. En dehors de ces horaires, il consulte, si convoqué.

Les limites de notre étude

Le faible effectif du groupe et difficultés d'analyse statistique ci-lié, ont été soulevés. Toutefois, un groupe précis des patients a été pris en compte. La sous-estimation des patients avec des lésions rétiniennes suite aux traumatismes multiples a été soulignée ainsi que des cas pédiatriques.

Comparaison avec la littérature

Il faut noter une concordance de nos résultats épidémiologiques avec ceux de la littérature concernant des traumatismes oculaires en général. Le plus grand nombre des patients mâles à l'âge de plus de 40 ans à Poznań ainsi que les différences dans le contexte de traumatisme dans les deux centres ont été mis en évidence et sont liés le plus probablement avec les différences de mode de vie.

Les résultats des séries de traumatismes oculaires où le sport était responsable des lésions graves à globe fermé ont été cités. Le problème des éléments culturels dans la pratique des sports et la popularité croissante des sports modernes comme squash et d'activités para-sportives comme: paintball, bungee, etc. a été soulignée. Dans ce contexte, la nécessité d'information et de protection oculaire a été soulevée. La sélection des patients avant la consultation ophtalmologique au CHU de Rennes a été mentionnée. Le plus long délai à l'examen ophtalmologique en résultait, néanmoins d'après les études précédentes et des observations personnelles si l'évaluation ophtalmologique a lieu dans les premiers jours suivant le traumatisme, le temps exact n'influence pas l'attitude thérapeutique dans la majorité des cas. La valeur d'examen ophtalmologique initial avec évaluation d'acuité visuelle et d'extension des lésions a été mis en évidence. Le fait de la possible présence des altérations rétiniennes malgré l'absence des lésions des annexes ou du segment antérieur a été rappelé. Faute de standardisation du traitement général, la valeur d'individualisation du prise en charge thérapeutique et des expériences personnelles a été mentionnée.

Le problème des déhiscences rétiniennes post-traumatiques ainsi que du décollement de la rétine a été discuté. Pendant que les études expérimentales ont démontré la production des lésions au cours d'impact, les données de la littérature parlent de seulement 18 % des décollements de la rétine diagnostiqués dans le mois suivant le traumatisme. L'ignorance du traumatisme par le patient, l'impossibilité de visualisation de la périphérie rétinienne à l'examen initial due aux altérations des milieux, gêne ressentie par le patient ou la présentation du patient seulement si les signes de décollement surviennent en sont les causes possibles.

Les études précédentes ont souligné la valeur des visites de contrôle après le traumatisme oculaire. Néanmoins, seulement quelques-unes ont intégré ce problème et dans tous les cas, il s'agissait des formes cliniques précises des lésions d'origine contusive (décollement de la rétine, lésions au fond d'oeil accompagnant l'hyphéma). Les auteurs ont souligné les difficultés résultant du jeune âge des patients, leur grande mobilité et absence des plaintes oculaires.

Dans notre étude, le schéma du suivi prenait en compte la MAVC et l'extension des lésions à l'examen post-traumatique. Dans tous les cas la fréquence des visites était adaptée selon la possibilité d'évaluation de la périphérie rétinienne. Toutes les déhiscences rétiniennes périphériques ont été diagnostiquées dans le mois suivant le traumatisme. Il n'y avait pas de nouvelles déhiscences au cours du suivi d'un an. L'évolution des lésions au fond d'oeil et chez une partie des patients, des séquelles rétiniennes permanentes d'origine contusive ont été observées.

VIII. Conclusions

1. Les résultats de cette étude permettent de constater que des contusions rétiniennes dominent chez des patients mâles. Le nombre des mâles après l'âge de 40 ans semble être plus élevé à Poznań qu'à Rennes. Les activités quotidiennes apparaissent une cause dominante des contusions rétiniennes à Poznań, pendant que le sport en est à Rennes.
2. Le commotio retinae est une lésion la plus fréquente à l'examen initial, néanmoins il est isolé seulement dans un tiers des cas. Cette étude semble indiquer que les lésions contusives rétiniennes sont plus graves vu la MAVC et leur extension.
3. La présence des lésions rétiniennes doit être exclue après chaque contusion de l'oeil. Si diagnostiquées, les lésions rétiniennes imposent des examens de contrôle. L'examen

méticuleux de la périphérie rétinienne au cours du premier mois en post-traumatique devrait avoir lieu dans tous les cas des lésions rétinienne initiales.

4. La fréquence élevée, la durée prolongée et les examen d'imagerie à répétition sont indiqué dans les cas des lésions traumatiques centrales.
5. La MAVC initiale post-traumatique et l'extension des altérations ont une valeur pronostique. Associées à la possibilité de visualisation de la périphérie du fond d'oeil, elles aident adapter stratégie des examens de contrôle.

Renseignement sur les risques des traumatismes oculaires, ainsi que sur la protection oculaire au cours du sport, loisirs et activités domestiques devrait être renforcé afin de réduire l'incidence et sévérité des traumatismes oculaires.

1.0. INTRODUCTION

Ocular trauma is an important cause of visual impairment in developed countries [29, 118, 122, 129]. Sociological and economic consequences thereof are considerable [20, 29, 129].

According to the Birmingham Eye Trauma Terminology System (BETTS), established by the Ocular Trauma Classification Group, ocular contusions are closed-globe injuries resulting from blunt forces [91, 123]. These forces may damage the ocular globe directly or indirectly following orbital, cranial or remote injury [34, 84, 146]. Damage of eye posterior segment are at high risk of permanent visual consequences.

The first mention of posttraumatic retinal damage was made in 1691 by Maître-Jan [130]. In 1854 von Graefe described choroidal rupture [35]. The first clinical description of post-traumatic retinal break was made in 1867 by Lawson and commotio retinae was depicted in 1873 by Berlin [35]. Hence many pathophysiological theories of posterior segment blunt ocular trauma were postulated and some incidents of posttraumatic damage were reproduced in experimental studies [23, 26, 67, 131]. Posterior segment examination techniques and methods of retinal diseases therapy continue to evolve.

Retrospective analysis of ocular trauma characteristics, especially demographic and economic ones were frequent [12, 83, 101, 108, 109, 129]. Less frequent, retinal contusions studies were mostly retrospective and focused on the particular clinical form [77, 78, 90, 95, 104, 128, 139, 148, 150] or activity result [13, 14, 38, 63, 71, 74, 87, 94, 99, 100, 138, 143].

In the literature, there is no prospective study which analyze all retinal consequences of ocular contusions in the context of etiology, evolution and prognosis.

The organization of follow-up visits for patients with different types of retinal blunt post-traumatic damage is to be considered a distinct issue.

In the context of potential severe consequences of retinal contusions, possible prevention and in some cases, prognosis amelioration by early diagnosis and treatment, the determination of risk population, occupations and damage characteristics appears to be fundamental.

The aim of this prospective study, realized in the cadre of the cooperation between Poznań Medical University and University of Rennes 1, was to evaluate epidemiology, etiology, initial characteristics and 12 month evolution of closed-globe blunt retinal injuries in 35 eyes of patients from Poznań and Rennes.

We hoped that results of this study would give helpful indications concerning prevention, prognosis and adapted follow-up proposed to patients with retinal contusion damage.

Having briefly discussed human retina anatomy, methods of eye's posterior segment examination and ocular trauma classification, the author reviews retinal contusions. Following that, an analysis and discussion of study results are presented.

2.0. RETINA

2.1. Retinal cells [42, 46, 81]

2.1.1. Retinal pigment epithelium (RPE) [140]

It is a monolayer of hexagonal cells lying on Bruch's membrane. Their apical villous processes envelop photoreceptors outer segments. Apex-to-apex arrangement results in a potential subretinal space. Its integrity is maintained by:

- the outer blood retina barrier, formed by RPE cells and intervening tight junctions
- active pumping of water and ions by RPE out of the subretinal space.

RPE cells are involved in vitamin A cycle, waste products degradation, nourishment of outer retinal layers, basement membrane material secretion, production of melanin, adhesion of neurosensory retina and development of photoreceptors during embryogenesis.

RPE cells may undergo hypertrophy, hyperplasia and metaplasia.

2.1.2. Photoreceptors [16]

The human retina contains two types of photoreceptors: rods and cones.

Rods, which are approximately 120 million, mediate dim-light vision (scotopic vision), are responsible for sensing contrasts, brightness and motion. They provide peripheral visual champ. Cones, in number of 6 million, function in bright light, provide visual acuity, color vision and central visual champ.

Each photoreceptor consists of an outer and an inner segment joined by a modified cilium and separated from the cell body by the outer limiting membrane. An outer segment of photoreceptor contains visual pigment. Metabolic organs are located in the inner segment. Peripheral region contains nucleus and terminal synapse.

Rods and cones are morphologically distinguishable by the shape of an outer and inner segment, position of nuclei and shape of synaptic terminals.

The photoreceptors outer segment

The outer segment of photoreceptor is the site of phototransduction- conversion of light energy into an electrical signal. It is cylindrical and long in rods (100-120 μm) and shorter (60-75 μm), tapering in width from the inner to the outer segments in cones. It contains a system of stocked membranous discs arising from invaginations of the cell plasma membrane which are constantly

renewed. In rods discs are separated from outer membrane, whereas cone discs remain connected to the surface membrane. There are four types of visual pigments, one rod pigment and three cone pigments, each composed of 11-cis-retinal and protein (opsin). Rhodopsin contained in rods peaks at 505 nm. The peak of sensitivity for cone pigments are: 575 nm for the red ones, 545 nm for green and 445 nm for the blue ones.

The photoreceptors inner segment

There are two distinct morphologic parts of the inner segment: ellipsoid and myoid. The ellipsoid contains a dense aggregation of mitochondria, whereas myoid region contains the Golgi system, scattered vesicular components and both free and membrane-bound ribosomes.

The photoreceptor peripheral region

It contains the nucleus. The axonal extension ends by specialized expanded synaptic terminal which is large in cones (pedicle) and much smaller, called spherule in rod. They synapse with bipolar and horizontal cells at the outer plexiform layer.

2.1.3. Bipolar cells

In number of approximately 35,7 million, bipolar cells are interposed between photoreceptors and ganglion cells. Their dendrites synapse with photoreceptors and horizontal cells in the outer plexiform layer, while their axon forms synapses with ganglion and amacrine cells in the inner plexiform layer.

2.1.4. Ganglion cells

There are approximately 1,2 million ganglion cells in human retina. Characterized by an abundant Nissl substance and a large Golgi apparatus, most ganglion cells bodies lie in the ganglion layer, however displaced ganglion cells have been identified in the inner nuclear layer. Their axons form the nerve fiber layer. Nerve fibers originating from periphery lie deep in the retina, whereas these originating closer to the optic nerve head lie more superficially. They exit the eye as the optic nerve and become myelinated with oligodendrocytes upon passing through the lamina cribrosa. They terminate in the lateral geniculate nucleus of the thalamus, in other diencephalic centers and the superior colliculus.

2.1.5. Horizontal and amacrine cells

Horizontal and amacrine cells are considered to be local-circuit neurons. They modulate and transform visual information which is conveyed to the brain. Their cell bodies are located in the inner nuclear layer. The horizontal cells form means of lateral communication between photoreceptor cells. Amacrine cells extend their processes to adjacent amacrine or bipolar cells and their axons synapse with ganglion cells.

2.1.6. Müller's cells

Müller's cells are major glial cells of the retina. They have a radial orientation and extend through the depths of the retina from the outer limiting membrane (OLM) to the inner limiting membrane (ILM). OLM consists of adherent junctions between Müller's cells and photoreceptor cells inner segments whereas, ILM is formed of laterally contacting Müller's cells foot and associated basement membrane constituents. Within the retina, fine processes of Müller's cells envelop blood vessels and all the neurons.

2.2. Histology [42,46]

In human retina ten histological layers have been identified:

1. Retinal pigment epithelium (RPE)
2. Outer segments of photoreceptors (OS)
3. Outer limiting membrane (OLM)

which consist of fenestrated intercellular bridges formed by tight junctions between Müller's cells and photoreceptors inner segments.

4. Outer nuclear layer (ONL)

which contains cell bodies of photoreceptors

5. Outer plexiform layer (OPL)

containing connections between rod and cones and vertically running bipolar cells and horizontally oriented horizontal cells

6. Inner nuclear layer (INL)

which contains cell bodies of bipolar, horizontal, amacrine and Müller's cells

7. Inner plexiform layer (IPL)

which is a relay station for bipolar cells to connect to ganglion and amacrine cells.

8. Ganglion cell layer (GC)

which contains cell bodies of ganglion cells

9. Nerve fibre layer (NFL)

formed by unmyelinated ganglion cell axons

10. Inner limiting membrane (ILM)

composed of laterally contacting foot processes of Müller's cell and associated basement membrane constituents. It is the surface of the retina bordering the vitreous.

2.3. Topography [81]

2.3.1. Posterior pole topography

The macula

The macula is a round area located at the posterior pole, between superior and inferior temporal arteries and measuring 5 to 6 mm of diameter. Histologically this region is cone dominated, contains xanthophyll pigment and more than one layer of ganglion cell bodies.

The fovea

The fovea is a 1,5 mm diameter depression in the inner retinal surface at the centre of the macula. Because of the increased thickness of the retina and ILM at its border (foveal rim or parafovea), it gives rise to an oval light reflex seen in ophthalmoscopy. Foveal RPE cells are taller, thinner and contain more and larger melanosomes than elsewhere in the retina.

The foveola

The foveola is a central 0,35 mm wide zone forming the central floor of the fovea. The inner layers of the retina being displaced laterally, foveola consists purely of cones.

The umbo

It is a tiny depression in the very center of the fovea corresponding to the foveal reflex.

2.3.2. Retinal periphery topography

Retinal periphery regions

Peripheral retina extends beyond macular area to the ora serrata.

The following regions are distinguished:

- Oral- situated within the vitreous base
- Post oral- located between the posterior border of the vitreous base and equator

- Equatorial- situated at and in the proximity of the equator
- Post-equatorial- located between the equator and the posterior pole.

Retinal periphery anatomic landmarks [46, 80]

Ora serrata

It is the junction between the retina and ciliary body. At this transition zone, the neurosensory retina is continuous with the non-pigmented epithelial cells of the pars plana.

At nasal, ora serrata is characterized by teeth-like extensions of the retina into pars plana (dentate processes), separated by oral bays.

Vitreous base

Formed by a strongly adherent cortical vitreous, it is a 3-4 mm wide zone straddling the ora serrata.

The long posterior ciliary arteries

They appear as yellow lines starting behind the equator and running anteriorly in the 3 and 9 o'clock meridians in the suprachoroidal space. Corresponding nerves accompany.

The short posterior ciliary arteries

Unaccompanied by nerves, they are recognized as peripheral radial yellow lines.

Vortex ampullae

Located just posterior to the equator in the 1, 5, 7, 11 o'clock meridians, they pass through the suprachoroidal space into their scleral canals.

2.4. Vitreoretinal adhesions and tractions

Two types of **vitreoretinal** adherences are distinguished: normal and abnormal.

Normal adhesions are present at the vitreous base, around the optic disc margin, around the fovea and peripheral retinal blood vessels.

Abnormal adhesions may occasionally be associated with retinal tear formation caused by dynamic vitreoretinal traction in eye with acute posterior vitreous detachment. They occur at the posterior border of lattice degeneration, retinal pigment clumps, congenital cystic retinal tufts, vitreous base anomalies and areas of white without pressure.

Vitreoretinal traction

It is a force exerted on the retina by structures originating in the vitreous and may be dynamic or static.

Dynamic vitreoretinal traction is induced by rapid eye movements and exerts a centripeted force towards the vitreous cavity. It is relevant to the pathogenesis of retinal tears and rhegmatogenous retinal detachment.

Static vitreoretinal traction is independent of ocular movements. It plays an important role in the pathogenesis of tractional retinal detachment and proliferative vitreoretinopathy.

2.5. Retinal vascularisation [42,46]

2.5.1. Arterial system

Double blood supply system of the retina include:

- choriocapillaris which are responsible for nourishment of RPE and photoreceptors
- central retinal artery and its branches and inconstant cilio-retinal arteries (from posterior ciliary arteries) which supply inner retinal layers.

Outer retina layers blood supply

Choriocapillaris provide nutritional support for the RPE and photoreceptors by intermediary of Bruch's membrane. They are supplied by long and short posterior ciliary arteries and recurrent branches from a major arterial iris circle. The bore of the capillaries and their density is greatest near the macula. Diffusion by Bruch's membrane is possible due to fenestrations on retinal aspect of choriocapillaris.

Inner retina layers blood supply

Inner layers blood supply is assured by branches of central retinal artery and inconstantly by chorio-retinal arteries.

Central retinal artery arises from the ophthalmic artery, branch of the internal carotid artery. It passes in the centre of the optic nerve and divides into superior and inferior branches at optic nerve head surface. They subdivide into nasal and temporal arteries. These arteries extend superficially in the retina, giving rise to retinal capillaries. Capillar endothelium tight junctions (zonulae occludentes) constitute the inner blood retina barrier.

Inconstant cilio-retinal arteries provide from arterial circle of Zinn and are present at 6 to 20 % of people. If present, they supply a part of macular and juxta-papillar area.

Retinal capillaries are disposed in two main levels of network:

- The inner (peripheral) is situated at nerve fibres layer
- The outer (deep) is located at the level of the inner nuclear layer.

Foveal avascular zone (FAZ)

Retinal capillaries pass only to the depth of the inner nuclear layer, the outer layers being avascular. Located within the fovea but extending beyond the foveola, foveal avascular zone consists of the retina dependent on the choriocapillaris for nutritional support.

2.5.2. Venous system

Veniules fusion centripetally to form finally four trunks: two temporal (superior and inferior) and two nasal (superior and inferior). The junction of two superior branches gives a superior branch of central retinal vein and the junction of two inferior branches give rise to inferior branch of central retinal vein. From these two branches central retinal vein provides at optic nerve surface. It gains cavernous sinus. Inconstant cilio-retinal veins gain choroid veins and vortex veins.

3.0. EYE FUNDUS EXAMINATION **AND IMAGING METHODS**

3.1. Ophthalmoscopy

History of ophthalmoscopy

The first ophthalmoscopic observation of normal eye fundus was incidental. In 1704 Méry observed retinal vessels of a cat sunken in water [113]. The fundus was easily visible due to reflex pupil dilatation and neutralization of the refractive power of the cornea by the flat surface.

The phenomenon observed by Méry was explained five years later by de la Hire (1709) [25].

In 1845 Kussmaul made his observations of eye fundus after cornea ablation or using lenses of the same curvature that the cornea [50]. First trails of human eye fundus observation were made by Purkinje in 1823. He was using his own glasses to observed illuminated pupil.

In 1838 Carron du Villars tried to lighten eye fundus with a concave mirror placed behind the patient and it was in 1847 when Cumming in London and Brücke in Vienne managed to illuminate eye fundus, standing in front of the patient [50].

Direct ophthalmoscopy (Right image ophthalmoscopy)

On 6th December 1850 Herman Helmholtz communicated to the Berlin Society of Physique an invention of a new ophthalmic instrument. The demonstration took place on 11th November 1851 and the principles of direct ophthalmoscopy were described by Helmholtz in his monograph published the same year [43].

Basis [50]

The observer regards by the central hole of a mirror which is also used to lighten the patient's eye and is associated to biconcave lens placed behind it. Light rays reflected from eye fundus are dispersed by the lens. Virtual, enlarged, right image results.

Characteristics

This type of ophthalmoscopy gives:

- high magnification (x 15)
- narrow visual range (10°)
- near distance observer – patient.

Nowadays direct ophthalmoscopy represents monocular method of examination utilized for details search and completion of the reverse image examination. Ophthalmoscopes possess corrective plate with lenses assuring compensation of refractive error and diagrams of lighting range. They are equipped by optic systems reducing corneal reflects, have ergonomic shape and additional orbital support.

Clinical application

- Biomicroscopy complement
- Details evaluation: macula, optic disc, vessels
- Detection examination
- Fundus examination by non ophthalmologists
- Lying patients
- Children.

Indirect ophthalmoscopy (reverse image ophthalmoscopy)

The first indirect ophthalmoscope was designed by Ruete in 1852 [43].

Basis [50]

Eye is illuminated a by concave mirror on which light derived from lamp placed aside is concentrated. Light arriving to eye fundus illuminate it and reflected forms the real and reversed image. Biconvex (convergent) lens placed on light way makes the image more distinct but smaller.

Characteristics

This type of ophthalmoscopy gives:

- low magnification (x 3-4)
- whole posterior pole image
- distance observer - patient of about 50-60 cm.

Indirect ophthalmoscopy was replaced by biomicroscopy which have the same optic principle.

Indirect stereo-ophthalmoscopy

In 1861 Giraud-Teulon devised the first binocular ophthalmoscope characterized by higher brightness, wider visual range and relief perception [50, 55]. Nowadays indirect ophthalmoscopy represents binocular method of fundus examination. The Giraud-Teulon idea was modified and popularized by Schepens in 1947 [132] and Fison.

Characteristics [93]

Indirect binocular ophthalmoscopes give:

- real and reversed image
- visual rang proportional to lens power
- magnification inversely proportional to lens power
- stereoscopy inversely proportional to lens power.

Clinical application

Diagnostic method:

- Peripheral eye fundus examination with indentation
- Post-traumatic eyes
- Post-surgery follow-up
- Trouble media: cornea, lens, vitreous
- Small pupils: synechiae, pseudophakic patients
- Important ametropia (myopia, astigmatism)
- Infants and pretermates
- Lying patients.

Treatment method:

- Laserotherapy due to laser fiber
- During cryoapplication
- During gas injection
- In retinal detachment surgery.

Advantages:

- Good peripheral visibility especially with indentation
- Correct visual range
- Good range deepness
- Very good relief perception (stereoscopy)
- Powerful lighten system
- Non-contact method
- Examination possible with small patient pupil.

Disadvantages:

- Small magnification
- Inverted image
- Learning curve
- Optical section non accessible.

Ophthalmoscopic examination [50]

In 1875 Gałęzowski described general rules of ophthalmoscopy procedure. He emphasized the importance of :

- choice of ophthalmoscopy type
- darkened room
- preparatory exercise on artificial eye
- patient and physician position
- pupil dilatation
- lamp position
- mirror position
- lens position
- observed eye regard direction
- examination sequence: optic disc, vessels, macula, ora serrata
- reversed image examination followed by direct image examination.

Peripheral retina examination [43]

In 1889 Magnus published first images of ora serrata and as the first described retinal periphery pathology: lattice degeneration and pavementous degeneration. Association of small power lens and powerful prism was introduced in 1892 by Gałęzowski resulting on the first publication of retinal periphery images. In 1900 Trantas introduced scleral depression method during direct ophthalmoscopy to examine retinal periphery [142]. The indentation was made by thumbnail through the superior eyelid. Unfortunately scleral depression was not extensively used until almost 50 years later when Schepens modernized and popularized the method during binocular ophthalmoscopy [132].

3.2. Biomicroscopy [9, 130]

Principle

Examination in binocular microscopy of different eye structures on which intense light is focalized in form of light beam.

Slit lamp

Slit lamp ophthalmoscopy of the fundus evolved gradually from ophthalmoscopy. Focal illumination of the retina and deep vitreous was recommended as early as in 1901 by Wolff who used this method with direct electric ophthalmoscope. In 1912 Gullstrand presented in Heidelberg slit lamp model with independent light beam source and observation system.

In 1918 Koepe adapted the Gullstrand slit lamp to fundus examination and associated it with contact lens use. His biomicroscope called Bitumi, gave inverted image and was secondary replaced by Orthobitumi where introduction of prism assured image reversion to right one.

The last important step was made by Goldmann who in 1938 developed instrument with light slit confocal to biomicroscope and common vertical axis allowing angle reduction.

Followed characteristics are present in slit lamps used nowadays:

- binocular microscopy
- light slit as a lighten system
- slit of important lightness and variable position
- whole lighten system of variable position
- vertical, horizontal and recline optic section possibility
- variable magnification of image
- possibility of image decentralization to examine in reflected light
- variability of stereoscopic angle.

Lenses [93]

Concave lenses

- Their objective is to neutralize the focalization power of the eye
- Right and virtual image results
- Image is formed at anterior vitreous level.

The idea of neutralization of the eye focalization power provided from phenomenon observed by Méry (1704) et de la Hire (1709) and was developed into an instrument called hydrophthalmoscope by Czermak (1851, 1853). A further improvement was the use of a flat contact lens by Coccius (1853) [130].

Concave contact lenses

Inspired by Coccius lens, Koeppel introduced in 1918 the first contact lens, concave at its posterior surface, - 59,5 D of power, giving virtual image of the eye fundus located 16,7 mm behind the cornea. Disadvantages of Koeppel lens were: fragility, big size, traumatic effect, only posterior pole visibility and patient horizontal position during examination [11].

The further improvement was done by Goldmann in 1938. Inspired by Koeppel lens, he developed contact, plastic lens of -64 D of power, giving a right image and appointed of three lens of horizontal inclination of 59 °, 67 °, 73°, giving inverted image. The Goldmann lens is called triple mirror. It is weightless, non-traumatic and less vulnerable [60].

Concave non contact lenses

A different approach was the use of a strongly concave lens in front of the eye. This principle, originally applied by Stilling in 1879, was developed by Lemarne and Valois in 1923 [9]. They used non contact flat-concave lens of -55 D of power which was fixed on a slit lamp and have horizontal mobility.

This method was improved and popularized by Hruby in 1950. He introduced a non contact, flat-concave lens of -58,6 D and -78 D of power, fixed to the lever associated to a head support of a slit lamp, which assured it a great mobility [72].

Convex lenses [93]

- Their objective is to enhance refractive power of the eye similarly to indirect ophthalmoscopy.
- Inverted, real, air image results.
- The image is formed in front of the eye and the lens at a distance varying due to lens power.

Characteristics:

- Visual range increases with lens power

- Image size decreases with lens power
- Good visibility at myopic patients.

Convex non contact lenses

In 1953 El Bayadi introduced flat-convex lens of + 60 D of power [39]. It was characterized by excessive spherical aberrations and difficult manipulation. Inspired by this lens Kajiura designed in 1974 a flat-convex aspheric lens of +58,6 D of power. The lens of El Bayadi-Kajiura (EBK) resulted fixated on slit lamp by lever [9].

From 1985 lots of types of double, aspheric, biconvex lens of refractive power varying from 60 to more than 100 D were developed. They are characterized by high optic quality and possibility of dynamic examination. They assure good visibility of eye fundus in case of small pupils, pseudophakia and media troubles [93].

Convex contact lenses

The first convex contact lens was developed in 1968 by Rodenstock [9]. This type of high power lens (from +100 to +150 D) assures large examination range, gives panoramic view and image stability.

3.3. Eye fundus photography

As early as in 1864 Dr A.M. Rosebrugh showed the Canadian Institute how to take photograph of the fundus by reflecting its image onto a sensitized plate. In 1925 Nordensen camera based on Gullstrand large stand-mounted, reflex-free ophthalmoscope was presented [43].

Basis

The optical design of this specialized low power microscope is based on the principle of monocular indirect ophthalmoscopy in which the observation and illumination systems follow dissimilar paths. The light reflected from the eye fundus is redirected by the observation telescope onto the capturing medium.

A typical camera provides a right image of 30 to 50 degrees of retinal area, with a magnification of 2,5x. Modifications of this relationship through zoom or auxiliary lenses are possible.

Clinical application

Fundus camera examination is used for screening, monitoring and documentation of eye fundus pathology. Different types of software are available, providing photos edition, catalogue, stock and search.

3.4. Modalities of eye fundus examination methods [5]

They are available in certain models of direct and indirect ophthalmoscopes, slit lamps and funduscameras.

Examination at green light

Advantages:

- More comfortable for patient than examination at white light
- Reveals or makes more visible vascular damage, hemorrhages, RPE atrophy
- Allows localization in deepness of pigmented changes
- Allows examination of ILM
- Facilitates anatomical landmarks recognition especially vascular.

This method is limited by cataract presence.

Examination at red light

- Masks vascular structures and reveals RPE damage, large choroidal vessels and their changes
- Allows deep lesions visibility
- Is utilized during indocyanin angiography.

Examination at blue light

- Reveals nerve fibers and epiretinal membranes
- Allows xanthophyll pigment evaluation
- Is utilized during fluorescein angiography.

3.5. Fluorescein angiography [43, 81]

Synthesized in 1871 by Bayer and introduced into ophthalmologic use in 1881 by Ehrlich, fluorescein is an orange, water-soluble dye with fluorescence properties. It emits light energy of longer wavelength (530 nm- green part of the spectrum) when stimulated by light of a shorter wavelength (490 nm- blue part of the spectrum).

Fluorescein angiography involves photographic surveillance of the fluorescein passage through the retinal and choroidal circulation. The first angiography was done in 1960 by MacLean and Maumenee in patient with diagnosis of choroidal tumor. In 1961 medical students at the Indiana University Harold R. Novotny et David L. Alvis made the first fluorescein angiography in objective to analyze retinal circulation in human.

Basis

On intravenous injection 70-85 % of fluorescein molecules bind to serum proteins (bound fluorescein). The remainder remains unbound (free fluorescein). The major choroidal vessels are impermeable to bound or free fluorescein. Choriocapillaris leaks the unbound dye freely into the extravascular space from which it passes across Bruch membrane. Outer blood retinal barrier prevents the passage of free fluorescein across the retinal pigment epithelium while the inner blood retinal barrier prevents both bound and free fluorescein passage.

The fluorescein sodium passage through the vessels of retina is photographed using fundus camera equipped with special filters allowing only blue light enter the eye and the fluorescent yellow-green light to be photographed and a fast recycling electronic flash tube that allows a capture rate of up to 1 frame per second. Software tools provide adjustments for brightness, contrast and sharpness. Digital analysis enables measurement of pathologic structures, digital overlays can be used to identify potential changes in lesion size in serial photographs, and multiple fields can be linked together to form composite wide-field images.

The normal angiogram consists of the following overlapping phases [81]:

- 1. Pre-arterial (choroidal):** Patchy filling of the choroid occurs 8-12 seconds after dye injection. Choroidal circulation is filled one second before retinal circulation.
- 2. Arterial phase:** shows retinal arterial filling and continuation of choroidal filling
- 3. Arterio-venous (capillary) phase:** shows complete filling of the arteries and capillaries and early laminar flow in veins.
- 4. Venous phase:** shows complete venous filling with maximum vessel fluorescence occurring within 30-35 seconds after injection.
- 5. Elimination phase:** the intensity of fluorescence becomes weaker and is absent after 5-10 minutes.

The abnormal angiogram [81]

Hyperfluorescence results from:

- **Transmission** (window defect)
 - RPE atrophy or absence
- **Pooling** (outer blood-retinal barrier defect)
 - in subretinal space

- in sub-RPE space
- **Leakage** (breakdown of the inner blood-retinal barrier)
 - from abnormal choroidal vasculature
 - from abnormal retinal vasculature
- **Staining** (result of prolonged retention of dye).

Hypofluorescence results from:

- **Blockage of retinal fluorescence**
 - caused by lesions anterior to the retina: vitreous opacities, pre-retinal structures
 - caused by deep retinal lesions (blockage of capillary fluorescence)
- **Blockage of background choroidal fluorescence**
 - caused by subretinal lesions
 - sub-RPE lesions
 - increased density of RPE
 - choroidal lesions
- **Filling defect**
 - vascular occlusion
 - loss of the vascular bed.

3.6. Ultrasonography [61]

First reports of diagnostic use of ultrasounds in ophthalmology was made by Mundt and Hughes in 1956 and concerned ocular tumors. In 1958 Baum and Greenwood presented first two dimensional scans (mode B) using immersion technique. The idea of standardized ultrasonography was postulated in 1964 by Ossoinig.

Basis

The transducer emits pulses of ultrasounds waves due to piezo-electric material and then receives the returning echoes. These echoes may be affected by size and shape of acoustic interfaces, the angle of sound beam incidence, absorption, scattering and refraction. Echoes are processed in the instrument by filtration and amplification and then displayed on the screen as echograms. The optimal frequency of probe is of 10-12 MHz for ocular globe and 7-10 MHz for orbital structures.

Modes

A-scan: In this one-dimensional acoustic display, detected echoes are presented as vertical spikes from a baseline. The height of spikes corresponds to the strength of the echoes and the spacing depends on the time that takes to the sound beam to reach the interface and its echo to return to the probe.

B-scan: Echo is represented as a dot, the brightness of which corresponds to the echo strength. The coalescence of multiple dots forms on the screen a two-dimensional acoustic section which allows evaluation of structure location and configuration.

3.7. Optical coherence tomography (OCT)

In 1991 first optical section images of in vitro retina and in 1995 of human in vivo retina were published [43].

Basis [52]

The principle of this non invasive and non contact method of examination is based on a low coherence light beam reflectometry and high sensibility interferometry. Infrared light beam of low power (830 nm) is directed to the retina. Delay of light reflection providing from different retinal structures is measured. Antero-posterior section of the retinal tissue results.

Image presentation [53]

Due to false colors introduction following layers are distinguished:

- hyperreflective (white and red): two principal correspond to optic nerve fibers and RPE-Bruch membrane- choriocapillaries complex. Another hyperreflective line is situated anteriorly to the last and corresponds to junction of photoreceptors outer and inner segments.
- two modern reflectivity layers (yellow and green): correspond to outer and inner plexiform layers
- two hyporefective layers (blue and black): correspond to outer nuclear layer, photoreceptors layer and choroid.

Retinal thickness measurement

It is defined according to the distance between anterior retinal profile line (first peak of reflectivity after vitreous hyporefectivity) and anterior face of RPE-choriocapillaries complex (principal posterior hyperreflective peak). Macular cartography (mapping) calculates mean value of retinal thickness at different sectors of posterior pole.

4.0. OCULAR TRAUMA

4.1. Ocular Trauma Score (OTS) [120]

Developed by the United States Eye Injury Registry (USEIR) with the support from the Centers for Disease Control and Prevention, this score estimates probability of 6 month follow-up visual acuity category after eye trauma. It is used to facilitate treatment, patient counseling, rehabilitation and research. Initial visual factors and assigned raw point values are presented at Table 4.1.

| | Initial Visual Factor | Raw points |
|----|--------------------------------|--|
| A. | Initial visual acuity category | NLP 60 LP-HM 70 1/200-19/200 80 20/200-20/50 90 ≥20/40 100 |
| B. | Globe rupture | -23 |
| C. | Endophthalmitis | -17 |
| D. | Perforating injury | -14 |
| E. | Retinal detachment | -11 |
| F. | Afferent pupillary defect | -10 |
| | Raw score sum | |

Table 4.1. OTS score: initial visual factors and assigned raw point values [120].

Table 4.2. presents the estimated probability of 6 month follow-up visual acuity category.

| Raw score sum | OTS Score | NLP | LP/HM | 1/200-19/200 | 20/200-20/50 | ≥20/40 |
|---------------|-----------|-----|-------|--------------|--------------|--------|
| 0-44 | 1 | 73% | 17% | 7% | 2% | 1% |
| 45-65 | 2 | 28% | 26% | 18% | 13% | 15% |
| 66-80 | 3 | 2% | 11% | 15% | 28% | 44% |
| 81-91 | 4 | 1% | 2% | 2% | 21% | 74% |
| 92-100 | 5 | 0% | 1% | 2% | 5% | 92% |

Table 4.2. OTS: estimated probability of 6 month follow-up visual acuity category [120].

4.2. Birmingham Eye Trauma Terminology System (BETTS) [91, 123]

Established for mechanical injuries of the globe, the classification provides clear definitions for all injury types and the framework of a comprehensive system.

Mechanical injuries are defined as resulting of sharp or blunt objects striking the eye or periocular tissues and causing open or closed-globe injuries.

Open-globe injury is defined as a full-thickness wound of the eyewall (cornea or sclera) whereas closed-globe injury include damage without full-thickness wound of the eyewall. The pathologic response and treatment strategies are different in the two categories.

The classification system was based on four characteristics, proved to be prognostic of final visual outcome. These four elements are:

1. Type of injury
2. Grade of injury
3. Relative afferent pupil defect
4. Zone of injury.

4.2.1. Type of injury

It refers to the mechanism of injury categorized as resulting from blunt or sharp force.

4.2.1.1. Open-globe injuries

They include four types:

- Globe's rupture resulting from blunt object

and three categories caused by sharp forces:

- Perforating injury (two full-thickness lacerations: entrance and exit)
- Penetrating injury (single full-thickness laceration)
- Intraocular foreign body (single entrance wound caused by the retained foreign object).

4.2.1.2. Closed-globe injuries

They include three types:

- Lamellar laceration (partial thickness wound caused by a sharp object)
- Superficial foreign body (the foreign body becomes lodged in conjunctiva or eyewall).
The force of impact may be blunt, sharp or both.
- Contusions (resulting from blunt trauma).

4.2.2. Grade

It is based on visual acuity of the injured eye at the initial examination. It has been proven in numerous retrospective studies to be the strongest predictor of visual outcome in open-globe injuries. Visual acuity is measured with correction and pinhole when appropriate.

Five grades has been distinguished:

- 1) $\geq 20/40$
- 2) 20/50-20/100
- 3) 19/100-5/200
- 4) 4/200 to light perception
- 5) No light perception.

4.2.3. Relative afferent pupil defect

The testing of afferent pupillary reaction grossly measures optic nerve and retinal function. This variable is positive when a relative afferent pupillary defect is present and negative when absent in the injured eye.

4.2.4. Zone

Open-globe injuries

It is based on the location of the globe opening as follows:

- I: isolated to the cornea
- II: from corneoscleral limbus to a point 5 mm posterior into the sclera
- III: posterior to the anterior 5 mm of sclera.

Closed-globe injuries

The location of the most posterior structure involved determines the zone as follows:

- I: external (limited to bulbar conjunctiva)
- II: anterior segment (structures internal to the cornea and anterior to the posterior lens capsule)
- III: posterior segment: (include all structures posterior to the posterior lens capsule).

4.3. Ocular contusions

They are defined as damage caused by shock, compression or blunt object, without penetration into ocular globe [5]. Direct and indirect ocular contusions are distinguished.

Direct contusions result from object acting on the eye globe with or without interposition of periocular tissues. Indirect contusions are due to object acting on other structures than eye but resulting in ocular damage secondary to changes in globe configuration or brutal intraocular pressure elevation.

Anterior segment damage due to ocular contusion

They include:

- corneal abrasion
- conjunctival hemorrhage
- hyphema
- iridodialysis
- sphincterotomy
- cyclodialysis
- angle recession
- lens anterior or posterior subluxation or luxation
- contusive cataract.

Posterior segment lesions

Damage resulting from contusion may be divided into [34, 84, 146]:

- direct trauma damage (coup and contre-coup mechanism)
- indirect trauma lesions which may follow orbital, cranial or remote trauma.

5.0. RETINAL CONTUSIONS

5.1. Pathophysiology

5.1.1. Cup-contrecoup theory

The cup-contrecoup mechanism of ocular injuries, analogical to posttraumatic brain damage, was postulated in 1963 by Wolter [147]. Cup was assigned to product damage directly in regard of the contusion area (anterior segment or peripheral retina), while contrecoup damage were situated at the opposite to impact site (posterior pole included).

5.1.2. Pathogenesis of peripheral damage

In 1966 Weidenthal and Schepens [144] showed that high velocity impact to the central cornea of enucleated pig eyes resulted into:

- lens capsule rupture near the equator
- tenting of the retina and nonpigmented pars plana epithelium at the nasal ora serrata
- frequent retinal dialysis near the crest of tented ora serrata
- temporal tears in the nonpigmented ciliary epithelium of pars plana along the anterior border of vitreous base.

The protective effect of the orbit was postulated after experimentations in which the eye was mounted in stone mold with posterior aperture. The study explained also that the frequency of posttraumatic clinical retinal dialysis in the lower temporal quadrant, is due to the configuration of human orbit which renders this area most vulnerable.

In 1969 Delori, Pomerantzeff and Cox investigated the mechanism of contusion damage to the region of vitreous base in the study of the deformation by high –speed impact [26]. The sequence of resulting events was recorded photographically and four stages were distinguished:

1. compression (0-0,25 ms)
2. decompression (0,25-1,00 ms)
3. overshooting (1,00-2,50 ms)
4. oscillations (2,50-100 ms).

Ad. 1. After impact the cornea is indented and after about 0,25 ms 59 % reduction of globe's original antero-posterior diameter is noted.

Ad. 2. During decompression phase the equatorial diameter continues its expansion until 0,4 ms when it reaches 111 % of its original value. Vitreous starts to move posteriorly until 1,00 ms after impact when eye assumes a pear shape.

Ad. 3. The bullet leaves the eye at a speed 5,4 times less than the impact one and deformation wave originated from limbus is traveling posteriorly in the sclera. The anteroposterior diameter overshoots up to 112 % of its original length while equatorial diameter decreases. Globe reaches an ellipsoide shape.

Ad. 4. Finally oscillations of the whole globe and intraocular fluid with frequency of 85 cycles per second appear.

This study proved that both tangential and normal acceleration of the sclera were greatest in the vitreous base area and the strongest shearing forces in the retina were located along the posterior border of the vitreous base.

5.1.3. Pathogenesis of posterior pole damage

Posterior pole damage were not studied by Delori, Pomerantzeff and Cox but explained as a result of rapid deformation of the posterior pole during the overshooting period 1,00-2,50 ms after the impact [26]. They postulated that viscoelastic vitreous gel resisting to deformation may stretch vitreomacular attachment, causing Berlin's edema and macular tears. The similar mechanism may be responsible for retinal tears at sites of vitreo-retinal adhesion. Choroidal tears may occur near points of attachment of the choroid to the sclera (optic nerve, entry points of ciliary vessels, exit channels of the vortex veins). Shearing effect on vortex veins may result into subretinal bleeding, causing overlaying retina necrosis and breaks.

In 1987 Pruett, Weiter and Goldstein revised Delori, Pomerantzeff et Cox experimental films [124]. Exact posterior pole measures were impossible but images of acute conoidal posterior pole deformation were noted, explaining that Bruch membrane ruptures appear concentric to the optic nerve. Oblique insertion of optic nerve may result in preferential temporal location of choroidal ruptures.

5.2. Diagnosis of retinal contusions

5.2.1. Symptoms

5.2.1.1. Immediate

Retinal contusions are frequently asymptomatic (especially if peripheral retina involved). Visual acuity may be decreased if optic nerve, foveal photoreceptors or retinal pigment epithelium cells are damaged, in case of retinal, sub- or preretinal hemorrhage involving macula or vitreous hemorrhage masking this area.

Hemorrhagic vitreous opacities result in the sensation of floaters, due to perception of movement when they cast a shadow upon the retina. They may be solitary or multiple, perceived as a sudden shower of red-colored or dark spots, depending on vitreous hemorrhage intensity [80].

5.2.1.2. Retarded

Decrease of visual acuity may result of posttraumatic maculopathy (atrophy, epimacular membrane, macular hole) or posttraumatic optic neuropathy.

Disturbance in foveal photoreceptors arrangement due to posttraumatic maculopathy or choroidal neovascularization may result in metamorphopsia.

Acute posterior vitreous detachment following trauma and traction on the retina at sites of vitreoretinal adherences may cause perception of light flashes (photopsia) [80].

A dark curtain is perceived if a visual field defect secondary to retinal detachment appears. Loss of central vision in this case may be due either to involvement of the fovea or by obstruction of visual axis.

5.2.2. Classification

5.2.2.1. Depending on contusion mechanism [34, 84, 146]

a) From direct eye injury (cup and contrecoup damage)

1. Commotio retinae
2. Choroidal rupture
3. Retinal breaks
4. Optic nerve avulsion
5. Chorioretinal rupture (sclopetaria)
6. Vitreous base avulsion

b) from remote injuries of orbit and head

1. Whiplash retinopathy
2. Chorioretinal rupture (sclopetaria)
3. Terson's syndrome

c) from other remote injuries

1. Purtscher's retinopathy
2. Valsalva retinopathy (Venous retinopathy)
3. Fat embolism syndrome
4. Shaken baby syndrome.

5.2.2.2. Depending of contusion damage location [34, 84]

a) Central

1. Commotio retinae
2. Choroidal rupture
3. Macular hole
4. Optic nerve avulsion
5. Whiplash retinopathy
6. Terson's syndrome
7. Purtscher's retinopathy
8. Valsalva retinopathy (Venous retinopathy)
9. Fat embolism syndrome
10. Shaken baby syndrome

b) Peripheral

1. Commotio retinae
2. Choroidal rupture
3. Retinal breaks
4. Vitreous base avulsion
5. Chorioretinal rupture (sclopetaria).

5.2.3. Mechanism and clinical appearance of well-defined entities of traumatic posterior segment abnormalities

5.2.3.1. from direct eye injury

5.2.3.1.1. Commotio retinae (Retinal concussion / Retinal contusion)

- **Mechanism:**

Disruption of photoreceptors outer segments, followed by phagocytosis by migrating retinal pigment epithelium was shown at experimental and post-mortem reports [7, 102, 135]. The anatomical explication was postulated: vitreous deformation tends the retina at external segments level, the rest being stabilized by Muller cells [102]. The absence of extra- or intracellular edema was emphasized [102,135]. Functional study, using non invasive fundus refraction densitometry to measure photopigment level and its regeneration time showed that the essential lesion is situated at the photoreceptor- RPE complex. The regression of lesions in three months was observed and functional character of commotio retinae was proved [96].

- **Fundus of the eye:**

Commotio retinae is characterized by transient grey-white coloration of the deep layers of involved retina, located at coup area (peripherally) or at contrecoup site (peripherally or centrally) [34, 84, 146]. Lateral limits of the area are blurred and retinal vessels are well visible. If posterior pole is involved cherry red spot of the fovea is observed and the condition is called Berlin's edema.

- **Imaging**

FA

Early hypofluorescence due to masking effect, without leakage and followed by complete capillary filling was observed. In more serious cases associated to RPE edema, progressive patchy staining [146] accompanied or not by hyperfluorescence involving fovea and resulting from serous retinal detachment was described.

Fluorescein angiography is useful especially in atypical commotio retinae associated with RPE changes, retinal hemorrhages and choroidal ruptures.

OCT

Only few studies presenting OCT images of commotio retinae associated with posttraumatic macular hole have been published.

- **Classification and prognosis**

Depending on associated retinal pigment epithelium contusion, the division into retinal concussion (without RPE contusion) and contusion (with RPE contusion) is traditional and clinically useful with differentiating characteristics (Table 5.1.) [34].

| CONCUSSION | CONTUSION |
|---|--|
| ■VA > 1/10 | ■VA < 1/10 |
| <ul style="list-style-type: none"> ■Grey-white coloration of the retina ■Hemorrhages less frequent ■Reversible with no late pigment scarring ■Disruption of photoreceptors outer segments | <ul style="list-style-type: none"> ■Whitening more intense ■Frequent hemorrhages ■Persistent pigmented or mottled scar ■Disruption of photoreceptors outer segments + RPE damage (apical processes loss, membrane damage and edema of cells) |
| AF: Early hypofluorescence (masking effect) No leakage Complete capillary filling | AF: Progressive patchy staining +/- Hyperfluorescence involving fovea (serous retinal detachment) |
| Resolves in few days with good final visual acuity. | Reduction of visual function is permanent. |

Table 5.1. Differential diagnosis of two types of commotio retinae: retinal concussion and contusion [34].

- **Evolution:**

The retinal opacity clears spontaneously in few days or weeks.

Retinal atrophy, pigmentary changes due to RPE hyperplasia and migration or macular hole may occur [35].

5.2.3.1.2. Choroidal rupture

- **Mechanism and classification:**

Direct choroidal ruptures result from choroidal necrosis [35].

Indirect choroidal ruptures result from break of relatively inelastic Bruch's membrane with closely opposed RPE and chorio-capillaries due to mechanical deformation and pressure

wave within the eye. The sclera is strong enough to resist rupturing, while the retina is elastic and resists tearing. Tethering or stabilizing role of the optic nerve is postulated as an explanation of frequent localization concentric to optic nerve [149].

- **Fundus of the eye and classification [34,146]**

Direct choroidal rupture

Uncommon, direct choroidal rupture is situated at the site of impact, anteriorly to the equator and parallel to the ora serrata.

Indirect choroidal rupture

More common (5-10 % ocular trauma), indirect choroidal rupture occurs posteriorly at contrecoup site, is crescent-shaped and concentric to the optic disc or macula. Initially, it may be obscured by subretinal hemorrhage [56].

- **Imaging**

FA

It may reveal choroidal ruptures not visible in ophthalmoscopy and localize them in rapport to the fovea [35]. Large vessels of the choroid in pre-arterial phase, early hyperfluorescence due to window defect and late tissue coloration are observed.

OCT

Choroidal rupture allows deeper penetration and increased reflectivity of the signal and results in a thick, intense outer band in OCT.

- **Prognostic factors**

Prognosis factors of indirect choroidal ruptures were studied by Wood [148]. Diffuse impact due to punch trauma resulted more frequently into peripapillary ruptures while macular lesions were less frequent. There were minimal damages of the anterior part of the uvea. The visual prognosis was better. Focal high energy impact due to projectile trauma resulted into multiple, extensive, irregular ruptures with more frequent macular and optic nerve lesions. Damage of the anterior uvea, iridodialysis, direct choroidal ruptures were more frequent. Visual prognosis was worse.

Temporal lesions were also associated with poorer visual prognosis because of higher risk of macular lesions: macular choroidal rupture, inner retinal lesions, pigmented maculopathy and subretinal neovascularization.

- **Evolution:**

RPE hyperplasia, fibrovascular tissue proliferation and scar formation three to four weeks after trauma are the rule. Choroidal neovascularization is a consistent feature during healing process and regress spontaneously in majority of cases [2].

The decrease of visual acuity may result from extension of the rupture into the fovea or late development of subretinal neovascularization. Neovascular membranes may occur months to years after the initial trauma and are usually associated with serous or hemorrhagic retinal detachment [2, 35, 49, 136].

Follow up with repeated fluorescein angiography during minimally 2 years after trauma is recommended [150]. Other findings possible to occur after choroidal rupture is chorioretinal anastomosis [59].

5.2.3.1.3. Retinal breaks and posttraumatic retinal detachment

Definitions [80]

Retinal breaks are full-thickness defects of the sensory retina.

Retinal detachment is a separation of the sensory retina from the retinal pigment epithelium by subretinal fluid. A combination of two pathologic changes must be present to produce a posttraumatic retinal detachment. First, retinal breaks resulting from tissue necrosis or vitreoretinal traction following lateral equatorial expansion of the globe must occur. Second, traumatic syneresis of the vitreous gel overlaying the break must appear.

Classification of retinal breaks:

They can be classified according to:

a) pathogenesis

- **tears**-caused by dynamic vitreoretinal traction
- **holes**-caused by atrophy of sensory retina

b) morphology

- **dialysis**- are circumferential tears along the ora serrata with vitreous attachment to their posterior margins
- **U-tears** (arrowhead tears), consist of a flap, the apex of which is pulled anteriorly by the vitreous, the base remaining attached to the retina.
- **operculated tears**- the flap is completely avulsed to the detached vitreous gel
- **giant tears**- involve 90° or more of the circumference of the globe. They are a variant of U-tears with the vitreous gel attached to the anterior margin of the break.

c) location

- **oral-** breaks are located within the vitreous base
- **post-oral-** located between the posterior border of the vitreous base and equator
- **equatorial-** are at or near the equator
- **post-equatorial-** are located behind the equator
- **macular-**located within macular area.

Retinal dialysis

Resulting from severe vitreoretinal traction at the zone of vitreous base, it is the most common type of posttraumatic retinal tear and traumatic retinal detachment. (24, 36, 139).

- **Mechanism:**

Forceful anteroposterior compression of the globe results in lateral expansion of the equator and tractional forces on the vitreous base. Experimental studies showed that retinal dialysis form at the time of ocular impact [26, 144].

- **Fundus of the eye:**

The most common localizations are: superonasal (resulting from contrecoup mechanism) [23, 24] or inferotemporal quadrant (coup mechanism) [36, 58, 127]. Traumatic dialysis is frequently accompanied by:

- chorioretinal atrophy at ora serrata zone
- vitreous base avulsion
- small vitreous hemorrhage [24]
- irido-corneal angle recession [70].

Because of formed vitreous at young patients, retinal detachment caused by traumatic dialysis progresses slowly, especially at inferior quadrants and signs of chronicity (demarcation lines, intraretinal cysts, microcystic degeneration similar to retinoschisis) are frequent [24, 58]. It was suggested that more frequent inferotemporal localization found at majority of studies, results from the fact that this quadrant is the most exposed to trauma whereas most of minimal contusions passes without signs [127].

Breaks due to vitreoretinal traction (Tears)

- **Mechanism:**

Retinal tears formation results from vitreous traction at zones of pathological adherence in consequence of sudden vitreous mobilization due to contrecoup mechanism.

- **Fundus of the eye:**

Located preferentially nasaly U-tears and operculated tears are included. The rapid evolution into retinal detachment is the rule [23, 24]. **Giant tears** involve more than 90° of the retina. They are located typically at inferotemporal or superonasal quadrant, along the posterior border of the vitreous base. The vitreous traction affects the anterior lamb while the posterior border floats freely in the vitreous. This mobility allows retinal inversion which complicate treatment and increase the risk of vitreoretinal proliferation.

Characteristics essential to differential diagnosis of giant tears and oral dialysis are presented at Table 5.2. [34, 84].

| ORAL DIALYSIS | GIANT TEAR |
|--|--|
| <ul style="list-style-type: none"> ▪ Vitreous little modified ▪ Flap not present (posterior border equal to anterior border in length) ▪ Regular posterior border ▪ PVR not present ▪ Signs of chronicity frequent ▪ Treatment: external surgery | <ul style="list-style-type: none"> ▪ Pigmented vitreous sign ▪ Anterior lamb present ▪ Rolled or everted posterior border ▪ PVR of variable severity ▪ Often symptomatic ▪ Treatment: internal surgery |

Table 5.2. Differential diagnosis of giant tears and oral dialysis [34, 84].

Retinal breaks without vitreoretinal traction (Retinal holes)

- **Mechanism:**

Resulting from retinal necrosis due to coup mechanism, retinal holes are located preferentially at inferotemporal quadrant which is the most exposed. Retinal fragmentation was noted within 24 hours after injury but subsequent liquefaction of the overlying vitreous may be necessary for retinal detachment to occur [8, 23, 24].

- **Fundus of the eye:**

This type of retinal breaks include: small, round multiple holes and large, irregular holes with ragged and rolled edges, both in the equatorial zone. Pieces of the necrotic retina may be visible in the overlying vitreous. Initially these breaks may be masked by vitreous or pre-retinal hemorrhage. If surrounded by chorioretinal scar, the evolution into retinal detachment is less possible. If no, the prevention by photocoagulation should be considered.

Imaging in retinal breaks and retinal detachment

- **Ultrasonography [40, 61]**

At B mode retinal tears appear as bright linear structures, projecting into vitreous cavity with an abrupt termination. Vitreous strand or posterior vitreous detachment is often seen adhering to the retinal flap and only slight aftermovement is observed. Focal, shallow retinal detachment may surround the tear. At mode A the tear produce very high reflectivity.

Retinal detachment appears at mode B as a bright, linear, continuous membrane attached usually obliquely to eye coats and separated from them by a clear zone (subretinal space). The difference between the gain of disappearance of the membrane and eye coats is of 10 to 15 dB. When sound beam directed perpendicular to the detachment, a 100 % spike of height on A-scan is produced (except of atrophy, several folds or retinal disruption).

The configuration of the detachment may vary from shallow, flat and smooth membrane to a bullous, folded and funnel-shaped one.

Recent detachments have an undulating type of mobility on dynamic examination. Longstanding detachments shows flapping type of motion in early stages of proliferative vitreo-retinopathy and the rigid membrane is stated at late stages. The presence of intraretinal cystes is possible. Associated signs may include retinal tears, vitreous tractions or posterior vitreous detachment, subretinal or vitreous hemorrhage.

- **OCT**

In retinal detachments OCT may confirm the presence of an optically clear space beneath the neurosensory retina and evaluate foveal involvement. In longstanding retinal detachments cystic intraretinal spaces of reduced reflectivity are observed especially in external retinal layers due to fluid accumulation.

Macular hole

- **Mechanism theories include [51, 77]:**

1. post-contusional necrosis with cystic formation

2. subfoveal hemorrhage in conjunction with a choroidal rupture
3. acute antero-posterior vitreous traction resulting from a contrecoup injury
4. a sudden tangential traction to the fovea following postcontusive posterior displacement of posterior pole.

- **Fundus of the eye:**

Macular hole occur at up to 9% of patients after ocular trauma [44]. It may complicate commotio retinae, subfoveal hemorrhage or choroidal rupture.

Full-thickness, round, oval or irregular, sharply defined hole in the center of the macula is present.

- **Imaging**

- **FA [146]**

Focal, slight, early fluorescence due to window effect is stated.

- **OCT**

This exam is the reference for diagnosis of traumatic macular hole.

It shows full-thickness foveal defect with thickened and elevated borders. Not detached, vitreous is not visible. Spontaneous closures documented by OCT were reported [125,137].

- **Evolution**

Macular hole rarely leads to retinal detachment [103]. Spontaneous closure of macular hole is possible within few months following contusion. The predisposing factors are: young age, small hole diameter (0,1-0,2 DD), absence of associated PVD or epiretinal membrane [92, 119]. The implicated mechanism is glial cells proliferation [30].

5.2.3.1.4. Optic nerve avulsion (Anterior indirect traumatic optic neuropathy)

- **Mechanism [21, 145]:**

1. extreme rotation and anterior displacement of the globe
2. brutally increased intraocular pressure pushing the nerve out of the scleral canal
3. abrupt increase of the intraorbital pressure displacing the globe anteriorly and stretching the optic nerve.

First clinical descriptions of complete optic nerve avulsion were due to severe concussive or penetrating orbital injuries during wartime. Actually optic nerve avulsion has been reported after road traffic accidents [69], sports injuries [18, 68, 73] falls and door-handles injuries [15].

- **Eye fundus:**

Optic nerve is disinserted from the retina, choroid and vitreous. The lamina cribrosa is retracted from the scleral rim. The absence of the optic nerve head is associated with variable degree of vitreous hemorrhage. Associated retinal vessels damage is not constant due to higher elasticity of vessels comparing to nerve fibers. The associated avulsion of the peripapillary retina with concomitant interruption of retinal vasculature was reported [4, 145].

- **Classification:**

Partial or complete avulsion are distinguished [68].

- **Imaging**

Fluorescein angiography may demonstrate partial or absent filling of the retinal vessels.

- **Evolution:**

Fibroglial proliferation obliterates the cavity caused by nerve avulsion [4, 28]. A case of total retinal detachment due to associated retinal avulsion was reported [4]. Neovascular glaucoma may complicate CRAO concomitant to optic nerve avulsion [4]. Visual loss is irreversible.

5.2.3.1.5. Traumatic chorioretinal rupture (sclopetaria)

- **Mechanism:**

High velocity missile striking or passing adjacent to but not penetrating the globe produces chock wave. Globe deformation, direct mechanical disruption of the choroid and retina, their simultaneous displacement and retraction due to lack of scleral attachments to the choroid between the ora serrata and equator result [104, 117].

- **Fundus of the eye :**

Full-thickness break of the choroid and retina with adjacent retinal edema and associated retinal and vitreous hemorrhages are observed. Tissue at the posterior margin of the rupture has usually an accordion-like appearance. The posterior hyaloid and sclera are intact.

- **Imaging**

- OCT**

The thinning of the neurosensory retina and loss of its normal architecture associated to the irregular thickening of the RPE/choriocapillaries were observed in cases of retinal atrophy. Regions of high backscattering consistent with fibrous fusion of the neurosensory retina and RPE/choriocapillaris layer were also depicted. Increased reflectivity of internal layers associated to highly reflective and thickened RPE/choriocapillaries corresponded to preretinal fibrosis.

- **Evolution**

The development of PVD and traction at the margin of the chorioretinal rupture may result into late vitreous hemorrhage. The white proliferative scar tissue may be seen in the late stage of chorioretinal rupture [126]. Associated pigment disturbance is observed. Careful and long-term follow-up is needed [104].

5.2.3.1.6. Vitreous base avulsion

- **Mechanism:**

Secondary to sudden modifications of globe after shock, vitreous base avulsion is pathognomonic of ocular contusion [24].

- **Fundus of the eye:**

Pigmented band in the area of the retinal insertion corresponding to pars plana epithelium disinserted with vitreous base is noted [82].

- **Evolution:**

Evolution into vitreous hemorrhage due to retinal peripheral vessel damage is possible. Careful examination of retinal periphery is important due to the risk of associated retinal dialysis.

5.2.3.2. retinal contusions from remote injuries (orbit and head)

5.2.3.2.1. Whiplash retinopathy

Whiplash retinopathy is associated with extreme flexion-extension of the head and neck without direct eye injury [85].

- **Mechanism theories include [64, 85]:**

1. central vitreoretinal traction (appearance of the micro-eperculum in reported cases)
2. selective central photoreceptors destruction
3. foveal susceptibility due to marked thinning of the ILM and strong vitreous attachment at the crest of foveal clivus.

- **Eye fundus examination shows:**

gray swelling of the foveal zone and a foveal pit 50 to 100 µm in diameter
slight RPE disturbance

occasionally a wisp of vitreoretinal tissue may extend anteriorly from the pit-like depression in the fovea [64].

- **Imaging**

FA is normal or thin focal area of early hyperfluorescence is noted [85].

5.2.3.2.2. Terson's syndrome

Terson's syndrome was originally described in 1900 as a vitreous hemorrhage occurring in association with subarachnoid hemorrhage. Today the syndrome is ascribed to patients with vitreous hemorrhage associated with any form of intracranial hemorrhage, also post-traumatic [142].

- **Following mechanism sequence is postulated:**

1. acute rise in intracranial pressure is transmitted down the sheaths of the optic nerve compressing and stretching intraorbital veins and resulting in venous stasis
2. sudden increase in intraocular venous pressure results in rapid distension and rupture of the fine papillary and retinal capillaries and subsequent vitreous hemorrhage.

- **Fundus of the eye:**

Bilateral involvement is common. Multiple preretinal, intraretinal and subretinal hemorrhages associated with vitreous hemorrhage may be observed [146]. Papillar edema may also be present.

- **Imaging:**

FA

Hypofluorescence due to mask effect on retinal and choroidal circulation in areas of hemorrhages is present. Hyperfluorescence of the optic nerve head in early phases followed by dye diffusion is related to optic nerve edema.

Ultrasonography

In fresh vitreous hemorrhage B scan shows dots and short lines. A chain of low-amplitude reflections is seen on mode A. Reflectivity increases markedly over the next few days. Mobile linear opacities and fibrinous membranes within the gel have been observed. They are located especially inferiorly because of blood gravity, are usually finer than a detached retina and move with the vitreous gel on dynamic examination. Subhyaloid hemorrhage may be visible as dots behind detached posterior hyaloid membrane. It typically does not clot and remains low-reflective and mobile. While patient in supine position or head tilted blood shifts inferiorly.

It is counseled to follow up uncomplicated vitreous hemorrhages in 4 weeks intervals to check for clearing, membrane formation or the development of retinal detachment [40].

- **Evolution**

Spontaneous resolution is common, although the course may be protracted.

Complications include:

- macular abnormalities: macular pucker [133]
- retinal detachment
- cataract
- amblyopia and myopia in infants [116].

5.2.3.3. from remote injuries

5.2.3.3.1. Purtscher's retinopathy

In 1912 Purtscher described a retinopathy occurring after severe head trauma. The condition may also be seen following compressive trunk injuries [34, 146].

- **Mechanism theories include [10, 75, 97] :**

1. fat embolism (long bone fractures, acute pancreatitis)

2. air embolism (chest injuries) venous reflux with endothelial cells swelling and capillary engorgement of the upper body severe arteriolar spasm from sudden increase of venous pressure following thoracic compression
3. complement induced granulocyte aggregation (leucoembolisation).

- **Fundus of the eye :**

Unilateral or bilateral superficial retinal whitening located primary in the posterior pole is associated with cotton-wool spots, preretinal and intraretinal hemorrhages, hyperhemic optic nerve and a cherry red spot of the macula. Pathognomonic sign, Purthers fleckens, described as whitening of the internal retina between arterioles and veniules with the respect of the 50 µm around arterioles, are present only at 50 % [34].

- **Imaging**

FA

The following abnormalities may be observed [10]:

1. capillary bed dilatation and leakage
2. non-perfusion areas
3. staining of vessels walls
4. venous dilatation
5. venous leakage.

- **Evolution include:**

- nerve fiber layer atrophy
- optic disc atrophy
- gliosis.

5.2.3.3.2. Valsalva retinopathy (Venous retinopathy)

- **Mechanism [33, 34, 86, 146]**

The sequence of events is postulated:

- forceful exhalation against a closed glottis (Valsalva's maneuver)

- direct transmission of intrathoracic or intra-abdominal pressure into the head and neck allowed by incompetent or absent valves.
- sudden pressure increase in intraocular veins results in rupture of superficial retinal capillaries.

Predilection to the macular area is explained by the absence of firm attachments of the ILM to the retina at this region.

- **Fundus:**

Typically a circumscribed, round or dumbbell-shaped hemorrhage, located beneath the inner limiting membrane or subhyaloid membrane in or near the central macular area, is found [115]. The development of fluid level is possible [146]. Retinal hemorrhages were also described.

- **Imaging**

FA

Masking effect of the hemorrhage on retinal and /or choroidal vessels is stated.

OCT [114, 115]

In cases of sub-ILM hemorrhages OCT performed just above the level of sedimented blood demonstrated two distinct membranes: a highly reflective band immediately above the premacular hemorrhage, corresponding to the ILM and an overlying patchy membrane with low reflectivity consistent with the posterior hyaloid.

In subhyaloid hemorrhage dome-shaped reflective area consistent with blood beneath a reflective band corresponding to posterior hyaloid were described. The neurosensory retina was visualized under-neath the hemorrhage. The diminution of the retinal reflectivity due to the blood masking was observed.

- **Evolution:**

Return of normal vision in case of intraretinal hemorrhages is the rule. Epiretinal membrane may complicate subhyaloid hemorrhage.

5.2.3.3.3. Fat embolism syndrome (FES)

- **Mechanism**

Clinically recognized in 5 % of patients with long medullated bones fractures [31], the syndrome appears 48 hours after fracture reduction or patient's mobilization. Fat embolism of retinal arteries is postulated as mechanism.

- **Fundus :**

Retinal lesions are seen in 50 to 60 % of patients with FES [1] and consist of cotton-wool spots and blot retinal hemorrhages that may appear and resolve in successive crops [6, 19].

- **Evolution**

Systemic involvements include:

- neurological syndrome
- respiratory syndrome
- skin and mucous membranes syndrome.

While visual prognosis is good, general prognosis depends on systemic involvement [19].

5.2.3.3.4. Shaken baby syndrome

- **Mechanism [34,84]:**

Head consists 10 % of total weight of an infant.

The observed damage result from violent shaking, direct ocular or head trauma, chest injuries or shocking [31] and are due to:

- poor neural control of the muscles of the neck
- severe head accelerations and decelerations
- sudden oscillating vitreous traction associated to formed vitreous gel and firm attachments to the perimacular retina in children.

- **Fundus of the eye**

Following abnormalities may be observed [47, 66, 76, 146]:

1. diffuse retinal hemorrhages
2. cotton-wool spots

3. traumatic retinoschisis [62]
4. retinal folds [105]
5. papilledema
6. vitreous hemorrhage.

Retinal hemorrhage may be more sensitive indication of intracranial hemorrhage than computer tomography [54].

Cardinal triad of skeletal injury due to shaking includes:

- metaphysis avulsion
- rib fractures
- stripping of periosteum [84].

5.3. Retinal contusions treatment

5.3.1. Medical treatment

There is no treatment of proved efficiency in commotio retinae. However glucocorticosteroids and vasodilators, like trimetazidine and pentoxifylline, are used in objective to combat edema and arteriolar constriction and reduce risk of potential evolution to macular hole [45].

The observation must be proposed to patients with RPE ruptures, choroidal ruptures, optic nerve avulsion, chorioretinal rupture and Purtscher's retinopathy. Resorption of the subretinal, retinal, subhyaloidal and vitreous hemorrhages may occur spontaneously but takes from few days to few months. Toxic effects of longstanding hemorrhages are the most pronounced in photoreceptors layer [57]. Reduction of physical activity and observation for up to 3 months for spontaneous clearing is a clinically accepted practice in these cases. Spontaneous closure of post traumatic macular hole has been reported [30, 92, 119].

5.3.2. Prophylaxis of retinal detachment

In case of post-traumatic retinal break, prophylactic treatment must be considered.

The purpose is to induce chorioretinal scar which must seal off the retinal break in such a fashion that vitreous fluid cannot seep under the retina and the scar is able to resist vitreoretinal traction.

5.3.2.1. Laser photocoagulation [80]

Laser photocoagulation is a form of therapy dependent on the absorption of light energy by ocular pigments (melanin, hemoglobin and xanthophyll) and its conversion into heat.

The purpose is to produce a therapeutic burn to a pre-selected retinal area while causing minimal damage to surrounding tissue. Currently used argon laser emits coherent blue-green light of 488-515 nm, well absorbed by all tree pigments.

Laser therapy modalities include:

- slit lamp photocoagulation: the most common method requiring contact lens use
- binocular indirect ophthalmoscopy photocoagulation
- endolaser: intraocular photocoagulation via optic fiber probe during pars plana vitrectomy.

Traumatic indications for laser prophylaxis are high-risk retinal breaks likely to lead to the retinal detachment. The following characteristics are at high risk [80]:

- tears
- large size
- symptomatic
- superior
- equatorial
- non-pigmented
- with associated sub-clinical retinal detachment
- associated to aphakia, myopia, family history of retinal detachment, systemic diseases associated with high risk of retinal detachment (Marfan syndrome, Stickler syndrome, Ehlers-Danlos syndrome, Pierre-Robin syndrome)
- in one-eyed patients.

Serious complications following peripheral laser photocoagulation are uncommon and usually associated with excessively heavy treatment to large retinal periphery areas.

5.3.2.2. Cryotherapy [80]

The chorioretinal scar is obtained due to freezing. Nowadays this method is used especially in association to surgical treatment. The sclera is indented with the tip of cryoprobe in objective to surround the break with a single row of cryoapplications. Freezing is terminated as soon as retina whitens. After about 5 days pigmentation begins to appear followed by chorio-retinal atrophy formation. Side effects include chemosis and lid edema which are innocuous, transient diplopia, vitritis and rarely maculopathy.

5.3.2.3. Causes of prophylaxis failure

They include:

- an inadequate treatment due to the failure to surround the lesion and to apply contiguous treatment when treating large break or dialysis
- new break formation.

5.3.3. Other laser treatment

In case of extrafoveal neovascular membrane resulting from choroidal rupture, laser photocoagulation may be considered [136]. The PDT may be an alternative method [110]. Laser drainage of subhyaloidal and sub-ILM hemorrhages (membranotomy, laser puncturing) was proposed in aim to give the entrapped blood a focal opening into the vitreous cavity and accelerate clearing and visual improvement [112]. The most common complication is the formation of epiretinal membranes, mainly in cases of sub-ILM hemorrhages, in which laser drainage requires disruption of ILM with a consequent gliotic wound-healing response [112, 114].

5.3.4. Surgical treatment

5.3.4.1. External surgery (Scleral buckling) [80]

Scleral buckling is a surgical technique in which the wall of the eye is indented toward the vitreous by using explants sutured directly onto the sclera. The purposes are:

- to close retinal break by apposing RPE to the retina
- to reduce dynamic vitreoretinal traction at sites of local vitreoretinal adhesion.

Indications to the external surgery include retinal detachments by:

- oral dialysis
- pre-equatorial U-tears involving less than 90°
- peripheral holes
- solitary breaks or multiples breaks involving less than 3 quadrants
- retinal detachment of phaque patient

5.3.4.1.1. Local explants

Two types of explants configuration are possible:

- radial explants- placed at right angles to the corneal limbus, indicated at case of large U-tears and relatively posterior tears

- circumferential explants- placed parallel to the corneal limbus, indicated at multiple breaks located in one or two quadrants, anterior breaks and dialysis.

5.3.4.1.2. Encirclement

Explants are placed around entire circumference of the globe in objective to create 360° buckle.

Mean traumatic indications to the encirclement are:

- multiple breaks located in more than two quadrants
- extensive retinal detachment without detectable break
- failed local procedures.

5.3.4.1.3. Subretinal fluid drainage (SFD) [80]

Drainage of subretinal fluid affords immediate apposition between RPE and the sensory retina. The following are indications to the SFD:

- difficulty to localization of breaks in bullous detachment
- immobile retina
- long-standing retinal detachment because of subretinal fluid viscosity
- inferior retinal detachment.

5.3.4.1.4. Causes of external surgery failure

The most common cause of early failure is the presence of persistent open break as a result of:

- break non identified at preoperative time
- buckle failure (inadequate size, height or positioning)
- fishmouthing of the retinal tear
- missed iatrogenic break.

Late failure may be due to the following :

- proliferative vitreoretinopathy (the most common cause)
- reopening of a retinal break
- new break formation.

5.3.4.2. Vitrectomy [80, 106]

This microsurgical procedure is designed to remove vitreous gel. Three separate incisions through pars plana serve as ports for instrumentation introduction.

The objectives of vitrectomy in posterior segment trauma are as following:

- optical

- relief of vitreoretinal traction
 - excision of the posterior hyaloid face
 - retinal manipulation and reattachment
- creation of a space for internal tamponade.

Traumatic indications include:

- posterior or large tears difficult to close by scleral buckling
- multiple tears at 4 quadrants
- giant tears
- vitreous hemorrhage in children, bilateral involvement in adults
- dense, non-clearing vitreous hemorrhage lasting more than 3 months after trauma (shaken baby and Terson’s syndrome),
- traumatic macular hole if spontaneous closure is not observed [17, 48, 77]
- severe ocular contusion
- vision impairing posttraumatic epiretinal membranes
- retinal breaks in pseudophakia or aphakia
- severe PVR.

Surgical excision of subfoveal neovascular membranes associated to traumatic choroidal ruptures was proposed in 1996 by Gross [65]. Recombinant tissue plasminogen activator and gas were used successfully to treat subhyaloidal or sub-ILM hemorrhages occurring in Valsalva retinopathy, shaken baby and Terson’s syndrome [27, 111].

5.3.4.2.1. Tamponading agents [80, 107]

Two characteristics are essential:

- force of the internal tamponade- associated to the surface tension, it corresponds to the capacity of break closure
- force of reapplication- corresponds to the capacity of sub-retinal fluid displacement and is dependent on material density.

Tamponading agents used during vitrectomy procedure are:

- air
- perfluorocarbon gases used pure or in non expansive concentrations:

sulphur hexafluoride (SF₆)

perfluoroethane (C₂F₆)

perfluoropropane (C₃F₈)

- perfluorocarbon liquids (used at per-operative time)
- silicone oils.

5.3.4.2.2. Postoperative complications

Postoperative complications include:

- raised intraocular pressure due to
 - overexpansion of intraocular gas
 - early silicone-oil induced glaucoma
 - late silicone-oil induced glaucoma
 - ghost cell glaucoma
 - steroid induced glaucoma
- cataract
 - gas-induced lens opacity (transient)
 - silicone-oil- induced cataract
 - nuclear sclerosis (within 5-10 years)
- retinal re-detachment
 - reopening of the original break especially due to PVR
 - new or missed breaks.

6.0. OUR STUDY

6.1. Aim and type of the study

The aim of this prospective observational case series study was to evaluate epidemiology, etiology, initial characteristics, 12-month evolution and prognostic factors of closed-globe blunt retinal injuries of patients diagnosed at the Eye Emergency Department of Poznań District Hospital and the one of Pontchaillou Hospital of Rennes and formulate helpful indications on prevention and adapted follow-up.

6.2. Patients and methods

A prospective analysis of patients presenting to the Eye Emergency Department of Poznań District Hospital from March 2008 to December 2008 and from June 2009 to September 2009 (total of 14 months) and to the Eye Emergency Department of Pontchaillou Hospital of Rennes from October 2007 to February 2008 and January 2009 to May 2009 (total of 10 months) was performed.

6.2.1. Inclusion criteria

Patients with diagnosis of retinal damage following blunt, closed-globe ocular injury, called ocular contusion, according to Birmingham Eye Trauma Terminology System (BETTS), dated of five days or less were included into the study.

6.2.2. Exclusion criteria

Exclusion criteria included retinal damage resulting from mixed ocular trauma, pre-existing retinal pathologies, ocular surgery and non-cooperative patients.

6.3. Methods

6.3.1. Initial examination

6.3.1.1. Interview

The following details were recorded from each patient:

- age and sex,
- ocular contusion date, type and activity at the time of injury,
- presence of ocular protection,
- subjective signs,
- laterality,
- place of the first medical consultation,
- ophthalmological consultation delay after the trauma,
- previous ophthalmologic history.

6.3.1.2. Examination

A bilateral ocular examination was carried out, including:

- adnexia inspection: orbital region, eyelids, lacrimal system, conjunctiva,
- oculomotricity examination,
- best corrected visual acuity (BCVA) for far,
- pupillary reflexes,
- slit-lamp microscopy of the anterior segment,
- applanation tonometry,
- ocular fundus examination after pupillary dilatation with Super Field Volk lens and triple

mirror when possible, including:

- Posterior pole examination: optic nerve, macula, retina
- Retinal periphery examination.

6.3.1.3. Imaging examinations

In selected cases imaging examinations included:

- retinal photographs
- ultrasonography
- optical coherence tomography (OCT)
- fluorescein angiography (FA).

6.3.1.4. Classification after initial examination

Type of injury

Trauma was classified as direct (trauma of the eye) or indirect (traumatic eye damage resulting from trauma of other structure).

Activity at the time of injury

Activities performed at the time of injury were classified as:

- sport
- recreation (leisure activities excluding recognized sports)
- assault
- everyday activities (home, work).

Initial best corrected visual acuity (BCVA)

Two groups of initial best corrected visual acuity were distinguished:

- I group: BCVA < 5/10
- II group: BCVA ≥ 5/10.

Extent of retinal injury

Three groups of extent of injury were distinguished:

- I group: central and peripheral damage
- II group: central damage
- III group: peripheral damage

Data providing from patients followed in Poznań and Rennes were compared.

6.3.2. Follow-up examinations

All patients were monitored during a period of one year, all follow-up visits were scheduled depending on the initial best corrected visual acuity and damage extent as follows:

- Initial BCVA < 5/10 or large extent of damage: at 1 week, at 1 months, at 6 months, at one year after the injury
- Initial BCVA \geq 5/10 and damage isolated: at 3 weeks, at 3 months, at one year.

Follow-up visits were more frequent when indicated. BCVA at the initial and final clinical visit were compared.

6.3.3. Treatment

Initial treatment as well as further details of treatment and outcome were determined.

Treatment of retinal damage was classified as either prophylactic or therapeutic.

6.3.4. Data analysis

6.3.4.1. Clinical analysis

It was based on interview, examination and imaging examinations.

6.3.4.2. Statistical methods

Statistical analysis of data was performed using Statistica 9 and StatXact 8 software. For data with distribution differing from normal, medians, quartiles, minimal and maximal values were presented. Destined for small groups, the Fisher exact test and Fisher-Freeman-Halton test were used for the analysis of quality type of data in 2-by-2 and r-by-c tables respectively. They were used also to determine statistically significant prognostic factors related to final BCVA and presence of permanent retinal lesions. t-Student test and non-parametric tests of Mann-Whitney and Wilcoxon were used for quantity type of data. The value of $p < 0,05$ was considered as statistically significant.

Visual acuity measured in decimal chart was transformed into log MAR units for a statistical analysis. For values below 0,05 following conversions were done:

Count fingers from 2 meters = +1,5 log MAR

Count fingers from 1 meter = +1,7 log MAR

Count fingers from 30 centimeters = +2 log MAR

Hand movements = +2,3 log MAR

Light perception = +2,6 log MAR

No light perception = +2,9 log MAR.

Means or medians of visual acuity expressed in log MAR units were transformed into a decimal chart for a more comprehensive result. The study was approved by the Bioethics Committee of Faculty of Medicine at Poznań University of Medical Sciences.

6.4. Results

Demography

A total number of 35 cases of retinal contusions was included: 20 eyes (19 patients) in Poznań and 15 eyes (15 patients) in Rennes. Details of the sex and age distribution are shown in Table 6.1. and Fig 1. Two peaks of age were noted in Poznań and the number of men over 40 was significantly higher ($p=0,0464$).

| | Total | POZNAŃ | RENNES |
|-------------------------|----------------------------------|--------------------------------------|--------------------------------------|
| Patients number | 34 | 19 | 15 |
| M/F ratio | 25/9 (74%/ 26%) | 14 /5 (74 %)/(26 %) | 11 /4 (73 %)/(27 %) |
| Age (years) | 7-58 | 15-58 | 7-53 |
| Mean age (years) | 32,7 ± 14,4 | 35,9 ± 16,0 | 29,2 ± 12,2 |
| M | 30,6 ± 14,0 | 34,6 ± 16,6 | 25,7 ± 8,6 |
| F | 38,9 ± 14,6 | 39,4 ± 15,0 | 38,8 ± 16,9 |

Table 6.1. Demographic characteristics of patients with retinal contusion.

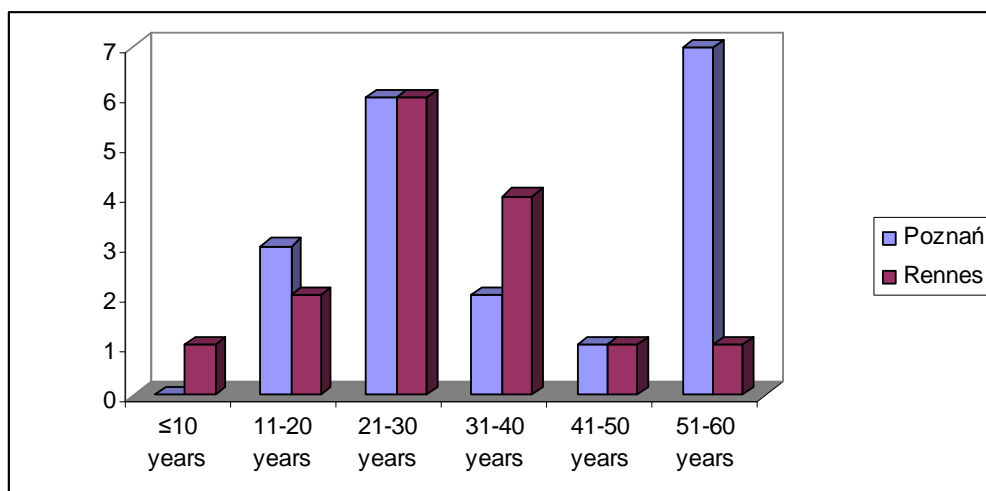


Fig. 1. Age distribution of patients presenting with retinal contusions.

Previous ocular history collected in Poznań included: one case of myopia corrected by spectacles and in Rennes: two cases of myopia (one corrected by spectacles, the other by soft contact lenses and one case of hypermetropia with presbyopia corrected by progressive spectacles.

Type of trauma

In 18 of 20 eyes in Poznań (90%) retinal contusions resulted from a direct ocular shock. In the case of two eyes of one patient, the indirect eyes trauma during a motor accident was the reason. Direct trauma was responsible for damage observed in 14 eyes in Rennes (93%). One indirect eye trauma resulted from a bike accident. In both cases of indirect eye trauma, there was loss of consciousness and patients were hospitalized beside ophthalmology ward.

Activity at the time of injury

Activity of patients during ocular trauma is shown at Fig. 2 and 3 and Table 6.2. In Poznań, the most frequent were retinal contusions resulting from everyday activities and in Rennes retinal damage due to sports were most common. Differences were statistically significant ($p= 0,0019$ for everyday activities and $p= 0,0282$ for sports). None of patients had ocular protection at the time of direct eye injury.

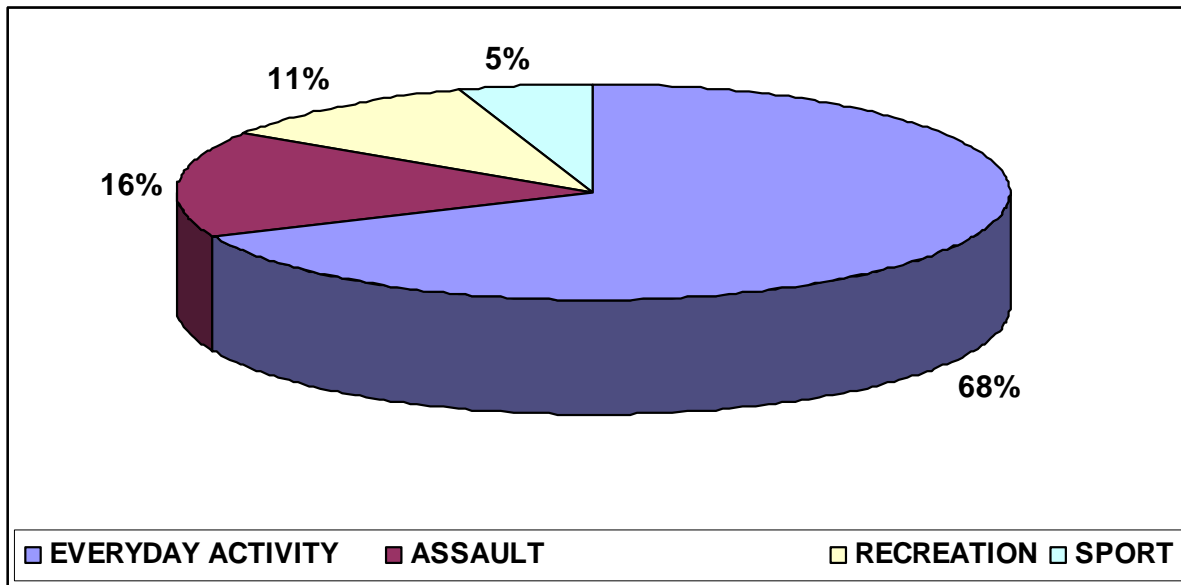


Fig.2. Activity at the time of injury in Poznań.

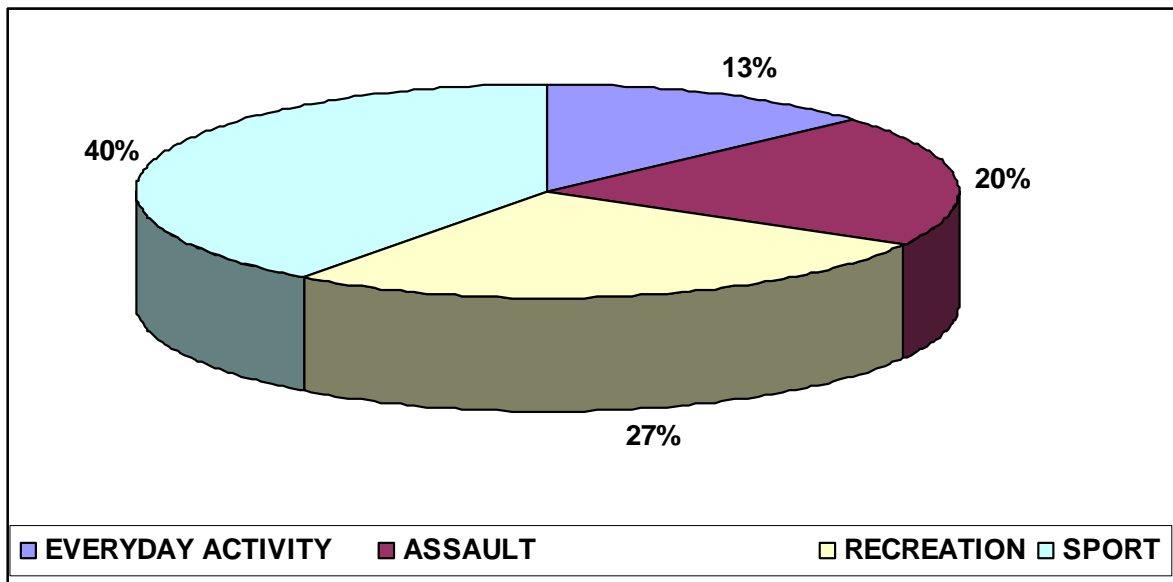


Fig.3. Activity at the time of injury in Rennes.

| POZNAŃ | | RENNES | | p |
|-----------------------------|--------------|--------------------------|-------------|------------------|
| EVERYDAY ACTIVITY | 13/19 | EVERYDAY ACTIVITY | 2/15 | 0,0019 |
| wood piece (chopping) | 4/13 | tow rope (work) | 1/15 | |
| dog-lead | 1/13 | bike accident | 1/15 | |
| collision with a cockchafer | 1/13 | | | |
| champagne pop | 1/13 | | | |
| clothes hanger | 1/13 | | | |
| electric cable | 1/13 | | | |
| child's heel | 1/13 | | | |
| motor accident | 1/13 | | | |
| branch | 1/13 | | | |
| buzz saw | 1/13 | | | |
| ASSAULT | 3/19 | ASSAULT | 3/15 | p>0,05 |
| Fist | 2/3 | Fist | 2/3 | |
| Stone | 1/3 | Egg | 1/3 | |
| RECREATION | 2/19 | RECREATION | 4/15 | p>0,05 |
| Paintball | 1/2 | Paintball | 2/4 | |
| Firework | 1/2 | Bumerang | 1/4 | |
| | | Branch (hunting) | 1/4 | |
| SPORT | 1/19 | SPORT | 6/15 | 0,0282 |
| Football (ball) | 1/1 | Badminton (shuttlecock) | 2/6 | |
| | | Football (ball) | 1/6 | |
| | | Squash (ball) | 1/6 | |
| | | Hokey (stick) | 1/6 | |
| | | Tennis (ball) | 1/6 | |

Table 6.2. Activity at the time of injury.

Place of the first consultation

37 % of patients in Poznań consulted ophthalmologic emergency directly. 26 % were referred by an ophthalmologic practice, the same by out-hospital emergency unit and 5 % by other ward (Table 6.3.). 33,3 % of patients from Rennes were referred to the ophthalmologist by the emergency ward out of CHU, 26,7 % by the emergency ward of CHU, the same by an ophthalmologic practice and 6,7 % by an occupational medicine doctor and other ward.

| POZNAŃ | | RENNES | |
|--------------------------------------|-------------|--------------------------------------|---------------|
| Ophthalmologic emergency | 7/19 (37 %) | Emergency ward out of CHU | 5/15 (33,3 %) |
| Out-hospital emergency unit | 5/19 (26 %) | Emergency ward of CHU | 4/15 (26,7 %) |
| Ophthalmologic practice | 5/19 (26%) | Ophthalmologic practice | 4/15 (26,7 %) |
| | | Occupational medicine doctor | 1/15 (6,7 %) |
| Hospitalization beside ophthalmology | 1/19 (5%) | Hospitalization beside ophthalmology | 1/15(6,7 %) |

Table 6.3. Place of the first consultation.

Time to ophthalmologic examination

The ophthalmologic examination was performed in first 3 hours following the trauma in 63 % of patients from Poznań comparing with 47 % in Rennes (Table 6.4.). There was no statistical significance ($p > 0,05$).

| POZNAŃ | | RENNES | |
|---------------|-------|---------------|------|
| <3h | 12/19 | <3h | 7/15 |
| 3-12 h | 3/19 | 3-12 h | 6/15 |
| 12-24 h | 3/19 | 12-24 h | - |
| 24-48 h | 1/19 | 24-48 h | 2/15 |

Table 6.4. Time from ocular trauma to ophthalmologic examination.

6.4.1. Initial examination

Tables 6.5. and 6.6. show the relationship of initially diagnosed retinal damage to the nature of the injury, anterior segment lesions, initial posttraumatic visual acuity and type of initial treatment respectively in Poznań and in Rennes. The most frequent damage on initial examination was commotio retinae: 18 of 20 eyes in Poznań (90%) and 14 of 15 eyes in Rennes (93%).

| Case | Sex and age | Object | Anterior segment | Central retina | Retinal periphery | BC VA | Initial treatment |
|------|-------------|----------------|---|--|---|------------|-------------------|
| 1 | F, 22 | firework | Skin and conjunctival burn | Commotio retinae Choroidal rupture | Commotio retinae Vitreous hemorrhage | 0,06 | Hospit. |
| 2 | M, 32 | buzz saw | Lid contusion Lens subluxation Traumatic cataract | Commotio retinae Papilar edema | Ø | 0,06 | Hospit. |
| 3 | M, 18 | branch | Hyphema Iridodialisis | Commotio retinae | Ø | 0,06 | Hospit. |
| 4 | M, 25 | football | Lid contusion Subconjunctival hemorrhage | Commotio retinae Vitreous hemorrhage | Vitreous hemorrhage | 0,06 | AT. |
| 5 | M, 58 | wood piece | Subconjunctival hemorrhage Corneal abrasion | Commotio retinae | Commotio retinae | 0,2 | Hospit. |
| 6 | M, 25 | motor accident | Lid contusion | Bilateral commotio retinae with RPE changes | Ø | 0,2 0,4 | Other ward |
| 7 | F, 55 | dog-lead | Lid and conjunctiva laceration Hyphema Angle recession | Commotio retinae Retinal hemorrhage Choroidal ruptures | Ø | 0,3 | Hospit. |
| 8 | M, 55 | wood piece | Corneal abrasion | Commotio retinae | Ø | 0,4 | AT. |
| 9 | M, 26 | paintball | Lid contusion Subconjunctival hemorrhage Corneal abrasion Hyphema Angle recession | Commotio retinae Choroidal ruptures | Commotio retinae Retinal hemorrhage Vitreous hemorrhage | 0,5 | Hospit. |

| | | | | | | | |
|----|-------|-------------------|--|---|--|-----|---------|
| 10 | M, 15 | stone | Lid contusion Inferior orbital rim fracture Corneal abrasion Hyphema | Commotio retinae | Retinal hemorrhage Vitreous hemorrhage | 0,8 | Hospit. |
| 11 | M, 55 | cockchafer | Lid contusion Subconjunctival hemorrhage Iris sphincter rupture Lens subluxation Hyphema | Retinal hemorrhages | Ø | 0,8 | Hospit. |
| 12 | M, 18 | fist | Lid contusion | Commotio retinae | Commotio retinae | 1,0 | AT. |
| 13 | M, 50 | wood piece | Conjunctiva laceration | Ø | Commotio retinae Retinal hemorrhage | 1,0 | AT. |
| 14 | F, 25 | champagne pop | Lid contusion | Commotio retinae Retinal hemorrhages | Commotio retinae | 1,0 | AT. |
| 15 | F, 50 | clothes hanger | Conjunctiva laceration | Ø | Commotio retinae | 1,0 | AT. |
| 16 | F, 45 | child's heel | Corneal abrasion | Peripapillar hemorrhage | Ø | 1,0 | AT. |
| 17 | M, 20 | fist | Lid contusion Skin emphysema | Peripapillar hemorrhage | Commotio retinae | 1,0 | AT. |
| 18 | M, 58 | wood piece | Conjunctiva laceration | Ø | Commotio retinae Vitreous base avulsion | 1,0 | AT. |
| 19 | M, 30 | electric cable | Conjunctiva laceration | Ø | Commotio retinae | 1,0 | AT. |

Table 6.5. Relationship of initially diagnosed retinal damage to the nature of the injury, anterior segment lesions, initial posttraumatic visual acuity and type of initial treatment in Poznań.

| Case | Sex and age | Object | Anterior segment | Central retina | Retinal periphery | BC VA | Initial treatment |
|------|-------------|-----------|---|---|--|---------------|-------------------|
| 1 | M, 22 | paintball | Subconjunctival hemorrhage Corneal abrasion Hyphema | Commotio retinae | Retinal hematoma Vitreous hemorrhage | LP | Hospit. |
| 2 | M, 40 | paintball | Lid contusion Conjunctiva laceration Corneal abrasion Hyphema Angle recession | Commotio retinae | Commotio retinae Subretinal hematoma Retinal hemorrhages | CF from 30 cm | Hospit. |
| 3 | M, 7 | boumerang | Lid contusion and laceration Conjunctiva laceration Hyphema | Commotio retinae | Commotio retinae Subretinal hematoma | CF from 30 cm | Hospit. |
| 4 | M, 37 | badminton | Hyphema Iris sphincter rupture | Commotio retinae | Commotio retinae | 0,06 | AT. |
| 5 | M, 33 | tow rope | Lid contusion Conjunctiva laceration Corneal abrasion | Commotio retinae | Commotio retinae Retinal hematoma | 0,06 | AT. |
| 6 | M, 25 | football | Lid contusion Subconjunctival hemorrhage | Commotio retinae Vitreous hemorrhage | Commotio retinae Intraretinal hemorrhages | 0,1 | AT. |
| 7 | M, 19 | tennis | Conjunctival hyperhemia | Subretinal hematoma | Commotio retinae | 0,1 | AT. |
| 8 | F, 47 | fist | Lid contusion Hyphema | Commotio retinae Peripapillar hemorrhage | Ø | 0,2 | Hospit. |
| 9 | F, 39 | egg | Lid contusion Subconjunctival hemorrhage Corneal abrasion hyphema | Commotio retinae | Ø | 0,8 | AT. |

| | | | | | | | |
|----|-------|---------------|--|------------------------|--|-----|------------|
| 10 | M, 26 | squash | Ø | Commotio retinae | Commotio retinae | 1,0 | AT. |
| 11 | F, 15 | badminton | Corneal abrasion | Ø | Commotio retinae | 1,0 | AT. |
| 12 | M, 23 | fist | Lid contusion Lacrimal ducts laceration | Ø | Commotio retinae | 1,0 | Hospit. |
| 13 | F, 52 | bike accident | Lid contusion and laceration | Peripapilar hemorrhage | Ø | 1,0 | Other ward |
| 14 | M, 28 | hockey | Lid contusion and laceration | Commotio retinae | Commotio retinae | 1,0 | AT. |
| 15 | M, 25 | branch | Lid contusion and laceration Conjunctiva laceration Corneal abrasion | Ø | Commotio retinae Retinal hemorrhages Vitreous hemorrhage | 1,0 | Hospit. |

Table 6.6. Relationship of initially diagnosed retinal damage to the nature of the injury, anterior segment lesions, initial posttraumatic visual acuity and type of initial treatment in Rennes.

Initial extent of retinal injury

The initial extent of retinal injury is summarized at Table 6.7.

| Initial retinal injury localization | Total | POZNAŃ | RENNES |
|--------------------------------------|-----------------|----------------|----------------|
| Eyes number | 35 | 20 | 15 |
| Central and peripheral damage | 17 (49%) | 8 (40%) | 9 (60%) |
| Purely central damage | 11 (31%) | 8 (40 %) | 3 (20%) |
| Purely peripheral damage | 7 (20%) | 4 (20%) | 3 (20%) |

Table 6.7. Initial extent of retinal injury.

Initial VA

Statistically significant difference in category of initial BCVA was noted in three groups of initial damage extent ($p=0,0141$). 59 % of patients with both central and peripheral damage and 64 % of these with only central lesions were in group of BCVA $<0,5$. All patients with peripheral injuries were classified into group of initial BCVA $\geq 5/10$.

Table 6.8. shows the median of initial posttraumatic visual acuity in logMAR units (distribution differing from normal) and corresponding visual acuity in decimal chart. There was no statistically significant difference between two centers of recruitment. However, the initial VA was significantly lower at the group of patients with both central and peripheral retinal damage in Rennes and was of 1,2 logMAR (0,06 in decimal chart), comparing with 0,4 logMAR (0,4 in decimal chart) in Poznań ($p= 0,0445$). There was no significant difference between two centers in other groups of initial damage extent.

| BCVA | Total | POZNAŃ | RENNES | p-value |
|--|----------------------------|--------------------|--------------------|----------|
| Median LogMAR scale | 0,3 | 0,2 | 0,7 | $p>0,05$ |
| Q1-Q3 Min-Max | (0-1,2) (0-2,6) | (0-0,7) (0-1,2) | (0-1,2) (0-2,6) | |
| Corresponding VA in decimal chart | 0,5 | 0,63 | 0,2 | |
| Min-Max | (LP-1,0) | (0,06-1,0) | (LP-1,0) | |

Table 6.8. Initial posttraumatic visual acuity.

Primary hospitalization

8 of 18 (44%) patients in Poznań and 6 of 14 (43%) patients in Rennes were hospitalized after the presentation to an ophthalmologic emergency unit ($p>0,05$). Patients treated in other wards were not considered. Causes of eye trauma in hospitalized patients and arguments for primary hospitalization were summarized at Table 6.9. The duration of primary hospitalization in Poznań was significantly longer (6,75 versus 3 days, $p= 0,0319$).

Treatment

Topical treatment was adapted individually to each eye according to general rules (antibiotics, anti-inflammatory medications, drugs decreasing IOP). In 9 of 19 patients in Poznań (47%) and 4 of 15 in Rennes (27%) general treatment by glicocorticosteroids (oral or intravenous) was introduced ($p > 0,05$).

| Primary hospitalization | POZNAŃ 8/18 (44%) | RENNES 6/14 (43%) |
|---|-----------------------------|-----------------------------|
| Activity at the time of injury | | |
| Everyday activity | 5 | 0 |
| Assault | 1 | 2 |
| Recreation | 2 | 4 |
| Sport | 0 | 0 |
| Reasons for hospitalization | | |
| Large extent of damage | 1 | 0 |
| Large extent of damage + reduction of VA | 4 | 2 |
| Large extent of damage + rise of IOP | 2 | 0 |
| Large extent of damage + reduction of VA + rise of IOP | 1 | 1 |
| Large extent of damage + reduction of VA + conjunctival wound exploration (child) | 0 | 1 |
| Conjunctiva wound exploration | 0 | 0 |
| Lacrimal ducts wound reparation | 0 | 1 |
| Average duration (days) and range | 6,75 ± 2,7 (3-11) | 3 ± 2,5 (1-7) |

Table 6.9. Causes of eye trauma and arguments for primary hospitalization.

6.4.2. Follow-up examinations

The scheme of examinations was adapted according to the initial posttraumatic visual acuity and damage extent. Results of one year follow-ups in groups depending on initial lesion localization were presented. Selected cases from two centers with imaging examination results were presented above tables for each group.

Initially central and peripheral retinal damage

Table 6.10. summarizes results of one year follow-up examinations of patients from Poznań with initially both central and peripheral retinal damage.

| Case N° | Sex and age | Object | Central retina damage on 1-year follow-up | Retinal periphery damage on 1-year follow-up | Initial BC VA | Retinal treatment | Associated problems | 1 year BC VA |
|---------|-------------|---------------|---|---|---------------|---|------------------------------|--------------|
| 1 | F, 22 | firework | Macular atrophy Indirect choroidal rupture | ∅ | 0,06 | ∅ | ∅ | 0,3 |
| 4 | M, 25 | football | | One quadrant multiple retinal tears (8 th day) Retinal detachment (18 th day) PVR | 0,06 | Laser (8 th , 14 th day) Surgery 1 st time: Encirclement (25 th day) 2 nd time: Phaco+ ppv +silicone (46 th day) | ∅ | 0,1 |
| 5 | M, 58 | wood piece | ∅ | ∅ | 0,2 | ∅ | Posttraumatic cataract | 0,5 |
| 9 | M, 26 | paintball | Indirect choroidal ruptures | Direct choroidal rupture | 0,5 | ∅ | Ocular hypertonia (9 months) | 1,0 |
| 10 | M, 15 | stone | ∅ | ∅ | 0,8 | ∅ | Ocular hypertonia (3 months) | 1,0 |
| 12 | M, 18 | fist | ∅ | ∅ | 1,0 | ∅ | ∅ | 1,0 |
| 14 | F, 25 | champagne pop | ∅ | ∅ | 1,0 | ∅ | ∅ | 1,0 |
| 17 | M, 20 | fist | ∅ | ∅ | 1,0 | ∅ | ∅ | 1,0 |

Table 6.10. One year follow-up examinations of patients from Poznań with initial central and peripheral retinal damage.

Case 1

A 22-year old woman was struck on the right eye by a firework. The initial BCVA was of 0,06. It improved to 0,3 one month after the trauma. The aspect of eye fundus and result of macular OCT at that time are presented at Fig. 4.

Fig. 5. shows 3-month angiography. The BCVA and stated damage were stable during 1 year follow-up (Fig. 6. and Fig. 7.).

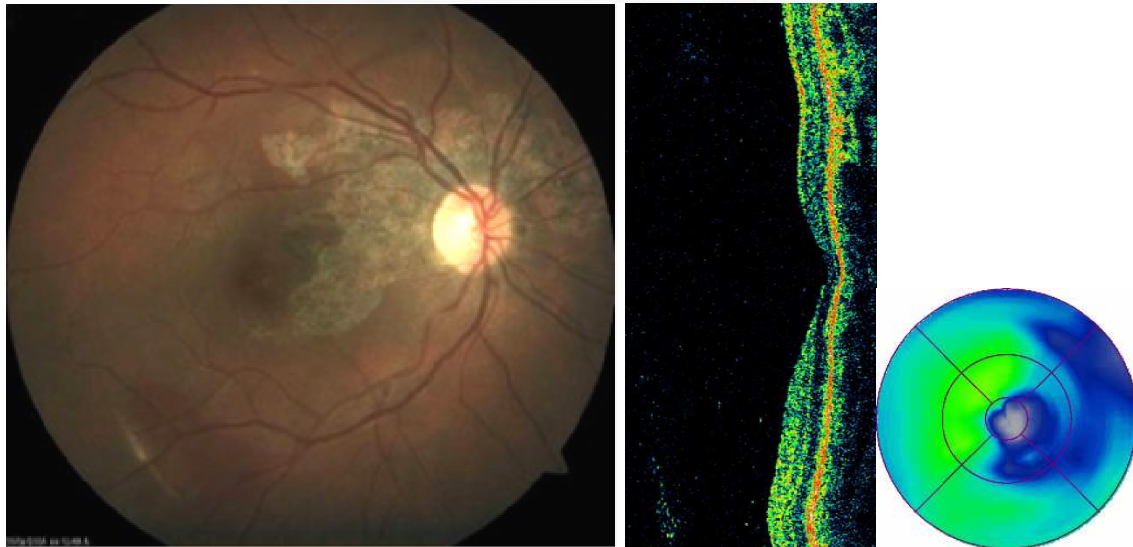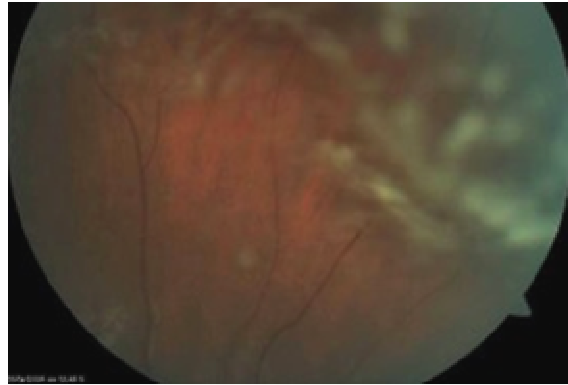


Fig. 4. The aspect of eye fundus: RPE changes, indirect choroidal rupture, vitreous hemorrhage and foveal atrophy in macular OCT one month after the firework trauma, BCVA 0,3.

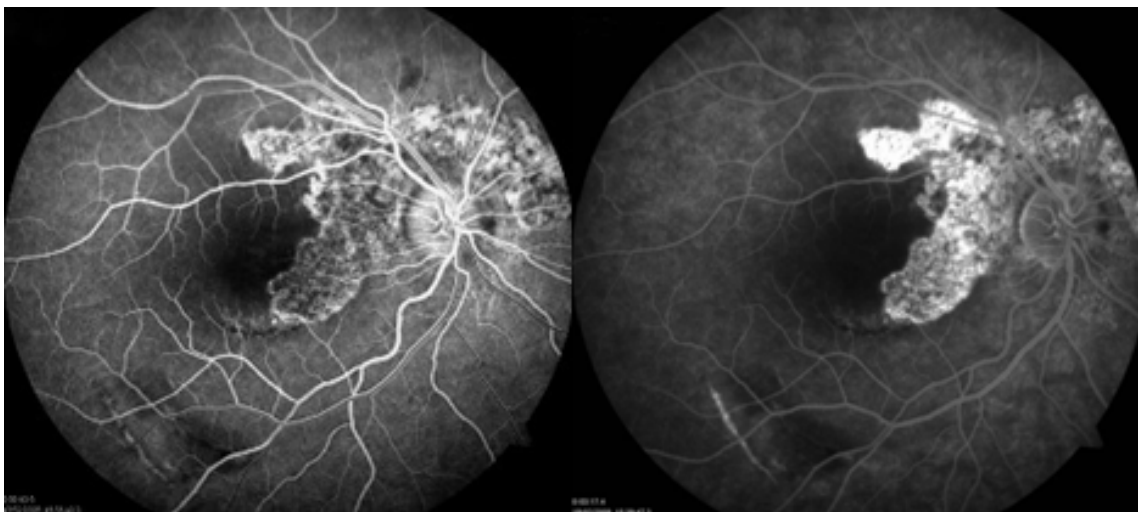


Fig. 5. Angiography three months after the firework trauma, BCVA 0,3.

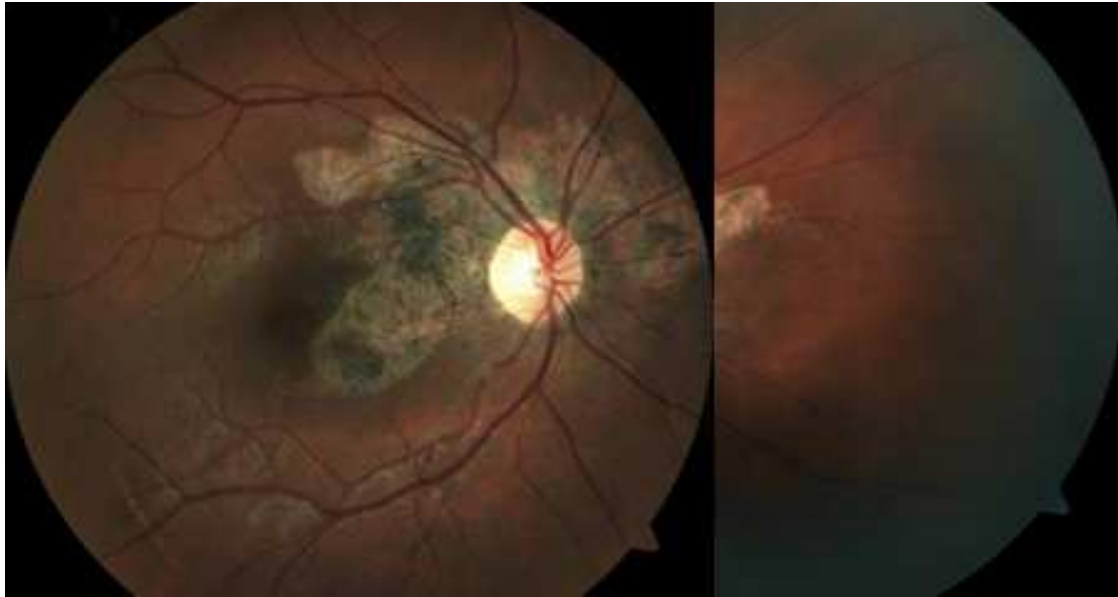


Fig. 6. Eye fundus aspect one year after the firework trauma, BCVA 0,3.

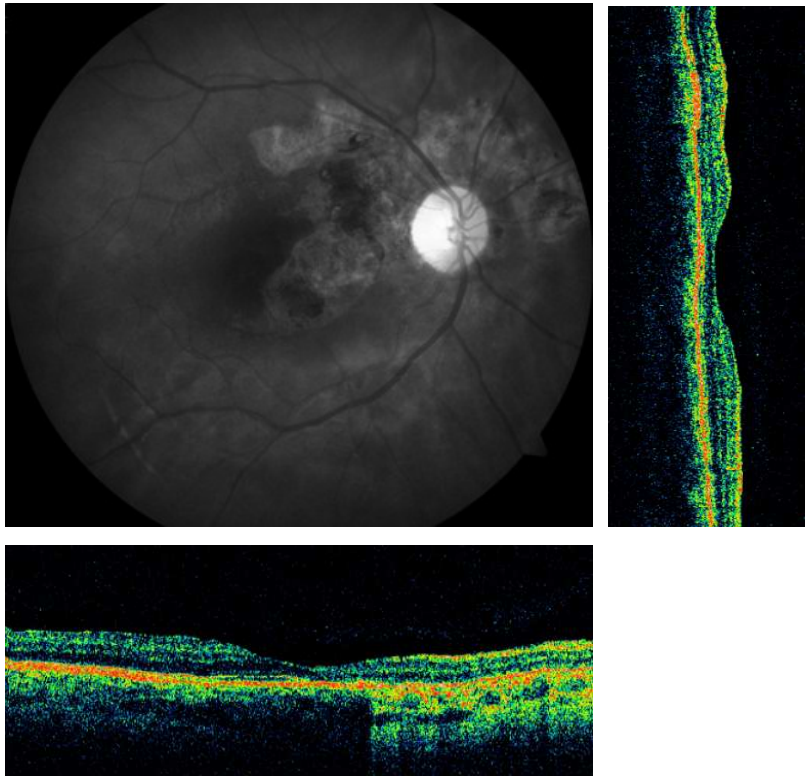


Fig. 7. Posterior pole image at red light and macular OCT one year after the firework trauma: RPE damage and foveal abnormalities, BCVA 0,3.

Case 9

A 26-year-old man was admitted with anterior and posterior segment lesions after left eye trauma during paintball game. BCVA was of 0,5. It improved to 1,0 within 1 week. Fig. 8. shows eye fundus and macular OCT three weeks after the trauma. The aspect after six months and one year are shown at Fig. 9 and 10 respectively.

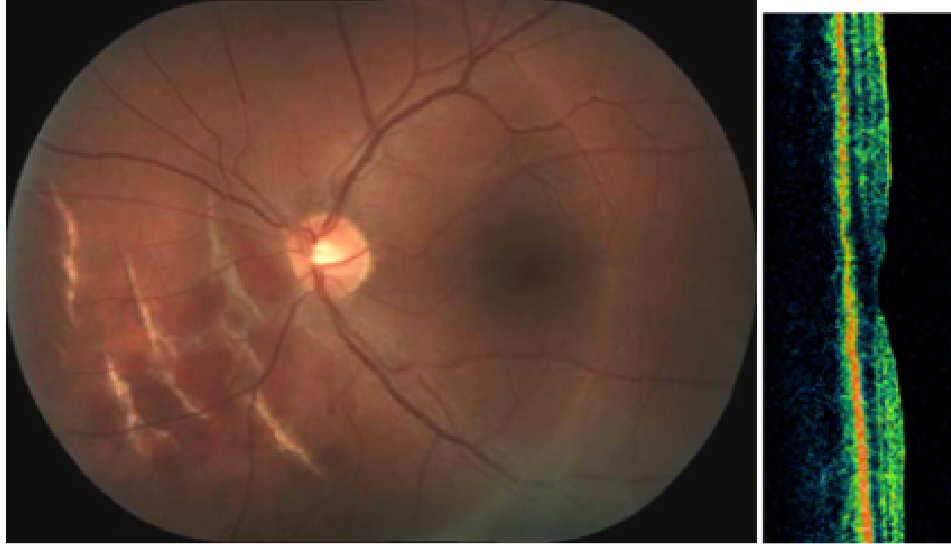

Fig. 8. Peri-papillar indirect choroidal ruptures and macular OCT three weeks after the trauma during paintball game, BCVA 1,0.

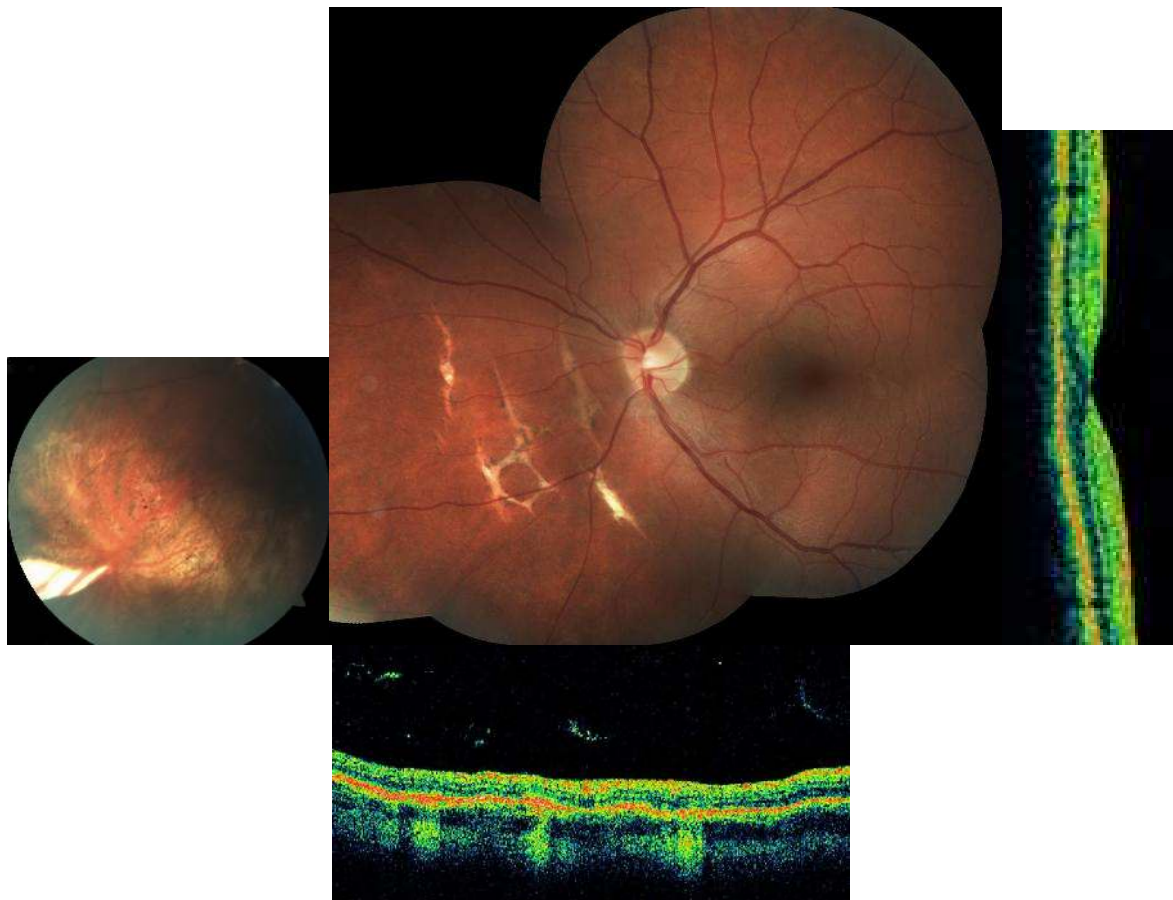


Fig. 9. Peripheral direct and peripapillar indirect choroidal ruptures: eye fundus and OCT six months after the trauma during paintball game. BCVA 1,0.

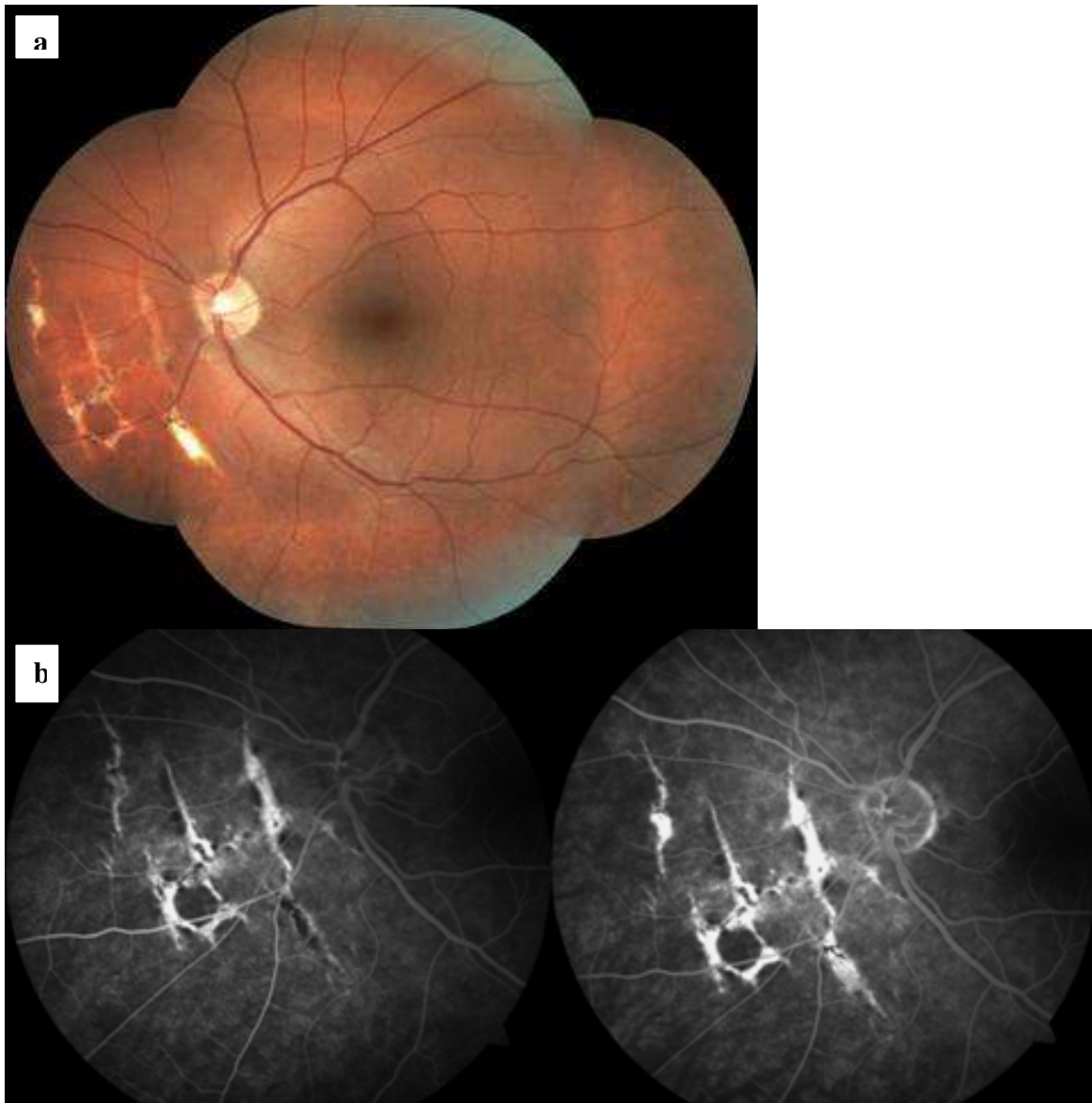


Fig. 10. Eye fundus (a) and fluorescein angiography (b) of choroidal ruptures area one year after the trauma during paintball game. BCVA 1,0.

Case 14

A 24-year-old woman after a champagne pop injury was found to have both central and peripheral retinal lesions. BCVA was of 1,0. The aspect of eye fundus and OCT one day after the trauma are shown at Fig. 11. Three weeks after there were no retinal sequellae (Fig. 12). One year follow-up was without incident.

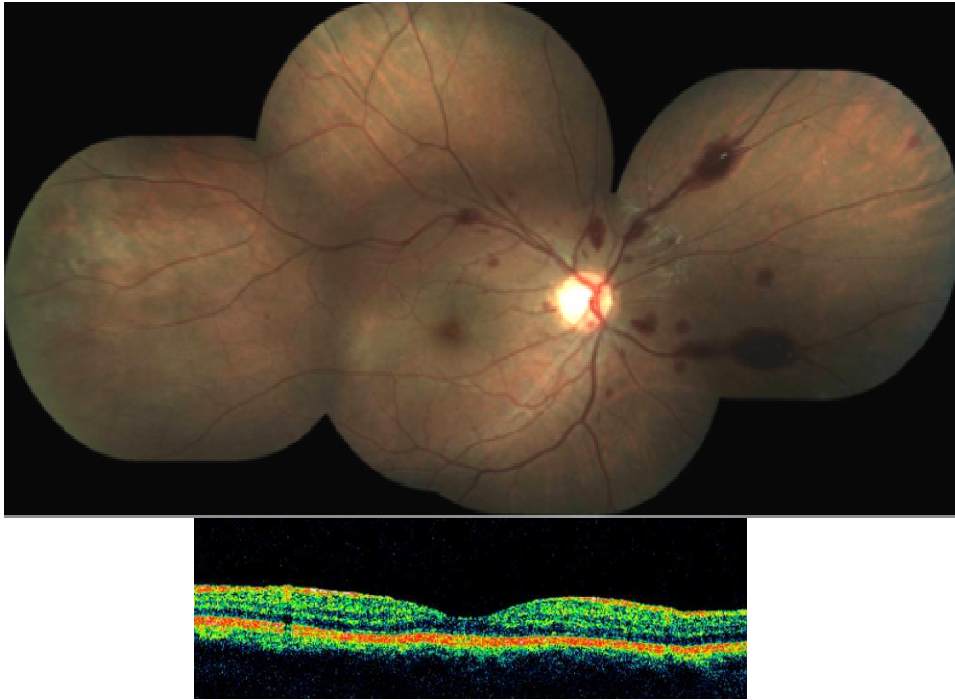


Fig. 11. Central and temporal commotio retinae associated to retinal hemorrhages: fundus of the eye and macular OCT one day after a champagne pop injury, BCVA 1,0.

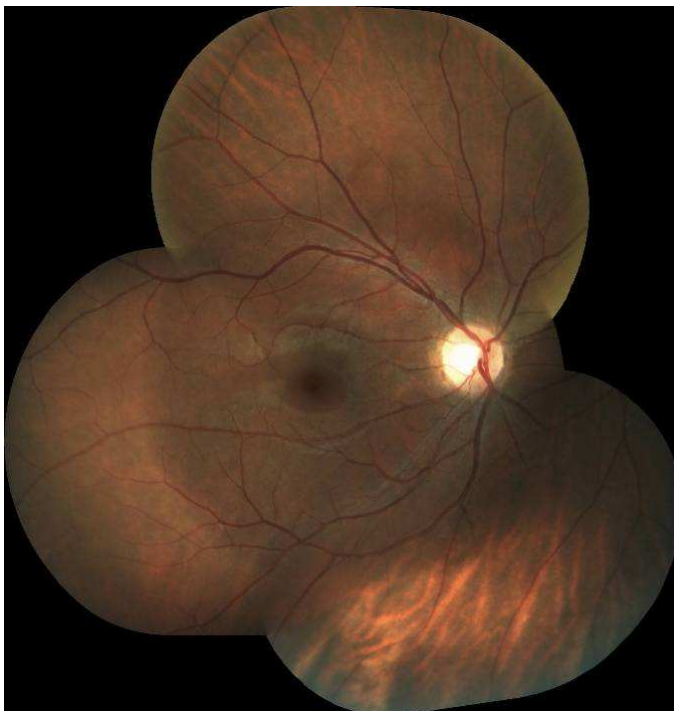


Fig. 12. Regression of retinal abnormalities: eye fundus three weeks after a champagne pop injury, BCVA 1,0.

Results of one year follow-up examinations of patients from Rennes with initially both central and peripheral retinal damage are summarized at Table 6.11.

| Case N° | Sex and age | Object | Central retina damage | Retinal periphery damage | Initial BC VA | Retinal treatment | Associated problems | 1 year BC VA |
|---------|-------------|------------|---|---|---------------|---|------------------------------|--------------|
| 1 | M, 22 | paint-ball | Persistent vitreous hemorrhage Macular atrophy Optic neuropathy | Choroido-retinal rupture (sclopetaria) Posttraumatic retinoschisis | LP | Phaco-aspiration+ ppv (28 th day) | Orbital neuralgia | NLP |
| 2 | M, 40 | paint-ball | Macular hole (12 th month) | Posttraumatic retinopathy | CF from 30 cm | | Ocular hypertonia (2 months) | 0,6 |
| 3 | M, 7 | boumerang | Persistent vitreous hemorrhage Macular atrophy | Direct choroidal rupture | CF from 30 cm | Ppv+ inferior scleral buckling (15 th day) | Visual reeducation | 0,8 |
| 4 | M, 37 | badminton | Ø | Retinal detachment (6 th day) | 0,06 | Laser barrage (8 th day) | Subcapsular cataract | 1,0 |
| 5 | M, 33 | tow rope | Macular atrophy | Retinal detachment (3 rd week) Direct choroidal rupture | 0,06 | Cryo+ Scleral buckling (6 th week) | Ø | 0,4 |
| 6 | M, 25 | football | Macular hole (8 th day) Pigmented maculopathy | Persurgical retinal break | 0,1 | Cryo+Ppv+ ILM peeling+ gaz (16 th day) | Subcapsular cataract | 0,6 |
| 7 | M, 19 | tennis | Choroidal rupture | Ø | 0,1 | Ø | Ø | 0,4 |
| 10 | M, 26 | squash | Ø | Ø | 1,0 | Ø | Ø | 1,0 |
| 14 | M, 28 | hockey | Ø | Ø | 1,0 | Ø | Ø | 1,0 |

Table 6.11. One year follow-up examinations of patients from Rennes with initial central and peripheral retinal damage.

Case 1

A 22-year-old man was struck on his left eye playing paintball. Initial BCVA was restricted to luminous perception. At admission preretinal hemorrhage at posterior pole and associated vitreous hemorrhage were seen (Fig. 13 a). After 48 hours initial hospitalization, every one week follow-up was counseled. Clinical increase of vitreous hemorrhage with membrane formation on ultrasonography was found on three-week follow-up visit (Fig. 13 b).

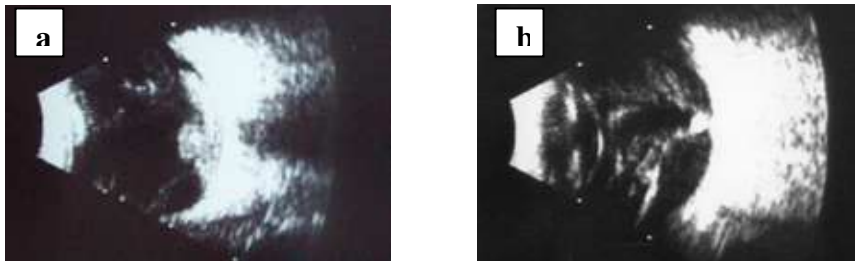


Fig. 13. Ultrasonographic image 70 dB, C12 **a**: posterior pole pre-retinal hemorrhage and vitreous hemorrhage 1st day after paintball injury, VA LP; **b**: 3 weeks after paintball injury, VA LP

Phacoaspiration and pars plana vitrectomy were performed on fourth week after the trauma revealing large chorioretinal rupture (sclopetaria) as well as macular damage. On a 2-month follow-up there was no light perception, due to optic neuropathy confirmed by VEP. The appearance of the eye fundus and OCT one year after the trauma are shown in Fig. 14.

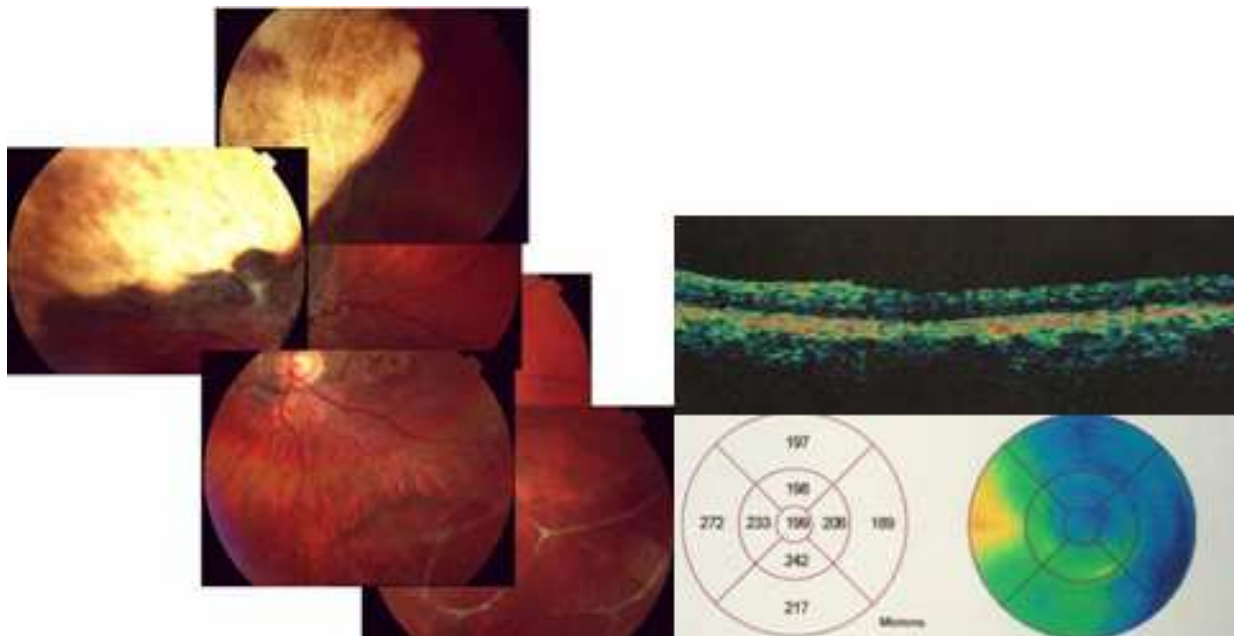


Fig. 14. Clinical and OCT appearance one year after the trauma, VA NLP.

Case 2

A 40-year-old man was admitted with anterior and posterior segment lesions after right eye trauma during paintball game. BCVA was of CF from 30 cm. Progressive resolution of retinal hemorrhage resulting in pigmented disturbances was observed. Six months after the trauma, foveal profile at OCT was preserved with possible early disruption of photoreceptors/RPE layer (Fig. 15). BCVA was of 0,6. Twelve month after the incident fundus examination and OCT revealed macular hole (Fig. 16, Fig. 17). VA was unchanged. Therapeutic abstinence was proposed.

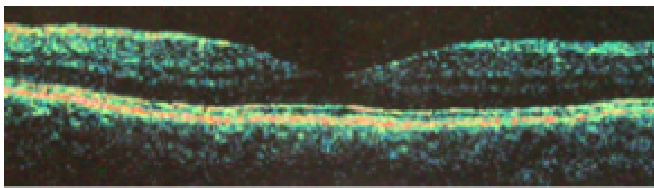


Fig. 15. Six months after paintball trauma: foveal profile in OCT preserved, possible early disruption of photoreceptors/RPE layer, BCVA 0,6.

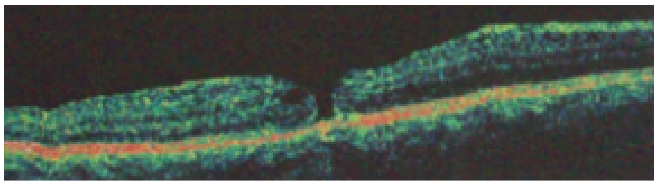


Fig. 16. Macular hole diagnosed at follow-up visit one year after paintball trauma, BCVA 0,6.

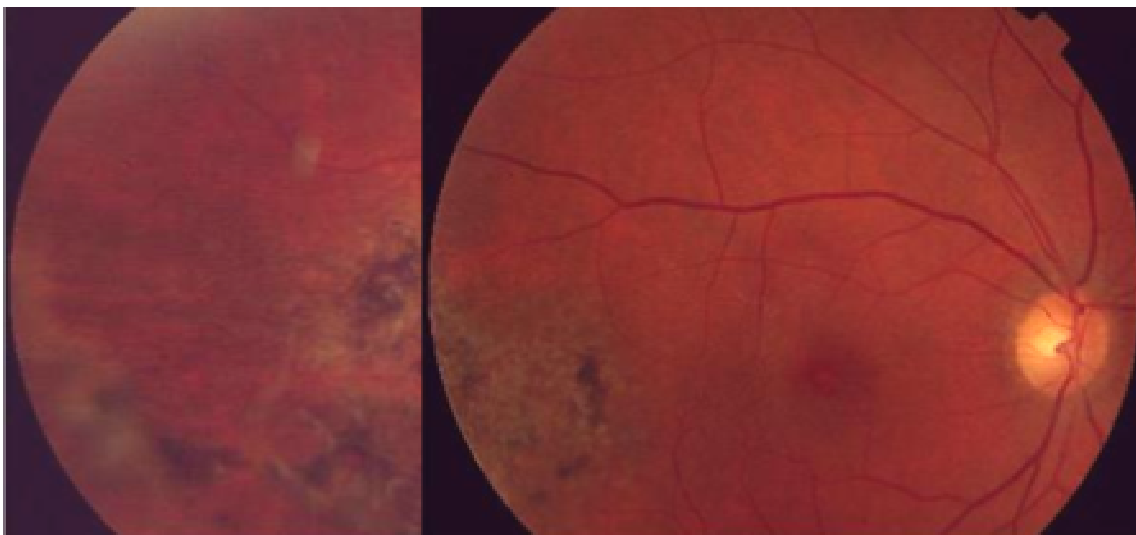


Fig. 17. One year after paintball trauma: macular hole and temporal posttraumatic retinopathy, BCVA 0,6.

Case 5

A 33-year-old man was admitted after occupational trauma by a tow rope. Eye fundus appearance immediately after the accident is shown at Fig. 18. BCVA was of 0,06.

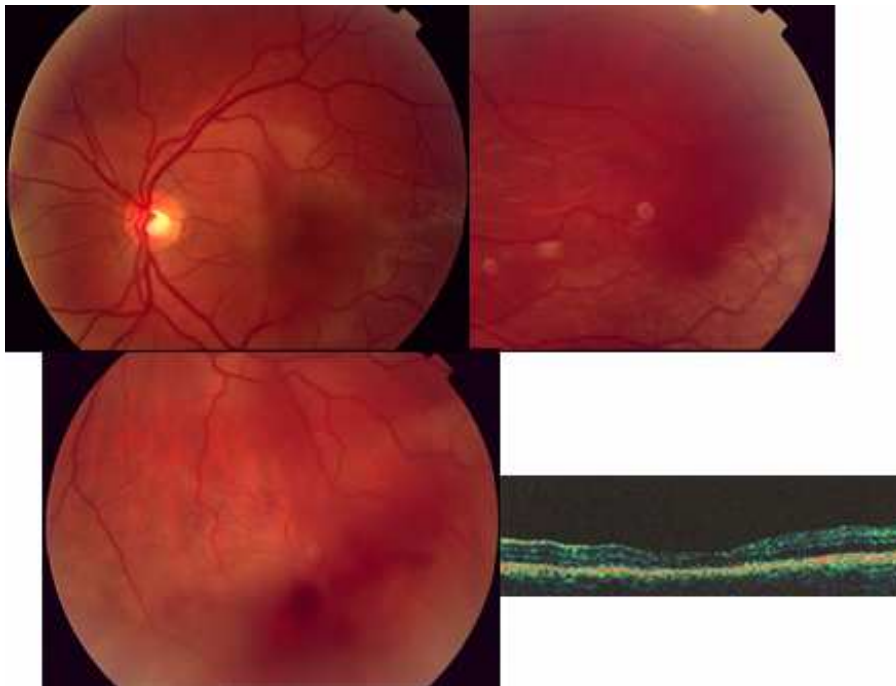


Fig. 18. Central and peripheral commotio retinae, vitreous hemorrhage: eye fundus appearance and macular OCT immediately after occupational trauma by a tow rope, BCVA 0,06.

On third week after the trauma VA remounted to 0,3. Superior retinal detachment was diagnosed and treated with cryoapplication and scleral buckling. Eye fundus photograph and OCT image one year after the trauma are presented in Fig. 19. VA was stable.

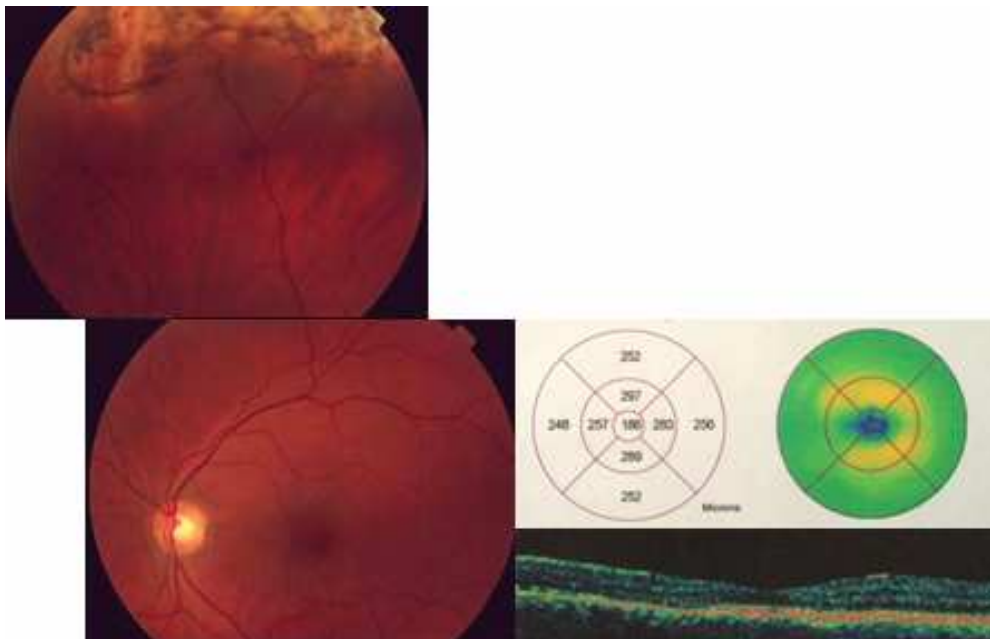


Fig. 19. Eye fundus appearance and macular OCT one year after the occupational accident by a tow rope, BCVA 0,3.

Case 6

A 25-year-old man was struck on his left eye playing football. On the 8th day macular hole was diagnosed after eye fundus examination and confirmed in OCT (Fig. 20). The aspect of macular hole remained unchanged at 2-week after-trauma follow-up visit. The patient demanded macular surgery. Five weeks after the surgery, BCVA remounted to 0,8 and OCT showed the closure of macular hole. Eye fundus aspect was stable during the follow-up (Fig. 21). One year after the trauma BCVA was of 0,6 due to progression of subcapsular cataract.

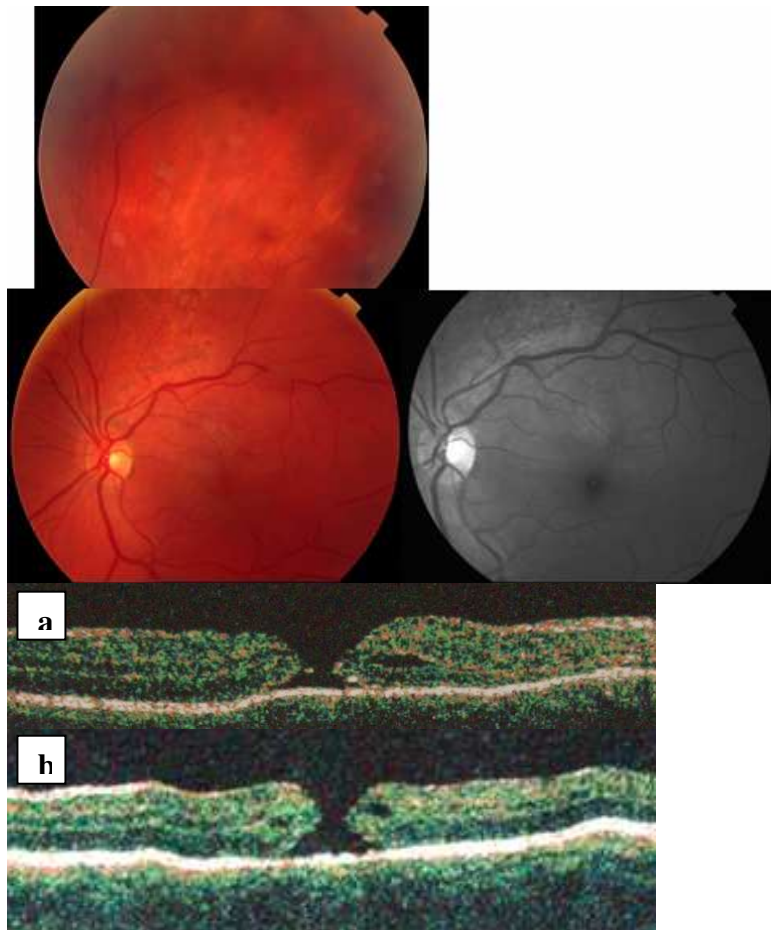


Fig. 20. Eye fundus photograph, blue light image of posterior pole and OCT appearance of macular hole one week (a) and two weeks (b) after the football injury, BCVA 0,1.

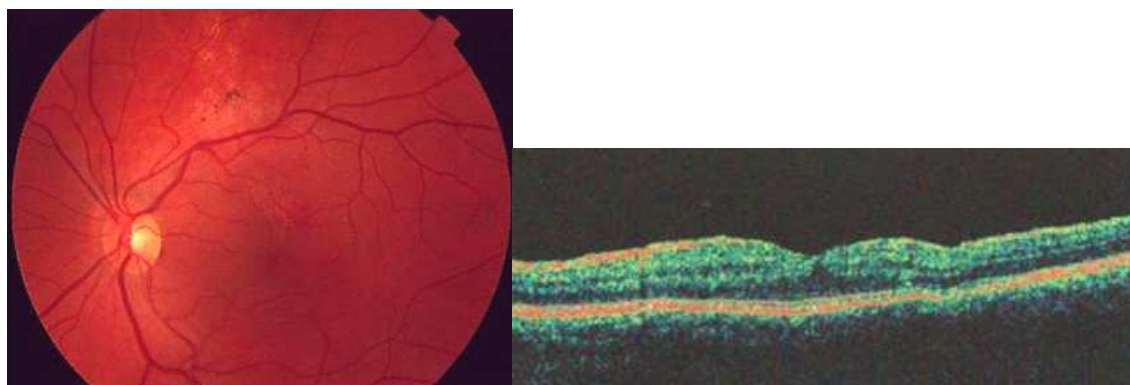


Fig. 21. Eye fundus appearance and macular OCT one year after the injury, BCVA 0,6.

Initially only central retinal damage present

Results of one-year follow-up of patients recruited in Poznań are presented in Table 6.12.

| Case N° | Sex and age | Object | Central retina damage on 1-year follow-up | Retinal periphery damage on 1-year follow-up | Initial BC VA | Retinal treatment | Associated problems | 1 year BC VA |
|---------|-------------|----------------|--|--|---------------|-------------------|---|--------------|
| 2 | M, 32 | buzz saw | Papillary and retinal edema (to 3rd month after trauma) Epimacular membrane | ∅ | 0,06 | ∅ | Traumatic subluxated cataract Ocular hypertonia (7 months) | 1,0 |
| 3 | M, 18 | branch | Pigmented maculopathy | ∅ | 0,06 | ∅ | Posttraumatic glaucoma- Trabeculectomy | 1,0 |
| 6 | M, 25 | motor accident | ∅ | ∅ | 0,2 0,4 | ∅ | ∅ | 1,0 1,0 |
| 7 | F, 55 | dog-lead | Choroidal ruptures Epimacular membrane | Retinal dialysis with retinal detachment (5 th day) | 0,3 | ∅ | Ocular hypertonia | 0,4 |
| 8 | M, 55 | wood piece | ∅ | ∅ | 0,4 | ∅ | ∅ | 1,0 |
| 11 | M, 55 | cockchafer | Bruch's membrane ruptures | ∅ | 0,8 | ∅ | Subluxated lens Traumatic cataract (two times surgery) Macular edema in afakia Ocular hypertonia | 0,8 |
| 16 | F, 45 | child's heel | ∅ | ∅ | 1,0 | ∅ | ∅ | 1,0 |

Table 6.12. One year follow-up examinations of patients from Poznań with initially only central retinal damage.

Case 2

A 32-year old man was struck on his right eye by a buzz saw. On admission BCVA was of 0,06 The posttraumatic cataract and retinal and papillary edema were diagnosed (Fig. 22). Systemic corticosteroids were introduced.

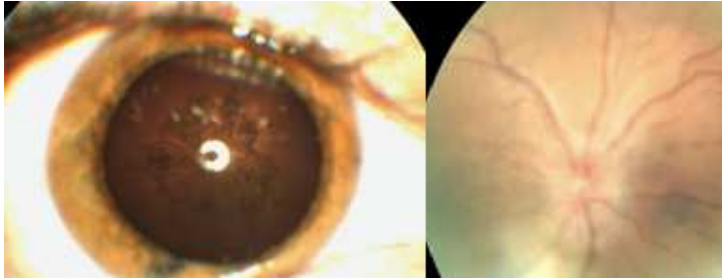


Fig. 22. Post-traumatic cataract and papillary and retinal edema after a buzz saw injury, BCVA 0,06.

2,5 months after the trauma the subluxated lens with posttraumatic cataract was extracted. Papillary and retinal edema were always present (Fig. 23).

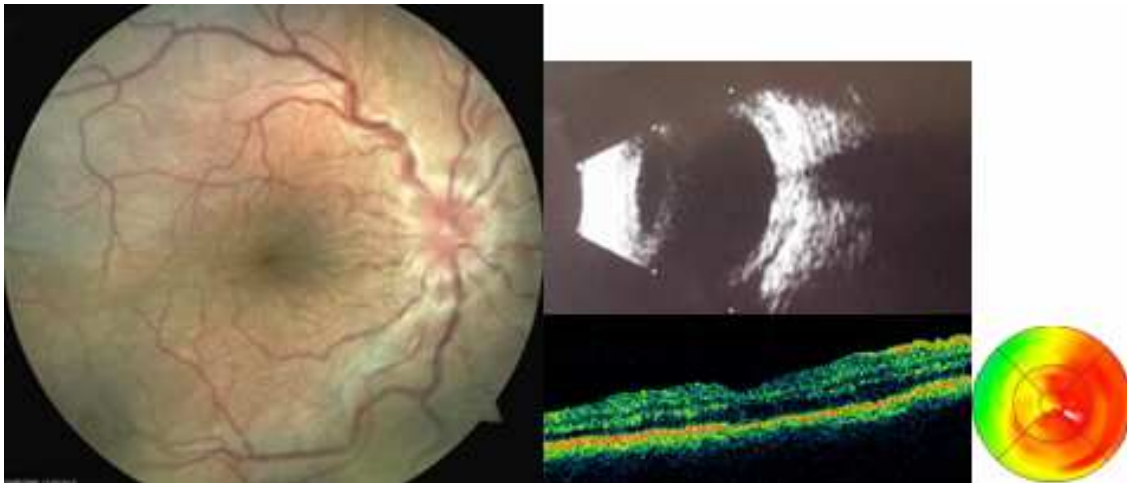


Fig. 23. Papillary and retinal edema: eye fundus, ultrasonography image (C12, 70 dB) and macular OCT 2,5 months after a buzz saw injury, BCVA 0,1.

The second course of oral corticotherapy resulted in amelioration of VA to 1,0 in one month. The formation of epimacular membrane was diagnosed (Fig. 24). BCVA remained stable.

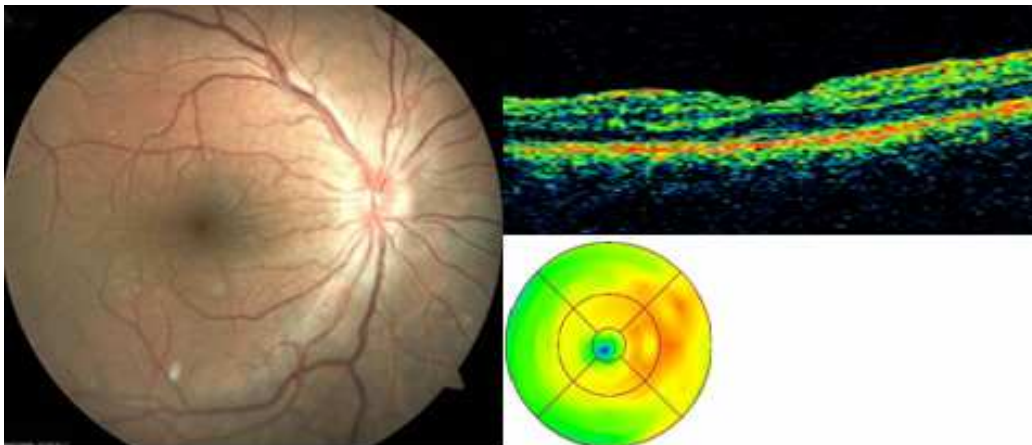


Fig. 24. Eye fundus and macular OCT 3,5 months after a buzz saw injury, BCVA 1,0.

Case 7

A 56-year old woman was hit by a dog-lead. Fig. 25 shows the aspect of eye fundus after one month.

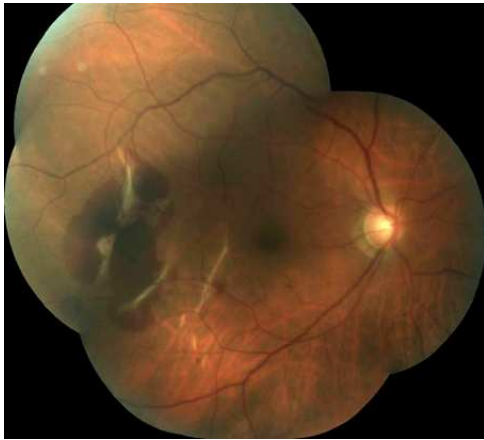


Fig. 25. Indirect choroidal ruptures and retinal hemorrhage: eye fundus one month after a dog-lead injury, BCVA 0,3.

The aspect of eye fundus as well as macular OCT and retinal angiography after six months are shown in Fig. 26.

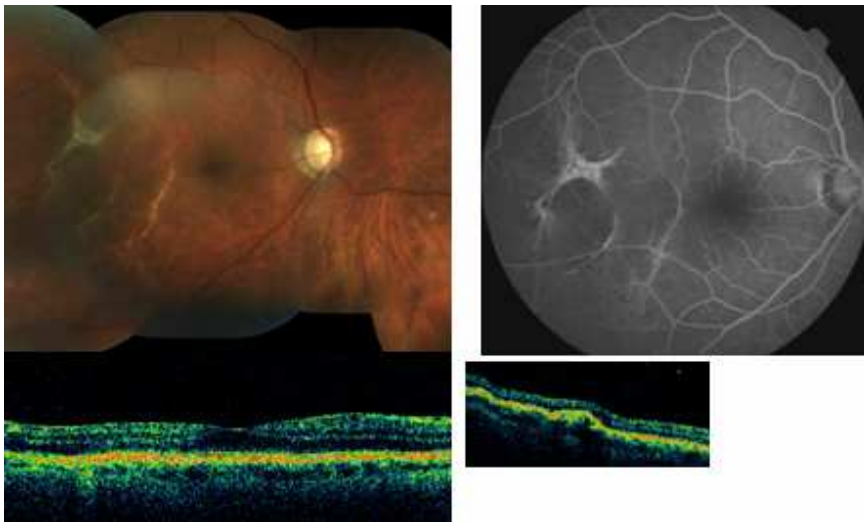


Fig. 26. Indirect choroidal ruptures: eye fundus, OCT and AF six months after a dog-lead injury, BCVA 0,4.

On the 5th day after the trauma retinal dialysis at inferior temporal quadrant was diagnosed (Fig. 27). Encirclement with cryoapplication were successful. In the posterior pole the formation of epimacular membrane was stated on one year follow-up.

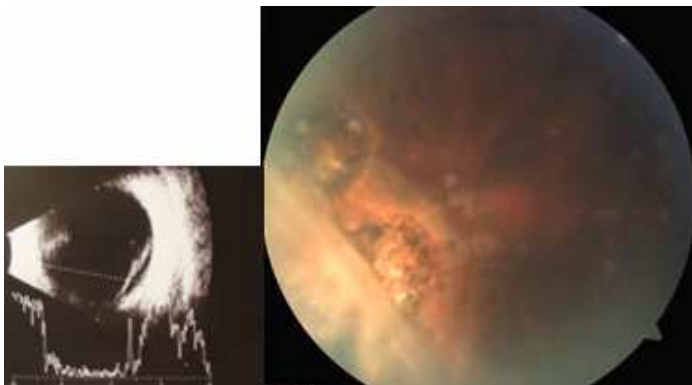


Fig. 27. Traumatic retinal dialysis: 5th day after the trauma (usg) and six months after external surgery.

Case 11

A 55-year old man was struck on his right eye by a cockchafer while riding a bike. Lens subluxation and two retinal hemorrhages were stated on admission (Fig. 28). After one month two Bruch's membrane ruptures appeared at the place of hemorrhages (Fig. 29). Posterior segment image remained stable during one-year follow-up. The surgery of subluxated lens was performed in two times. Ocular hypertonia required medical treatment. Secondary to temporary afakia and diagnosed diabetes, cystoid macular edema appeared resulting in VA of 0,8 one year after the trauma.

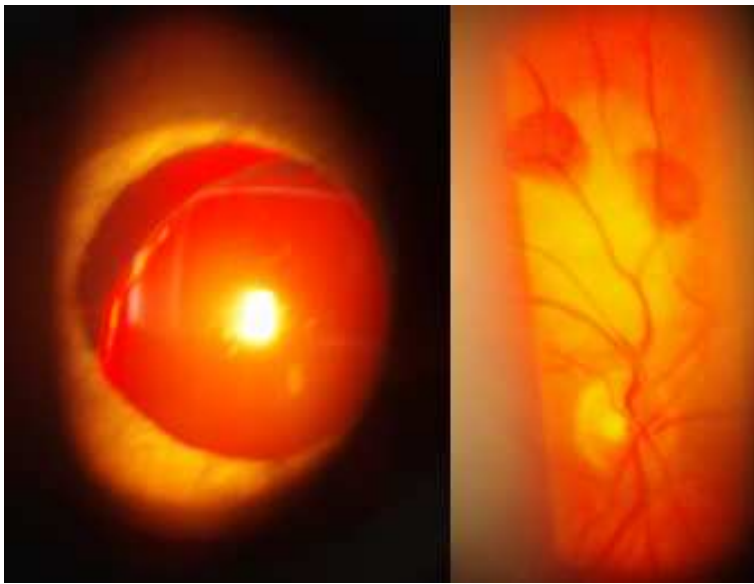


Fig. 28. Lens subluxation and two retinal hemorrhages after collision with a cockchafer, BCVA 0,8.

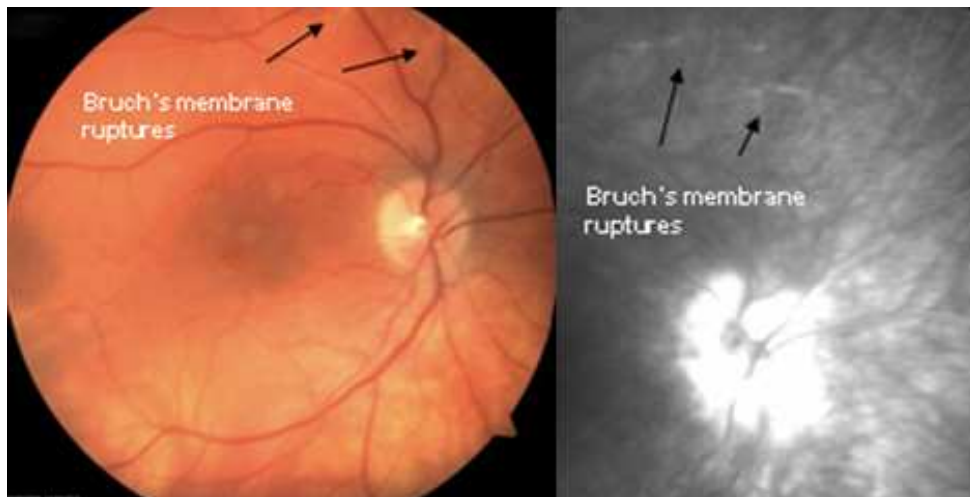


Fig. 29. Bruch's membrane ruptures: eye fundus aspect and retinal angiography one year after the injury, BCVA 0,8.

In the case of three patients from Rennes with initially diagnosed only central retinal damage, follow-up visits did not reveal posttraumatic lesions or associated problems (Table 6.13.).

In all these cases visual acuity one year after the trauma was of 1,0.

| Case N° | Sex and age | Object | Central retina damage on 1-year follow-up | Retinal periphery damage on 1-year follow-up | Initial BC VA | Retinal treatment | Associated problems | 1 year BC VA |
|---------|-------------|---------------|---|--|---------------|-------------------|---------------------|--------------|
| 8 | F, 47 | fist | ∅ | ∅ | 0,2 | ∅ | ∅ | 1,0 |
| 9 | F, 39 | egg | ∅ | ∅ | 0,8 | ∅ | ∅ | 1,0 |
| 13 | F, 52 | bike accident | ∅ | ∅ | 1,0 | ∅ | ∅ | 1,0 |

Table 6.13. One year follow-up examinations of patients from Rennes with initially only central retinal damage.

Initially only peripheral damage present

All patients from Poznań with initially diagnosed only peripheral damage had a posttraumatic VA of 1,0 (Table 6.14). At the 3rd week follow-up visit one patient was found to have a small, round retinal hole with enrolled borders. The prophylaxis with laser was performed. The further history was without complication.

| Case N° | Sex and age | Object | Central retina damage on 1-year follow-up | Retinal periphery damage on 1-year follow-up | Initial BC VA | Retinal treatment | Associated problems | 1 year BC VA |
|---------|-------------|----------------|---|--|---------------|-------------------|---------------------|--------------|
| 13 | M, 50 | wood piece | ∅ | ∅ | 1,0 | ∅ | ∅ | 1,0 |
| 15 | F, 50 | clothes hanger | ∅ | ∅ | 1,0 | ∅ | ∅ | 1,0 |
| 18 | M, 58 | wood piece | ∅ | ∅ | 1,0 | ∅ | ∅ | 1,0 |
| 19 | M, 30 | electric cable | ∅ | Retinal hole (3rd week) | 1,0 | Laser (3rd week) | ∅ | 1,0 |

Table 6.14. One year follow-up examinations of patients from Poznań with initially only peripheral retinal damage.

Case 18

A 50-year old man received a wood piece in his right eye while chopping. BCVA equaled 1,0. Peripheral commotio retinae and vitreous base avulsion were observed on admission (Fig. 30). The follow-up was unremarkable.

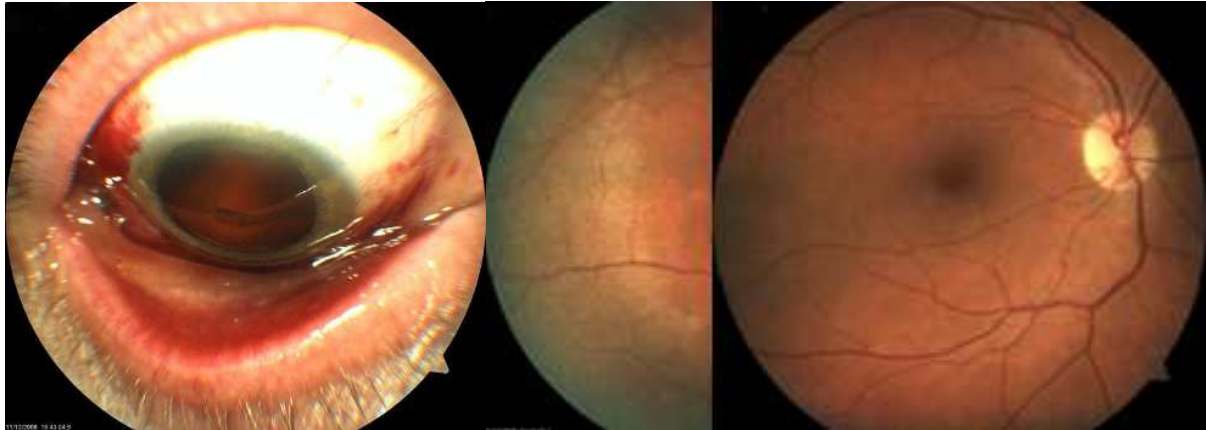


Fig. 30. Vitreous base avulsion and peripheral commotio retinae after wood piece injury, BCVA 1,0.

The initial posttraumatic visual acuity in patients with initially diagnosed only peripheral damage in Rennes was also 1,0 (Table 6.15). At the 3rd-week follow-up two from three patients were found to have peripheral sequelles. In the first case, it was a small, round retinal break with a persistent vitreo-retinal traction in a 15-year-old girl. The trail of slit-lamp laser prophylaxis was not successful due to patient's pain. Laser barrage using binocular ophthalmoscopy and under general anesthesia was performed. The further history was without complication. The second case is described below (Case 15).

| Case N° | Sex and age | Object | Central retina damage on 1-year follow-up | Retinal periphery damage on 1-year follow-up | Initial BC VA | Retinal treatment | Associated problems | 1 year BC VA |
|---------|-------------|-----------|---|---|---------------|---|---------------------|--------------|
| 11 | F, 15 | badminton | Ø | Operculated retinal tear (3 rd week) | 1,0 | Laser (binocular ophthalmoscopy) (4 th week) | Ø | 1,0 |
| 12 | M, 23 | fist | Ø | Ø | 1,0 | Ø | Ø | 1,0 |
| 15 | M, 25 | branch | Ø | Choroido-retinal rupture (sclopetaria) | 1,0 | Laser (8 th week) | Ø | 1,0 |

Table 6.15. One year follow-up examinations of patients from Rennes with initially only peripheral retinal damage.

Case 15

A 25-year-old man was struck on his left eye by a branch during hunting. Peripheral choroido-retinal rupture (sclopetaria) was diagnosed (Fig. 31). Three weeks after the trauma the decision to make laser preventive treatment of the area was made. There were no further eye problems.

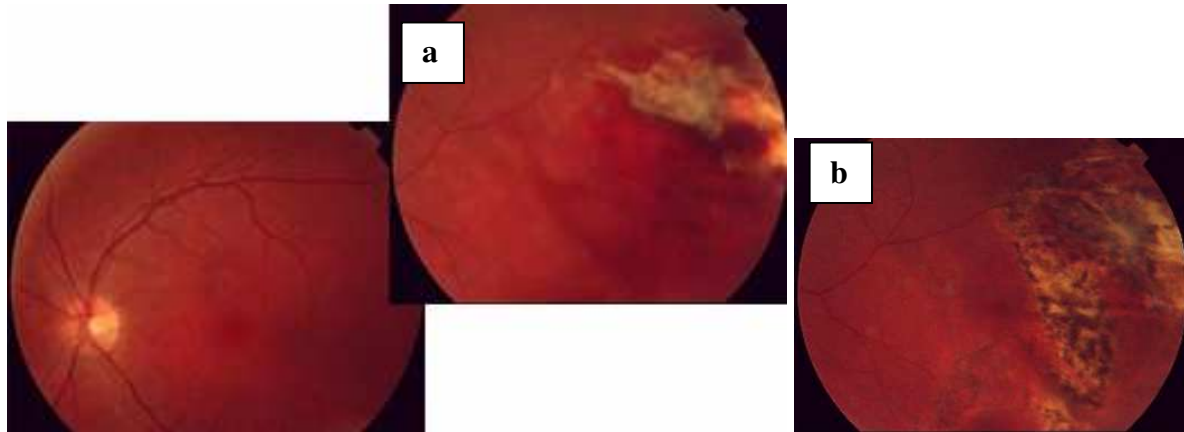


Fig. 31. Peripheral choroido-retinal rupture (sclopetaria) 1 week after a branch trauma (a) and three weeks after laser barrage (b), BCVA 1,0.

Delayed hospitalizations and retinal treatment

Out of 8 patients hospitalized immediately in Poznań, there were 3 cases that required re-hospitalization during the following year: for sub-luxated post-traumatic cataract extraction (Cases: 2 and 11) and for trabeculectomy (Case 3). One patient, followed initially as an outpatient, was admitted three weeks after the trauma and one week after retinal breaks laser barrage because of retinal detachment. External surgery was performed. Unfortunately, the re-application was not obtained due to PVR and vitrectomy followed on the 7th week after the injury.

In Rennes, 2 out of 6 patients admitted immediately, were re-hospitalized for vitrectomy (Cases: 1, 3). Three patients treated initially as outpatients, were hospitalized later: one for surgery of macular hole (Case 6), one for external surgery of retinal detachment (Case 5) and one to perform laser barrage under general anesthesia (Case 11).

Table 6.16 shows a summary of performed laser prophylaxis of retinal detachment and retinal surgery with average interval after eye trauma.

| | Poznań | Rennes |
|---|---|---|
| Laser photocoagulation Average interval after trauma | 2/20 (10%) 15 days | 3/15 (20%) 30 days |
| Retinal surgery Average interval after trauma | 2/20 (10%) 16 days | 4/15 (27%) 23 days |
| Cryo+ scleral buckling Cryo+ encirclement Pars plana vitrectomy | 2/2 (retinal detachment) 1/2 (persistent retinal detachment) | 1/4 (retinal detachment) 3/4 1/3 (macular hole) 2/3 (persistent vitreous hemorrhage) |

Table 6.16. Summary of performed laser prophylaxis of retinal detachment or retinal surgery with average interval after eye trauma.

6.4.3. One year visual acuity evolution

The median of BCVA expressed in logMAR units remounted in Poznań from 0,2 on initial examination (corresponding to 0,63 in decimal chart) to 0 after one year (VA of 1,0), $p = 0,0033$. In Rennes, the median of BCVA remounted from logMAR 0,7 (VA of 0,2) to 0 (VA of 1,0) after one year ($p = 0,0152$). There was no statistical difference between two centers of recruitment.

Visual acuity evolution in two groups of BCVA distinguished on initial examination

The statistically significant increase of BCVA was noted in the group of initial BCVA $<0,5$ in both centers. From total of 17 patients of this group, after one year, 11 passed into the group of VA $\geq 0,5$, whereas all patients with initial BCVA $\geq 0,5$ remained in this group ($p=0,0025$). The number of patients in two groups of BCVA on initial and final examinations are presented in Table 6.17.

| | BCVA | <0,5 | ≥0,5 |
|---------------|----------------|--------------------|--------------------|
| Poznań | Initial | 9/20 (45%) | 11/20 (55%) |
| | Final | 3/20 (15%) | 17/20 (85%) |
| Rennes | Initial | 8/15 (53%) | 7/15 (47%) |
| | Final | 3/15 (20%) | 12/15 (80%) |
| Total | Initial | 17/35 (49%) | 18/35 (51%) |
| | Final | 6/35 (17%) | 29/35 (83%) |

Table 6.17. Groups of BCVA on initial and final examinations.

One year retinal sequelae

Retinal damage were present in 13 from 17 eyes (76%) of the group of initial BCVA <0,5. Conversely, 14 from 18 eyes (78 %) from the group of BCVA ≥0,5 had no retinal sequelae one year after the trauma. The difference was statistically significant (p= 0,0002).

On one year follow-up there were six eyes with final BCVA <0,5 (35 % of these with permanent retinal lesions), p= 0,0001.

60 % of patients from Poznań and 40 % from Rennes had no retinal lesions on one year follow-up (Table 6.18.). There was no statistical significance between two centers (p>0,05).

| | No sequelae | Sequelae with normal VA | Sequelae with decreased VA |
|---------------|-----------------|-------------------------|----------------------------|
| Poznań | 12 (60%) | 5 (25%) | 3 (15%) |
| Rennes | 6 (40%) | 3 (20%) | 6 (40%) |
| Total | 18 (51%) | 8 (23%) | 9 (26%) |

Table 6.18. Presence of retinal sequelae one year after the trauma.

Associated ophthalmologic problems

In 7 of 20 eyes in Poznań (35 %) and 5 of 15 in Rennes (33 %) associated ophthalmologic problems were observed during one year follow-up ($p>0,05$). The most frequent were posttraumatic cataract, ocular hypertonia and posttraumatic glaucoma. Other included need of visual reeducation in 7-year-old boy and orbital neuralgia after paint-ball injury. The presence of associated ophthalmologic problems was not associated to the initial BCVA group ($p>0,05$).

7.0. DISCUSSION

7.1. Study value

Although multiple analysis on ocular trauma and open-globe injuries were done, closed-globe trauma studies are less frequent, especially retrospective and focused on particular characteristics or clinical forms. Potentially blinding posterior segment manifestations of blunt ocular trauma, are usually presented as case reports [17, 28, 30, 68, 71, 92, 95].

In the context of potential severe consequences of ocular contusions and possible prevention or in some cases, prognosis amelioration by early diagnosis and treatment, the determination of risk population, occupations and damage characteristics appears to be fundamental.

This study attempts to analyze the full breadth of retinal contusions as well as its clinical evolution on one year period. After the initial diagnosis, the patient was followed by the same physician. In selected cases, the evolution was documented with imaging examinations. The collection of eye fundus photographs, OCT, ultrasonographic and fluorescein angiography images of different retinal contusions and their evolution during one year follow-up results. Worth of emphasizing is the fact that patients were recruited in two centers: Polish and French, differing in system of eye emergency organization. Poznań District Hospital is one of three hospitals in Poznań providing ophthalmologic emergency care for adult patients during 24 hours seven days per week. The separate children hospital with ophthalmologic hospitalization unit worked in Poznań during the study period.

The Pontchaillou Hospital of Rennes assures ophthalmologic emergency from 9 a.m. to 17 p.m. Beyond these hours and at weekends general emergency ensures first ophthalmologic care, calling ophthalmologist only when necessary.

7.2. Study limitations

The main limitation of the study is a small size of patients group. However, we selected the particular but heterogeneous form of ocular trauma. Furthermore, retinal contusions appear to be not so frequent in the total number of ocular trauma. Given these conditions, elaborated statistical analysis was not our aim. We concentrated on clinical analysis and recognition of major differential characteristics of retinal contusions in two groups of visual acuity and two centers of recruitment.

In addition, patients with ocular trauma resulting multi-organ injuries are underrepresented. In Poznań, it is also the case of pediatric injuries. During the period of the study, the majority of children were consulted by the pediatric hospital.

7.3. Comparison of study results with results of literature

Demographic characteristics of our patients with retinal post-traumatic damage corresponds to that observed in other trauma studies [98, 121, 129]. The male-to-female ratio are similar in two centers of recruitment and comparative to the literature. Dasai emphasizes that in the age group 15-64 which is at the highest risk of severe ocular trauma in his study and corresponds to our series, males and females differ in their daily work, leisure and domestic activities while each of the related environments have their own inherent factors for eye injury [29].

The general tendency for ocular injury to occur at a younger age in men than in women [20, 129] was also observed in our study focused on blunt ocular trauma. Young males dominated in our two centers of recruitment, however, in Poznań the number of male patients over 40 was significantly higher and two peaks in age distribution were noted. This may reflect life style differences in two countries resulting in the context of the injury.

Interestingly, in Poznań retinal trauma were due in majority of cases to everyday activity, domestic work included. Chopping, responsible for 4 cases of retinal contusions in our study, is popular among men, especially over 40. In contrast, we found that in Rennes, the major context of eye injury resulting in retinal trauma, was sport (6 cases). These injuries occurred especially in young men and were due to projectile contact (ball or shuttlecock) during badminton, football, squash and tennis. In one case, the stick trauma was the reason (hockey). Worth of emphasizing is that in our study only one case of retinal damage occurred at work place (trauma by a tow rope).

Work activity is the most common reason of ocular trauma while regarding open and close-globe injuries together and attends 70% in Schein and 69,9% in Macewen studies [129, 98]. In Schein study only 3,4 % of all injuries were sport-related but responsible for more serious damage. Macewen reported 18,3 % of injuries occurred during domestic activities, 2,3 % during sports and 1,9 % due to assault. In addition, sport and assault were more frequently responsible for close-globe injuries and posterior segment damage [99]. It was shown that in sport- related injuries the most frequent reason is a blow from a ball, followed by racquet, fist or elbow contact [87, 99, 100]. Cultural and geographic conditioning for ocular sport trauma was reported by previous studies (football in Britain, hurling in West

Ireland, basketball in USA, badminton in South-East Asia [99, 87, 94,14]. With increasing importance of health life style and free time occupation in adults and children, sport and derivative leisure become more popular and injuries more frequent [63]. It is also the case of spectacularly increasing in popularity modern sports, like: squash, intramural soccer and leisure, like: bungee jumping or paintball [13, 74]. In this context, the issue is likely to become more pertinent in the future in Poland due to an increase of sport practice. The need for development of eye trauma prevention strategy is obvious. The correct information is the first step. In our series, none of patient had ocular protection during direct eye injury. All trauma during paint-ball and the trauma due to hockey stick, occurred when patients removed eye-protective device. This context was responsible for 86% to 100 % of trauma in paintball injuries analysis [3, 41, 138].

Organization system of eye emergency in Poznań, similar to other Polish big cities, ensures direct consultations to all patients [22]. The higher number of patients per physician, greater number of conditions non requiring urgent help and the need for complete examination, in majority of cases, are results. Ocular adnexia diseases and less severe ocular injuries predominate. MacEwen reported that 98,3 % of all injuries involved periorbital or superficial structures only, whereas Schein noted 94,9 % of less severe traumatic eye damage [98, 129]. The system accepted in CHU of Rennes was designed to reduce costs of specialist consultations and assure patients selection. The delay to the ophthalmologic consultation in our series with diagnosed posterior segment damage, tended to be longer in Rennes. However, the absence of immediate ocular hazard (47 % with VA of 5/10) may be the reason.

Furthermore, in the case of retinal contusions, if the ophthalmologic consultation takes place in first days after the trauma, the exact time to that seems to be not so important [94]. The value of the initial examination must be highlighted. Difficult, because of patient's pain, fear and associated traumatic damage, it permits to evaluate VA, injury extent and has a prognostic value [100]. It is worth of reminding, that patients presenting only with superficial injury of ocular adnexia or anterior segment, may disclose damage on eye fundus which was confirmed in our and other studies [94, 18].

Injuries involving both central and peripheral retina dominated in Rennes. The initial VA was significantly lower in this group of patients comparing with the same group of damage extent in Poznań. This can be explained by more severe sport- and modern leisure-related injuries, dominating in this group. The participation of emergency patients selection is also possible.

Controversy surrounds the question of systemic treatment or laser prophylactic treatment of retinal lesions. The efficiency of glucocorticosteroids and vasodilators used in objective to combat edema, arteriolar constriction and reduce risk of potential evolution to macular hole in commotio retinae is not proved [45]. Lack of standardization, their use depends on individual judgement on a case-by-case basis and own experience. It is also the case of laser prophylactic treatment. Because of the small sample size and different types of retinal lesions in our study, we cannot make recommendations regarding systemic or prophylactic treatment. Primary hospitalization indications included in our study: systematic observation of the patient, especially if injuries of the anterior segment coexisted, conjunctival injury exploration and surgical repair of canalicular wound. It corresponds to Eagling series of patients after blunt trauma [37]. Similarly to other studies, hyphema was the most common serious anterior segment damage after blunt injury [14, 20, 37, 94]. It is noteworthy that only in one case, during the primary hospitalization the surgical treatment of post-traumatic retinal damage was performed. It was in the case of retinal detachment by dialysis, diagnosed on the fifth day after the injury, during hospitalization in Poznań and operated on by encirclement on the sixth day.

Classic laboratory experiments of Weidenthal and Deliori show that retinal breaks form at the time of ocular impact [26, 144]. Delayed hole formation can occur due to impact site retinal necrosis [23]. The associated retinal detachment may develop immediately (feature of necrotic retinal breaks which predominated in Johnston series of traumatic retinal detachment, diagnosed within 24 hours) or years after the trauma (especially retinal dialyses, the unique cause of retinal detachments diagnosed more than six weeks after the trauma in the same study) [78]. In Ross study of 34 cases of retinal detachment caused by traumatic retinal dialysis and resulting in majority of cases from assaults and sports, only 18 % were diagnosed within 1 month after the trauma [127]. In 41% the diagnosis was made between one month and one year whereas another 41% were diagnosed more than one year after the injury. Three reasons of the delay in diagnosis of traumatic retinal detachment were found. First, the fact that in many cases, the initial trauma was ignored. Second, even if patients consulted the ophthalmologist soon after the trauma, the presence of vitreous hemorrhage, hyphema and ocular discomfort prevented immediate examination of the peripheral retina. Third, some of patients consulted only if symptoms of retinal detachment appeared. This highlights the importance of peripheral retina examination soon after the trauma even if patients are asymptomatic. It emphasized also the fact that if the visualization of peripheral retina is not

possible, patients should be reexamined until the diagnosis of retinal break has been ruled out [78, 128].

However, only few studies on prospective basis included the problem of follow-up after a close-globe, blunt trauma. Tasman followed 52 patients after ocular contusion for a period of two years [139]. Retinal dialysis was diagnosed in nine patients within three weeks of injury, whereas in one patient a dialysis was found four months after the injury, when vitreous hemorrhage cleared. There was no other case of retinal dialysis seen to occur over the ensuing two-year follow-up. Holmes Sellors and Mooney in their study concerning fundus changes after traumatic hyphema, found retinal abnormalities in 17 from 52 patients during a 3-year period [70]. They postulated that more extensive examination of eye fundus may be deferred until a month after the injury, when retinal changes if occurred, will be visible. They believed that patients without retinal pathology at this time, do not require repeated re-examinations. Three follow-up examinations were projected in Eagling study: on the 4th day, 6th week and 6th month after the blunt trauma to the eye [37]. 12 of 30 patients with initially diagnosed posterior pole damage, presented permanent macular damage on 6th month examination. Two of them were blind: one due to optic nerve avulsion, the second from massive choroidal haematoma, related to multiple choroidal ruptures. In 37 patients permanent scarring to the peripheral retina was noted. In 7 cases closer follow-up was necessary: five retinal dialysis, one large round hole and one case of multiple retinal tears were found from 2 to 5 weeks after the injury. All of peripheral damage were directly related to the site of the impact and in the majority of cases anterior segment involvement was minimal. Few studies reported only follow-up telephone interviews on sequelae of eye injury between 3 and 18 months after the trauma [94, 129]. Many patients were lost to long-term follow-up, presumably due to young age and great mobility, return of normal vision and absence of ocular symptoms [94].

In our study, we decided to make follow-up visits with frequency depending on initial VA (reported to have prognostic value in general ocular trauma classifications) and damage extent. In all cases, the adaptation of follow-up visits to the peripheral retina visualization was done. Our results suggest that initial BCVA and damage extent are predictors of final BCVA. In all cases of isolated peripheral retinal damage at initial examination, control visits are necessary to rule out the presence of retinal break or detachment which is usually possible in the first month after the trauma. The presence of central retinal post-traumatic sequelae

impose more frequent, prolonged follow-up and repeated imaging examinations because of the risk of retarded complications, as observed in our study (macular atrophy, hole, membrane). The patient must be aware of possible vision consequences and follow-up necessity after the ocular trauma even if asymptomatic.

As in previous studies, the dominating finding on eye fundus during the initial examination, was commotio retinae (91 % of total) [37,70]. Only in 12 cases (34 %), it was the unique type of damage. In remaining cases, commotio retinae was accompanied by choroidal ruptures, RPE changes, retinal and vitreous hemorrhages, papilar edema, vitreous base avulsion and macular hematoma. In eight cases from twelve in both centers (67% of total), there was no complications of isolated commotio retinae.

One-year central sequelae of blunt eye injury were present in 12 of 35 eyes (34%) in both centers and included: pigmented maculopathy, macular atrophy, epimacular membranes, indirect choroidal ruptures, ruptures of Bruch's membrane, late macular hole (diagnosed on one year follow-up visit) and optic neuropathy confirmed by VEP examination. In the last case, the patient became blind due to ocular contusion. All of these patients require further observation and need complex follow-up with imaging methods.

Three patients in Poznań were diagnosed to have retinal breaks during follow-up. There was one case of retinal dialysis diagnosed on 5th day and described above. In the second case, multiple tears on one quadrant were diagnosed on 8th day after the trauma by football. The laser prophylaxis was not successful and retinal detachment was qualified to external surgery. The anatomical success was obtained only after vitrectomy but VA remained at 0,1. The third patient, initially presenting an isolated peripheral commotio retinae, was diagnosed to have retinal hole on 3rd week after the trauma with electric cable. Laser prophylaxis was done and there was no other complications. In Rennes, peripheral operculated tear was found in one case (3rd week follow-up visit) and peripheral retinal elevation without break in the other one (1st week follow-up visit). Both cases resulted from badminton injury. One case of retinal detachment with no break found, was diagnosed on 3rd week follow-up visit after painter injury and treated successfully with cryotherapy and scleral buckling on 6th week.

In both centers all retinal breaks or retinal elevations (no break found) were diagnosed until 3rd week after the trauma. During one-year follow-up there was no other break seen to occur which corresponds to Tasman results and highlights the importance of careful retinal periphery examination in the first month after the injury [139].

Other one-year peripheral sequelae of blunt eye injury were found in five patients in both centers and included: direct choroidal ruptures, choroido-retinal rupture (sclopetaria), posttraumatic retinoschisis and posttraumatic retinopathy.

Even if it is encouraging that 83 % of our patients had BCVA of 0,5 or better one year after the trauma, it is also true that 49 % had permanent eye fundus damage and there was one case of no light perception. Considering the context of eye blunt trauma, the information on ocular trauma risks, suitable eye protection and appropriate follow-up are always needed.

8.0 CONCLUSIONS

1. Results of this study show that retinal contusive damage, as other eye trauma, dominate in men. The number of male patients over 40 seems to be higher in Poznań. Everyday activities appear to be the most common cause of retinal contusions in Poznań, whereas sport in Rennes.
2. Commotio retinae is the most frequent closed-globe blunt traumatic damage diagnosed at initial examination but it seems to be the unique type of lesion only in one third of cases. In Rennes retinal contusive damage seems to be more severe regarding BCVA and lesions extent.
3. The presence of retinal damage should be ruled out after each ocular contusion. Careful retinal periphery re-examination in the first month after the injury should be performed in all cases of initial retinal damage.
4. The presence of central retinal post-traumatic sequellae impose more frequent, prolonged follow-up and repeated imaging examinations because of the risk of retarded complications.
5. Initial post-traumatic visual acuity and damage extent have a prognostic value and related to a possibility of retinal visualization may help to adapt a follow-up strategy.

The information on ocular trauma risks and use of eye protection during sport, leisure and domestic activities should be enhanced to reduce the incidence and severity of ocular trauma.

BIBLIOGRAPHY

1. Adams C.B.T. The retinal manifestations of fat embolism. *Injury* 1971; 2: 221-224.
2. Aguilar J.P., Green W.R.: Choroidal Rupture: a histopathologic study of 47 eyes, *Retina*, 1984; 4 (4): 269-75.
3. Allimana K.J. et al. Ocular trauma and visual outcome secondary to paintball projectiles. *Am J Ophthalmol.* 2009 Feb; 147: 239-242.
4. Anderou P. et al.: A case of traumatic retinal avulsion at the optic nerve head, *Br J Ophthalmol*, 1996; 80: 575-576.
5. Bailliart P. Les maladies de la rétine In : Bailliart P. et al. : *Traité d'ophtalmologie*, Société Française d'Ophtalmologie, Masson, Paris, 1939 : 239-270.
6. Blake J. Ocular embolism . *Trans Ophthalmol Soc UK* 1975; 95: 88-93.
7. Blight R., Hart JCD. Structural changes in the outer retinal layer following blunt mechanical non-perforating trauma to the globe: An experimental study. *Br J Ophthalmol*, 1977; 61: 573-87.
8. Bloome M.A., Ruiz R.S., Russo C.E. Acute retinal necrosis. *Ann Ophthalmol*, 1979; 11: 723-728.
9. Brasseur G. Examen du vitré. Examen clinique. In: *Pathologie du vitré*, Brasseur G., Masson, 2003: 32-44.
10. Burton T.C. Unilateral Purtscher's retinopathy. *Ophthalmology* 1980; 87: 1096-1105.
11. Busacca A., Goldmann H., Schiff-Wertheimer S. Historique. *Biomicroscopie du corps vitré et du fond d'oeil*. Société Française d'Ophtalmologie, Masson, Paris, 1957 : 5-14.
12. Canavan Y.M. et al.: A 10-year survey of eye injuries in Northern Ireland 1967-1976. *Br J Ophthalmol* 1980; 64: 618-625.
13. Capão Filipe J. A. et al.: Modern sports eye injuries. *Br J Ophthalmol* 2003; 87: 1336-1339.
14. Chandran S. Ocular hazards of playing badminton. *Br J Ophthalmol* 1974; 58: 757-760.
15. Chaudhry I.A. et al.: Optic nerve avulsion from door-handle trauma in children. *Br J Ophthalmol.* 2006; 90:844-846.
16. Chen J., Flannery J.: Structure and function of rod photoreceptors. In: *Retina*, Ryan S.J., Mosby, 2001: 122-127.
17. Chow D.R. et al.: Successful closure of traumatic macular holes, *Retina* 1999; 19: 405-409.

18. Chow A.Y. Evulsion of optic nerve in association with basketball injuries. *Ann Ophthalmol.* 1984;16: 35-37.
19. Chuang E.L. et al.: Retinal lesions following long bone fractures. *Ophthalmology* 1985; 92: 370-374.
20. Cillino S. et al.: A five-year retrospective study of the epidemiological characteristics and visual outcomes of patients hospitalized for ocular trauma in a Mediterranean area. *BMC Ophthalmology* 2008; 8: 6.
21. Cirovic S et al.: Computer modelling study of the mechanism of optic nerve injury in blunt trauma. *Br J Ophthalmol.* 2006; 90: 778-783.
22. Ciszewska J. et al.: Retrospektywna analiza zgłoszeń na ostry dyżur okulistyczny. *Okulistyka* 2003; 4: 3-8.
23. Cox M.S. Retinal breaks caused by blunt nonperforating trauma at the point of impact. *Trans Am Ophthalmol Soc* 1980; 78: 414-466.
24. Cox M.S., Schepens C.L., Freeman H.M. Retinal detachment due to ocular contusion, *Arch of Ophthalmol*, 1966; 76: 678-685.
25. de la Hire. Explication de quelques faits d'optique et de la manière dont se fait la vision. *Hist.Acad.R. Sci.*, Mar. 30, 1709: 95-106.
26. Delori F, Pomerantzeff O., Cox M.: Deformation of the globe under high-speed impact, Its relation to contusion injuries, *Invest Ophtahl*, 1969; 8: 290- 301.
27. De Maeyer K. et al.: Sub-inner limiting membrane haemorrhage : causes and treatment with vitrectomy. *Br J Ophthalmol.* 2007; 91: 869-872.
28. Denion E. et al.: Avulsion du nerf optique : à propos d'un cas. *J Fr. Ophtalmol*, 2007; 30, e23.
29. Desai P. et al.: Incidence of cases of ocular trauma admitted to hospital and incidence of blinding outcome. *Br J Ophthalmol* 1996; 80: 592-596.
30. Dipak N. et al. Imaging of a traumatic macular hole with spontaneous closure, *Retina* 1999;19: 470-472.
31. Donnell J.M. Observations of clinical fat embolism. *Can Med Assoc J* 1962; 86: 1060-1066.
32. Drack A.V. Unilateral retinal hemorrhages in documented cases of child abuse. *Am J Ophthalmol* 1999; 128: 340-344.
33. Duane T.D. Valsalva hemorrhagic retinopathy. *Trans Am Ophthalmol Soc* 1972; 70: 298-313.

34. Dugel P.U., Ober R.R.: Posterior segment manifestations of closed-globe contusion injury. W: Retina, Ryan S.J., 2001: 2386-2399.
35. Duke-Elder S.: System of Ophthalmology, Mechanical injuries, CV Mosby, London 1972: 130-163.
36. Dumas J.J. Retinal detachment following contusion to the eye. Int Ophthalmol. Clin 1967; 7:19-38.
37. Eagling E.M. Ocular damage after blunt trauma to the eye. Its relationship to the nature of the injury. Br J Ophthalmol 1974; 58: 126-140.
38. Eagling E.M., Jones N.P. Eye injuries in racquet sports. Proper protection needed. BMJ 1991; 302: 1415-1416.
39. El Bayadi G. New method of slit-lamp microophthalmoscopy. Brit.J. Ophth., 1953; 37, 625-628.
40. Fielding J.A. The assessment of ocular injury by ultrasounds. Clin Radiology 2004; 59: 301-312.
41. Fineman M. S. et al.: Changing trends in paintball sport-related ocular injuries. Arch Ophthalmol 2000; 118: 60-64.
42. Forrester J.V. et al.: Anatomy of the eye and orbit. In: The eye. Basic sciences in practice, Forrester J.V et al., W.B Saunders, 2002, 35-58.
43. Franceschetti A. Notions historiques. In: Pathologies vasculaires oculaires, Pournaras C.J., Masson, 2008: 1-5.
44. Frangieh G.T. et al.: A histopathologic study of macular cysts and holes, Retina, 1981; 1: 311-336.
45. Frau E. Traumatismes par contusion du globe oculaire. Ophtalmologie 1996 [21-700-A-65], www.emc-consulte.com.
46. Friedman N.J. et al.: Posterior segment. In: Review of ophthalmology, Elsevier Saunders, 2005: 295-299.
47. Friendly D.S. Ocular manifestation of the physical child abuse. Trans Am Acad Ophthalmol Otolaryngol 1971; 75:318-332.
48. Fujio A. et al.: Vitreous surgery for traumatic macular holes, Retina 1999; 19(5):410-413.
49. Fuller B., Gitter K.A. Traumatic Choroidal rupture with late serous detachment of macula, Arch Ophthalmol. 1973, 89: 354-355.
50. Gałęzowski X. Ophthalmoscope. In :Traité des maladies des yeux. Librairie J.-B. Baillière et Fils, Paris, 1888 ; 464-475.

51. Gass J.D.M. Stereoscopic atlas of macular diseases: Diagnosis and treatment. CV Mosby, St Louis; 1987; 2: 684-693.
52. Gaudric A, Haouchine B. Principes optiques de l'OCT. In: OCT de la macula, Gaudric A, Haouchine B., Elsevier Masson, 2007: 6-16.
53. Gaudric A, Haouchine B. Techniques et interprétation de l'OCT. In: OCT de la macula, Gaudric A, Haouchine B., Elsevier Masson, 2007: 17-36.
54. Giangiacoimo J. et al.: Sequential cranial computer tomography in infants with retinal hemorrhages. *Ophthalmology* 1988; 95: 295-299.
55. Giraud-Teulon. Ophthalmoscopie binoculaire ou s'exerçant par le concours des deux yeux associés. *Ann. Ocul.* 1861, 45: 233-250.
56. Gitter K.A. et al.: Traumatic hemorrhagic detachment of retinal pigment epithelium. *Arch Ophthalmol.* 1968, 79: 729-732.
57. Glatt H., Machemer R.: Experimental subretinal hemorrhage in rabbits. *Am J Ophthalmol.* 1982; 94: 762-773.
58. Goffstein R., Burton T.C.: Differentiating traumatic from nontraumatic retinal detachment. *Ophthalmology* 1982; 89:361-368.
59. Goldberg M.F.: Choroidoretinal vascular anastomosis after blunt trauma to the eye, *Am J Ophthalmol*, 1976; 82: 892-895.
60. Goldmann H. Le corps vitré. In: Busacca A., Goldmann H., Schiff-Wertheimer S. Historique. Biomicroscopie du corps vitré et du fond d'oeil. Société Française d'Ophthalmologie, Masson, Paris, 1957 ; 97-98.
61. Green R.L., Byrne S.F. Diagnostic Ophthalmic Ultrasounds. In *Retina*, Ryan S.J., Mosby, 2001: 224-302.
62. Greenwald M.J.: Traumatic retinoschisis in battered babies. *Ophthalmology* 1986; 93: 618-625.
63. Gregory P.T.S.: Sussex Eye Hospital sports injuries. *Br J Ophthalmol* 1986; 70: 748-750.
64. Grey R.H.: Foveo-macular retinitis, solar retinopathy and trauma. *Br J Ophthalmol* 1978; 62: 543-546.
65. Gross J.G. et al.: Subfoveal neovascular membrane removal in patients with traumatic choroidal rupture, *Ophthalmology*, 1996: 103(4):579-85.
66. Harley R.D. Ocular manifestation of child abuse. *J Pediatr Ophthalmol Strab* 1980;17:5-13.
67. Hart J.C., Blight R. Early changes in peripheral retina following concussive ocular injuries: an experimental study. *J Roy S Med* 1979; 72: 180-184.

68. Hart J.C., Pilley S.F. Partial evulsion of optic nerve. Fluorescein angiographic study. *Br J Ophthalmol*, 1970; 54: 781-785.
69. Hillman J.S. et al.: Complete avulsion of the optic nerve. A clinical, angiographic and electrodiagnostic study. *Br J Ophthalmol*. 1975; 59:503-509.
70. Holmes Sellors P.J., Mooney D.: Fundus changes after traumatic hyphaema. *Br J Ophthalmol* 1973; 57: 600-607.
71. Horn E.P. et al.: Soccer ball-related retinal injuries. A report of 13 cases. *Retina* 2000; 20: 604-609.
72. Hruby K.: Slit lamp microscopy of the posterior section of the eye with the new preset lens. *Arch Ophthalmol* 1950; 43: 330-338.
73. Hykin P.G.: Optic nerve avulsion due to forced rotation of the globe by a snooker cue. *Br J Ophthalmol*. 1990; 74: 499-501.
74. Ingram D.V., Lewkonja I.: Ocular hazards of playing squash rackets. *Br J Ophthalmol* 1973; 57: 434-438.
75. Jacob H.S. et al.: Complement-induced granulocyte aggregation. An unsuspected mechanism of disease. *N Engl J Med* 1980; 302: 789-794.
76. Jensen A.D.: Ocular clues to child abuse. *J Pediatr Ophthalmol* 1971; 8: 270.
77. Johnson R.N. et al.: Traumatic Macular Hole: Observations, Pathogenesis and Results of Vitrectomy Surgery, *Ophthalmology*, 2001; 108: 853–857.
78. Johnston P.B.: Traumatic retinal detachment. *Br J Ophthalmol* 1991; 75:18-21.
79. Jones N.P. One year of severe eye injuries in sport. *Eye* 1988; 2: 484-487.
80. Kański J.J.: Retinal Detachment. In: *Clinical Ophthalmology: a systematic approach*, Butterworth Heinemann, 2006: 349-368.
81. Kański J.J.: Acquired macular disorders. In: *Clinical Ophthalmology: a systematic approach*, Butterworth Heinemann, 2006: 390-401.
82. Kański J.J.: Trauma. In: *Clinical Ophthalmology: a systematic approach*, Butterworth Heinemann, 2006, 669-671.
83. Katz J, Tielsch J.M. Lifetime prevalence of ocular injuries from the Baltimore Eye Survey. *Arch Ophthalmol* 1993; 111:1564-1568.
84. Kelley J.S., Hartranft C.D. Traumatic Chorioretinopathies. W: *Retina*, Ryan S.J., 2001:1810-1820.
85. Kelley J.S.: Whiplash maculopathy. *Arch Ophthalmol*. 1978; 96: 834-835.
86. Kelley J.S.: Purtscher's retinopathy related to chest compression by safety belts: Fluorescein angiographic findings. *Am J Ophthalmol*. 1972; 74:278-283.

87. Kelly S, Nolan J.: Eye injuries in organised sport in a rural area. *Br J Ophthalmol* 1983; 67: 837-839.
88. Kennedy C.J. et al.: Retinal Detachment caused by retinal dialysis. *Aust N Z J Ophthalmol*, 1997; 25 (1): 25-30.
89. Klopfer J. et al.: Ocular trauma in the United States: Eye injuries resulting in hospitalization, 1984 through 1987. *Arch Ophthalmol* 1992;110: 838-842.
90. Knorr H.L.J., Jonas J.B. Retinal Detachment by Squash Ball Accidents, *Am J Ophthalmol*, 1996; 122 (2): 260-261.
91. Kuhn F. et al.: A standardized classification of ocular trauma. *Ophthalmology* 1996; 103: 240-243.
92. Kusaka S et al.: Spontaneous Disappearance of Traumatic Macular Holes in Young Patients, *Am J of Ophthalmol*, 1997; 123: 837-839.
93. Lafontaine P.O. Le choix d'une lentille d'examen en ophtalmologie. *Réalités Ophtalmol* 2007; 145: 46-54.
94. Larrison W. I. et al.: Sports-related Ocular Trauma. *Ophthalmology* 1990; 97: 1265-1269.
95. Levin L.A. et al.: Retinal Pigment Epithelial Tears Associated With Trauma. *Am J Ophthalmol*. 1991; 112: 396-400.
96. Liem et al.: Reversible cone photoreceptor injury in commotio retinae of the macula, *Retina*, 1995; 15: 58-61.
97. Lyle D.J. et al.: Ophthalmologic hydrostatic pressure syndrome. *Am J Ophthalmol*. 1957; 44: 652-657.
98. MacEwen C. J.: Eye injuries: a prospective survey of 5671 cases. *Br J Ophthalmol* 1989; 73: 888-894.
99. MacEwen C. J.: Sport associated eye injury: a casualty department survey. *Br J Ophthalmol* 1987; 71: 701-705.
100. MacEwen C. J.: Eye injuries in racquet sports. Proper protection needed. *Br M J* 1991; 302: 1415-1416.
101. MacEwen C. J.: Eye injuries in children: the current picture. *Br J Ophthalmol* 1999; 83: 933-936.
102. Mansour A.M. et al.: Histopathology of commotio retinae. Case report: post-mortem examination of ocular globe with peripheral retinal contusion, *Retina*, 1992; 12: 24-28.
103. Margheria R.R., Schepens C.L.: Macular breaks: diagnosis, etiology and observations, *Am J Ophthalmol*, 1972; 74(2):219-232.

104. Martin D.F. et al.: Treatment and pathogenesis of traumatic chorioretinal rupture (sclopetaria). *Am J Ophthalmol.* 1994, 117: 190-200.
105. Massicotte S.J. et al.: Vitreoretinal traction and perimacular retinal folds in the eyes of deliberately traumatized children. *Ophthalmology* 1991; 98: 1124-1127.
106. Mathis A et al.: Techniques de base de la vitrectomie. In: *Pathologie du vitré*, Brasseur G., Masson, 2003: 389-410.
107. Mathis A et al.: Techniques additionnelles au cours de la vitrectomie. In: *Pathologie du vitré*, Brasseur G., Masson, 2003: 411-446.
108. McGwin G, Owsley C. Rate of eye injury in the United States. *Arch Ophthalmol* 2005;123 (7): 970-976.
109. McGwin G et al.: Trends in eye injury in the United States, 1992-2001. *Invest Ophthalmol and Visual Sciences* 2006; 47: 521-527.
110. Mehta H.B., Shanmugam M.P.: Photodynamic therapy of a posttraumatic choroidal neovascular membrane. *Ind J of Ophthalmol* 2005; 53: 131-132.
111. Meier P et al.: Vitrectomy for pre-macular hemorrhagic cyst in children and young adults. *Graefe's Arch Clin Exp Ophthalmol* 2005; 243: 824-828.
112. Mennel S.: Subhyaloidal and macular haemorrhage: localisation and treatment strategies. *Br J ophthalmol* 2007; 91: 850-852.
113. Méry. Des mouvements de l'iris. *Hist.Acad.R. Sci.*, nov.12, 1704, pp. 261-271.
114. Meyer C.H. et al.: Persistent premacular cavity after membranotomy in Valsalva retinopathy evident by optical coherence tomography. *Retina* 2006; 26: 116-118.
115. Meyer C.H. et al.: Is the location of Valsalva hemorrhages submembranous or subhyaloidal? *Am J Ophthalmol* 2006;141: 231-232.
116. Miller-Meeks M.J. et al.: Myopia induced by vitreous hemorrhage *Am J Ophthalmol* 1990; 109: 199-203.
117. Moses R.A. Detachment of ciliary body. Anatomical and physical consideration. *Invest. Ophthalmol.* 1965; 4: 935.
118. National Society to prevent blindness: Vision problems in the U.S.: facts and figures on eye injury. Fact Sheet. New York, National Society to prevent blindness, 1980.
119. Nunode Y. et al. A case of traumatic macular hole with interesting course, *Jpn Rev Clin Ophthalmol* 1983; 77: 922-924.
120. Ocular Trauma Score. American Society of Ocular Trauma. www.isotonline.org/ots.html

121. Oner A. et al.: Ocular trauma in Turkey: a 2-year prospective study. *Adv Ther* 2006; 23: 274-83.
122. Parver L.M. Eye Trauma. The neglected disorder. *Arch Ophthalmol* 1986; 104 (10): 1452-1453.
123. Pieramici D.J. et al.: A system for Classifying Mechanical Injuries of the Eye (Globe). *American Journal of Ophthalmology* 1997; 123: 820-831.
124. Pruett R.C., Weiter J.J., Goldstein R.B.: Myopic Cracks, Angioid Streaks, and Traumatic Tears in Bruch's Membrane, *Am J of Ophth*, 1987; 103: 537-543.
125. Querques G. et al.: Fermeture spontanée d'un trou maculaire post-traumatique évaluée par tomographie par cohérence optique et micropérimétrie. *J Fr Ophtalmol*. 2008 ; 31: 710-713.
126. Richards R.D. et al.: Chorioretinitis sclopetaria. *Am J Ophthalmol*. 1968; 66: 852-860.
127. Ross W.H.: Retinal Dialysis: lack of evidence for genetic cause, *Canadian Journal of Ophthalmology*, 1991; 26: 309-312.
128. Ross W.H.: Traumatic Retinal Dialyses. *Arch Ophthalmol* 1981; 99: 1371-1374.
129. Schein O. D. et al.: The spectrum and Burden of Ocular Injury. *Ophthalmology* 1988; 95: 300-305.
130. Schepens C.L.: Lessons from history. W: Retinal detachment and allied diseases, Volume 1, W.B. Saunders Company, 1983, 5-16.
131. Schepens C.L.: Pathogenesis of traumatic rhegmatogenous retinal detachment. In: Retinal detachment and allied diseases, Volume 1, W.B. Saunders Company, 1983, 68-87.
132. Schepens C.L.: Examination of the ora serrata region: Its clinical significance. *Acta, XVI Concilium Ophthalmologicum, Britannia*, 1950. London, British Medical Association, 1951, vol. 2. pp. 1384-1393
133. Schultz P.N.: Long-term visual outcome in Terson syndrome. *Ophthalmology* 1991; 98: 1814-1819
134. Schuman J.S. et al.: Miscellaneous retinal diseases. In: Optical coherence tomography of ocular diseases. Schuman J.S. et al., Slack Incorporated, 2004: 469-472.
135. Sipperley J.O. et al.: Traumatic Retinopathy in Primates. The Explanation of Commotio Retinae, *Arch Ophtalmol* 1978; 96: 2267-2273.
136. Smith R.E. et al.: Late macular complications of choroidal ruptures, *Am J Ophthalmol*, 1974; 77(5):650-658.
137. Souteyrand G. et al.: Documentation par OCT-3 de la résolution spontanée d'un trou maculaire post-traumatique. *J Fr Ophthalmol* 2008 ; 31: 422-426.

138. Taban M. et al.: Ocular findings following trauma from paintball sports. *Eye* 2008; 22: 930-4.
139. Tasman W.: Peripheral retinal changes following blunt trauma. *Trans Am Ophthalmol Soc* 1972; 70: 190-198.
140. Thuman G., Hinton D.R.: Cell biology of the retinal pigment epithelium. In: *Retina*, Ryan S.J., Mosby, 2001: 104-115.
141. Tielsch J.M. et al.: Time trends in the Incidence of hospitalized ocular trauma. *Arch Ophthalmol* 1989; 107: 519-523.
142. Trantas A. : Moyens d'explorer par l'ophtalmoscope-et par translucidité-la partie antérieure du fond oculaire, le cercle ciliaire y compris. *Arch Ophtalmol* 1900, 20: 314-326.
143. Vinger P.F. Eye injury resulting from violence. *Arch Ophthalmol* 1992; 110: 765-766.
144. Weidenthal W.T., Schepens C.I.: Peripheral fundus changes associated with ocular contusion, *Am J Ophthalmol*. 1966; 62: 465-477.
145. Williams DF et al.: Evulsion of the retina associated with optic nerve evulsion. *Am J Ophthalmol*. 1987; 104: 5-9.
146. Williams D.F., Mieler W.F., Williams G.A: Posterior segment manifestations of ocular trauma. *Retina* 1990: S35-S44.
147. Wolter J.R.: Cup-contrecoup mechanism of ocular injuries, *Am J Ophth*, 1963; 56: 785-796.
148. Wood C.M. et al.: Indirect choroidal ruptures: aetiological factors, patterns of ocular damage, and final visual outcome, *British Journal of Ophthalmology*, 1990; 74: 208-211.
149. Wszyński R.E. et al.: Indirect Choroidal rupture secondary to blunt ocular trauma: a review of eight eyes. *Retina* 1988; 8(4): 237-243.
150. Zografos L, Chamero J.: Evolution au long cours des ruptures indirectes traumatiques de la choroïde. *Journal Français d'Ophtalmologie*, 1990; 13: 269-275.