

Retinotopy and color sensitivity in human visual cortical area V8

Nouchine Hadjikhani, Arthur K. Liu, Anders M. Dale, Patrick Cavanagh and Roger B. H. Tootell

Nuclear Magnetic Resonance Center, Massachusetts General Hospital, 149 13th Street, Charlestown, Massachusetts 02129, USA

Correspondence should be addressed to N.H. (nouchine@nmr.mgh.harvard.edu)

Prior studies suggest the presence of a color-selective area in the inferior occipital-temporal region of human visual cortex. It has been proposed that this human area is homologous to macaque area V4, which is arguably color selective, but this has never been tested directly. To test this model, we compared the location of the human color-selective region to the retinotopic area boundaries in the same subjects, using functional magnetic resonance imaging (fMRI), cortical flattening and retinotopic mapping techniques. The human color-selective region did not match the location of area V4 (neither its dorsal nor ventral subdivisions), as extrapolated from macaque maps. Instead this region coincides with a new retinotopic area that we call 'V8', which includes a distinct representation of the fovea and both upper and lower visual fields. We also tested the response to stimuli that produce color afterimages and found that these stimuli, like real colors, caused preferential activation of V8 but not V4.

In Old World primates such as macaque monkeys and humans, visual information about color is processed in anatomically segregated columns, layers, channels or areas. It is important to know to what extent color is processed in separate versus convergent visual information pathways, because the added dimension of color is so rich in visual information. For example, we can discriminate about fifteen hundred different levels of luminance¹, whereas we can make several million discriminations if we also consider variations in color². It is likely that this glut of color information is incorporated into the labeled lines of the neural architecture in some organized way.

In macaque monkeys, an anatomical segregation between chromatic-opponent versus achromatic-opponent cells has been reported as early as the lateral geniculate nucleus. Color-specific anatomical segregation has also been described in primary (V1) and secondary (V2) visual cortex. In V1, prominent populations of color-selective cells have been reported in specific layers³⁻⁵ and in the cytochrome-oxidase blobs⁴⁻⁶, though the latter claim has been disputed^{7,8}. Similar (and equally controversial) claims have been made about the prominence of color-opponent cells in the 'thin' stripes in area V2, to which the V1 blobs project (ref. 9,10, but see 11).

However, the most prominent controversy about the anatomical segregation of color-selective neurons occurs at a higher level, in cortical area V4. According to different reports, a high percentage of color-selective cells is either present¹²⁻¹⁵ or absent¹⁶ in the largest and best-studied portion of that area, dorsal V4 (V4d). A high percentage of color-selective cells has not been reported in the smaller, ventral subdivision of V4 (V4v). More recent evidence suggests that brain mechanisms critical for color selectivity are located not in macaque V4, but rather in areas anterior to it (ref. 17-19, Vanduffel *et al.* *Soc. Neurosci. Abstr.* 23, 845, 1997).

This controversy about color selectivity in V4 has now been extended to human visual cortex. Based on human neuroimag-

ing studies, a small patch of color-selective activity near the middle of the collateral sulcus has been named 'V4' (ref. 20-22). This choice of name presupposes that (1) an area homologous to macaque V4 exists in humans, (2) V4 is color-selective, and (3) this region in or near the collateral sulcus is the macaque V4 homolog. However, in humans, the location of this color-selective region has not yet been compared with the map of retinotopic areas, to see whether color selectivity is really in a retinotopically defined human area V4. Furthermore, the degree of color selectivity in macaque V4 is itself controversial¹⁷⁻¹⁹.

This issue is not just of academic interest. In an intriguing clinical syndrome ('achromatopsia'), human patients report that the visual world becomes colorless following damage to a cortical region that apparently includes this color-selective area in the collateral sulcus²³⁻²⁵. This suggests that the conscious percept of 'color' involves that area, although it is known that physical wavelength-dependent differences are coded throughout prior levels of the visual system as well. If we can define better which area this is in humans, we can learn something about where conscious perceptions of color arise. Accurate localization in humans should also make it possible to study the homologous area in macaques using more incisive (but invasive) classical neurobiological techniques.

We have attempted to clarify these issues in humans using functional magnetic resonance imaging (fMRI). Technical details were similar to those described elsewhere²⁶, except that here we manipulated the color content of the visual stimuli. We also used a high-field MRI scanner and other improvements to substantially increase the sensitivity of the retinotopic maps (Methods).

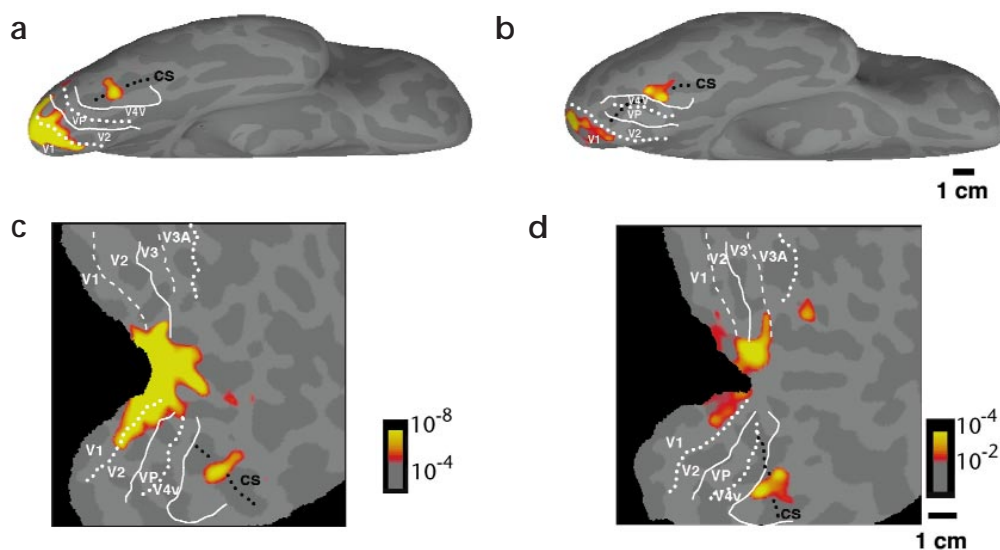
Results

COLOR- VERSUS LUMINANCE-VARYING STIMULI

First, we compared the activity produced by color variations to that produced by variations in luminance, in the same sub-

articles

Fig. 1. Topography of color-selective activity in human visual cortex. **(a, b)** The inferior, 'inflated' cortex, with posterior to the left and anterior to the right, in two subjects. **(c, d)** The posterior portion of cortex in fully flattened format, another view of the same data shown in **(a)** and **(b)**, respectively. In all panels, gyri from the original brain are shown as light gray and sulci as dark gray. The fundus of the collateral sulcus (cs) is indicated by the dashed black line. The borders of previously described retinotopic areas (V1, V2, V3, VP, V3A, and V4v) are indicated in white (horizontal meridians, solid lines, upper vertical meridians, dotted lines, lower vertical meridians, dashed lines). Typically, color-varying stimuli produced relatively higher activation in the foveal representation of V1 and often V2 and V3/VP and a distinctive patch of color-selective activation approximately midway in the collateral sulcus. When present, the latter patch was always located just anterior to the horizontal meridian representation marking the anterior border of area V4v, rather than within V4v.



jects (**Fig. 1**). Our stimuli consisted of slowly moving sinusoidal radial gratings ('pinwheels') of low spatial frequency, defined by either color or luminance contrast (Methods). As shown earlier in V1 and V2 (ref. 27), we found that both color- and luminance-varying stimuli produced robust activation in many areas of visual cortex, when compared with a uniform gray field (data not shown).

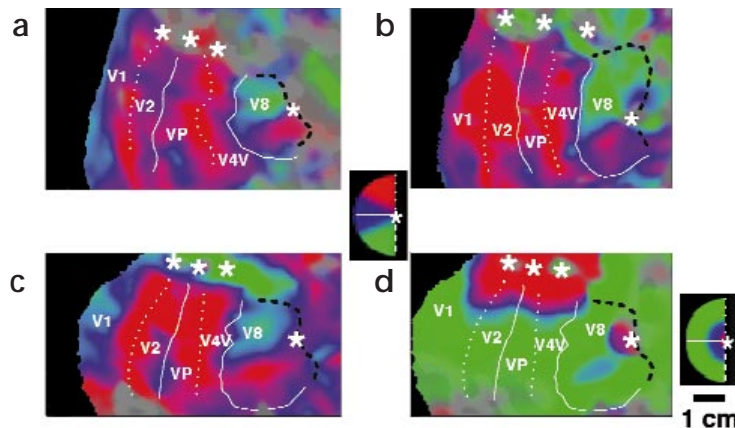
Here we focused on those locations where the color stimuli produced more activation than the luminance stimuli. In the classically retinotopic visual areas (V1, V2, V3/VP, V3A and V4v), we found prominent color-selective activation in the representations of the fovea (center of gaze) but not in peripheral representations (**Fig. 1**). A foveal color bias has not been reported in previous imaging studies, perhaps because it is more obvious in our flattened maps. However, such a foveal color bias is consistent with the well known predominance of cone photoreceptors, and the corresponding absence of rods, in the fovea

of the retina. A similar foveal color bias is found in routine clinical perimetry and in numerous psychophysical studies.

In 25 of 26 hemispheres (13 subjects) tested, we found an additional region that responded preferentially to color, located midway along the length of the collateral sulcus. Based on the anatomical location and the nature of the functional comparison used here, this collateral color-selective patch appears equivalent to the previously reported area involved in achromatopsia^{20,22}, which has been proposed as the human homologue of macaque area V4 (refs 20–22, 28–30).

However, when we compared the location of that collateral color-selective patch to the retinotopic borders in the same subjects, we found that the color-selective patch was consistently located just beyond the most anterior retinotopic area defined previously, area V4v. Earlier reports^{26,31–33} suggested that human V4v is a quarter-field representation of the contralateral upper visual field. The more sensitive retinotopic mapping

Fig. 2. Retinotopic features of area V8 by fMRI mapping. **(a–c)** Retinotopy of polar angle in the inferior row of cortical areas, from three flattened hemispheres. From left to right, each panel shows the representations of the contralateral upper quarter field (red through blue or vice versa; see pseudocolor logo) in inferior V1, then inferior V2, then VP, then V4v. To the right of (anterior to) V4v is the distinctive half-field representation comprising V8 (green through blue through red, from upper to lower in this figure). **(d)** Retinotopic representation of eccentricity (the other dimension in polar space), from the same hemisphere shown in **(c)**. The representations of central-through-more-peripheral eccentricities are coded in red-through-blue-through-green, respectively (see pseudocolor logo, bottom right). The representations of the center of gaze are indicated with an asterisk. Area V8 has its own representation of the fovea, quite distinct (and 3.5 cm) from the foveal representation in adjacent area V4v.






Fig. 3. Detailed retinotopy of the polar angle representation, from the same hemisphere shown in Fig. 2a. This figure shows the peak fMRI response (noisy white lines) corresponding to polar angle gradients of approximately 20° , superimposed on the standard pseudocolor rendering of areas V1, V2, VP and V4v (drawn in a). To the right of each panel is a logo indicating the specific polar angle (white line) stimulated. The complete contralateral visual field is represented in V8, from the lower visual field (a and b), across the horizontal meridian (c–e) to the upper visual field (f–h). Note in (e–h) that the upper visual field representation in V8 can clearly be distinguished from, and is mirror symmetric to, that in adjacent V4v.

methods used here confirmed that V4v represents just that quarter field, with its foveal representation located superiorly alongside that of adjacent areas V3/VP (Figs 2 and 3).

The improved retinotopic methods also revealed additional retinotopic features anterior to V4v. Taken together, these features indicate the presence of an additional retinotopic map, comprising a previously undifferentiated cortical area that we call 'V8'. This continues the naming scheme begun by Zeki and colleagues, who identified areas V1 through V6^{12–15,21,22,34}. (We also identified an area 'V7', which is a representation of the contralateral lower visual field anterior to human V3A.)

Area V8 has a unique polar angle retinotopy and a distinctive foveal representation. This contrasts significantly with the three extrastriate representations posterior to V8 (V4v, VP, and the inferior wing of V2), all of which are quarter-field representations of the contralateral upper visual field. Although the polar-angle retinotopy in V8 includes an additional representation of this quarter field, it also extends further to include a lower-field representation as well (Figs 2 and 3). These three extrastriate visual areas (V4v, VP and inferior V2) also share a contiguous representation of the fovea, at the top (superior) end of this row of areas (Fig. 2d). However, the foveal representation in V8 is not part of this contiguous foveal band; instead it is located about 3.5 centimeters away along the cortical surface, at the anterior border of V8 (Fig. 2d).

HUMAN VERSUS MACAQUE MAPS

Because so much of the historical controversy about cortical color processing arose in studies of macaque monkey, it is natural to wonder which area in macaque corresponds to area V8 in humans. To clarify the topographic relationship of the human and macaque maps, we first averaged together

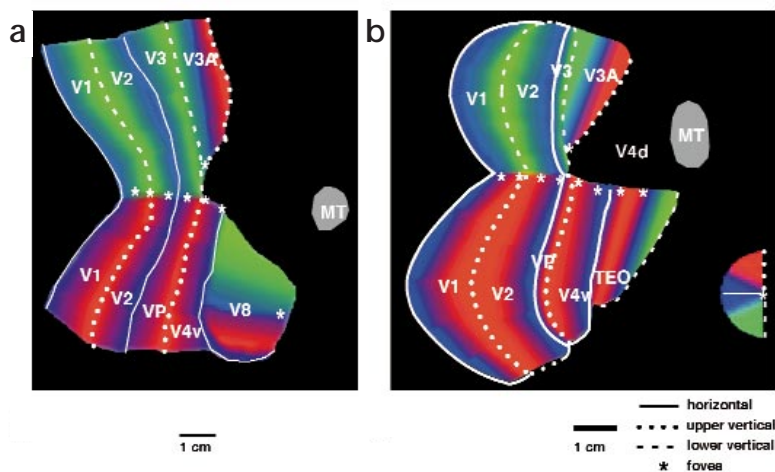


Fig. 4. Comparison of the polar angle retinotopy in human visual cortex, relative to that reported in macaque monkeys. In both species, visual cortex is shown in flattened format, with visual area boundaries and polar angle continua as in Fig. 2a–c. Area MT is shown in gray. In macaque, dorsal area V4 is also indicated (V4d). The retinotopy of V8 is similar to that reported in area TEO, in that both areas are located immediately adjacent to area V4v. However, the two areas differ in overall shape, and the retinotopy of V8 is rotated approximately 90° relative to that reported in TEO.

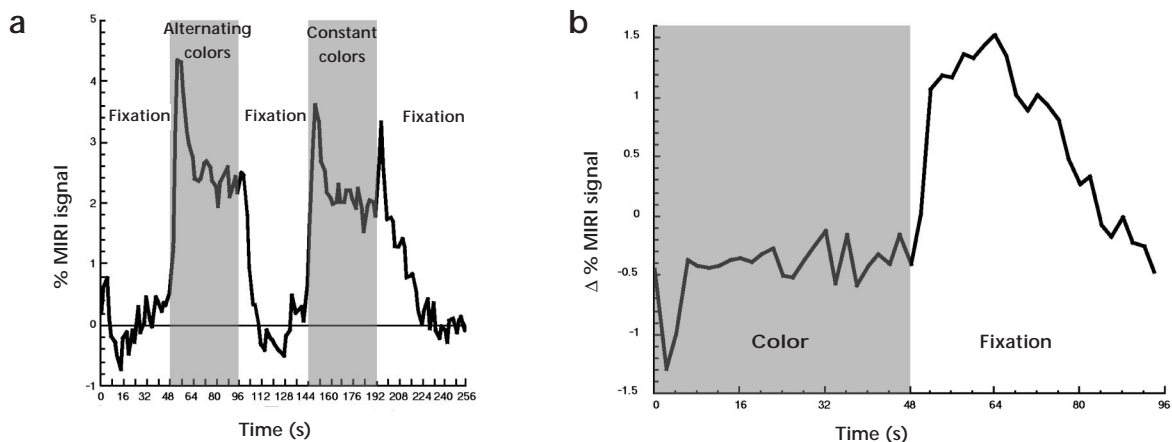


Fig. 5. The time course of V8 activity is related to the perception of color afterimages. **(a)** Time course from all voxels in retinotopically defined V8 that responded ($p < 0.00001$) to the colored stimuli, relative to the initial presentation of the uniform gray stimulus, averaged across 16 MR scans, showing the response to both the actual and the illusory color stimuli. Epochs in which subjects viewed a uniform gray field, or an illusory afterimage on a gray background, are indicated with a white background; epochs when the subjects viewed colored stimuli (alternating- or constant-colored) are indicated with a gray background. After the color stimulus, subjects viewed a uniform gray field, or an illusory afterimage on a gray background. During a color afterimage, the fMRI response was quite prolonged, consistent with the time course of the percept of the illusory colors. **(b)** The MR afterimage is shown more directly by subtracting signal during constant color and subsequent gray period from alternating color and subsequent gray period.

six of the most robust human retinotopic maps, using digital morphing techniques (Fig. 4b) as described²⁶. These averaged maps could then be compared to the map of macaque retinotopy, as estimated from single-unit mapping³⁵ (Fig. 4a). This comparison suggests that human area V8 shows some retinotopic and topographic similarity to macaque area TEO. Furthermore, TEO and/or more anterior areas have appeared strongly color selective in recent studies of macaque visual cortex (refs 17–19, 28, Vanduffel *et al. Soc Neurosci. Abstr.* 23, 845, 1997).

However, the retinotopic similarity between V8 and TEO is far from exact (Fig. 4). Furthermore, other investigators have proposed different area boundaries in this region of macaque cortex^{36–38}. Unfortunately, those alternative models of the macaque maps are even less similar to the empirical human maps in this region of cortex. Thus it is not clear which macaque area is homologous to human area V8. However, the flat maps in Fig. 4 do make it clear that this human collateral color area is not topographically similar to macaque V4 (neither dorsal nor ventral subdivisions). Human V8 is also topographically inconsistent with the location of subdivisions proposed in macaque dorsal V4, such as V4t (ref. 39) and V4A (e.g. ref. 14).

COLOR AFTERIMAGES

Another way to assess functional selectivity is by measuring the fMRI responses during visual aftereffects, rather than during the fMRI effects produced by the visual stimuli themselves. In other dimensions such as motion⁴⁰ and orientation⁴¹, such indirect aftereffects have ironically proven to be functionally more selective than the effects themselves. Here we tested whether illusory color would also activate V8, as did real color stimuli.

If one stares for a time at a saturated color, then looks away at a uniform gray field, one sees an illusory percept of the complementary color. Unlike motion or orientation aftereffects, these negative color afterimages are thought to arise primarily

in the retina^{42,43}. However, they also presumably trigger activity at higher levels, as would a real stimulus that was similarly stabilized on the retina^{29,44}. To test for the presence of fMRI responses to these illusory colors, we produced such color afterimages in the MR scanner, along with control stimuli that were very similar but did not produce color afterimages.

Figure 5 shows the time course of fMRI activity produced by these stimuli in area V8. As expected, the colored stimuli produced robust fMRI activity in V8, whether alternating or constant. However, only the constant-colored stimuli produced a perceptual color afterimage and a corresponding fMRI aftereffect in V8 during subsequent viewing of the uniform gray field (Fig. 5a). The alternating-colored stimuli produced neither a perceptual color afterimage nor a prolongation of the normal fMRI return to baseline during the subsequent viewing period (Fig. 5a). The duration of the isolated fMRI color aftereffect was prolonged, consistent with the prolonged duration of the illusory color percept (Fig. 5b). Overall, this strongly suggests that these fMRI responses were related to the processing of the illusory colors.

One unexpected finding was that the stimuli with alternating colors produced slightly more activity than the stimuli in which color remained constant (Fig. 5a). This may reflect the fact that the hues in the constant-colored stimuli become progressively less saturated (less densely colored) with time because of chromatic adaptation⁴⁵. Essentially one begins to see the mixture of the color afterimage and the actual color. Because these two colors are complementary, they produce a less saturated, more 'washed-out' color. This decreased fMRI response to the decreasingly saturated colors supports the other evidence that V8 is involved in color perception.

Findings similar to our fMRI afterimages in V8 were reported from scattered voxels in single-slice imaging through nearby posterior fusiform gyrus²⁹, but the location of those voxels was not localized to any specific cortical area. However,

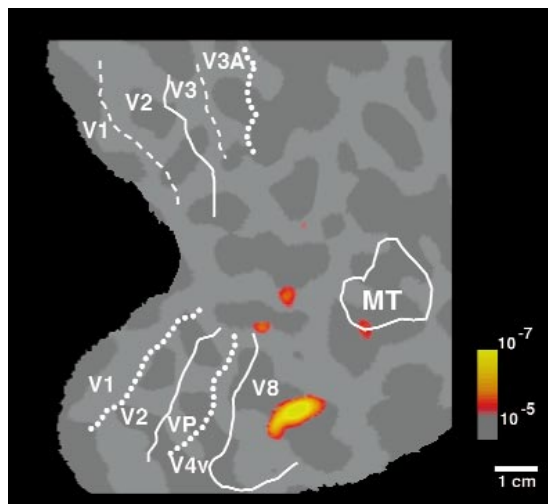


Fig. 6. The perception of color afterimages produces relatively higher activation in cortical area V8, compared with other cortical areas. The activation shown here represents all regions that responded significantly more ($p < 0.00001$) during viewing of the uniform gray stimulus following the constant color stimulus, compared with viewing of the same gray stimulus following the alternating color stimulus.

none of these data address the possibility that similar fMRI afterimages occur nonspecifically throughout much wider areas of visual cortex. This could arise from retinal color processing that is transmitted passively to cortex, or from globally increased attention when viewing the color afterimages.

To test this, we reanalyzed our data to find the areas in an activity map that respond differentially during the presence of the visual afterimage (Fig. 6). At lower levels of significance than shown here, a number of additional visual areas (e.g., V1, V2) do respond more to color afterimages. However, at the more strict significance threshold used in Fig. 6, the activity in V8 was more prominent than in any other area. In particular, the wider areas of foveal color selective activities including areas such as V1, V2, etc., were relatively less prominent in the afterimage test, compared to the direct comparisons of color versus luminance (see Fig. 1c and Fig. 6, showing the same hemisphere).

Discussion

The retinotopic maps make it clear that an additional area (V8) exists beyond those areas described previously in human visual cortex. Area V8 is retinotopically distinct from the previously described area V4v, based on at least four different criteria. First, V4v and V8 have separate foveal representations, approximately 3.5 cm apart along the cortical surface. Second, V4v and V8 each include separate representations of the upper visual field, separated from each other by a representation of the horizontal meridian. Third, V8 differs from V4v in its global functional properties, including but not limited to color sensitivity. Fourth, the nature of the retinotopy in V8 is different from that in V4v.

The direct comparisons between color- and luminance-varying stimuli (Fig. 1) indicate that area V8 responds slightly better than neighboring cortical regions to colored stimuli. However, we also found that the color-varying stimuli produce preferen-

tial activation in the foveal representation of all retinotopic areas. Thus, V8 may seem especially biased for color stimuli merely because its foveal representation sets it topographically apart from the conjoined foveal color responses of its neighbors (Figs 2 and 3). This is a relatively trivial explanation for the color selectivity reported earlier, but we cannot rule it out completely. This idea is further supported by the fact that area V8 responds at reasonable levels to a wider variety of visual stimuli.

However, other evidence argues that V8 is involved in wavelength-dependent processing and perhaps in the conscious perception of color itself. The robust and selective response to illusory colors (Figs 5 and 6) strongly supports this idea. Also, the anatomical colocalization of V8 compared with the previous clinical data makes it likely that area V8 is damaged in achromatopsic patients^{23–25}.

What do these human data tell us about macaque visual cortex? This question is constrained by several factors. The human data are based on clinical and neuroimaging data, whereas the macaque data are derived from different techniques (e.g., single units, lesions and DG imaging), which could conceivably produce different results. Also, there may be significant biological differences between the cortical organization of color sensitivity in humans compared with macaques. As we learn more about human and macaque visual cortex, the number of differences between these species are increasing correspondingly^{26,46–48}.

Despite these caveats, the data suggest that the area of macaque cortex that is homologous to the human 'achromatopsia' area should be located in or anterior to TEO, rather than in V4. This is supported by data from macaque^{17–19} as well as the present data from human V8.

Methods

GENERAL PROCEDURES. Except for modifications described below, the methods in this study are similar to those described²⁶. Informed written consent was obtained for each subject prior to the scanning session, and all procedures were approved by Massachusetts General Hospital Human Studies Protocol numbers 90–7227 and 96–7464. Normal human subjects, with (or corrected to) emmetropic vision, were scanned in General Electric magnetic resonance (MR) scanners retrofitted with ANMR echo-planar imaging. Most scans were acquired in a high-field (3 T) scanner, but some early scans were acquired in a scanner of conventional (1.5 T) field strength. Based on signal-to-noise ratios obtained during otherwise comparable conditions, four functional scans at 1.5 T were found to be approximately equal to one functional scan at 3 T, so this was the ratio used to equate data acquired from the two scanners. Head motion was minimized by using bite bars with deep, individually molded dental impressions. The subject's task in all experiments was to fixate the center of each type of visual stimulus throughout the period of scan acquisition.

MR images were acquired using a custom-built quadrature surface coil, shaped to fit the posterior portion of the head. MR slices were 3–4 mm thick, with an in-plane resolution of 3.1 x 3.1 mm, oriented approximately perpendicular to the calcarine fissure. Each scan took either 4 min 16 s (color-versus-luminance and color afterimage scans) or 8 min 32 s (retinotopy), using a TR of either two or four seconds, respectively. Each scan included 2,048 images, comprised of 128 images per slice in 16 contiguous slices.

Improved retinotopic maps were obtained from 32 subjects (79 scans polar angle, 79 scans eccentricity, 323,584 images total). Among them, 13 subjects were also tested for color-versus-luminance (112 scans, 229,376 images total). Of these, five subjects were tested extensively for color afterimages (100 scans; 204,800 images total). In most subjects, additional scans were done to clarify the location of area MT and other visual areas.

VISUAL STIMULI. The goal of the first color-related experiment (Fig. 1) was to map the MR activity produced by color- versus luminance-varying stimuli throughout visual cortex, using conventional psychophysical stimuli. Prior to scanning, the equiluminance values for different color combinations (red-cyan, CIE x and y coordinates 0.645, 0.345 and 0.185, 0.248 respectively, or green-purple, CIE x and y coordinates 0.277, 0.684 and 0.351, 0.220, respectively) were measured for each subject, outside the scanner. Equiluminance was measured using a motion-null test, with the same stimulus projector (NEC model MT 800), lens and color software used subsequently in the MR experiments. In the first experiment, both color- and luminance-varying stimuli were produced using slowly moving (0.5 Hz) sinusoidal radial gratings ('pinwheels') of low spatial frequency (3 cycles per revolution). The gratings varied either in achromatic luminance (maximum, 95% luminance contrast) or in equiluminant color (at maximum available saturations of the display device within constraints of approximately 140 cd per m² mean luminance and approximately white mean chromaticity), in direct alternation, in 16-second epochs, using 16 epochs per scan.

In a second experiment (Figs 5 and 6), color afterimages were produced by showing subjects colored adaptation patterns. Subjects adapted to two general types of stimuli; one produced a pronounced color afterimage when subjects subsequently viewed a uniform gray field, but a very similar control stimulus did not produce such a color afterimage. There were five epochs in each scan, presented in the following order: (1) uniform gray, (2) alternating-color (control adaptation), (3) uniform gray, (4) constant-color (experimental adaptation) and (5) uniform gray. All epochs were 48-s long, except that the final fixation period was prolonged 16 s to reveal the final traces of the MR afterimage. In the analysis for Fig. 5b, the last 16 s in that final epoch was truncated to match the duration of all other epochs. Both the constant- and the alternating-colored patterns were comprised of complementary colors (red-cyan or green-purple), spatially arranged in opposed quarter-fields (i.e. two-cycle-per-revolution polar square waves), akin to interleaved bow ties. All hues were presented at equal luminance, based on motion-null tests in each subject. Following adaptation to the constant colors, subjects initially experienced a prominent color afterimage against the uniform gray background, which faded over tens of seconds. The afterimage was retinotopically similar to the adaptation stimulus, but of complementary color. As controls, we presented stimuli equivalent to the constant colors, except that the colors alternated between color and complementary color, reversing every 2 s. The latter condition produced no perceptual color afterimages during the subsequent epoch of uniform gray stimulation.

Stimuli for retinotopic mapping were slowly moving, phase-encoded thin rays or rings comprised of counterphasing black and white checks, scaled according to polar coordinates, similar to those described^{26,31,32,50}. However, to produce the most informative retinotopic maps possible, several stimulus modifications and new procedures were implemented. First, all retinotopic measurements were made in the 3 T scanner. This increased the MR amplitudes by a factor near four, and the physiological signal-to-noise ratio by a factor near two. Second, we signal-averaged the information from 4–12 scans (8,192–24,576 MR images) of polar angle or eccentricity. Data were also combined from different slice prescriptions on the same cortical surface, to reduce intervoxel aliasing. Third, the retinotopic stimuli were increased in extent both foveally and peripherally, to extend from 0.2° through 18–30°. This activated correspondingly more surface in each cortical area. Fourth, the visual stimuli were presented using a new LCD projector of higher spatial resolution (800 x 600), using better optics than previously (aperture lens, bypassing shielding screen, etc.). Fifth, the retinotopic stimuli varied in color as well as luminance, to better activate any color-selective cells in the region. The sum of all these manipulations produced very robust retinotopic maps.

DATA ANALYSIS. Data from two-condition experiments (e.g., color-versus-luminance comparisons) and phase-encoded retinotopic experiments were

initially analyzed by doing a fast Fourier transform on the MR time course from each voxel. Statistical significance was calculated by converting the Fourier magnitude of the response to an *f*-statistic. The phase of the signal at the stimulus frequency was used to track stimulus location in the case of retinotopic stimuli, and to distinguish between positive- or negative-going MR fluctuations in the case of two-condition stimulus comparisons.

Scans comparing more than two stimuli (e.g., the color afterimage data) were analyzed by selective averaging of two conditions. This was followed by statistical comparison using a *t*-test of the difference of the first seconds following onset of the next epoch (here stimulus offset).

For topographic clarity, all data were analyzed and displayed in cortical surface format, as described^{36,43,44}. This made it possible to extract the MR time courses from voxels in specific cortical areas, which were defined in the same subjects. The specific areas sampled were V1, V2, V3/VP, V3A, V4v, MT+, and V8. Area 'MT+' was defined on the basis of additional scans comparing moving and stationary stimuli^{26,40}. All other areas were based on retinotopic criteria.

For ease of comparison, all hemispheres are shown in right hemisphere format. Above a minimum threshold, the statistical significance of the displayed pseudocolor range has been normalized according to the overall sensitivity of each subject, as described elsewhere.

Acknowledgments

This work was supported by grants from the Human Frontiers Science Foundation and NEI EY07980 to R.B.H.T., NEI EY09258 to P.C. and Swiss Fonds National de la Recherche Scientifique to N.H. We thank Terry Campbell and Mary Foley for scanning and participation in these experiments, Robert Savoy, Ken Kwong, Bruce Fischl and Kevin Hall for advice, Tommy Vaughan for coil design and manufacture and Martin Sereno for modifying pilot stimuli. Wim Vanduffel, Ekkehardt Kustermann and Irene Tracy also helped in preliminary versions of this experiment.

RECEIVED 16 APRIL; ACCEPTED 21 MAY 1998

- Cornsweet, T.N. *Visual Perception* (Academic Press, New York, 1970).
- Judd, D.B. & Wyszecki, G. *Color in Business, Science, & Industry* 3rd edn 388 (Wiley, New York, 1975).
- Dow, B.M. Functional classes of cells and their laminar distribution in monkey visual cortex. *J. Neurophysiol.* 37, 927–946 (1974).
- Livingstone, M.S. & Hubel, D.H. Anatomy and physiology of a color system in the primate visual cortex. *J. Neurosci.* 4, 309–356 (1984).
- Tootell, R.B.H., Silverman, M.S., Hamilton, S.L., De Valois, R.L. & Switkes, E. Functional anatomy of macaque striate cortex: III. Color. *J. Neurosci.* 8, 1569–1593 (1988).
- Ts'o, D.Y., Frostig, R.D., Lieke, E.E. & Grinvald, A. Functional organization of primate visual cortex revealed by high resolution optical imaging. *Science* 249, 417–420 (1990).
- Lennie, P., Krauskopf, J. & Sclar, G. Chromatic mechanisms in striate cortex of macaque. *J. Neurosci.* 10, 649–669 (1990).
- Leventhal, A.G., Thompson, K.G., Liu, D., Zhou, Y. & Ault, S.J. Concomitant sensitivity to orientation, direction and color of cells in layers 2, 3 and 4 of monkey striate cortex. *J. Neurosci.* 15, 1808–1818 (1995).
- Hubel, D.H. & Livingstone, M.S. Segregation of form, color and stereopsis in primate area 18. *J. Neurosci.* 7, 3378–3415 (1987).
- Tootell, R.B.H. & Hamilton, S.L. Functional anatomy of the second cortical visual area (V2) in the macaque. *J. Neurosci.* 9, 2620–2644 (1989).
- Gegenfurtner, K.R., Kiper, D.C. & Fenstemaker, S.B. Processing of color, form and motion in macaque area V2. *Vis. Neurosci.* 13, 161–172 (1996).
- Zeki, S.M. Colour coding in rhesus monkey prestriate cortex. *Brain Res.* 27, 422–427 (1973).
- Zeki, S.M. Colour coding in the superior temporal sulcus of rhesus monkey visual cortex. *Proc. R. Soc. Lond. B* 197, 195–223 (1977).
- Zeki, S. Uniformity and diversity of structure and function in rhesus monkey prestriate visual cortex. *J. Physiol. (Lond.)* 277, 273–290 (1978).
- Zeki, S. The distribution of wavelength and orientation selective cells in different areas of monkey visual cortex. *Proc. R. Soc. Lond. B* 217, 449–470 (1983).
- Schein, S.J., Marrocco, R.T. & de Monasterio, F.M. Is there a high concentration of color-selective cells in area V4 of monkey visual cortex? *J. Neurophysiol.* 47, 193–213 (1982).
- Heywood, C.A., Gadotti, A. & Cowey, A. Cortical area V4 and its role in the perception of color. *J. Neurosci.* 12, 4056–4065 (1992).

18. Heywood, C.A., Gaffan, D. & Cowey, A. Cerebral achromatopsia in monkeys. *Eur. J. Neurosci.* **7**, 1064–1073 (1995).
19. Cowey, A. & Heywood, C.A. There's more to colour than meets the eye. *Behav. Brain Res.* **71**, 89–100 (1995).
20. Lueck, C.J. *et al.* The colour centre in the cerebral cortex of man. *Nature* **340**, 386–389 (1989).
21. Zeki, S. *et al.* A direct demonstration of functional specialization in human visual cortex. *J. Neurosci.* **11**, 641–649 (1991).
22. McKeefry, D.J. & Zeki, S. The position and topography of the human colour centre as revealed by functional magnetic resonance imaging. *Brain* **120**, 2229–2242 (1997).
23. Pearlman, A.L., Birch, J. & Meadows, J.C. Cerebral color blindness: An acquired defect in hue discrimination. *Ann. Neurol.* **5**, 253–261 (1979).
24. Damasio, A., Yamada, T., Damasio, H., Corbett, J. & McKee, J. Central achromatopsia: Behavioral, anatomic, and physiologic aspects. *Neurology* **30**, 1064–1071 (1980).
25. Zeki, S. A century of cerebral achromatopsia. *Brain* **113**, 1721–1777 (1990).
26. Tootell, R.B.H. *et al.* Functional analysis of V3A and related areas in human visual cortex. *J. Neurosci.* **17**, 7076–7078 (1997).
27. Engel, S., Zhang, X. & Wandell, B. Colour tuning in human visual cortex measured with functional magnetic resonance imaging. *Nature* **388**, 68–71 (1997).
28. Kennard, C., Lawden, M., Morland, A.B. & Ruddock, K.H. Colour identification and colour constancy are impaired in a patient with incomplete achromatopsia associated with prestriate cortical lesions. *Proc. R. Soc. Lond. B* **260**, 169–175 (1995).
29. Sakai, K. *et al.* Functional mapping of the human colour centre with echo-planar magnetic resonance imaging. *Proc. R. Soc. Lond. B* **261**, 89–98 (1995).
30. Kleinschmidt, A., Lee, B.B., Requardt, M. & Frahm, J. Functional mapping of color processing by magnetic resonance imaging of responses to selective P- and M-pathway stimulation. *Exp. Brain Res.* **110**, 279–288 (1996).
31. DeYoe, E.A. *et al.* Mapping striate and extrastriate visual areas in human cerebral cortex. *Proc. Natl. Acad. Sci. USA* **93**, 2382–2386 (1996).
32. Sereno, M.I. *et al.* Borders of multiple visual areas in humans revealed by functional magnetic resonance imaging. *Science* **268**, 889–893 (1995).
33. Tootell, R.B.H., Dale, A.M., Sereno, M.I. & Malach, R. New images from human visual cortex. *Trends Neurosci.* **19**, 481–489 (1996).
34. Galletti, C., Fattori, P., Battaglini, P.P., Shipp, S. & Zeki, S. Functional demarcation of a border between areas V6 and V6A in the superior parietal gyrus of the macaque monkey. *Eur. J. Neurosci.* **8**, 30–52 (1996).
35. Boussaoud, D., Desimone, R. & Ungerleider, L.G. Visual topography of area TEO in the macaque. *J. Comp. Neurol.* **306**, 554–575 (1991).
36. Felleman, D.J. & Van Essen, D.C. Distributed hierarchical processing in the primate cerebral cortex. *Cereb. Cortex* **1**, 1–47 (1991).
37. Zeki, S. Are areas TEO and PIT of monkey visual cortex wholly distinct from the fourth visual complex (V4 complex)? *Proc. R. Soc. Lond. B* **263**, 1539–1544 (1996).
38. Maguire, W.M. & Baizer, J.S. Visuotopic organization of the prelunate gyrus in rhesus monkey. *J. Neurosci.* **7**, 1690–1704 (1984).
39. Van Essen, D.C., Maunsell, J.H. & Bixby J.L. The middle temporal visual area in the macaque: Myeloarchitecture, connections, functional properties and topographic organization. *J. Comp. Neurol.* **199**, 293–326 (1981).
40. Tootell, R.B.H. *et al.* Visual motion aftereffect in human cortical area MT revealed by functional magnetic resonance imaging. *Nature* **375**, 139–141 (1995).
41. Tootell, R.B.H. *et al.* Functional analysis of primary visual cortex (V1) in humans. *Proc. Natl. Acad. Sci. USA* **95**, 811–817 (1998).
42. Craik, K.J.W. Origin of visual afterimages. *Nature* **145**, 512 (1940).
43. Brindley, G.S. Two new properties of foveal afterimages and a photochemical hypothesis to explain them. *J. Physiol.* **164**, 168–179 (1962).
44. Schiller, P.H. & Dolan, R.P. Visual aftereffects and the consequences of visual system lesions on their perception in the rhesus monkey. *Vis. Neurosci.* **11**, 643–665 (1994).
45. Jameson, D., Hurvich, L.M. & Varner, F.D. Receptor and postreceptor processes in recovery from chromatic adaptation. *Proc. Natl. Acad. Sci. USA* **76**, 3034–3038 (1979).
46. Tootell, R.B.H. & Taylor, J.B. Anatomical evidence for MT and additional cortical visual areas in humans. *Cereb. Cortex* **5**, 39–55 (1995).
47. Tootell, R.B.H. *et al.* Functional analysis of human MT and related visual cortical areas using magnetic resonance imaging. *J. Neurosci.* **15**, 3215–3230 (1995).
48. Jacobs, G.H. & Deegan, J.F. Spectral sensitivity of macaque monkeys measured with ERG flicker photometry. *Vis. Neurosci.* **14**, 921–928 (1997).
49. DeYoe, E.A., Felleman, D.J., Van Essen, D.C. & McClendon, E. Multiple processing streams in occipitotemporal visual cortex. *Nature* **371**, 151–154 (1994).
50. Engel, S.A., Glover, G.H. & Wandell, B.A. Retinotopic organization in human visual cortex and the spatial precision of functional MRI. *Cereb. Cortex* **7**, 181–192 (1997).