

ORIGINAL ARTICLES

Endourology and Stone Diseases

Retrograde Flexible Ureteroscopic Approach for Pyelocaliceal Calculi

Petrisor Geavlete, Seyed Abdulah Seyed Aghamiri,* Razvan Multescu

Department of Urology, St John Clinical Emergency Hospital, Bucharest, Romania

ABSTRACT

Introduction: Our goal was to investigate the efficacy of flexible ureteroscopy (FU) in the treatment of pyelocaliceal calculi.

Materials and Methods: Between September 2002 and December 2004, a total of 41 patients with multiple (23 cases), pelvic (7 cases), and inferior caliceal (11 cases) SWL-resistant calculi underwent FU. We used a 7.5-F flexible ureteroscope with pressure irrigation and electro-hydraulic lithotripsy. The fragments were retrieved with triradiate graspers or tipless baskets.

Results: A double J stent had been previously placed in 34% of the patients. Dilation of the ureteral orifice was necessary in 9.8%. The location of the calculi was renal pelvis, inferior calyx, and pelvis and calyces in 7, 11, and 23 patients, respectively. The median operative time was 64 minutes for pyelocaliceal, 46 minutes for pelvic, and 39 minutes for inferior caliceal calculi. Complete stone clearance or good fragmentation (fragments less than 3 mm) was obtained in 71% of patients (57% for pyelocaliceal, 87% for pelvic, and 71% for inferior caliceal calculi). A successful outcome was achieved in 78%, 72%, and 49% for calculi sized 10 mm or smaller, 11 mm to 20 mm, and greater than 20 mm, respectively. Two or more procedures were required in 11 patients (27%). The complication rate was 7.3% (hematuria, persistent renal colic, and hyperthermia).

Conclusion: Our experience shows that FU can be an effective approach in selected patients, especially those with kidney calculi that are resistant to SWL. However, percutaneous approach is a better alternative for calculi greater than 20 mm.

KEY WORDS: flexible ureteroscopy, kidney calculus, shock wave lithotripsy

Introduction

The first flexible ureteroscopy (FU) was performed for diagnostic purposes in 1964 by Marshall.⁽¹⁾ He used a 9-F endoscope produced by an American cystoscope manufacturer, without a working channel or active deflection facilities.

At the beginning of the 1980s, Bagley and

colleagues^(2,3) contributed significantly to the development of FU by adding three essential technical characteristics: the working channel, an active deflection, and—by reducing the rigidity in the distal portion of the sheath—a passive deflection. By miniaturization of the endoscopes and development of the optical system, ureteroscopes became very useful tools in the diagnosis and treatment of upper urinary tract lesions.⁽⁴⁾

Although shock wave lithotripsy (SWL) represents the first-line treatment of pyelocaliceal

Received November 2005

Accepted February 2006

**Corresponding author: Tel: +40 722 402 887,*

Fax: +40 21 321 0507, E-mail: seyedag@yahoo.com

calculi smaller than 20 mm, other alternatives of endourologic techniques for SWL-resistant calculi are necessary. Since 2002, the use of FU in the diagnostic and therapeutic arsenal at St John Clinical Emergency Hospital in Bucharest has substantially improved the diagnosis and treatment of the upper urinary tract diseases, especially kidney calculi. The purpose of this study was to evaluate the efficacy, limits, and complications of the FU in SWL-resistant pyelocaliceal calculi.

Materials and Methods

Between September 2002 and December 2004, a total of 41 patients with SWL-resistant pyelocaliceal calculi underwent FU in our department. The investigational protocol included physical examination, routine blood tests, abdominal ultrasonography, plain abdominal radiography (kidney, ureter, and bladder), intravenous urography (IVU), and, in selected cases, retrograde ureteropyelography and CT scan.

The characteristics of the calculi are summarized in Table 1. In the patients with multiple calculi, the location of calculi was either concomitant pelvic and caliceal (inferior, middle, or superior) or multiple caliceal. The maximum dimensions were 25 mm for pelvic calculi and 12 mm for caliceal ones; the mean area was 328 mm² (range, 175 mm² to 610 mm²). In 14 patients (34%) with obstructive pelvic calculi and hydronephrosis, double J stenting had been previously performed and the stent maintained for 14 days before FU.

In all patients, SWL had been attempted and the mean number of procedures was 2.9 (range, 1 to 4). They were treated using a 7.5-F Storz

flexible ureteroscope (Karl Storz, Tuttlingen, Germany) with an active deflection, a secondary passive deflection, and a 3.6-F working channel. As an energy source, we used an electrohydraulic lithotripter (Calcutript, Karl Storz, Tuttlingen, Germany) with 1.6-F and 1.9-F flexible probes. For irrigation, saline (0.9% NaCl) solution was used. For retrieval of calculi fragments, we used flexible triradiate graspers or Nitinol tipless baskets. All interventions were performed under fluoroscopic guidance using a mobile radiological unit (Siemens, Erlangen, Germany).

Ureteral orifice dilation was necessary in 4 patients (9.8%). The insertion of the FU was fluoroscopically controlled by sliding on a Nitinol guide wire (Figure 1); no access ureteral sheath was used.

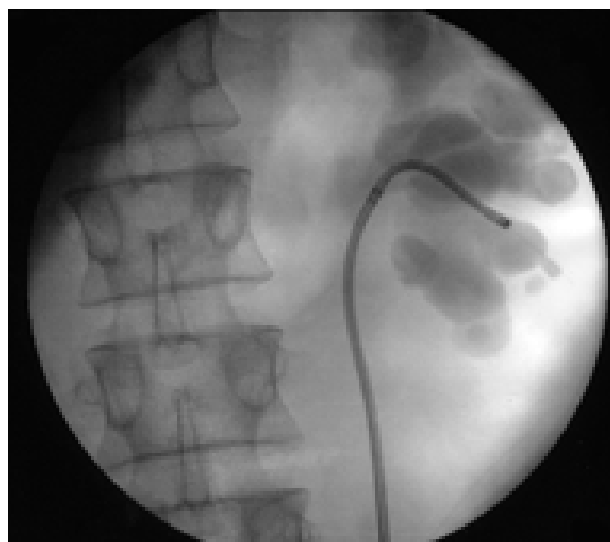

FIG. 1. Flexible ureteroscopic approach to the middle caliceal calculi (fluoroscopic aspect)

In 33 patients (80.4%), ureteral stenting after the procedure was not necessary. Stents were used only in patients who needed meatal dilation (4 cases) and those with significant renal bleeding during lithotripsy (4 cases), which were left in place for 14 days.

The procedure was considered successful if all the calculi were extracted (Figures 2 to 4) or if the resulted fragments were smaller than 3 mm, small enough not to be considered as obstructive. The follow-up protocol included abdominal ultrasonography, plain abdominal radiography (in patients with radio-opaque calculi), and in selected cases (6 patients), IVU.

TABLE 1. Size and location of the kidney calculi

	Number of calculi (%)
Size of the calculi	
< 10 mm	45 (51.7)
10 mm to 20 mm	25 (28.7)
> 20 mm	17 (19.5)
Location of the calculi	
	Number of patients (%)
Pelvic	7 (17)
Inferior calyx	11 (26.8)
Pyelocaliceal	23 (56.1)

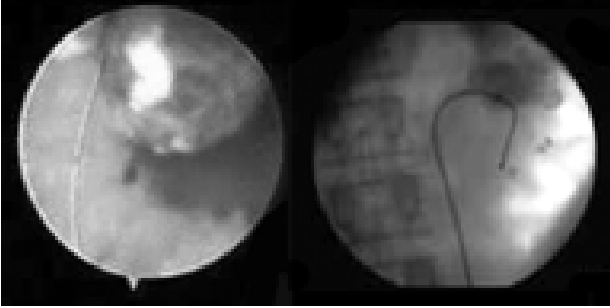


FIG. 2. Multiple caliceal calculi (endoscopic and fluoroscopic intra-operative aspect)

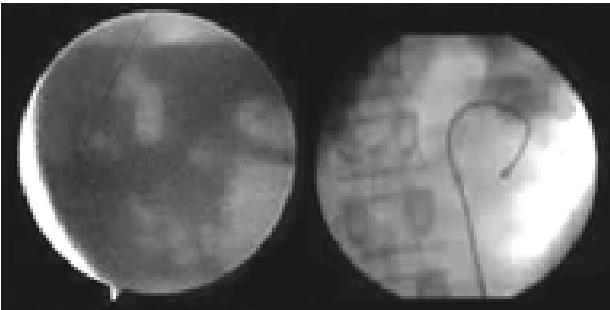


FIG. 3. A stone-free inferior calyx (endoscopic and fluoroscopic intra-operative aspect)

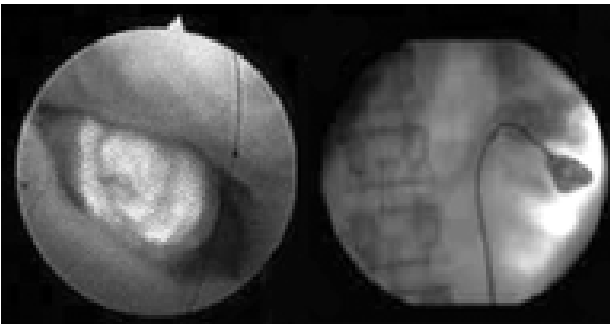


FIG. 4. Middle caliceal calculi (endoscopic and fluoroscopic intra-operative aspect)

Results

The median operative time was 64 minutes (range, 41 to 215 minutes) for pyelocaliceal, 46 minutes (range, 28 to 89 minutes) for pelvic, and 39 minutes (range, 27 to 70 minutes) for inferior caliceal calculi. The mean follow-up period was 7 months (range, 3 to 22 months).

Eleven patients (26.8%) required to repeat the procedure. In 6 of them (54.5%), the initial procedure was interrupted due to a low visibility (bleeding in 5 and pyuria in 1) and lithotripsy was performed in a secondary procedure. In the other 5 patients (45.5%), the inferior caliceal calculi could not be approached by flexible retrograde ureteroscopy, requiring a second procedure.

The overall success rate was 71%; it was 57% for pyelocaliceal, 87% for pelvic, and 71% for inferior

caliceal calculi. Considering the calculi dimensions, the success rate was 78% for calculi sized 10 mm or smaller, 72% for calculi between 11 mm and 20 mm, and 49% for calculi larger than 20 mm.

The causes of FU failure were the impossibility of calculi approach (only in inferior caliceal calculi), impossibility of fragmentation, or the necessity of procedure interruption. In all cases, percutaneous nephrolithotripsy (PCNL) was performed thereafter. There were no major complications or deaths. Complication rate was 7.3% (3 patients) presented as minor complications including hematuria, persistent lumbar pain, and pyelonephritis.

Discussion

The therapeutic options for pyelocaliceal calculi are represented by SWL, FU, and PCNL, selected according to the therapeutic strategy for each patient.

Developed in the 1980s, SWL became the first line treatment of calculi smaller than 20 mm. Although the success rate of this method reaches 92% in selected patients, it is 33% to 65% for calculi larger than 20 mm,^(5,6) and only 41% for inferior caliceal calculi.⁽⁷⁾

In all SWL-resistant calculi, other methods of fragmentation and/or extraction are necessary. Although it has very good results (90% stone-free rate), PCNL is an invasive method with a high morbidity rate.⁽⁸⁾

Allowing, at least theoretically, the access to any upper urinary tract region, FU represents a valuable alternative in the therapeutic arsenal for kidney calculi. Flexible ureteroscopy offers the advantages of direct visualization and extraction of the calculi, followed by inspection of the pyelocaliceal system for potential remnant fragments.⁽⁷⁾

Parameters such as dimension, composition, and multiplicity of the calculi influence the success rate of the lithotripsy methods. The success rate of SWL in lower caliceal calculi is low (41% to 79%).^(7,9,10) Large dimensions of the calculi, higher concentration of cystine or calcium monohydrate oxalate,⁽¹¹⁾ or anatomical particularities of intrarenal ducts (inferior caliceal infundibular length of more than 3 mm and/or a diameter smaller than 5 mm, acute infundibulo-pelvic angle) are associated with a poor SWL success rate.⁽¹²⁾ In the presence of these negative factors, the FU could be a superior alternative.

Grasso and Ficazzola have treated 90 cases of lower pole calculi with a small diameter, actively deflectable, flexible ureteropyeloscope and reported a 94% success rate using FU for inferior caliceal calculi smaller than 10 mm and a 95% rate for those between 11 mm and 20 mm.⁽¹³⁾ Hollenbeck and colleagues have reported a 79 % stone-free rate after one attempt, raised to 88% after the second procedure.⁽¹⁴⁾ The 71 % stone-free rate for inferior caliceal calculi in our study—lower than that in other reports—can be explained by the patient selection (with SWL-resistant calculi) and by the type of energy used to fragment calculi (electrohydraulic lithotripter). In a study on 81 patients with SWL-resistant kidney calculi, Stav and associates have reported a 67 % success rate.⁽⁷⁾

Hallenbeck have suggested that anatomical particularities of intrarenal ducts associated with a poor SWL success rate also makes the endoscopic approach difficult.⁽¹⁴⁾ Likewise, Grasso and Ficazzola have indicated that hydronephrosis, inferior caliceal duct stenosis, and infundibular length of more than 3 mm are most frequently associated with the failure of intrarenal lithotripsy using FU.⁽¹³⁾ Oxalate calcium monohydrate calculi associated with a low SWL success rate are frequently electrohydraulic lithotripsy-resistant. The use of a Holmium laser energy source would probably improve the stone-free rate.⁽¹⁵⁾

The success rate of FU in patients with pyelocaliceal calculi larger than 20 mm is less than 50%; Grasso and Ficazzola have reported the complete fragmentation of calculi of such dimensions in 45% of patients,⁽¹³⁾ and Robert and colleagues have reported it in 47 %.⁽¹⁶⁾ Shock wave lithotripsy is also associated with poor results for this type of calculi (average success rate of 63%). The best therapeutic alternative for this type of calculi remains PCNL.^(5,6,17)

In 14 patients (35%) of our series with obstructive pelvic calculi and hydronephrosis, a double J stent was placed and FU was performed 14 days thereafter. The double J stent reduces the hydronephrosis, enhancing the performances of FU by offering the possibility of obtaining the secondary passive deflection, which allows the access to the inferior caliceal group.

The complication rate reported in literature is between 0% and 13%—mostly due to minor complications.⁽¹¹⁾ Only one major complication was cited: retroperitoneal hematoma in a patient

with uncontrolled hemorrhagic diathesis.⁽¹⁸⁾ Stav and colleagues have reported a 10% rate of minor complications and no major ones.⁽⁷⁾

Because of the reduced dimensions of the flexible ureteroscope, the injury to the upper urinary tract is minimal⁽¹⁹⁾; this technical particularity associated with an adequate preoperative assessment makes FU a safe method with a lower morbidity and practically no mortality.

Conclusion

Flexible ureteroscopy can be an efficient treatment alternative in kidney calculi, especially in SWL-resistant calculi smaller than 20 mm. This method provides a good approach for inferior caliceal calculi (with a success rate higher in selected cases than that obtained by SWL). For calculi larger than 20 mm, the most efficient method remains PCNL, despite its higher morbidity rate.

Overall, respecting the anatomical urinary tract, FU is a minimally invasive method with a low morbidity rate.

References

1. Marshall VF. Fiber optics in urology. *J Urol.* 1964;91:110-4.
2. Bagley DH, Huffman JL, Lyon ES. Combined rigid and flexible ureteropyeloscopy. *J Urol.* 1983;130:243-4.
3. Bagley DH, Huffman JL, Lyon ES. Flexible ureteropyeloscopy: diagnosis and treatment in the upper urinary tract. *J Urol.* 1987;138:280-5.
4. Grasso M. Ureteroscopy. *eMedicine* [cited 2002 May 29]. Available from: <http://www.emedicine.com/med/topic3079.htm>
5. Tiselius HG, Ackermann D, Alken P, Buck C, Conort P, Gallucci M; Working Party on Lithiasis, European Association of Urology. Guidelines on urolithiasis. *Eur Urol.* 2001;40:362-71.
6. Lingeman JE, Lifshitz DA, Evan AP. Surgical management of urinary lithiasis. In: Walsh PC, Retik AB, Vaughan ED Jr, et al, editors. *Campbell's urology.* 8th ed. Philadelphia: WB Saunders; 2002. p. 3361-436.
7. Stav K, Cooper A, Zisman A, Leibovici D, Lindner A, Siegel YI. Retrograde intrarenal lithotripsy outcome after failure of shock wave lithotripsy. *J Urol.* 2003;170:2198-201.
8. Kerbl K, Rehman J, Landman J, Lee D, Sundaram C, Clayman RV. Current management of urolithiasis: progress or regress? *J Endourol.* 2002;16:281-8.
9. Lingeman JE, Siegel YI, Steele B, Nyhuis AW, Woods JR. Management of lower pole nephrolithiasis: a critical analysis. *J Urol.* 1994;151:663-7.
10. Netto NR Jr, Claro JF, Lemos GC, Cortado PL. Renal

calculi in lower pole calices: what is the best method of treatment? *J Urol.* 1991;146:721-3.

11. Busby JE, Low RK. Ureteroscopic treatment of renal calculi. *Urol Clin North Am.* 2004;31:89-98.
12. Elbahnasy AM, Shalhav AL, Hoenig DM, et al. Lower caliceal stone clearance after shock wave lithotripsy or ureteroscopy: the impact of lower pole radiographic anatomy. *J Urol.* 1998;159:676-82.
13. Grasso M, Ficazzola M. Retrograde ureteropyeloscopy for lower pole caliceal calculi. *J Urol.* 1999;162:1904-8.
14. Hollenbeck BK, Schuster TG, Faerber GJ, Wolf JS. Flexible ureteroscopy in conjunction with in situ lithotripsy for lower pole calculi. *Urology.* 2001;58:859-63.
15. Sofer M, Watterson JD, Wollin TA, Nott L, Razvi H, Denstedt JD. Holmium:YAG laser lithotripsy for upper urinary tract calculi in 598 patients. *J Urol.* 2002;167:31-4.
16. Robert M, Drianno N, Marotta J, Delbos O, Guiter J, Grasset D. [The value of retrograde ureterorenoscopy in the treatment of bulky kidney calculi]. *Prog Urol.* 1997;7:35-41. French.
17. Conort P, Dore B, Saussine C; Comite Lithiase de l'Association Francaise d'Urologie. [Guidelines for the urological management of renal and ureteric stones in adults]. *Prog Urol.* 2004;14:1095-102. French.
18. Watterson JD, Girvan AR, Cook AJ, et al. Safety and efficacy of holmium: YAG laser lithotripsy in patients with bleeding diatheses. *J Urol.* 2002;168:442-5.
19. Bagley DH. Ureteroscopic surgery: changing times and perspectives. *Urol Clin North Am.* 2004;31:1-4, vii.

Editorial Comment

Consistent with other reports, the success rate of ureteroscopy in the treatment of calculi greater than 2 cm and multiple pyelocaliceal calculi was lower in this study. However, it should be noted that the patients with such calculi constituted a very smaller proportion of the patients in this report. Thus, with a larger sample size and increasing the surgeons' experience, a different outcome may be achieved. Moreover, the

relatively low success rate in patients with multiple calculi could be related to the total size of the calculi.

The authors have mentioned that the energy source was provided by an electrohydraulic lithotripter. Nonetheless, using holmium laser is nowadays a more recommended method as electrohydraulic lithotripsy can lead to injuries to the ureteral mucosa and damage to the ureteroscope lens. This can explain the cause of intra-operative bleeding in 5 out of 41 patients, resulting in lithotripsy failure.

Abbas Basiri

*Department of Urology, Shaheed
Labbafinejad Medical Center,
Shaheed Beheshti University of
Medical Sciences, Tehran, Iran*

Reply by Author

Indeed, the electrohydraulic lithotripsy has some disadvantages comparing with laser lithotripsy: lower success rate in stone fragmentation, higher risk of damaging the pyelocaliceal mucosa, and the ureteroscope's optical system. Nonetheless, electrohydraulic lithotripsy presents some advantages: lower costs and also a higher flexibility of the thin 1.6-F electrohydraulic probes, in comparison with the 200- μ m laser fiber. These flexible probes inserted through the working channel have a reduced influence on the maximum deflection angle of the flexible ureteroscope, important when the access to the inferior calyx is difficult.

Seyed Abdulah Seyed Aghamiri
*Department of Urology, St John
Clinical Emergency Hospital,
Bucharest, Romania*