

President, Staff Society  
M. E. Yeolekar

Editor  
Sandeep Bavdekar

Associate Editors  
Nithya Gogtay  
D. Muzumdar

Consulting Editors  
Vinita Salvi  
Pradip Vaideeswar  
Manjula Sarkar

Ombudsman  
Sunil Pandya

Managing Editor  
D. K. Sahu

Members  
Amita Mehta  
Anil Patwardhan  
Atul Goel  
Avinash Supe  
Keya Lahiri  
Prafulla Kerkar  
Pritha Bhuiyan  
Rajeev Satoskar  
Sucheta Dandekar  
Uday Khopkar

Editorial Assistants  
Anahita Chauhan  
Jignesh Gandhi  
Anita Mathew

Advisory Board  
Thomas B. Ferguson, *USA*  
Nobuo Hashimoto, *Japan*  
Laurence Klotz, *Canada*  
Nora Noni MacDonald, *Canada*  
Anand Malaviya, *India*  
Ana Marusic, *Croatia*  
V. Mohan, *India*  
Dan J. Ncayiyana, *South Africa*  
G. B. Parulkar, *India*  
David J. Pierson, *USA*  
Andrew P. Schachat, *USA*  
Shirish S. Sheth, *India*  
Michael Swash, *UK*  
P. N. Tandon, *India*  
Jim Thornton, *UK*  
Jean-Louis Vincent, *Belgium*

## Contents

### EDITORIAL

- Indian festivals: Ethos and health impact  
*Yeolekar ME, Bavdekar SB* 219

### ORIGINAL ARTICLES

- A prospective randomized comparative study of the effects of intranasal and transdermal 17  $\beta$ -estradiol on postmenopausal symptoms and vaginal cytology  
*Odabaşı AR, Yüksel H, Demircan SS, Kaçar DF, Çulhacı N, Özkara EE* 221
- Miliary tuberculosis in human immunodeficiency virus infected patients not on antiretroviral therapy: Clinical profile and response to short-course chemotherapy  
*Swaminathan S, Padmapriyadarsini C, Ponnuraja C, Sumathi CH, Rajasekaran S, Amerandran VA, Reddy MVK, Deivanayagam CN* 228
- Retrospective study of severe cases of leptospirosis admitted in the intensive care unit  
*Ittyachen AM, Krishnapillai TV, Nair MC, Rajan AR* 232
- Field rats form a major infection source of leptospirosis in and around Madurai, India  
*Priya CG, Hoogendijk KT, Berg MVD, Rathinam SR, Ahmed A, Muthukkaruppan VR, Hartskeerl RA* 236
- Regional brain metabolism in schizophrenia: The influence of antipsychotics  
*Seethalakshmi R, Parkar SR, Nair N, Batra SA, Pandit AG, Adarkar SA, Baghel NS, Moghe SH* 241

### CASE REPORTS

- Tumoral calcinosis of the foot with unusual presentation in an 11-year-old boy: A case report and review of literature  
*Mohamed S, Jong-Hun J, Weon-Yoo K* 247
- Immune reconstitution inflammatory syndrome in a patient with cryptococcal lymphadenitis as the first presentation of acquired immunodeficiency syndrome  
*Tahir M, Sharma SK, Sinha S, Das CJ* 250
- Great auricular nerve involvement in leprosy: Scope for misdiagnosis  
*Ramesh V, Jain RK, Avinder S* 253

### IMAGES IN RADIOLOGY

- Snap sound and detumescence: Fracture penis  
*Rao A, Surendrababu NRS* 255

### REVIEW ARTICLE

- One gene, many phenotypes  
*Prasun P, Pradhan M, Agarwal S* 257

### VIEW POINT

- Religion, spirituality, health and medicine: Why should Indian physicians care?  
*Chattopadhyay S* 262

Journal of Postgraduate Medicine is indexed/listed with Index Medicus, MEDLINE, Current Contents-Clinical Medicine, Science Citation Index, Excerpta Medica/EMBASE, Bioline International, CAB Abstracts, Global Health, Index Copernicus, Cumulative Index to Nursing and Allied Health Literature, CINAHL Database, DOAJ, SIIC Databases, Allied and Complementary Medicine Database, CIRRIE Database of International Rehabilitation Research, MANTIS, Indian Science Abstracts, Health and Wellness Research Center, Health Reference Center Academic, InfoTrac One File, Expanded Academic ASAP, ProQuest Databases, getCITED, POPLINE, CANCERLIT, TOXLINE, CAIH, Jeffline, PsychLine, e-psyche, DERMLINE, UltraMED, OCLC FirstSearch, OCLC ContentsFirst, Genamics JournalSeek, Ulrich's International Periodical Directory, NIWI, and CISTI Source Journals.

The journal is official publication of the Staff Society of Seth G. S. Medical College and K. E. M. Hospital, Mumbai, India and is managed, printed and distributed by Medknow Publications. Issues are published quarterly in the last week of January, April, July and October.

All the rights are reserved. Apart from any fair dealing for the purposes of research or private study, or criticism or review, no part of the publication can be reproduced, stored, or transmitted, in any form or by any means, without the prior permission of the Editor, Journal of Postgraduate Medicine.

Journal of Postgraduate Medicine and/or its publisher cannot be held responsible for errors or for any consequences arising from the use of the information contained in this journal.

The appearance of advertising or product information in the various sections in the journal does not constitute an endorsement or approval by the journal and/or its publisher of the quality or value of the said product or of claims made for it by its manufacturer.

The Journal is printed on acid free paper.

#### Editorial Office

Department of Neurosurgery,  
Seth GS Medical College and KEM Hospital, Parel, Mumbai 400012, India.  
E-mail: [jpgm@jpgmonline.com](mailto:jpgm@jpgmonline.com)

#### Administrative Office

Medknow Publications,  
A-108/109 Kanara Business Centre, Chhatkopar (E), Mumbai - 400075, India.  
Phone: 91-22-6649 1818/1816  
Fax: 91-22-6649 1817  
Website: [www.medknow.com](http://www.medknow.com)

#### Websites

<http://www.jpgmonline.com>  
<http://www.journalonweb.com/jpgm>  
<http://www.bioline.org.br/jp>

## STUDENTS' CORNER

The Bayesian clinician  
*Kulkarni UP*

267

## LETTERS

Natural history of non-ischemic central retinal vein occlusion versus iatrogenic intervention	270
Authors' reply	270
Replacing the illogic of anesthesia by the logic of aneuronia	271
Drug rash with eosinophilia and systemic symptoms syndrome due to quinine	272
A massive myxoid liposarcoma with hyperferritinemia	273
Risedronate induced transient ocular myasthenia	274
Exposure to blood-borne viruses among healthcare workers in a tertiary care hospital in south India	275
Gabapentin and hypersensitivity syndrome	276
Diagnostic accuracy and specialist consultation patterns upon transient loss of consciousness in primary health care	277
Angiodysplasia of colon in a seven-year-old boy: A rare cause of intestinal bleeding	278

## AUTHOR INDEX, 2007

280

## TITLE INDEX, 2007

283

## SUBSCRIPTION DETAILS

235,279

# Retrospective study of severe cases of leptospirosis admitted in the intensive care unit

Ittyachen AM, Krishnapillai TV, Nair MC, Rajan AR

Division of Critical Care and Emergency Services; Department of Medicine, MOSC Medical College, Kolenchery, Cochin, Kerala, India

## Correspondence:

Abraham M Ittyachen  
E-mail: abylyz@rediffmail.com

Received : 17-11-06  
Review completed : 03-09-07  
Accepted : 15-09-07  
PubMed ID : ????

J Postgrad Med 2007;53:232-5

## ABSTRACT

**Objectives:** Evaluate patient demographics, risk factors, complications, seropositivity, treatment and outcome among leptospirosis patients. **Design:** Retrospective analysis of 104 patients admitted in the intensive care unit (ICU) with a clinical suspicion of leptospirosis. **Setting:** Ten-bedded medical ICU in a medical school situated in a rural area endemic for leptospirosis. **Main Outcome Measures:** Seropositivity for leptospirosis, patient demographics, risk factors, complications, treatment and survival. **Results:** One hundred and four patients were admitted with a clinical suspicion of leptospirosis. Fifty-three (50.7%) were serologically confirmed cases. Males dominated both groups. Most of the admissions were in the monsoon season. Exposure to moist soil was the main risk factor. The mortality in the seronegative group was 26.8% while it was only 3.8% in the seropositive group. Multi-organ dysfunction syndrome, primarily acute respiratory distress syndrome with thrombocytopenia and renal failure were the causes for mortality. All the patients who died presented late into the illness. **Conclusions:** The initial diagnosis of leptospirosis depends on a high index of clinical suspicion, routinely available diagnostic tests being unreliable in the initial period. A reliable, unsophisticated test should be developed for early detection of this disease. As leptospirosis in its early stage mimics other tropical infections, both medical professionals and the general public (especially with risk of occupational exposure) should be educated about the disease and the need to seek early medical intervention.

**KEY WORDS:** Acute respiratory distress syndrome, leptospirosis, thrombocytopenia

Leptospirosis is an important zoonotic disease with a worldwide distribution.<sup>[1]</sup> The disease has a wide spectrum of manifestation varying from mild influenza-like illness to fulminant and often fatal presentation with multi-organ involvement (Weil's disease). Though advances have taken place in the treatment of leptospirosis, especially involving critical life supports and intensive care unit (ICU) care, the initial diagnosis of leptospirosis still remains presumptive taking into consideration the clinical presentation, risk factors and residence in an endemic area. Tests considered as 'gold-standard' in the diagnosis of leptospirosis such as seroconversion, rise in antibody titer and leptospiral culture become positive only late into the illness; antibody levels attain detectable levels only by the second week and culture may take two to four weeks.<sup>[2]</sup> By this period the disease would have taken its course. Hence these tests do not contribute significantly in the initial diagnosis of leptospirosis.

Our hospital is situated in an area endemic for leptospirosis. The economy is predominantly agrarian with rice, pineapple and cash crops like rubber and spices being cultivated. Serologically confirmed cases of leptospirosis were first reported from our institution in 1987-1988 and leptospira was first cultured in 1989.<sup>[3]</sup> A new serovar has also been identified.<sup>[3]</sup>

This study was done to evaluate the patient demographics, risk factors, complications, seropositivity, treatment and outcome among patients admitted with a clinical diagnosis of leptospirosis in our ICU.

## Materials and Methods

The study was done between 1<sup>st</sup> January, 2005 and 30<sup>th</sup> June, 2006 (18 months). Patients admitted to the ICU with a clinical diagnosis of leptospirosis were included in the study. The initial diagnosis was based on the clinical scoring system proposed by Faine (WHO guidelines).<sup>[4]</sup> Patients were also screened for other common tropical infections with similar clinical presentations. Dyspnoea, thrombocytopenia, renal failure, hypotension and myocarditis were the indications for ICU admission. Thrombocytopenia was taken as platelet count of less than 100,000/cu.mm and renal failure was defined as serum creatinine of more than 1.4 mg%. The diagnosis of ARDS/ALI (acute respiratory distress syndrome / acute lung injury) was based on the North American-European Consensus Conference Criteria.<sup>[5]</sup> The IgM antibody to leptospira was considered positive when the titer was above 80 (tested at admission and after one week if the patient survived). This was based on unpublished data from our hospital, data which supported an earlier study.<sup>[3]</sup> The patient's

demographic details, month of admission, risk for leptospirosis, leptospira IgM antibody positivity (serologically confirmed cases), complications, treatment details and outcome were reviewed.

All patients received crystalline penicillin which is the standard antibiotic for leptospirosis.<sup>[6]</sup> Platelets were transfused prophylactically when the platelet count fell below 15,000/cu.mm. Cases of ARDS/ALI received mechanical ventilation (invasive/noninvasive) and methylprednisolone.

**Results**

One hundred and four patients were admitted with a clinical suspicion of leptospirosis. Fifty-three (50.7%) were serologically confirmed cases; forty-one (39.4 %) were serologically negative (clinically leptospirosis) and 10 (9.6 %) were confirmed to have other diseases.

Males dominated both groups, 40 (75.5%) in the serologically positive group and 40 (75.5%) in the serologically negative group. In both groups the majority of patients were between 20 to 60 years of age.

Figure 1 shows that most of the admissions were between June to September. Exposure to soil and water (farming, especially rice) were the main risk factors; laborers in pineapple orchards and rubber tappers were also involved

Increase in liver enzymes, renal failure, thrombocytopenia and ARDS/ALI were the main complications; pancreatitis, myocarditis and pneumonia were also seen [Table 1].

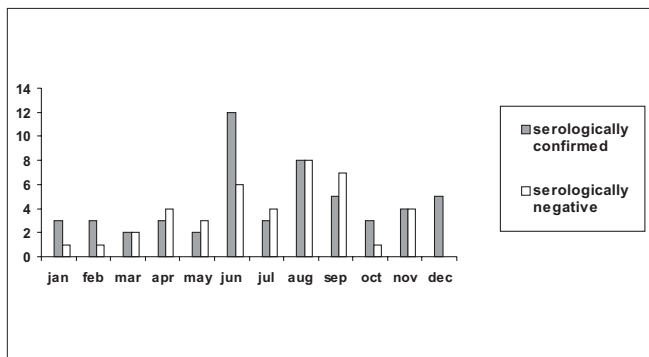


Figure 1: Seasonal distribution of patients

Fifteen patients received platelet transfusion in both the groups. Nine patients (five in the serologically positive group and four in the serologically negative group) had to be dialyzed.

The mortality in the seronegative group was 26.8% while it was only 3.8% in the seropositive group. The two patients who died in the serologically positive group had ARDS with multi-organ dysfunction syndrome (MODS) - primarily thrombocytopenia and renal failure. In the serologically negative group 11 patients died, six patients of ARDS and five with MODS [Figure 2]. All the patients who died presented late into the illness.

**Discussion**

Of the 104 patients admitted with a presumptive diagnosis of leptospirosis, only 50.7% had serological evidence of leptospirosis. This is in agreement with WHO data; the initial diagnosis of leptospirosis still remains clinical, a presumptive one made in the correct epidemiological and clinical context.<sup>[4]</sup> As there is a clear correlation between complications and delay in onset of treatment<sup>[2]</sup> it is also imperative that a diagnosis be made early. Also, there is the confounding factor of other tropical infections with similar clinical presentations<sup>[2]</sup> to be taken care of. In this series 9.6% were confirmed to have other diseases (six were confirmed to have dengue fever, two had hepatitis-A, one was HIV positive and one turned out to be myelofibrosis). Routinely available serological tests such as microscopic agglutination test (MAT) and enzyme-linked immunosorbent assay (ELISA) do not become positive until the second week. In addition, low titers or a delayed response may be observed in severe cases, in immunosuppressed patients and when high doses of antibiotics are administered in the early phase of the disease.<sup>[2]</sup> For these reasons detection of IgM

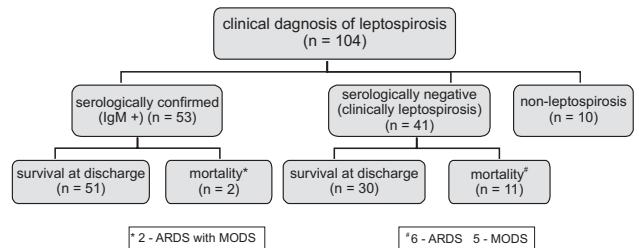


Figure 2: Distribution (and outcome) of patients admitted with clinical suspicion of leptospirosis

Table 1: Distribution of complications in serologically positive and negative groups

	Total (n - 94)	Serologically confirmed (n - 53)	Serologically negative (n - 41)
Increased liver enzymes	75 (79.8)	45 (84.9)	30 (73.2)
Renal failure	70 (74.5)	40 (75.5)	30 (73.2)
Thrombocytopenia	62 (66)	39 (73.6)	23 (56.1)
ARDS / ALI	12 (12.8)	6 (11.3)	6 (14.6)

Pancreatitis - 2 in serologically confirmed and 1 in serologically negative group, Myocarditis - 2 in serologically confirmed and 1 in serologically negative group, Pneumonia - 2 in serologically confirmed and none in serologically negative group, Figures in parentheses are in percentage

antibody to leptospirosis may not be reliable. This could also be a plausible explanation for serological negativity and the disproportionate mortality (severity of illness), in this group in this study. Though rapid leptospiral antigen detection tests as PCR (polymerase chain reaction) are available this requires special equipment, dedicated laboratory space and also highly skilled personnel.<sup>[2]</sup>

Preponderance of male involvement in this study reflects the high risk of occupational exposure in this group. The fact that the majority were in the productive age-group is of concern as often they are the sole bread-winners in the family.

June to September corresponds to the monsoon season when risk for leptospirosis is highest and admissions were also maximum during this time. The risk of leptospirosis among those involved in rice cultivation is well known. We also describe the involvement of pineapple farmers and rubber tappers; abrasions caused by the serrated edges of the pineapple plant and the rubber tapper's knife may be the portal of entry for the organism.

The classic presentation of leptospirosis is a biphasic illness with complications occurring in the second phase. Important causes of death include renal failure, cardiopulmonary failure and widespread hemorrhage.<sup>[2]</sup> Leptospirosis with multi-organ involvement uniformly carries a poor prognosis and is more common in patients in whom there has been a delay in the initiation of antibiotics.<sup>[2]</sup> This was true of all the patients who expired in this study. Also, the benefit of antibiotics after the fifth day of the disease is controversial.<sup>[2]</sup> The disproportionate mortality, 3.8% in the confirmed group and 26.8% in the negative group probably reflects the severity of illness; a poor antibody response has already been described in those with severe illness.<sup>[2]</sup>

Many case reports, clinical series and descriptions of outbreaks have documented pulmonary involvement in leptospirosis.<sup>[7,8]</sup> Direct involvement of the organism,<sup>[9]</sup> inflammatory mediators<sup>[10]</sup> and vasculitis have all been incriminated as the cause.<sup>[11,12]</sup> The evidence for use of steroids in ARDS is conflicting<sup>[13]</sup> but we have observed it to be useful when used in early ARDS due to leptospirosis and have reported it;<sup>[14]</sup> later studies confirm the same.<sup>[15]</sup> All the patients with ARDS in the serologically negative group died in this study while only two out of four died in the confirmed group.

Renal involvement is common in leptospirosis. Prognosis in renal failure is usually good unless complicated by multi-organ involvement.<sup>[16]</sup> All the patients who died of renal failure (one in the serologically positive group and two in the serologically negative group) in this study had multi-organ damage. Bacterial invasion, inflammatory processes, hemodynamic alterations and direct toxicity of bacterial products all contribute to the nephropathy of leptospirosis.<sup>[17,18]</sup> Interstitial nephritis is the basic lesion seen.<sup>[19]</sup>

Unlike renal failure the pathogenesis of thrombocytopenia in leptospirosis is not well elucidated. Postulates include

disseminated intravascular coagulation (DIC),<sup>[20]</sup> toxin-mediated mechanism,<sup>[21]</sup> as a direct complication of leptospiral vasculitis or due to an undetected platelet antibody.<sup>[22]</sup> Though thrombocytopenia with widespread hemorrhage is described as one of the complications<sup>[2]</sup> in leptospirosis, this was not observed in our series.

Increase in liver enzymes - SGPT/ALT and SGOT/AST (up to five times the normal) with a disproportionately high jaundice which was seen in this study has been described as a prognostic marker in leptospirosis.<sup>[23]</sup> This was the predominant finding in both the groups in this study.

Pancreatitis,<sup>[24]</sup> myocarditis<sup>[25,26]</sup> and pneumonia,<sup>[27,28]</sup> the other complications reported in this series are described in leptospirosis.

### Conclusion

Leptospirosis is a zoonotic disease with multi-system involvement in severe cases. Advances in critical care life supports may have improved the prognosis of this disease but the initial diagnosis still depends on a high index of clinical suspicion, routinely available diagnostic tests being unreliable in the initial period. Development of a reliable, unsophisticated diagnostic technique for early detection would mitigate this problem.

As leptospirosis in its early stage mimics other tropical infections of less severity, there is a need to educate both medical professionals and the general public (especially with risk of occupational exposure) about the disease and the need to seek early medical intervention.

The pathogenesis and treatment of complications of leptospirosis like renal failure, thrombocytopenia and ARDS, especially the role of steroids merits further evaluation.

### Acknowledgment

The authors wish to acknowledge the help given by Dr. Marina Rajan Joseph, Associate Professor and Mrs. Celine T.M, Assistant Professor, of Department of Community Medicine, M.O.S.C Medical College.

### References

1. Bharti AR, Nally JE, Ricalde JN, Matthias MA, Diaz MM, Lovett MA, *et al.* Leptospirosis: A zoonotic disease of global importance. *Lancet Infect Dis* 2003;3:757-71.
2. Terpstra WJ. International leptospirosis Society. Human Leptospirosis: Guidance for diagnosis, surveillance and control. World Health Organization: Geneva: 2003.
3. Kuriakose M, Eapen CK, Paul R. Leptospirosis in Kolenchery, Kerala, India: Epidemiology, prevalent local serogroups and serovars and a new serovar. *Eur J Epidemiol* 1997;13:691-7.
4. Faine S. Guidelines for the control of Leptospirosis. World Health Organization: Geneva; 1982. WHO offset publication No. 67.
5. Bernard GR, Artigas A, Brigham KL, Carlet J, Falke K, Hudson L, *et al.* The American-European Consensus Conference on ARDS: Definitions, mechanisms, relevant outcomes and clinical trial coordination. *Am J Respir Crit Care Med* 1994;149:818-24.
6. Watt G, Padre LP, Tuazon ML, Calubaquib C, Santiago E, Ranoa CP, *et al.* Placebo-controlled trial of intravenous penicillin for severe and

- late leptospirosis. *Lancet* 1988;1:433-5.
7. O'Neil KM, Rickman LS, Lazarus AA. Pulmonary manifestations of leptospirosis. *Rev Infect Dis* 1991;13:705-9.
  8. Martínez García MA, de Diego Damia A, Menendez Villanueva R, López Hontagas JL. Pulmonary involvement in leptospirosis. *Eur J Clin Microbiol Infect Dis* 2000;19:471-4.
  9. Silva JJ, Dalston MO, Carvalho JE, Setubal S, Oliveira JM, Pereira MM. Clinicopathological and immunohistochemical features of the severe pulmonary form of leptospirosis. *Rev Soc Bras Med Trop* 2002;35:395-9.
  10. Nally JE, Chantranuwat C, Wu XY, Fishbein MC, Pereira MM, Da Silva JJ, *et al.* Alveolar septal deposition of immunoglobulin and complement parallels pulmonary hemorrhage in a guinea pig model of severe pulmonary leptospirosis. *Am J Pathol* 2004;164:1115-27.
  11. Miller NG, Allen JE, Wilson RB. The pathogenesis of hemorrhage in the lung of the hamster during acute leptospirosis. *Med Microbiol Immunol* 1974;160:269-78.
  12. De Brito T, Bohm GM, Yasuda PH. Vascular damage in acute experimental leptospirosis of the guinea-pig. *J Pathol* 1979;128:177-82.
  13. Steinberg KP, Hudson LD, Goodman RB, Hough CL, Lanken PN, Hyzy R, *et al.* Efficacy and safety of corticosteroids for persistent acute respiratory distress syndrome. *N Engl J Med* 2006;354:1671-84.
  14. Ittyachen AM, Lakshmanakumar VK, Eapen CK, Joseph MR. Methylprednisolone as adjuvant in treatment of acute respiratory distress syndrome owing to leptospirosis: A pilot study. *Indian J Crit Care Med* 2005;9:133-6.
  15. Shenoy VV, Nagar VS, Chowdhury AA, Bhargat PS, Juvale NI. Pulmonary leptospirosis: An excellent response to bolus methylprednisolone. *Postgrad Med J* 2006;82:602-6.
  16. Daher E, Zanetta DM, Cavalcante MB, Abdulkader RC. Risk factors for death and changing patterns in leptospirosis acute renal failure. *Am J Trop Med Hyg* 1999;61:630-4.
  17. Sitprijia V, Losuwanrak K, Kanjanabuch T. Leptospiral nephropathy. *Semin Nephrol* 2003;23:42-8.
  18. Sitprijia V. Overview of tropical nephrology. *Semin Nephrol* 2003;23:3-11.
  19. Visith S, Kearkiat P. Nephropathy in leptospirosis. *J Postgrad Med* 2005;51:184-8.
  20. Sitprijia V, Papatanagul V, Mertowidjojo K, Boonpcknavig V, Boonpcknavig S. Pathogenesis of renal disease in leptospirosis: Clinical and experimental studies. *Kidney Int* 1980;17:827-36.
  21. O'Neil KM, Rickman LS, Lazarus AA. Pulmonary manifestations of leptospirosis. *Rev Infect Dis* 1991;13:705-9.
  22. Kahn JB. A case of Weil's disease requiring steroid therapy for thrombocytopenia and bleeding. *Am J Trop Med Hyg* 1982;31:1213-5.
  23. Chang ML, Yang CW, Chen JC, Ho YP, Pan MJ, Lin CH, *et al.* Disproportional exaggerated aspartate transaminase is a useful prognostic parameter in late leptospirosis. *World J Gastroenterol* 2005;11:5553-6.
  24. Edwards CN, Evarard CO. Hyperamylasemia and pancreatitis in leptospirosis. *Am J Gastroenterol* 1991;86:1665-8.
  25. Edwards CN, Nicholson GD, Hassell TA, Everard CO, Callender J. Leptospirosis in Barbados: A clinical study. *West Indian Med J* 1990;39:27-34.
  26. de Brito T, Morais CF, Yasuda PH, Lancellotti CP, Hoshino-Shimizu S, Yamashiro E, *et al.* Cardiovascular involvement in human and experimental leptospirosis: Pathologic findings and immunohistochemical detection of leptospiral antigen. *Ann Trop Med Parasitol* 1987;81:207-14.
  27. Teglia OF, Battagliotti C, Villavicencio RL, Cunha BA. Leptospiral pneumonia. *Chest* 1995;108:874-5.
  28. Hill MK, Sanders CV. Leptospiral pneumonia. *Semin Respir Infect* 1997;12:44-9.

**Source of Support:** Nil, **Conflict of Interest:** None declared.