

Reversal of Central Nervous System and Cardiac Toxicity After Local Anesthetic Intoxication by Lipid Emulsion Injection

Rainer J. Litz, MD

Thomas Roessel, MD

Axel R. Heller, MD

Sebastian N. Stehr, MD

A 91-yr-old man (57 kg, 156 cm, ASA III) received an infraclavicular brachial plexus block for surgery of bursitis of the olecranon. Twenty minutes after infraclavicular injection of 30 mL of mepivacaine 1% (Scandicain®) and 5 min after supplementation of 10 mL of prilocaïne 1% (Xylonest®) using an axillary approach, the patient complained of agitation and dizziness and became unresponsive to verbal commands. In addition, supraventricular extrasystole with bigeminy occurred. Local anesthetic toxicity was suspected and a dose of 200 mL of a 20% lipid emulsion was infused. Symptoms of central nervous system and cardiac toxicity disappeared within 5 and 15 min after the first lipid injection, respectively. Plasma concentrations of local anesthetics were determined before, 20, and 40 min after lipid infusion and were 4.08, 2.30, and 1.73 $\mu\text{g}/\text{mL}$ for mepivacaine and 0.92, 0.35, and 0.24 $\mu\text{g}/\text{mL}$ for prilocaïne. These concentrations are below previously reported thresholds of toxicity above 5 $\mu\text{g}/\text{mL}$ for both local anesthetics. Signs of toxicity resolved and the patient underwent the scheduled surgical procedure uneventfully under brachial plexus blockade.

(Anesth Analg 2008;106:1575-7)

Laboratory investigations have suggested that lipid emulsion infusion may be a treatment option for local anesthetic (LA)-induced systemic toxicity after failure of established resuscitation measures.^{1,2} Recently, two case reports described successful resuscitation of patients after ropivacaine- and bupivacaine-related cardiac arrest, respectively.^{3,4} The exact mechanism of lipid emulsion reversal of toxicity is unclear; however, recent data support the theory of a "lipid sink" by demonstrating decreased cardiac bupivacaine concentrations after lipid infusion in the isolated heart⁵ and a possible positive metabolic effect of lipid infusion.⁶ The usefulness of lipid infusion has been reported for the more cardiotoxic LAs ropivacaine and bupivacaine, but not for the less cardiotoxic mepivacaine or prilocaïne. We report a case of systemic LA intoxication after infraclavicular plexus block with 30 mL mepivacaine 1%, and 10 mL prilocaïne 1%, which was successfully treated by infusion of 200 mL of a 20% lipid solution.

CASE REPORT

A 91-yr-old man (57 kg, 156 cm, ASA III) with exacerbated chronic obstructive pulmonary disease was admitted for olecranon bursitis surgery. His medical history included hypertension, coronary ischemic heart disease (stage I), myocardial insufficiency (New York Heart Association II) and reflux esophagitis complicated by repeated gastrointestinal bleeding. His medications included ambroxol-HCl, omeprazol, and esomeprazol. In the operating room, a 5-lead electrocardiogram, pulse oximetry, noninvasive arterial blood pressure measurement (5-min intervals), and peripheral venous access were established. An infraclavicular brachial plexus block was performed using a 22-gauge short bevel insulated needle with nerve stimulation. During needle advancement, blood was aspirated and the needle was redirected uneventfully. After eliciting motor responses and a negative aspiration test, 30 mL of plain mepivacaine 1% (Scandicain®, Astra, Wedel) was slowly injected. Because of block of the ulnar nerve was incomplete after 15 min, the block was supplemented with 10 mL of plain prilocaïne 1% (Xylonest®, Astra) by an axillary approach after a negative aspiration test.

Within 5 min, the patient complained of dizziness, nausea, and agitation, and became unresponsive to verbal commands. He immediately received oxygen by mask and 12.5 mg dolastrone IV. His heart rate increased from 76 to 92 bpm and supraventricular extrasystoles with intermittent bigeminy appeared (Fig. 1A). His arterial blood pressure increased from 160/70 to 190/90 mm Hg and was then measured every minute. LA toxicity was suspected and an IV bolus of 1 mL/kg Intralipid 20%® was injected and repeated after 3 min (total of 100 mL). A continuous Intralipid infusion was started at a rate of 14 mL/min (0.25 mL · kg⁻¹ · min⁻¹). The patient regained consciousness within 5 min after the first lipid injection. Because extrasystoles were still apparent, lipid infusion was continued up to a total dose of 200 mL when extrasystoles disappeared (Fig. 1B). Blood samples were drawn, centrifugated, and stored at

From the Department of Anesthesiology and Intensive Care Medicine, University Hospital Carl Gustav Carus, University of Technology, Dresden, Germany.

Accepted for publication December 18, 2007.

Address correspondence and reprint requests to Dr. Rainer J. Litz, Department of Anesthesiology and Intensive Care Medicine, University Hospital Carl Gustav Carus, University of Technology, Fetscherstr. 74, 01307 Dresden, Germany. Address e-mail to rainer.litz@uniklinikum-dresden.de.

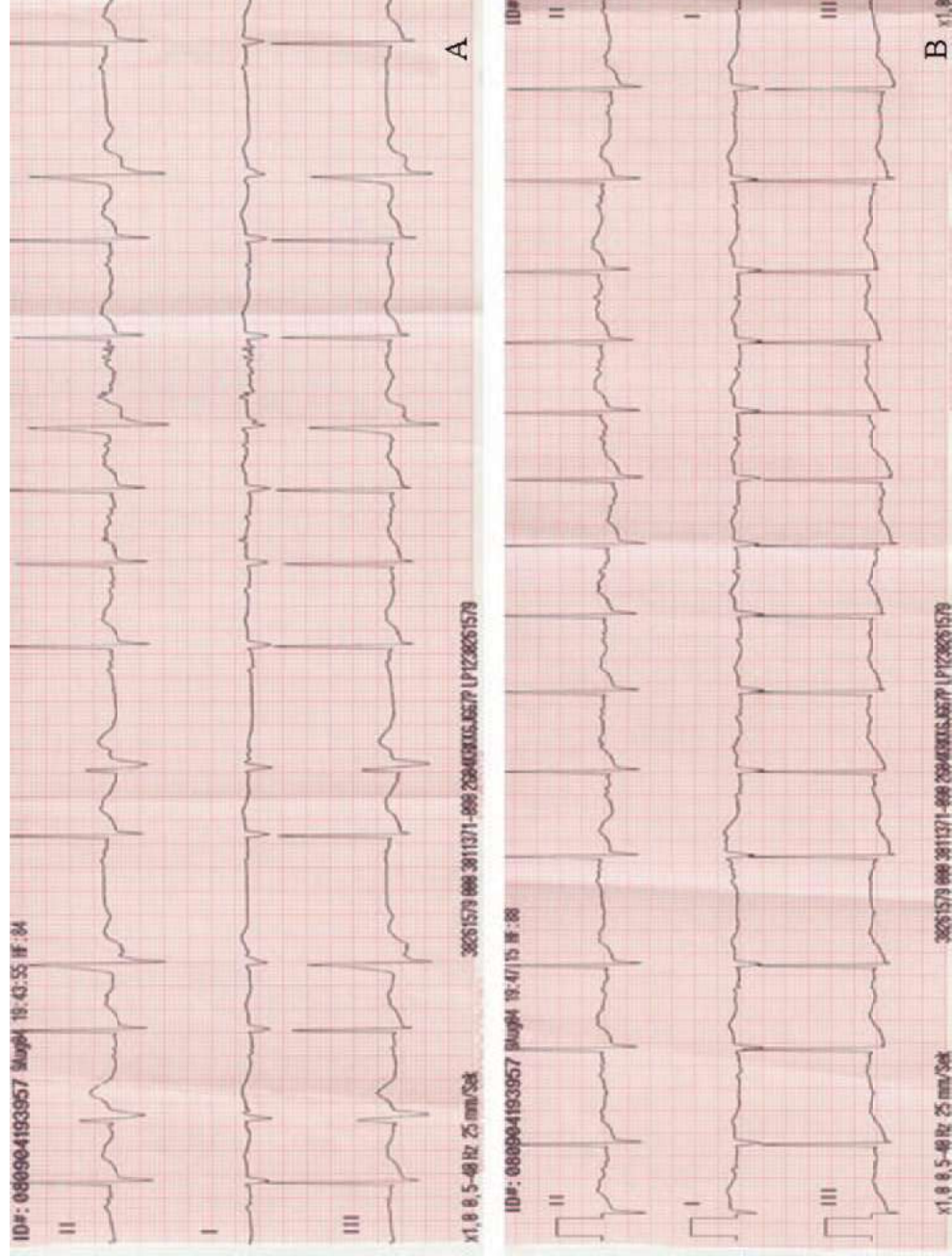


Figure 1. A, electrocardiogram (ECG) at onset of central nervous system toxicity and before lipid emulsion infusion showing supraventricular extrasystoles with intermittent bigeminy. B, ECG after administration of 200 mL of lipid emulsion showing sinus rhythm with respiratory variation. Supraventricular extrasystoles are no longer present.

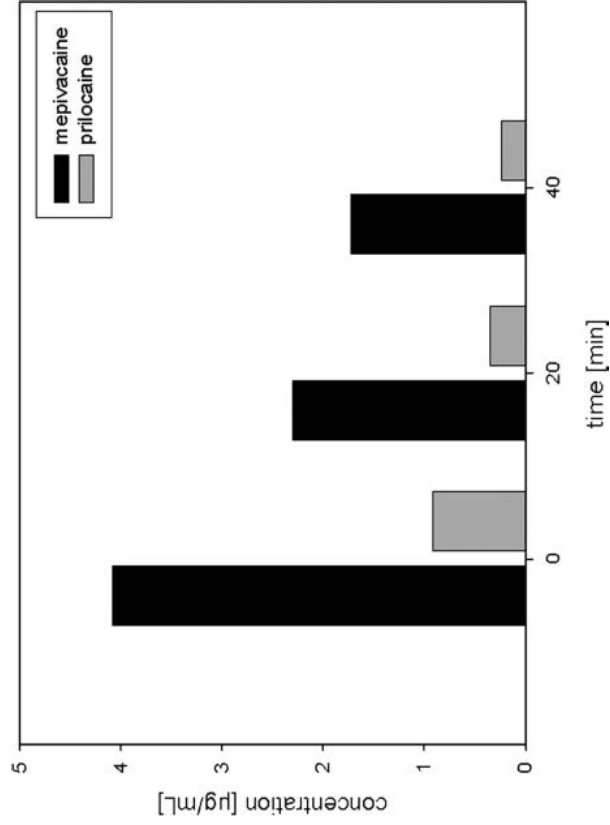


Figure 2. Time course of the plasma concentration of mepivacaine and prilocaine at the start and 20 and 40 min after administration of lipid emulsion.

-20°C to determine the plasma concentration of LAs by means of high-performance liquid chromatography immediately before, 20, and 40 min after lipid administration (20, 40, and 60 min after mepivacaine injection, respectively; Fig. 2); Serum concentrations for mepivacaine were 4.08, 2.30,

and 1.73 µg/mL and 0.92, 0.35, and 0.24 µg/mL for prilocaine and, therefore, below previously reported toxic concentrations.

The block was tested again and judged adequate. Therefore, surgery was started and performed uneventfully. The

further postoperative course was uneventful. The patient's electrocardiogram showed regular sinus rhythm and he was transferred to a medical ward for further treatment of the exacerbated chronic obstructive pulmonary disease.

DISCUSSION

This is the first report of the clinical effect of lipid emulsion infusion on reversal of central nervous system (CNS) and cardiac toxicity with sequential LA plasma concentrations. The plasma concentration of mepivacaine was below 6 µg/mL, generally considered a threshold for mepivacaine CNS toxicity.⁷ Similar thresholds have been suggested for prilocaine toxicity.⁸ However, thresholds for onset of LA toxicity are subject to a wide interindividual range.^{9–11} Toxicity has been reported with a peak mepivacaine plasma concentration of 5.1 µg/mL,¹² and comparable serum concentrations of prilocaine have been associated with CNS toxicity after cuff deflation in IV regional anaesthesia.¹⁰ Notably, the plasma concentration of prilocaine 5 min after injection of only 100 mg was surprisingly high in our patient, suggesting possible intravascular injection, since peak plasma concentrations after absorption should occur 20–30 min later.¹³ Hence, the toxic effects of mepivacaine could have been enhanced. Although no definite studies concerning the effects of LA mixtures on toxicity have been reported in humans, such additive effects of LAs have been demonstrated in animal models.¹⁴ Unfortunately, no epinephrine was added as a marker for intravascular injection.

Yamamoto et al. described the time course of plasma mepivacaine concentration after axillary plexus block and described a 50% reduction after 120 min.¹¹ In our patient, the plasma concentration of both mepivacaine and prilocaine was decreased by half within 20 min. This finding supports Weinberg's hypothesis of a "lipid sink" effect.¹⁵ Unfortunately, no fourth sample was obtained, and we were therefore not able to calculate the pharmacokinetics as described previously.¹⁶

Lipids are readily available in the operating room at our institution because of a previous positive experience with LA toxicity.³ Lipid infusion was immediately started after onset of symptoms, but before seizures occurred. The onset of arrhythmia at small doses of LAs implies reduced tolerance to the cardiac effects of both LAs. There could have been a significant influence of age on tolerance of LA. It remains unclear whether cardiac events were caused only by direct LA toxicity or possibly also caused by a secondary sympathetic response to CNS excitation. In our patient, CNS toxicity was reversed after injection of two boluses of 1 mL/kg each of Intralipid 20%. To reverse cardiac toxicity, a further dose of 2 mL/kg was required, given as a continuous infusion, which was in

accordance with the dose used in both case reports^{3,4} and Weinberg's recommendations for treatment of LA related toxicity (<http://www.lipidrescue.org>).^{15,17}

ACKNOWLEDGMENTS

Dr. Wolfram Oettler, Department of Cardiology, University Hospital of Dresden, for expert advice and interpretation of the ECG changes. Dr. Joerg Pietsch, Department of Forensic Medicine, Medical Faculty, University of Technology Dresden, for measuring serum concentrations of mepivacaine and prilocaine.

REFERENCES

1. Nolan JP, Deakin CD, Soar J, Bottiger BW, Smith G. European Resuscitation Council guidelines for resuscitation 2005. Section 4. Adult advanced life support. Resuscitation 2005;67(suppl 1):S39–S86
2. Weinberg G. Reply to Drs. Goor, Groban, and Butterworth—Lipid rescue: Caveats and recommendations for the "silver bullet" (letter). Reg Anesth Pain Med 2004;29:74
3. Litz RJ, Popp M, Stehr SN, Koch T. Successful resuscitation of a patient with ropivacaine-induced asystole after axillary plexus block using lipid infusion. Anaesthesia 2006;61:800–1
4. Rosenblatt MA, Abel M, Fischer GW, Itzkovich CJ, Eisenkraft JB. Successful use of a 20% lipid emulsion to resuscitate a patient after a presumed bupivacaine-related cardiac arrest. Anesthesiology 2006;105:217–8
5. Weinberg GL, Ripper R, Murphy P, Edelman LB, Hoffman W, Strichartz G, Feinstein DL. Lipid infusion accelerates removal of bupivacaine and recovery from bupivacaine toxicity in the isolated rat heart. Reg Anesth Pain Med 2006;31:296–303
6. Stehr SN, Ziegeler JC, Pexa A, Oertel R, Deussen A, Koch T, Hubler M. The effects of lipid infusion on myocardial function and bioenergetics in 1-bupivacaine toxicity in the isolated rat heart. Anesth Analg 2007;104:186–92
7. Jorfeldt L, Lofstrom B, Pernow B, Persson B, Wahren J, Widman B. The effect of local anaesthetics on the central circulation and respiration in man and dog. Acta Anaesthesiol Scand 1968; 12:153–69
8. Scott DB, Cousins MJ. Clinical pharmacology of local anesthetic agents. In: Cousins MJ, Bridenbaugh PO, eds. Neural blockade, Philadelphia: Lippincott, 1980:88
9. Koscielniak-Nielsen ZJ, Nielsen PR, Nielsen SL, Gardi T, Hermann C. Comparison of transarterial and multiple nerve stimulation techniques for axillary block using a high dose of mepivacaine with adrenaline. Acta Anaesthesiol Scand 1999;43:398–404
10. Niemi TT, Neuvonen PJ, Rosenberg PH. Comparison of ropivacaine 2 mg mL⁻¹ and prilocaine 5 mg mL⁻¹ for iv. regional anaesthesia in outpatient surgery. Br J Anaesth 2006;96:640–4
11. Yamamoto K, Nomura T, Shibata K, Ohmura S. Failed axillary brachial plexus block techniques result in high plasma concentrations of mepivacaine. Reg Anesth 1997;22:557–61
12. Tanoubi I, Vialles N, Cuuvillon P, Ripart J. [Systemic toxicity with mepivacaine following axillary block in a patient with terminal kidney failure]. Ann Fr Anesth Reanim 2006;25:33–5
13. Arthur GR, Scott DH, Boyes RN, Scott DB. Pharmacokinetic and clinical pharmacological studies with mepivacaine and prilocaine. Br J Anaesth 1979;51:481–5
14. Mets B, Janicki PK, James MF, Erskine R, Sasman B. Lidocaine and bupivacaine cardiorespiratory toxicity is additive: a study in rats. Anesth Analg 1992;75:611–4
15. Weinberg G. Lipid infusion resuscitation for local anesthetic toxicity: proof of clinical efficacy. Anesthesiology 2006;105:7–8
16. Muller M, Litz RJ, Hulter M, Albrecht DM. Grand mal convulsion and plasma concentrations after intravascular injection of ropivacaine for axillary brachial plexus blockade. Br J Anaesth 2001;87:784–7
17. Weinberg G, Hertz P, Newman J. Lipid, not propofol, treats bupivacaine overdose. Anesth Analg 2004;99:1875–6