

## **Review of Past Research and Current Concepts on the Etiology of Moyamoya Disease**

Kiyohiro HOUKIN,<sup>1</sup> Masaki ITO,<sup>1</sup> Taku SUGIYAMA,<sup>1</sup> Hideo SHICHINOHE,<sup>1</sup>  
Naoki NAKAYAMA,<sup>1</sup> Ken KAZUMATA,<sup>1</sup> and Satoshi KURODA<sup>1</sup>

<sup>1</sup>Department of Neurosurgery, Hokkaido University Graduate School of Medicine,  
Sapporo, Hokkaido

### **Abstract**

Research on moyamoya disease has progressed remarkably in the past several decades. Indeed, many new facts concerning the epidemiology of the disease have been revealed and surgical treatments have been drastically improved. However, despite extensive research, the mechanism of moyamoya disease is still unknown. Consequently, the cardinal treatment of this disease has not yet been developed. For further clarification of its etiology, innovative studies are therefore indispensable. The aim of this paper is to review research on the pathogenesis of moyamoya disease to identify milestones in the direction of its true solution. Many hypotheses of the pathogenesis of moyamoya disease have been proposed in the past half century, including infection (viral and bacterial), autoimmune disorders, proteins abnormality, and gene abnormality. Some of these are now considered to be historical achievements. Others, however, can be still subjected to contemporary research. Currently, several genetic abnormalities are considered to offer the most probable hypothesis. In addition, interesting papers have been presented on the role of the endothelial progenitor cell on the pathogenesis of moyamoya disease. Intuitively, however, it appears that a single theory cannot always explain the pathogenesis of this disease adequately. In other words, the complex mechanism of several factors may comprehensively explain the formation of moyamoya disease. The “double hit hypothesis” is probably the best explanation for the complicated pathology and epidemiology of this disease.

Key words: moyamoya disease, etiology, proteomics, genetics, endothelial progenitor cell

### **Introduction**

Cerebrovascular moyamoya disease is characterized by progressive stenotic change in the terminal portion of the bilateral internal carotid arteries and the formation of an abnormal vascular network at the base of the brain.<sup>35,49,62,63,67</sup> The latter is thought to be a secondary phenomenon that compensates for the cerebral ischemia due to the primary internal carotid artery stenosis. The abnormally developed vascular network is defined as “moyamoya vessels.”<sup>63</sup>

The pathological entity of moyamoya disease was established in the 1960s.<sup>35,49,63,67</sup> Since then, particularly enthusiastic research has been conducted in Japan and progress has been remarkable in the past several decades. So far, many new aspects of the epidemiology have been uncovered and innovations

in surgical treatment have been developed, including direct bypass surgery and other combined revascularization treatments.<sup>6,36,37,71</sup>

Despite these many and extensive studies, however, the mechanism of moyamoya disease is still unknown. From a historical point of view, some of the hypotheses are now considered to be historical achievements. Thus, cerebrovascular disease with certain basic diseases or conditions, including infection and autoimmune disease are currently distinguished from definitive or probable moyamoya disease.<sup>11</sup> However, these hypotheses have been occasionally proposed in the history of the investigation of moyamoya disease. Innovative research is indispensable for further clarification of the pathogenesis. In a sense, moyamoya disease is shrouded still in mystery, literally as a “puff of smoke” (Table 1). Consequently, the cardinal treatment to block the pathogenesis of the disease has not yet been developed. The aim of this paper is, therefore, to review the past clinical and basic research on the pathogen-

**Table 1 Summary of unknown issues in moyamoya disease**

1 Geographical distribution	Japanese, Korean
2 Sex specificity	woman 2 times
3 Heredity	10–20%, low penetration
4 Pathological specificity	different from atherosclerosis
5 Vasculogenesis (angiogenesis?)	
6 Etiology	unknown

esis of moyamoya disease in order to find a guide to the true solution of this disease.<sup>1,58)</sup>

There are many ways to uncover the etiology of a disease. Conventional methods include the epidemiological approach, basic research including the animal model approach, and the clinical approach. As is well known, however, the animal model of this disease has not been established.<sup>9,10,23,40)</sup> In this paper, therefore, research on moyamoya disease and moyamoya syndrome using conventional pathological methods as well as research on proteomics, relationship between immune system and moyamoya disease or syndrome, gene abnormality, and cell abnormality will be reviewed. Finally, the authors will propose a comprehensive idea to explain the many aspects revealed by many approaches.

## Materials and Methods

In this paper, studies published in English and the main studies in Japan on moyamoya disease are reviewed as comprehensively as possible. The main studies are summarized according to the following five viewpoints: i) Pathological study and abnormal thrombogenesis, ii) proteomics, iii) infection and autoimmune abnormality and human leucocytes antigen (HLA) abnormality, iv) genetics, and v) endothelial progenitor cell (EPC). These particular viewpoints are discussed in each part.

## Results

### I. Pathological study and abnormal thrombogenesis

Needless to say, pathological study offers essential information about the pathogenesis of moyamoya disease. However, the difficulty of the pathological approach is that specimens of the terminal portion of the internal carotid artery are difficult to obtain since autopsies conducted in patients with moyamoya disease have decreased recently. For this reason, pathological study has to be traced back to the 1990s.

Firstly, the inflammatory process hypothesis has

been proposed by Masuda et al.<sup>41)</sup> However, as is well known, the characteristics of the stenotic change seen in moyamoya disease are quite different from those of the atherosclerotic process seen in adults. There is no lipid pool or inflammatory cell or macrophage invasion to the sub-intimal layer as typically seen in atherosclerosis.<sup>20)</sup> The typical pathological finding seen in the terminal of the internal carotid artery is a concentric and eccentric fibrocellular thickening of the intima that induces the stenosis of the vascular lumen. The intimal elastic lamina shows an abnormal waving form without the rupture, although it is basically maintained. Masuda et al. have demonstrated that the thickening of the intimal layer includes migration of the smooth muscle cell of media that resembles atherosclerosis but no inflammatory cells are observed. From these classic studies, we can learn that the mechanism of stenotic change seen in moyamoya disease is quite different from that of atherosclerosis. However, unfortunately, no clear hints are obtained to connect with the true pathogenesis of moyamoya disease.

On the other hand, a hypothesis of abnormal thrombogenesis has been advanced by Hosoda et al.,<sup>17)</sup> who reported that thromboemboli are occasionally (around 50% in their autopsy cases) seen in the internal wall of the moyamoya artery and its distribution correlates well with the character of moyamoya disease. They have suggested that abnormal thrombogenesis plays an important role in the etiology of this disease. However, another study by Ikeda and Hosoda has failed to demonstrate any difference in expression of the thrombomodulin (anticoagulant protein expressed in the endothelial cells) between normal controls and moyamoya patients.<sup>21)</sup> Subsequently, few papers have been published to demonstrate the relationship between the etiology of moyamoya disease and abnormal thrombogenesis. Clinically sickle cell anemia is well known to cause moyamoya syndrome and abnormality in thrombogenesis is suspected in its etiology. Other research has pointed out that prothrombotic abnormality, antiphospholipid syndrome, and protein-S abnormality are commonly reported in moyamoya disease and moyamoya syndrome.<sup>2,7,27,57,60)</sup>

In conclusion, morphological study using classical techniques has successfully demonstrated the typical change in internal thickening of the intima in moyamoya disease. However, it has not necessarily offered insight into the essential pathogenesis of this disease.

### II. Proteomics

There are many successful studies on the detec-

**Table 2 Change in cytokines**

	Elevation	No change
CSF	b-FGF	TGF- $\beta$
	HGF	VEGF, IL-8
	CRABP-I	PDGF
	ICAM-I	
	E-selectin	
Cerebral artery, STA, cultured SMCs	b-FGF	
	TGF- $\beta$	
	PDGF	
	HGF	
	HIF-1 $\alpha$	

b-FGF: basic fibroblast growth factor, CRABP-I: cellular retinoic acid-binding protein type I, HGF: hepatocyte growth factor, HIF-1 $\alpha$ : hypoxia-inducible factor 1 $\alpha$ , ICAM-1: intercellular adhesion molecule type 1, IL-8: interleukin-8, PDGF: platelet-derived growth factor, SMCs: smooth muscle cells, STA: superficial temporal artery, TGF- $\beta$ : transforming growth factor  $\beta$ , VEGF: vascular endothelial growth factor.

tion of cytokine increase in specimens obtained from patients with moyamoya disease. Indeed, in the last 15 years, many investigations have been conducted in this field.<sup>3,15,18,30,33,46,65,69,75</sup> The results are summarized in Table 2. Most studies are based on the examination of cerebrospinal fluid (CSF) obtained from the surface subarachnoid space during surgery on moyamoya disease patients. Angiogenetic cytokines such as basic fibroblast growth factor (b-FGF), hepatocyte growth factor, and transforming growth factor (TGF) are mainly shown to have increased in CSF and other surgical specimens such as artery walls and the dura mater. These proteins may relate to the pathogenesis of moyamoya disease.

Among the angiogenetic cytokines, the b-FGF has attracted most attention since it can rationally explain the apparently inconsistent phenomena seen in moyamoya disease, namely, steno-occlusive lesion in the Willis ring and the development of moyamoya vessels and dilation of the cortical small arterioles and angiogenesis/vasculogenesis after indirect synangiosis. It is well known that b-FGF induces the proliferation of endothelial cells which may produce the stenotic change of the major arteries in moyamoya disease. On the other hand, b-FGF has an angiogenetic and vasodilative effect on the small pial arteries that can rationally explain the development of abnormally dilated vasculature and the dilated superficial pial arterioles on the cortex in moyamoya disease. In addition, it has been demonstrated that the level of b-FGF in the CSF is closely related to the level of neo-vascularization after an indirect bypass. It is noteworthy, however, that strong angiogenetic factors such as vascular endothelial

**Table 3 Correlation between moyamoya disease and infection/autoimmune disease**

Infection	
bacterial infection	pneumococcus tuberculous infection <i>Propionibacterium acnes</i> <i>Leptospira</i> <i>Streptococcus</i>
viral infection	Epstein-Barr virus varicella-zoster virus measles virus human immunodeficiency virus cytomegalovirus
Auto-immune disease	antiphospholipid antibodies syndrome systemic lupus erythematosus Graves' disease

growth factor (VEGF) and platelet-derived growth factor (PDGF) are not always increased in moyamoya disease.<sup>18)</sup>

Nevertheless, there is some skepticism regarding the role of abnormality of proteins seen in moyamoya disease. We do not have reliable control data of the cytokine level that may differ according to location and age. In addition, under some hypoxic and ischemic conditions, it is well known that these cytokines significantly fluctuate. In other words, the data might simply reflect the response of cytokines to hypoxic and ischemic processes in moyamoya disease. It is thus conceivable that cytokine abnormalities may be the result of ischemia but not the cause of moyamoya disease.<sup>18)</sup>

### III. Infection and autoimmune abnormality and HLA abnormality

These three hypotheses have been occasionally proposed in the history of the investigation of moyamoya disease (Table 3). As mentioned above, the moyamoya phenomenon observed in patients with infection or autoimmune diseases is now eliminated from moyamoya disease. However, all three are considered to correlate with each other through the common pathway of abnormality in the immune system in moyamoya disease. It is important, therefore, to review and know past research on the relationships between moyamoya disease or moyamoya syndrome and infection or immune system disorder, including autoimmune abnormality and HLA abnormality. Many infections have been reported to be related to the moyamoya phenomenon, including bacterial meningitis due to pneumococcus, tuberculous infection, viral infection by varicella-zoster virus, measles virus, human immunodeficiency virus, cytomegalovirus, Epstein-Barr virus, and *Leptospira* infection.<sup>8,19,42,45,66,68,70)</sup>

Among these sporadic case reports, Yamada et al. have systematically studied the serum of 85 patients suffering moyamoya disease, and revealed that *Propionibacterium acnes* antibody and immunoglobulin M, transferrin, and  $\alpha$ 2-macroglobulin levels are significantly higher in cases of moyamoya disease.<sup>74)</sup> However, there are few systemic studies on subsequent infection and moyamoya disease.

Many autoimmune diseases have been reported to be related to the moyamoya phenomenon, including antiphospholipid antibodies syndrome, systemic lupus erythematosus, Graves' disease, and HLA class I or II alleles abnormality.<sup>13,56,64,72)</sup> However, these studies have indirectly proved the correlation between abnormalities of the immune system and moyamoya disease. Indeed, it is conceivable that the true genetic triggers of moyamoya disease are close to the abnormalities seen in HLA alleles disclosed.

#### IV. Genetics

Some genetic factors are believed to contribute to the etiology and development of moyamoya disease.<sup>1,14,37,52,73)</sup> Evidence for a genetic contribution to moyamoya disease is suggested by strong regional differences with a high occurrence in Asian countries (primarily Japan and Korea) and much smaller rates in Western countries, as well as with many familial occurrences and high incidence in concordant monozygotic twins.<sup>12,37,50,52)</sup> Further evidence shows that the female to male ratio rises from 1.6:1 in sporadic cases to 5.0:1 in familial cases; and the mean age of onset drops from 30.0 years in sporadic cases to 11.8 years in familial cases.

Moreover, while the onset of symptoms in parents of affected families shows an average of 30.7 years, their offspring show the first signs of moyamoya disease at an average age of 7.2 years.<sup>37)</sup> Moyamoya syndrome has also been reported in patients with other diseases of known genetic origin, such as neurofibromatosis type I and Down syndrome, among others, highlighting the evidence for a possible genetic etiology for this severe disease.<sup>37)</sup> Additionally, the following facts suggest a multifactorial etiology of moyamoya disease: the predisposition of familial occurrence,<sup>6,71,76)</sup> the non-Mendelian pattern of inheritance in familial cases.<sup>44,50)</sup> Based on these considerations, some researchers believe that moyamoya disease is inherited in a polygenic or autosomal dominant mode with a low penetrance.<sup>44,50)</sup> For decades, studies have implicated certain genetic loci or susceptibility genes in harboring a risk for developing moyamoya disease, as shown in Tables 4, 5, and 6.

To specify the locus or the causative gene for moyamoya disease, linkage analysis (family-based studies such as parametric linkage analysis and affected sibling pair analysis) and association studies (case-control studies) have been performed. As shown in Table 4, four reports from Japan have conducted linkage analysis by using microsatellite markers to specify the susceptible genetic loci on familial moyamoya disease.<sup>22,25,54,77)</sup> These reports have specified the susceptible linkage at 3p24.2-p26, 6q25, 17q25, and 8q23 for familial moyamoya disease. A suggestive linkage at 12p12 has also been demonstrated. As shown in Table 5, several association stu-

**Table 4 Summary of linkage analysis to specify the susceptible genetic loci for familial moyamoya disease (MMD)**

Author (Year)	Method	Subject	Ethnicity	DNA marker	Coverage	Result
Ikeda et al. (1999) <sup>22)</sup>	non-parametric linkage analysis	77 individuals in 16 families, including 37 MMD patients	Japanese	371 microsatellite markers	22 autosomes	linkage at 3p24.2-p26 (maximal NPL score 3.46 on D3S3050)
Inoue et al. (2000) <sup>25)</sup>	non-parametric linkage analysis; affected sibling pair analysis	20 affected sibling pairs in 19 families	Japanese	15 microsatellite markers	chromosome 6	linkage at 6q25 (linkage disequilibrium at D6S441; IBD [0:12:8])
Yamauchi et al. (2000) <sup>77)</sup>	a combination of parametric and non-parametric linkage analysis	103 individuals in 24 families, including 56 MMD patients	Japanese	22 microsatellite markers	chromosome 17	linkage at 17q25 (maximal LOD score 4.58) within the 9-cM region of D17S785 to D17S836
Sakurai et al. (2004) <sup>54)</sup>	non-parametric linkage analysis followed by TDT method	46 individuals in 12 families, including 12 affected sibling pairs	Japanese	428 microsatellite markers	genome-wide linkage analysis	linkage at 8q23 (MLS 3.6 and NPL 3.3 on D8S546) and suggestive linkage at 12p12 (MLS 2.3, NPL 2.5 on D12S1690), no linkage disequilibrium at markers in these loci

DNA: deoxyribonucleic acid, IBD: identical by descent, LOD: logarithm of odds, MLS: maximal LOD score, NPL: non-parametric LOD, TDT: transmission disequilibrium test.

**Table 5 Summary of case-control association studies to specify the candidate gene or polymorphism for moyamoya disease (MMD)**

Author (Year)	Subjects	Control	Ethnicity	Candidate genotype	Significantly associated allele for MMD
Kitahara et al. (1982) <sup>34)</sup>	18 patients and 31 reviewed cases with MMD	106 normal controls	Japanese	HLA class I genotype	HLA-AW24(RR 3.83), BW46(RR6.50), BW54(RR3.58)
Aoyagi et al. (1995) <sup>4)</sup>	32 unrelated patients with MMD	178 unrelated normal controls without history of CVD	Japanese	HLA class I and II genotype	HLA-B51(RR 3.7), the combination of the HLA-B51 and -DR4
Inoue et al. (1997) <sup>24,26)</sup>	71 unrelated patients with MMD	525 normal controls	Japanese	HLA class I and II genotype	HLA-DQB1*0502 (positive association), HLA-DRB1*0405 and -DQB1*0401 (negative association)
Han et al. (2003) <sup>13)</sup>	28 patients with MMD	198 normal controls	Korean	HLA-B and HLA class II genotype	HLA-B35 (RR4.2)
Kang et al. (2006) <sup>31)</sup>	11 patients with familial MMD	50 patients with non-familial MMD and 50 normal controls	Korean	SNPs of TIMP4 and TIMP2 gene on chromosomes 3p24.2-p26 and 17q25	G/C heterozygous genotype at position -418 in TIMP2 promoter (OR9.56: familial vs non-familial MMD, OR10.5: familial MMD vs non-MMD)
Hong et al. (2009) <sup>16)</sup>	10 children with familial MMD	54 children with non-familial MMD and 207 normal controls	Korean	high resolution HLA-DRB1 and DQB1 genotypes	HLA-DRB1*1302 (OR12.76: familial MMD vs non MMD, OR13.42: familial vs non-familial MMD), HLA-DQB1*0609 (OR14.67: familial MMD vs non-MMD, OR35.33: familial vs non-familial MMD)
Roder et al. (2010) <sup>53)</sup>	40 patients with MMD	68 normal controls	central European	13 SNPs in and upstream of b-FGF, CRABP1, PDGFR $\beta$ and TGF $\beta$ 1 gene	rs382861(A/C) in the promoter region of PDGFR $\beta$ (OR1.81) and rs1800471(C/G) in the first exon of TGF $\beta$ 1 (OR7.65)

b-FGF: basic fibroblast growth factor, CRABP1: cellular retinoic acid-binding protein 1, CVD: cerebrovascular disease, HLA: human leukocyte antigen, OR: odds ratio, PDGFR $\beta$ : platelet derived-growth factor receptor  $\beta$ , RR: relative risk, SNP: single nucleotide polymorphism, TIMP: tissue inhibitor of metalloproteinase, TGF  $\beta$ 1: transforming growth factor  $\beta$ 1.

dies have been reported by using HLA genotype and single nucleotide polymorphisms (SNPs) of several cytokines or growth factors.<sup>4,13,16,24,26,31,34,53)</sup> Thus, the association has been investigated between moyamoya disease and several markers involved in cell proliferation, constituting vessel strictures or expressing in the brain and/or vessels. As a result, several HLA alleles, SNPs of tissue inhibitor of metalloproteinase 2 promoter, PDGF receptor  $\beta$  and TGF  $\beta$ 1 have been revealed to be candidate genes or polymorphism. However, these studies have not elucidated the susceptibility gene for moyamoya disease. As Mineharu et al. have pointed out, there seem to be three main explanations as follow.<sup>44)</sup> First, moyamoya disease may be caused by several different mechanisms (disease heterogeneity). Second, moyamoya disease exhibits different modes of inheritance (genetic heterogeneity). Finally, several genetic factors in different loci can cause the same disease (locus heterogeneity). From these view points, several studies have been conducted by using a combination of several methods to specify the susceptibility gene for moyamoya disease (Table 6).<sup>29,38,39,43,47)</sup> Of these, two independent groups from Japan have identified, very recently, the susceptibility gene for moyamoya disease by employing a com-

bination of several methods, including linkage analysis, case-control association studies, and gene annotation studies. Thus, Kamada and colleagues from Tohoku University employed a genome-wide association study and identified ring finger protein (RNF) 213 (\*613768; <http://omim.org/entry/613768>) as the first moyamoya disease gene.<sup>29)</sup> Around the same time, Liu and colleagues from Kyoto University, the University of Tübingen, Palacky University, the Chinese People's Liberation Army General Hospital, and Seoul National University employed genome-wide linkage analysis by assuming the inheritance pattern of moyamoya disease as autosomal dominant mode with incomplete penetrance and whole genome-exome analysis. As a result, they provided evidence suggesting the involvement of RNF213 in genetic susceptibility to moyamoya disease.<sup>39)</sup> As Liu et al. noted, the discoveries of the susceptibility gene, its association with moyamoya disease, and its unique roles in angiogenesis may yield a way to early diagnosis and prevention of the disease. It should be noted, however, that further studies are necessary to clarify the biochemical function and pathological role of RNF213 in moyamoya disease.

**Table 6 Summary of genetic studies combining several methods to specify the susceptibility gene for moyamoya disease (MMD)**

Author (Year)	Methods	Subject	Ethnicity	Coverage	Result
Nanba et al. (2005) <sup>47)</sup>	sequence analysis and bioinformatics analysis	9 individuals from one family, including 4 patients	Japanese	the 9-cM region within 17q25 and 26753 EST with significant similarity to the sequences of 17q25	no MMD related variation
Mineharu et al. (2008) <sup>43)</sup>	genome-wide parametric linkage analysis, haplotype and mutation analysis of candidate genes	15 highly affected families, including 55 patients	Japanese	382 markers for 22 autosomes and 18 markers for the X chromosome	17q25.3 with a MLS 8.07 (broad classification) and 6.57 (narrow classification) at D17S704
Liu et al. (2009) <sup>38)</sup>	parametric multi-point linkage analysis, sequence analysis of candidate 3 genes, segregation and linkage confirmation followed by case-control study	194 Japanese in 36 families, including 109 patients; 5 Koreans in one family, including 2 patients	Japanese and Korean	13 markers at 5.1-Mb intervals in the 17q25-qter linkage region	17q25.3 with the LOD score 9.67 and Raptor ss161110142 (G/A) SNP with the LOD score 14.2
		90, 41, 23, and 25 non-familial patients and 384, 223, 100, and 164 controls (Japanese, Korean, Chinese, and Caucasian, respectively)	Japanese, Korean, Chinese, and Caucasian	SNPs of Raptor gene	Raptor ss161110142 (G/A) polymorphism in Asian cases with an OR 52.2
Kamada et al. (2011) <sup>29)</sup>	genome-wide association study and locus-specific association study followed by mutational analysis of RNF213 and FLJ35220	72 patients, including 8 familial cases and 45 normal controls	Japanese	genome-wide 785720 SNPs and 335 SNPs in the 17q25-ter region	a single haplotype consisting of 7 SNPs at the RNF213 locus was tightly associated with MMD p.R4859K (a founder mutation of RNF213) was found in 95% of familial MMD, 73% of non-familial MMD, and 1.4% of controls
Liu et al. (2011) <sup>39)</sup>	genome-wide linkage analysis and haplotype and segregation analysis	8 three-generation families with MMD	Japanese	382 markers for 22 autosomes and 18 markers for the X chromosome	linkage at 17q25.3 ( $p < 10^{-4}$ ) with the MLS 8.46 at D17S784
	whole genome-exome analysis	8 index cases in above families	Japanese	the 1.5-Mb region on 17q25.3	p.N321S in PCMTD and p.R4810K in RNF213
	segregation confirmation	41 Japanese and one Korean families	Japanese and Korean		p.R4810K in RNF213 segregated in all 42 families
	association study	161, 384 Japanese cases and controls; 38, 223 Korean cases and controls; 52, 100 Chinese cases and controls	east Asian	ss179362673 (p.R4810K in RNF213)	strong association of pR4810K (OR338.9 in Japanese cases, OR135.6 in Korean cases, and OR14.7 in Chinese cases)
confirmation study by cloning, biochemical and functional analysis			transcription level, ubiquitination activity of RNF213 and RNF213-knockdown zebrafish	RNF213 involves in genetic susceptibility to MMD	

EST: expressed sequence tag, LOD: logarithm of odds, MLS: maximal LOD score, OR: odds ratio, SNP: single nucleotide polymorphism.

## V. EPC

Since Asahara et al. first described the presence of EPCs in the peripheral blood in 1997, their biological features have been widely investigated.<sup>5)</sup> EPCs are also expected to be donor cells in cell therapy for several ischemic vascular diseases, because they are known to contribute to vasculogenesis and en-

dothelial repair under pathological conditions. Recently, participation of EPCs has been introduced in the pathogenesis of moyamoya disease.

Firstly, Yoshihara et al. found a significant increase of circulating CD34<sup>+</sup> cells in the peripheral blood in patients of major cerebral artery occlusion with angiographic moyamoya vessels.<sup>78)</sup> Subse-

quently, Rafat et al. reported a significant increase of circulating EPCs (CD34<sup>+</sup>CD133<sup>+</sup>VEGFR2<sup>+</sup> cells) in adult patients with moyamoya disease.<sup>51)</sup> They also found increasing plasma levels of VEGF and granulocyte-macrophage colony-stimulating factor, which were thought to mediate mobilization of EPCs. Likewise, Ni et al. reported an increase of circulating CD34<sup>+</sup>CXCR4<sup>+</sup> cell number and plasma level of stromal cell-derived factor-1 $\alpha$  in patients with moyamoya disease.<sup>48)</sup> On the other hand, Kim et al. reported a significant decrease of circulating EPCs (CD34<sup>+</sup>CD133<sup>+</sup>VEGFR2<sup>+</sup> cells) in child patients with moyamoya disease.<sup>32)</sup> A future discussion would be necessary whether this discrepancy might be originated from the age of the patients or stages of the disease. In both cases, these studies were quite important in a point that EPCs may participate in the formation of extensive collateral vessels (moyamoya vessel) in moyamoya disease.

As an another viewpoint, Jung et al. have found disturbed function of the circulating EPCs isolated from the peripheral blood of adult patients with moyamoya disease.<sup>28)</sup> Similar findings were also observed in pediatric moyamoya disease.<sup>32)</sup> However, the question still remains whether EPCs participate in the progressive occlusive lesion of the internal carotid artery, which is a 'primary' initiation site of moyamoya disease.

As mentioned above, EPCs contribute to vasculogenesis and endothelial repair. However, recent laboratory studies point that some circulating progenitor cells also participate in vascular remodeling including the development and progression of atherosclerotic plaque.<sup>55)</sup> Since the existence of smooth muscle progenitor cells (SMPCs) was described by Simper et al., attention has focused on the finding that SMPCs have opposite role to EPCs in the development of several vascular diseases.<sup>59)</sup>

Recently, our laboratory found that the CD34<sup>+</sup>VEGFR2<sup>+</sup> cells were closely involved in the intimal thickening of the supraclinoid internal carotid artery collected from adult patients with moyamoya disease.<sup>61)</sup> This study was interesting in that certain progenitor cells also participated in the progressive occlusive lesion in moyamoya disease. However, the roles and the identity of such cells are still unknown.

As mentioned above, vascular progenitor cells (VPCs) such as EPC and SMPC might shed new light on the pathogenesis of moyamoya disease. However, there are several issues in such 'progenitor cell' research. These 'progenitor cells' were mostly defined by surface cell markers such as CD34, CD133, and VEGFR2, but definitive specific cell markers of such 'progenitor cell' have not been identified so far. Moreover, in this field, there were some discrepan-

cies among studies. Further detailed study with different viewpoints would be necessary to elucidate the role of the VPCs in the pathogenesis of moyamoya disease.

## Discussion

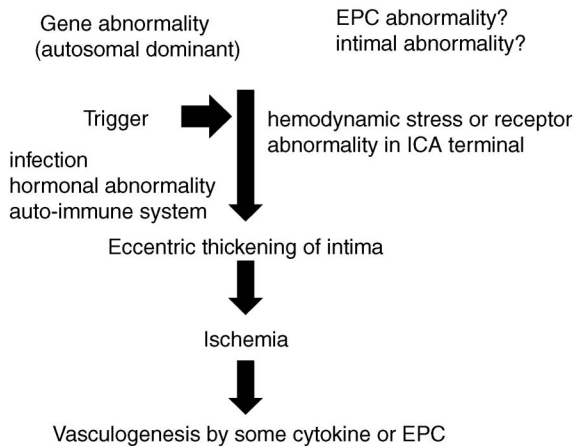
The classical and contemporary concepts shown in this review may cause confusion. None of the studies introduced can explain, by themselves, the particular aspects of pathology and clinical presentation, or the epidemiological features of moyamoya disease. None, for example, can answer the simple question of whether or not the primary lesions of moyamoya disease are localized to the terminal portion of the internal carotid artery.<sup>1,35,49,62,63)</sup>

Probably some studies, such as those of the abnormal value of cytokines, may reflect the secondary phenomena accompanying moyamoya disease rather than its essential cause. In addition, some phenomena, such as infection and HLA alleles abnormality, may be correlated to some trigger or enhancer of the disease. Among these phenomena, the genetic abnormality and the EPC hypothesis seem to come closest to identifying the primary cause of moyamoya disease since they have a chance of rationally explaining its particular epidemiological features. However, as mentioned, the simplest but most difficult question is the particular location of the lesion seen in the terminal portion of the internal carotid arteries. One hypothesis that may provide an answer is that, in children, the carotid bifurcation is the portion first exposed to hemodynamic shearing stress.

Consequently, it is clear that none of these hypotheses completely explains the pathological processes and clinical and epidemiological presentations of moyamoya disease.<sup>1)</sup> Inevitably, we must consider the possibility that multiple causes are involved to the etiology of moyamoya disease.<sup>35,49,63)</sup>

A "double hits hypothesis" combining existing hypotheses is shown in Fig. 1. The primary causes of moyamoya disease are considered to be multiple gene abnormalities. Some of those abnormalities may be related to qualitative and/or quantitative abnormalities in EPC. However, some triggers, such as infection or immune disorder, seem to be indispensable in starting the first step in the pathological process of the disease. Hemodynamic stress is probably also important in booting up the first mechanism.

Needless to say, the hypothesis presented in Fig. 1 is not an original one, but has simply combined existing hypotheses and arbitrarily assembled parts of existing hypotheses that are consistent with the



**Fig. 1 Double hit hypothesis. EPC: endothelial progenitor cell, ICA: internal carotid artery.**

complicated aspects of moyamoya disease. However, the double-hit hypothesis offers an attractive thesis since it can rationally explain the complicated aspects of moyamoya disease.

We may still not understand the true etiology of moyamoya disease. As shown in this review paper, a breakthrough is not visible. However, past basic studies offer important hints for new research. It is quite important that future work on moyamoya disease pays careful attention to past and present studies.

## Disclosure and Conflict of Interest

This study was partly supported by the Research Committee on Spontaneous Occlusion of the Circle of Willis (Moyamoya disease) (Chaired by Dr. Nobuo Hashimoto) by Science Research Grants of the Ministry of Health, Labour and Welfare of Japan (H23-Nanji-Ippan-019). We have no other conflict of interest concerning this paper.

## References

- 1) Achrol AS, Guzman R, Lee M, Steinberg GK: Pathophysiology and genetic factors in moyamoya disease. *Neurosurg Focus* 26(4): E4, 2009
- 2) Akgun D, YiLmaz S, Senbil N, Aslan B, Gurer YY: Moyamoya syndrome with protein S deficiency. *Eur J Paediatr Neurol* 4: 185–188, 2000
- 3) Albala MM, Levine PH: Platelet factor 4 and beta thromboglobulin in Moya-Moya disease. *Am J Pediatr Hematol Oncol* 6: 96–99, 1984
- 4) Aoyagi M, Ogami K, Matsushima Y, Shikata M, Yamamoto M, Yamamoto K: Human leukocyte antigen in patients with moyamoya disease. *Stroke* 26: 415–417, 1995
- 5) Asahara T, Murohara T, Sullivan A, Silver M, van der Zee R, Li T, Witztenbichler B, Schatteman G, Isner JM: Isolation of putative progenitor endothelial cells for angiogenesis. *Science* 275(5302): 964–967, 1997
- 6) Baba T, Houkin K, Kuroda S: Novel epidemiological features of moyamoya disease. *J Neurol Neurosurg Psychiatry* 79: 900–904, 2008
- 7) Carhuapoma JR, D’Olhaberriague L, Levine SR: Moyamoya syndrome associated with Sneddon’s syndrome and antiphospholipid-protein antibodies. *J Stroke Cerebrovasc Dis* 8: 51–56, 1999
- 8) Czartoski T, Hallam D, Lacy JM, Chun MR, Becker K: Postinfectious vasculopathy with evolution to moyamoya syndrome. *J Neurol Neurosurg Psychiatry* 76: 256–259, 2005
- 9) Deguchi K, Iwamura M, Yamada H: *The Influence of Propionibacterium Acnes Infection on Intracranial Arteries in Rats*. Tokyo, The Research Committee on Spontaneous Occlusion of the Circle of Willis (Moyamoya Disease) of the Ministry of Health and Welfare Japan, 1992, pp 168–171
- 10) Fujiwara S, Ezura M, Yoshimoto T: *The Experimental Study on Causal Genesis of Moyamoya Disease—Introduction of Immunological Cerebral Arterial Changes*. Tokyo, The Research Committee on Spontaneous Occlusion of the Circle of Willis (Moyamoya Disease) of the Ministry of Health and Welfare Japan, 1992, pp 157–162
- 11) Fukui M: Guidelines for the diagnosis and treatment of spontaneous occlusion of the circle of Willis (‘moyamoya’ disease). Research Committee on Spontaneous Occlusion of the Circle of Willis (Moyamoya Disease) of the Ministry of Health and Welfare, Japan. *Clin Neurol Neurosurg* 99 Suppl 2: S238–240, 1997
- 12) Fukuyama Y, Kanai N, Osawa M: *Clinical Genetic Analysis on the Moyamoya Disease*. Tokyo, The Research Committee on Spontaneous Occlusion of the Circle of Willis (Moyamoya Disease) of the Ministry of Health and Welfare Japan, 1992, pp 141–146
- 13) Han H, Pyo CW, Yoo DS, Huh PW, Cho KS, Kim DS: Associations of Moyamoya patients with HLA class I and class II alleles in the Korean population. *J Korean Med Sci* 18: 876–880, 2003
- 14) Hashikata H, Liu W, Mineharu Y, Inoue K, Takenaka K, Ikeda H, Houkin K, Kuroda S, Kikuchi K, Kimura M, Taki T, Sonobe M, Ban S, Nogaki H, Handa A, Kikuta K, Takagi Y, Nozaki K, Hashimoto N, Koizumi A: [Current knowledge on the genetic factors involved in moyamoya disease]. *Brain Nerve* 60: 1261–1269, 2008 (Japanese)
- 15) Hojo M, Hoshimaru M, Miyamoto S, Taki W, Nagata I, Asahi M, Matsuura N, Ishizaki R, Kikuchi H, Hashimoto N: Role of transforming growth factor-beta1 in the pathogenesis of moyamoya disease. *J Neurosurg* 89: 623–629, 1998
- 16) Hong SH, Wang KC, Kim SK, Cho BK, Park MH: Association of HLA-DR and -DQ genes with familial moyamoya disease in Koreans. *J Korean Neurosurg*



- Soc 46: 558–563, 2009
- 17) Hosoda Y, Ikeda E, Hirose S: Histopathological studies on spontaneous occlusion of the circle of Willis (cerebrovascular moyamoya disease). *Clin Neurol Neurosurg* 99 Suppl 2: S203–208, 1997
  - 18) Houkin K, Yoshimoto T, Abe H, Nagashima K, Nagashima M, Takeda M, Isu T: Role of basic fibroblast growth factor in the pathogenesis of moyamoya disease. *Neurosurg Focus* 5(5): e2, 1998
  - 19) Hsiung GY, Sotero de Menezes M: Moyamoya syndrome in a patient with congenital human immunodeficiency virus infection. *J Child Neurol* 14: 268–270, 1999
  - 20) Ikeda E, Hosoda Y: Distribution of thrombotic lesions in the cerebral arteries in spontaneous occlusion of the circle of Willis: cerebrovascular moyamoya disease. *Clin Neuropathol* 12: 44–48, 1993
  - 21) Ikeda E, Maruyama I, Hosoda Y: Expression of thrombomodulin in patients with spontaneous occlusion of the circle of Willis. *Stroke* 24: 657–660, 1993
  - 22) Ikeda H, Sasaki T, Yoshimoto T, Fukui M, Arinami T: Mapping of a familial moyamoya disease gene to chromosome 3p24.2-p26. *Am J Hum Genet* 64: 533–537, 1999
  - 23) Ikehara S: *The Research Committee on Spontaneous Occlusion of the Circle of Willis (Moyamoya Disease) of the Ministry of Health and Welfare Japan*. Ministry of Health and Welfare Japan, 1992, p 156
  - 24) Inoue TK, Ikezaki K, Sasazuki T, Matsushima T, Fukui M: Analysis of class II genes of human leukocyte antigen in patients with moyamoya disease. *Clin Neurol Neurosurg* 99 Suppl 2: S234–237, 1997
  - 25) Inoue TK, Ikezaki K, Sasazuki T, Matsushima T, Fukui M: Linkage analysis of moyamoya disease on chromosome 6. *J Child Neurol* 15: 179–182, 2000
  - 26) Inoue TK, Ikezaki K, Sasazuki T, Ono T, Kamikawaji N, Matsushima T, Fukui M: DNA typing of HLA in the patients with moyamoya disease. *Jpn J Hum Genet* 42: 507–515, 1997
  - 27) Jeong HC, Kim YJ, Yoon W, Joo SP, Lee SS, Park YW: Moyamoya syndrome associated with systemic lupus erythematosus. *Lupus* 17: 679–682, 2008
  - 28) Jung KH, Chu K, Lee ST, Park HK, Kim DH, Kim JH, Bahn JJ, Song EC, Kim M, Lee SK, Roh JK: Circulating endothelial progenitor cells as a pathogenetic marker of moyamoya disease. *J Cereb Blood Flow Metab* 28: 1795–1803, 2008
  - 29) Kamada F, Aoki Y, Narisawa A, Abe Y, Komatsuzaki S, Kikuchi A, Kanno J, Niihori T, Ono M, Ishii N, Owada Y, Fujimura M, Mashimo Y, Suzuki Y, Hata A, Tsuchiya S, Tominaga T, Matsubara Y, Kure S: A genome-wide association study identifies RNF213 as the first Moyamoya disease gene. *J Hum Genet* 56: 34–40, 2011
  - 30) Kang HS, Kim JH, Phi JH, Kim YY, Kim JE, Wang KC, Cho BK, Kim SK: Plasma matrix metalloproteinases, cytokines and angiogenic factors in moyamoya disease. *J Neurol Neurosurg Psychiatry* 81: 673–678, 2010
  - 31) Kang HS, Kim SK, Cho BK, Kim YY, Hwang YS, Wang KC: Single nucleotide polymorphisms of tissue inhibitor of metalloproteinase genes in familial moyamoya disease. *Neurosurgery* 58: 1074–1080, 2006
  - 32) Kim JH, Jung JH, Phi JH, Kang HS, Kim JE, Chae JH, Kim SJ, Kim YH, Kim YY, Cho BK, Wang KC, Kim SK: Decreased level and defective function of circulating endothelial progenitor cells in children with moyamoya disease. *J Neurosci Res* 88: 510–518, 2010
  - 33) Kim SK, Yoo JI, Cho BK, Hong SJ, Kim YK, Moon JA, Kim JH, Chung YN, Wang KC: Elevation of CRABP-I in the cerebrospinal fluid of patients with Moyamoya disease. *Stroke* 34: 2835–2841, 2003
  - 34) Kitahara T, Okumura K, Semba A, Yamaura A, Maki-no H: Genetic and immunologic analysis on moyamoya. *J Neurol Neurosurg Psychiatry* 45: 1048–1052, 1982
  - 35) Kudo T: Spontaneous occlusion of the circle of Willis. A disease apparently confined to Japanese. *Neurology* 18: 485–496, 1968
  - 36) Kuriyama S, Kusaka Y, Fujimura M, Wakai K, Tamakoshi A, Hashimoto S, Tsuji I, Inaba Y, Yoshimoto T: Prevalence and clinicoepidemiological features of moyamoya disease in Japan: findings from a nationwide epidemiological survey. *Stroke* 39: 42–47, 2008
  - 37) Kuroda S, Houkin K: Moyamoya disease: current concepts and future perspectives. *Lancet Neurol* 7: 1056–1066, 2008
  - 38) Liu W, Hashikata H, Inoue K, Matsuura N, Mineharu Y, Kobayashi H, Kikuta KI, Takagi Y, Hitomi T, Krischek B, Zou LP, Fang F, Herzig R, Kim JE, Kang HS, Oh CW, Tregouet DA, Hashimoto N, Koizumi A: A rare Asian founder polymorphism of Raptor may explain the high prevalence of Moyamoya disease among East Asians and its low prevalence among Caucasians. *Environ Health Prev Med Epub* 2009 Nov 19
  - 39) Liu W, Morito D, Takashima S, Mineharu Y, Kobayashi H, Hitomi T, Hashikata H, Matsuura N, Yamazaki S, Toyoda A, Kikuta K, Takagi Y, Harada KH, Fujiyama A, Herzig R, Krischek B, Zou L, Kim JE, Kitakaze M, Miyamoto S, Nagata K, Hashimoto N, Koizumi A: Identification of RNF213 as a susceptibility gene for moyamoya disease and its possible role in vascular development. *PLoS One* 6: e22542, 2011
  - 40) Mandai S, Tokunaga K, Sugiu K, Terai Y, Kamata I, Kinugasa K, Ohmoto T, Nishimoto A: *Experimental Study of the Pathogenesis of Moyamoya Disease*. Tokyo, The Research Committee on Spontaneous Occlusion of the Circle of Willis (Moyamoya Disease) of the Ministry of Health and Welfare Japan, 1992, pp 163–167
  - 41) Masuda J, Ogata J, Yutani C: Smooth muscle cell proliferation and localization of macrophages and T cells in the occlusive intracranial major arteries in moyamoya disease. *Stroke* 24: 1960–1967, 1993
  - 42) Matsushima Y, Qian L, Aoyagi M: Comparison of

- moyamoya disease in Japan and moyamoya disease (or syndrome) in the People's Republic of China. *Clin Neurol Neurosurg* 99 Suppl 2: S19–22, 1997
- 43) Mineharu Y, Liu W, Inoue K, Matsuura N, Inoue S, Takenaka K, Ikeda H, Houkin K, Takagi Y, Kikuta K, Nozaki K, Hashimoto N, Koizumi A: Autosomal dominant moyamoya disease maps to chromosome 17q25.3. *Neurology* 70(24 Pt 2): 2357–2363, 2008
  - 44) Mineharu Y, Takenaka K, Yamakawa H, Inoue K, Ikeda H, Kikuta KI, Takagi Y, Nozaki K, Hashimoto N, Koizumi A: Inheritance pattern of familial moyamoya disease: autosomal dominant mode and genomic imprinting. *J Neurol Neurosurg Psychiatry* 77: 1025–1029, 2006
  - 45) Nakayama Y, Tanaka A, Nagasaka S, Ikui H: [Intracerebral hemorrhage in a patient with moyamoya phenomenon caused by tuberculous arteritis: a case report]. *No Shinkei Geka* 27: 751–755, 1999 (Japanese)
  - 46) Nanba R, Kuroda S, Ishikawa T, Houkin K, Iwasaki Y: Increased expression of hepatocyte growth factor in cerebrospinal fluid and intracranial artery in moyamoya disease. *Stroke* 35: 2837–2842, 2004
  - 47) Nanba R, Tada M, Kuroda S, Houkin K, Iwasaki Y: Sequence analysis and bioinformatics analysis of chromosome 17q25 in familial moyamoya disease. *Childs Nerv Syst* 21: 62–68, 2005
  - 48) Ni G, Liu W, Huang X, Zhu S, Yue X, Chen Z, Chen M, Liu X, Xu G: Increased levels of circulating SDF-1 $\alpha$  and CD34+ CXCR4+ cells in patients with moyamoya disease. *Eur J Neurol* 18: 1304–1309, 2011
  - 49) Nishimoto A, Takeuchi S: Abnormal cerebrovascular network related to the internal carotid arteries. *J Neurosurg* 29: 255–260, 1968
  - 50) Osawa M, Kanai N, Kawai M, Fukuyama Y: Clinical genetic study on the idiopathic occlusion of the circle of Willis, in: *The Research Committee on Spontaneous Occlusion of the Circle of Willis (Moyamoya Disease) of the Ministry of Health and Welfare Japan Annual Report 1992*. 1992
  - 51) Rafat N, Beck G, Pena-Tapia PG, Schmiedek P, Vajkoczy P: Increased levels of circulating endothelial progenitor cells in patients with Moyamoya disease. *Stroke* 40: 432–438, 2009
  - 52) Roder C, Nayak NR, Khan N, Tatagiba M, Inoue I, Krischek B: Genetics of Moyamoya disease. *J Hum Genet* 55: 711–716, 2010
  - 53) Roder C, Peters V, Kasuya H, Nishizawa T, Takehara Y, Berg D, Schulte C, Khan N, Tatagiba M, Krischek B: Polymorphisms in TGFB1 and PDGFRB are associated with Moyamoya disease in European patients. *Acta Neurochir (Wien)* 152: 2153–2160, 2010
  - 54) Sakurai K, Horiuchi Y, Ikeda H, Ikezaki K, Yoshimoto T, Fukui M, Arinami T: A novel susceptibility locus for moyamoya disease on chromosome 8q23. *J Hum Genet* 49: 278–281, 2004
  - 55) Sata M, Saiura A, Kunisato A, Tojo A, Okada S, Tokuhisa T, Hirai H, Makuuchi M, Hirata Y, Nagai R: Hematopoietic stem cells differentiate into vascular cells that participate in the pathogenesis of atherosclerosis. *Nat Med* 8: 403–409, 2002
  - 56) Schonling M, Klein R, Krageloh-Mann I, Falck M, Bien S, Berg PA, Michaelis R: Antiphospholipid antibodies in cerebrovascular ischemia and stroke in childhood. *Neuropediatrics* 25: 8–14, 1994
  - 57) Scott RM: Moyamoya. *J Neurosurg Pediatr* 2: 158, author reply 158, 2008
  - 58) Scott RM, Smith ER: Moyamoya disease and moyamoya syndrome. *N Engl J Med* 360: 1226–1237, 2009
  - 59) Simper D, Stalboerger PG, Panetta CJ, Wang S, Caplice NM: Smooth muscle progenitor cells in human blood. *Circulation* 106: 1199–1204, 2002
  - 60) Smith ER, McClain CD, Heeney M, Scott RM: Pial synangiosis in patients with moyamoya syndrome and sickle cell anemia: perioperative management and surgical outcome. *Neurosurg Focus* 26(4): E10, 2009
  - 61) Sugiyama T, Kuroda S, Nakayama N, Tanaka S, Houkin K: Bone marrow-derived endothelial progenitor cells participate in the initiation of moyamoya disease. *Neurol Med Chir (Tokyo)* 51: 767–773, 2011
  - 62) Suzuki J, Kodama N: Cerebrovascular “Moyamoya” disease. 2. Collateral routes to forebrain via ethmoid sinus and superior nasal meatus. *Angiology* 22: 223–236, 1971
  - 63) Suzuki J, Takaku A: Cerebrovascular “moyamoya” disease. Disease showing abnormal net-like vessels in base of brain. *Arch Neurol* 20: 288–299, 1969
  - 64) Suzuki S, Mitsuyama T, Horiba A, Fukushima S, Hashimoto N, Kawamata T: Moyamoya disease complicated by Graves' disease and type 2 diabetes mellitus: report of two cases. *Clin Neurol Neurosurg* 113: 325–329, 2011
  - 65) Takagi Y, Kikuta K, Nozaki K, Fujimoto M, Hayashi J, Imamura H, Hashimoto N: Expression of hypoxia-inducing factor-1  $\alpha$  and endoglin in intimal hyperplasia of the middle cerebral artery of patients with Moyamoya disease. *Neurosurgery* 60: 338–345, 2007
  - 66) Takasugi H, Maemoto T, Kitazawa K, Honda A: [A case of Down syndrome with moyamoya syndrome presenting extensive multiple cerebral infarction during measles infection]. *No To Hattatsu* 32: 39–43, 2000 (Japanese)
  - 67) Takeuchi K, Shimizu K: Hypoplasia of the bilateral internal carotid arteries. *Brain Nerve* 9: 37–43, 1957
  - 68) Tanigawara T, Yamada H, Sakai N, Andoh T, Deguchi K, Iwamura M: Studies on cytomegalovirus and Epstein-Barr virus infection in moyamoya disease. *Clin Neurol Neurosurg* 99 Suppl 2: S225–228, 1997
  - 69) Ueno M, Kira R, Matsushima T, Inoue T, Fukui M, Gondo K, Ihara K, Hara T: Moyamoya disease and transforming growth factor-beta1. *J Neurosurg* 92: 907–908, 2000
  - 70) Ueno M, Oka A, Koeda T, Okamoto R, Takeshita K: Unilateral occlusion of the middle cerebral artery after varicella-zoster virus infection. *Brain Dev* 24: 106–108, 2002

- 71) Wakai K, Tamakoshi A, Ikezaki K, Fukui M, Kawamura T, Aoki R, Kojima M, Lin Y, Ohno Y: Epidemiological features of moyamoya disease in Japan: findings from a nationwide survey. *Clin Neurol Neurosurg* 99 Suppl 2: S1-5, 1997
- 72) Wanifuchi H, Kagawa M, Takeshita M, Izawa M, Maruyama S, Kitamura K: [Autoimmune antibody in moyamoya disease]. *No Shinkei Geka* 14: 31-35, 1986 (Japanese)
- 73) Weinberg DG, Arnaout OM, Rahme RJ, Aoun SG, Batjer HH, Bendok BR: Moyamoya disease: a review of histopathology, biochemistry, and genetics. *Neurosurg Focus* 30(6): E20, 2011
- 74) Yamada H, Deguchi K, Tanigawara T, Takenaka K, Nishimura Y, Shinoda J, Hattori T, Andoh T, Sakai N: The relationship between moyamoya disease and bacterial infection. *Clin Neurol Neurosurg* 99 Suppl 2: S221-224, 1997
- 75) Yamamoto M, Aoyagi M, Fukai N, Matsushima Y, Yamamoto K: Increase in prostaglandin E(2) production by interleukin-1beta in arterial smooth muscle cells derived from patients with moyamoya disease. *Circ Res* 85: 912-918, 1999
- 76) Yamauchi T, Houkin K, Tada M, Abe H: Familial occurrence of moyamoya disease. *Clin Neurol Neurosurg* 99 Suppl 2: S162-167, 1997
- 77) Yamauchi T, Tada M, Houkin K, Tanaka T, Nakamura Y, Kuroda S, Abe, H, Inoue, T, Ikezaki, K, Matsushima, T, Fukui, M: Linkage of familial moyamoya disease (spontaneous occlusion of the circle of Willis) to chromosome 17q25. *Stroke* 31: 930-935, 2000
- 78) Yoshihara T, Taguchi A, Matsuyama T, Shimizu Y, Kikuchi-Taura A, Soma T, Stern DM, Yoshikawa H, Kasahara Y, Moriwaki H, Nagatsuka K, Naritomi H: Increase in circulating CD34-positive cells in patients with angiographic evidence of moyamoya-like vessels. *J Cereb Blood Flow Metab* 28: 1086-1089, 2008

---

Address reprint requests to: Kiyohiro Houkin, MD, Department of Neurosurgery, Hokkaido University Graduate School of Medicine, North 15 West 7, Kita-ku, Sapporo, Hokkaido 060-8638, Japan.  
e-mail: houkin@med.hokudai.ac.jp