

## Review of the functional surgical treatment of dystonia

KRACK, Paul, VERCUCIL, Laurent

KRACK, Paul, VERCUCIL, Laurent. Review of the functional surgical treatment of dystonia. *European journal of neurology*, 2001, vol. 8, no. 5, p. 389-399

PMID : 11554902

Available at:

<http://archive-ouverte.unige.ch/unige:95865>

Disclaimer: layout of this document may differ from the published version.

## Review of the functional surgical treatment of dystonia

Paul Krack<sup>a</sup> and Laurent Vercueil<sup>b</sup>

<sup>a</sup>Neurology Department, University of Kiel; and <sup>b</sup>Neurology Department, University of Grenoble, Germany

### Key words:

deep brain stimulation, dystonia, pallidotomy, thalamotomy

Received 12 September 2000  
Accepted 28 February 2001

A review of functional surgery for dystonia is presented. Recently renewed interest in stereotaxy for dystonia has followed the resurgence of pallidotomy and the introduction of deep brain stimulation (DBS) in Parkinson's disease (PD) in the early 1990s. However, even since the 1950s, small series of patients treated with ablative surgery have been carefully studied, providing useful information, notably regarding the tolerability of surgery. In the setting of dystonia, thalamotomy was first performed with substantial benefits, but some authors outlined the great variability in outcome, and the high incidence of operative side-effects. In the 'modern' era of functional surgery for movement disorders, the globus pallidus internus (GPi) has emerged to be currently the best target for dystonia, based on small series of patients published in the last few years. Both bilateral posteroventral pallidotomy (PVP) and bilateral pallidal stimulation, performed by several teams, have benefited a variety of patients with severe dystonia, the most dramatic improvements being seen in primary dystonia with a mutation in the DYT1 gene. Whereas patients with secondary dystonia have often shown a lesser degree of improvement, some publications have nevertheless reported major benefit. There is today a strong need for carefully controlled studies comparing secondary and primary dystonia, DYT1 and non-DYT1 dystonia, ablative surgery and DBS, with additional assessment of neuropsychological changes, especially in children treated with bilateral pallidal procedures.

### Introduction

Dystonia is a clinical syndrome characterized by sustained muscle contractions, frequently causing twisting and repetitive movements or abnormal postures (Fahn, 1988). In some subjects dystonia may progress to a life-threatening stage or constitute a major fixed handicap. Whilst the established efficacy of botulinum toxin is limited to focal manifestations, and despite the notable exception of dopa-responsive dystonia, pharmacological treatment is mostly unsatisfactory in generalized dystonia or hemidystonia. In this context, efforts have been made since the early 1950s to provide alternative solutions, including peripheral denervation surgery, intrathecal baclofen pumps and functional stereotactic surgery. The present review will focus on stereotaxy for severe dystonia.

Today, the definition of dystonia includes athetosis. In the older literature, distal mobile dystonia used to

be called athetosis, and generalized dystonia in the setting of perinatal cerebral hypoxia used to be called double athetosis. Etiologic classification of dystonia is also changing with the progress in classification of genetic dystonias (Fahn *et al.*, 1998). The present review deals with primary dystonias (including those with a known genetic defect), and secondary dystonias.

Classically, the main target for dystonia was the thalamus (Cooper, 1976). Presently, there is a trend in favour of pallidotomy, which is related to the renaissance of posteroventral pallidotomy (PVP) for Parkinson's disease (PD), its spectacular effects on levodopa-induced dyskinesias, including off dystonia (Lozano *et al.*, 1995; Jankovic *et al.*, 1999), and some reports of spectacular improvements of generalized dystonia related to pallidotomy (Iacono *et al.*, 1996; Lozano *et al.*, 1997). In parallel, successful development of deep brain stimulation (DBS) in the setting of movement disorders (Benabid *et al.*, 1996; Limousin *et al.*, 1998), including various type of dystonia related to PD (Krack *et al.*, 1999), represent an alternative to ablative surgery. Recent reports on bilateral pallidal stimulation in primary generalized dystonia are highly encouraging (Coubes *et al.*, 1999, 2000c).

Correspondence: Paul Krack, Neurology Department, University of Kiel, Niemannsweg 147, 24105 Kiel, Germany  
(fax: +49-431-597-2712; e-mail: p.krack@neurologie.uni-kiel.de).

## Lesions

### Thalamotomy for dystonia

Brain surgery for dystonia followed the development of surgery for PD and the observation of improvement of dystonic symptoms in parkinsonian subjects. In the setting of thalamotomy, the lesions required to improve dystonia often had to be larger than those that led to suppression of PD tremor. Apart from the ventrolateral thalamus (Voa, Vop, Vim), the subthalamic region and the centromedian nucleus, the sensory ventrolateral thalamus and the pulvinar were also targeted (Hassler and Riechert, 1954; Hassler and Dieckmann, 1970; Mundinger *et al.*, 1970; Krayenbühl and Siegfried, 1972; Andrew *et al.*, 1974; Gros *et al.*, 1976; Andrew *et al.*, 1983; Tasker *et al.*, 1988; Cardoso *et al.*, 1995; Tasker, 1998a,b). Cooper had the largest experience. Between 1955 and 1974, he performed thalamotomies in 226 patients with generalized dystonia. Many patients were operated more than once, with up to seven operations and up to 13 lesions in single patients. Because of the risk of speech disturbance, he did not carry out simultaneous bilateral operations. Without any doubt, Cooper obtained very spectacular long-term results in some of his patients with severe generalized dystonia, as evidenced by his published photographs (Cooper, 1976). The vast majority of the patients he had operated for generalized dystonia were available for long-term follow up. Amongst these, after an average of 8 years after surgery, 25% had good and 45% moderate improvement, despite the frequently progressive nature of this disease. The initial target was the VL and the centromedian nucleus. Post-operative improvement was progressive for up to 6 months. If a further operation was required, Cooper tried to destroy all the pallidal and cerebellar afferents to the thalamus. If the patient was still disabled, he added a pulvinotomy. Operative mortality was 0.7% but increased to 2% after repeated interventions. Patients were mostly young. The outcome was best in patients with hereditary torsion dystonia. Cooper attributed this to the fact that in this group of patients, appendicular dystonia was more prominent, because in his experience axial dystonia was more resistant to thalamic surgery. Despite good results in single cases with cervical dystonia, Cooper did not regard focal cervical dystonia as an indication, as bilateral surgery was necessary, with mortality risk of 2%, an incidence of speech disturbance of 15%, and a failure of this therapy in one-third of the patients (Cooper, 1976). On the other hand, Tasker found a 25–50% improvement in 25% of his patients, a more than 50%

improvement in another 25%, and severe complications in 20% (Tasker *et al.*, 1988). In his opinion, the global success was moderate. Bertrand pointed out that the corticobulbar tract within the internal capsule is much closer to the thalamic target than the corticospinal tract. Because of the high incidence of speech disturbance he only performed unilateral thalamotomies (Bertrand *et al.*, 1979). According to Ohye, dysarthria is related to a disturbance in proprioception. Therefore, his advice is to avoid lesioning those cells which, on microrecording, show kinesthetic responses from stimulation of the lips, tongue or pharynx (Ohye, 1998). Andrew also observed a higher incidence of speech disturbance than Cooper (Andrew *et al.*, 1983). To him hemidystonia after a brain lesion was a better indication than generalized primary dystonia, as hemidystonia is not usually progressive, and the risk of dysarthria is lower with unilateral surgery (Andrew *et al.*, 1983). In another case series, patients with secondary dystonia showed greater improvement after thalamotomy than patients with primary dystonia (Cardoso *et al.*, 1995). The authors destroyed unilaterally (in all but one patient) the anterior portion of the ventrolateral nucleus for patients with dystonia, whilst they targeted the nucleus ventrointermedius of the thalamus (Vim) in hemiballismus with good results. Based on a retrospective analysis of the long-term outcome, Speelman and van Manen considered moderate infantile cerebral palsy with hyperkinesia, especially when lateralized, as a good indication for unilateral thalamotomy (and pallidotomy). However, in case of severe bilateral symptoms or in diplegia, they did not recommend surgery (Speelman and Van Manen, 1989). Thalamotomy can also be effective in tardive dystonia (Hillier *et al.*, 1999), or dopa-responsive dystonia (Batshaw and Haslam, 1976) although others have not found improvement (De la Fuente-Fernandez, 1998).

In summary, whilst comparing findings from different reports is difficult because of the difference in the nuclei targeted, the surgical procedure, selection of patients and rating scales, thalamotomy can certainly induce spectacular improvement in generalized dystonia (Cooper, 1976). However, some authors believe that the number and severity of complications, notably of speech disturbance, is lower after pallidotomy, than after thalamotomy (Bertrand *et al.*, 1979; Hariz and DeSalles, 1997; Hariz, 2000a). Moreover, there are no comparative studies, the number of patients operated with modern technology is very low and the follow up very short, so the place of thalamotomy in the setting of functional surgery for dystonia remains uncertain.

## Pallidotomy

### The lessons from pallidotomy for dyskinesia in PD

Successful surgery for PD started with Meyers' 'experimental' open surgery of the basal ganglia. Lesions of the internal pallidum were found to potentially improve parkinsonism (Meyers, 1940, 1942a, 1942b, 1958). However, the morbidity of Meyers' open surgery was high, and therefore only very few neurosurgeons dared to operate on the basal ganglia (Fénelon, 1950; Guiot and Brion, 1952). After the introduction of stereotaxy in humans by Spiegel and Wycis (Spiegel *et al.*, 1947), several neurosurgeons started to perform stereotactic pallidotomies in parkinsonism in the 1950s (Guiot, 1958; Narabayashi and Okuma, 1953; Cooper and Poloukhine, 1955; Bertrand, 1958; Svnilson *et al.*, 1960). This 'early' globus pallidus internus (GPi) pallidotomy survived for only a short time. Although pallidotomy was clearly shown to improve akinesia (Orthner & Roeder, 1959; Svnilson *et al.*, 1960), most neurosurgeons abandoned their pallidotomies in the 1960s and moved to VL and later to Vim thalamotomy because of a more reproducible antitremor effect (for review see Laitinen, 2000). Subsequently, the introduction of levodopa treatment in PD led to the almost complete disappearance of functional surgery for parkinsonism. However, the considerable amount of motor complications related to dopaminergic therapy, including on-period dyskinesia and off-period dystonia, induced a resurgence of functional surgery, stimulated by the development of techniques allowing more accurate targeting. Following 'modern' PVP, it has been observed that, in on-drug condition, dyskinesias are improved by 77% contralaterally, and by 43% ipsilaterally (Lang *et al.*, 1997). Off dystonia is also improved. These results have been confirmed in a randomized, single-blind, multicenter trial (De Bie *et al.*, 1999). However, only a few studies have a follow up of more than 1 year (Laitinen *et al.*, 1992; Fazzini *et al.*, 1997; Lang *et al.*, 1997; Kondziolka *et al.*, 1999; Samii *et al.*, 1999; Baron *et al.*, 2000; Fine *et al.*, 2000). Improvements of ipsilateral dyskinesias and of axial symptoms were lost after 2 years, whereas the dramatic reduction in contralateral dyskinesias persisted (Lang *et al.*, 1997; Baron *et al.*, 2000; Fine *et al.*, 2000; Hariz, 2000b).

#### *Side-effects of unilateral pallidotomy*

The most serious complications of pallidotomy are intracerebral hematomas. In a meta-analysis of 19 papers from 1992 to 1998, the incidence ranged from 0 to 15% with a mean of approximately 2% (11 of 554 patients). The overall incidence of death from pallido-

tomy was 0.3% (Hallett *et al.*, 1999). Other serious reported complications including worsening of cognitive function, most commonly decreased verbal fluency and working memory (Trépanier *et al.*, 1998; Junqué *et al.*, 1999). Generally the functional consequences of cognitive problems after unilateral PVP are considered to be minimal, provided there had been no cognitive deterioration prior to the surgery (Baron *et al.*, 1996; Hariz and DeSalles, 1997; Soukup *et al.*, 1997; Masterman *et al.*, 1998; Perrine *et al.*, 1998). Delayed infarctions are rare, but belong to the serious complications of PVP (Lim *et al.*, 1997; Samuel *et al.*, 1998). Hemiparesis and/or pseudobulbar paresis may occur, if the lesion encroaches on the internal capsule (Baron *et al.*, 1996; Hariz and DeSalles, 1997; Lang *et al.*, 1997; Giller *et al.*, 1998). One study was devoted to the side-effects and complications of 152 pallidotomies in 138 consecutive patients. Transient side-effects occurred after 18%, and permanent complications after 9% of the procedures. There was no mortality (Hariz and DeSalles, 1997).

#### *Side-effects of bilateral pallidotomy*

In contrast to the pre-levodopa era, bilateral pallidotomies are rarely performed today (Iacono *et al.*, 1995; Laitinen, 1995; Hariz and DeSalles, 1997; Schuurman *et al.*, 1997; Scott *et al.*, 1998; Ghika *et al.*, 1999). Bilateral lesions of the pallido-thalamo-cortical circuit in the pallidum (Hartmann von Monakow, 1959; Svnilson *et al.*, 1960; Dubois *et al.*, 1995; Ghika *et al.*, 1999) can lead to a severe frontal dysexecutive syndrome. Therefore, the exact size and site of the lesion are of major importance. This was first pointed out by Orthner and Roeder, who, in a series of bilateral posterior pallidotomies in 18 patients with a mean follow up of 3 years, found no severe neuropsychologic problems, which they attributed to the sparing of the oral region of the pallidum (Orthner *et al.*, 1962). Laitinen also recommended sparing the anterodorsal pallidum in order to avoid cognitive problems, and he warned against too medial lesions in order to avoid capsular effects and visual field deficits. Therefore, he called his approach ventropostero *lateral* pallidotomy, which he considered as relatively safe, even when performed bilaterally (Laitinen, 1995, 1998, 2000). Recently Lombardi *et al.* found a relationship between lesion location and cognitive outcome. Anteromedial lesions led to post-surgical impairment, whereas posterolateral lesions did not, or even improved the performance in some neuropsychological tests (Lombardi *et al.*, 2000). Speech problems are also a matter of concern after bilateral pallidotomy, but the incidence and severity of pseudobulbar syndromes after pallidotomy is estimated to be much lower than after bilateral thalamotomy (Hariz and DeSalles, 1997). Based on its

high morbidity in the recent literature, bilateral pallidotomy was not recommended by a task force on surgery for PD (Hallett *et al.*, 1999). However, the reports that have been reviewed represent the initial experience of several groups with variable experience in functional neurosurgery, some of the lesions obviously being too large or misplaced in the anterodorsal pallidum. On the other hand Laitinen, from 1985 to 1996 carried out pallidotomies, without microrecording, in 470 patients. Over 60 of them had staged bilateral pallidotomies. There was neither mortality nor any severe morbidity in his series. Based on the experience of a few experienced groups with positive results (Orthner *et al.*, 1962; Laitinen, 1995; Hariz, 1997), one can hope that future studies will rehabilitate bilateral PVP, especially in view of the promising preliminary results of pallidotomy in generalized dystonia.

### Pallidotomy for dystonia

In generalized dystonia, compared with thalamotomy, only a few small series of pallidotomies were published during the first era of functional surgery (Guiot and Brion, 1952; Hassler *et al.*, 1960; Cooper, 1969; Burzaco, 1985). Pallidotomies were also rarely performed in cervical dystonia (Hassler and Riechert, 1954; Munding *et al.*, 1972; Bertrand *et al.*, 1978). Spiegel *et al.* reported successful pallidotomy in posthemiplegic athetosis and in double athetosis when operating contralaterally to the most severely affected side (Spiegel *et al.*, 1958). Altogether, judgement of surgery for hyperkinesia in infantile cerebral palsy was reserved, because of the higher risks of side-effects in brains with a prior lesion (Speelman and van Manen, 1989).

In recent years, with the renaissance of PVP for PD, pallidotomy was also rediscovered in the treatment of generalized dystonia (Iacono *et al.*, 1995; Lozano *et al.*, 1997; Shima *et al.*, 1997; Lenz *et al.*, 1998; Lin *et al.*, 1998, 1999a, 1999b; Ondo *et al.*, 1998; Vitek *et al.*, 1998; 1999). For different reasons (dystonic postures incompatible with the stereotactic frame, reduced ability of children to cooperate during surgery, questionable intraoperative effects of stimulation on dystonia), surgery was partly performed under general anesthesia (Lozano *et al.*, 1997; Ondo *et al.*, 1998). When using propofol anesthesia, microrecording could be used (Lozano *et al.*, 1997), whilst macrostimulation allowed an assessment of surrounding structures (mainly internal capsular side-effects). In contrast to PD, post-operative improvements were slowly progressive in the course of the first post-operative months (Iacono *et al.*, 1996; Lozano *et al.*, 1997; Ondo *et al.*, 1998). Improvements in paroxysmal (Bhatia *et al.*, 1998) or tardive dystonia (Weetman *et al.*, 1997; Vitek

*et al.*, 1999) with PVP were also reported. Single spectacular results of PVP were mainly observed in primary dystonia (Iacono *et al.*, 1996; Lozano *et al.*, 1997). However, in secondary dystonia the results are not always positive (Lin *et al.*, 1999a, 1999b; Khan *et al.*, 2000). Significant improvement has been reported for dystonia in the setting of progressive neurodegeneration such as Hallervorden-Spatz (Justesen *et al.*, 1999) or Huntington's disease (Cubo *et al.*, 1999), but in one detailed case report, this improvement appeared to be modest (Cubo *et al.*, 2000). In contrast, two patients with corticobasal degeneration were not improved after pallidotomy (Junn *et al.*, 1998). Overall, authors have suggested that the more the pre-operative brain images look normal, the better should be the outcome after pallidal surgery (Khan *et al.*, 2000). However, even in DYT1 patients, a risk for recurrence of dystonia in the months or years following ablative surgery, may not be low (Nomura *et al.*, 2000).

Little is known about neuropsychological outcome, but bilateral pallidotomies appeared to be well tolerated in children, even with large lesions.

### DBS for dystonia

The introduction of DBS of the ventral Vim for the treatment of drug-resistant tremors (Benabid *et al.*, 1987, 1991; Limousin *et al.*, 1999), followed by the application of the same procedure to the subthalamic nucleus (STN) (Pollak *et al.*, 1993; Limousin *et al.*, 1995, 1998) and the GPi (Siegfried and Lippitz, 1994), with even greater improvements of motor fluctuations and dyskinesia, including dystonia (Krack *et al.*, 1999), suggests that DBS could constitute a first-line treatment for dystonia, as it is reversible and modifiable (Pollak, 1999).

### Thalamic DBS

In 1977, Munding reported good short-term (up to 8 months) results of unilateral intermittent (30 min, several times per day), low-frequency (2–12 Hz) thalamic (Voa, Voi and subthalamic area) DBS in seven patients with cervical dystonia (Munding, 1977). However, for unknown reasons, the method was abandoned and no long-term results were reported. Andy also found intermittent low frequency thalamic stimulation to be useful in two patients with torticollis (Andy, 1983) whilst another report mentioned reduction of dyskinesias in four patients treated with low-frequency (33 Hz) stimulation of the thalamus sensory nucleus for painful thalamic syndrome (Siegfried, 1986). Sellal *et al.* found a dramatic improvement of a symptomatic hemidystonia with stimulation of the

ventroposterolateral thalamus using the following parameters: 1.75 V/210  $\mu$ s/60 Hz intermittent stimulation during 6 ms in intervals of 10 s. In this particular patient, dystonia was highly sensitive to superficial sensory stimuli, in the sense of a 'geste antagoniste'. As the patient experienced dysaesthesiae in the dystonic hand with the beginning of each series of stimulation, the authors suggested that the stimulation effect in this patient could be related to this repetitive sensory stimulus (Sellal *et al.*, 1993). The Grenoble group applied their technique of high frequency Vim stimulation in 12 patients with generalized dystonia. Stimulation frequency was the same, but voltage and pulse width were higher than in patients with PD tremor. Five patients experienced a mild to moderate improvement of limb dystonia, whereas axial symptoms were not improved. Seven patients had no benefit (Pollak *et al.*, 1998; Pollak, 1999; Vercueil L *et al.*, in press).

### Pallidal DBS

Interestingly, an old report had mentioned that low frequency (4–8 Hz) stimulation of the pallidum in torsion dystonia and athetosis could elicit abnormal movements, whilst higher stimulus frequencies applied to the same target may eventually suppress them (Hassler *et al.*, 1960). However, little was inferred from this observation, and so far there are only a few reports of the effects of pallidal DBS in dystonia (Coubes *et al.*, 1999, 2000a,b,c; Krauss *et al.*, 1999; Kumar *et al.*, 1999; Loher *et al.*, 2000; Tronnier and Fogel, 2000; Gill *et al.*, 2000; Kulisevsky *et al.*, 2000; Liu *et al.*, 2000; Parkin *et al.*, 2001). A dramatic improvement was observed in an 8-year-old girl, who had been under sedation and permanent controlled respiratory assistance because of severe generalized primary (DYT1 negative) dystonia. The girl became independent and returned to school after bilateral pallidal DBS. Thirty months after operation, the neurological examination was close to normal (Coubes *et al.*, 1999). The same team extended their observations to 15 patients, with a mean reduction in dystonia scores by 81.3%, even greater in DYT1 patients (90.3% reduction), and a mean follow up of 12 months (range 3–36) (Coubes *et al.*, 2000a). A similar degree of benefit was obtained in one DYT1 patient treated with pallidal DBS by another team (Vercueil L. *et al.*, submitted). Three patients with severe focal cervical dystonia had a good improvement of dystonia intensity, pain and function with bilateral pallidal DBS (Krauss *et al.*, 1999). These results in cervical dystonia have been reproduced by another team (Parkin *et al.*, 2001), whilst two patients were reported with pain reduction without significant improvement in the cervical motor disorder (Kulisevsky

*et al.*, 2000). Myoclonus in familial myoclonic dystonia has been reported to be improved by GPi DBS in one patient (Liu *et al.*, 2000). In some of the reports, the pulse width and voltage used were much higher than generally used in PD (Coubes *et al.*, 1999; Krauss *et al.*, 1999), thus certainly diffusing to other structures than the GPi. The stimulation frequencies were identical to those used in PD (130–160 Hz). In the young girl reported by Coubes (Coubes *et al.*, 1999), the pulse generators had to be replaced after less than 1 year. Tronnier and Fogel reported three patients with bilateral pallidal DBS for generalized dystonia, with a follow up of 6–18 months. The two patients who suffered from primary dystonia (one DYT1 negative, one DYT1 positive) experienced good to marked improvement, whereas the patient with a secondary dystonia was only mildly improved. Stimulation parameters are not mentioned in the paper (Tronnier and Fogel, 2000). A PET study was carried out in one patient whose dystonia was improved with bilateral pallidal DBS (Kumar *et al.*, 1999). During joystick movement, GPi DBS reduced PET activation bilaterally in a large part of the frontal cortex, and ipsilaterally in the lentiform nucleus. In this patient the pulse width and voltage used were very high. In contrast to all other reports, the authors found a stimulation frequency of 50 Hz to be optimal. Another report mentioned long-term efficacy (4 years) of GPi DBS for post-traumatic dystonia. In this patient, stimulation amplitude was lower than in previous reports (Loher *et al.*, 2000).

So far, this therapy remains investigational, but many other teams are currently using the technique, mainly in Europe (Bötzel *et al.*, 2000; Fogel *et al.*, 2000; Funk *et al.*, 2000; Islekel *et al.*, 2000; Paul *et al.*, 2000). Too little is known to judge the efficacy or to compare pallidal DBS with pallidotomy for dystonia. However some trends are emerging. By analogy to pallidotomy, the post-operative improvement occurs progressively in the first weeks or months. This complicates the setting of the electrical parameters. Stimulation parameters tend to be much higher than in PD. This may be because of the lack of experience, or of the fact that the best target within the pallidum is not yet known. However, if it turns out that such high stimulation parameters will be necessary as a rule to obtain good clinical results, then one should not speak of GPi stimulation, but rather of pallidal stimulation. DBS using these electrical parameters would be much more expensive than in pallidal DBS for PD, especially as patients with generalized dystonia tend to be younger than patients with PD. The pressure to use bilateral pallidotomy rather than bilateral pallidal DBS for economic reasons may be growing, despite the side-effects of bilateral pallidotomy discussed in the chapter

on PVP for PD. However, the concerns of pediatric neurosurgeons, who warn against lesioning a brain in development, must also be taken very seriously.

## Current issues in stereotaxy for dystonia

### Is pallidal surgery better than thalamic surgery?

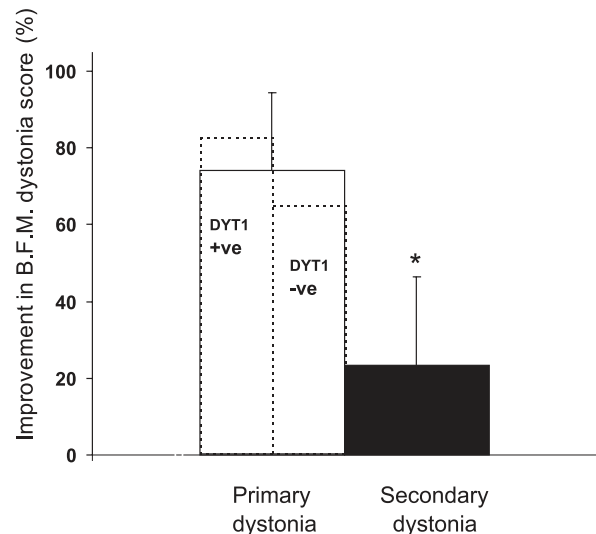
The dramatic improvement observed following pallidal surgery in patients with generalized primary dystonia appears superior to the results of thalamic surgery. However, there are very few data comparing the two targets. Furthermore, one report with DBS (where multiple procedures are relatively safe) seemed to indicate, at least in some patients, that results could be better with a thalamic than with a pallidal target (Ghika *et al.*, 2000). A careful investigation between the respective indication of the two targets is mandatory.

### Should surgery be proposed in secondary dystonia?

Evidence has accumulated to favour primary dystonia in the setting of functional surgery (Coubes *et al.*, 2000c). However, examination of the literature shows that occasionally dramatic improvement may be achieved in secondary dystonia, and that the benefit can be maintained in the long term (Speelman *et al.*, 1989; Loher *et al.*, 2000). On average, mean improvement of dystonia scores is lower in secondary dystonia, with a larger standard deviation, indicating more variable results (Fig. 1). Efforts should be made to determine the patients, amongst those with secondary dystonias, who will respond best to surgery. In the absence of a pharmacological test comparable with the levodopa challenge in PD, and of functional imaging revealing underlying neurotransmitter defects, it may turn out that magnetic resonance imaging (MRI) is the main predictor of outcome. Normal MRI seems to predict the best results, whereas patients with diffuse lesions usually do not seem to benefit from stereotactic surgery (Khan *et al.*, 2000). In primary dystonias, classification of genetic defects may also be of predictive value (Coubes *et al.*, 2000a).

### Ablative procedures versus DBS

In experienced hands, DBS carries the risk of infection of the implanted material, breaking of the connecting leads or migration of the material in 3–4% of implants (Pollak *et al.*, 1998). However, these side-effects can be managed without permanent morbidity. Batteries must be replaced at regular intervals. The device is expensive. Adapting electrical parameters can be time consuming. Development of a tolerance phenomenon to DBS



**Figure 1** Mean percentage improvements in the Burke-Fahn-Marsden Dystonia Rating Scale for movement (Burke *et al.*, 1985) after bilateral pallidal surgery (either DBS or lesioning) from the literature. Three groups of patients are compared (i) 10 patients with primary DYT1 positive, (ii) 10 patients with primary DYT1 negative and (iii) 28 patients with secondary dystonias. There was a trend for a better improvement in DYT1 positive versus DYT1 negative primary dystonias (dotted lines represent DYT1 positive and negative subgroups), and a significant ( $*P < 0.05$ , using Student's *t*-test) difference between primary (DYT1 positive and negative) and secondary dystonias. Mean maximal post-operative follow-up was  $10.5 \pm 3.4$  months for DYT1 positive,  $7.5 \pm 5.8$  for DYT1 negative primary dystonia, and  $10.4 \pm 3.3$  for secondary dystonia. Data are from the following references: Lozano *et al.*, 1997; Ondo *et al.*, 1998; Lin *et al.*, 1998, 1999a, 1999b; Kumar *et al.*, 1999; Coubes *et al.*, 2000c; Tronnier and Fogel, 2000; Vercueil *et al.*, in press.

(Pollak *et al.*, 1998) is a concern that will have to be compared with the loss of efficacy in the long term after ablative surgery.

The most striking argument in favour of DBS is the feasibility of bilateral surgery which, in contrast to ablative surgery, has an acceptable morbidity rate (Pollak *et al.*, 1998). Recently Schuurman *et al.* conducted a randomized single-centre trial of thalamotomy versus Vim stimulation with the same surgical team using the same stereotactic approach. Thalamic stimulation and thalamotomy were equally effective for tremor suppression, but stimulation had a lower morbidity. Vim stimulation resulted in more improvement of functional abilities than thalamotomy (Schuurman *et al.*, 2000). Another argument that favours DBS is its reversibility. Worsening of dystonia has been reported in one case after PVP without subsequent resolution after implantation of a contralateral pallidal electrode for chronic stimulation. Switching on the stimulator invariably resulted in further worsening of the dystonia,

so it was decided to switch off the stimulator. Because of the controlateral lesion, the patient did not recover to his pre-operative state (Cervera *et al.*, 2000).

### Functional surgery allows a better understanding of the pathophysiology of dystonia

Presently, there is no good animal model of dystonia. Microrecording during surgical procedures has given the possibility to analyse the pattern of neuronal discharge in subcortical structures. Reorganization of sensory maps had been demonstrated within the motor thalamus of patients with dystonia (Zihr *et al.*, 1998; Lenz *et al.*, 1999), which may parallel the abnormal sensory cortical function disclosed in dystonic subjects (Hallett, 1995, 1998; Bara-Jimenez *et al.*, 1998, 2000). Similar findings were evident during pallidal recording (Lenz *et al.*, 1998). These findings emphasize the concept that dystonia is not just a motor, but rather a sensorimotor, disorder (Hallett, 1995). A large decrease in firing rate of internal pallidal neurons, with abnormal grouping of discharges in burst-pause pattern, has recently been shown (Lenz *et al.*, 1998; Vitek *et al.*, 1999). The results of pallidal surgery in dystonia may prove (i) the key role of basal ganglia dysfunction in the physiology of dystonia, and (ii) the relevance of an abnormal pattern of neuronal activity, rather than the quantitative amount of firing rate, as pallidotomy can relieve dystonia without inducing other neurological deficits.

### Requirements for future studies

Dystonia encompasses a very wide range of patients. The clinical, etiological and, presumably pathophysiological, heterogeneity of these patients suggests the need for the constitution of homogeneously controlled group of patients requiring stereotaxy, with a special emphasis on etiology. Careful selection of patients, for example on genetic grounds, will be mandatory for correctly assessing the clinical efficacy of stereotaxic surgery (Coubes *et al.*, 2000c).

Another major concern is represented by the evaluation of the outcome after surgery. Dystonia scales are numerous, but few are validated. Although subject to certain criticisms, the Burke, Fahn and Marsden scale remains the most frequently used (Burke *et al.*, 1985). Attempts to develop new scales have so far been unsatisfactory, with poor inter-rater reliability. Blinded assessment of clinical outcome after pallidotomy, or double-blind evaluation with the stimulator alternatively switched OFF and ON in the case of DBS, will be mandatory for future studies, as dystonia is very sensitive to psychological factors, and the degree of placebo effect following aggressive procedures is presumably high.

### Conclusions

In patients with generalized dystonia, the internal pallidum presently seems to be the best surgical target. These patients require bilateral surgery using either DBS or lesioning. There are presently not enough data on the safety of bilateral pallidotomies, especially in children. On the other hand, little is known about the long-term effects and side-effects of bilateral pallidal stimulation. Only a comparative study of bilateral pallidal DBS versus bilateral pallidotomy for generalized primary dystonia, with a long-term follow up, could establish the respective value of these two promising therapies.

### References

- Andrew J, Edwards JM, Rudolf NM (1974). The placement of stereotaxic lesions for involuntary movements other than in Parkinson's disease. *Acta Neurochir (Wien)* **21**:39–47.
- Andrew J, Fowler CJ, Harrison MJG (1983). Stereo-taxic thalamotomy in 55 cases of dystonia. *Brain* **106**: 981–1000.
- Andy OJ (1983). Thalamic stimulation for control of movement disorders. *Appl Neurophysiol* **46**:107–123.
- Bara-Jimenez W, Catalan MJ, Hallett M, Gerloff C (1998). Abnormal somatosensory homunculus in dystonia of the hand. *Ann Neurol* **44**:828–831.
- Bara-Jimenez W, Shelton P, Sanger TD, Hallett M (2000). Sensory discrimination capabilities in patients with focal hand dystonia. *Ann Neurol* **47**:377–380.
- Baron MS, Vitek JL, Bakay RAE *et al.* (1996). Treatment of advanced Parkinson's disease by posterior GPi pallidotomy: 1-year results of a pilot study. *Ann Neurol* **40**:355–366.
- Baron MS, Vitek JL, Bakay RAE *et al.* (2000). Treatment of advanced Parkinson's disease by unilateral posterior GPi pallidotomy: 4-year results of a pilot study. *Mov Disord* **15**:230–237.
- Batshaw ML, Haslam RHA (1976). Multidisciplinary management of dystonia misdiagnosed as hysteria. In: Eldridge R, Fahn S, eds. *Advances in Neurology* Vol. 14. Raven Press, New York, 423–452.
- Benabid AL, Pollak P, Louveau A, Henry S, de Rougemont J (1987). Combined (thalamotomy and stimulation) stereotaxic surgery of the VIM thalamic nucleus for bilateral Parkinson's disease. *Appl Neurophysiol* **30**:344–346.
- Benabid AL, Pollak P, Gervason C *et al.* (1991). Long-term suppression of tremor by chronic stimulation of the ventral intermediate thalamic nucleus. *Lancet* **337**:403–406.
- Benabid AL, Pollak P, Gao D *et al.* (1996). Chronic electrical stimulation of the ventralis intermedialis nucleus of the thalamus as a treatment of movement disorders. *J Neurosurg* **84**:203–214.
- Bertrand CM (1958). A pneumotaxic method for producing localized cerebral lesions and its use in the treatment of Parkinson's disease. *J Neurosurgery* **15**:251–263.
- Bertrand C, Molina NP, Martinez SN (1978). Combined stereotaxic and peripheral surgical approach for spasmodic torticollis. *Appl Neurophysiol* **41**:122–133.
- Bertrand C, Molina Negro P, Martinez SN (1979). Stereotaxic targets for dystonias and dyskinesias: relationship to corticobulbar fibers and other adjoining structures. In:



- Poirier LJ, Sourkes TL, Bédard PJ, eds. *Advances in Neurology* Vol. 24. Raven Press, New York, 395–399.
- Bhatia KP, Marsden CD, Thomas DG (1998). Posteroventral pallidotomy can ameliorate attacks of paroxysmal dystonia induced by exercise [letter]. *J Neurol Neurosurg Psychiatry* **65**:604–605.
- Bötzel K, Bereznai B, Steude U, Jäger M, Gasser T (2000). Chronic high-frequency stimulation of globus pallidus internus in different types of dystonia: a clinical, video and MRI report of 3 patients. *Mov Disord* **15**:168.
- Burke RE, Fahn S, Marsden CD, Bressman SB, Moskowitz C, Friedman J (1985). Validity and reliability of a rating scale for the primary torsion dystonias. *Neurology* **35**:73–77.
- Burzaco J (1985). Stereotactic pallidotomy in extrapyramidal disorders. *Appl Neurophysiol* **48**:283–287.
- Cardoso F, Jankovic J, Grossman R, Hamilton W (1995). Outcome after stereotactic thalamotomy for dystonia and hemiballismus. *Neurosurgery* **38**:501–508.
- Cervera A, Vallderiola F, Marti MJ, Molinuevo JL, Pilleri M, Tolosa E (2000). Worsening of dystonia after pallidal surgery. *Mov Disord* **15**:167.
- Cooper IS (1969). Dystonia musculorum deformans: natural history and neurosurgical alleviation. *J Pediatr* **74**:585–592.
- Cooper IS (1976). 20 year follow-up study on the neurosurgical treatment of dystonia musculorum deformans. In: Eldridge R, Fahn S, eds. *Advances in Neurology* Vol. 14. Raven Press, New York. 423–452.
- Cooper IS, Poloukhine N (1955). Chemopallidectomy, a new neurosurgical technique useful in geriatric parkinsonians. *J Am Geriatr Soc* **3**:839–895.
- Coubes P, Echenne B, Roubertie A *et al.* (1999). Traitement de la dystonie généralisée à début précoce par stimulation chronique bilatérale des globus pallidus internes. A propos d'un cas. *Neurochirurgie* **45**:139–144.
- Coubes P, Roubertie A, Echenne B *et al.* (2000a). Early-onset generalized dystonia; neurosurgical treatment by continuous bilateral stimulation of the internal globus pallidus in 15 patients. *Neurology* **54**:A220.
- Coubes P, Roubertie A, Vayssiere N *et al.* (2000b). Early-onset generalized dystonia; neurosurgical treatment by continuous bilateral stimulation of the internal globus pallidus in sixteen patients. *Mov Disord* **15**:154.
- Coubes P, Roubertie A, Vayssiere N, Hemm S, Echenne B (2000c). Treatment of DYT1-generalized dystonia by stimulation of the internal globus pallidus. *Lancet* **355**:2220–2221.
- Cubo E, Shannon KM, Penn RD, Kvoins J (1999). Pallidotomy in dystonia secondary to Huntington's disease. *Park Rel Disord* **5**:S100.
- Cubo E, Shannon KM, Penn RD, Kroin JS (2000). Internal globus pallidotomy in dystonia secondary Huntington's disease. *Mov Disord* **15**:1248–1251.
- De Bie RMA, de Haan RJ, Nijssen PCG *et al.* (1999). Unilateral pallidotomy in Parkinson's disease: a randomised, single-blind, multicentre trial. *The Lancet* **354**:1665–1669.
- De la Fuente-Fernandez R (1998). Tardive dyskinesia in dopa-responsive dystonia. a reappraisal of the dopamine hypothesis of tardive dyskinesia. *Neurology* **50**:1134–1135.
- Dubois B, Defontaine B, Deweer B *et al.* (1995). Cognitive and behavioral changes in patients with focal lesions of the basal ganglia. In: Weiner WJ, Lang AE, eds. *Behavioral Neurology of Movement Disorders*. Raven Press, New York. 29–41.
- Fahn S (1988). Concept and classification of dystonia. *Adv Neurol* **50**:1–8.
- Fahn S, Bressman SB, Marsden CD (1998). Classification of dystonia. *Adv Neurol* **78**:1–10.
- Fazzini E, Dogali M, Sterio D, Eidelberg D, Beric A (1997). Stereotactic pallidotomy for Parkinson's disease: a long-term follow-up of unilateral pallidotomy. *Neurology* **48**:1273–1277.
- Fénelon F (1950). Essais de traitement neurochirurgical du syndrome parkinsonien par intervention directe sur les voies extrapyramidales immédiatement sous-striatopallidales (anse lenticulaire). Communication suivie de projection du film d un des opérés pris avant et après l'intervention. *Rev Neurol* **83**:437–440.
- Fine J, Duff J, Chen R, Hutchison W, Lozano AM, Lang AE (2000). Long-term follow-up of unilateral pallidotomy in advanced Parkinson's disease. *New Engl J Med* **342**:1708–1714.
- Fogel W, Krause M, Tronnier V (2000) Globus pallidus deux stimulation in generalized dystonia: clinical data (abstract). *Mov Disord* **15**(Suppl. 3):144.
- Funk T, Vesper J, Klostermann F, Straschill M, Brock M (2000). Deep brain stimulation of the globus pallidus internus. *Mov Disord* **15**:42.
- Ghika J, Ghika-Schmid F, Fankhauser H *et al.* (1999). Bilateral contemporaneous posteroventral pallidotomy for the treatment of Parkinson's disease: neuropsychological and neurological side effects. report of four cases and review of the literature. *J Neurosurgery* **91**:313–321.
- Ghika J, Vingerhoets F, Temperli P, Pollo C, Villemure J-G (2000). Ventrooralis nucleus thalamic deep brain stimulation (DBS) but not pallidal DBS is effective in generalized postanoxic dystonia with necrosis of bilateral pallida. *Neurology* **54**; *Suppl* **3**:A220.
- Gill S, Curran AL, Tripp J, Malerikos LO, Sullivan K, Stanley O (2000). Severe hyperkinetic movement disorder in a child treated with deep brain stimulation: a case report. *Arch Dis Child* **82**; *Suppl* **1**:A56.
- Giller CA, Dewey RB, Ginsburg MI, Mendelsohn DB, Berk AM (1998). Stereotactic pallidotomy and thalamotomy using individual variations of anatomic landmarks for localization. *Neurosurgery* **42**:56–62.
- Gros C, Frerebeau P, Perez DE, Bazin M, Privat JM (1976). Long term results of stereotaxic surgery for infantile dystonia and dyskinesia. *Neurochirurgie* **19**:171–178.
- Guiot G (1958). Le traitement des syndromes parkinsoniens par la destruction du pallidum interne. *Neurochirurgia* **1**:94–98.
- Guiot G, Brion S (1952). Traitement neurochirurgical des syndromes choréo-athétosique et parkinsonien. *Sém Hop Paris* **28**:2095–2099.
- Hallett M (1995). Is dystonia a sensory disorder? *Ann Neurol* **38**:139–140.
- Hallett M (1998). Physiology of dystonia. *Adv Neurol* **78**:11–18.
- Hallett M, Litvan I and the Task Force on Surgery for Parkinson's Disease. (1999). Evaluation of surgery for Parkinson's disease. *Neurology* **53**:1910–1921.
- Hariz MI (1997). Controversies in pallidal surgery. *Acta Neurochir Suppl (Wien)* **68**:1–10.
- Hariz MI (2000a). Complications of movement disorder surgery and how to avoid them. In: Lozano A, eds. *Progress in Neurological Surgery* Vol. 15, Karger, Basel, 246–265.

- Hariz MI (2000b). Ten years follow-up of posteroventral pallidotomy for Parkinson's disease. *Mov Disord* **15**:67.
- Hariz MI, DeSalles AA (1997). The side-effects and complications of posteroventral pallidotomy. *Acta Neurochir Suppl (Wien)* **68**:42–48.
- Hartmann von Monakow K (1959). Halluzinosen nach doppelseitiger stereotaktischer Operation bei Parkinson-Kranken. *Arch Psychiatrie* **199**:477–486.
- Hassler R, Riechert T (1954). Indikationen und Lokalisationsmethode der gezielten Hirnoperationen. *Nervenarzt* **25**:441–447.
- Hassler R, Dieckmann G (1970). Die stereotaktische Behandlung des Torticollis aufgrund tierexperimenteller Erfahrungen ueber die richtungsbestimmenden Bewegungen. *Nervenarzt* **41**:473–487.
- Hassler R, Riechert T, Mundinger F, Umbach W, Ganglberger JA (1960). Physiological observations in stereotaxic operations in extrapyramidal motor disturbances. *Brain* **83**:337–356.
- Hillier CE, Wiles CM, Simpson BA (1999). Thalamotomy for severe antipsychotic induced tardive dyskinesia and dystonia [letter]. *J Neurol Neurosurg Psychiatry* **66**:250–251.
- Iacono RP, Lonser RR, Kuniyoshi S (1995). Unilateral versus bilateral simultaneous posteroventral pallidotomy in subgroups of patients with Parkinson's disease. *Stereotact Funct Neurosurg* **65**:6–9.
- Iacono RP, Kuniyoshi SM, Lonser RR, Maeda G, Inae AM, Ashwal S (1996). Simultaneous bilateral pallidotomy for idiopathic dystonia musculorum deformans. *Pediatr Neurol* **14**:145–148.
- Islekel S, Zileli M, Cakmur R, Zileli B (2000). Pallidal stimulation: an effective method in the treatment of spasmodic torticollis. *Mov Disord* **15**:162.
- Jankovic J, Lai EC, Krauss J, Grossman R (1999). Surgical treatment of levodopa-induced dyskinesias. In: Stern GM, ed. *Parkinson's Disease: Advances in Neurology* Vol. 80, Lippincott-Raven, Philadelphia. 603–609.
- Junn F, LeWitt PA, Trosch RM, Jenrow K (1998). Role of pallidotomy in corticobasal ganglionic degeneration. *Mov Disord* **13**:261.
- Junqué C, Alegret M, Nobbe FA *et al.* (1999). Cognitive and behavioral changes after unilateral posteroventral pallidotomy: relationship with lesional data from MRI. *Mov Disord* **14**:780–789.
- Justesen CR, Penn RD, Kroin JS, Egel RT (1999). Stereotactic pallidotomy in a child with Hallervorden-Spatz disease. Case report. *J Neurosurg* **90**:551–554.
- Khan F, Alkhani A, Hutchison W, Dostrovsky J, Giladi N, Lang AE, Lozano AM (2000). The response to pallidal surgery for dystonia is dependent on the etiology. Teaching course on Functional Stereotaxy for Movement Disorders. Meeting of the Movement Disorder Society, Barcelona.
- Kondziolka D, Bonaroti E, Baser S, Brandt F, Kim YS, Lunsford LD (1999). Outcomes after stereotactically guided pallidotomy for advanced Parkinson's disease. *J Neurosurg* **90**:197–202.
- Krack P, Pollak P, Limousin P, Benazzouz A, Deuschl G, Benabid AL (1999). From off-period dystonia to peak-dose chorea: the clinical spectrum of varying subthalamic nucleus activity. *Brain* **122**:1133–1146.
- Krauss JK, Pohle T, Weber S, Ozdoba C, Burgunder JM (1999). Bilateral stimulation of globus pallidus internus for treatment of cervical dystonia. *Lancet* **354**:837–838.
- Krayenbühl H, Siegfried J (1972). Dentatomies or thalamotomies in the treatment of hyperkinesia. *Confin Neurol* **34**:29–33.
- Kulisevsky J, Lleo A, Gironell A, Molet J, Pascual-Sedano B, Pares P (2000). Bilateral pallidal stimulation for cervical dystonia: dissociated pain and motor improvement. *Neurology* **55**:1754–1755.
- Kumar R, Dagher A, Hutchison WD, Lang AE, Lozano AM (1999). Globus pallidus deep brain stimulation for generalized dystonia. *Clin PET Investigation Neurology* **53**:871–874.
- Laitinen LV (1995). Pallidotomy for Parkinson's disease. *Neurosurg Clin North Am* **6**:105–112.
- Laitinen LV (1998). Optimal target of pallidotomy. a controversy. In: Krauss JK, Grossman RG, Jankovic J, eds. *Pallidal Surgery for the Treatment of Parkinson's Disease and Movement Disorders*. Lippincott-Raven, Philadelphia. 285–289.
- Laitinen LV (2000). Behavioral complications of early pallidotomy. *Brain Cogn* **42**:313–323.
- Laitinen LV, Bergenheim AT, Hariz MI (1992). Leksell's posteroventral pallidotomy in the treatment of Parkinson's disease. *J Neurosurg* **76**:53–61.
- Lang AE, Lozano AM, Montgomery EB, Duff J, Tasker RR, Hutchison WD (1997). Posteroventral medial pallidotomy in advanced Parkinson's disease. *N Engl J Med* **337**:1036–1042.
- Lenz FA, Suarez JL, Metman LV *et al.* (1998). Pallidal activity during dystonia: somatosensory reorganization and changes with severity. *J Neurol Neurosurg Psychiatry* **65**:767–770.
- Lenz FA, Jaeger CJ, Seike MS *et al.* (1999). Thalamic single neuron activity in patients with dystonia: dystonia-related activity and somatic sensory reorganization. *J Neurophysiol* **82**:2372–2392.
- Lim JY, DeSalles AAF, Bronstein J, Mastermann D, Saver JL (1997). Delayed internal capsule infarctions following radiofrequency pallidotomy. *J Neurosurg* **87**:955–960.
- Limousin P, Pollak P, Benazzouz A *et al.* (1995). Effect on parkinsonian signs and symptoms of bilateral subthalamic nucleus stimulation. *Lancet* **345**:91–95.
- Limousin P, Krack P, Pollak P *et al.* (1998). Electrical stimulation of the subthalamic nucleus in advanced Parkinson's disease. *N Engl J Med* **339**:1105–1111.
- Limousin P, Speelman JD, Gielen F, Janssens M and the study collaborators (1999). Multicenter European study of thalamic stimulation in parkinsonian and essential tremor. *J Neurol Neurosurg Psychiatr* **66**:289–296.
- Lin JJ, Lin SZ, Lin GY, Chang DC, Lee CC (1998). Application of bilateral sequential pallidotomy to treat a patient with generalized dystonia. *Eur Neurol* **40**:108–110.
- Lin JJ, Lin GY, Shih C, Lin SZ, Chang DC, Lee CC (1999a). Benefit of bilateral pallidotomy in the treatment of generalized dystonia. *J Neurosurg* **90**:974–976.
- Lin JJ, Lin SZ, Chang D (1999b). Pallidotomy and generalized dystonia. *Mov Disord* **14**:1057–1059.
- Liu X, Griffin I, Miall C, Parkin S, Aziz T, Stein J (2000). Coherence of pallidal field potential with surface EMG in familial myoclonic dystonia. *Mov Disord* **15**:81.
- Loher TJ, Hasdemir MG, Burgunder J-M, Krauss JK (2000). Long-term follow-up study of chronic globus pallidus internus stimulation for posttraumatic hemidystonia. Case report. *J Neurosurg* **92**:457–460.
- Lombardi WJ, Gross RE, Trépanier LL, Lang AE, Lozano AM, Saint-Cyr JA (2000). Relationship of lesion location to cognitive outcome following microelectrode-guided pallidotomy

- for Parkinson's disease: support for the existence of cognitive circuits in the human pallidum. *Brain* **123**:746–775.
- Lozano AM, Lang AE, Galvez-Jimenez N *et al.* (1995). Effect of GPi pallidotomy on motor function in Parkinson's disease. *Lancet* **346**:1383–1387.
- Lozano AM, Kumar R, Gross RE *et al.* (1997). Globus pallidus internus pallidotomy for generalized dystonia. *Mov Disord* **12**:865–870.
- Masterman D, DeSalles A, Baloh R *et al.* (1998). Motor, cognitive, and behavioral performance following unilateral ventroposterior pallidotomy for Parkinson disease. *Arch Neurol* **55**:1201–1208.
- Meyers HR (1940). Surgical procedures for postencephalitic tremor with notes on the physiology of premotor fibers. *Arch Neurol Psychiatry* **44**:453–459.
- Meyers R (1942a). The modification of alternating tremors, rigidity and festination by surgery of the basal ganglia. *Proc Assoc Res Nerv Ment Dis* **21**:602–665.
- Meyers R (1942b). Surgical interruption of the pallidofugal fibers, its effect on the syndrome of paralysis agitans and technical consideration in its application. *NY State J Med* **42**:317–325.
- Meyers R (1958). Historical background and personal experiences in surgical relief of hyperkinesia and hypertonus. In: Fields WS, ed. *Pathogenesis and Treatment of Parkinsonism*. CC Thomas, Springfield, IL. 229–270.
- Munding F (1977). Neue stereotaktisch-funktionelle Behandlungsmethode des Torticollis spasmodicus mit Hirnstimulatoren. *Med Klinik* **72**:1982–1986.
- Munding F, Riechert T, Disselhoff J (1970). Long term results of stereotactic operations on extrapyramidal hyperkinesia (excluding parkinsonism). *Confinia Neurologica* **32**:71–78.
- Munding F, Riechert T, Disselhoff J (1972). Long-term results of stereotactic treatment of spasmodic torticollis. *Confin Neurol* **34**:41–46.
- Narabayashi H, Okuma T (1953). Procaine oil blocking of the globus pallidus for the treatment of rigidity and tremor of parkinsonism. *Proc Jpn Acad* **29**:134–137.
- Nomura Y, Ikeuchi T, Tsuji S, Segawa M (2000). Two phenotypes and anticipation observed in Japanese cases with early onset torsion dystonia (DYT1)-pathophysiological consideration. *Brain Dev* **22**:S92–S101.
- Ohye C (1998). Thalamotomy for Parkinson's disease and other types of tremor. Part I. Historical background and technique. In: Gildenberg PL, Tasker RR, eds. *Textbook of Stereotactic and Functional Neurosurgery*. McGraw-Hill, New York. 1167–1178.
- Ondo WG, Desaloms JM, Jankovic J, Grossman RG (1998). Pallidotomy for generalized dystonia. *Mov Disord* **13**:693–698.
- Orthner H, Roeder F (1959). *Das Parkinson-Syndrom und seine Behandlung durch Elektrokoagulation des Globus Pallidus*. Stuttgart: Gustav Fischer Verlag.
- Orthner H, Roeder F, Leitzke G (1962). Erfahrungen mit stereotaktischen Eingriffen. IV. Mitteilung: Über den Dauereffekt der doppelseitigen Pallidotomie beim Parkinsonsyndrom. *Acta Neurochir (Wien)* **10**:572–629.
- Paul G, Trottenberg Th, Maier-Hauff K *et al.* (2000). Quadruple neurostimulation for treatment of axial dystonia. *Mov Disord* **15**:158.
- Parkin S, Aziz T, Gregory R, Bain P (2001). Bilateral internal globus pallidus stimulation for the treatment of spasmodic torticollis. *Mov Disord* (in press).
- Perrine K, Dogali M, Fazzini E *et al.* (1998). Cognitive functioning after pallidotomy for refractory Parkinson's disease. *J Neurol Neurosurg Psychiatry* **65**:150–154.
- Pollak P (1999). Neurosurgical treatment of dyskinesia. pathophysiological considerations. *Mov Disord* **14**:33–39.
- Pollak P, Benabid AL, Gross C *et al.* (1993). Effet de la stimulation du noyau sous-thalamique dans la maladie de Parkinson. *Rev Neurol (Paris)* **149**:175–176.
- Pollak P, Benabid AL, Krack P *et al.* (1998). Deep brain stimulation. In: Jankovic J, Tolosa E, eds. *Parkinson's Disease and Movement Disorders*. Williams & Wilkins, Baltimore. 1085–1101.
- Samii A, Turnbull IM, Kishore A *et al.* (1999). Reassessment of unilateral pallidotomy in Parkinson's disease. A 2-year follow-up study. *Brain* **122**:417–425.
- Samuel M, Caputo E, Brooks DJ *et al.* (1998). A study of medial pallidotomy for Parkinson's disease: clinical outcome, MRI location and complications. *Brain* **121**:59–75.
- Schuurman PR, DeBie RMA, Speelman JD, Bosch DA (1997). Bilateral posteroventral pallidotomy in advanced Parkinson's disease in three patients. *Mov Disord* **12**:752–755.
- Schuurman PR, Bosch DA, Bossuyt PMM *et al.* (2000). A comparison of continuous thalamic stimulation and thalamotomy for suppression of severe tremor. *N Engl J Med* **342**:461–468.
- Scott R, Gregory R, Hines N *et al.* (1998). Neuropsychological, neurological and functional outcome following pallidotomy for Parkinson's disease. *Brain* **121**:659–675.
- Sellal F, Hirsch E, Barth P, Blond S, Marescaux C (1993). A case of symptomatic hemidystonia improved by ventrolateral thalamic stimulation. *Mov Disord* **8**:515–518.
- Shima F, Ishido K, Kato M (1997). Roles of the basal ganglia outputs in movement disorders: a viewpoint based on experiences of stereotactic surgery for idiopathic dystonia. *Brain Dev* **29**:206–212.
- Siegfried J (1986). Effets de la stimulation du noyau sensitif du thalamus sur les dyskinésies et la spasticité. *Rev Neurol (Paris)* **142**:380–383.
- Siegfried J, Lippitz B (1994). Bilateral chronic electrostimulation of ventroposterolateral pallidum: a new therapeutic approach for alleviating all parkinsonian symptoms. *Neurosurgery* **35**:1126–1130.
- Soukup VM, Ingram F, Schiess MC, Bonnen JG, Nauta HJ, Calverley JR (1997). Cognitive sequelae of unilateral posteroventral pallidotomy. *Arch Neurol* **54**:947–950.
- Speelman J, Van Manen J (1989). Cerebral palsy and stereotactic neurosurgery: long term results. *J Neurol Neurosurg Psychiatr* **52**:23–30.
- Spiegel EA, Wycis HT, Marks M, Lee AJ (1947). Stereotaxic apparatus for operations on the human brain. *Science* **106**:349–350.
- Spiegel EA, Wycis HT, Baird HW (1958). Long-range effects of electropallidotomy in extrapyramidal and convulsive disorders. *Neurology* **8**:734–740.
- Svensnilson E, Torvik A, Lowe R, Leksell L (1960). Treatment of Parkinsonism by stereotactic thermolesions in the pallidal region. A clinical evaluation of 81 cases. *Acta Psychiatr Neurol Scand* **35**:358–377.
- Tasker RR (1998a). Ablative procedures for dystonia. In: Germano IM, ed. *Neurosurgical Treatment of Movement Disorders*. The American Association of Neurological Surgeons, Park Ridge. 255–266.

- Tasker RR (1998b). Surgical treatment of the dystonias. In: Gildenberg PL, Tasker RR, eds. *Textbook of Stereotactic and Functional Neurosurgery*. McGraw-Hill, New York. 1015–1032.
- Tasker RR, Doorly T, Yamashiro K (1988). Thalamotomy in generalized dystonia. *Adv Neurol* **50**:615–631.
- Trépanier LL, Saint-Cyr JA, Lozano A, Lang AE (1998). Neuropsychological consequences of posteroventral pallidotomy for the treatment of Parkinson's disease. *Neurology* **51**:207–215.
- Tronnier V, Fogel W (2000). Pallidal stimulation for generalized dystonia. *J Neurosurg* **92**:453–456.
- Vercueil L, Pollak P, Fraix V, Caputo E, Moro E, Benazzouz A *et al.* (2001). Deep brain stimulation in the treatment of severe dystonia. *J Neurol* **248**:(in press).
- Vitek JL, Zhang J, Evatt M *et al.* (1998). GPi pallidotomy for dystonia: clinical outcome and neuronal activity. *Adv Neurol* **78**:211–219.
- Vitek JL, Chockkan V, Zhang J-Y *et al.* (1999). Neuronal activity in the basal ganglia in patients with generalized dystonia and hemiballismus. *Ann Neurol* **46**:22–35.
- Weetman J, Anderson IM, Gregory RP, Gill SS (1997). Bilateral posteroventral pallidotomy for severe antipsychotic induced tardive dyskinesia and dystonia. *J Neurol Neurosurg Psychiatry* **63**:554–556.
- Zihr TA, Reich SG, Perry V, Lenz FA (1998). Thalamic single neuron and electromyographic activities in patients with dystonia. *Adv Neurol* **78**:27–32.

### List of abbreviations

CT	computed tomography
DBS	deep brain stimulation
GPi	globus pallidus internus
MRI	magnetic resonance imaging
PD	Parkinson's disease
PVP	posteroventral pallidotomy
STN	subthalamic nucleus
BFS	Burke and Fahn scale for dystonia
Vim	nucleus ventrointermedius of the thalamus
Voa	nucleus ventrooralis anterior of the thalamus
Vop	nucleus ventrooralis posterior of the thalamus.