

Rhegmatogenous Retinal Detachment: A Reappraisal of Its Pathophysiology and Treatment

Ferenc Kuhn^{a, b} Bill Aylward^c

^aHelen Keller Foundation for Research and Education, Birmingham, Ala., USA; ^bMilos Eye Hospital, Belgrade, Serbia;

^cMoorfields Eye Hospital, London, UK

Key Words

Retinal detachment · Vitrectomy · Scleral buckling · Pathophysiology · Treatment · Vitreoschisis · Vitreoretinal interface · Posterior vitreous detachment · Tamponade

Abstract

This article represents a synthesis of an extensive literature review and the authors' decades-long personal experience with both scleral buckling (SB) and vitrectomy for rhegmatogenous retinal detachment (RD). Presenting a coherent understanding of the pathophysiology and treatment of RD, the authors confirm numerous findings described in earlier publications but also challenge certain long-standing dogmas. The key argument made here is that it is extremely rare for the chain of events leading to an RD to start with a *retinal* pathology. Rather, the initial pathology is syneresis of the *vitreous*, which then allows gel movement (intraocular currents). At the point of vitreoretinal adhesion, dynamic traction is exerted on the retina, which may be sufficient to tear it. If the tear is operculated and the dynamic traction overcomes the forces keeping the neuroretina and retinal pigment epithelium (RPE) together, the heretofore virtual subretinal space becomes accessible through the retinal tear. The intraocular cur-

rents allow the free (nonbound) intravitreal fluid to enter the subretinal space, and once the amount of the incoming fluid overwhelms the draining capacity of the RPE, an RD ensues. Detachment of the posterior cortical vitreous (PVD) is not a necessary prerequisite to RD development; furthermore, PVD cannot be diagnosed preoperatively with adequate certainty with current technology such as biomicroscopy, ultrasonography or optical coherence tomography. The surgeon should expect no or only partial (anomalous) PVD at the time of surgical repair in over half of eyes. The treatment's primary goal must thus be weakening (pneumatic retinopexy, SB) or eliminating (vitrectomy) this dynamic traction. If vitrectomy is employed, it must be a truly complete vitreous removal. This includes a surgically induced PVD if one is not present, close shaving at the periphery, and removing the vitreous immediately behind the lens. The vitrectomy is followed by the creation of a chorioretinal scar around the tear and aided by some form of intraocular tamponade. The main function of the tamponade is not to temporarily cover the break but to significantly reduce the intraocular currents and thus prevent fluid entry through the break until the chorioretinal adhesion will have become sufficiently strong to seal the retinal edge around the tear; postoperative positioning is therefore not as important as currently assumed.

© 2013 S. Karger AG, Basel

Introduction

In this review the authors present a reevaluation of the pathophysiology and treatment of the rhegmatogenous type of retinal detachment (RD; fig. 1; see table 1 for all terms used in this article). The review also reflects the authors' personal observations, based on their experience spanning several decades.

The Normal Vitreoretinal Architecture: What Keeps the Retina Attached?

Attachment of the retina is mandatory for its proper functioning. To understand the pathogenesis of RD, and thus optimize its treatment, one must first appreciate the factors that prevent the retina from detaching.

Retinal attachment is mainly due to two factors. The first is the retinal pigment epithelium (RPE) pumping fluid out of the (thus virtual) subretinal space toward the choriocapillaris [1]. Drugs that interfere with this active transport reduce retinal adhesiveness [2]. In eyes with high myopia, reduced pumping by the RPE is assumed to contribute to the development of central RD spanning the curvature of the staphyloma. The significance of the RPE pump is also shown by the fact that retinas detach post mortem [3]. The second crucial factor maintaining retinal attachment is the interphotoreceptor matrix (IPM) glue [4, 5]. Enzymes which, when given intravitreally or directly into the IPM, degrade the proteoglycans that are part of the IPM 'glue' result in marked loss of retinal adhesion in primate eyes [6, 7].

Once the IPM is broken, the reattached retina requires time to firmly readhere to the RPE. This is clearly shown during pars plana vitrectomy (PPV): even if the RD is freshly created during surgery, a retina intraoperatively reattached with an air bubble readily redetaches when the air is reexchanged for fluid. The delay in the retina being firmly (re)adherent is explained by the time the IPM needs to become effective again [8].

The significance of the RPE pump and the IPM is also shown by the occasional occurrence of an intraoperative RD developing at the periphery in diabetic eyes. The strong suction force (or flow) of the vitrectomy machine may cause a temporary RD, even in the absence of a retinal break, when the vitrectomy probe is in close proximity to the retina during 'shaving' at the vitreous base.

There are additional factors in keeping the retina attached, such as the presence of the vitreous gel [9] – RD occurs faster in vitrectomized eyes – or the intraocular

pressure, but these play a much smaller role. The role of the healthy (homogeneous) vitreous gel, however, and especially the architecture of the vitreoretinal interface, deserve further discussion.

The Normal Anatomy of the Vitreoretinal Interface and Its Clinical Implications

When the vitreous is completely healthy, it is 100% gel; there is no free fluid, even though some 98% of the vitreous body consists of water. The vitreous has three main components: water, hyaluronic acid and collagen fibers. The collagen fibers in most of the gel are not aligned, except at the border of the vitreous (cortical vitreous), where they are more condensed and run parallel to the surface [10].

The vitreous gel is in contact with the retina throughout the entire vitreous cavity (vitreoretinal interface). In certain areas there is also actual adhesion [11] between them [12–14]. There is individual variability in the strength of adhesion between retina and vitreous. The typical areas of physical adhesion include the disk margin, the major retinal vessels, closer to the periphery (firmer anterior to the equator than posterior to it) and, especially, at the vitreous base [13]. Here the collagen fibers of the vitreous (mostly types II and VI) become contiguous with those of the retina (mostly type IV) [15]. Furthermore, adhesion may form after inflammatory diseases (uveitis), proliferative diseases (diabetes; proliferative vitreoretinopathy, PVR) and trauma [16], and following excessive cryopexy or laser treatment.

Posterior to the vitreous base, the collagen fibers of the cortical vitreous are orientated parallel to the internal limiting membrane (ILM) [17]. Vitreoretinal separation is therefore impossible at the periphery but, at least in principle, possible elsewhere. Spontaneous separation of the cortical vitreous, typically starting from the posterior pole and advancing toward the periphery, is part of the normal aging process. The separation is not necessarily complete or uniform, and detachment of the (posterior) vitreous can be present in one area but absent adjacent to it [18]. It is a common error to equate the presence of a Weiss ring with the presence of a posterior vitreous detachment (PVD) [19]. Despite a Weiss ring that is clearly visible at the slit lamp, however, the vitreous may still be attached to the retina elsewhere.

There are two additional implications of all that has been described above for the vitreoretinal surgeon. First, surgical detachment of the posterior cortical vitreous, a maneuver employed in the vast majority of vitrectomies,

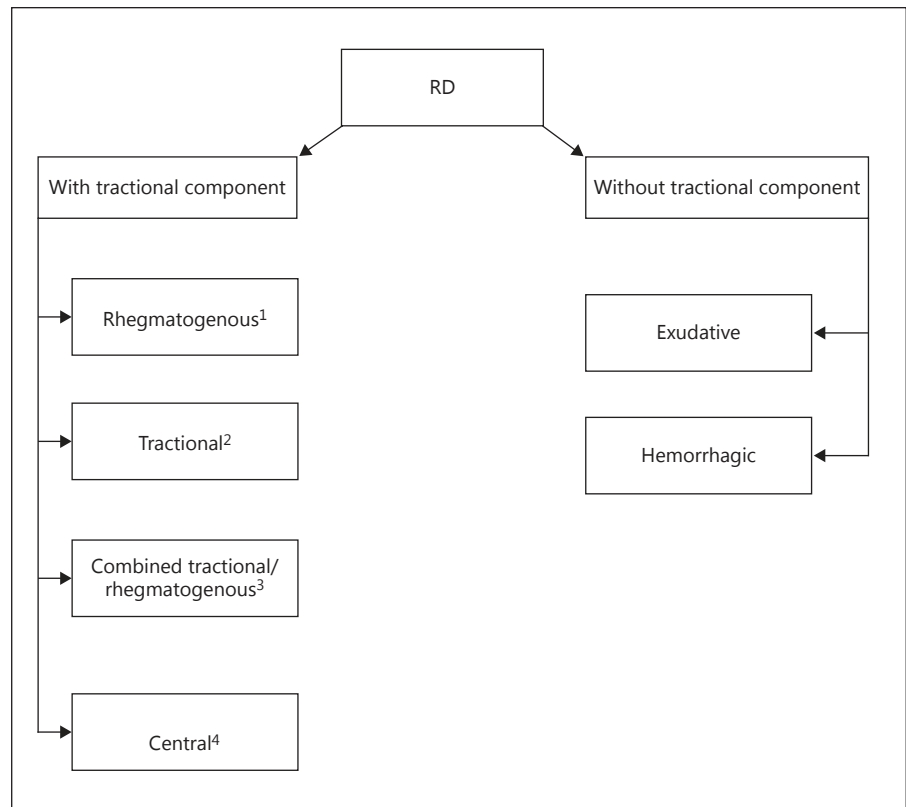


Fig. 1. Flowchart demonstrating the various types of RD. ¹ The tractional component precedes the rhegmatogenous one but does not dominate the clinical picture. ² There is no rhegmatogenous component. ³ The tractional component precedes the rhegmatogenous one and continues to dominate the clinical picture. ⁴ The tractional component is minimally visible on biomicroscopic examination in eyes with a macular hole; in highly myopic eyes with a staphyloma, the undetached posterior hyaloid and the rigid internal limiting membrane are probably both responsible.

cannot be carried too anteriorly. Where that point of ‘stop here’ is varies by the individual, but, generally, it is at the equator where the surgical PVD should be terminated, even if in many eyes the point of safety is in fact more anterior, and for certain pathologies, such as an RD, it would be ideal to carry the separation up to the vitreous base.

Second, at the vitreous base it is impossible to separate the two tissues. The blunt dissection (‘peeling’ of the cortical vitreous) is, by necessity, turned into ‘shaving’, a mechanical splitting, rather than peeling, of the vitreous fibers. The surgical goal is to leave a minimal amount of the vitreous on the retinal surface while removing all traction forces, but without the creation of (additional) retinal breaks.

The Pathoanatomy of the Vitreoretinal Architecture and Its Clinical Implications

With time (aging) and in many pathological conditions such as myopia or vitreous hemorrhage, or following surgery such as cataract extraction, the hyaluronic acid content of the gel decreases and some of the collagen fibers release the water they heretofore kept bound. By the

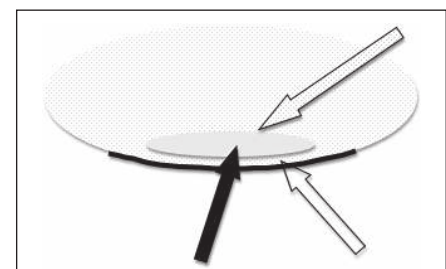


Fig. 2. Vitreoschisis. Schematic representation. The anterior wall (dotted arrow) of the vitreoschisis cavity (solid arrow) may appear as a PVD; in reality, the cortical vitreous (blank arrow) is still attached to the retina (solid black line). See the text for more details.

end of the 2nd decade of life, 20% of the total vitreous volume is liquid, and by the age of 90 years, more than half of the vitreous is liquid [20]. The result of liquefaction [18] is a syneretic vitreous body; it now contains two main elements, gel and fluid, with aggregates of the collagen fibers ‘swimming’ in the water content (floaters).

A uniquely important form of syneresis is called ‘vitreoschisis’ (fig. 2) [21], where a fluid pocket lies in front

Table 1. Terminology and definitions used in this article

Central RD	Separation of the neuroretina from the RPE at or around the macula; the peripheral retina is attached. The detachment may be minimal (perifoveal fluid cuff in eyes with a macular hole) or widespread (spanning the staphyloma in highly myopic eyes). In the latter case, the presence of the break (macular hole) is more likely to be secondary to the RD, not its cause (see the text for more details).
Combined RD	Separation of the neuroretina from the RPE with the tractional component developing first and remaining dominant even if secondary retinal breaks occur.
Configuration of the vitreoretinal interface (see also: PVD)	PVD can be: <i>none</i> : complete, contiguous and uniform apposition or attachment ('in contact with') of the vitreous to the retina; <i>focal</i> : a very small area of separation, which cannot be detected on clinical examination (see the text for more details); <i>localized</i> : a larger area of separation, which may not be detectable on preoperative examination but can be seen during vitrectomy with proper marking of the vitreous such as with TA (see the text for more details); <i>incomplete</i> : PVD present in a much larger area and far more anteriorly, close to the vitreous base or the retinal tear; this is the configuration traditionally shown to illustrate the pathophysiology of RD development (see the text for more details); <i>complete</i> : this occurs only after a truly thorough PPV; the vitreous has been removed posteriorly (PVD) + centrally (core) + at the vitreous base (peripheral), where it is shaved very close to the retinal surface + behind the lens.
Cortical vitreous	The 100- to 300- μ m-thick outermost part of the vitreous gel, whose collagen fibers are interwoven by those of the retina at the vitreous base but run parallel to the surface without such strong physical linkage elsewhere. The cortical vitreous is somewhat adherent to the posterior lens capsule (the strength diminishes with age). The adhesion to the retina posterior to the vitreous base is typically weak but stronger at certain locations (the margins of the optic disk and the fovea, along major retinal vessels, and in areas of various pathologies such as chorioretinitis, retinal degenerations or trauma).
Exudative RD	Separation of the neuroretina from the RPE caused by fluid production (secretion), rather than fluid entry from the vitreous cavity. Neither traction nor a retinal break need be present; if either is, it is secondary and not causative.
Failure in RD surgery	<i>Primary</i> : The retina is not reattached intraoperatively and remains detached if no secondary intervention is performed (the term does not cover cases with self-absorbing residual subretinal fluid). <i>Secondary</i> : The retina reattaches during surgery or shortly after (disappearance of the residual subretinal fluid) but then redetaches due to a rhegmatogenous component (reopening of the original break or the development of new ones). The underlying cause is virtually always vitreous traction that has not been dealt with primarily or strengthens subsequently; failure to remove the outer wall of a vitreoschisis cavity is one potential source of such traction development. <i>Tertiary</i> : The retina redetaches after a few weeks, due to PVR.
Flashes	'The seeing of light' (phosphene) as a result of focal vitreoretinal traction. Flashes may or may not be associated with PVD; it is incorrect to equate the complaint of flashes with a PVD in progress. If no break is present initially, the risk of a break appearing at a later date decreases rather rapidly.
Floater	As a result of syneresis, collagen fibers 'swim' in the fluid pockets within the vitreous cavity. A floater only rarely represents a piece of retina (operculum). The presence of floaters obviously implies that syneresis has already occurred (a risk, however small, for RD development), and if the floaters are associated with flashes, traction is also present (increased RD risk).
Hemorrhagic RD	Separation of the neuroretina from the RPE caused by blood accumulation in the subretinal space. Neither traction nor a retinal break need be present; if either is, it is secondary.
Intraocular currents	The joint presence of gel and free fluid in the vitreous cavity (syneresis) allows gel movement if the eyeball or head moves (acceleration and deceleration). The movement of the fluid leads to sheer stress on the retina and can lead to the lifting of the unsecured retinal edge by the adherent gel (vitreoretinal traction), thus letting the unbound intravitreal fluid enter the subretinal space.
Posterior hyaloid face	The collagen-rich outermost portion of the vitreous, immediately adjacent to the retinal surface (synonymous with cortical vitreous or posterior cortical vitreous); it terminates at the vitreous base (see also: PVD).
Posterior pole	The part of retina bordered by the optic disk (included) and the temporal vascular arcade.

Table 1 (continued)

PPV for RD	Vitreous removal is used to facilitate reapposition of the neuroretina to the RPE by eliminating all the traction forces.
PVD	The posterior vitreous face is understood to terminate at the vitreous base; in this context, ‘posterior’ is not confined to the area posterior to the posterior pole or the equator; rather, it describes the outermost layer (cortex) of the vitreous body. A complete PVD occurs when the cortical vitreous is uniformly separated from the retina; in clinical practice, such complete vitreoretinal separation is rare. More typically, an anomalous PVD occurs: the separation is partial, allowing dynamic traction to be present.
Rhegmatogenous RD	Separation of the neuroretina from the RPE in the presence of a retinal break and consequent accumulation of subretinal fluid, which originates in the vitreous. A central RD surrounding a macular hole or spanning the staphyloma in a highly myopic eye does not belong to this category (see above).
SB for RD	Some type of material is used to permanently (e.g. silicone sponge) or temporarily (e.g. Lincoff balloon) intend the eye wall to reappose the neuroretina to the RPE.
Syneresis	Partial liquefaction of the vitreous gel so that both gel and fluid are present in the vitreous cavity (‘vitreo-fluidic admixture’), with aggregates of collagen fibers floating in the fluid pockets. Traction potential exists because the gel that lost its homogenous structure becomes mobile (intraocular currents). Liquefaction is thus a prerequisite to traction development. Syneresis can be the result of aging, myopia, cataract, hemorrhage (trauma), etc.
Traction	A permanent (static) or intermittent (dynamic) force in the vitreous cavity with a main vector acting so as to separate the neuroretina from the RPE (classification and further definitions are shown in table 3). Subretinal strands exert static traction by pushing up the retina as they contract.
Tractional RD	Separation of the neuroretina from the RPE with accumulation of subretinal fluid without the presence of a retinal break; the cause is a force (vector) that is pulling the retina away from the RPE. The static force prevents the detached retina from being mobile.
Weiss ring	The visible condensation of collagen fibers that used to form the attachment of the vitreous to the rim of the optic disk.
Vitreoretinal architecture	The configuration of the vitreous body (mostly its outermost portion) and its relation to the retina.
Vitreoretinal interface	The surface area where the two tissues have physical contact.
Vitreoschisis	A uniquely important form of syneretic change. This fluid-filled cavity is surrounded by gel vitreous on all sides and is located adjacent to the posterior retina. Its outer wall is rarely detectable on preoperative biomicroscopic examination, but in certain cases may be visible on OCT. Its inner wall is much easier to visualize at the slit lamp and is commonly misdiagnosed as a PVD (fig. 3). Vitreoschisis allows traction forces (dynamic) to be present or develop.
Vitreous base	The anterior vitreous skirt, 4–6 mm in width, where its densely packed collagen fibers intersect with those of the retina, representing an area where the two tissues are impossible to truly separate (during vitrectomy, shaving is the only surgical option); used synonymously as ‘the periphery’.

RPE = Retinal pigment epithelium; PVD = posterior vitreous detachment; TA = triamcinolone acetonide; PPV = pars plana vitrectomy; PVR = proliferative vitreoretinopathy; SB = scleral buckling; OCT = optical coherence tomography.

of the macula, surrounded by a static outer wall (cortical vitreous still adherent to the retinal surface) and a mobile inner wall (a gel constituting an interface). The first significance of a posterior vitreoschisis is diagnostic: it is very common to interpret this inner wall of the vitreoschisis cavity as a PVD. The second significance is associated with treatment: a failure to look for, and therefore to

remove, the remaining cortical vitreous (outer wall of the vitreoschisis cavity) from the posterior retina (see later in this review).

The assumed prevalence of a spontaneous PVD is thus much higher than its true prevalence. One ultrasonographic study [22], for instance, found a 46% rate of ‘complete PVD’ in the 80- to 89-year-old age group; in reality,

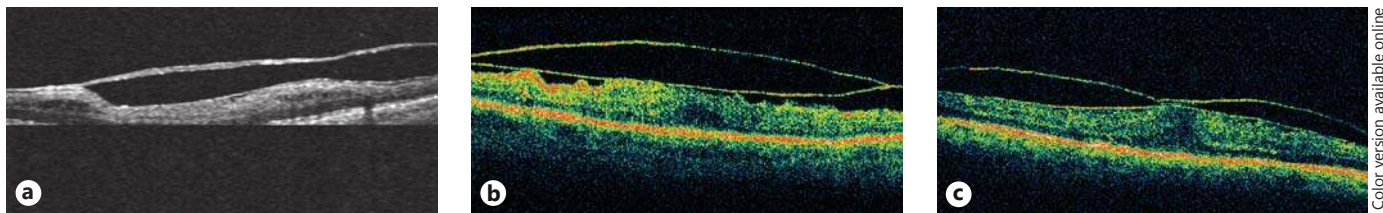


Fig. 3. Vitreoschisis as seen on OCT. Vitreoschisis whose anterior (inner) wall is clearly mimicking PVD; the thin outer wall is almost never recognized preoperatively. The posterior cortical vitreous is split ('lambda sign' [63]): one layer remains attached to the retinal surface, the other is seen as a (mobile) surface; it is very often confused with PVD. **a** The outer wall is invisible in some areas even if it is clearly present elsewhere (courtesy of J. Sebag) [63]. **b** Both

walls of the schisis cavity are obvious to see; the outer wall causes mild traction and makes the retinal surface uneven (courtesy of J. Pollack). **c** As is usually the case, the inner wall of the vitreoschisis cavity is much easier to detect; the outer wall causes significant traction in the one area where it is strongly adherent to the retina (courtesy of V. Mester).

ultrasonography until this day cannot detect the thin outer wall of a vitreoschisis cavity. With the rapid improvement in the resolution of optical coherence tomography (OCT) technology even the outer wall will become visible, but currently only those are easily detected that are more robust (fig. 3).

Vitreoretinal surgeons have only rather recently realized [19] that, despite the biomicroscopic findings reported previously [23], what appears to be a PVD is not necessarily that. While, using careful biomicroscopic techniques, a PVD prevalence of 72% in the 7th and a 100% rate in the 8th decade has been described in highly myopic eyes [24], the vitreoretinal surgeon almost never finds true PVD in these eyes. Instead, there is a posterior vitreoschisis, and the still attached posterior vitreous is reasonably assumed to play an important role in the development of the central RD often seen in eyes with a posterior staphyloma (fig. 4).

It was common in the older literature to describe a partial PVD in eyes with proliferative diabetic retinopathy as a cause of a 'table-top retinal detachment' (fig. 5a) [25]. It is now obvious that the true vitreoretinal architecture is very different. The cortical vitreous is rarely detached in these eyes; rather there is a rather large, but anterior, ring-like vitreoschisis, with multiple smaller ones, present more posteriorly (fig. 5b). If the surgeon does not remove the outer wall of each cavity – a thin but very adherent layer of the cortical vitreous, occasionally absent over the macula – postoperative complications such as re proliferation and tractional redetachment often occur.

The significance of syneresis lies not in its bothersome visual consequence ('mouches volantes') but in the fact that currents can now occur in the vitreous cavity. With every movement of the eyeball and especially the head, the gel accelerates and then decelerates [26], and each

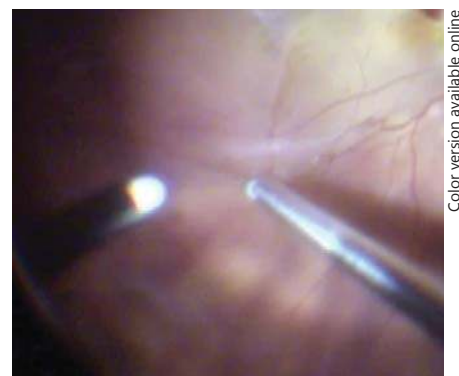


Fig. 4. Lack of PVD in a highly myopic eye with RD over the staphyloma. In this intraoperative image, the vitrectomy cutter, with only aspiration but not the cutting activated, is seen engaging the still adherent posterior cortical vitreous (vertical line), with the separation between vitreous and retina delineated by the light reflex (horizontal line). The adhesion between the two tissues was so strong temporal to the macula that the vitreous had to be cut by scissors to avoid tearing of the retina or extending its detachment.

movement has a shearing effect on the retina at all points of adhesion, creating dynamic traction [27]. Whether the dynamic traction actually causes a retinal break depends on the strength of two opposing forces: the extent, frequency and duration of the traction on one side, and a combined power of the RPE pump, the IPM and tensile strength (physical resistance) of the retina on the other side. Should a retinal break develop and remain flapped, it is up to the RPE and the IPM to prevent the adjacent retina from being pulled off.

If a small area of retina detaches (subclinical RD) and there is subretinal fluid accumulation as the next step in the pathological cascade, the RPE pump may still be sufficient to prevent the spread of the detachment. A true RD

will develop when the amount of the incoming fluid from the vitreous exceeds the amount the RPE can remove and pass on to the choriocapillaris.

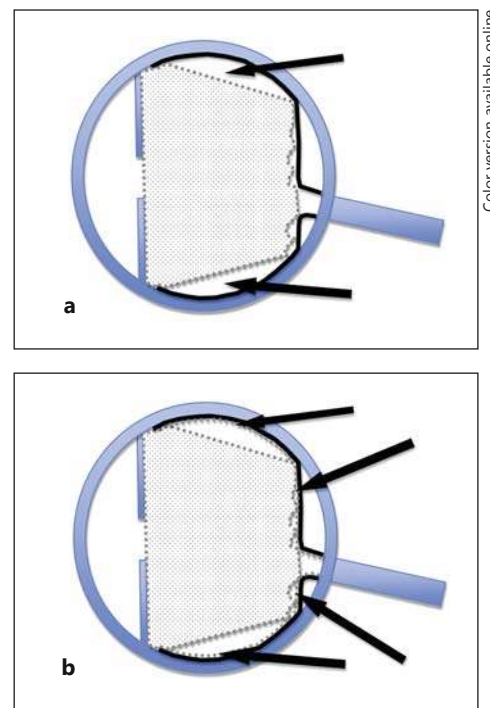
Spontaneous PVD: Assumption versus Reality

As mentioned before, one of the most common diagnostic errors is to declare the presence of a PVD based on history and/or biomicroscopic (OCT) examination. A history of flashes does not necessarily signify, and cannot be equated with, PVD. Flashes signal two things: that there is traction on the retina from the mobile vitreous and that this traction is sufficiently strong to elicit a response from the brain ('light is being seen'). Whether the traction is indeed caused by a PVD, or by a synergetic but still (completely or partly) attached vitreous pulling on the retina, is a diagnosis that cannot be reliably made preoperatively in the vast majority of cases.

The very definition of a PVD (table 1) makes its (preoperative) diagnosis difficult. If the cortical vitreous is unusually thick, as shown by OCT in figure 3, or marked by certain pathologies such as blood or sychysis scintillans, its recognition at the slit lamp is relatively straightforward. However, and this is the typical scenario, if the outer wall of the vitreoschisis cavity is thin and transparent (fig. 2), this layer is impossible to detect clinically or with current OCT technology. Neither is the presence of a Weiss ring, as mentioned earlier, necessarily synonymous with a PVD.

Recognizing a 'native' PVD can be difficult even during PPV. The nonmarked posterior cortical vitreous is transparent, therefore invisible. In eyes with vitreomacular traction syndrome, the posterior hyaloid face is unusually condensed and well defined, but varying the positioning of the light pipe may still be required for detection. For reliable identification of the posterior cortical vitreous, it is necessary to mark it with triamcinolone acetonide (TA). Once a tiny amount of the drug, following a small core vitrectomy above the posterior pole, has been injected and the free-floating crystals have been removed, the posterior hyaloid face becomes visible as the crystals adhere to it. If the crystals that settled on the retina can be easily washed away or aspirated, it typically means that no vitreous is present on the retinal surface.

Even this test, however, is not always able to provide absolute proof that a true PVD has occurred. Occasionally, the internal surface of the still present cortical vitreous is too smooth for the TA crystals to stick to. In these cases, the surgeon usually recognizes the presence of the



Color version available online

Fig. 5. The typically described and the real 'table-top' type of RD in an eye with proliferative diabetic retinopathy. **a** The typical representation, showing a partly detached (posterior) and partly attached (anterior) retina (thick black line). The RD is caused by vitreous traction originating from a partial PVD; the vitreous is attached posteriorly (albeit not uniformly) but, forming a conical or funnel-shaped configuration, is detached anteriorly (arrows). **b** In the vast majority of cases, however, the cortical vitreous is split (vitreoschisis). A second, thin layer of the cortical vitreous (arrows) remains adherent to both the detached and the attached retina. Serious postoperative complications threaten if this outermost vitreous layer (the outer wall of the schisis cavity) is not removed. Depending on the actual case, there may be several vitreoschisis cavities, and the surgeon must be watchful to peel the outer wall in its entirety, both in terms of the surface area and its thickness; the adherent cortical vitreous may consist of multiple layers.

cortical vitreous when trying to peel ILM or by applying a stain such as indocyanine green (ICG) to highlight it. Table 2 summarizes the diagnostic traps related to PVD.

The Pathogenesis of RD

Traditionally [28], the retinal break is considered to be the crucial factor in the development of an RD, as summarized in the following typical statement: 'The most common form [of retinal detachment] is rhegmatogenous RD, which occurs as a result of a full-thickness reti-

Table 2. Diagnostic traps related to PVD

Category	Variable	Comment
History	Flashes	May signal a PVD occurring – or is simply a consequence of vitreoretinal traction
	Old age	Complete PVD has not necessarily occurred
	Vitreous hemorrhage	Even if caused by trauma and being months old, PVD is not necessarily present
	High myopia	Vitreoschisis is much more common than true PVD
	Proliferative diabetic vitreoretinopathy with RD	Vitreoschisis is much more common than true PVD
Preoperative examination	Weiss ring	The vitreous may still be attached elsewhere; conversely, the absence of a Weiss ring does not mean PVD has not occurred
	Visible surface at the slit lamp	May be a PVD but also the inner wall of a vitreoschisis cavity
	Visible surface on OCT, detached from the retinal surface	May be a PVD but also the inner wall of a vitreoschisis cavity with an outer wall not being sufficiently thick/dense to be detected by the machine
Intra-operative finding	No vitreous visible on the retinal surface	The cortical vitreous may or may not be attached; ‘trial and error’ (aspiration-lifting, see ‘enlarging peripapillary circle’) or some type of marking is necessary to prove or disprove the presence of a PVD
	‘Enlarging peripapillary circle’	With high aspiration (or flow) applied at the disk margin and gradually extended toward the periphery, an ever-larger concentric, dark ‘wave’ may be seen; this marks the true separation between the posterior cortical vitreous and the retina
	Marking by TA	In most cases, the crystals adhere to the remaining vitreous and clearly delineate it; however, the inner vitreous surface may be too smooth to capture the crystals (false-negative result)
	ICG	The remaining vitreous has a light-green tint, but it is not always easy to visualize

nal break’ [29]. That 5–10% of postmortem eyes show the presence of a full-thickness retinal break but no RD [30], however, should raise some doubt about the break’s primary role in RD development.

Similarly, PVD is widely considered to be a crucial element in the formation of a retinal tear: ‘a spontaneous RD is usually preceded by a PVD’ [29], or ‘posterior vitreous detachment is the principal predisposing event related to the development of rhegmatogenous RD because the posterior vitreous separation from the retina can cause retinal tears and subsequent RD’ [31]. The rate of RD has been reported to increase from 1.5 to 7% if PVD has occurred [32, 33], and up to a third of eyes with a spontaneous PVD have been reported to have a retinal break or detachment [34, 35].

Even though the importance of traction has been properly noted in some reports [36–39], in many publications it is either not mentioned at all [40] or not emphasized according to its real significance [29, 41, 42]. This is especially strange since it has been reported that once operculated, tears do not pose a threat any more [43, 44], clearly demonstrating the importance of traction as the cause of the break and thus the detachment. The findings that if the PVD causes a symptomatic retinal tear, RD ensues in up

to 90% of eyes [44–46], and that atrophic holes (i.e. no traction is present) almost never cause symptoms (flashes) – and, thus, no more than subclinical RD – until a ‘PVD’ (traction) occurs, and when symptoms appear and an RD develops [32], also point to the primary role of traction.

In the authors’ appreciation of the pathogenesis of RD, it is the traction and not the retinal tear that is the key element, but it must also be examined why traction develops. The significance of syneresis as the initial link in the chain of events leading to RD is well demonstrated by clinical observations related to dialysis. This uncommon type of retinal break usually develops in young patients with a healthy (nonsyneretic) vitreous. The separation typically occurs at the time of the contusion, yet the RD follows only years later [47] when the vitreous starts to lose its homogeneous structure and becomes syneretic.

In the presence of intraocular adhesions, once syneresis occurs and there is a higher degree of liquefaction than separation of the vitreous from the retina (anomalous PVD [18]), the retina is exposed to what can be compared to a tug of war. Dynamic traction is exerted with every movement of the eye or head, trying to pull the retina off; this force is countered by the cumulative effect of the RPE, the IPM and the retina’s tensile strength. Most of the time

Table 3. Classification of traction on the retina and definitions of the various types of traction forces

Classification according to the traction's location	Subretinal	Bridging a concave-shaped structure, the contractile membrane/strand is capable of 'pushing up' the overlying retina. The proliferative tissue may be highly visible yet not lead to RD development. If RD does develop, it is typically limited in height and extent, and its progression is usually very slow. The contractile membrane/strand may be adherent to only the retina, only to the RPE, or both. These membranes virtually always represent static traction (see below).
	Intraretinal	There is retinal shortening, leaving two options to reattach the retina: turning the concave surface into convex (SB) or allowing the retina to contract to alleviate it from being stretched (retinotomy). These membranes typically represent static traction (see below).
	Preretinal (intravitreal, vitreoretinal, trans-vitreous)	The most common form of traction, with the proliferative tissue acting on the retinal surface. The sum of the vectors is pulling the retina up and away from the RPE. The contractile membrane/strand is adherent to the retina at least at one location. These membranes may represent both dynamic and static traction (see below); the latter is most prominent in proliferative diabetic vitreoretinopathy.
Classification according to the traction's type	Dynamic (vitreoretinal)	Vitreoretinal traction is present only when there is movement of the eyeball or the head. If there is no intraocular current caused by such eye or head movement for a sufficiently long period of time, a detached retina will spontaneously reattach. The contractile membrane/strand is adherent to the retina at least at one location. When a retinal break develops, the RD progresses rather rapidly.
	Static (retinoretinal)	The contractile membrane/strand is adherent to the retina at more than one location and lifts it permanently, irrespective of eye/head movement. The proliferative tissue may be on either the surfaces of or inside the retina, but may also be transvitreal 'anterior or loop'. Static traction is significant and present all the time, but eye/head movement may exacerbate it. Even when a retinal break develops, the RD progresses rather slowly because the proliferative membranes hold the retina in a somewhat fixed position, limiting the effects of intraocular currents; conversely, if the proliferative element is removed during surgery but the rhegmatogenous component is not dealt with, the RD progression is very rapid and it easily becomes bullous.
Classification according to the traction's vector	Tangential (surface)	The primary vector of the traction force is parallel to the retina. It may be epiretinal (such as in a macular pucker) or subretinal.
	Intravitreal	At least one end of the proliferative tissue is adherent to the retina; based on its architecture, it may be sagittal, oblique or frontal/coronal (connecting the vitreous base 360° behind the lens)

the latter prevails and the retina does not tear and remains attached. However, with a shift of the equilibrium, either by the increase in traction, the weakening of the forces keeping the retina in place, or a combination of both, the retina tears.

A retinal tear, however, does not necessarily lead to detachment [48]. The smallish retinal area to which the vitreous is strongly adherent may tear off (operculum), leaving the surrounding retina not only attached but now free of traction. (What the patient sees as a floater is much less commonly the torn-off retina than the degenerated collagen fibers floating in the synergetic fluid pocket.)

The flashes noticed by the patient communicate the presence of dynamic traction (table 3), as the seeing of light is the only response the retina, lacking pain recep-

tors [49], has to a physical force. The flash is thus a much more threatening phenomenon than the floaters are; it is a warning sign that traction forces are at play. The presence of lattice degeneration is a known, although rather weak, risk factor for RD [33], by itself not justifying prophylactic (laser) treatment. However, when risky peripheral degenerations are present and flashes occur, such prophylactic treatment is highly recommended.

If the tear, typically of horse-shoe shape, does not lead to operculum formation, the risk of RD is measurable, since the mobile vitreous remains attached to the tip of the tear. With intraocular currents [50] being present during saccadic eye and normal head movements [27], the retina immediately adjacent to the tear may also get lifted, literally opening the door for the intravitreal fluid

Table 4. The chain of events leading to RD

Progressive links in the chain	Comment
Syneresis	The breakdown of the gel can be caused by age or a multitude of pathological events.
Gel movement (intraocular currents)	With the coexistence of gel and free (unbound) water in the vitreous cavity, movement of the head and/or eyeball forces the gel to move rapidly (acceleration/deceleration). The movement of the gel helps the development of separation between the vitreous gel and the ILM.
Partial separation of the vitreous cortex from the retina	The risk of retinal tear formation disappears if there is absolutely no gel in the vitreous or there is absolutely no PVD; any condition in between (anomalous PVD), whether there is one or several, large or very small, area(s) of adhesion between them, creates the possibility of traction development.
Development of vitreoretinal traction	Once there is gel movement in the presence of vitreoretinal adhesion, the potential for the retina to be torn exists. Whether and when it actually occurs depends on the outcome of a constant ‘tug of war’ between two groups of forces.
‘Tug of war’	On the one hand, the dynamic traction tries to lift the retina at the point/in the area of adhesion. On the other hand, the suction force of the RPE, the ‘glue’ effect of the IPM and the resistance (tensile strength) of the retina work against the tearing itself as well as the torn retina being lifted. The patient may notice flashes upon head/eyeball movement.
Formation of a retinal break	If the dynamic traction overcomes the forces working against its effect, the retina tears; the adhesion persists, leaving vitreous fibers attached to the torn retina. As the vitreous is more mobile posterior to the tear than anterior to it, the apex of the torn retina virtually always points toward the center (horse-shoe tear, with its base closer to the periphery).
Tractional retinal tear: possible scenarios	In principle, there are three possibilities: (1) the retina already torn tears again; an operculum is formed; with the effect of vitreoretinal traction now eliminated, the retina remains attached; the flashes cease, but the patient may see a mobile shadow (floater, operculum or a small hemorrhage); (2) the forces keeping the retina attached keep winning in the tug of war, and no RD ensues; the patient continues to experience flashes; with time, reactive pigmentation surrounds the tear and the RD risk diminishes; (3) the dynamic traction overcomes the sum of the ‘defensive forces’ and the retina detaches; how fast the detachment spreads depends on many factors: the strength of the defenses (especially the efficacy of the RPE pump), the strength of the traction and shear stress on the retina (the more advanced the syneresis and the more movement of the head/eyeball, the more pronounced the effect; if there is absolutely no eye movement, the retina almost always reattaches), and the location of the tear (due to gravity, superior tears lead to RD earlier).
RD development	The traction/shearing force not only tears the retina but elevates it, allowing the unbound water to enter the subretinal space. Once too much fluid is present for the RPE to remove, the typical clinical picture of a rhegmatogenous RD emerges.

to enter the subretinal space, thereby giving rise to RD development once the amount of incoming fluid exceeds the RPE’s clearance capacity. Table 4 and figure 6 summarize the chain of events leading to RD.

As mentioned before, a peripheral round hole is extremely unlikely to lead to RD as there is no traction at play. In this case, the retinal tissue simply disintegrates, but the RPE and IPM in the surrounding area are sufficient to keep the retina attached. This is also the reason why a macular hole virtually never leads to more than a small ring (‘cuff’) of subretinal fluid accumulation. The

substantial detachment and fluid pooling over the staphyloma in highly myopic eyes is of an entirely different mechanism: the vitreoretinal traction produces a vector that pulls the mostly elastic membrane [27] away from the concave surface underneath. The presence of a macular hole in these eyes is more the cause than the consequence of the central RD, but it aggravates the condition by allowing ever more fluid to enter the subretinal space [51]; removal of the ILM, the only inelastic part of the retina, is often sufficient to deal with both the detachment and the hole.

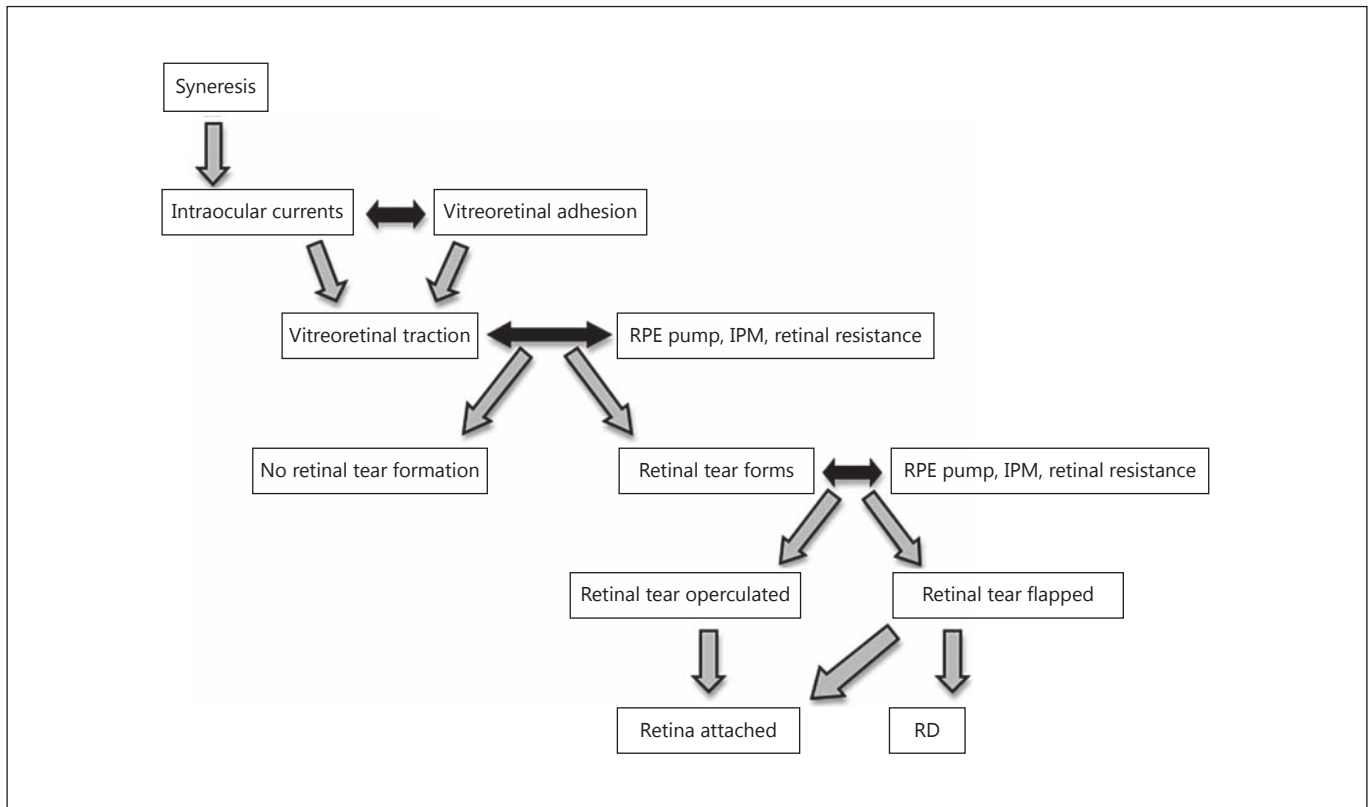



Fig. 6. Flowchart of the pathophysiology of RD.

The risk of dynamic traction leading to RD development is proportional to the extent of gel movement (allowed by the synergetic changes). If a mismatch between the amount of gel present and the space available for gel movement exists (such as in highly myopic eyes, where the gel is unable to keep up with the growth of the eyeball or eyes after cataract extraction), the risk also increases.

The significance of dynamic traction and thus intraocular currents is readily supported by clinical experience. In an eye with combined RD/tractional RD (TRD; or when a retinal break is accidentally caused during TRD surgery), the end result is actually worse than the preoperative situation. Once the tractional elements have been released, the intraocular currents further the entry of intravitreal fluid into the subretinal space, and the retina becomes highly mobile (bullous RD).

In the literature, the horse-shoe tear is almost uniformly appreciated to occur where the PVD terminates anteriorly (fig. 7). The vitreous is described as being detached posterior but attached anterior to this point; the anterior vitreous is adherent to the retinal flap, but a complete PVD is present over the detached posterior retina. However, the reality is often different.



Color version available online

Fig. 7. Schematic representation showing the typically described configuration of the vitreoretinal interface (PVD) in eyes with RD. The vitreous, still having gel consistency, is detached posterior but attached anterior to the retina (thick black line). The tear is located at the posterior border of, and is caused by, the PVD. The lens and the macula are not shown for simplicity.

In more than half of eyes undergoing PPV for an RD [Kuhn, unpubl. data], the intraoperative use of TA shows that PVD either has not occurred at all or is incomplete. Figure 8 shows these scenarios in a schematic format; figure 9 shows intraoperative examples of the vitreous re-

maintaining attached posterior to the tear. Figure 10 presents a histological specimen explaining how eyes with no clinically visible PVD can still develop traction at the edge of a focal PVD if syneresis has occurred, allowing dynamic traction to affect the retina with the potential for tearing and eventually detaching it.

Therapy: Theoretical Considerations

Traditionally, the literature focuses on treating the break, occasionally not even mentioning the traction as a treatment target: ‘(1) find all breaks; (2) create a chorio-retinal irritation around each break, (3) bring the retina and choroid in contact for sufficient time to produce a chorioretinal adhesion to permanently close the break(s)’ [40]. While the retinal tear must indeed be addressed and an intraocular tamponade applied, the primary target of any treatment modality should be the dynamic traction. Any doubt that may still exist about the importance of this traction (and intraocular currents) should be dispelled by the age-old observation that the retina reattaches after the eye is immobilized (generally, the person is bilaterally patched and kept in bed) [52, 53]. Although the retinal break is still present, there is no movement of the eyeball and head (hence the dynamic traction is eliminated), fluid entry through the tear ceases and the subretinal fluid is cleared by the RPE. Furthermore, this experience also underlines the difference between the effects of dynamic and static traction; the TRD will not disappear even with bilateral patching and bed rest, because the traction is permanent (independent of eyeball/head movement).

The dynamic traction can be addressed in a number of ways. SB is a very effective therapy because by indenting the eye wall, it turns the eye wall’s distant concave contour into a proximal convex one, thereby modifying the direction (vector) of the force that is pulling on the retina (fig. 11) and reducing its strength. SB must satisfy two criteria to be effective. First, the weakening of the traction has to be sufficient (a buckle high enough [42]). It must be understood, however, that the traction is not eliminated but neutralized. Second, the break must be properly positioned on the indentation. The correct position is on the very crest of the buckle or immediately adjacent to it on its anterior slope so as to minimize the effect of the still present dynamic traction. If the break is on the posterior slope, the retina may remain mobile enough to allow the break to be kept open (fish-mouthing) by the remaining traction, allowing continual fluid entry into the subretinal space.

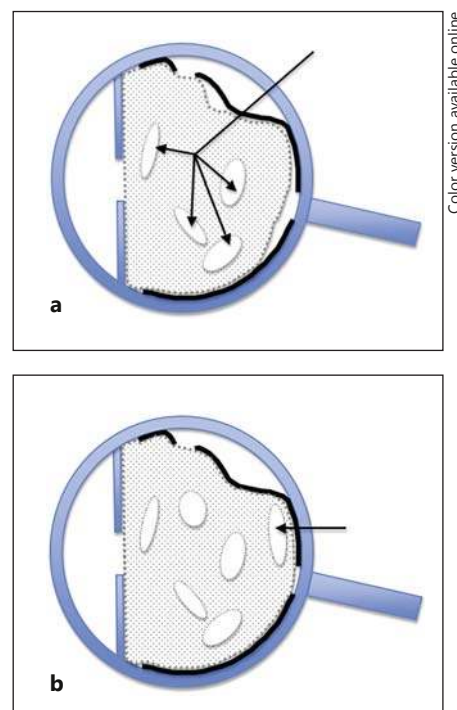


Fig. 8. Schematic representation showing additional configurations of the vitreoretinal interface (PVD) in eyes with RD. The lens and the macula are not shown for simplicity. **a** The syneretic (arrows) vitreous is still attached to the retina (thick black line) almost everywhere; there is only minimal PVD. **b** The syneretic vitreous is still attached to the retina seemingly everywhere (no PVD is present). There is a large vitreoschisis in front of the macula (arrow).

Pneumatic retinopexy works by limiting the flow of fluid through the break (a temporary effect until the pexy takes effect), and probably also by weakening the vitreoretinal traction, as the expanding gas bubble stretches it (a more permanent effect). However, space inside the vitreous cavity is limited, therefore this stretching can also create, or increase existing, traction elsewhere [54] – hence the up to 30% occurrence of new retinal breaks after the procedure [55]. Proper indications for pneumatic retinopexy are not the absence of vitreoretinal (dynamic) traction [56], since such traction is always present, but a traction that is not too advanced and syneretic changes that are rather limited.

PPV, unlike the two previous surgical options, works by eliminating the traction. As opposed to the indirect effect of SB, vitrectomy addresses the essence of the problem by removing the syneretic vitreous and thus the dynamic traction it implies. The removal of the vitreous, however, must be complete (see below).

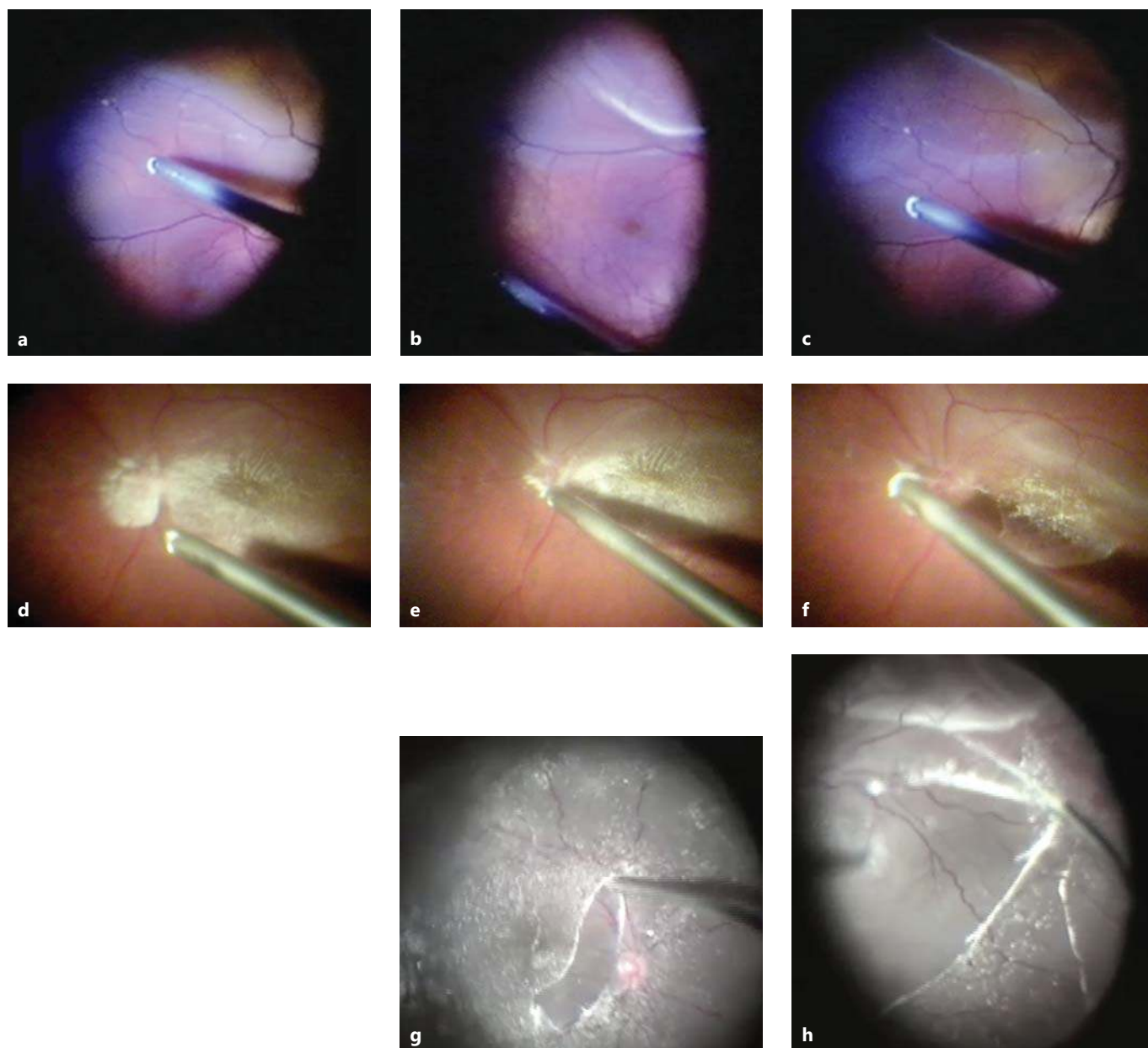


Fig. 9. Intraoperative images showing a lack of PVD posterior to the retinal tear in eyes with RD. **a** The vitrectomy cutter is engaging the undetached posterior vitreous in an eye with an RD caused by an inferior retinal break at the periphery. **b, c** Using only aspiration, the vitreous is progressively detached (PVD creation) toward the periphery, as shown on the image (**b**) by a light reflex delineating the line between the central area with and the peripheral without PVD. The separation line is then clearly extended anteriorly.

d-f Identical clinical conditions, but the still attached posterior cortical vitreous is marked with TA. **d** No PVD over the detached posterior retina. **e, f** In the same eye, a PVD is created and progressively carried toward the inferior periphery. In this eye with total RD, the Tano scraper has been used to create a small central PVD (**g**), which is then enlarged; the traction exerted on the inferior retina is clearly visible as the Tano scraper is moved toward to nasal periphery (**h**). **g, h** Courtesy of H. Mortada.



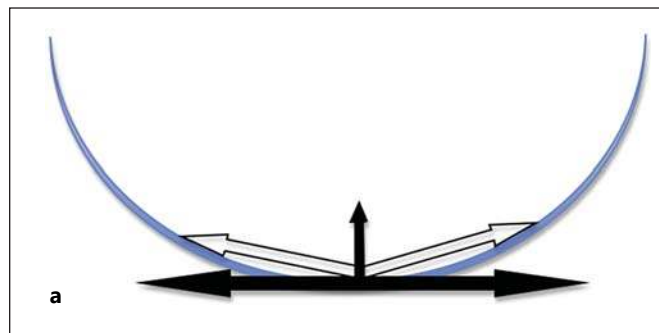
Color version available online

Fig. 10. Histological specimen showing a focal PVD. The arrows point to where tearing can occur: at the border of the ‘in situ’ area of separation of the vitreous from the retina (star) (courtesy of S. Bopp). See the text for additional details.

Whether performing pneumatic retinopexy, SB or PPV, an important part of the surgery is to create a barrier around the peripheral retinal break – chorioretinal adhesion by cryopexy or, preferably, laser. The goal is to seal the edge of the retina immediately adjacent to the break to supplement the effects of the RPE and IPM and to ‘close the door’ to fluid entry from the vitreous. If vitrectomy is the chosen therapy, the flap must be removed and any curled edge of the remaining retina cut so that the laser is applied over a surface that is and will remain flat. Crucially, the chorioretinal adhesion counters the sloshing effects of intraocular currents.

If the retinal break is a macular hole over the staphyloma in a highly myopic eye, lasering around it is not recommended for several reasons: first, so as to avoid enlarging the scotoma; second, because here – unlike at the periphery – it is possible to completely eliminate the causative traction by creating a PVD (which, contrary to common belief [24], is very rare) and by removing the ILM, the only nonelastic part of the retina [51]; and third, as the reduced pigment content of the RPE makes the laser largely ineffective. Conversely, peripheral retinal breaks do require laser retinopexy because it is not possible to completely remove the vitreous in their vicinity. As described above, it is also possible that the RPE pump and the IMP are not as efficient here as they are in the central retina, justifying the need for the extra adhesive protection the laser provides.

In eyes undergoing PPV for RD, a tamponade is almost always employed. Air is too short-acting to allow for the pexy to reach sufficient strength in a timely manner, leaving gas (usually a nonexpansible concentration of SF₆, sulfur hexafluoride) or silicone oil. The latter is an



Color version available online

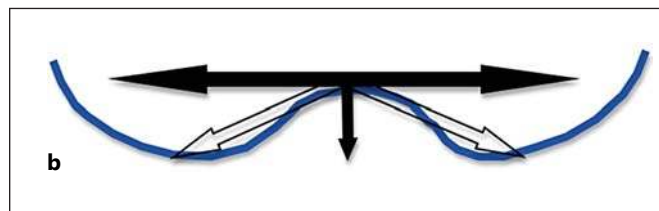


Fig. 11. Vectors acting upon the attached and detached retina. The retina has elastic properties, therefore there is a constant tangential force trying to contract it. **a** When the retina (curved line) lines a concave surface, this force (blank arrows) resolves into a horizontal component and a vertical component (solid arrows). The vertical component acts to detach the retina. **b** However, when the surface is convex (e.g. after SB), that vertical component acts to (re)attach the retina.

option selected if the tamponade is felt to be necessary for several weeks or months to prevent PVR, and there are reports to support that this may indeed be effective [R. Morris, unpubl. data]. Another advantage of silicone oil is that it will limit the extent and speed of progression of the retinal redetachment should a severe PVR indeed occur, allowing the surgeon ample time to plan and execute the reoperation.

Especially in the case of gas, the importance of proper positioning [57] is traditionally emphasized to the patient. The rationale for positioning is to block the intravitreal fluid from accessing the subretinal space through the break before the pexy permanently seals the edges of the tear, which is widely accepted to happen within a week or so. However, the true effect of the gas bubble may well be different: it reduces the amount of space for the intraocular fluid to exert its sloshing effect (intraocular currents) and thus the shear stress on the retina [27]. Indeed, the personal experience of the authors supports this hypothesis. In a quick succession of 5 consecutive eyes with inferior breaks, one of the authors (F.K.) was handed a premixed syringe containing a gas with a 5% SF₆ concentration, a fact unknown to the surgeon. As can be expect-

ed, the gas fill was no more than 50% the next day. The gas bubble covered the area of the break only for a few hours, yet not a single retina redetached. (The fact that there was no tamponade before the laser could have taken effect does not argue in favor of forgoing the laser treatment.)

This unintended experience supports the clinical experience of others that, contrary to the commonly held view [58], there is no need for a supplementary buckle support in eyes with an RD caused by an inferior break – provided that the vitrectomy was truly complete (traction eliminated). Apparently, the RPE pump and the IPM glue recover fast enough to reduce the risk of secondary failure even in the absence of a complete gas fill. This is, of course, not to say that the surgeon should refrain from aiming for a 100% fill using a proper gas concentration.

In summary, the primary goal of surgery remains the elimination of traction and the creation of a chorioretinal adhesion around the tear. The goal of using a gas bubble is to prevent the intraocular currents from causing retinal shear stress and fluid reentry through the retinal break, and not to cover the break ('tamponade'). Positioning, a part of the postoperative course despised by most patients, then loses the high importance attributed to it [27].

Therapy: Practical Considerations for Eyes Undergoing PPV for RD

The arguments and clinical observations listed above confirm that the most important attribute of vitreous removal is to be truly complete. Traditionally, it is at the periphery where the need for such completeness is emphasized (see above). The authors' recommendation is to include two additional areas where achieving completeness of PPV should constitute an integral step of the surgery: posteriorly (PVD) and in the coronal plane immediately behind the lens, whether crystalline or artificial.

As shown in figures 3, 4, 8 and 9, it may be impossible to determine intraoperatively, much less preoperatively, whether a complete PVD is present. It is thus recommended to start the PPV by removing a small amount of vitreous in front of the posterior pole to create space for the injection of a small amount of TA over the posterior retina. In the vast majority of eyes, the crystals will adhere to the vitreous still present on the retinal surface, and will make it conspicuous. As described earlier, in a few eyes with too smooth an outer wall of the posterior vitreoschisis cavity, ICG staining or 'blind' aspiration may be need-

ed. A more judicious application of TA ('intraretinal snowfall') is somewhat annoying due to the time it takes for all the free-floating crystals to be removed. Conversely, larger amounts of TA are very useful for delineating any vitreous remaining on the retinal surface (fig. 9f, g), including at the periphery.

The second area of vitreous removal to which little attention has been paid in the past is the anterior vitreous face. While omission of this step may not have immediate consequences, it can be another source of late failure; if the gel immediately posterior to the lens subsequently contracts, it can cause new peripheral retinal tears or the reopening of an original one.

In pseudophakic eyes it is easy and risk-free to perform vitrectomy behind the posterior capsule; in fact, it is also advantageous to perform a capsulectomy as well. In phakic eyes, however, the surgeon must tread carefully to avoid injuring the lens. The method the authors found to be most effective is to switch out the otherwise used binocular indirect ophthalmomicroscope (Oculus, Wetzlar, Germany) and to use the microscope at high magnification for this maneuver. If the lens is not perfectly clear, the posterior capsule is visible enough to safely detach and remove the anterior vitreous face. If the posterior capsule is difficult to discern, a small air bubble needs to be injected behind the lens. If vitreous is present, the bubble is trapped behind the lens. In the absence of the gel, the bubble readily escapes toward the vitreous base.

With all the rest of the vitreous removed, the surgeon must attend to the retinal periphery. The goal here is first to remove all the vitreous around the break and to cut the tear's operculum completely; then, removal of the vitreous must be completed 360°. In phakic eyes, this requires two things to be done properly. First, the working sclerotomies, whether cannulated or not, must be made very close to the 3- and 9-o'clock positions. Sclerotomies placed too superiorly make complete removal of the vitreous in the inferior periphery impossible without causing lens injury – hence the common recommendation to 'add a scleral buckle if the break is inferior'. Second, the surgeon must switch hands to be able to complete the vitrectomy on both sides.

As mentioned above, PPV at the periphery cannot be as complete as it is posteriorly. At the vitreous base, the surgery is, in reality, shaving, not removal. However, as little vitreous as possible should be left behind ('close shaving'). This is best achieved by using the highest possible cut rate with minimal flow in a machine with a peristaltic pump, and low aspiration in a machine with a Venturi pump.

Even with such a cautious approach, the detached retina may be too mobile to eliminate the risk of iatrogenic retinal injury. While using a heavy liquid may help, it is expensive, or its use may be unadvisable for other reasons. One alternative is to perform what the authors call 'pneumovitrectomy'. Once a fluid-air exchange has been performed, the remaining peripheral vitreous becomes easily visible under air when the vitrectomy cutter is submerged in it. The vitreous can then be trimmed as the air constantly pushes back the retina, greatly reducing the risk of injury. After the removal of the vitreous has been completed, the surgeon should perform laser retinopexy. A properly executed laser cerclage should at least be considered [59], as opposed to treating only those areas with a visible pathology. Since a large proportion of retinal breaks occur at or around the equator, not at the vitreous base [38], lasering (prophylaxis) should not be restricted to the extreme periphery but include a wider area to be effective ('ora secunda cerclage') [59]. The eye is left with a gas bubble but without the requirement for strict positioning. Using the surgical approach described above, the primary failure rate was zero in one of the authors' (F.K.) series of 254 consecutive vitrectomies for RD; the secondary failure rate was 0.4%, and the tertiary 3.5%.

Conclusions

This article does not argue against pneumatic retinopexy for RD treatment. In properly selected cases, pneumatic retinopexy is a rather effective option, and it does not appear to reduce the success of secondary surgery in the relatively high proportion of secondary failures [60]. SB is a highly successful operation, and this article does

not argue against this treatment either. However, the authors do want to emphasize that the notion that 'scleral buckling is an art' is wrong if it is meant to convey a message of vitrectomy not being one; to be as effective as its potential suggests, PPV must also be done correctly.

If one accepts the accumulated evidence and sees dynamic traction as the primary target of surgery, PPV should be not just a more rational but also a more effective operation than SB, since vitrectomy addresses the very cause of the RD. Indeed, a study comparing the rate of late failures of eyes undergoing SB versus PPV for RD identified traction as the cause of the redetachment, and the failure rate was over 4 times higher when SB rather than PPV was performed [61]. However, most investigations reported in the literature found the results of the two techniques to be very similar [62]. The question is obvious: Why is this the case? Why has PPV not been found to be superior?

The authors believe the reason for the secondary failure rates being similar with SB and PPV lies in the failure to perform a truly complete PPV. A PVD is too often assumed to have preceded – in fact, caused – the RD, and the importance and diagnostic challenge of a vitreoschisis are not properly acknowledged. As a result, vitreous is often left behind, which then may create a situation even more dangerous than the original one. With an incomplete PPV there still is mobile gel in the eye, but there is now more room for it to exert dynamic traction (mismatch; table 2), intraocular currents, retinal shear stress and redetachment as the free fluid enters the newly formed or original break at the point of residual vitreoretinal adhesion. If, therefore, PPV is the selected treatment option for an RD, it must be done properly, thoroughly and meticulously – an art indeed [36].

References

- 1 Cantrill HL, Pederson JE: Experimental retinal detachment. VI. The permeability of the blood-retinal barrier. *Arch Ophthalmol* 1984; 102:747–751.
- 2 Marmor MF, Negi A: Pharmacologic modification of subretinal fluid absorption in the rabbit eye. *Arch Ophthalmol* 1986;104:1674–1677.
- 3 Kim R, Yao X, Marmor M: Oxygen dependency of retinal adhesion. *Invest Ophthalmol Vis Sci* 1993;34:2074–2078.
- 4 Hageman GS, Marmor MF, Yao XY, Johnson LV: The interphotoreceptor matrix mediates primate retinal adhesion. *Arch Ophthalmol* 1995;113:655–660.
- 5 Hollyfield JG, Varner HH, Rayborn ME, Osterfeld AM: Retinal attachment to the pigment epithelium: linkage through an extracellular sheath surrounding cone photoreceptors. *Retina* 1989;9:59–68.
- 6 Marmor MF, Yao XY, Hageman GS: Retinal adhesiveness in surgically enucleated human eyes. *Retina* 1994;14:181–186.
- 7 Yao XY, Hageman GS, Marmor MF: Retinal adhesiveness is weakened by enzymatic modification of the interphotoreceptor matrix in vivo. *Invest Ophthalmol Vis Sci* 1990;31: 2051–2058.
- 8 Anderson DH, Guerin CJ, Erickson PA, Stern WH, Fisher SK: Morphological recovery in the reattached retina. *Invest Ophthalmol Vis Sci* 1986;27:168–183.
- 9 Foulds WS: The vitreous in retinal detachment. *Trans Ophthalmol Soc UK* 1975;95: 412–416.
- 10 Hogan MJ: The vitreous, its structure, and relation to the ciliary body and retina (Proctor award lecture). *Invest Ophthalmol* 1963;2: 418–445.
- 11 Bishop PN: Structural macromolecules and supramolecular organisation of the vitreous gel. *Prog Retin Eye Res* 2000;19:323–344.

- 12 Sebag J, Balazs EA: Human vitreous fibres and vitreoretinal disease. *Trans Ophthalmol Soc UK* 1985;104:123–128.
- 13 Sebag J, Balazs EA: Morphology and ultrastructure of human vitreous fibers. *Invest Ophthalmol Vis Sci* 1989;30:1867–1871.
- 14 Sebag J, Hageman GS: Interfaces. *Eur J Ophthalmol* 2000;10:1–3.
- 15 Snead MP, Snead DR, Richards AJ, Harrison JB, Poulson AV, Morris AH, Sheard RM, Scott JD: Clinical, histological and ultrastructural studies of the posterior hyaloid membrane. *Eye (Lond)* 2002;16:447–453.
- 16 Kuhn F, Mester V, Morris R: A proactive treatment approach for eyes with perforating injury. *Klin Monbl Augenheilkd* 2004;221:622–628.
- 17 Matsumoto B, Blanks J, Ryan S: Topographic variations in the rabbit and primate internal limiting membrane. *Invest Ophthalmol Vis Sci* 1984;25:71–78.
- 18 Sebag J: Anomalous posterior vitreous detachment: a unifying concept in vitreo-retinal disease. *Graefes Arch Clin Exp Ophthalmol* 2004;42:690–698.
- 19 Snead MP, Snead DR, James S, Richards AJ: Clinicopathological changes at the vitreoretinal junction: posterior vitreous detachment. *Eye (Lond)* 2008;22:1257–1262.
- 20 Balazs E, Denlinger J: Ageing changes in the vitreous; in Sekuler R, Kline D, Dismukes K (eds): *Ageing and Human Visual Function*. New York, Liss, 1982, pp 45–57.
- 21 Chu TG, Lopez PF, Cano MR, Freeman WR, Lean JS, Liggett PE, Thomas EL, Green RL: Posterior vitreoschisis: an echographic finding in proliferative diabetic retinopathy. *Ophthalmology* 1996;103:315–322.
- 22 Weber-Krause B, Eckardt C: Incidence of posterior vitreous detachment in the elderly (in German). *Ophthalmologie* 1997;94:619–623.
- 23 Morita H, Funata M, Tokoro T: A clinical study of the development of posterior vitreous detachment in high myopia. *Retina* 1995;15:117–124.
- 24 Akiba J: Prevalence of posterior vitreous detachment in high myopia. *Ophthalmology* 1993;100:1384–1388.
- 25 Hutton WL, Bernstein I, Fuller D: Diabetic traction retinal detachment: factors influencing final visual acuity. *Ophthalmology* 1980;87:1071–1077.
- 26 Repetto R, Stocchino A, Cafferata C: Experimental investigation of vitreous humour motion within a human eye model. *Phys Med Biol* 2005;50:4729–4743.
- 27 Angunawela RI, Azarbadegan A, Aylward GW, Eames I: Intraocular fluid dynamics and retinal shear stress after vitrectomy and gas tamponade. *Invest Ophthalmol Vis Sci* 2011;52:7046–7051.
- 28 Gonin J: La pathogénie du décollement spontané de la rétine. *Ann Oculist* 1904;132:30–55.
- 29 Bradbury M, Landers MI: Pathogenetic mechanisms of retinal detachment; in Ryan S, Wilkinson C (eds): *Retina*. St Louis, Mosby, 2001, p 1987.
- 30 Okun E: Gross and microscopic pathology in autopsy eyes. III. Retinal breaks without detachment. *Am J Ophthalmol* 1961;51:369–391.
- 31 Kroll A, Cohen R, Patel S: Retinal breaks; in Albert D, Jakobiec F (eds): *Principles and Practice of Ophthalmology*. Philadelphia, WB Saunders, 2000, pp 2319–2328.
- 32 Byer N: Peripheral retinal lesions related to rhegmatogenous retinal detachment; in Guyer D, Yannuzzi L, Chang S, Shields J, Green W (eds): *Retina, Vitreous, Macula*. Philadelphia, WB Saunders, 1999, pp 1219–1247.
- 33 Byer NE: Long-term natural history of lattice degeneration of the retina. *Ophthalmology* 1989;96:1396–1401.
- 34 Boldrey EE: Risk of retinal tears in patients with vitreous floaters. *Am J Ophthalmol* 1983;96:783–787.
- 35 Jaffe NS: Complications of acute posterior vitreous detachment. *Arch Ophthalmol* 1968;79:568–571.
- 36 Foster RE, Meyers SM: Recurrent retinal detachment more than 1 year after reattachment. *Ophthalmology* 2002;109:1821–1827.
- 37 McLeod D: Fresh retinal detachments: the role of scleral buckling. *Trans Ophthalmol Soc UK* 1986;105:480–488.
- 38 Mitrzy D, Fleck BW, Wright AF, Campbell H, Charteris DG: Pathogenesis of rhegmatogenous retinal detachment: predisposing anatomy and cell biology. *Retina* 2010;30:1561–1572.
- 39 Oshima Y, Emi K, Motokura M, Yamanishi S: Survey of surgical indications and results of primary pars plana vitrectomy for rhegmatogenous retinal detachments. *Jpn J Ophthalmol* 1999;43:120–126.
- 40 American Academy of Ophthalmology BSBC series: *Retina*. San Francisco, American Academy of Ophthalmology, 2005.
- 41 Michels R, Wilkinson C, Rice T: *Retinal Detachment*. St Louis, Mosby, 1990.
- 42 Smiddy WE, Glaser BM, Michels RG, de Bustros S: Scleral buckle revision to treat recurrent rhegmatogenous retinal detachment. *Ophthalmic Surg* 1990;21:716–720.
- 43 Benson W: Prophylactic therapy of retinal breaks. *Surv Ophthalmol* 1977;22:41.
- 44 Neumann E, Hyams S: Conservative management of retinal breaks: a follow-up study of subsequent retinal detachment. *Br J Ophthalmol* 1972;56:482–486.
- 45 Colyear BH Jr, Pischel DK: Clinical tears in the retina without detachment. *Trans Pac Coast Otoophthalmol Soc Annu Meet* 1955;36:185–219.
- 46 Davis MD: Natural history of retinal breaks. *Arch Ophthalmol* 1974;92:183.
- 47 Ross WH: Traumatic retinal dialyses. *Arch Ophthalmol* 1981;99:1371–1374.
- 48 Byer NE: Prognosis of asymptomatic retinal breaks. *Arch Ophthalmol* 1974;92:208–210.
- 49 van Buren JM: The retinal ganglion cell layer. *Br J Surg* 1964;51:399–410.
- 50 Machemer R: The importance of fluid absorption, traction, intraocular currents, and chorioretinal scars in the therapy of rhegmatogenous retinal detachments. XLI Edward Jackson memorial lecture. *Am J Ophthalmol* 1984;98:681–693.
- 51 Kuhn F: Internal limiting membrane removal for macular detachment in highly myopic eyes. *Am J Ophthalmol* 2003;135:547–549.
- 52 Algvere P, Rosengren B: Immobilization of the eye: evaluation of a new method in retinal detachment surgery. *Acta Ophthalmol (Copenh)* 1977;55:303–316.
- 53 Chen CY, Chen SN, Lin SM, Ho CL: Reduction of subretinal fluid after preoperative immobilization of the eyes with rhegmatogenous retinal detachment. *Chang Gung Med J* 2001;24:799–804.
- 54 Johnston PB, Maguire CJ, Logan WC: Failed retinal surgery caused by intraocular gas injection. *Br J Ophthalmol* 1988;72:322–325.
- 55 Poliner LS, Grand MG, Schoch LH, Olk RJ, Johnston GP, Okun E, Boniuk I, Escoffery RF: New retinal detachment after pneumatic retinopexy. *Ophthalmology* 1987;94:315–318.
- 56 Lisle C, Mortensen KK, Sjølie AK: Pneumatic retinopexy: a long-term follow-up study. *Acta Ophthalmol Scand* 1998;76:486–490.
- 57 Sharma A, Grigoropoulos V, Williamson TH: Management of primary rhegmatogenous retinal detachment with inferior breaks. *Br J Ophthalmol* 2004;88:1372–1375.
- 58 Gartry DS, Chignell AH, Franks WA, Wong D: Pars plana vitrectomy for the treatment of rhegmatogenous retinal detachment uncomplicated by advanced proliferative vitreoretinopathy. *Br J Ophthalmol* 1993;77:199–203.
- 59 Morris R, Witherspoon C, Kuhn F, Sapp M: Retinal detachment laser prophylaxis ora secunda cerclage (OSC): creating a second ora. *Retina Today* 2008;3:63–66.
- 60 Zaidi AA, Alvarado R, Irvine A: Pneumatic retinopexy: success rate and complications. *Br J Ophthalmol* 2006;90:427–428.
- 61 Bopp S, Böhm K: Late recurrences more than 1 year after primary successful surgery for rhegmatogenous retinal detachment (in German). *Klin Monbl Augenheilkd* 2008;225:227–235.
- 62 Heimann H, Bartz-Schmidt KU, Bornfeld N, Weiss C, Hilgers RD, Foerster MH: Scleral buckling versus primary vitrectomy in rhegmatogenous retinal detachment: a prospective randomized multicenter clinical study. *Ophthalmology* 2007;114:2142–2154.
- 63 Sebag J: Vitreoschisis. *Graefes Arch Clin Exp Ophthalmol* 2008;246:329–332.