

Ring chromosome 14 syndrome presenting with intractable epilepsy: a case report

Faruk İncecik¹, M. Özlem Hergüner¹, Gülen Mert¹, Sevcan Erdem², Şakir Altunbaşak¹

Divisions of ¹Pediatric Neurology and ²Pediatric Cardiology, Department of Pediatrics, Çukurova University Faculty of Medicine, Adana, Turkey. E-mail: fincecik@yahoo.com

SUMMARY: İncecik F, Hergüner MÖ, Mert G, Erdem S, Altunbaşak Ş. Ring chromosome 14 syndrome presenting with intractable epilepsy: a case report. Turk J Pediatr 2013; 55: 549-551.

Ring chromosome 14 syndrome is a rare genetic disorder. Typically, children with this syndrome have distinct facial features, development delay, microcephaly, seizures, ocular abnormalities, and recurrent respiratory infections. Epilepsy associated with ring chromosome 14 generally shows intractable seizures. We describe a six-month-old girl with ring chromosome 14 syndrome who presented with early-onset and drug-resistant seizures.

Key words: ring chromosome 14 syndrome, microcephaly, intractable epilepsy, developmental delay, children.

Ring chromosome 14 syndrome is a rare chromosomal anomaly, with clinical signs including characteristic face, microcephaly, psychomotor delay, hypotonia, seizures, feeding and growth difficulties, recurrent respiratory infections, and ocular abnormalities. Dysmorphic features are usually mild and include a high and prominent forehead, an elongated face with puffy cheeks, widely spaced eyes with blepharophimosis and epicanthus, a flat nasal bridge with a prominent nasal tip, and low-set ears^{1,2}.

To our knowledge, about 70 cases have been reported in the literature³. Epilepsy and mental retardation are the most common neurological symptoms in this syndrome. Seizures are generally of variable types and are typically hard to control².

Here, we present the case of a six-month-old girl with medically intractable seizures who was diagnosed with ring chromosome 14 syndrome.

Case Report

A six-month-old girl was admitted to our hospital because of recurrent seizures. According to the medical and family history, she was born after 40 weeks of gestation with a birth weight of 2800 g (P25), length of 47 cm (P3-10), and head circumference of 32 cm (<P3). Her parents were nonconsanguineous.

There was no family history of seizures or developmental or other neurologic disorders.

She was hospitalized. She had experienced complex partial seizures with secondary generalization since the age of three months. Despite phenobarbital therapy, her seizures persisted. Phenytoin was then started for seizures, but was also ineffective. During the hospitalization, her seizures continued daily, despite the administration of phenobarbital and phenytoin therapy. Therefore, oxcarbazepine was initiated in addition to the two conventional antiepileptic drugs, and the frequency of seizures decreased to several times per week. She was then discharged.

On her physical examination at admission, her weight was 7 kg (P50), length 62 cm (P10), and head circumference 38 cm (<P3). She had microcephaly, generalized hypotonia and some dysmorphism (blepharophimosis, epicanthus, a flat nasal bridge, low-set ears) (Fig. 1). She had no social and visual contact or visual following of objects, and she had not smiled. She could not control her head or sit without support. Her cardiac examination was remarkable for normal S1 and fixed splitting of S2 with grade II/VI systolic ejection murmur. The ophthalmologic examination was normal. The remainder of the physical and neurological examination was unremarkable.

Laboratory investigations were normal (serum lactate, pyruvate, biotinidase levels, urine and blood amino acid chromatography, urinary organic acids). Her cranial magnetic resonance imaging (MRI) showed mild hypoplasia of the corpus callosum. Initial and following interictal EEGs were normal. Echocardiogram was performed and detected secundum atrial septal defect. Abdominal ultrasound revealed no abnormality.

A combination of microcephaly, mild dysmorphic features, developmental delay, and intractable seizures suggested the presence of a chromosomal abnormality. Karyotype analysis was performed from peripheral blood cell culture and GTG banding was applied. The karyotype was 46, XX, r(14) in all cells (Fig. 2).

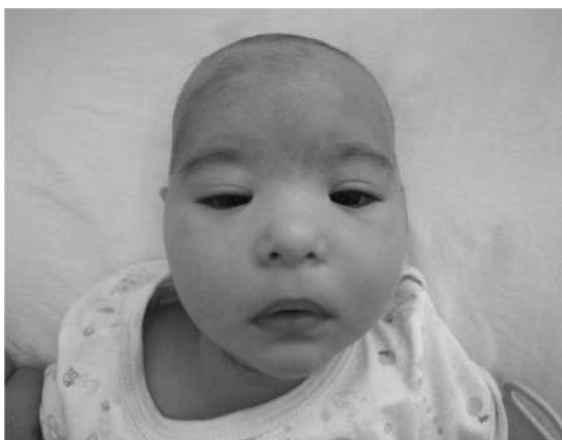

Fig. 1. A 6-month-old girl with a ring chromosome 14 with dysmorphic features. (Permission from the patient's legal guardians was obtained for publishing her image).

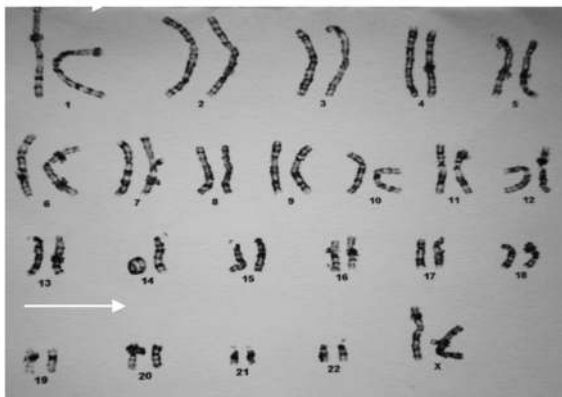


Fig. 2. The karyotype of the patient showing 46, XX, r(14).

Discussion

Ring chromosome 14 syndrome is a rare genetic condition first described by Gilgenkrantz et al. in 1971¹. The main characteristics of this syndrome are a distinctive facial appearance, microcephaly, ocular abnormalities, developmental delay, and drug-resistant epilepsy. Some patients also have congenital heart defects and some have cutaneous pigmentary changes. Some affected individuals have problems with their immune system that lead to recurrent infections, especially involving the respiratory system^{3,4}.

In patients with chromosomal disorders, epilepsy may be seen, and it is often resistant to antiepileptic drugs⁵. Some chromosomal disorders associated with epilepsy are 18q-ter microdeletion syndrome, ring 20 syndrome, and Angelman syndrome⁵⁻⁷. Ring chromosome 14 syndrome is also one of these chromosomal abnormalities in which intractable epilepsy is seen.

In this syndrome, seizures begin in early childhood, typically in the middle of the first year. These seizures have been reported to be of various types, and they may be generalized, partial, or mixed type, mainly originating from the mid-temporal and frontal lobes. Seizures that occur in almost all cases are often drug-resistant^{3,8,9}. Morimoto et al.⁸ reported three patients whose seizures were resistant to common antiepileptic drugs. Zollino et al.³ reported 27 patients with ring chromosome 14 syndrome, and they detected epilepsy in all of them. Guilherme et al.¹⁰ presented a 20-year follow-up on a patient with ring chromosome 14. The patient had seizures, skeletal abnormalities, susceptibility to infections, and retinal pigmentation. His seizures started at 22 months of age, and were drug-resistant at onset but were finally controlled with valproic acid by three years of age. Seizures were frequently intractable and mainly focal, as in our patient. In contrast to the prevalence of generalized seizures described in the early literature, we observed that the epilepsy is predominately focal seizures. It is also possible to recognize a rather typical evolution of epilepsy, which may be empirically divided into three successive stages. In stage 1, epilepsy presents with frequent clusters of seizures sometimes before the development of

other recognizable clinical features. In stage 2, seizure activity is quite stable but intellectual decline and speech problems become evident. In the final stage, epilepsy tends to decrease in severity and frequency of episodes, up to total absence of seizures in some older patients. Further clinical progression does not seem to occur, but cognitive impairment persists at a moderate to severe degree³.

Several hypotheses have been put forward to account for clinical manifestations such as learning disability, epilepsy, and growth retardation in ring chromosome syndromes¹¹: (1) the presence of a susceptibility gene on the q arm, which is deleted during ring formation; (2) a telomere position effect, silencing the genes on the q arm juxtaposed near the p arm telomere; (3) and the silencing of genes as a result of the spreading of the inactivated heterochromatin state of the DNA of the p arm to the adjacent q arm. In ring chromosome 14 syndrome, the telomeric region of the long arm was thought to be a region of interest, because some cases with telomere 14q deletion have characteristics also seen in cases of ring 14 syndrome^{12,13}. Another abnormality of chromosome 14 is trisomy 14. It has been reported in association with myeloid disorders such as myelodysplastic syndrome, myeloproliferative disorders, atypical chronic myeloid leukemia, and acute myeloid leukemia, but is not associated with seizures^{15,16}.

It is reported that most of the patients with ring chromosome 14 syndrome have focal lesions in the central nervous system, like focal cerebral atrophy, and hypoplasia of the corpus callosum¹⁶. We also detected hypoplasia of the corpus callosum in the cerebral MRI in our patient. The mechanisms of hypoplasia of the corpus callosum are still in question.

In conclusion, chromosomal analysis should be performed on children with intractable epilepsy with dysmorphic features especially when no focal lesion is identified on MRI.

REFERENCES

1. Gilgenkrantz S, Cabrol C, Lausecker C, Hartley ME, Bohe B. The Dr syndrome. Study of a further case (46, XX, 14r). *Ann Genet* 1971; 14: 23-31.
2. van Karnebeek CD, Quik S, Sluijter S, Hulsbeek MM, Hoovers JM, Hennekam RC. Further delineation of the chromosome 14q terminal deletion syndrome. *Am J Genet* 2002; 110: 65-72.
3. Zollino M, Ponzi E, Gobbi G, Neri G. The ring 14 syndrome. *Eur J Med Genet* 2012; 55: 374-380.
4. Zollino M, Seminara L, Orteschi D, et al. The ring 14 syndrome: clinical and molecular definition. *Am J Med Genet A* 2009; 149A: 1116-1124.
5. Yamanouchi H, Imataka G, Nakagawa E, et al. An analysis of epilepsy with chromosomal abnormalities. *Brain Dev* 2005; 27: 370-377.
6. Elens I, Vanrykel K, De Waele L, et al. Ring chromosome 20 syndrome: electroclinical description of six patients and review of the literature. *Epilepsy Behav* 2012; 23: 409-14.
7. Minassian BA, DeLorey TM, Olsen RW, et al. Angelman syndrome: correlations between epilepsy phenotypes and genotypes. *Ann Neurol* 1998; 43: 485-493.
8. Morimoto M, Usuku T, Tanaka M, et al. Ring chromosome 14 with localization-related epilepsy: three cases. *Epilepsia* 2003; 44: 1245-1249.
9. Shirasaka Y, Ito M, Okuno T, Fujii T, Nozaki K, Mikawa H. Ring 14 chromosome with complex partial seizures: a case report. *Brain Dev* 1992; 14: 257-260.
10. Guilherme RS, de Freitas Ayres Meloni V, Sodr  CP, et al. Cytogenetic and molecular evaluation and 20-year follow-up of a patient with ring chromosome 14. *Am J Med Genet A* 2010; 152A: 2865-2869.
11. Lippe B M, Sparkes RS. Ring 14 chromosome: association with seizures. *Am J Genet* 1981; 9: 301-305.
12. Elia M, Striano P, Fichera M, et al. 6q terminal deletion syndrome associated with a distinctive EEG and clinical pattern: a report of five cases. *Epilepsia* 2006; 47: 830-838.
13. Ville D, DE Bellescize J, Nguyen MA, et al. Ring 14 chromosome presenting as early-onset isolated partial epilepsy. *Dev Med Child Neurol* 2009; 51: 917-922.
14. Horton YM, Johnson PR. Trisomy 14 in myeloid malignancies: report of two cases and review of the literature. *Cancer Genet Cytogenet* 2001; 124: 172-174.
15. Durmaz B, Karaca E, Vural F, et al. Chronic myelogenous leukemia exhibiting trisomy 14 due to a Robertsonian translocation with Philadelphia chromosome. *Acta Oncol* 2008; 47: 1604-1606.
16. Ono J, Nishiike K, Imai K, Otani K, Okada S. Ring chromosome 14 complicated with complex partial seizures and hypoplastic corpus callosum. *Pediatr Neurol* 1999; 20: 70-72.