

## Robotic abdominal surgery

Eric J. Hanly, M.D.<sup>a,b,c</sup>, Mark A. Talamini, M.D.<sup>a,\*</sup>

<sup>a</sup>*Department of Surgery, The Johns Hopkins University School of Medicine, 600 North Wolfe Street, Blalock 665, Baltimore, Maryland, 21287-4665, USA*

<sup>b</sup>*Department of Surgery, Uniformed Services University of the Health Sciences, Bethesda, Maryland, USA*

<sup>c</sup>*Department of Surgery, Malcolm Grow Medical Center, Andrews Air Force Base, Maryland, USA*

---

### Abstract

As a whole, abdominal surgeons possess excellent videoendoscopic surgical skills. However, the limitations of laparoscopy—such as reduced range of motion and instrument dexterity and 2-dimensional view of the operative field—have inspired even the most accomplished laparoscopists to investigate the potential of surgical robotics to broaden their application of the minimally invasive surgery paradigm. This review discusses data obtained from articles indexed in the MEDLINE database written in English and mapped to the following key words: “surgical robotics,” “robotic surgery,” “robotics,” “computer-assisted surgery,” “da Vinci,” “Zeus,” “fundoplication,” “morbid obesity,” “hepatectomy,” “pancreatectomy,” “small intestine,” “splenectomy,” “colectomy,” “adrenalectomy,” and “pediatric surgery.” A limited subset of 387 publications was reviewed to determine article relevance to abdominal robotic surgery. Particular emphasis was placed on reports that limited their discussion to human applications and surgical outcomes. Included are comments about the initial 202 robotic abdominal surgery cases performed at Johns Hopkins University Hospital (Baltimore, MD) from August 2000 to January 2004. Surgical robotic systems are being used to apply laparoscopy to the surgical treatment of diseases in virtually every abdominal organ. Procedures demanding superior visualization or requiring complex reconstruction necessitating extensive suturing obtain the greatest benefit from robotics over conventional laparoscopy. Whereas advanced surgical robotic systems offer the promise of a unique combination of advantages over open and conventional laparoscopic approaches, clinical data demonstrating improved outcomes are lacking for robotic surgical applications within the abdomen. Outcomes data for surgical robotics are essential given the exorbitant costs associated with the use of these tools. © 2004 Excerpta Medica, Inc. All rights reserved.

Any surgeon who performs laparoscopy and has operated using the da Vinci Surgical System (Intuitive Surgical, Inc., Sunnyvale, CA), or any of a number of its now-defunct competitors, will testify to the advantages that the field of robotics has to offer surgeons and the practice of minimally invasive surgery. The view is spectacular, the movements are intuitive, and, during a case with a long operative time, the chair is like a first-class seat on a transcontinental flight. For 2 specific surgical disciplines, urology and cardiac surgery, surgical robots are proving to be the key to transforming technically challenging open procedures (such as prostatectomy and mitral valve repair) into technically feasible minimally invasive operations [1,2]. But for surgeons scoping the coelom, outcomes data justifying the cost of the now 5-year-old da Vinci Surgical System have thus far been elusive.

Compared with conventional laparoscopy, it seems only

logical that a high-definition, magnified, 3-dimensional view of the operative field and instinctively controlled articulating instruments would enhance surgeon skills and thus provide patients with superior, safer surgery. Robotic abdominal surgery is still a young field, however, and because of their generally excellent conventional videoendoscopic skills, abdominal surgeons have felt less urgency than their urologic and cardiac colleagues to embrace the routine use of these expensive tools. Nevertheless, the limitations of laparoscopy—such as reduced range of motion and instrument dexterity and 2-dimensional view of the operative field—have inspired even some of the most accomplished laparoscopists to investigate the potential of surgical robotics to broaden their application of the minimally invasive surgery paradigm. Robotic surgery is here and is almost certainly here to stay in one form or another [3]. This article therefore addresses how robotics is being used in the abdomen by the gastrointestinal (GI) and endocrine surgeon. Data were obtained from articles indexed in MEDLINE written in English and mapped to the following key words: “surgical robotics,” “robotic surgery,” “robot-

---

\* Corresponding author. Tel.: +1-410-955-0377; fax: +1-410-614-9493.

E-mail address: [talamini@jhmi.edu](mailto:talamini@jhmi.edu)

ics,” “computer-assisted surgery,” “da Vinci,” “Zeus,” “fundoplication,” “morbid obesity,” “hepatectomy,” “pancreatectomy,” “small intestine,” “splenectomy,” “colectomy,” “adrenalectomy,” and “pediatric surgery.” A limited subset of 387 publications was reviewed to determine article relevance to abdominal robotic surgery. Particular emphasis was placed on reports that limited their discussion to human applications and surgical outcomes.

## History

The rise to prominence of surgical robotics in abdominal surgery is occurring as a consequence of 2 phenomena: (1) the demand from surgeons and patients to recapture conventional surgical capability while maintaining a minimum degree of invasiveness, and (2) ongoing technological advances in computer power and robotic engineering.

When laparoscopic cholecystectomy was first reported in 1987, Mouret introduced a truly disruptive technology that quickly revolutionized the field of surgery [4]. However, as desirable as minimally invasive approaches to surgical therapy may be for patients, the methods used to perform such procedures represent a significant step backward with respect to the technology used. In laparoscopy, we have reduced our manual dexterity by trading instruments in our hands with 7 degrees of freedom of motion for ergonomically awkward “chopsticks” with only 4 degrees of freedom. We have introduced a fulcrum (the abdominal wall) that necessitates moving our hands in counterintuitive ways. Moreover, we have distanced our hands from the operative field with long instruments that magnify our natural tremor and reduce our tactile sense and appreciation of force feedback. Finally, we have traded a profoundly natural view of the tissue being manipulated for a flat, ergonomically misplaced, 2-dimensional representation of reality that can be obtained only through the hiring or conscription of additional personnel (to hold the camera).

Concomitant with this surgical “revolution,” Moore’s law—the doubling of the number of transistors on a microprocessor (and thus the doubling of processor speed) approximately every 2 years [5]—has held true for >3 decades, and computer-integrated mechanical labor devices (ie, robots) have proved their utility in large manufacturing fields such as the automotive industry. Simple computer-controlled mechanical devices with nonabdominal applications began to appear in the late 1980s [6], with robots possessing abdominal surgery application potential being developed in the early 1990s [7]. In 1995, a team of researchers from Johns Hopkins University (Baltimore, MD) developed LARS (Laparoscopic-Assisted Robotic System), a robot with integrated force-sensors designed to perform organ retraction during laparoscopic surgery [8]. Computer Motion, Inc. (Goleta, CA; now operated by Intuitive Surgical) produced the first commercially available voice-controlled robotic arm controlling the laparoscopic camera (Au-

tomated Endoscopic System for Optimal Positioning [AESOP]) in 1994 [9]. The 21st century was ushered in with 2 advanced surgical robotic systems, the da Vinci Surgical System and the Zeus robot (Computer Motion).

## Current systems

Commercial production of surgical robots for abdominal surgery has proved to be an extremely difficult market. Although a number of promising robotic systems have reached the end stages of development—such as EndoVia Medical’s (Norwood, MA) Laprotek Surgical System [10]—the majority have seen their companies financially dissolve before the systems could be brought to market. Of the 2 advanced surgical robotic systems with abdominal surgery applicability, only da Vinci remains since the 2003 acquisition of Computer Motion by Intuitive Surgical and the corporate decision to stop production of the Zeus system.

The da Vinci system’s dual-offset video cameras provide a 3-dimensional view of the operative field with adjustable magnification. The console at which the operating surgeon sits contains a viewfinder that displays the 2 camera views on separate monitors directed to right and left eyes. The images are impressively crisp, with very high resolution, and rather than relying on light-polarizing or color-separating technology for the rendering of 3 dimensions, the system takes advantage of the human brain’s natural ability to integrate offset images and produce visual depth. Thus, the view of the operative field, though limited by the narrow angle view of the scope, is as virtually “real” as can be imagined.

In addition to the arm that holds and positions the 3-dimensional camera, the current-model da Vinci robot possesses 3 robotic arms for positioning and control of 3 da Vinci-specific surgical instruments (Fig. 1). The articulating laparoscopic instruments have a complex cable-driven joint at the distal end, which moves with the same 7 degrees of freedom as the human wrist in open surgery (Fig. 2). The digitization of the surgeon’s hand movements on the controls provides the ability to eliminate surgeon tremor and produce motion scaling (up to 5×). The combination of such processing and filtering allows an unparalleled level of operative precision.

A survey of surgeons conducted by our group at the 2003 meeting of the Society of American Gastrointestinal and Endoscopic Surgeons has suggested that the most significant limitation of surgical robotics is the high cost of the technology [11]. A 4-armed da Vinci Surgical System sells for \$1.25 million in 2004 US dollars, and the costs of the annual maintenance contract (10% annually) and the semi-reusable instruments (\$2,000 for a 10-use instrument) add considerable ongoing operating expenses to an already costly initial purchase price. When factoring in all overhead costs, Costi and colleagues [12] have estimated that the use




Fig. 1. Instruments currently available for the da Vinci Surgical System (Intuitive Surgical, Inc., Sunnyvale, CA). (A) Black diamond micro forceps; (B) Cadiere forceps; (C) cautery with spatula; (D) Cichon tissue forceps; (E) DeBakey forceps; (F) PreCise bipolar forceps; (G) ProGrasp forceps; (H) large needle driver; (I) long-tip forceps; (J) permanent cautery hook; (K) Potts scissors; (L) round-tip scissors; (M) round-tooth forceps; (N) scalpel cautery with 15-degree blade; (O) scalpel cautery with Beaver blade; (P) small clip applicator; (Q) ultrasonic shears; and (R) dual-channel laparoscope. (Courtesy of Intuitive Surgical.)

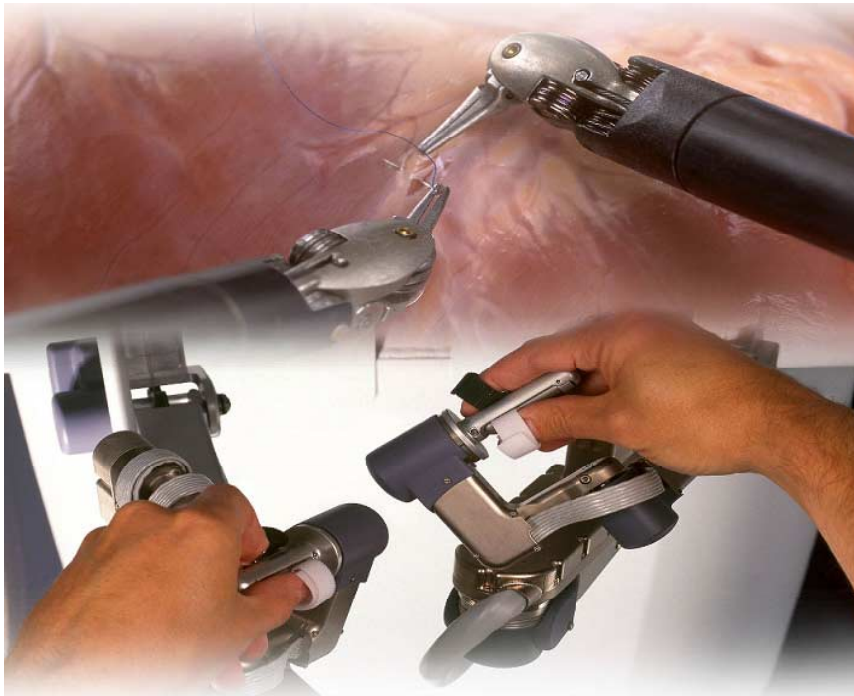


Fig. 2. The da Vinci Surgical System (Intuitive Surgical, Inc., Sunnyvale, CA) translates the movements of the surgeon's hands and wrists into precise laparoscopic instrument movements with 7 degrees of freedom of motion inside the patient. (Courtesy of Intuitive Surgical.)

of the da Vinci robot can add \$2,000 to the cost of an antireflux procedure. Given the paucity of data describing a cost-effective model for the use of such a system, the da Vinci's price tag limits its use primarily to large academic medical centers with a surgical technology research focus. Other limitations of the da Vinci robot include its physical obtrusiveness in the operating room, lack of haptic feedback, and limited teaching capability.

### Clinical applications

Other articles in this supplement address the application of da Vinci, in both experimental and clinical capacities, to

virtually every surgical subspecialty. The remainder of this article, therefore, will focus exclusively on applications of robotics for surgery of the intra-abdominal GI and endocrine systems. Although most published clinical data about surgical robotics are limited to feasibility studies, actual outcomes data will be presented whenever possible.

### *Antireflux surgery*

Antireflux surgery is the only general surgery application of robotics for which class 1 (randomized controlled clinical trial) evidence is available. Two controlled clinical trials have been published comparing robot-assisted Nissen fundoplication with the conventional laparoscopic approach.

Table 1  
The Johns Hopkins Hospital abdominal surgery robotics experience from August 2000 to January 2004 (3.5 years)

Procedure	n	Average operative time (min)	Unplanned conversions	
			Laparoscopic	Open
Antireflux procedure	57	193	1	12
Colon resection	35	177	0	5
Adrenalectomy	30	188	0	0
Small bowel resection	24	150	0	2
Heller myotomy	16	169	1	2
Splenectomy	16	164	0	5
Cholecystectomy	10	99	0	1
Other	14	143	1	1
Total	202	172	3	28

The study by Cadiere and colleagues [13] randomized 21 patients, whereas the study by Melvin and associates [14] enrolled 40 patients (consecutive, but nonrandomized). Both studies used the da Vinci robot, found robotic antireflux surgery to be feasible and comparably safe, encountered longer operative times when using the robot, and found the robotic procedure to be more expensive. Other than a lower rate of postoperative antisecretory medication use among robotically operated patients in the larger study (which was not believed by the authors to actually represent less reflux), no clinical benefit was demonstrated with the use of the robot.

We have performed 57 antireflux procedures with the da Vinci robot at Johns Hopkins University School of Medicine (Table 1) and have experienced findings similar to those of the aforementioned investigators. However, we believe that among our patients with significant hiatal hernias (18 in our series), we are able to perform a technically better repair using the robot than via conventional laparoscopy. Given the high rate of recurrence documented in the literature for surgically repaired hiatal hernias [15], it seems quite plausible that a technically superior repair could translate into lower long-term recurrence for patients. Data to support such a notion will require multi-institutional cooperative randomized trials among robotic groups treating significant numbers of patients with appropriately large hiatal hernias.

### Bariatric surgery

Laparoscopic approaches to bariatric surgery can be extremely challenging. Many bariatric procedures require the construction of multiple enteric anastomoses. Furthermore, the body habitus of the bariatric patient presents unique challenges to a methodology that requires abdominal insufflation and the passage of linear instruments through the abdominal wall. For these reasons, a number of groups have begun exploring the potential role for surgical robotics in bariatrics.

Horgan and Vanuno [16] published the first series of robot-assisted gastric bypasses and gastrojejunostomies in 2001. In 2003, Jacobsen and coworkers [17] published a multi-institutional series of 107 robotically assisted Roux-en-Y gastric bypasses in which the gastrojejunostomies were “hand-sewn.” Outcomes were excellent, with no postoperative leaks and no mortality. One postoperative stricture required dilation, and 4 cases were complicated by improper port placement (3 cases) or mechanical difficulties with a robotic arm (1 case). The authors noted the following benefits when using the robot compared with conventional laparoscopic bariatric surgery: (1) a hand-sewn gastrojejunostomy is significantly easier with the robot; (2) stapling device avoidance is possible with the robot, which eliminates complications due to the nasogastric passage of an anvil; (3) absence of the intraluminal stapler facilitates the construction of a smaller gastric pouch; and (4) the robot affords 2 advantages with respect to increased abdominal wall thickness—stiffer instruments and mechanical power.

### Gallbladder

A number of case series have been published demonstrating the feasibility of robotic laparoscopic cholecystectomy [18–20]. The authors of these studies reported similar findings: compared with historical data for conventional laparoscopic cholecystectomy, operative times are slightly longer (due primarily to the longer set-up time involved when using a robot), and clinical outcomes are equivalent. All authors who use the da Vinci robot appear to be in agreement that the view of ductal anatomy is subjectively superior during robotic cholecystectomy because of the magnified 3-dimensional picture.

It has been well established over time that, although the global transition from open to laparoscopic cholecystectomy has uniformly reduced postoperative pain, hospital length of stay, and return-to-work times for patients, the steady-state rate of bile duct injury is slightly higher in the laparoscopic cholecystectomy era [21]. Most investigators have speculated that this phenomenon is due to inferior instrumentation and visualization of anatomical structures during laparoscopy. Whether the improved dexterity and visualization achieved with an advanced surgical robotic system will translate into a reduction in bile duct injuries will not be known until larger multi-institutional series are published and/or randomized controlled trials are performed. In the meantime, robotic cholecystectomy is likely to remain a very appropriate “practice” operation for general surgeons entering the realm of surgical robotics.

### Liver

Although robotic liver surgery is clearly in its infancy, computer-aided surgical technology offers tremendous potential for advancement of liver resection. Our collaboration with researchers from the Center for Computer Integrated

Surgical Systems and Technology has resulted in the development of a device that allows us to capture the da Vinci's 2 video streams and manipulate them in a myriad of ways (B. C. Herman, E. J. Hanly, N. S. Schenkman, et al, unpublished data). By overlaying these video signals with preoperative and real-time imaging data, we, and other researchers [22], hope to develop systems that will allow surgeons to "see" beyond the surface of the liver to facilitate safe dissection and resection of the hepatic parenchyma.

### *Pancreas*

The first robotic resection of a pancreatic lesion was reported by Melvin and colleagues [23] in 2003. In this case, a neuroendocrine tumor in the tail of the pancreas was removed along with the spleen using the da Vinci robot. This same group has begun work using the robot to perform pancreaticojejunostomy following an open pancreaticoduodenectomy [24]. Giulianotti and associates [25] have reported a series of 8 patients in whom pancreaticoduodenectomies were performed completely laparoscopically with the assistance of the robot. In this advanced technique, the hepaticojejunostomies and gastrojejunostomies were hand-sewn intracorporeally and the remnant pancreatic duct was injected with surgical glue. One death occurred in this small series.

We recently performed an enucleation of an endocrine neoplasm of the body of the pancreas using the robot. In this case, the precise dissection that is achievable with da Vinci allowed us to perform what, at our institution, would normally be a open procedure using a minimally invasive approach. Whether the current-generation surgical robot is advanced enough to allow routine performance of pancreatic head tumor resections remains to be seen. In an operation like the Whipple procedure, where we rely so heavily on blind palpation for careful dissection of the portal vein off the posterior pancreatic surface, it is possible that the da Vinci's lack of haptic feedback may preclude its safe application.

### *Spleen*

We have performed 16 robotically assisted laparoscopic splenectomies. Our experience with this technique has been similar to others [26,27]: the high-definition, magnified, binocular view afforded by the da Vinci system improves our ability to identify vessel architecture and makes it easier to delineate the spleen's relation to the pancreas. Furthermore, we have found that the da Vinci instruments allow subjectively more precise manipulation of the splenic hilum and exposure of the splenic vessels, and that the ultrasonic shears are especially helpful in this dissection despite their lack of wrist articulation. Operative times for this procedure at our institution have ranged from 90 to 240 minutes.

### *Small bowel*

Very little has been published regarding the use of surgical robotics to approach surgical conditions of the small bowel. The 211-patient series published by the Academic Robotics Group [28] and our institution's initial robotic surgery experience [20] includes a small number of small-bowel resection cases. Because of the large number of inflammatory bowel disease patients cared for at our institution, we have performed 24 robotic operations of the small bowel in 3.5 years, including 17 small bowel resections for refractory Crohn disease. We have found that the surgeon's ability to "run" the bowel, hand over hand from one end to the other, with the da Vinci robot greatly facilitates careful inspection of the entire length of small bowel. This is essential in patients with Crohn disease, who may have multiple segments of diseased bowel separated by significant lengths of normal bowel. This technique is made possible by orienting the robot's port sites along the axis of the mesentery (from left upper quadrant to right lower quadrant) with the camera port in either the left lower or right upper quadrant. The robot is also useful for hand-sewing anastomoses and suturing enteric feeding tubes.

### *Colon*

The first 2 robotically assisted laparoscopic colectomies were performed in March 2001 [29]. Since that time, 2 groups have published studies comparing laparoscopic and robotically assisted colon surgery. The study by Delaney and colleagues [30] compared 2 right hemicolectomies, 3 sigmoid colectomies, and 1 proctopexy with appropriately matched laparoscopic controls. The only parameters found to be significantly different between the groups were operative time (57 minutes longer in the robotic group) and cost (\$350 more per robotic case, excluding the overhead associated with the >\$1 million robot purchase and maintenance). In an effort to play to what many believe to be a strength of the da Vinci robot, the British group has focused their robotic colon surgery effort on the pelvis; their use of the robot exclusively for the pelvic dissections in proctopexies, low anterior resections, and abdominoperineal resections has been well described [31]. Recently, a series of 6 robotic nonresection proctopexies were compared with historical laparoscopic controls [32]. Early results (3 to 6 months of follow-up) were promising, with no perioperative morbidity and no recurrent prolapse or constipation (compared with 19% morbidity in the same authors' historical control series). However, only with larger randomized controlled studies will a long-term benefit from the robotic approach be demonstrable.

We have used the robot to assist us in 35 colon resections performed at least partially laparoscopically. Until recently, we have limited laparoscopic colon resection to patients with benign disease; thus, the 2 main indications for surgery in our patients have been recurrent diverticular disease in

appropriately aged patients and polyps that are unresectable intraluminally. Operations in our robotic colon surgery series include cecectomies, right hemicolectomies, left hemicolectomies, sigmoidectomies (in 1 case with proctopexy), and a single total abdominal colectomy in a patient with familial adenomatous polyposis. Our experience corroborates the findings of others [30–33]: robotically assisted laparoscopic colon surgery using the current-generation da Vinci robot is expensive and is useful only in cases that do not require multiquadrant surgery. However, this technique may prove to be of clinical benefit in cases where extensive dissection of the pelvis (especially the narrow male pelvis) is required. Now that data showing the oncologic equivalence of the open and laparoscopic approaches are available [33,34], it appears that robotics may also play a role in shortening the learning curve [35] for surgeons transitioning from open colectomy to laparoscopic colectomy for malignant disease.

#### *Adrenal glands*

A number of published reports describing robotically assisted laparoscopic adrenalectomy exist in the literature [36], but no clinical trials have been performed comparing robotic adrenalectomy with either open or conventional laparoscopic adrenalectomy. However, 1 robotic adrenalectomy was reported by a urologist who did not consider himself a laparoscopic surgeon; thus, the utility of robotic systems to enable nonlaparoscopists to engage in minimally invasive surgery is demonstrated anecdotally in this case [37].

We have performed 30 robotic adrenalectomies without a conversion. The preoperative indications for surgery in our series included 18 adrenal masses, 9 pheochromocytomas, and 3 aldosteronomas. We have found that the da Vinci's enhanced vision system greatly facilitates identification of the small, and often numerous, adrenal vessels. Given the proximity of the right adrenal gland to the vena cava, careful identification and dissection of the short right adrenal vein is essential [38]. Anecdotally, therefore, we have found the robot to be of significant benefit in these cases.

#### *Pediatric surgery*

The application of minimally invasive approaches to pediatric abdominal surgery has been somewhat limited by the inability to perform precise anastomoses of a size small enough for children using conventional laparoscopic instrumentation [39]. With further miniaturization of instruments, application of 3-dimensional high-resolution endoscopic vision, and use of computer-assisted motion scaling and tremor elimination, robotics offers enormous potential for the field of pediatric laparoscopic surgery. One reported series of pediatric robotic surgery cases has been published [40]. In this study of 14 individuals, 11 patients with un-

controlled symptoms of regurgitation and pulmonary infection underwent robotically assisted fundoplication, 2 patients underwent robotically assisted cholecystectomy for symptomatic cholelithiasis, and 1 patient with a gonadal tumor underwent bilateral salpingo-oophorectomy. The da Vinci robot was used in all cases. The authors concluded that robotic pediatric surgery is feasible, but that smaller instrumentation and reduced costs are needed before routine pediatric robotic surgery can become a reality.

#### **Future of robotic abdominal surgery**

Many consider the current da Vinci Surgical System to be an excellent "rough draft." It has certainly given back to surgeons much of what we lost at the beginning of the laparoscopic surgery era—including intuitive instrument control and depth perception—but a number of significant limitations hamper the wide adoption of this tool in its current form.

Although clinical data demonstrating clinical efficacy for advanced surgical robots are lacking, available information suggests that the most significant current impediment to the adoption of robotic abdominal surgery is cost [11]. In fact, nearly 75% of surgeons polled in our survey indicated that systems priced >\$500,000 would not be financially viable in their practices. The Laprotek robot (known early on as the Brock-Rogers robot) manufactured by the now-bankrupt EndoVia Medical had promised to offer advanced surgical robotics at a quarter of the cost of da Vinci [10,41]. Nevertheless, there certainly appears to be a relatively high-volume market for a lower-cost surgical robot.

One advantage of the now-shelved Zeus robot was its table-mounted, modular, and compact form. In contrast, the da Vinci robot is a single, large, floor-mounted machine. The large "footprint" of da Vinci makes patient positioning after robot deployment difficult, limits tableside assistant access to the patient, and creates unique challenges for the anesthesia team [42]. Given military medicine's interest in surgical robotics for future telesurgery applications, it is essential that future surgical robot design engineers construct a more portable and flexible machine if they are to meet the needs of these important customers.

Although the high-quality 3-dimensional vision system of da Vinci does make up for some of the precision, dexterity, and safety lost without haptics [43], a number of situations occur during robotic cases that make the lack of sensory feedback a significant drawback (eg, inadvertent breaking of suture during knot tying, iatrogenic organ injury from instruments during transitory "off camera" time) [44]. Although some engineers still consider haptics the "holy grail" of robotics, progress in this area is being made. In the meantime, alternative solutions exist that are being applied in the research setting. At Johns Hopkins, researchers have provided evidence that visual sensory substitution may permit surgeons to apply more consistent, precise, and greater

tensions during operative tasks without exceeding potentially harmful force thresholds [45].

In the current safety-minded, simulator-dependent aviation industry, aircraft design and respective simulator design often occur concurrently. In this way, pilots can be ready to fly new planes before the aircraft are even certified for public use. Furthermore, difficult and dangerous scenarios can be practiced in a low-stakes environment. Future design of surgical robots should incorporate the learning needs of surgeons and surgeons in training. It is our hope that a driver-education-type console will soon be developed for the da Vinci robot that will facilitate graduate medical education and continuing medical education for this tool.

Because all information exchanged between surgeon and patient during robotic surgery is digitized, surgical robotics has also ushered in the era of telesurgery. On September 7, 2001, Marescaux and colleagues from the European Institute of Telesurgery (IRCAD)/Louis Pasteur University in Strasbourg, France, performed the first transatlantic telerobotic laparoscopic cholecystectomy using the Zeus robot [46,47]. Anvari [48] has since used a similar model to perform advanced laparoscopic surgery from Hamilton, Ontario, on a number of patients in rural areas of northern Canada. A number of technical, legal, economic, and social factors currently prevent pervasive adoption of routine telesurgery, but it is clear that surgical robotics will have a significant impact on the way we practice surgery—even with respect to aspects of surgery as fundamental as the physician-patient relationship.

Finally, the potential associated with integration of patient imaging information into surgical robotics platforms is staggering. Overlaying preoperative and real-time image data on the surgeon's view of the operative field may soon allow surgeons to operate where their view is obscured, just as pilots today can fly through clouds with no visibility. Computed tomography and other imaging modalities are now routinely reconstructed in 3 dimensions. Because robots are capable of "knowing" where they are at all times in 3-dimensional space, the melding of data describing patient anatomy and robot position creates the potential for virtual surgery wherein surgeons may be able to "practice" a particular patient's operation until they find the best procedure for that individual patient [49].

## Summary

Advancements in technology are clearly changing the way we practice abdominal surgery. In the past 15 years, we have transitioned from open surgery to laparoscopic surgery, to robotic camera operation, to robotic surgery, and finally to telerobotic surgery. Thus, while it is clear that surgical robotics has not yet arrived at a level of refinement necessary to become commonplace in the operating room, if history can help predict the future, it is only a matter of time. Surgical robots will become smaller, less expensive,

able to provide force feedback, and capable of routine operation over telecommunication networks. Just as conventional laparoscopic surgery is proving to be a transitional technology, the current generation of surgical robots will likely yield to a breed of advanced machines with clear clinical advantages that are obvious to everyone [50]. In the meantime, we must do the due diligence, conduct the clinical trials for appropriate procedures, and obtain the outcomes data necessary to convince or silence the critics of robotic abdominal surgery.

## References

- [1] Menon M, Tewari A, Baize B, Guillonau B, Vallancien G. Prospective comparison of radical retropubic prostatectomy and robot-assisted anatomic prostatectomy: the Vattikuti Urology Institute experience. *Urology* 2002;60:864–8.
- [2] Tatooles AJ, Pappas PS, Gordon PJ, Slaughter MS. Minimally invasive mitral valve repair using the da Vinci robotic system. *Ann Thorac Surg* 2004;77:1978–82.
- [3] Talamini MA. Surgery of the 21st century. *Ann Surg* 2001;234:8–9.
- [4] Mouret P. How I developed laparoscopic cholecystectomy. *Ann Acad Med Singapore* 1996;25:744–7.
- [5] Moore GE. Cramming more components onto integrated circuits. *Electronics* 1965;38:114–7.
- [6] Kwoh YS, Hou J, Jonckheere EA, et al. A robot with improved absolute positioning accuracy for CT guided stereotactic brain surgery. *IEEE Trans Biomed Eng* 1988;35:153–61.
- [7] Satava RM. Surgical robotics: the early chronicles: a personal historical perspective. *Surg Laparosc Endosc Percutan Tech* 2002;12:6–16.
- [8] Taylor RH, Funda J, Eldridge B, et al. A telerobotic assistant for laparoscopic surgery. *IEEE Eng Med Biol* 1995;14:279–87.
- [9] Jacobs LK, Shayani V, Sackier JM. Determination of the learning curve of the AESOP robot. *Surg Endosc* 1997;11:54–5.
- [10] Franzino RJ. The Laprotek surgical system and the next generation of robotics. *Surg Clin North Am* 2003;83:1317–20.
- [11] Hanly EJ, Zand J, Bachman SL, Marohn MR, Talamini MA. Value of the SAGES learning center in introducing new technology. *Surg Endosc* (in press).
- [12] Costi R, Himpens J, Bruyns J, Cadiere GB. Robotic fundoplication: from theoretic advantages to real problems. *J Am Coll Surg* 2003; 197:500–7.
- [13] Cadiere GB, Himpens J, Vertruyen M, et al. Evaluation of telesurgical (robotic) Nissen fundoplication. *Surg Endosc* 2001;15:918–23.
- [14] Melvin WS, Needleman BJ, Krause KR, Schneider C, Ellison EC. Computer-enhanced vs. standard laparoscopic antireflux surgery. *J Gastrointest Surg* 2002;6:11–6.
- [15] Hashemi M, Peters JH, DeMeester TR, et al. Laparoscopic repair of large type III hiatal hernia: objective follow up reveals high recurrence rate. *J Am Coll Surg* 2000;190:553–60.
- [16] Horgan S, Vanuno D. Robots in laparoscopic surgery. *J Laparoendosc Adv Surg Tech A* 2001;11:415–9.
- [17] Jacobsen G, Berger R, Horgan S. The role of robotic surgery in morbid obesity. *J Laparoendosc Adv Surg Tech A* 2003;13:279–83.
- [18] Cadiere GB, Himpens J, Gernay O, et al. Feasibility of robotic laparoscopic surgery: 146 cases. *World J Surg* 2001;25:1467–77.
- [19] Marescaux J, Smith MK, Folscher D, et al. Telerobotic laparoscopic cholecystectomy: initial clinical experience with 25 patients. *Ann Surg* 2001;234:1–7.
- [20] Talamini M, Campbell K, Stanfield C. Robotic gastrointestinal surgery: early experience and system description. *J Laparoendosc Adv Surg Tech A* 2002;12:225–32.

- [21] Wherry DC, Marohn MR, Malanoski MP, Hetz SP, Rich NM. An external audit of laparoscopic cholecystectomy in the steady state performed in medical treatment facilities of the Department of Defense. *Ann Surg* 1996;224:145–54.
- [22] Marescaux J, Solere L. Image-guided robotic surgery. *Semin Laparosc Surg* 2004;11:113–22.
- [23] Melvin WS, Needleman BJ, Krause KR, Ellison EC. Robotic resection of pancreatic neuroendocrine tumor. *J Laparoendosc Adv Surg Tech A* 2003;13:33–6.
- [24] Melvin WS. Minimally invasive pancreatic surgery. *Am J Surg* 2003;186:274–8.
- [25] Giulianotti PC, Coratti A, Angelini M, et al. Robotics in general surgery: personal experience in a large community hospital. *Arch Surg* 2003;138:777–84.
- [26] Hashizume M, Shimada M, Tomikawa M, et al. Early experiences of endoscopic procedures in general surgery assisted by a computer-enhanced surgical system. *Surg Endosc* 2002;16:1187–91.
- [27] Chapman WH III, Albrecht RJ, Kim VB, Young JA, Chitwood WR Jr. Computer-assisted laparoscopic splenectomy with the da Vinci surgical robot. *J Laparoendosc Adv Surg Tech A* 2002;12:155–9.
- [28] Talamini MA, Chapman S, Horgan S, Melvin WS, for the Academic Robotics Group. A prospective analysis of 211 robotic-assisted surgical procedures. *Surg Endosc* 2003;17:1521–4.
- [29] Weber PA, Merola S, Wasielewski A, Ballantyne GH. Telerobotic-assisted laparoscopic right and sigmoid colectomies for benign disease. *Dis Colon Rectum* 2002;45:1689–94.
- [30] Delaney CP, Lynch AC, Senagore AJ, Fazio VW. Comparison of robotically performed and traditional laparoscopic colorectal surgery. *Dis Colon Rectum* 2003;46:1633–9.
- [31] Rockall TA, Darzi A. Robot-assisted laparoscopic colorectal surgery. *Surg Clin North Am* 2003;83:1463–8.
- [32] Munz Y, Moorthy K, Kudchadkar R, et al. Robotic assisted resection. *Am J Surg* 2004;187:88–92.
- [33] Lacy AM, Garcia-Valdecasas JC, Delgado S, et al. Laparoscopy-assisted colectomy versus open colectomy for treatment of non-metastatic colon cancer: a randomised trial. *Lancet* 2002;359:2224–9.
- [34] Clinical Outcomes of Surgical Therapy Study Group. A comparison of laparoscopically assisted and open colectomy for colon cancer. *N Engl J Med* 2004;350:2050–9.
- [35] Prasad SM, Maniar HS, Soper NJ, et al. The effect of robotic assistance on learning curves for basic laparoscopic skills. *Am J Surg* 2002;183:702–7.
- [36] Desai MM, Gill IS, Kaouk JH, Matin SF, Sung GT, Bravo EL. Robotic-assisted laparoscopic adrenalectomy. *Urology* 2002;60:1104–7.
- [37] Bentas W, Wolfram M, Brautigam R, Binder J. Laparoscopic transperitoneal adrenalectomy using a remote-controlled robotic surgical system. *J Endourol* 2002;16:373–6.
- [38] Young JA, Chapman WHH, Kim VB, et al. Robotic-assisted adrenalectomy for adrenal incidentaloma: case and review of the technique. *Surg Laparosc Endosc Percutan Tech* 2002;12:126–30.
- [39] Lanfranco AR, Castellanos AE, Desai JP, Meyers WC. Robotic surgery: a current perspective. *Ann Surg* 2004;239:14–21.
- [40] Gutt CN, Markus B, Kim ZG, Meininger D, Brinkmann L, Heller K. Early experiences of robotic surgery in children. *Surg Endosc* 2002;16:1083–6.
- [41] Hanly EJ, Bachman SL, Zand J, Marohn MR, Talamini MA. Robotic task metrics: a diverse assessment [abstract]. *Surg Endosc* 2004;18(Suppl):S279.
- [42] Parr KG, Talamini MA. Anesthetic implications of the addition of an operative robot for endoscopic surgery: a case report. *J Clin Anesth* 2002;14:228–33.
- [43] Jourdan IC, Dutson E, Garcia A, et al. Stereoscopic vision provides a significant advantage for precision robotic laparoscopy. *Br J Surg* 2004;91:879–85.
- [44] Hanly EJ, Marohn MR, Bachman SL, et al. Multiservice laparoscopic surgical training using the da Vinci surgical system. *Am J Surg* 2004;187:309–15.
- [45] Bethea BT, Okamura AM, Kitagawa M, et al. Application of haptic feedback to robotic surgery. *J Laparoendosc Adv Surg Tech A* 2004;14:191–5.
- [46] Marescaux J, Leroy J, Gagner M, et al. Transatlantic robot-assisted telesurgery. *Nature* 2001;413:379–80.
- [47] Marescaux J, Leroy J, Rubino F, et al. Transcontinental robot-assisted remote telesurgery: feasibility and potential applications. *Ann Surg* 2002;235:487–92.
- [48] Anvari M. Robot-assisted remote telepresence surgery. *Semin Laparosc Surg* 2004;11:123–8.
- [49] Marohn MR, Hanly EJ. 21st century surgery using 21st century technology: surgical robotics. *Curr Surg* (in press).
- [50] Talamini MA. Overview—current clinical and preclinical use of robotics for surgery. *J Gastrointest Surg* 2003;7:479–80.