

# Role of Distorted Body Image in Pain

*Martin Lotze, MD, and G. Lorimer Moseley, PhD*

---

## Corresponding author

G. Lorimer Moseley, PhD  
Department of Physiology, Anatomy and Genetics,  
Pain Imaging Neuroscience Group, University of Oxford,  
Le Gros Clark Building, South Parks Road, Oxford OX1 3QX, UK.  
E-mail: lorimer.moseley@medsci.ox.ac.uk

**Current Rheumatology Reports** 2007, **9**:488–496  
Current Medicine Group LLC ISSN 1523-3774  
Copyright © 2007 by Current Medicine Group LLC

Body image is the way a person's body feels to them. Growing evidence shows that body image can be distorted in people with pain, particularly chronic pain. Most data relate to people with deafferentation via amputation or neural injury, but deafferentation is neither sufficient nor necessary for distorted body image or pain. In this review, we examine the literature relating to body image distortion in people with pain, and we discuss three themes: 1) evidence of distorted body image in people with pain; 2) evidence of distortion of the neural representations of body image held in primary sensory and primary motor cortex; and 3) clinical findings that correlate with distorted body image, distorted neural representation, or both. We then review the emerging evidence regarding therapeutic approaches to distorted body image in people with painful disease.

## Introduction

### Defining body image

In order to discuss body image and pain, we must first clarify the term “body image,” which is a complex task, as it is used in many different ways. First, we examine how the term is used elsewhere and then explain how we define it here.

A very large body of academic and lay literature uses the term “body image” to define how an individual perceives the physical appearance of their own body. Thus, in this sense, body image measures how closely one's perception of their physical appearance matches their ideal. Therefore, it is highly dependent on the individual's idea of perfection, a construct built on complex psychosocial variables. This idea of body image has been mentioned with regard to pain [1] and discussed anecdotally as it refers to some people with complex regional pain syndrome (CRPS) [2•], but it is not the subject of this review.

From a sensorimotor perspective, body image often refers to the implicit maps that encode the position, movement, and

anthropometric characteristics of the body that are the basis for motor commands. Therefore, this notion of body image is not an explicit or conscious construct. It is integral to one as yet unsubstantiated theory relating to pain [3], which we mention later, but we do not use this definition of body image.

From a homeostasis perspective, body image has been used to define both the capacity for the body to monitor its own internal state (interoception) and the neural maps that are thought to represent that physical state. This notion of body image has also been mentioned with regard to pain, in particular with regard to the interoceptive function of small diameter peripheral neurons [4], but again, this notion of body image is not the subject of this review.

In this review, we define body image as the way one's body feels to its owner. Like pain, it is necessarily conscious. It is probably important in sensorimotor control, but it may involve neural networks distinct from those used for motor commands. Body image is thought to be maintained by ongoing tactile, proprioceptive, and visual input. It can be modulated by memory, belief, and psychosocial factors, and it is reasonably labile. The extent to which and the speed with which different inputs influence body image varies. For example, a blindfolded subject can quickly get the feeling that their nose is getting longer by tapping a nose situated at arm's length while simultaneously receiving an identical tap on their own nose. Also, consider the swollen lip you felt you had last time you went to the dentist. Formal investigations have been conducted of such body image distortion during tendon vibration and following anesthesia, neurosurgery, and electrical stimulation [5,6,7•,8]. However, in most cases, body image distortion resolves when the stimulus is removed.

To review body image within the context of pain in general and painful disease in particular, we adopt three themes. First, we discuss evidence that people in pain report a distorted body image. Second, we discuss evidence that painful disease is associated with the disruption of the neural correlates of body image. Third, we discuss clinical findings consistent with distortions of the body image, distortions of the neural correlates of body image, or both. We complete this review by briefly discussing therapeutic strategies to rectify one or more of the above and the effect of those strategies on pain and function in people with painful disease.

### People in Pain Report Distorted Body Image

Distortions of body image are thought to be common in some pain states, perhaps none as obvious as phantom limb pain.

About 80% of amputees experience phantom limb pain; most of them describe it as moderate or severe and somewhat or extremely bothersome [9]. In about 40% of amputees, phantom limb pain rather than impairment renders them completely disabled [10]. In addition to pain, many amputees with phantom limb pain report that their missing limb feels heavy, swollen, floating, stuck in a particular position, missing digits or entire segments (“telescoping”) [11], or stiff [12]. Unfortunately, incidence and prevalence data are incomplete and little is known about the relationship between distorted body image and pain. Because similar distortions of body image are not uncommon after parietal infarction, in which case they are only sometimes accompanied by pain [13,14], researchers have assumed that body image distortions result from sensory deprivation and that pain results from neural injury. However, recent observations in conditions involving neither sensory deprivation nor neural injury suggest the need for reconsideration of this assumption: deafferentation is neither sufficient nor necessary for distorted body image or pain.

CRPS is a disease in which peripheral sensory input appears fully intact, cortical injury is very unlikely, and neural injury cannot be identified. However, patients with CRPS often describe their limb as swollen when it is not. When asked to select one of a number of photographs of the affected and opposite limb, patients with CRPS tend to select a photograph that depicts the affected limb to be bigger than it really is [15], and when asked to resize a photograph of both limbs to its correct dimensions, they tend to settle on an image approximately 106% of its original size (Moseley, unpublished data). In addition to distortions of the size of the painful limb, some patients report distortion of its shape, such that they might describe the painful limb as being too short or missing a segment. Some patients reported that they find it difficult to determine the position of the limb without looking at it, and some patients report that it feels as if it is in one position even though it is actually in another [16].

Data about distorted body image in other pain states are lacking. In our experience, patients with spinal pain can report that their back feels swollen when it does not appear to be. More commonly, however, patients report difficulty in feeling their back (ie, they have difficulty “locating” it). To our knowledge, such distortions of body image have not been formally investigated in patients with spinal pain, but several studies touch on this issue by way of assessing proprioceptive acuity. For example, patients with back pain have difficulty in matching postures on the basis of watching someone else model the posture [17] and in returning to set postures on the basis of proprioceptive feedback [18]. Asell et al. [19] present an alternative view.

### Cortical Representation of Body Image Becomes Distorted in Some Pain States

The physical body is probably represented many times throughout the central nervous system. The most studied representations of the physical body are those held in the

primary (S1) and secondary (S2) somatosensory cortices and in the primary motor cortex (M1). Because activity in S1 and S2 is thought to be important for the consciously felt body (ie, for the notion of body image defined within this review), and because S1 and M1 are functionally closely linked, this section focuses on these brain areas and their role within the cerebral pain network.

### Somatosensory and motor cortices, part of the cerebral pain network

The cerebral representation of pain can be considered to consist of two neural networks: one representing the discriminative dimension of pain and one representing the affective dimension of pain. Although oversimplistic, this model is useful when considering neural correlates of body image. Neurons in S1 and S2 would be considered part of the discriminative network. Neurons in the anterior cingulate cortex, insula (predominantly the anterior regions), ventral prefrontal lobe, amygdala, and adjacent hippocampus would be considered part of the affective (or affective-motor [20]) dimension.

S1 and M1 probably hold the most precise representations of the body. They are tightly connected and are functional entities for movement control and execution. This somatotopic representation is thought to be maintained by lateral cortical inhibition, whereby input from a particular body part exerts an excitatory influence on its target S1 neurons and an inhibitory influence on neurons in adjacent representations. The likely biochemical candidate for this mechanism seems to be the GABAergic system [21].

### Cortical reorganization without pain or pathology

Cortical representation behaves according to the “use it or lose it” principle: training expands the S1 representation of the trained area and deafferentation by regional anesthesia can shrink it [22]. Braun et al. [23] used source localization with magnetoencephalography of digits 1 (thumb) and 5 (little finger) before and after a somatosensory discrimination training and found segregation of S1 representation between the fingers. In contrast, a stimulation-alone condition led to functional integration of the two-finger representations in S1.

Later, the same group demonstrated that the S1-representation of the fingers changed dynamically in reference to the context in which the fingers are used [24]. Thus, S1 representation seems responsive to motor training as well as sensory training. According to the proposed mechanism of cortical representations—that of ongoing and competitive lateral inhibition—increased input should inhibit nearby representations, thus expanding the receptive field of the former and reducing the receptive field of the latter [25]. Conversely, loss of this inhibitory control seems to lead previously silent thalamocortical projections to become active, which expands the receptive field of the intact representations and reduces that of the disengaged representations [21].

Although elegant, this model may be overly simplistic. Exceptions can be observed when increased sensory input seems to lead to reduced [26] or unchanged receptive fields. Nonetheless, attention to the sensory input or a behavioral objective associated with sensory input or motor output is important in evoking changes in cortical representation [22].

### Painful disease is associated with changes in cortical representation

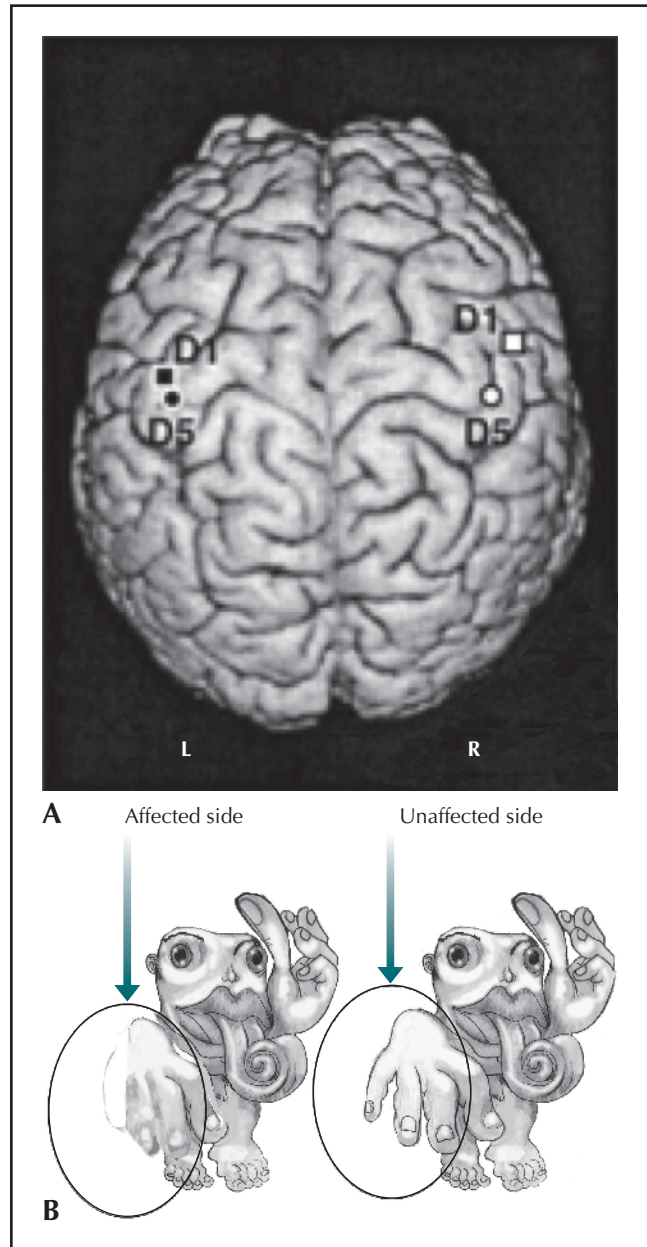
#### *Phantom limb pain*

Microelectrode studies in animals provided the first robust data concerning changes in cortical organization after amputation. For example, amputation of digits in an adult owl monkey led to an invasion of adjacent areas into the cortical representation zone of the deafferented fingers [27]. The larger the area deafferented, the greater the cortical reorganization: deafferentation of the entire dorsal root led to the cheek representation taking over the cortical arm and hand representation, a shift of several centimeters [28]. These animal studies have been largely replicated in humans who have sustained amputations. Imaging studies have reported that upper limb amputees show a shift of the mouth into the hand representation in S1 [23,30] (Fig. 1).

A case study of a patient with a traumatic upper limb amputation, in whom the authors mapped S1 and M1 during craniotomy, corroborate this pattern of effect. When the deafferented motor cortex was stimulated (ie, the M1 hand representation), shoulder movements were elicited; when S1 representation of the shoulder was stimulated, the patient reported sensation in the hand and arm as well as the shoulder [31]. Further imaging studies have demonstrated that the extent of S1 reorganization relates to the intensity of phantom limb pain [32•].

M1 reorganization also occurs after deafferentation. Using transcranial magnetic stimulation, Cohen et al. [33] showed larger contralateral M1 representation sites, larger motor evoked potentials, and a larger percentage of motor neuron pool activation on the affected side than on the intact side. Kew et al. [34] used positron emission tomography and transcranial magnetic stimulation and reported greater regional cerebral blood flow in the deafferented M1 than the intact M1 during paced shoulder movements. Pascual-Leone et al. [35] reported an enlargement of the contralateral M1 representational maps of the lower face muscles and the biceps in a patient who underwent a traumatic arm amputation at the height of the middle upper arm.

More recently, researchers have investigated the relationship between M1 reorganization and pain. Some report a close relationship. For example, Karl et al. [36] observed larger motor-evoked potentials from the biceps brachii and greater shift in M1 representation of ipsilateral face muscles in forearm amputees with phantom limb pain, than in those without phantom limb pain. Functional MRI group analysis corroborates this differential



**Figure 1.** A, Reorganization of the somatic representation of the affected body part in a patient with unilateral complex regional pain syndrome of the upper limb. The location of the response in primary somatosensory cortex (S1) to stimulation of the thumb (D1) and little finger (D5) on the affected (*filled shapes, right upper limb, represented in left S1*) and unaffected (*open shapes*) sides. Notice that representation of the hand is smaller on the affected side than on the unaffected side. (From Juottonen et al. [41], with permission.) B, Artist's impression of S1 and M1 reorganization showing a schematic version of the homunculus for a normal healthy right hand (*right*) and the right hand of someone with chronic hand pain (*left*). (From Butler and Moseley [77], with permission.)

effect [37] and shows reorganization is reduced by usage of a myoelectrical prosthesis [38]. Thus, even without a limb, “use it or lose it” seems to hold.

One assumption that underpins interpretation of the above studies is that invasion from a nearby repre-

sensation implies shrinkage of the representation of the deafferented area. One way to avoid this assumption is via motor imagery, which involves the same cortical networks as executed movements [39]. Imaging studies of amputees performing imagined movements corroborate the previous findings: they show activation of M1 representation of the neighboring face area, but in amputees without phantom limb pain, M1 activation is confined to the normal limb representation area [37].

#### *Complex regional pain syndrome*

CRPS affects about 5% of the patients after limb trauma [40] and leads to chronic limb pain usually associated with sensory, motor, and autonomic dysfunctions. S1 reorganization in CRPS is similar to that observed for phantom limb pain: decreased representational area in S1 of the affected part, which correlates with pain intensity [41] (Fig. 1). S1 reorganization normalizes when CRPS resolves [42]. Researchers have observed reorganization of M1 in CRPS [43], and they have reported functional changes consistent with motor disinhibition [44]. Although such distortions of the neural correlates of body image are related to pain, no evidence exists that they cause or are caused by pain.

#### *Spinal cord injury*

Although several parallels exist between spinal cord damage and deafferentation, and between peripheral deafferentation and damage, they seem to evoke different cortical effects. Spinal cord injury (SCI) results in both nonpainful and painful phantom sensations. Severe pain syndromes are present in approximately 20% of spinal cord-injured patients [45], but those with and without pain demonstrate displacement of movement representation. After SCI, M1 reorganization correlates with clinical and demographic findings such as the level of injury, the severity of injury (in incomplete SCI), and the time at which a complete SCI is present [46,47]. Patients with chronic SCI show more cortical reorganization of areas adjacent to the deafferented region than those with acute SCI. We observed an average shift of elbow movement representation maxima of more than 18 mm [46].

#### *Low back pain*

There are limited data concerning cortical organization in patients with back pain. One study suggested that the back representation in S1 in response to painful stimulation is more medial in patients with back pain than in controls, and that pain intensity relates to the extent representational shift ( $r = 0.74$ ) [48]. The authors interpreted this dipole-shift as an enlargement of the representation area of the painful back. The phenomenon of increased somatosensory response amplitude seems ubiquitous in patients suffering from chronic pain, whereas the increase or decrease of representation areas might be related to immobilization and attentional factors. However, data are lacking.

#### **Possible mechanisms of changes in the neural correlates of body image in pain states**

In healthy subjects, training, deafferentation, and immobilization can all evoke cortical reorganization. Essentially, the same processes are thought to occur in pain states. For example, abnormal ongoing input from peripheral neuropathy increases S1 representation of the affected area [49]; selective loss of C-fibers, which occurs after amputation, might drive the decrease in S1 representation [50]; and reorganization of the thalamus [51] and changes in the strength of the thalamocortical loops might cause S1 reorganization [52]. Regardless of contributing factors, a change in intracortical inhibition is probably the common mechanism. This may involve unmasking of latent excitatory synapses via increased release of excitatory neurotransmitters, increased density of postsynaptic receptors, changes in conductance of the neuronal membrane, decreased inhibitory inputs, or the removal of inhibition from excitatory inputs [53]. GABAergic systems are probably key and may involve the entire contralateral hemisphere [37,54]. Finally, structural changes may occur via axonal sprouting, and use-dependent plasticity might lead to additional changes based on Hebbian learning and long-term potentiation [24].

Currently, no evidence seems to show that cortical reorganization causes pain, although it is possible. However, emerging evidence exists to suggest that pain may enhance cortical reorganization. That position is supported by findings that patients with amputation of a limb without phantom limb pain also show marked alterations of the cortical representation maxima [55], but this reorganization increases in line with phantom limb pain [56]. The fact that motor and sensory excitability is enhanced (or inhibition is inhibited) lends further support. For example, amputees with phantom limb pain demonstrate larger M1 representation sites, larger motor-evoked potentials, and a larger percentage of motor neuron pool activation on the affected side than the intact side. Perhaps this increased excitability enhances cortical reorganization processes in S1 and M1, as it is observed in experimentally induced increased excitability [57]. Data from animal studies suggest underlying reorganization processes are likely due to cortical rather than subcortical mechanisms [58], which suggests that the increased cortical excitability found in pain patients [59,60] may help drive cortical reorganization. This finding might explain the rapid normalization of S1 organization when pain is eliminated [61].

#### **Quantifiable Clinical Findings Consistent with Distortions of Body Image, Neural Correlates of Body Image, or Both Mislocalization of tactile stimuli**

Accurate perception of tactile stimuli relies on an intact body image. In patients with chronic pain, tactile perception can be disrupted in two ways: mislocalization of tactile stimuli

and reduced tactile acuity. Mislocalization has been reported in patients with CRPS. For example, a single stimulus delivered to the affected upper limb of a patient with CRPS could evoke sensation at other points on that limb [62]. Notably, Maihofner et al. [62] reported a positive relationship between the extent of mislocalization and mechanical hyperalgesia. In some patients with CRPS, tactile stimuli can be referred to remote locations. For example, stimuli applied to the affected hand can also evoke sensation on the ipsilateral face, although no relationship seems to exist between the extent of mislocalization and pain intensity [63].

Finally, tactile stimuli applied to the contralateral limb can evoke sensation in the affected limb if the patient looks at the reflected image of the contralateral limb being touched [64]. This clinical phenomenon, called dysynchronia, depends on visual input. Therefore, it may depend on enhanced sensitivity of the neural network that subserves pain to input from bimodal visuotactile neurons, rather than on reorganization of centrally held somatotopies.

Mislocalization of tactile stimuli has also been reported in amputees with phantom limb pain. Although mislocalization of tactile stimuli is common in healthy subjects when the adjacent area is anesthetized [27], mislocalization of tactile stimuli occurs when stimuli are delivered to the neurally intact stump of amputees. These patients report a sensation either elsewhere on the stump, proximal to the stump, or, in the case of upper limb amputees, on the face [65]. The extent of mislocalization relates to both pain intensity and the extent to which the S1 representation of the lip has invaded that of the missing limb [66]. The pattern of cortical reorganization and mislocalization is similar in patients with phantom limb pain and patients with CRPS. Acerra et al. [67] presented a review of commonalities between these groups.

### Reduced tactile acuity

Reduced tactile acuity is often assessed by two-point discrimination (TPD) threshold, or the distance between two points at which the subject perceives two stimuli instead of one. Increased TPD reflects decreased tactile acuity. TPD on the stump of amputees is larger in those with phantom limb pain than in those without phantom limb pain. TPD correlates with pain and with the extent to which S1 representation of the lip has invaded that of the missing limb [56]. In CRPS, TPD is larger on the affected limb than on the unaffected limb, and the difference between limbs relates to pain intensity and the reduction in S1 representation of the affected limb (Moseley, unpublished data) [28,68,69]. In patients with unilateral back pain, TPD is larger on the painful side than on the nonpainful side. In patients with bilateral back pain, TPD on the back is larger than that of healthy control subjects. In both cases, TPD relates to pain intensity (Moseley, unpublished data).

These data have important clinical implications. First, TPD seems a reasonable and fairly simple clinical assessment to provide insight into the likely state of S1. Second, S1 organization can be improved via training. Third, if

body image relates to pain, treating body image may reduce pain, and treating pain may normalize body image.

### Therapeutic Approaches Targeting Distorted Body Image

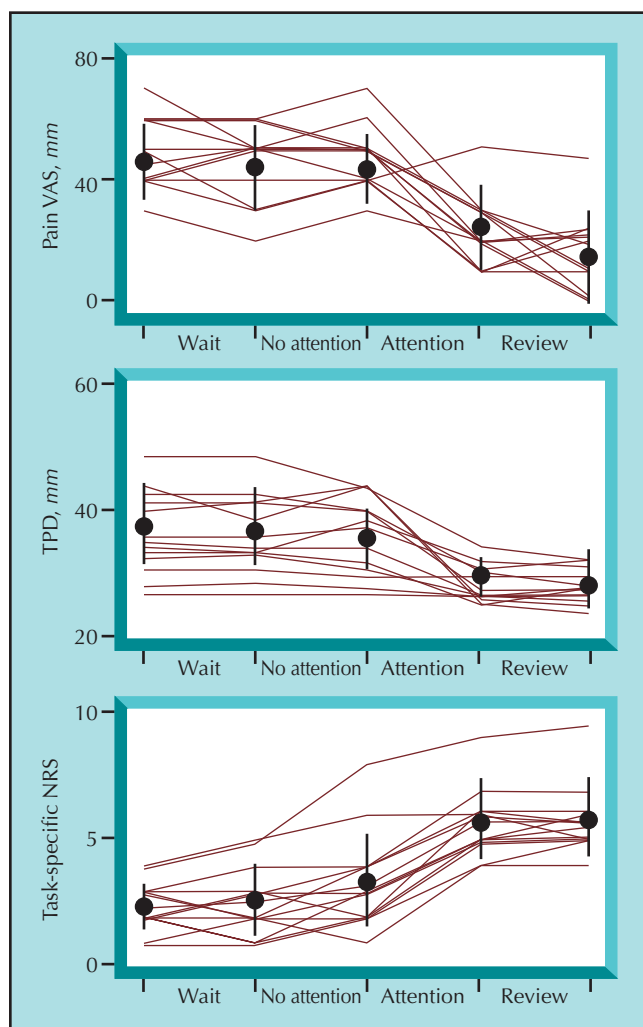
Recently, several attempts to reduce pain have targeted coexistent body image disruption. Justification of this strategy is as yet undefined, but some experimental evidence suggests it may be effective in select patients.

Tactile input can sharpen the receptive fields of S1 neurons, especially when the individual allocates attention to the sensory input or a behavioral objective is associated with it. A landmark study applied this principle to patients with phantom limb pain after amputation [70]. Patients were randomly allocated to control or to a training program involving two different stimuli delivered to four different sites on their stump. The behavioral objective of the task was for the patient to identify the stimuli used and the site being stimulated. Patients underwent daily 90-minute sessions for 2 weeks. Over that time, performance on the task doubled. S1 representation of the lip ipsilateral to the amputated limb—which was encroaching the area normally representing the arm (see above)—normalized. Finally, phantom limb pain decreased or was eliminated. Moreover, these three variables demonstrated a strong relationship ( $r < 0.73$ ,  $P < 0.05$ ).

Recently, this S1 training paradigm was applied to patients with unilateral CRPS (Moseley et al., unpublished data). In that study, patients received two different tactile stimuli at five points on their affected limb under two conditions. The first condition simply involved the stimuli, and in the second condition, the patient was required to identify which site was stimulated and with which stimulus. The duration of a baseline waiting period and of each condition was randomized between 11 and 17 days to control for any effect of time on symptoms. No changes were observed in pain, function, or tactile acuity during the waiting period nor during the stimulation-alone condition. However, reduction in pain, increase in function, and increase in tactile acuity were seen during the tactile discrimination condition (Fig. 2). Moreover, these three variables were also related.

On the basis of a range of data that showed visual input to have a potent effect on S1 activity and organization [71], a subsequent study used visual input and spatial attention to optimize the effect of tactile discrimination training. The study showed that a single 30-minute training session can increase tactile acuity and decrease pain for at least 48 hours (Moseley et al., unpublished data).

A separate approach attempted to utilize vision to normalize body image, without making the specific neuroanatomic assumption implicit in the above studies. That approach involved the use of visual illusion in paraplegic patients with severe neuropathic pain [72]. The study consisted of two parts. The first compared “virtual walk-



**Figure 2.** Effect of tactile stimulation alone (No attention) and tactile discrimination training (Attention) on pain. Tactile acuity as measured by two-point discrimination threshold (TPD) and function as self-rated ability to perform five tasks selected by the patient (task-specific numerical rating scale [NRS]), in patients with complex regional pain syndrome. Mean (circles) and standard deviation error bars are shown. Individual data also shown as individual lines.

ing” to guided imagery and distraction. Virtual walking involved patients sitting in their wheelchairs in front of a screen. A film of someone walking was projected onto the back of the screen and a mirror was placed over the top of the screen such that the patient could get the impression that they were watching themselves walk. Pain reduced markedly in four of five patients (Fig. 3).

The second part of this study was a 3-week training study in which the four patients who responded well to virtual walking in the first experiment did it every day for 3 weeks. Each patient showed a gradual increase in the magnitude and duration of pain relief.

An alternative application of the use of visual input to reduce pain in patients with distorted body image aims to use the automatic activation of motor mechanisms during implicit motor imagery. This motor usage may provide an

opportunity to normalize the implicit maps of the body by activating them without “igniting” the pain matrix. A graded motor imagery program was devised, such that patients with unilateral CRPS began by identifying pictured limbs as being left or right. This task, known as the left/right limb judgment task, activates motor systems, because to make the judgment, one mirrors the posture shown in the picture [73]. Patients with CRPS performed this task hourly for 2 weeks, then performed imagined movements, and then watched the mirror reflection of their unaffected limb as they moved both limbs (so-called mirror movements or mirror-visual feedback therapy). Two randomized clinical trials show a substantial reduction in pain and disability in patients with CRPS [74,75], and a third showed similar efficacy in patients with phantom limb pain after amputation or brachial plexus avulsion injury [76].

In summary, therapeutic approaches to targeting distorted body image in pain rehabilitation are in their infancy. Initial data are promising, but much work including robust clinical trials of current approaches must be done. Also, as our understanding of the relationship between distorted body image and pain increases, so too will the effectiveness of therapeutic approaches.

## Conclusions

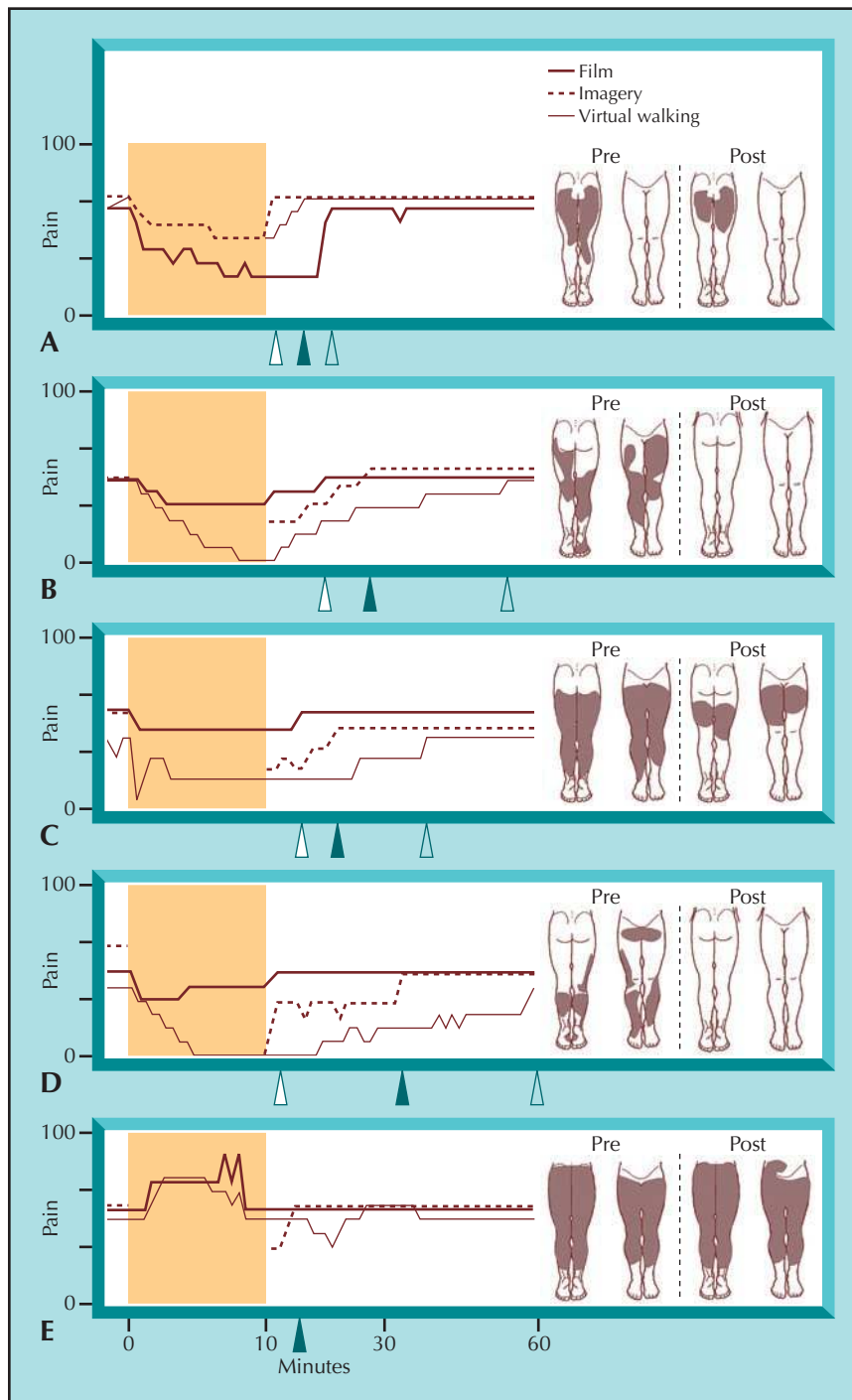
This review defined body image as the way one’s body feels to its owner. By doing so, we focus on a small part of the substantial literature relevant to how the brain represents, constructs, and controls the body and how those processes might change when people are in pain. Even that small portion of the literature is not completely understood. We know that body image is labile, but we do not know exactly how it is constructed by the brain. We know that the neural correlates of body image, at least those held in S1 and M1, are also labile and distorted in many pain states.

A relationship seems to exist between the extent of the body image distortion, disruption of cortical representation, and pain. It seems unlikely that the distortion in body image or cortical reorganization causes pain, but pain may contribute to them. Therapeutic approaches based on these relationships seem effective, at least in some patients, but we do not yet fully understand how or why they work. However, there is good reason to hope that as our understanding improves so too will our treatment of patients in pain.

## Acknowledgments

The authors have no potential conflicts of interest, financial or otherwise.

This project was supported by a grant of the Ministry of Research and Education in Germany (BMBF), project number 01EM0505.



**Figure 3.** Therapeutic attempts to normalize distorted body image as a way of treating patients in pain. *Left*, An experiment evaluating virtual walking for neuropathic pain in paraplegic patients. Resting pain (y-axis) in five volunteers (A–E) before, during, and after a 10-minute session of virtual walking (solid line, gray triangle), guided imagery (dotted line, open triangle), and distraction via watching a film (dashed line, solid triangle). Triangles denote time at which pain returned to pretask level. *Right*, Distribution of pain before and after the 10-minute virtual walking session. (From Moseley [72], with permission.)

## References and Recommended Reading

Papers of particular interest, published recently, have been highlighted as:

- Of importance
- Of major importance

1. Novy DM, Nelson DV, Averill PM, Berry LA: Gender differences in the expression of depressive symptoms among chronic pain patients. *Clin J Pain* 1996, 12:23–29.
2. Lewis JS, Kersten P, McCabe CS, et al.: Body perception disturbance: A contribution to pain in complex regional pain syndrome (CRPS). *Pain* 2007, Epub ahead of print.

Provided data on disturbances of the body image in patients suffering from CRPS.

3. Harris AJ: Cortical origin of pathological pain. *Lancet* 1999, 354:1464–1466.
4. Craig A: How do you feel? Interoception: the sense of the physiological condition of the body. *Nature Rev Neurosci* 2002, 3:655–66.
5. Gandevia SC: Illusory movements produced by electrical-stimulation of low-threshold muscle afferents from the hand. *Brain* 1985, 108:965–981.
6. Craske B: Perception of impossible limb positions induced by tendon vibration. *Science* 1977, 196:71–73.

7. Moseley GL, McCormick K, Hudson M, Zalucki N: **Disrupted cortical proprioceptive representation evokes symptoms of peculiarity, foreignness and swelling, but not pain.** *Rheumatology* 2006, 45:196–200.
- Provided evidence that a mere proprioceptive deafferentation is not causing pain but nonpainful perceptive changes of deafferented body part.
8. Paqueron X, Leguen M, Rosenthal D, et al.: **The phenomenology of body image distortions induced by regional anaesthesia.** *Brain* 2003, 126:702–712.
9. Ephraim PL, Wegener ST, MacKenzie EJ, et al.: **Phantom pain, residual limb pain, and back pain in amputees: Results of a national survey.** *Arch Phys Med Rehabil* 2005, 86:1910–1919.
10. Pezzin LE, Dillingham TR, MacKenzie EJ: **Rehabilitation and the long-term outcomes of persons with trauma-related amputations.** *Arch Phys Med Rehabil* 2000, 81:292–300.
11. Giummarra MJ, Gibson SJ, Georgiou-Karistianis N, Bradshaw JL: **Central mechanisms in phantom limb perception: The past, present and future.** *Brain Res Rev* 2007, 54:219–232.
12. Haigh RC, McCabe CS, Halligan PW, Blake DR: **Joint stiffness in a phantom limb: evidence of central nervous system involvement in rheumatoid arthritis.** *Rheumatology* 2003, 42:888–892.
13. Sellal F, RenaseauLeclerc C, Labrecque R: **The man who had six arms. Analysis of supernumerary phantom limbs after right hemisphere stroke.** *Rev Neurol (Paris)* 1996, 152:190–195.
14. Halligan PW, Marshall JC, Wade DT: **Three arms: a case study of supernumerary phantom limb after right hemisphere stroke.** *J Neurolog Neurosurg Psychiat* 1993, 56:159–166.
15. Moseley GL: **Distorted body image in complex regional pain syndrome type 1.** *Neurology* 2005, 65:773.
16. Lewis JS, McCabe CS, Blake DR: **Body perception disturbance in complex regional pain syndrome.** *Rheumatology* 2005, 44:I111–I112.
17. Claus A, Hides JA, Moseley GL, Hodges P: **Sitting versus standing: does the intradiscal pressure cause disc degeneration or low back pain?** *J Electromyog Kinesiol* 2007, Epub ahead of print.
18. Brumagne S, Cordo P, Lysens R, et al.: **The role of paraspinal muscle spindles in lumbosacral position sense in individuals with and without low back pain.** *Spine* 2000, 25:989–994.
19. Asell M, Sjolander P, Kerschbaum H, Djupsjobacka M: **Are lumbar repositioning errors larger among patients with chronic low back pain compared with asymptomatic subjects?** *Arch Phys Med Rehabil* 2006, 87:1170–1176.
20. Moseley G, Hodges P: **Chronic pain and motor control.** In *Grievous Modern Manual Therapy of the Vertebral column*, 4 edn. Edited by Jull G, Boyling J. Edinburgh: Churchill-Livingstone; 2005:##–##.
21. Tremere L, Hicks TP, Rasmusson DD: **Role of inhibition in cortical reorganization of the adult raccoon revealed by microiontophoretic blockade of GABA(A) receptors.** *J Neurophysiol* 2001, 86:94–103.
22. Elbert T, Rockstroh B: **Reorganization of human cerebral cortex: The range of changes following use and injury.** *Neuroscientist* 2004, 10:129–141.
23. Braun C, Schweizer R, Elbert T, et al.: **Differential activation in somatosensory cortex for different discrimination tasks.** *J Neurosci* 2000, 20:446–450.
24. Braun C, Heinz U, Schweizer R, et al.: **Dynamic organization of the somatosensory cortex induced by motor activity.** *Brain* 2001, 124(Pt 11):2259–2267.
25. Weiss T, Miltner WH, Liepert J, et al.: **Rapid functional plasticity in the primary somatomotor cortex and perceptual changes after nerve block.** *Eur J Neurosci* 2004, 20:3413–3423.
26. Pleger B, Ragert P, Schwenkreis P, et al.: **Patterns of cortical reorganization parallel impaired tactile discrimination and pain intensity in complex regional pain syndrome.** *Neuroimage* 2006, 32:503–510.
27. Merzenich MM, Nelson RJ, Stryker MP, et al.: **Somatosensory cortical map changes following digit amputation in adult monkeys.** *J Comp Neurol* 1984, 224:591–605.
28. Pons TP, Garraghty PE, Ommaya AK, et al.: **Massive cortical reorganization after sensory deafferentation in adult macaques.** *Science* 1991, 252:1857–1860. [Comment in: *Science* 1992, 258:1159–60; *Science* 1994, 265:546–548.]
29. Elbert T, Flor H, Birbaumer N, et al.: **Extensive reorganization of the somatosensory cortex in adult humans after nervous system injury.** *Neuroreport* 1994, 5:2593–2597.
30. Yang TT, Gallen C, Schwartz B, et al.: **Sensory maps in the human brain.** *Nature* 1994, 368:592–593.
31. Ojemann JG, Silbergeld DL: **Cortical stimulation mapping of phantom limb rolandic cortex – case report.** *J Neurosurg* 1995, 82:641–644.
32. Flor H, Nikolajsen L, Jensen TS: **Phantom limb pain: a case of maladaptive CNS plasticity?** *Nature Rev Neurosci* 2006, 7:873–881.
- A recent review on plastic changes in the nerve system in respect to phantom limb pain.
33. Cohen LG, Bandinelli S, Findley TW, Hallett M: **Motor reorganization after upper limb amputation in man—a study with focal magnetic stimulation.** *Brain* 1991, 114:615–627.
34. Kew JJ, Ridding MC, Rothwell JC, et al.: **Reorganization of cortical blood-flow and transcranial magnetic stimulation maps in human-subjects after upper-limb amputation.** *J Neurophysiol* 1994, 72:2517–2524.
35. Pascual-Leone A, Peris M, Tormos JM, et al.: **Reorganization of human cortical motor output maps following traumatic forearm amputation.** *Neuroreport* 1996, 7:2068–2070.
36. Karl A, Birbaumer N, Lutzenberger W, et al.: **Reorganization of motor and somatosensory cortex in upper extremity amputees with phantom limb pain.** *J Neurosci* 2001, 21:3609–3618.
37. Lotze M, Flor H, Grodd W, et al.: **Phantom movements and pain - An MRI study in upper limb amputees.** *Brain* 2001, 124:2268–2277.
38. Lotze M, Grodd W, Birbaumer N, et al.: **Does use of a myoelectric prosthesis prevent cortical reorganization and phantom limb pain?** *Nat Neurosci* 1999, 2:501–502.
39. Lotze M, Montoya P, Erb M, et al.: **Activation of cortical and cerebellar motor areas during executed and imagined hand movements: an fMRI study.** *J Cogn Neurosci* 1999, 11:491–501.
40. van Rijn MA, Marinus J, Putter H, van Hilten JJ: **Onset and progression of dystonia in complex regional pain syndrome.** *Pain* 2007, 130:287–293.
41. Juottonen K, Gockel M, Silen T, et al.: **Altered central sensorimotor processing in patients with complex regional pain syndrome.** *Pain* 2002, 98:315–323.
42. Maihofner C, Handwerker HO, Neundorfer B, Birklein F: **Cortical reorganization during recovery from complex regional pain syndrome.** *Neurology* 2004, 63:693–701.
43. Krause P, Forderreuther S, Straube A: **Motor cortical representation in patients with complex regional pain syndrome. A TMS study [in German].** *Schmerz* 2006, 20:186–188.
44. Maihofner C, Baron R, DeCol R, et al.: **The motor system shows adaptive changes in complex regional pain syndrome.** *Brain* 2007, Epub ahead of print.
45. Siddal P, Yezierski RP, Loeser JD: **Taxonomy and epidemiology of spinal cord injury pain.** In *Progress in Pain Research and Management*. Edited by Burchiel KJ, Yezierski R. Seattle: IASP; 2002:##–##.
46. Lotze M, Laubis-Herrmann U, Topka H: **Combination of TMS and fMRI reveals a specific pattern of reorganization in M1 in patients after complete spinal cord injury.** *Restor Neurol Neurosci* 2006, 24:97–107.



47. Lotze M, Laubis-Herrmann U, Topka H, et al.: **Reorganization in the primary motor cortex after spinal cord injury - A functional magnetic resonance (fMRI) study.** *Restor Neurol Neurosci* 1999, 14:183-187.
48. Flor H, Braun C, Elbert T, Birbaumer N: **Extensive reorganization of primary somatosensory cortex in chronic back pain patients.** *Neurosci Lett* 1997, 224:5-8.
49. Spitzer M, Bohler P, Weisbrod M, Kischka U: **A neural network model of phantom limbs.** *Biol Cybern* 1995, 72:197-206.
50. Devor M, Seltzer Z: **Pathophysiology of damaged nerves in relation to chronic pain.** In *The Textbook of Pain*, 4 edn. Edited by Wall P, Melzack R. Edinburgh: Churchill Livingstone; 1999:129-64.
51. Verley R, Onnen I: **Somatotopic organization of the tactile thalamus in normal adult and developing mice and in adult mice dewhiskered since birth.** *Exp Neurol* 1981, 72:462-474.
52. Kaas JH: **Is most of neural plasticity in the thalamus cortical?** *Proc Natl Acad Sci U S A* 1999, 96:7622-7623.
53. Kaas JH, Florence SL: **Mechanisms of reorganization in sensory systems of primates after peripheral nerve injury.** *Adv Neurol* 1997, 73:147-158.
54. Pelled G, Chuang KH, Dodd SJ, Koretsky AP: **Functional MRI detection of bilateral cortical reorganization in the rodent brain following peripheral nerve deafferentation.** *Neuroimage* 2007, 37:262-273.
55. Schwenkreis P, Witscher K, Janssen F, et al.: **Changes of cortical excitability in patients with upper limb amputation.** *Neurosci Lett* 2000, 293:143-146.
56. Flor H, Elbert T, Knecht S, et al.: **Phantom-limb pain as a perceptual correlate of cortical reorganization following arm amputation.** *Nature* 1995, 375:482-484.
57. Takano B, Drzezga A, Peller M, et al.: **Short-term modulation of regional excitability and blood flow in human motor cortex following rapid-rate transcranial magnetic stimulation.** *Neuroimage* 2004, 23:849-859.
58. Florence SL, Boydston LA, Hackett TA, Lachoff HT, Strata F, Niblock MM: **Sensory enrichment after peripheral nerve injury restores cortical, not thalamic, receptive field organization.** *Eur J Neurosci* 2001;13(9):1755-66.
59. Karl A, Muhlneckel W, Kurth R, Flor H: **Neuroelectric source imaging of steady-state movement-related cortical potentials in human upper extremity amputees with and without phantom limb pain.** *Pain* 2004, 110:90-102.
60. Eisenberg E, Chistyakov AV, Yudashkin M, et al.: **Evidence for cortical hyperexcitability of the affected limb representation area in CRPS: a psychophysical and transcranial magnetic stimulation study.** *Pain* 2005, 113:99-105.
61. Birbaumer N, Lutzenberger W, Montoya P, et al.: **Effects of regional anesthesia on phantom limb pain are mirrored in changes in cortical reorganization.** *J Neurosci* 1997, 17:5503-5508.
62. Maihofner C, Neundorfer B, Birklein F, Handwerker HO: **Mislocalization of tactile stimulation in patients with complex regional pain syndrome.** *J Neurol* 2006, 253:772-779.
63. McCabe CS, Haigh RC, Halligan PW, Blake DR: **Referred sensations in patients with complex regional pain syndrome type 1.** *Rheumatology* 2003, 42:1067-1073.
64. Acerra N, Moseley GL: **Dysynchiria: Watching the mirror image of the unaffected limb elicits pain on the affected side.** *Neurology* 2005, 65:751-753.
65. Ramachandran VS, Rogers Ramachandran D, Stewart M: **Perceptual correlates of massive cortical reorganization.** *Science* 1992, 258:1159-1160.
66. Knecht S, Henningsen H, Elbert T, et al.: **Cortical reorganization in human amputees and mislocalization of painful stimuli to the phantom limb.** *Neurosci Lett* 1995, 201:262-264.
67. Acerra N, Souvlis T, Moseley G: **Stroke, complex regional pain syndrome and phantom limb pain: Can commonalities direct future management?** *J Rehabil Med* 2007, 39:109-114.
68. Maihofner C, Handwerker HO, Neundorfer B, Birklein F: **Patterns of cortical reorganization in complex regional pain syndrome.** *Neurology* 2003, 61:1707-1715.
69. Pleger B, Tegenthoff M, Schwenkreis P, et al.: **Mean sustained pain levels are linked to hemispherical side-to-side differences of primary somatosensory cortex in the complex regional pain syndrome I.** *Exp Brain Res* 2004, 155:115-119.
70. Flor H, Denke C, Schaefer M, Grusser S: **Effect of sensory discrimination training on cortical reorganisation and phantom limb pain.** *Lancet* 2001, 357:1763-1764.
71. Macaluso E, Driver J: **Spatial attention and crossmodal interactions between vision and touch.** *Neuropsychologia* 2001, 39:1304-1316.
72. Moseley GL: **Using visual illusion to reduce at-level neuropathic pain in paraplegia.** *Pain* 2007, 130:294-298.
73. Parsons LM: **Integrating cognitive psychology, neurology and neuroimaging.** *Acta Psychol (Amst)* 2001, 107:155-181.
74. Moseley GL: **Graded motor imagery is effective for long-standing complex regional pain syndrome.** *Pain* 2004, 108:192-198.
75. Moseley GL: **Is successful rehabilitation of complex regional pain syndrome due to sustained attention to the affected limb? A randomised clinical trial.** *Pain* 2005, 114:54-61.
76. Moseley GL: **Graded motor imagery for pathologic pain - A randomized controlled trial.** *Neurology* 2006, 67:2129-2134.
77. Butler D, Moseley GL: *Explain Pain*. Adelaide: NOI Group Publishing; 2003.