

Role of the healthy hemisphere in recovery after resection of the supplementary motor area

A. Krainik, MD; H. Duffau, MD, PhD; L. Capelle, MD; P. Cornu, MD; A.-L. Boch, MD; J.-F. Mangin, PhD; D. Le Bihan, MD, PhD; C. Marsault, MD; J. Chiras, MD; and S. Lehericy, MD, PhD

Abstract—Objective: To determine the compensatory mechanisms involved in the recovery of motor function following surgical lesions of the supplementary motor area (SMA) and their relation to the clinical characteristics of recovery. **Subjects and Methods:** Twelve patients were referred for surgery of low-grade gliomas located in the SMA, and compared to eight healthy controls using fMRI before and after surgery during self-paced movements of both hands, successively. Magnitude and volume of activation within regions of interest (primary sensorimotor cortex, premotor cortex, SMA, preSMA, and parietal lobes) were compared and tested for correlation with anatomic characteristics of the tumor and resection, and clinical data. **Results:** Tumor growth induced preoperative underactivity in the adjacent SMA and overactivity in the opposite SMA. Postoperative recovery was associated with recruitment of a premotor network located in the healthy hemisphere including the SMA and the lateral premotor cortex. Postoperative premotor recruitment in the healthy hemisphere increased with the percentage of resection of preoperative SMA activation. Shortened onset and duration of recovery was associated with increased preoperative changes in activation levels. **Conclusions:** These findings suggest a dysfunction of the SMA ipsilateral to the tumor, partially compensated by a recruitment of the contralesional SMA which correlated with shortened postoperative recovery. SMA resection was compensated by the recruitment of a medial and lateral premotor circuitry in the healthy hemisphere.

NEUROLOGY 2004;62:1323–1332

Surgical resection of the supplementary motor area (SMA) leads to characteristic postoperative deficits, called the SMA syndrome.¹⁻⁵ The SMA syndrome is an executive disorder with variable motor and speech impairments, and variable severity ranging from complete suppression of motor and speech production to reduced spontaneous motor and speech output. One of the main features of the SMA syndrome is a complete or almost complete recovery within a few weeks or months.¹⁻⁵ This latter characteristic implies that plastic brain mechanisms occur, which are able to compensate for deficient motor and speech functions, and to supply the loss of activity of the resected SMA.

Recovery studies have emphasized the role of undamaged motor-related cortical areas (including the sensorimotor cortex, the SMA, the premotor cortex, particularly in the healthy hemisphere) after lesions involving the primary motor cortex or the corticospinal tract.⁶⁻¹⁵ How these areas participate in motor

recovery following lesion of medial premotor areas remains to be evaluated, as well as their beneficial role in this process. The purpose of this study was to determine the compensatory mechanisms associated both with tumor growth and recovery of motor function following surgical lesions of the SMA, and to determine whether compensatory activation patterns are related to the clinical characteristics of motor recovery. For that purpose, we examined pre- and postoperative clinical, anatomic, and functional imaging data in patients referred for surgical resection of a low-grade glioma of the SMA. We selected regions of interest (ROI) that are connected to the SMA as previously demonstrated in monkeys including the primary sensorimotor cortex, the medial and lateral premotor areas, the anterior and posterior cingulum, the preSMA, and the parietal lobes.¹⁶⁻¹⁸ The characteristics of postoperative deficit and recovery were also compared to tumoral, surgical, and functional characteristics.

Additional material related to this article can be found on the *Neurology* Web site. Go to www.neurology.org and scroll down the Table of Contents for the April 27 issue to find the title link for this article.

Subjects and methods. *Subjects.* *Patients.* Patients were selected according to the following criteria: 1) presence of a tumor of the medial frontal lobe; 2) low grade at histologic examination allowing minimization of possible local vascular disorders related

From the Departments of Neuroradiology (Drs. Krainik, Marsault, Chiras, and Lehericy) and Neurosurgery (Drs. Duffau, Capelle, Cornu, and Boch), INSERM EMI 007 (Drs. Krainik, Duffau, and Lehericy), Hôpital de la Pitié-Salpêtrière, Paris; and Service Hospitalier Frédéric Joliot (Drs. Mangin, Le Bihan, and Lehericy), CEA, Orsay, France.

Supported by PHRC 2001-AOR01109, the Société Française de Radiologie, and the GE William D. Coolidge innovation grant from the ECR R&E Fund (A.K.).

Received July 30, 2003. Accepted in final form December 23, 2003.

Address correspondence and reprint requests to Dr. Stéphane Lehericy, Service de Neuroradiologie Fishgold, Hôpital de la Pitié-Salpêtrière, 47 bd de l'Hôpital, 75013 Paris, France; e-mail: stephane.lehericy@psl.ap-hop-paris.fr

Table Clinical and surgical characteristics of the patients

Patient no./age, y/sex	Location of the lesion	Seizure history, mo	Volume of tumor, cm ³	Volume of surgical resection, cm ³	Percentage of occupancy of SMA by the tumor	Percentage of resection of SMA activation	Postoperative motor deficit	Motor recovery begin/complete, d/mo	Long-term follow-up 1 y
1/31/M	Left	27	67.6	115.9	90.8	100	Moderate hemiparesia RU	3/1	Normal
2/50/M	Right	1.5	50.1	12.7	100	90.0	Moderate hemiparesia LU	10/3	Normal
3/25/W	Right	15	39.1	44.9	33.8	27.3	Moderate hemiparesia LU	3/3	Normal
4/28/M	Right	4	139.8	89.4	56.9	100	Severe left hemiparesia	7/3	Grasping, bimanual coordination impairment
5/34/M	Left	4	50.9	37.3	94.6	50.0	Mild hemiparesia RU	2/2	Normal
6/45/M	Left	4	49.5	65.5	9.2	28.6	Severe right hemiparesia RU	15/4	Normal
7/48/M	Left	30	69.5	55.4	36.1	18.8	Mild hemiparesia RU	2/2	Normal
8/31/M	Left	24	62.4	49.9	70.8	90.9	Moderate hemiparesia RU	3/2	Normal
9/41/M	Right	60	21.9	16.6	23.1	50.0	Severe hemiparesia LU	7/3	Normal
10/37/F	Left	1.5	54.1	26.0	56.1	83.3	Moderate hemiparesia RU	5/2	Normal
11/68/F	Left	6	16.6	21.9	52.3	75.0	Moderate hemiparesia RU	21/3	Underutilization of RU
12/45/M	Right	1	22.7	27.1	49.2	83.3	Severe hemiparesia LU	3/2	Normal

* During preoperative movement of the contralesional hand.

SMA = supplementary motor area; RU = right upper limb predominance of the deficit; LU = left upper limb predominance of the deficit.

to the neovascularization of high-grade lesion, and longer follow-up; 3) absence of tumor extension in the primary sensorimotor cortex; 4) absence of preoperative motor deficit; 5) occurrence of a SMA syndrome with related motor disorders following surgery. From the 47 consecutive patients referred for surgical treatment of lesions of the medial frontal lobe in the neurosurgery department between November 1996 and November 2001, 12 right-handed patients fulfilled the criteria and were included (3 women and 9 men; age range: 25 to 68 years, mean: 40 years). All tumors were located close to the SMA in the left medial frontal lobe in seven patients, and in the right medial frontal lobe in five patients. The pre- and postoperative neurologic examinations were performed by neurologists and neurosurgeons using a standardized clinical scale.¹⁹ The intensity of the motor deficit was rated as follows: no deficit (0), mild deficit (1) (patient can use his or her limb almost normally), moderate deficit (2) (movement possible with help of examiner), severe deficit (3) (no spontaneous move-

ment against gravity). Clinical examinations were performed on the day of the fMRI, the day before surgery, immediately after surgery, after 1 week, and then after 1, 2, 3, 6, and 12 months. All patients had a seizure history for 1 to 60 months (mean: 15 months) (table). Preoperative motor or speech deficit was absent in all patients. All patients had preoperative cortical and subcortical electrical stimulations to avoid lesion of the primary motor cortex and the corticospinal fibers. All patients had steroid treatment during 3 days immediately after surgery. Motor recovery was considered complete once muscular strength and motor examination¹⁹ were normal at the time of clinical examination.

Healthy volunteers. Eight age-matched right-handed control subjects (4 women and 4 men; age range: 27 to 71 years, mean: 46.5 years) were compared to the patients. None of the volunteers had a history of neurologic or psychiatric disease, or diagnosed disability. The protocol was approved by the ethics committee of

our institution. All subjects gave their written informed consent according to the Declaration of Helsinki.

Imaging. The MR protocol was carried out with a 1.5 T MR unit. fMRI using blood oxygen level dependent contrast was performed preoperatively between 1 and 148 days before surgery (mean: 27 days), and postoperatively between 63 and 1,063 days after surgery (mean: 364 days). All patients had recovered at the time of postoperative fMRI and were able to perform motor tasks appropriately. The delay between the end of recovery and fMRI examination ranged from 3 days to 1,032 days (mean: 289 days). The protocol included 1) 20 axial gradient echo–echo planar images covering the whole frontal lobes (repetition time/echo time/flip angle: 3,000/60 msec/90°, 5 mm slice thickness, no gap, in plane resolution: 3.75 mm × 3.75 mm); 2) axial inversion recovery three-dimensional T1-weighted images for anatomic localization; and 3) axial fast fluid-attenuated inversion recovery images.

Two different tasks were performed by the subjects. The tasks consisted of self-paced flexion/extension of the fingers of the right and left hand, successively. The subjects were asked to perform the tasks at a movement rate of 0.5 Hz. Before the experiment started, all subjects practiced each movement to keep amplitude, acceleration, and strength constant. The paradigm was block-designed, alternating rest and activation, and consisted of seven epochs of 18 sec (duration of each run: 2 minutes 6 sec). The task instructions were auditory-cued using a digital audiotape and presented using standard headphones customized for fMRI experiments and inserted in a noise-protecting helmet that provided isolation from scanner noise. Direct observation of the tasks was performed by an investigator during the fMRI acquisitions.

Data analysis. Statistical analyses of functional images were performed in MATLAB (Mathworks, Natick, MA) with SPM99 (Wellcome Department of Cognitive Neurology, London, UK) using the general linear model. For each subject, images were corrected for subject motion with the first volume of each study used as a reference, and transformed stereotactically to Talairach coordinates using the standard template of the Montreal Neurologic Institute. In patients, focal lesions were masked to be excluded of the normalization transformation.²⁰ The resulting images were smoothed with a Gaussian spatial filter to a final smoothness of 5 mm. The data were then analyzed statistically using a two-temporal basis functions model. Overall signal differences between runs were also modeled. A temporal cut-off of 240 seconds was applied to filter subject-specific low frequency drift related mostly to subject biologic rhythms. Statistical parametric maps were calculated for the contrast action versus rest and thresholded at $T > 3.1$. Activated clusters were then considered significant at $p < 0.05$ corrected for multiple comparisons. fMRI studies with excessive head motion or important susceptibility artifacts related to postoperative metallic material were excluded. Data were analyzed for each subject.

A total of 64 fMRI acquisitions were performed in the 8 healthy control subjects and the 12 patients. Excessive motion artifacts were observed in two patients before surgery during the movement of the hand ipsilateral to the tumor, and important magnetic susceptibility artifacts related to postoperative metallic material were present in three patients. These functional series were excluded from analysis leaving 56 fMRI acquisitions for evaluation.

ROI were drawn onto the normalized T1-weighted anatomic images without knowledge of the activation patterns, using standard sulcal atlases.²¹ ROI drawing was performed on anatomic images using semiautomatic segmentation software based on region growing (Anatomist, SHFJ-CEA; <http://brainvisa.info>). This software provided volumes of tumors, resection cavities, activation (in cm^3), and overlap between ROI (e.g., between fMRI activation and surgical resection).

ROI were located in both hemispheres in the primary sensorimotor cortex (SMC), the lateral premotor cortex (PMC), the SMA, the preSMA, the anterior and the posterior cingulum, and the parietal lobes. The volume of each ROI was similar in each hemisphere. The SMA extended from the brain vertex to the cingulate sulcus and from the precentral sulcus to the VAC line (a vertical line passing at level of the anterior commissure and perpendicular to the anterior commissure–posterior commissure plane). The preSMA extended rostral to the VCA line to a virtual line passing through the genu of the corpus callosum parallel to the VAC line. The anterior and posterior parts of the cingulum were located

between the cingulate sulcus and the corpus callosum, separated by the VAC line.²²

Within each ROI, activation volume ([number of activated voxels] × [voxel volume], with voxel volume = 70.3 mm^3), magnitude (corresponding to the maximum T-value), and Talairach coordinates of the maximum T-value were obtained. When no activation was detected, maximum T-value was set to zero.

Laterality indices (LI) were calculated for each pair of ROI, defined as the ratio $LI = [(C-I)/(C+I)]$ with C corresponding to activation parameters in the hemisphere contralateral to the moving limb and I to activation parameters in the ipsilateral hemisphere. Two different types of LI were calculated: a magnitude LI (using for activation parameter the maximum T-value) and a volumetric LI (using the number of activated voxels within the ROI). LI ranged from -1 (activation in the ipsilateral hemisphere only) to $+1$ (activation in the contralateral hemisphere only). Four complete data sets of randomly chosen healthy volunteers were mirrored to match the bilateral distribution of the lesions in patients.

Statistical analysis. Analyses were conducted using statistical software (SPSS, version 11.0, Chicago, IL). All values are expressed as mean ± SD. Statistical comparisons were performed by using nonparametric procedures because of repeated violations of the assumption of distribution normality: k-related samples test (Friedman test) and follow-up pairwise comparisons (Wilcoxon test), and two independent-samples test (Mann-Whitney *U* test) when appropriate. Relationships between quantitative data sets (clinical history: seizures history, onset and duration of the recovery, severity of the deficit; imaging data: volumes of tumor and percentage of SMA occupancy by the tumor, percentage of resection of SMA activation, number of activated voxels, maximum T-value, laterality index) were assessed using Kendall's W test (coefficient of concordance) and r' Spearman correlation coefficient. Significance level was set at $p \leq 0.05$.

Results. Patients: clinical and anatomic findings. The table summarizes clinical and anatomic data in patients. The clinical presentation was unchanged between the preoperative fMRI session and surgery in all patients. All patients experienced an immediate postoperative motor deficit contralateral to the resection. In all patients but one, the motor deficit predominated in the upper limb. Recovery began 2 to 21 days after surgery (mean: 6.8 ± 5.9 days), and was complete between 30 days and 120 days after surgery (mean: 75 ± 23.9 days). At 1 year follow-up, the neurologic examinations were normal in all patients but Patients 4 and 11, who presented mild abnormalities (see the table). Muscular strength was normal in all patients. All patients with a left-sided tumor had a transient postoperative speech disorder. Except for the occurrence of postoperative speech disorder, no clinical or anatomic difference was observed between patients with tumors in the left and right hemispheres.

Mean tumor volume was $53.7 \pm 32.4 \text{ cm}^3$, mean resection volume was $46.9 \pm 31.1 \text{ cm}^3$, and both values were correlated ($r' = 0.67$; $p < 0.02$). Tumors occupied $7.3 \pm 3.7 \text{ cm}^3$ ($56.1 \pm 28.7\%$) of the volume of the SMA, $5.6 \pm 4.1 \text{ cm}^3$ ($40.6 \pm 29.7\%$) of the preSMA, and $7.3 \pm 3.7 \text{ cm}^3$ ($56.1 \pm 28.7\%$) of the PMC. Surgery resulted in the removal of $6.2 \pm 3.2 \text{ cm}^3$ ($47.9 \pm 24.9\%$) of SMA, $8.0 \pm 3.4 \text{ cm}^3$ ($57.7 \pm 24.9\%$) of preSMA, and $6.7 \pm 4.3 \text{ cm}^3$ ($19.2 \pm 12.3\%$) of PMC (figure E-1, available online at <http://www.neurology.org>; see the table).

fMRI studies. Activation was present in the contralateral SMC in 100% of the subjects, and in the ipsilateral or contralateral PMC in $94.4 \pm 9.3\%$, SMA in $96.3 \pm 9.1\%$, preSMA in $72.1 \pm 20.3\%$, posterior cingulum in $26.1 \pm 17.3\%$, anterior cingulum in $31.6 \pm 17.8\%$, and parietal lobes in $86.1 \pm 8.4\%$ of the subjects. Because activation in the cingulate cortex was inferior to 50% in controls and in

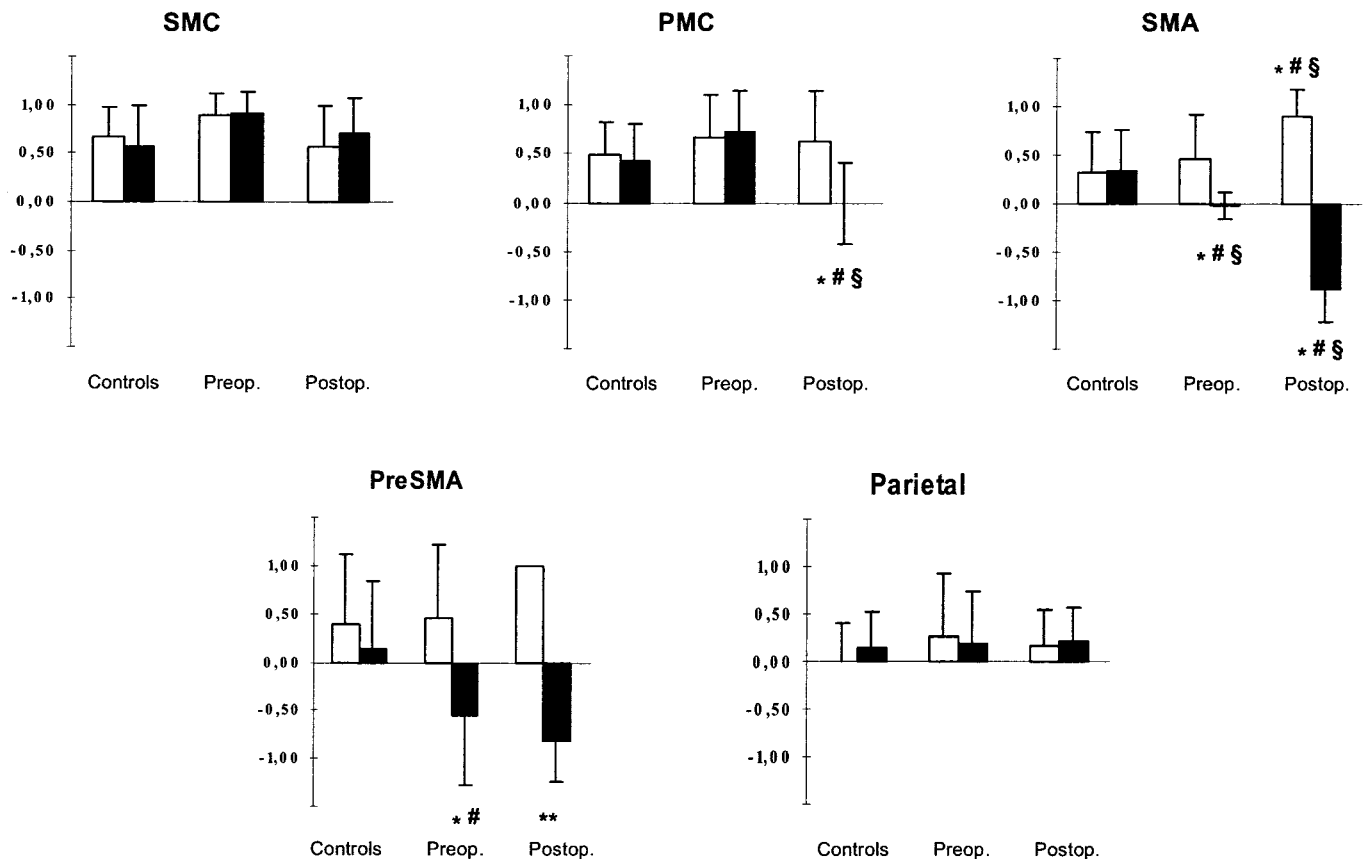


Figure 1. Laterality indices (LI) in healthy subjects and in patients. Magnitude LI (mean \pm SD) during movements of the unaffected hand (white bars) and the affected hand in patients (black bars) before (Preop.) and after (Postop.) surgery. In controls, matched hands were obtained after having mirrored data sets of four subjects. Comparisons between controls and patients were performed using Mann-Whitney U test with * $p \leq 0.05$. In patients, pairwise comparisons were performed using Wilcoxon test between opposite hands for the same examination (# $p \leq 0.05$), and between different examinations for the same hands (§ $p \leq 0.05$). ** After surgery, activation in the preSMA was detected in four patients during ipsilesional movements and in five patients during contralesional movements. SMC = supplementary motor cortex; PMC = premotor cortex; SMA = supplementary motor area.

patients, these regions were not included for further analysis.

Activation parameters were similar in patients with tumors in the left and the right frontal lobes. Therefore, activation data were presented according to the movement side related to the lesion, whether contralesional (CL) or ipsilesional (IL).

Analyses were performed on activation volume and magnitude (tables E-1 through E-3, available online at <http://www.neurology.org>), and on LI. For interindividual comparisons, LI were used. Magnitude and volumetric LI were strongly correlated ($r' = 0.90$; $p < 0.01$) and overall interindividual comparisons gave similar results with both LI. Only results for magnitude LI are presented (figure 1). Preoperative and postoperative activation maps are presented in figures 2 and 3.

Sensorimotor cortex. All activation values (activation volume and magnitude, LI) showed that activation predominated in the hemisphere contralateral to the moving hand without difference between controls and patients, before and after surgery. In controls, activation volumes were larger in the contralateral hemisphere during movement of the right dominant hand than the nondominant hand ($p < 0.02$). In patients after surgery, activation vol-

umes in the ipsilateral hemisphere were larger than before surgery. This difference predominated for CL movements, although it did not reach significance ($p < 0.07$).

Lateral premotor cortex. In controls for each hand and patients before surgery, activation volumes and magnitudes were higher in the hemisphere contralateral to the moving hand ($p < 0.05$). In patients after surgery, activation during CL movements became symmetric with LI being smaller than in controls ($p < 0.05$). Ipsilateral activation volume was larger during CL movements than IL movements ($p = 0.05$), but magnitude was similar. In patients during CL movements, both volumetric ($p < 0.02$) and magnitude ($p = 0.05$) LI were smaller postoperatively than preoperatively. In the diseased hemisphere, magnitude and volumes of activation decreased, but only magnitude decrease reached significance ($p = 0.05$). This effect was at least partially due to resection of PMC activation in four patients, including Patient 1 (37.5%), Patient 4 (3.13%), Patient 6 (54.55%), and Patient 8 (4.35%), with a mean surgical removal of $8.29 \pm 18.05\%$. No significant correlation between PMC tumoral extension or resection and activation values in each hemisphere was detected. In the healthy hemisphere, magnitude and volume of activation increased, but only volume increase reached signifi-

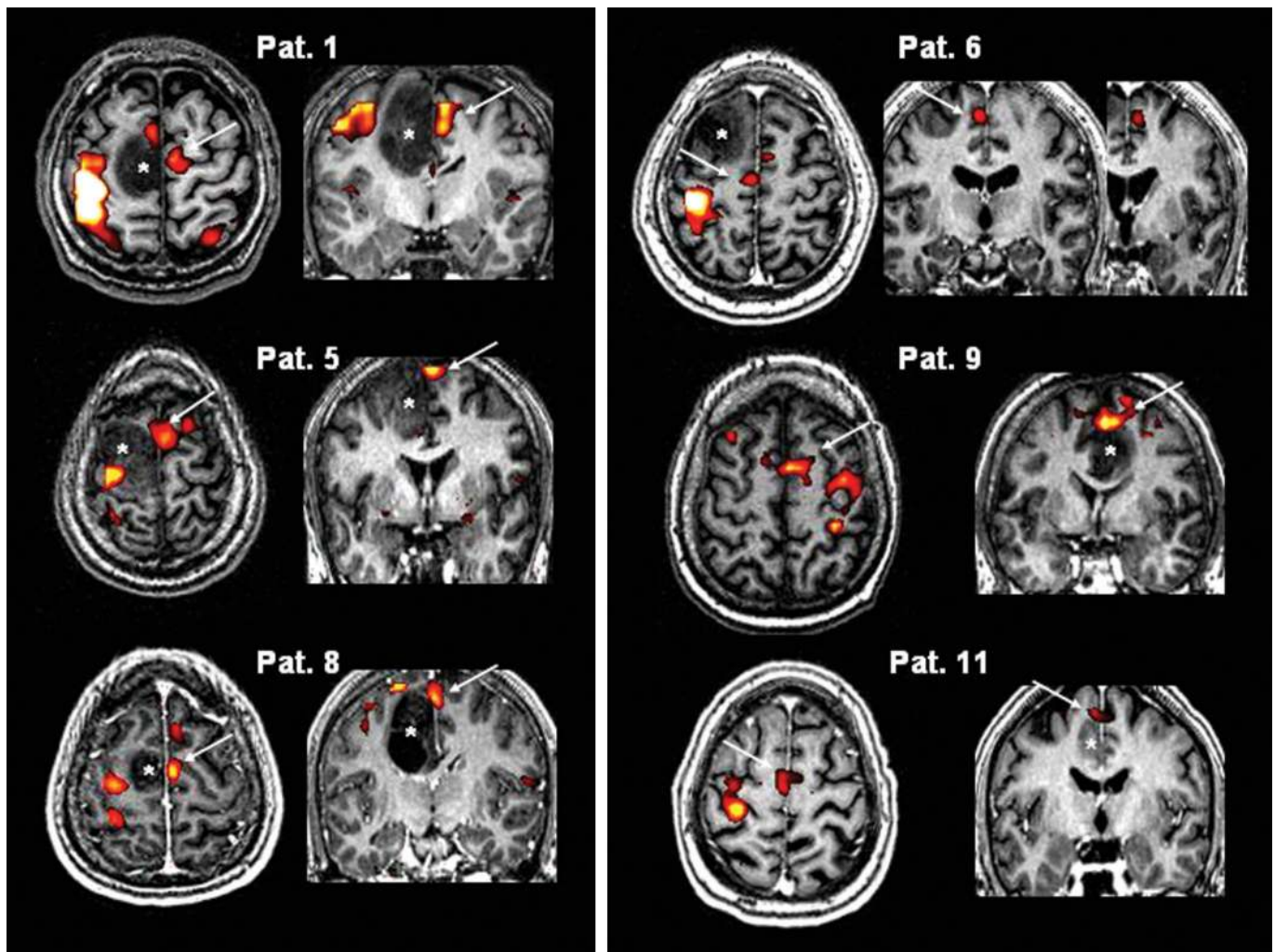


Figure 2. Preoperative fMRI in patients during contralesional movements. Preoperative anatomic and functional MRI in Patients 1, 5, and 8 (left column) showed large tumoral infiltration of the supplementary motor area (SMA) (asterisk), associated with underactivity in the SMA in the pathologic hemisphere, and overactivity in the healthy SMA resulting in negative magnitude laterality indices (LI) (-0.40 , -0.12 , -0.06). Recovery began within the first 3 days and lasted between 30 and 60 days. In Patients 6, 9, and 11 (right column), tumoral infiltration (asterisk) was lower, and LI remained positive (0.08 , 0.19 , 0.12). Arrows indicate predominant SMA activation. Recovery began after 7 to 21 days, and lasted between 90 and 120 days. See table 1 for details.

cance ($p = 0.05$). Mean coordinates in Talairach space demonstrated the changes in activity were located in the dorsal part of the PMC.

SMA. Overall, total activation volumes in both SMA were similar between controls and patients for both hands. In controls ($p < 0.05$) and patients during IL movements ($p < 0.01$), activation volume and magnitude were higher in the hemisphere contralateral to the moving hand.

Before surgery, activation volume in the damaged hemisphere during CL movements decreased and tended to correlate with tumoral infiltration ($r' = -0.57$; $p < 0.06$). On the opposite, activation magnitude in the healthy hemisphere increased and correlated with tumoral infiltration ($r' = 0.63$; $p < 0.03$). Activation volume and magnitude in the ipsilateral SMA were larger during CL than IL movements ($p < 0.05$). Surgery removed $66.8 \pm 29.7\%$ of the area activated in the SMA adjacent to the tumor during CL hand movements (see the table). After surgery and partial to complete resection of the SMA, activation adja-

cent to the resection cavity was detected in one patient during IL movements (Patient 12), and one patient during CL movements (Patient 2). Activation in the healthy hemisphere was similar to preoperative data. Both decreased activation in the diseased hemisphere (secondary to tumoral infiltration or resection) and increased activation in the healthy hemisphere resulted in LI significantly decreased as compared to control subjects (see figure 1).

PreSMA. In controls, activation during right hand movements was bilateral and symmetric with a nonsignificant ipsilateral predominance whereas activation during left hand movements was located in the contralateral preSMA ($p < 0.02$). In both tasks, predominance of right preSMA magnitude was observed ($p < 0.04$). In patients before surgery, IL movements activated preferentially the contralateral preSMA ($p < 0.05$), whereas CL movements activated preferentially the ipsilateral preSMA (larger activation volume in the ipsilateral hemisphere, $p = 0.05$). Ipsilateral activation volumes were larger during CL

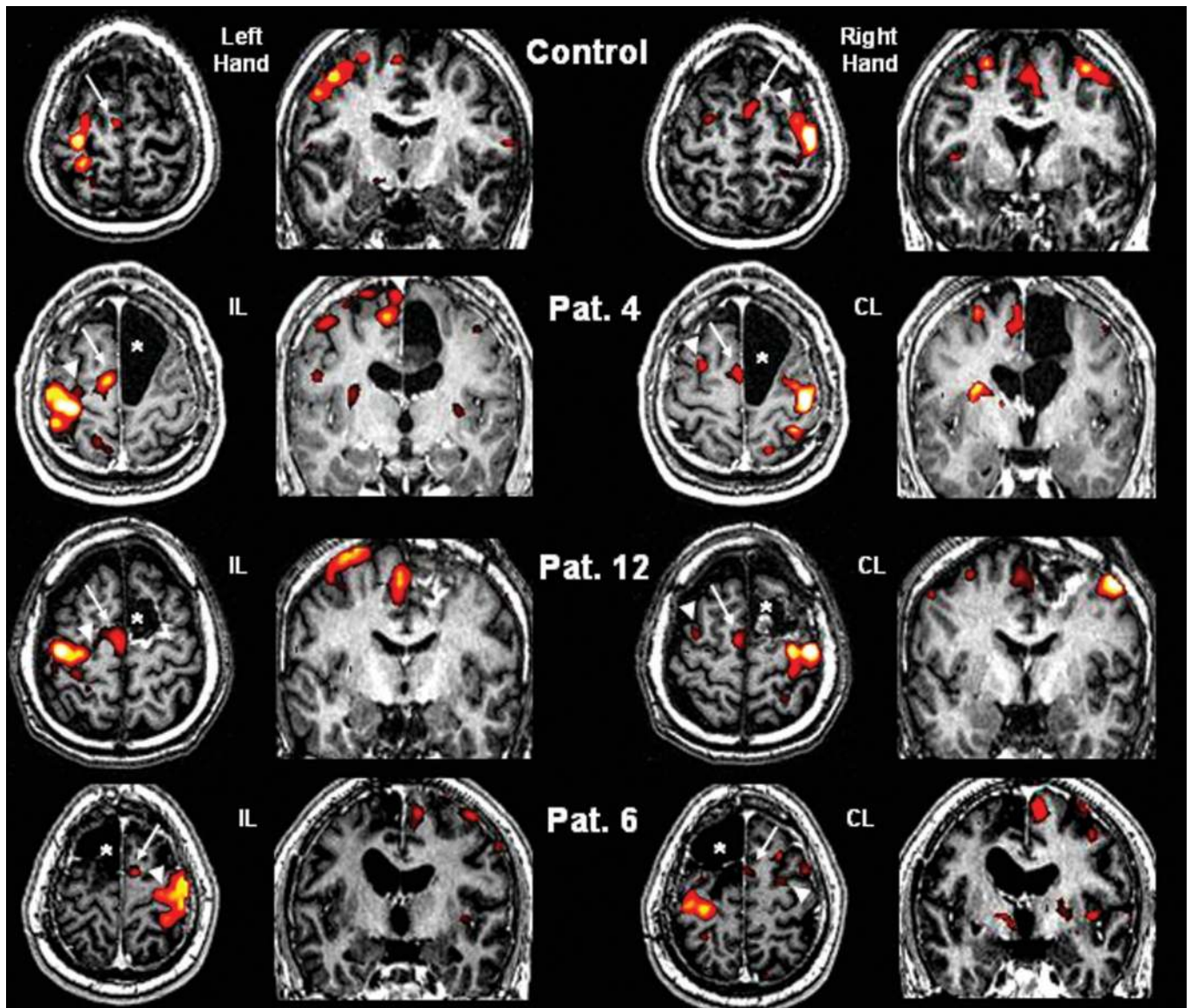


Figure 3. Postoperative fMRI. Anatomic and functional MRI in one representative control and in Patients 4, 6, and 12 during ipsilesional (IL) and contralesional (CL) movements after surgery. In controls and in patients during IL movements, supplementary motor area (SMA) (arrow) and premotor cortex (PMC) (arrowhead) activation predominated in the hemisphere contralateral to the moving hand. In patients during CL movements, SMA activation was located in the healthy hemisphere and PMC activation became more important in the ipsilateral healthy hemisphere. The resection cavity is indicated by the asterisk on axial planes.

movements than IL movements ($p < 0.03$). Differences in maximum T-value did not reach significance ($p < 0.1$). During CL movements, activation in the preSMA beside the tumor was detected in three patients (Patients 1, 2, and 5) and removed during surgery in two patients (Patient 1: 83%, Patient 5: 100%). After surgery, activation adjacent to the resection cavity was detected in only one patient (Patient 1) during CL movements. In the healthy hemisphere, activation was detected in four patients during IL movements and in five patients during CL movements. Thus, no further statistical analysis was conducted.

Parietal lobes. In controls and in patients before and after surgery, no significant difference was detected for LI, as well as activation volume and magnitude between hemispheres and side of movement.

Relationships between clinical and imaging data. All relationships between clinical history (duration since seizure onset, severity of the deficit, onset, and duration of recovery), tumor (volume, percentage of occupancy of the ROI), resection cavity (volume), and functional (percentage of activation resection, activation volume and magnitude) characteristics were tested.

Preoperative clinical presentation (duration since seizure onset) was not related to the characteristics of the tumor and preoperative fMRI activation.

There was a correlation between the tumoral extension in the SMA, the LI, and the temporal course of recovery (Kendall's W coefficient of concordance = 0.71; $p < 0.01$). Larger tumoral extension in the SMA was correlated with lower LI in the SMA during CL movements ($r' = -0.70$;

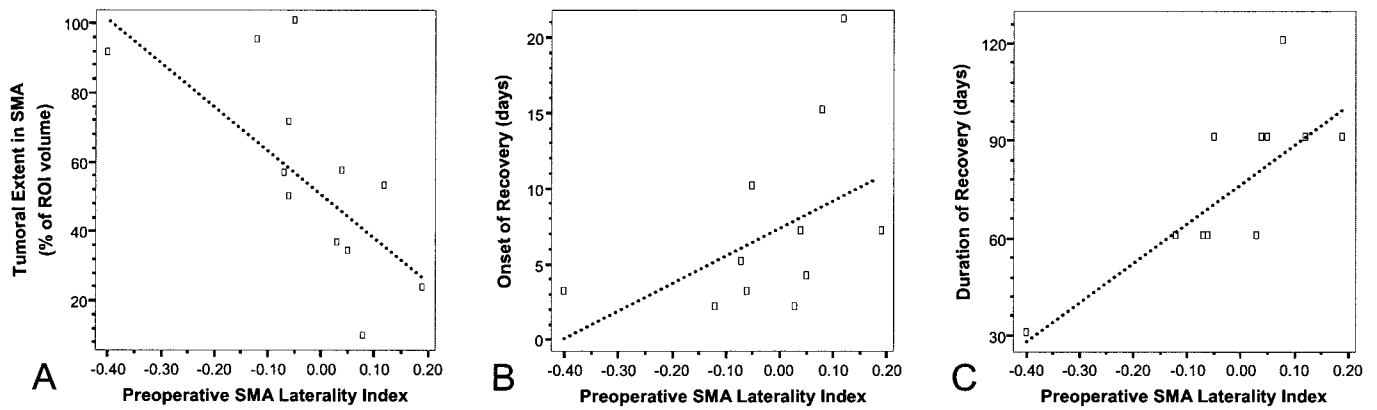


Figure 4. Relationships between preoperative supplementary motor area (SMA) activation during contralesional movements, tumoral extension in SMA, and recovery time course. Because of violation of normality distribution, nonparametric Spearman r' rank correlation coefficients were used. However, these scattergraphs show parametric values of the data with linear regression plots (dotted line) with each slope corresponding to the Pearson R correlation coefficient mentioned in brackets in the legend. (A) Correlation coefficient between SMA laterality indices (LI) and tumoral extension in the SMA was $r' = -0.70$, $p < 0.02$ ($R = -0.71$, $p < 0.01$). (B) Correlation coefficient between SMA LI and postoperative onset of recovery was $r' = 0.66$, $p < 0.02$ ($R = 0.48$, $p = 0.11$). (C) Correlation coefficient between SMA LI and duration of recovery was $r' = 0.85$, $p < 0.001$ ($R = 0.79$, $p < 0.002$). Note that Spearman r' coefficients remain significant without data of Patient 1, who had a preoperative SMA LI of -0.40 .

$p < 0.02$), and lower LI were correlated with shorter onset ($r' = 0.66$; $p < 0.02$), and duration of recovery ($r' = 0.85$; $p < 0.001$) (figure 4). Onset and duration of recovery were also correlated ($r' = 0.81$; $p < 0.001$). No correlation was found between the severity of the deficit and recovery characteristics or preoperative fMRI activity values. Figure 4 illustrates the clinical and preoperative imaging correlations.

Postoperative fMRI showed that the lateral premotor recruitment in the healthy hemisphere correlated with tumoral extension in the SMA and with the extent of resection of SMA activation (Kendall's W coefficient of concordance = 0.63; $p = 0.01$). Larger tumoral extension in the SMA correlated with larger percentage of resection of SMA activation during preoperative CL movements ($r' = 0.64$; $p < 0.03$). These two variables correlated with higher ipsilateral PMC magnitude (Kendall's W coefficient of concordance = 0.71; $p < 0.03$) and with higher ipsilateral SMA magnitude (Kendall's W coefficient of concordance = 0.77; $p < 0.02$). Larger resections of SMA activation tended to be observed in patients with higher postoperative magnitude in ipsilateral SMA ($r' = 0.60$; $p < 0.09$), but not in PMC ($r' = 0.51$; $p < 0.16$). Percentage of resection of preoperative activation was not correlated with the time course of recovery.

Discussion. Our main findings are as follows: tumor growth was accompanied by a preoperative reorganization of SMA activation to the contralateral healthy hemisphere, which was not sufficient to prevent the occurrence of postoperative deficit but was associated with faster recovery. After surgery and recovery of the motor deficit, SMA activation was almost exclusively located in the healthy hemisphere and there was a recruitment of the lateral premotor cortex in the same hemisphere. The recruitment of both lateral and medial premotor cortex in the healthy hemisphere increased as the extent of tu-

moral infiltration in the SMA, and of the resection of its functional portion increased, although direct correlation did not reach significance.

The clinical presentation was similar across patients, as previously reported.¹⁻⁵ Before surgery, all patients were referred for a seizure history, and none presented a neurologic deficit. After surgery, the deficit occurred immediately after the resection, and consisted of a contralateral motor paresis of variable severity. Consistent with the fact that the resection involved more the anterior part of the SMA and with the finding that the representation of the upper limb is located rostral to the lower limb,²³ an upper limb predominance of the deficit was noted in 11 out of 12 patients. Motor deficit was associated with speech impairment when the resection involved the hemisphere dominant for language,^{2,3,5} anteriorly to the motor representation.²³ All patients recovered within several weeks.^{1-5,23} This postoperative deficit was considered to result from the lesion of the SMA for the following reasons: 1) its occurrence correlated with the resection of SMA activation evidenced during preoperative fMRI motor task⁴; 2) the sensorimotor cortex was spared in all patients as shown using preoperative cortical and subcortical stimulations and no postoperative pyramidal syndrome was detected; 3) lesions of other frontal motor areas (premotor and prefrontal) were inconstant and not correlated with the occurrence of the deficit. Moreover, lesions of these areas are not clinically associated with paresis.

In control subjects and patients during IL movements, SMA activation was mainly bilateral, but predominated in the hemisphere contralateral to the moving limb as already reported.²⁴ On the opposite, preoperative SMA activation during CL movements

was decreased in the lesioned hemisphere and increased in the healthy hemisphere, resulting in abnormal LI values. Despite activation decrease in the pathologic SMA, this area remained activated during CL movements and its resection induced the SMA syndrome.⁵

Using fMRI, impaired activation of functional regions beside macroscopic lesions has been reported in tumors^{6,25} as well as vascular infarcts.²⁶ This impairment may be due to several factors such as mass effect, tumor extension, and abnormal cerebrovascular reactivity induced by the tumor. Abnormal cerebrovascular reactivity has been mainly described in high-grade tumors with neovascularization, and may affect activation of the whole tumoral hemisphere.²⁵ In the present study, only low-grade gliomas without neovascularization were selected and no global hemispheric underactivation was observed. Impaired SMA activation in the lesioned hemisphere and increased activation in the healthy hemisphere were correlated with tumoral extension in the SMA, suggesting that this shift was secondary to tumoral extension itself. Similarly, the preSMA was infiltrated by the tumor and underactive, but this underactivity was not significantly correlated with tumoral extension.

Recruitment of the premotor cortex in the healthy hemisphere was observed before and after surgery, with different patterns for the SMA and the lateral PM cortex. Before surgery, the SMA in the healthy hemisphere was overactive and there was no change in activation level in the lateral premotor cortex. Increased activation in primary motor and premotor areas of the healthy hemisphere has already been reported in patients with brain tumors involving the primary motor cortex.^{6,7} This recruitment was related to the severity of the preoperative deficit.⁶ In our study, patients had tumors located in the SMA without SMC involvement. None of them presented a preoperative motor deficit in line with previous reports,¹⁻⁵ or had tumoral infiltration of the primary motor cortex.

Preoperative recruitment of the normal SMA did not prevent the occurrence of the SMA syndrome, suggesting that preoperative reorganization remained partial without a complete contralateral transfer of SMA function. After surgery, additional plasticity phenomena should occur in motor related areas to support a complete recovery in motor functions.

Some studies of chronic stroke patients have suggested that the intact motor cortex may play a role in recovery of motor function in the paretic hand.^{11,12} It is unlikely that intact motor areas contributed to recovery, however. First, more recent TMS report suggested that primary motor areas of the affected and not the intact hemisphere mediate motor function recovery in the paretic hand in these patients.²⁷ Second, in the present study there was no lesion of primary motor areas and there was no change in activation levels in these areas.

Recruitment of lateral premotor areas ipsilateral to the deficient limb was observed after SMA sur-

gery. It is unlikely that PMC lesion contributed to PMC recruitment in the healthy hemisphere, as PMC resection was limited, observed in four patients only, and not correlated to PMC overactivity in the healthy hemisphere. Involvement of ipsilateral PMC is now well-documented in poststroke recovery studies.^{8,10,11,13-15} Several mechanisms have been proposed to explain the recruitment of ipsilateral premotor cortex after poststroke recovery.²⁸ Mirror movements observed in some patients after recovery may explain ipsilateral premotor cortex activity. None of the patients presented such movements. Increased difficulty to perform movements is another possible cause of activation in ipsilateral motor related areas, as observed in normal subjects during complex movements. Thus, patients performing a simple task with the affected hand may recruit areas in the ipsilateral motor related areas as if they were performing a more difficult task. In the present study, all patients had completely recovered. Some patients had subjective discomfort when performing tasks with the affected hand, but this was limited to more complex tasks than the one used in the present study. Recruitment of ipsilateral premotor regions may thus be linked to the recovery process itself, in line with the fact that lateral premotor recruitment after recovery was higher when SMA resection was larger. Recruitment of ipsilateral premotor areas has already been described in fully recovered patients.^{10,29,30} The question remains debated of the role of this premotor recruitment in recovery. Many authors did not find any correlation between lateral premotor recruitment and the quality of recovery^{11,14,31} and recent studies pointed out that intact lateral premotor involvement appeared to be more prominent in patients with poor recovery.^{15,32} TMS study of premotor cortex in poststroke patients¹⁵ has also suggested that this area was actively engaged in motor recovery and that its overactivity reflected an unmasking of ipsilateral premotor circuitry. On the other hand, recent clinical²⁷ and experimental studies³³ strengthen the role of motor related areas in the damaged hemisphere. Premotor reorganization in the damaged hemisphere has been reported after ischemic motor cortex lesions in monkeys, suggesting that remote premotor areas in the damaged hemisphere may provide a potential neural substrate for motor recovery.³³ Taken together, these results suggest that premotor recruitment in the healthy hemisphere is engaged when recovery is not possible in the motor areas of the damaged hemisphere and associated with poorer recovery.

Tumoral extension and activation changes in the SMA were related to the postoperative outcome. Larger tumoral extension in the SMA was associated with larger activation decrease in the SMA beside the tumor, larger activation increase in the healthy SMA, and faster recovery. A trend was also observed between the volume of SMA resection and the magnitude of postoperative SMA activation in the healthy hemisphere. Although a causal relationship

cannot be ascertained between these observations, they suggest that larger preoperative shift in SMA activation toward the healthy hemisphere facilitates recovery and thus that intact SMA could play an adaptive role. These results also give additional information to the surgeon for patient information and to manage the postoperative care. TMS study in patients with SMA lesions may help determine if premotor recruitment in the healthy hemisphere plays an adaptive role in recovery.

Comparison between postsurgery and poststroke patients has to be conducted cautiously, however. First, in patients with low-grade tumors, compensatory mechanisms occurred before surgery, as shown by decreased LI in the SMA, whereas such compensatory mechanisms were unlikely in poststroke patients before deficit onset. Second, in contrast to most poststroke patients, none of the patients in the present study had lesion in the primary motor cortex or the corticospinal tract originating from the motor cortex as assessed on clinical, imaging, and intraoperative cortico-subcortical stimulations examinations.^{34,35} Third, all patients had completely recovered at the time of the postoperative fMRI, at least according to the motor scale we used. Thus, activation changes that were observed were associated with good recovery, whereas in poststroke studies patients had residual motor impairments. Therefore, activation changes were correlated with onset and duration of recovery in the present study and not with the quality of the recovery.

By which anatomic pathways could the ipsilateral premotor cortex compensate for SMA dysfunction? Anatomic studies have shown that SMA is richly connected to the ipsilateral primary motor cortex, preSMA, PMC, cingulum, parietal lobe, basal ganglia, thalamus, and spine, and to the homologous contralateral motor-related regions.^{16-18,36} Before surgery, it is possible that the ipsilateral SMA supplied impaired SMA function using interhemispheric SMA projections. After surgery, such a mechanism is unlikely because of the SMA resection. The SMA in the healthy hemisphere may also compensate for SMA dysfunction through interhemispheric connections to the primary motor cortex in the tumoral hemisphere. Nine out of 12 patients had a partial resection of the corpus callosum, and whether these interhemispheric connections were still functional after surgery remains to be determined. Uncrossed corticospinal projections are another possible candidate, as suggested previously.^{12,15}

Most corticospinal projections originate from the primary motor cortex but a substantial component of the corticospinal system originates from both lateral and medial premotor areas in the frontal lobe.³⁶ Although there was no lesion of the corticospinal tract in these patients, uncrossed projections to the spine from SMA and PMC of the healthy hemisphere may be recruited to compensate for deficient SMA function. Finally, in monkeys, the SMA sends nearly symmetric bilateral projections to the striatum.³⁷ These bilateral projections may also participate in recovery.

Basic movement characteristics, including frequency, velocity, amplitude, and force, are known to influence motor and premotor activation.^{24,38-43} Kinematics study of a patient with lesion involving the SMA, cingulate, and callosal areas showed that movement rate of the hand contralateral to the lesion was irregular.⁴⁴ In patients with surgical resections of the SMA, bilateral reduced velocity was observed during unilateral targeted arm movements.⁴⁵ In the present study, although patients were trained to perform simple movements at 0.5 Hz, and visually monitored during the MR session, subtle changes of these variables may have occurred across subjects. Thus, interindividual variations may contribute to explain part of the activation variability. However, no statistical difference was detected either in the contralateral primary motor cortex or in the global amount of SMA activation between tasks or between controls and patients before and after surgery. These two regions are those that are the most influenced by changes in movement characteristics. Moreover, movement characteristics were not shown to influence activation levels in the ipsilateral hemisphere (except for cerebellum) without similar or more significant contralateral involvement.^{24,38-42} Therefore, variation in movement characteristics across groups cannot explain the main results of the present study, namely the balance observed between ipsi- and contralateral medial and lateral premotor activation and its correlation with recovery characteristics.

Acknowledgment

The authors thank F. Isel, PhD, for statistical advice.

References

1. Laplane D, Talairach J, Meininger V, Bancaud J, Orgogozo JM. Clinical consequences of corticectomies involving the supplementary motor area in man. *J Neurol Sci* 1977;34:301-314.
2. Rostomily RC, Berger MS, Ojemann GA, Lettich E. Postoperative deficits and functional recovery following removal of tumors involving the dominant hemisphere supplementary motor area. *J Neurosurg* 1991;75:62-68.
3. Bleasel A, Comair Y, Lüders H. Surgical ablations of the mesial frontal lobe in humans. In: Lüders H, ed. *Supplementary sensorimotor area*. Philadelphia: Lippincott-Raven, 1996:217-235.
4. Krainik A, Lehericy S, Duffau H, et al. Role of the supplementary motor area in motor deficit following medial frontal lobe surgery. *Neurology* 2001;57:871-878.
5. Krainik A, Lehericy S, Duffau H, et al. Postoperative speech disorder after medial frontal surgery: role of the supplementary motor area. *Neurology* 2003;60:587-594.
6. Krings T, Topper R, Willmes K, Reinges MH, Gilsbach JM, Thron A. Activation in primary and secondary motor areas in patients with CNS neoplasms and weakness. *Neurology* 2002;58:381-390.
7. Carpentier AC, Constable RT, Schlosser MJ, et al. Patterns of functional magnetic resonance imaging activation in association with structural lesions in the rolandic region: a classification system. *J Neurosurg* 2001;94:946-954.
8. Chollet F, DiPiero V, Wise RJ, Brooks DJ, Dolan RJ, Frackowiak RS. The functional anatomy of motor recovery after stroke in humans: a study with positron emission tomography. *Ann Neurol* 1991;29:63-71.
9. Weiller C, Ramsay SC, Wise RJ, Friston KJ, Frackowiak RS. Individual patterns of functional reorganization in the human cerebral cortex after capsular infarction. *Ann Neurol* 1993;33:181-189.
10. Cramer SC, Nelles G, Benson RR, et al. A functional MRI study of subjects recovered from hemiparetic stroke. *Stroke* 1997;28:2518-2527.
11. Cao Y, D'Olhaberriague L, Vikingstad EM, Levine SR, Welch KM. Pilot study of functional MRI to assess cerebral activation of motor function after poststroke hemiparesis. *Stroke* 1998;29:112-122.

12. Caramia MD, Palmieri MG, Giacomini P, Iani C, Dally L, Silvestrini M. Ipsilateral activation of the unaffected motor cortex in patients with hemiparetic stroke. *Clin Neurophysiol* 2000;111:1990–1996.
13. Nelles G, Spiekermann G, Jueptner M, et al. Reorganization of sensory and motor systems in hemiplegic stroke patients. A positron emission tomography study. *Stroke* 1999;30:1510–1516.
14. Feydy A, Carlier R, Roby-Brami A, et al. Longitudinal study of motor recovery after stroke: recruitment and focusing of brain activation. *Stroke* 2002;33:1610–1617.
15. Johansen-Berg H, Rushworth MF, Bogdanovic MD, Kischka U, Wimalaratna S, Matthews PM. The role of ipsilateral premotor cortex in hand movement after stroke. *Proc Natl Acad Sci USA* 2002;99:14518–14523.
16. Luppino G, Matelli M, Camarda R, Rizzolatti G. Corticocortical connections of area F3 (SMA-proper) and area F6 (pre-SMA) in the macaque monkey. *J Comp Neurol* 1993;338:114–140.
17. Liu J, Morel A, Wannier T, Rouiller EM. Origins of callosal projections to the supplementary motor area (SMA): a direct comparison between pre-SMA and SMA-proper in macaque monkeys. *J Comp Neurol* 2002;443:71–85.
18. Maier MA, Armand J, Kirkwood PA, Yang HW, Davis JN, Lemon RN. Differences in the corticospinal projection from primary motor cortex and supplementary motor area to macaque upper limb motoneurons: an anatomical and electrophysiological study. *Cereb Cortex* 2002;12:281–296.
19. Cote R, Battista RN, Wolfson C, Boucher J, Adam J, Hachinski V. The Canadian Neurological Scale: validation and reliability assessment. *Neurology* 1989;39:638–643.
20. Brett M, Leff AP, Rorden C, Ashburner J. Spatial normalization of brain images with focal lesions using cost function masking. *Neuroimage* 2001;14:486–500.
21. Talairach J, Tournoux P. Co-planar stereotaxic atlas of the human brain. New York: Thieme, 1988.
22. Picard N, Strick PL. Motor areas of the medial wall: a review of their location and functional activation. *Cereb Cortex* 1996;6:342–353.
23. Fontaine D, Capelle L, Duffau H. Somatotopy of the supplementary motor area: evidence from correlation of the extent of surgical resection with the clinical patterns of deficit. *Neurosurgery* 2002;50:297–303; discussion 303.
24. Jenkins IH, Passingham RE, Brooks DJ. The effect of movement frequency on cerebral activation: a positron emission tomography study. *J Neurol Sci* 1997;151:195–205.
25. Holodny AI, Schulder M, Liu WC, Wolko J, Maldjian JA, Kalnin AJ. The effect of brain tumors on BOLD functional MR imaging activation in the adjacent motor cortex: implications for image-guided neurosurgery. *AJNR Am J Neuroradiol* 2000;21:1415–1422.
26. Pineiro R, Pendlebury S, Johansen-Berg H, Matthews PM. Altered hemodynamic responses in patients after subcortical stroke measured by functional MRI. *Stroke* 2002;33:103–109.
27. Werhahn KJ, Conforto AB, Kadom N, Hallett M, Cohen LG. Contribution of the ipsilateral motor cortex to recovery after chronic stroke. *Ann Neurol* 2003;54:464–472.
28. Calautti C, Baron J-C. Functional neuroimaging studies of motor recovery after stroke in adults. *Stroke* 2003;34:1553–1566.
29. Seitz RJ, Hoflich P, Binkofski F, Tellmann L, Herzog H, Freund HJ. Role of the premotor cortex in recovery from middle cerebral artery infarction. *Arch Neurol* 1998;55:1081–1088.
30. Weiller C, Chollet F, Friston KJ, Wise RJ, Frackowiak RS. Functional reorganization of the brain in recovery from striatocapsular infarction in man. *Ann Neurol* 1992;31:463–472.
31. Netz J, Lammers T, Homberg V. Reorganization of motor output in the non-affected hemisphere after stroke. *Brain* 1997;120:1579–1586.
32. Ward N, Brown M, Thompson A, Frackowiak R. Neural correlates of outcome after stroke: a cross-sectional fMRI study. *Brain* 2003;126:1430–1448.
33. Frost SB, Barbay S, Friel KM, Plautz EJ, Nudo RJ. Reorganization of remote cortical regions after ischemic brain injury: a potential substrate for stroke recovery. *J Neurophysiol* 2003;89:3205–3214.
34. Duffau H, Capelle L, Denvil D, et al. Usefulness of intraoperative electrical subcortical mapping during surgery for low-grade gliomas located within eloquent brain regions: functional results in a consecutive series of 103 patients. *J Neurosurg* 2003;98:764–778.
35. Lehericy S, Duffau H, Cornu P, et al. Correspondence between functional magnetic resonance imaging somatotopy and individual brain anatomy of the central region: comparison with intraoperative stimulation in patients with brain tumors. *J Neurosurg* 2000;92:589–598.
36. Dum RP, Strick PL. The origin of corticospinal projections from the premotor areas in the frontal lobe. *J Neurosci* 1991;11:667–689.
37. McGuire P, Bates J, Goldmann-Rakic P. Interhemispheric integration: II. Symmetry and convergence of the corticostriatal projections of the left and the right principal sulcus (PS) and the left and the right supplementary motor area (SMA) of the rhesus monkey. *Cereb Cortex* 1991;1:408–417.
38. Dettmers C, Fink GR, Lemon RN, et al. Relation between cerebral activity and force in the motor areas of the human brain. *J Neurophysiol* 1995;74:802–815.
39. Cramer SC, Weisskoff RM, Schaechter JD, et al. Motor cortex activation is related to force of squeezing. *Hum Brain Mapp* 2002;16:197–205.
40. Deiber MP, Honda M, Ibanez V, Sadato N, Hallett M. Mesial motor areas in self-initiated versus externally triggered movements examined with fMRI: effect of movement type and rate. *J Neurophysiol* 1999;81:3065–3077.
41. Sadato N, Ibanez V, Deiber MP, Campbell G, Leonardo M, Hallett M. Frequency-dependent changes of regional cerebral blood flow during finger movements. *J Cereb Blood Flow Metab* 1996;16:23–33.
42. Wexler BE, Fulbright RK, Lacadie CM, et al. An fMRI study of the human cortical motor system response to increasing functional demands. *Magn Reson Imaging* 1997;15:385–396.
43. Waldvogel D, van Gelderen P, Ishkii K, Hallett M. The effect of movement amplitude on activation in functional magnetic imaging. *J Cereb Blood Flow Metab* 1999;19:1209–1212.
44. Stephan KM, Binkofski F, Halsband U, et al. The role of ventral medial wall motor areas in bimanual co-ordination. A combined lesion and activation study. *Brain* 1999;122:351–368.
45. Bell KR, Traylor GH, Anderson ME, Berger MS, Ojemann GA. Features of targeted arm movement after unilateral excisions that included the supplementary motor area in humans. *Brain Res* 1994;655:202–212.