

Root canal morphology of South Asian Indian maxillary molar teeth

Shishir Singh¹, Mansing Pawar¹

Correspondence: Dr. Shishir Singh,
Email: drshishirs@hotmail.com

¹Department of Conservative Dentistry and Endodontics, Government Dental College and Hospital, St. George Hospital compound, D Mello Road, Near GPO, Fort. Mumbai, Maharashtra, India

ABSTRACT

Objective: The objective was to study the root canal morphology of South Asian Indian Maxillary molars using a tooth clearing technique. **Materials and Methods:** Hundred teeth each comprising of first, second, and third molars collected from different dental schools and clinics in India were subjected to standard dye penetration, decalcification and clearing procedure before being studied. **Results:** The first molar mesiobuccal roots exhibited 69% Type I, 24% Type II, 4% Type IV, 2% Type V, and 1% exhibited a Vertuccis Type VIII canal anatomy. In the group with three separate roots the second molar mesiobuccal roots in exhibited 80.6% Type I, 15.3% Type II, 2.7% Type IV, and 1.4% Type V canal anatomy while the third molars mesiobuccal roots exhibited 57.4% Type I, 32% Type II, 2.1% Type III, 8.5% Type IV, 1% had a Type V canal anatomy in the similar group. **Conclusion:** A varied root canal anatomy was seen in the mesiobuccal root canal of the maxillary molars.

Key words: Clearing, India ink, maxillary molars, morphology, root canal, Vertucci

INTRODUCTION

The root canal anatomy of human teeth has puzzled the dentist to no end and has been a source of immense research interest. Starting from way back in 1925 when Hess^[1] studied the root canal anatomy by injecting Vulcanite resin into the root canals it was Okumura^[2] who stressed the advantages of dye injection and clearing of the teeth for studying the morphology and anatomy of root canals and gave a simple root canal classification.

Various techniques such as sectioning, radiography, dye penetration and clearing, posttreatment clinical examination to modern day cone beam computed tomography techniques have been used to study the root canal anatomy.^[3-7] Similarly, various classifications for root canal morphology have been suggested by Okumura 1927, Weine *et al.* and Vertucci.^[2,4,5]

Starting from the Caucasians to the Africans and Asians root canal anatomy patterns follow a racial

characteristic making endodontic treatment more challenging for the practitioners.^[8-23] The various root canal anatomies constituting lateral canals, apical deltas, intercanal anastomoses, and canal designs with their complexities itself, provide conducive environments for microorganisms to proliferate causing periapical infections whose successful elimination plays a major role in the outcome of the endodontic treatment.^[24] Finally, it becomes the responsibility of the endodontist to rid these canals of microbial biofilms with proper canal and shaping techniques using various medications and irrigants. A thorough knowledge of the root canal anatomy helps achieve this goal successfully. With globalization and the world coming closer people from various countries and races are found settled all over the world. Their dental needs and treatments confirm the fact that having a better picture of the root canal anatomy characteristics race wise will only but facilitate a more predictable outcome of the treatment.

How to cite this article: Singh S, Pawar M. Root canal morphology of South Asian Indian maxillary molar teeth. *Eur J Dent* 2015;9:133-44.

Copyright © 2015 Dental Investigations Society.

DOI: 10.4103/1305-7456.149662

The aim of this research was to study the following: (i) Number of roots and their morphology; (ii) number of root canals per tooth; (iii) root canal configuration in each root using Vertuccis classification, with additional modifications; (iv) presence and location of lateral canals and intercanal communications. This study is one of its first on the morphology of maxillary first, second, and third molars together in the Indian sample using the dye penetration and clearing technique.

MATERIALS AND METHODS

Three hundred permanent maxillary extracted molars constituting 100 maxillary first, second, and third molars with mature apices from indigenous South Asian Indians of varying age and sex were collected from different dental schools and dental clinics in India. The sample teeth were washed under tap water for 30 minutes and immersed in 2.5% sodium hypochlorite (Mumbai Healthcare Industries, India) for 30 minutes to remove adherent soft tissue. The adherent soft tissue was physically scraped using a scalpel blade and an ultrasonic scaler cleared calculus or stains after which they were stored in distilled water with Thymol iodide crystals.^[5,11,15,17,19-23,53]

Standard access preparations were done occlusally using tungsten carbide fissure bur/ diamond point in an air turbine handpiece with water irrigation. Any remaining caries was removed at this time. Canal orifices were identified visually or with a DG 16 probe or #8 K-flex file avoiding any damage/alteration of the pulpal floor and the root canal anatomy. Preparatory protocols were standardized by carrying out the procedures by a single operator.

The teeth were immersed in 2.5% sodium hypochlorite (Mumbai Healthcare Industries, India) for 24 h to dissolve the organic debris and pulp tissue remnants from the root canal systems. After which, the glass bottles containing the teeth and sodium hypochlorite were placed in an ultrasonic bath containing water for 30 min. Subsequently, the teeth were rinsed under running tap water for 2 h and placed on tissue paper and allowed to dry overnight. Drying is important to aid penetration of ink in the next stage.

A plastic disposable endodontic irrigating syringe gauge 27 needle was used to inject the non waterproof India ink (LOBAL Chemie Laboratory reagents and Fine Chemical, India) into the root canal systems.^[19-23] At the same time, a suction tip was placed at the root apex to draw the ink through the root canal system.

The appearance of ink at the apical foramen indicated the end of the process. The teeth were dried overnight again for 12 h.

Thereafter, the teeth were immersed in 10% nitric acid (Fisher Scientific, Qualigens Fine Chemicals, India) at room temperature for decalcification; the end point of which was determined by taking radiographs at daily intervals. The nitric acid solution was changed daily and agitated frequently, as demineralization occurs at the top of the static acid than the bottom. At the end of decalcification, the teeth were washed in running tap water for 4 h. Excess water was removed and the teeth were left to dry on tissue paper.^[19-23]

The teeth were dehydrated using ascending concentrations of methanol (Carbimol A.R. Himedia Laboratories, India) at 70%, 95%, and 100% consecutively for 1 day each. This meticulous process of dehydration permitted adequate penetration of the clearing agent. After dehydration, the teeth were placed again on tissue paper to dry for 2 h. The teeth were immersed in 2% methyl salicylate (Oil of Wintergreen, MERCK specialities Pvt. Ltd.) to render them transparent.^[19-23]

The transparent specimens were then examined by the naked eye as well as a magnifying lens (3X), dipped in methyl salicylate under special halogen lighting so as to improve the coefficient of refraction. The data regarding root and canal morphology of each sample were tabulated based on the number of roots, shape of roots, number of root canals, number of apical foramina, root canal configuration according to Vertuccis classification and number of lateral canals/inter-canal communications/canal anastomoses and compared statistically using the Chi-square test. Photographs of the specimens were taken with a Nikon D 40 camera with a Macro lens (Sigma AF105 mm 1:2.8 EX DG Macro) [Figure 1 and 2].

RESULTS

The findings of first, second, and the third molars are presented in Table 1.

Of the hundred maxillary first molars all hundred (100%) had three roots and three root canals. Ninety-three (93%) teeth had three apical foramen and six (6%) teeth had four apical foramen. All hundred teeth (100%) had three separate roots; the mesiobuccal roots exhibited sixty-nine (69%) with a Vertuccis Type I root canal anatomy, twenty-four (24%) had a Type II canal anatomy, four (4%) had a Type IV canal anatomy,

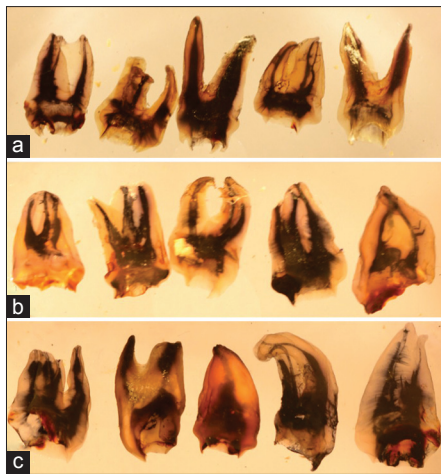


Figure 1: Photographs of injected dye and cleared specimens; maxillary first molars (a); second molars (b) and third molars (c) showing various roots with root canal numbers and canal anatomies

two (2%) had a Type V canal anatomy and one (1%) exhibited a Vertucci Type VIII canal anatomy. All the hundred (100%) distobuccal roots had a Type I root canal anatomy. All the hundred (100%) palatal roots had a Type I root canal anatomy. Twenty-eight (28%) teeth exhibited an MB2 canal. Three mesiobuccal roots (3%) had lateral canals with one (1%) in the middle third and two (2%) in the apical thirds. Six (6%) teeth showed intercommunications. Twenty-eight (28%) of maxillary first molars had an MB2 canal.

Of the hundred maxillary second molars, five (5%) teeth had one root and ninety five (95%) teeth had three roots. Five (5%) teeth had one root canal, thirteen (13%) teeth had two root canals, eighty-two (82%) teeth had three root canals. Five (5%) teeth had a single apical foramen, twenty-three (23%) teeth had two apical foramen, sixty-nine (69%) teeth had three apical foramen, and three (3%) had four apical foramen.

Seventy-two (72%) teeth had three separate roots, twenty-three (23%) had two separate roots and five (5%) teeth had a single root. In the group with three separate roots, the mesiobuccal roots exhibited fifty-eight (80.55%) with a Vertucci Type I root canal anatomy, eleven (15.3%) had a Type II canal anatomy, two (2.7%) had a Type IV canal anatomy, one (1.4%) had a Type V canal anatomy. All the seventy two (100%) distobuccal roots had a Type I root canal anatomy. Seventy (97.2%) palatal roots had a Type I root canal anatomy, one (1.4%) had a Type III anatomy and one (1.4%) palatal root had a Type IV root canal anatomy. In the group with two roots all 23 (100%) had Vertucci Type I anatomy for the buccal and palatal roots. In the Group with a single root, all 5 (100%) exhibited a type I root canal anatomy.

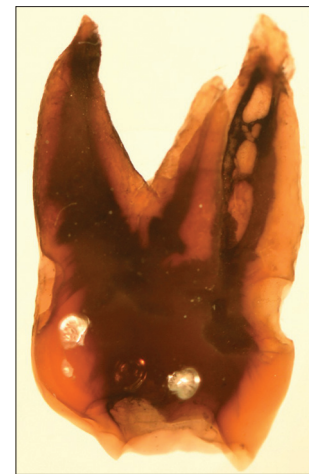


Figure 2: Cleared maxillary first molar showing intercommunications between canals

Six mesiobuccal roots (6%) had lateral canals with three (3%) in the middle third and three (3%) in the apical thirds. Six (6%) teeth showed intercommunications. Thirteen (18%) of maxillary second molars had an MB2 canal.

Of the hundred maxillary third molars, twenty (20%) teeth had one root, thirty-three (33%) teeth had two roots and forty seven (47%) teeth had three roots. Nineteen (19%) teeth had one root canal, thirty-three (33%) teeth had two root canals, forty-three (43%) teeth had three root canals, and five (5%) teeth had four root canals. Twenty (20%) teeth had a single apical foramen, thirty-three (33%) teeth had two apical foramen, forty-three (43%) teeth had three apical foramen, and four (4%) teeth had four apical foramen. Forty-seven (47%) teeth had three separate roots, thirty-three teeth (33%) had two separate roots and twenty (20%) teeth had a single conical root. In the group with three separate roots, the mesiobuccal roots exhibited twenty-seven (57.4%) with a Vertucci Type I root canal anatomy, fifteen (32%) had a Type II canal anatomy, one (2.1%) had a Type III canal anatomy and four (8.5%) teeth had a Type IV canal anatomy. All the forty-seven (100%) distobuccal roots and Palatal roots had a Type I root canal anatomy. In the group with thirty three two roots; the buccal roots showed 31 (94%) with Vertucci Type I anatomy, one (3%) Type III and one (3%) Type IV, As for the palatal roots thirty two (97%) teeth had a Type I anatomy and one (3%) tooth had a Type IV anatomy. In the Group with a twenty single roots eighteen (90%) exhibited a type I root canal anatomy, one (5%) Type III and one (5%) exhibited Type V canal anatomy. Four mesiobuccal roots (4%) had lateral canals with all four (4%) in the apical thirds. Two (2%) teeth showed intercommunications. Nineteen (40.5%) of maxillary third molars had a MB2 canal.

Table 1: Percentage of maxillary first, second, and third molars with root numbers, root canal numbers, foramen number, root shape, and canal anatomy

	Maxillary (%)														
	First molars	Second molars	Third molars												
Root numbers															
One	-	5	20												
Two	-	-	33												
Three	100	95	47												
Four	-	-	-												
Root canal numbers															
One	-	5	19												
Two	-	13	33												
Three	100	82	43												
Four	-	-	5												
Five	-	-	-												
Foramen number															
One	-	5	20												
Two	-	23	33												
Three	93	69	43												
Four	7	3	4												
Five	-	-	-												
Root shape															
Three roots: All separate	100	72	47												
Three roots: B roots fused	-	-	-												
Three roots: DB and P roots fused	-	-	-												
Three roots: All fused	-	-	-												
Two roots: Separate	-	23	33												
Two roots: Fused	-	-	-												
One root: Conical	-	5	20												
One root: C shaped	-	-	-												
Four roots: Fused	-	-	-												
Four roots: Other	-	-	-												
Lateral canals															
Coronal	-	-	-												
Middle	1	3	-												
Apical	2	3	4												
Inter communications	6	3	2												
Number of roots	Three roots (100) (%)			Three roots (72) (%)			Two roots (23) (%)		One root (5)	Three roots (47) (%)			Two roots (33) (%)		One root (20)
Roots	MB	DB	P	MB	DB	P	B	P	%	MB	DB	P	B	P	%
Canal anatomy															
Type I: 1	69	100	100	80.6	100	97.2	100	100	100	57.4	100	100	94	97	90
Type II: 2-1	24	-	-	15.3	-	-	-	-	-	32	-	-	-	-	-
Type III: 1-2-1	-	-	-	-	-	1.4	-	-	-	2.1	-	-	3	-	5
Type IV: 2	4	-	-	2.7	-	1.4	-	-	-	8.5	-	-	3	3	-
Type V: 1-2	2	-	-	1.4	-	-	-	-	-	-	-	-	-	-	5
Type VI: 2-1-2	-	-	-	-	-	-	-	-	-	-	-	-	-	-	-
Type VII: 1-2-1-2	-	-	-	-	-	-	-	-	-	-	-	-	-	-	-
Type VIII: 3	1	-	-	-	-	-	-	-	-	-	-	-	-	-	-
Additional	-	-	-	-	-	-	-	-	-	-	-	-	-	-	-

MB1: Mesiobuccal one, DB: Distobuccal, P: Palatal

DISCUSSION

Studies related to root canal anatomy of maxillary first, second, and third molars are summarized

in Table 2. The use of the dye penetration and clearing technique as mentioned by Okumura and Robertson *et al.* with its various advantages has been in use for decades by various researchers

Table 2: Percentage of maxillary first, second, and third molars root canal anatomy and numbers in various studies

Investigators	Sample size	Technique	Country	Roots	Types															
					I	II	III	IV	V	VI	VII	VIII	IX	X						
Maxillary first molars																				
Moral 1914 ^[25]	100 [^]	<i>In vitro</i> sectioning	Unknown	Mesiobuccal Distobuccal Palatal	37 * *									63 * *						
Zurcher 1925 ^[26]	40 [^]	<i>In vitro</i> clearing	Unknown	Mesiobuccal Distobuccal Palatal	57 100 100									42.5 0 0						
Hess 1925 ^[1]	513 [^]	<i>In vitro</i> clearing	Unknown	Mesiobuccal Distobuccal Palatal	46.4 100 100									53.6 0 0						
Okumura 1927 ^[2]	299 [^]	<i>In vitro</i> clearing	Unknown	Mesiobuccal Distobuccal Palatal	47.1 * *									52.9 * *						
Weine 1969 ^[4]	208 ^{^^^}	<i>In vitro</i> sectioning	USA	Mesiobuccal Distobuccal Palatal	48.5 * *	37.5 * *	14 * *	0 * *						# # #	# # #	# # #	# # #	# # #		
Sykaras and Economou 1971 ^[27]	100 [^]	<i>In vitro</i> radiographic	Unknown	Mesiobuccal Distobuccal Palatal	68 * *									32 * *						
Pineda and Kuttler 1972 ^[8]	262 ^{^^^}	<i>In vitro</i> radiographic	Mexico	Mesiobuccal Distobuccal Palatal	39.3 96.4 100	12.2 0 0	0 0 0	23.7 3.6 0	12.8 0 0					12 0 0	0 0 0	0 0 0	0 0 0	0 0 0		
Seidberg <i>et al.</i> 1973 ^[28]	100 [^]	<i>In vitro</i> sectioning	USA	Mesiobuccal Distobuccal Palatal	38 * *	37 * *	25 * *	0 * *	# # #					# # #	# # #	# # #	# # #	# # #		
Nosonowitz and Brenner 1973 ^[29]	336 [^]	<i>In vivo</i> RCT treatments	Unknown	Mesiobuccal Distobuccal Palatal	35.4 * *									64.6 * *						
Slowey 1974 ^[25]	103 [^]	<i>In vivo</i> clinical radiographic	Unknown	Mesiobuccal Distobuccal Palatal	49.6 * *									50.4 * *						
Pomeranz and Fishelberg 1974 ^[9]	100 [^]	<i>In vitro</i> clearing	USA	Mesiobuccal Distobuccal Palatal	72 * *									28 * *						
Pomeranz and Fishelberg 1974 ^[9]	71 [^]	<i>In vivo</i> clinical RCT	USA	Mesiobuccal Distobuccal Palatal	71.8 * *									28.2 * *						
Acosta Vigouroux and Trugeda Bosaans 1978 ^[31]	134 [^]	<i>In vitro</i> clinical+magnification	Chile	Mesiobuccal Distobuccal Palatal	28.4 100 100									71.6 0 0						

Contid...

Investigators	Sample size	Technique	Country	Roots	Types									
					I	II	III	IV	V	VI	VII	VIII	IX	X
Evenot 1999 ^[32]	378 ^{AA}	<i>In vitro</i> radiographic	France	Mesiobuccal Distobuccal Palatal	28.8 * *	23.5 * *	38.8 * *	8.8 * *	# # #	# # #	# # #	# # #	# # #	# # #
Hartwell and Bellizzi 1982 ^[33]	538 ^A	<i>In vivo</i> RCT treatments	USA	Mesiobuccal Distobuccal Palatal	91.4 100 99.8				18.6 0 0.2					
Gray 1983 ^[34]	85 ^A	<i>In vitro</i> clearing	USA	Mesiobuccal Distobuccal Palatal	41.1 97.6 100				58.9 2.4 0					
Vertucci 1984 ^[5]	100 ^{AAA}	<i>In vitro</i> clearing	USA	Mesiobuccal Distobuccal Palatal	45 100 100	37 0 0	0 0 0	18 0 0	0 0 0	0 0 0	0 0 0	0 0 0	0 0 0	0 0 0
Neaverth <i>et al.</i> 1987 ^[35]	228 ^A	<i>In vivo</i> clinical RCT	USA	Mesiobuccal Distobuccal Palatal	19.3 * *				80.3 * *					
Weller and Hartwell 1989 ^[10]	835 ^A	<i>In vivo</i> clinical radiographic	USA	Mesiobuccal Distobuccal Palatal	61 * *				39 * *					
Gilles and Reader 1990 ^[36]	21 ^{AAA}	<i>In vitro</i> clearing+SEM	USA	Mesiobuccal Distobuccal Palatal	9.5 * *	52.4 * *	33.3 * *	4.8 * *	0 * *	0 * *	0 * *	0 * *	0 * *	0 * *
Kulild and 1990 Peters ^[37]	51 ^A	<i>In vitro</i> microscopic+clinical	USA	Mesiobuccal Distobuccal Palatal	3.9 * *				96.1 * *					
Pécora <i>et al.</i> 1992 ^[11]	120 ^{AA}	<i>In vitro</i> clearing	Brazilian	Mesiobuccal Distobuccal Palatal	75 * *	17.5 * *	7.5 * *	0 * *	0 * *	0 * *	0 * *	0 * *	0 * *	0 * *
Thomas <i>et al.</i> 1993 ^[38]	216 ^{AAA}	<i>In vitro</i> radiographic	Australia	Mesiobuccal Distobuccal Palatal	26.4 95.7 97.7	19.9 0.5 0.9	27.3 0.5 0.5	1.9 1.4 0	12 0 0.9	12.5 1.9 0	0 0 0	0 0 0	0 0 0	0 0 0
Fogel <i>et al.</i> 1994 ^[39]	208 ^{AA}	<i>In vivo</i> clinical magnification	Canada	Mesiobuccal Distobuccal Palatal	28.9 * *	39.4 * *	31.7 * *	# * *	# * *	# * *	# * *	# * *	# * *	# * *
Caliskan <i>et al.</i> 1995 ^[17]	100 ^{AAA}	<i>In vitro</i> clearing	Turkey	Mesiobuccal Distobuccal Palatal	34.43 98.36 93.44	40.98 0 3.28	0 0 0	11.48 0 0	1.64 0 3.28	11.48 0 0	0 0 0	0 0 0	0 0 0	0 0 0
Zaatar <i>et al.</i> 1997 ^[12]	133 ^A	<i>In vivo</i> clinical radiographic	Kuwait	Mesiobuccal Distobuccal Palatal	59.4 100 100				40.6 0 0					

Contid...

Table 2: Contd...

Investigators	Sample size	Technique	Country	Roots	Types										
					I	II	III	IV	V	VI	VII	VIII	IX	X	
Imura et al. 1998 ^[10]	42 [^]	<i>In vitro</i> clearing	Unknown	Mesiobuccal Distobuccal Palatal	19 * *	9.5 * *	71.4 * *	0 * *	0 * *	# # #	# # #	# # #	# # #	# # #	# # #
Weine et al. 1999 ^[18]	293 ^{^^}	<i>In vitro</i> radiographic	Japan	Mesiobuccal Distobuccal Palatal	42 * *	24.2 * *	30.4 * *	3.4 * *	# # #	# # #	# # #	# # #	# # #	# # #	# # #
Stropko 1999 ^[3]	1096 [^]	<i>In vivo</i> clinical patient record	USA	Mesiobuccal Distobuccal Palatal	26.6 * *					73.2 * *					
Sempira and Hartwell 2000 ^[14]	130 [^]	<i>In vivo</i> clinical RCT magnification	Unknown	Mesiobuccal Distobuccal Palatal	66.9 * *					33.1 * *					
Al Shalabi et al. 2000 ^[19]	83 ^{^^^}	<i>In vitro</i> clearing	Irish	Mesiobuccal Distobuccal Palatal	19.3 95.18 97.59	15.66 0 0	0 0 0	36.14 0 0	6.02 2.4 1.2	6.02 0 0	16.86 0 0	1.7 0 0	1.2 0 0	0 0 0	0 0 0
Wasti et al. 2001 ^[20]	30 ^{^^^}	<i>In vitro</i> clearing	Pakistani	Mesiobuccal Distobuccal Palatal	33.3 83.3 66.7	23.3 0 0	0 0 0	23.3 0 0	13.3 16.7 33.3	6.8 0 0	0 0 0	0 0 0	0 0 0	0 0 0	0 0 0
Alavi et al. 2002 ^[21]	52 ^{^^^}	<i>In vitro</i> clearing	Thai	Mesiobuccal Distobuccal Palatal	32.7 98.1 100	17.3 1.9 0	1.9 0 0	44.2 0 0	1.9 0 0	0 0 0	0 0 0	0 0 0	1 0 0	0 0 0	1.9 0 0
Buhrley et al. 2002 ^[61]	208 [^]	<i>In vivo</i> clinical RCT magnification	Unknown	Mesiobuccal Distobuccal Palatal	29.9 * *					71.1 * *					
Wolcott et al. 2002 ^[42]	1193 [^]	<i>In vivo</i> Clinical RCT and retreatments	Unknown	Mesiobuccal Distobuccal Palatal	39 * *					61 * *					
Sert and Bayirli 2004 ^[22]	100 ^{^^^} males	<i>In vitro</i> clearing	Turkey	Mesiobuccal Distobuccal Palatal	3 92 94	42 1 0	19 5 3	29 1 3	2 1 0	2 0 0	1 0 0	2 0 0	0 0 0	0 0 0	0 0 0
Sert and Bayirli 2004 ^[22]	100 ^{^^^} females	<i>In vitro</i> clearing	Turkey	Mesiobuccal Distobuccal Palatal	10 89 95	37 5 0	10 2 0	27 4 0	2 0 2	4 0 0	10 0 0	0 0 0	0 0 0	0 0 0	0 0 3
Villegas et al. 2004 ^[43]	30 ^{^^^}	<i>In vitro</i> clearing	Japan	Mesiobuccal Distobuccal Palatal	26 * *	14 * *	43 * *	10 * *	7 * *	0 * *	0 * *	0 * *	0 * *	0 * *	0 * *
Yoshioka et al. 2005 ^[44]	98 ^{^^}	<i>In vitro</i> clearing	Japan	Mesiobuccal Distobuccal Palatal	32.7 * *	35.7 * *	30.6 * *	1 * *	# # #	# # #	# # #	# # #	# # #	# # #	# # #

Contid...

Table 2: Contd...

Investigators	Sample size	Technique	Country	Roots	Types												
					I	II	III	IV	V	VI	VII	VIII	IX	X			
Eder et al. 2006 ^[46]	152 ^{AAA}	In vitro computed tomography and clearing	Austria	Mesiobuccal	5.9	31.6	0	59.9	0.66	0.66	0	0	0	0	0	0	0
				Distobuccal	*	*	*	*	*	*	*	*	*	*	*	*	*
				Palatal	*	*	*	*	*	*	*	*	*	*	*	*	*
Rwenyonyi et al. 2007 ^[65]	221 ^{AAA}	In vitro clearing	Ugandan	Mesiobuccal	75.1	4.1	0.9	11.3	5.8	1.4	0.9	0	0	0.5	0	0	0
				Distobuccal	97.7	0.5	0	0	1.8	0	0	0	0	0	0	0	0
				Palatal	100	0	0	0	0	0	0	0	0	0	0	0	0
Shahi et al. 2007 ^[47]	137 ^{AAA}	In vitro clearing	Iranian	Mesiobuccal	37.96	24.08	0	24.08	9.5	4.38	0	0	0	0	0	0	0
				Distobuccal	96.36	0	0	0	3.64	0	0	0	0	0	0	0	0
				Palatal	99.27	0	0	0	0.73	0	0	0	0	0	0	0	0
Ameen and Hassan 2008 ^[48]	180 ^A	In vitro clearing	Egyptian	Mesiobuccal	42.3					57.7							
				Distobuccal	100					0							
				Palatal	100					0							
Pattanshetti et al. 2008 ^[16]	55 ^{AA}	In vivo clinical radiographic	Kuwait	Mesiobuccal	58.2	33.6	8.2	0	#	#	#	#	#	#	#	#	#
				Distobuccal	100	0	0	0	#	#	#	#	#	#	#	#	#
				Palatal	100	0	0	0	#	#	#	#	#	#	#	#	#
Sert et al. 2011 ^[23]	330 ^{AAA}	In vitro clearing	Turkey	Mesiobuccal	43.48	14.85	47.88	10	17.88	3.64	2.42	1.82	0	0	0	0	0
				Distobuccal	95.76	1.21	1.82	0.3	1.21	0	0	0	0	0	0	0	0
				Palatal	96.67	0	0.91	0.61	1.51	0	0	0	0	0.3	0	0	0
Silva et al. 2014 ^[51]	314 ^A	In vivo computed tomography	Brazil	Mesiobuccal	52.87					42.63							
				Distobuccal	100					0							
				Palatal	100					0							
Guo et al. 2014 ^[52]	628 ^{AAA}	In vivo computed tomography	North America	Mesiobuccal	28.3	26.3	1.1	41.9	2.4	0	0	0	0	0	0	0	0
				Distobuccal	99.6	0	0.2	0	0.2	0	0	0	0	0	0	0	0
				Palatal	100	0	0	0	0	0	0	0	0	0	0	0	0
Singh and Pawar 2014 ^{**}	100 ^{AAA}	In vitro clearing	India	Mesiobuccal	69	24	0	4	2	0	0	1	0	0	0	0	0
				Distobuccal	100	0	0	0	0	0	0	0	0	0	0	0	0
				Palatal	100	0	0	0	0	0	0	0	0	0	0	0	0
Maxillary second molars				Mesiobuccal	64.6	8.2	0	9.5	14.4	3.3	0	0	0	0	0	0	0
Pineda and Kuttler 1972 ^[8]	294 ^{AAA}	In vitro radiographic	Mexico	Distobuccal	100	0	0	0	0	0	0	0	0	0	0	0	0
				Palatal	100	0	0	0	0	0	0	0	0	0	0	0	0
Pomeranz and Fishelberg 1974 ^[9]	71 ^A	In vivo clinical RCT	USA	Mesiobuccal	62					38							
				Distobuccal	*					*							
				Palatal	*					*							
Hartwell and Bellizzi 1982 ^[33]	538 ^A	In vivo RCT treatments	USA	Mesiobuccal	91.4					9.6							
				Distobuccal	100					0							
				Palatal	99.8					0.2							
Vertucci 1984 ^[5]	100 ^{AAA}	In vitro clearing	USA	Mesiobuccal	71	17	0	12	0	0	0	0	0	0	0	0	0
				Distobuccal	100	0	0	0	0	0	0	0	0	0	0	0	0
				Palatal	100	0	0	0	0	0	0	0	0	0	0	0	0

Contid...

Investigators	Sample size	Technique	Country	Roots	Types																
					I	II	III	IV	V	VI	VII	VIII	IX	X							
Weller and Hartwell 1989 ^[10]	299 [^]	<i>In vivo</i> clinical radiographic	USA	Mesiobuccal Distobuccal Palatal	78.6 * *					21.4 * *											
Gilles and Reader 1990 ^[36]	37 [^]	<i>In vitro</i> clearing+SEM	USA	Mesiobuccal Distobuccal Palatal	29.7 * *	32.4 * *	35.1 * *	2.7 * *	0 * *	0 * *	0 * *	0 * *	0 * *	0 * *	0 * *	0 * *	0 * *	0 * *	0 * *	0 * *	
Kuolid and Peters 1990 ^[37]	32 [^]	<i>In vitro</i> microscopic+clinical	USA	Mesiobuccal Distobuccal Palatal	6.3 * *					93.7 * *											
Pécora <i>et al.</i> 1992 ^[11]	2050 [^]	<i>In vitro</i> clearing	Brazilian	Mesiobuccal Distobuccal Palatal	58 * *	22 * *	20 * *	0 * *	0 * *	0 * *	0 * *	0 * *	0 * *	0 * *	0 * *	0 * *	0 * *	0 * *	0 * *	0 * *	
Caliskan <i>et al.</i> 1995 ^[17]	100 [^]	<i>In vitro</i> clearing	Turkey	Mesiobuccal Distobuccal Palatal	27.08 100 97.92	23.58 0 0	2.08 0 0	14.67 0 0	4.17 0 2.08	6.25 0 0	0 0 0	0 0 0	0 0 0	4.16 0 0	0 0 0	0 0 0	0 0 0	0 0 0	0 0 0	0 0 0	
Zaatar <i>et al.</i> 1997 ^[12]	46 [^]	<i>In vivo</i> clinical radiographic	Kuwait	Mesiobuccal Distobuccal Palatal	76.1 100 100					23.9 0 0											
Imura <i>et al.</i> 1998 ^[40]	30 [^]	<i>In vitro</i> clearing	Unknown	Mesiobuccal Distobuccal Palatal	33.3 * *	20 * *	46.6 * *	0 * *	# # #	# # #	# # #	# # #	# # #	# # #	# # #	# # #	# # #	# # #	# # #	# # #	
Stropko 1999 ^[13]	611 [^]	<i>In vivo</i> clinical patient record	USA	Mesiobuccal Distobuccal Palatal	49.3 * *					50.7 * *											
Sempira and Hartwell 2000 ^[14]	70 [^]	<i>In vivo</i> clinical RCT magnification	Unknown	Mesiobuccal Distobuccal Palatal	75.7 * *					24.3 * *											
Al Shalabi <i>et al.</i> 2000 ^[19]	40 [^]	<i>In vitro</i> clearing	Irish	Mesiobuccal Distobuccal Palatal	37.5 85 95	5 0 0	2.5 0 0	17.5 0 0	15 0 0	12.5 0 0	0 0 0	0 0 0	0 0 0	0 0 0	0 0 0	0 0 0	0 0 0	0 0 0	0 0 0	0 0 0	
Alavi <i>et al.</i> 2002 ^[21]	65 [^]	<i>In vitro</i> clearing	Thai	Mesiobuccal Distobuccal Palatal	41.5 98.4 100	7.7 1.5 0	3.1 0 0	26.2 0 0	7.7 0 0	7.7 0 0	3.1 0 0	3.1 0 0	1.5 0 0	1.5 0 0	0 0 0	0 0 0	0 0 0	0 0 0	0 0 0	1.5 0 0	
Buhrey <i>et al.</i> 2002 ^[41]	208 [^]	<i>In vivo</i> clinical RCT magnification	Unknown	Mesiobuccal Distobuccal Palatal	63.9 * *	36.1 * *															
Wolcott <i>et al.</i> 2002 ^[42]	680 [^]	<i>In vivo</i> clinical RCT and retreatments	Unknown	Mesiobuccal Distobuccal Palatal	74 * *					36 * *											

Contid...

Investigators	Sample size	Technique	Country	Types									
				I	II	III	IV	V	VI	VII	VIII	IX	X
Sert and Bayirli 2004 ^[23]	100 ^{^^^} males	<i>In vitro</i> clearing	Turkey	26	31	14	19	5	1	1	1	0	1
				Mesiobuccal									
				Distobuccal	98	2	0	0	0	0	0	0	0
				Palatal	100	0	0	0	0	0	0	0	0
Sert and Bayirli 2004 ^[23]	100 ^{^^^} females	<i>In vitro</i> clearing	Turkey	56	22	2	6	4	0	0	0	0	2
				Mesiobuccal									
				Distobuccal	98	2	2	4	0	0	0	0	0
				Palatal	100	0	0	0	0	0	0	0	3
Yoshioka et al. 2005 ^[44]	110 ^{^^}	<i>In vitro</i> clearing	Japan	56.4	29.1	13.6	0.9						#
				Mesiobuccal	*	*	*	*					#
				Distobuccal	*	*	*	*					#
				Palatal	*	*	*	*					#
Rwenyonyi et al. 2007 ^[15]	221 ^{^^^}	<i>In vitro</i> clearing	Ugandan	86.9	1.8	0	6.7	3.2	1.8	0	0	0	0
				Mesiobuccal									
				Distobuccal	99.5	0.5	0	0	0.5	0	0	0	0
				Palatal	99	0	0.5	0	0.5	0	0	0	0
Silva et al. 2014 ^[51]	306 [^]	<i>In vivo</i> computed tomography	Brazil	45.09				34.32					0
				Mesiobuccal									0
				Distobuccal	100								0
				Palatal	100								0
Singh and Pawar ^{**} 2014 ^[56]	100 ^{^^^}	<i>In vitro</i> clearing	India	80.6	15.3	0	2.7	1.4	0	0	0	0	0
				Mesiobuccal									
				Distobuccal	100	0	0	0	0	0	0	0	0
				Palatal	97.2	0	1.4	1.4	0	0	0	0	0
Maxillary third molars				Mesiobuccal	21.4	20.6	0	31.1	0	0	0	21	0
Pineda and Kuttler 1972 ^[8]	292 ^{^^^}	<i>In vitro</i> radiographic	Mexico										5.9
				Distobuccal	0	0	0	3.6	0	0	0	0	0
				Palatal	0	0	0	0	0	0	0	0	0
Vertucci 1984 ^[5]	100 ^{^^^}	<i>In vitro</i> clearing	USA	45	37	0	18	0	0	0	0	0	0
				Mesiobuccal									
				Distobuccal	100	0	0	0	0	0	0	0	0
				Palatal	100	0	0	0	0	0	0	0	0
Pécora et al. 1992 ^[11]	50 ^{^^}	<i>In vitro</i> clearing	Brazilian	68	18	14	0	0	0	0	0	0	0
				Mesiobuccal	*	*	*	*	*	*	*	*	*
				Distobuccal	*	*	*	*	*	*	*	*	*
				Palatal	*	*	*	*	*	*	*	*	*
Stropko 1999 ^[13]	25 [^]	<i>In vivo</i> clinical patient record	USA	80				20					*
				Mesiobuccal	*	*	*	*	*	*	*	*	*
				Distobuccal	*	*	*	*	*	*	*	*	*
				Palatal	*	*	*	*	*	*	*	*	*
Alavi et al. 2002 ^[21]	77 ^{^^^}	<i>In vitro</i> clearing	Thai	54.5	13	4	13	9.1	2.6	2.6	0	0	1
				Mesiobuccal									
				Distobuccal	100	0	0	0	0	0	0	0	0
				Palatal	100	0	0	0	0	0	0	0	0
Singh and Pawar ^{**} 2014 ^[56]	100 ^{^^^}	<i>In vitro</i> clearing	India	57.4	3.1	2.1	8.4	0	0	0	0	0	0
				Mesiobuccal									
				Distobuccal	100	0	0	0	0	0	0	0	0
				Palatal	100	0	0	0	0	0	0	0	0

[^]Single or two or more canal systems, ^{^^}Weines classification, ^{^^^}Vertucci classification, *Not included in the study, #Weines classification, **Data are of molars with three separate roots. RCT: Root canal type, SEM: Scanning electron microscope

to study the root canal anatomy of human teeth worldwide.^[2,53,54]

The clearing technique followed in this study resulted in very clear specimens, allowing good visualization and photography of the canal anatomy. The incidence of lateral canals in the Indian population was not significant when compared with similar studies done on other racial populations suggesting this could be a racial characteristic. Observations were made by examining the specimens with a magnifying glass under good lighting to study their root canal morphology. The universally accepted Vertucci's classification was used to study the root canal anatomy.^[5]

Researchers worldwide have been studying the root canal anatomy of the maxillary molars for a century now. They have used various *in vitro* techniques such as sectioning, clearing, radiographic, microscopic, clinical, or a combination of two or more. The *in vivo* techniques constitute clinical, radiographic, post treatment records studies, which are less in number when compared with the *in vitro* techniques with the dye penetration and clearing being used most often setting it as the gold standard.^[3,30] The advantages of this technique have been discussed by Okumura,^[2] Robertson *et al.*,^[53,54] Omer *et al.*^[55] and has been used in a recently published study by Singh and Pawar.^[56] Though the modern CBCT techniques by Neelkantan *et al.*, Nur *et al.* and Altunsoy *et al.* and other researchers,^[6,45,49,50,57,58] as well as the combination of alternating image reformatting techniques in micro-computed tomography involving two-dimensional minimum intensity projection and 3-dimensional volume rendering reconstruction images have been discussed;^[7] the time tested clearing technique was used in this study. There is no doubt that the dye penetration and clearing technique helps in a better visualization and understanding of the root canal anatomy adding more value in endodontic teaching. Not all studies mentioned the racial characteristics of the sample nor have they used a standardized root canal classification system. While the earlier studies have mentioned a simple classification, a few have followed the Weines system with the detailed and more sensitive Vertuccis system being used in the later studies.^[5] It is noteworthy that many researchers have only studied anatomy of the mesiobuccal root of the maxillary molar, perhaps in the quest of the second mesiobuccal canal. In this study 28% of first molars of, 18% of second molars and 40.5% third molars exhibited MB2 canals which is an interesting finding for the clinician. The results

of various studies show that the incidence of an extra canal in the mesiobuccal root of Indians is much less than the Europeans^[17,23,31,36,46,47] and Far eastern Thai^[21] and Japanese races^[18,39] and is similar to the Brazilians,^[11] Mexicans,^[8] African Ugandans,^[15] and the Kuwaitis^[12,16] which can be considered a racial characteristic. This observation is of immense value during the endodontic treatment of Indian molars.

It is interesting to note the incidence of MB2 canals in the maxillary molars typical to Indian teeth as compared to other races. This could be a racial characteristic as their incidence is higher in the Caucasian, European and Far eastern Thai and Japanese races. Our findings suggest that the root canal morphology of Indian molar teeth is similar to the Mexicans, Brazilians, African Ugandans, and the Kuwaitis, which can be considered a racial characteristic. Further research on interracial anatomical characteristics from different geographical locations would be beneficial for a comparative study.

ACKNOWLEDGMENTS

This original research work is part of PhD dissertation requirement of Maharashtra University of Health Sciences. The authors appreciate the help given by Dr. Gaurav Kulkarni for processing the images.

REFERENCES

1. Hess W. The Anatomy of the Root Canals of the Teeth of the Permanent and Deciduous Dentition. New York: William Wood and Co.; 1925. p. 1-39.
2. Okumura T. Anatomy of the root canals. J Am Dent Assoc 1927;14:632-6.
3. Weine FS, Pasiewicz RA, Rice RT. Canal configuration of the mandibular second molar using a clinically oriented *in vitro* method. J Endod 1988;14:207-13.
4. Weine FS, Healey HJ, Gerstein H, Evanson L. Canal configuration in the mesiobuccal root of the maxillary first molar and its endodontic significance. Oral Surg Oral Med Oral Pathol 1969;28:419-25.
5. Vertucci FJ. Root canal anatomy of the human permanent teeth. Oral Surg Oral Med Oral Pathol 1984;58:589-99.
6. Neelakantan P, Subbarao C, Subbarao CV. Comparative evaluation of modified canal staining and clearing technique, cone-beam computed tomography, peripheral quantitative computed tomography, spiral computed tomography, and plain and contrast medium-enhanced digital radiography in studying root canal morphology. J Endod 2010;36:1547-51.
7. Lee KW, Kim Y, Perinpanayagam H, Lee JK, Yoo YJ, Lim SM, *et al.* Comparison of alternative image reformatting techniques in micro-computed tomography and tooth clearing for detailed canal morphology. J Endod 2014;40:417-22.
8. Pineda F, Kuttler Y. Mesiodistal and buccolingual roentgenographic investigation of 7,275 root canals. Oral Surg Oral Med Oral Pathol 1972;33:101-10.
9. Pomeranz HH, Fishelberg G. The secondary mesiobuccal canal of maxillary molars. J Am Dent Assoc 1974;88:119-24.
10. Weller RN, Hartwell GR. The impact of improved access and searching techniques on detection of the mesiolingual canal in maxillary molars. J Endod 1989;15:82-3.
11. Pécora JD, Woelfel JB, Sousa Neto MD, Issa EP. Morphologic study of the maxillary molars. Part II: Internal anatomy. Braz Dent J 1992;3:53-7.

12. Zaatari EI, al-Kandari AM, Alhomaidah S, al-Yasin IM. Frequency of endodontic treatment in Kuwait: Radiographic evaluation of 846 endodontically treated teeth. *J Endod* 1997;23:453-6.
13. Stropko JJ. Canal morphology of maxillary molars: Clinical observations of canal configurations. *J Endod* 1999;25:446-50.
14. Sempira HN, Hartwell GR. Frequency of second mesiobuccal canals in maxillary molars as determined by use of an operating microscope: A clinical study. *J Endod* 2000;26:673-4.
15. Rwenyonyi CM, Kutesa AM, Muwazi LM, Buwembo W. Root and canal morphology of maxillary first and second permanent molar teeth in a Ugandan population. *Int Endod J* 2007;40:679-83.
16. Pattanshetti N, Gaidhane M, Al Kandari AM. Root and canal morphology of the mesiobuccal and distal roots of permanent first molars in a Kuwait population – a clinical study. *Int Endod J* 2008;41:755-62.
17. Caliskan MK, Pehlivan Y, Sepetcioglu F, Türkün M, Tuncer SS. Root canal morphology of human permanent teeth in a Turkish population. *J Endod* 1995;21:200-4.
18. Weine FS, Hayami S, Hata G, Toda T. Canal configuration of the mesiobuccal root of the maxillary first molar of a Japanese sub-population. *Int Endod J* 1999;32:79-87.
19. Al Shalabi RM, Omer OE, Glennon J, Jennings M, Claffey NM. Root canal anatomy of maxillary first and second permanent molars. *Int Endod J* 2000;33:405-14.
20. Wasti F, Shearer AC, Wilson NH. Root canal systems of the mandibular and maxillary first permanent molar teeth of south Asian Pakistanis. *Int Endod J* 2001;34:263-6.
21. Alavi AM, Opananon A, Ng YL, Gulabivala K. Root and canal morphology of Thai maxillary molars. *Int Endod J* 2002;35:478-85.
22. Sert S, Bayirli GS. Evaluation of the root canal configurations of the mandibular and maxillary permanent teeth by gender in the Turkish population. *J Endod* 2004;30:391-8.
23. Sert S, Sahinkesen G, Topcu FT, Eroglu SE, Oktay EA. Root canal configurations of third molar teeth. A comparison with first and second molars in the Turkish population. *Aust Endod J* 2011;37:109-17.
24. Vertucci FJ. Root canal morphology and its relationship to endodontic procedures. *Endod Topics* 2005;10:3-29.
25. Moral H. 'Veber Pulpaaüsugesse.' *Deutsche Monatsschrift für Zahnheilkunde* 1914;32:617-624.
26. Zurcher E. The Anatomy of the Root Canals of the Teeth of the Deciduous Dentition and of the First Permanent Molars, Part 2. New York: William Wood and Co.; 1925.
27. Sykaras S, Economou P. Root canal morphology of the mesiobuccal root of the maxillary first molar. *Odontostomatol Proodos* 1970;24:99-108.
28. Seidberg BH, Altman M, Guttuso J, Suson M. Frequency of two mesiobuccal root canals in maxillary permanent first molars. *J Am Dent Assoc* 1973;87:852-6.
29. Nosenowitz DM, Brenner MR. The major canals of the mesiobuccal root of the maxillary 1st and 2nd molars. *N Y J Dent* 1973;43:12-5.
30. Slowey RR. Radiographic aids in the detection of extra root canals. *Oral Surg Oral Med Oral Pathol* 1974;37:762-72.
31. Acosta Vigouroux SA, Trugeda Bosaans SA. Anatomy of the pulp chamber floor of the permanent maxillary first molar. *J Endod* 1978;4:214-9.
32. Evenot M. Contribution a la connaissance des systemes endodontiques complexes la racine mesio vestibulaire de la premiere molaire maxillaire, approche, instrumentale, Clinique at pedagogique. PhD thesis. Academie de paris. Universite Rene Descartes, Paris, France; p. 347.
33. Hartwell G, Bellizzi R. Clinical investigation of *in vivo* endodontically treated mandibular and maxillary molars. *J Endod* 1982;8:555-7.
34. Gray R. The maxillary first molar. In: Björndal AM, Skidmore AE, editors. *Anatomy and Morphology of Permanent Teeth*. Iowa City: University of Iowa College of Dentistry; 1983.
35. Neaverth EJ, Kotler LM, Kaltenbach RF. Clinical investigation (*in vivo*) of endodontically treated maxillary first molars. *J Endod* 1987;13:506-12.
36. Gilles J, Reader A. An SEM investigation of the mesiolingual canal in human maxillary first and second molars. *Oral Surg Oral Med Oral Pathol* 1990;70:638-43.
37. Kulild JC, Peters DD. Incidence and configuration of canal systems in the mesiobuccal root of maxillary first and second molars. *J Endod* 1990;16:311-7.
38. Thomas RP, Moule AJ, Bryant R. Root canal morphology of maxillary permanent first molar teeth at various ages. *Int Endod J* 1993;26:257-67.
39. Fogel HM, Peikoff MD, Christie WH. Canal configuration in the mesiobuccal root of the maxillary first molar: A clinical study. *J Endod* 1994;20:135-7.
40. Imura N, Hata GI, Toda T, Otani SM, Fagundes MI. Two canals in mesiobuccal roots of maxillary molars. *Int Endod J* 1998;31:410-4.
41. Buhrlay LJ, Barrows MJ, BeGole EA, Wenckus CS. Effect of magnification on locating the MB2 canal in maxillary molars. *J Endod* 2002;28:324-7.
42. Wolcott J, Ishley D, Kennedy W, Johnson S, Minnich S. Clinical investigation of second mesiobuccal canals in endodontically treated and retreated maxillary molars. *J Endod* 2002;28:477-9.
43. Villegas JC, Yoshioka T, Kobayashi C, Suda H. Frequency of transverse anastomoses with and without apical communication in Japanese population teeth. *Aust Endod J* 2004;30:50-2.
44. Yoshioka T, Kikuchi I, Fukumoto Y, Kobayashi C, Suda H. Detection of the second mesiobuccal canal in mesiobuccal roots of maxillary molar teeth *ex vivo*. *Int Endod J* 2005;38:124-8.
45. Wu DM, Wu YN, Guo W, Sameer S. Accuracy of direct digital radiography in the study of the root canal type. *Dentomaxillofac Radiol* 2006;35:263-5.
46. Eder A, Kantor M, Nell A, Moser T, Gahleitner A, Schedle A, *et al*. Root canal system in the mesiobuccal root of the maxillary first molar: An *in vitro* comparison study of computed tomography and histology. *Dentomaxillofac Radiol* 2006;35:175-7.
47. Shahi S, Yavari HR, Rahimi S, Ahmadi A. Root canal configuration of maxillary first permanent molars in an Iranian population. *J Dent Res Dent Clin Dent Prospects* 2007;1:1-5.
48. Ameen RM, Hassan RM. A study on the external and internal root anatomy of Egyptian maxillary first permanent molar. *Cairo Dent J* 2008;24:29-36.
49. Degerness RA, Bowles WR. Dimension, anatomy and morphology of the mesiobuccal root canal system in maxillary molars. *J Endod* 2010;36:985-9.
50. Yu X, Guo B, Li KZ, Zhang R, Tian YY, Wang H, *et al*. Cone-beam computed tomography study of root and canal morphology of mandibular premolars in a western Chinese population. *BMC Med Imaging* 2012;12:18.
51. Silva EJ, Nejaim Y, Silva AI, Haiter-Neto F, Zaia AA, Cohenca N. Evaluation of root canal configuration of maxillary molars in a Brazilian population using cone-beam computed tomographic imaging: An *in vivo* study. *J Endod* 2014;40:173-6.
52. Guo J, Vahidnia A, Sedghizadeh P, Enciso R. Evaluation of root and canal morphology of maxillary permanent first molars in a North American population by cone-beam computed tomography. *J Endod* 2014;40:635-9.
53. Robertson D, Leeb IJ, McKee M, Brewer E. A clearing technique for the study of root canal systems. *J Endod* 1980;6:421-4.
54. Robertson DC, Leeb IJ. The evaluation of a transparent tooth model system for the evaluation of endodontically filled teeth. *J Endod* 1982;8:317-21.
55. Omer OE, Al Shalabi RM, Jennings M, Glennon J, Claffey NM. A comparison between clearing and radiographic techniques in the study of the root-canal anatomy of maxillary first and second molars. *Int Endod J* 2004;37:291-6.
56. Singh S, Pawar M. Root canal morphology of South asian Indian mandibular premolar teeth. *J Endod* 2014;40:1338-41.
57. Nur BG, Ok E, Altunsoy M, Aglarci OS, Colak M, Gungor E. Evaluation of the root and canal morphology of mandibular permanent molars in a south-eastern Turkish population using cone-beam computed tomography. *Eur J Dent* 2014;8:154-9.
58. Altunsoy M, Ok E, Nur BG, Aglarci OS, Gungor E, Colak M. A cone-beam computed tomography study of the root canal morphology of anterior teeth in a Turkish population. *Eur J Dent* 2014;8:302-6.

Access this article online

Quick Response Code:



Website:
www.eurjdent.com

Source of Support: Internal funding from Bharath University.
Conflict of Interest: None declared