



Sarcoids in Donkeys: Common Types and Available Treatment

Mohamed A.Semieka, Magda M.Ali*, A. A. Al-Iethie

Department of surgery, Faculty of Veterinary Medicine Assiut University, Assiut, Egypt

Abstract

Different forms of equine sarcoids were recorded in 100 donkeys admitted to the Veterinary Teaching Hospital- Assiut University and to Veterinary Units that belong to Assiut Governorate during the period from 2008-2010. In each animal, different data including: (types, size, multiplicity and anatomical location) were recorded. Histopathological examination, surgical and nonsurgical techniques for treatment of sarcoids were applied. Results of this study showed 123 sarcoid lesions classified into: Fibroblastic (87); nodular (21); verrucous (9); mixed (6). Treatment of sarcoid varied in results according to the seat and type of lesion. Injection of the sarcoid by live attenuated Bacille Calmette-Guérin (BCG) vaccine was the best treatment in case of preocular sarcoid lesions.

Keywords: Sarcoid; donkey; skin tumors; classification

Introduction

Equine sarcoids are the most common skin lesions in equine (Chambers *et al.*, 2003). They occur in horses, donkeys and mules (Knottenbelt, 2003). A higher incidence in donkeys and mules is reported (Yu, 2006). Most of literatures showed no age or sex predilections of equine sarcoid (Mc Conaghy *et al.*, 1994; Brandt *et al.*, 2007).). But in a study by Reid *et al.* (1994), both age and gender were seen to have a significant influence on the development of sarcoids in donkeys especially in age up to 15 years old. The most common sites recorded for sarcoid infestation are the ventral body regions, head, neck and all body regions, which contain thin skin layer (Teifke and Lohr, 1996). Sarcoids can occur either as a single lesion or in clusters (Foy *et al.*, 2002). Many lines of evidence suggested the involvement of an infectious agent in the development of equine sarcoids. Based on sarcoid appearance and pattern of spread, the first report suggested a virus origin for the sarcoid tumors (Jackson, 1936). Other investigations suggested that bovine papilloma virus is the main etiological agent of equine sarcoid (Reid *et al.*, 1994; Nasir

and Reid, 1999; Carr *et al.*, 2001; Martens *et al.*, 2001; Chambers *et al.*, 2003). Equine sarcoids have six distinct clinically recognizable types include: occult, verrucous, fibroblastic, nodular, mixed and malevolent sarcoids (Goodrich *et al.*, 1998, Marens *et al.*, 2000; Knottenbelt, 2005; Bogaert *et al.*, 2008).

Treatment of equine sarcoids has always been challenging for the veterinarians due to the variable clinical presentation of the lesions and the frequent local recurrences. Both surgical and non surgical techniques have been described with variable success rates. None of the current treatment techniques for equine sarcoid have been proven to be 100% successful (Marti *et al.*, 1993).

The available literatures lack information regarding sarcoid types in donkeys and their treatment especially with Bacille Calmette-Guerin (BCG) vaccine. This study aimed to study the main types of sarcoids and the efficiency of different types of treatment methods on the common forms of sarcoids affecting donkeys.

Materials and methods

The present study was carried out on 100 donkeys suffering from lesions suggestive of equine sarcoid. The animals were of both sexes (43 males and 57 females) and of different ages ranged from one year

*Corresponding author: Magda M. Ali

E-mail address: magdaali70@yahoo.com

to twelve years old. Donkeys were admitted to the Veterinary Teaching Hospital, Assiut University and to the Veterinary Unites in Assiut Governorate during the time period between 2008 and 2010. The types, size, multiplicity and anatomical location of the lesion were recoded for each animals.

Treatment of the cases:

According to the characters of the sarcoid and nature of the affected area, one of the following treatments was used:

Surgical excision of the sarcoid with or without suturing of the wound:

Surgical removal of the sarcoid lesion with suturing of the wound after resection was performed in 50 sarcoids affecting 37 donkeys. This technique was performed where a sufficient amount of skin was present around the sarcoid lesion. The technique was performed under effect of Chloral hydrates/ barbiturates combination. Chloral hydrate 10% was injected intravenous in a dose rate of 50 mg/kg b.w, followed by thiopental Na 2.5 % in a dose rate of 5mg/kg b.w; anesthesia was maintained by thiopental in a dose rate of 1 mg/ kg. b.w (Hall *et al.*, 2001). Surgical excision of the sarcoid was performed under complete aseptic condition as an ordinary procedure. In cases where the skin around the lesion was deficient to be sutured, the wound was left opened after resection of the lesion.

Injection of the sarcoid by live attenuated BCG vaccine:

This technique was performed in 20 sarcoids affecting 20 donkeys. Sarcoid were located at the eyelids in ten cases, cheek in one case, chin in one case and limbs and trunk in eight cases.

The animals were treated with corticosteroid (Dexamethasone in a dose rate of 0.5mg /kg. b.w intramuscularly) as a pre-medication to avoid anaphylactic shock of BCG (Knottenbelt and Kelly, 2000). The area of the lesion was prepared aseptically and BCG vaccine was injected into the tumor mass and in the junction between normal and neoplastic tissue in a dose rate of 1ml/cm³ tissue. Four injections were performed with two weeks intervals (Knottenbelt and Kelly 2000; Komaromy *et al.*, 2004; Hamann and Grabner, 2005). Follow up

of the cases was performed and results were recorded.

Histopathological examination:

Samples from the lesions were collected and fixed in 10% neutral buffered formalin and then embedded in paraffin by routine methods. Sections (4 µm thick) were stained with haematoxyline and eosin (HE) (Bancroft *et al.*, 1996).

Results

In the present study, a total of 123 sarcoids affected 100 donkeys were studied. Distribution of sarcoid according to age and sex were presented in table 1.

Table1. Distribution of sarcoids according to age and sex

Sex	1-3 years	3-7 years	7-10 years	>10	Total
Male	1	17	13	12	43
Female	0	34	17	6	57
Total	1	51	30	18	100

The following were observed after precise clinical examination for the types, size, multiplicity and location of sarcoids:

Types of sarcoids

According to the gross appearance, four types of sarcoids were recorded in the present study. These types included: Fibroblastic sarcoid, which were characterized by large masses with ulcerated surfaces and were often covered by necrotic debris (flesh appearance). Nodular sarcoids that were characterized by presence of firm well defined subcutaneous spherical nodules and were covered by grossly normal skin. Verrucous sarcoids, characterized by presence of rough hyperkeratosis on the surface with prominent scales (wartlike appearance). Mixed sarcoid had a mixture of two or three types of the above mentioned sarcoids (Table 2 and Fig. 1).

Size of sarcoids

In the present study, sizes of the sarcoids were varied from a very small mass as those observed around the eyelids, to a large mass that recorded mainly around the axilla.

Table 2. Types of sarcoids recorded in the present study (100 cases)

Types	Male	Female	Total	Site
Fibroblastic	36	51	87	Limbs, head, neck, chest, abdomen, wither, genital and para genital
Nodular	9	12	21	Periocular, nose, mandible, elbow, abdomen, penis, perineal region.
Verrucous	4	5	9	Chin, neck, chest, shoulder, forearm and metacarpus
Mixed	3	3	6	Cheek, neck, forearm and axilla
Total	52	71	123	

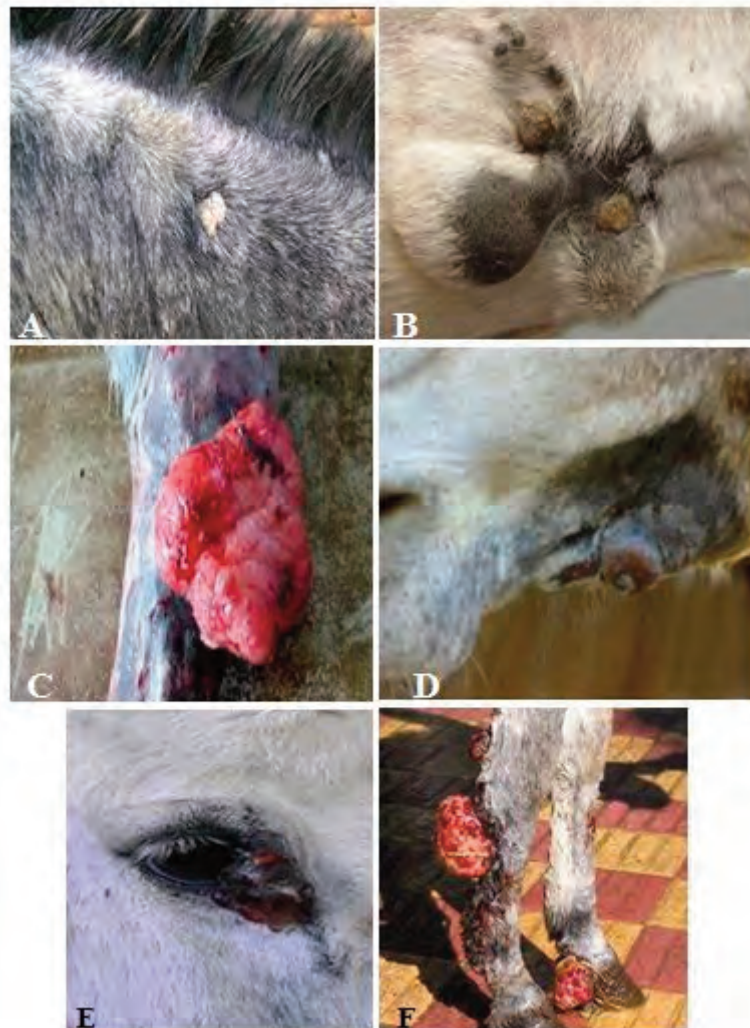

Fig. 1. Sarcoid in Donkey: A) Verrucous sarcoid located on the neck. B) Mixed sarcoid (nodular & verrucous) on the ventral abdomen. C) Fibroblastic sarcoid located on the metatarsal region. D) Nodular sarcoid located at the mandible. E) Single fibroblastic sarcoid at the medial canthus of the eye. F) Three fibroblastic sarcoids on the distal forelimb region.

Multiplicity of sarcoid.

Single or multiple sarcoid lesions were detected at different areas of the animal body (Figs. 1E, 1F).

Location of sarcoids

Sarcoids were found on head and neck; fore limbs; hind limbs; trunk; tail; genital, para-genital and perineal regions (Fig. 2).

Results of histopathological examination

Histopathological examination of the HE stained sections of sarcoids revealed typical characters of equine sarcoid in the form of epidermal hyperplasia, hyperkeratosis and elongation of rete pegs. Some examined sections showed ulceration of the epidermis. The dermis was infiltrated with lymphocytes and neutrophils as well as thrombosis of the blood vessels were found. Moreover, fibroblast cells were observed in different areas of the stained

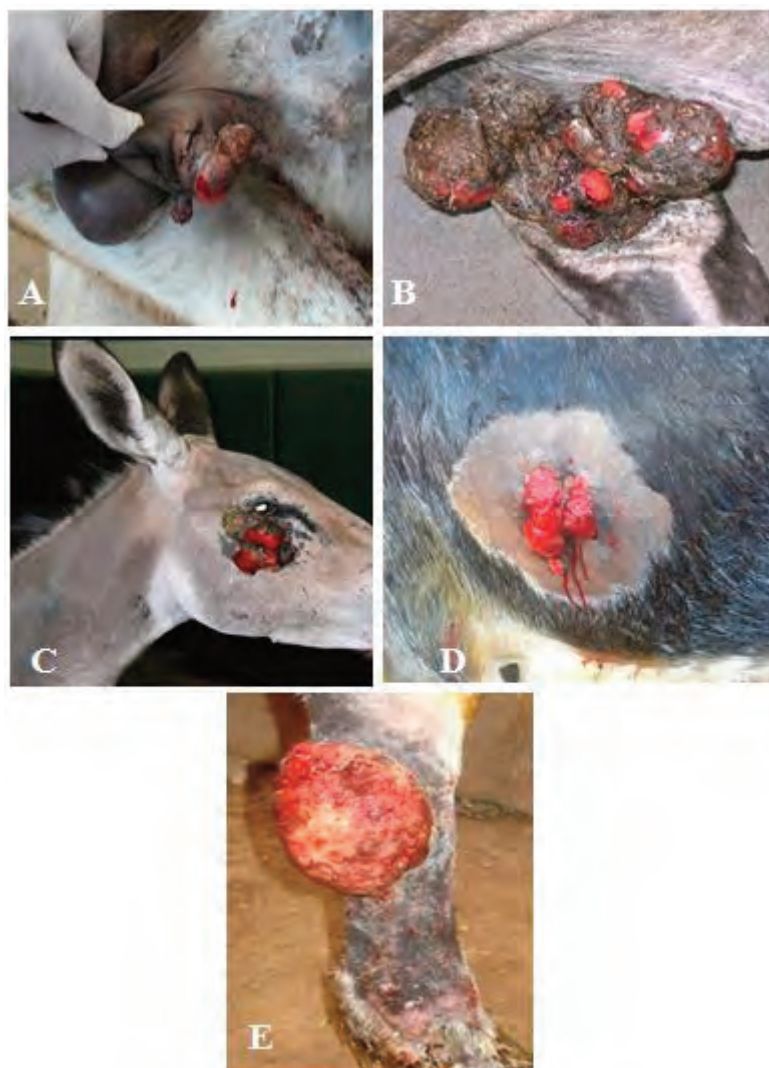


Fig. 2. Location of fibroblastic sarcoids. A) On the prepuce. B) On the axilla. C) Periocular sarcoid. D) On the chest. E) On the metacarpal region

sections. The fibromatous growth showed hemorrhage and infiltration with neutrophils and eosinophils. The inflammatory cell infiltration was extended to the underlying muscles (Fig. 3).

Follow up of the treated cases

In 39 sarcoids out of 50 (78%) cases treated by surgical resection of the sarcoids with suturing of the wound after resection of the sarcoid; recovery and healing of the wounds were good and no complications regarding wound healing were observed. Wound lip dehiscence and recurrence of sarcoids were recorded in 11 sarcoid out of 50 (22%). In the cases treated by surgical resection of sarcoids and the wound was left opened without suture, the recovery in 37 sarcoids out of 53 (69.8%) was good and complete wound closure was obtained within two weeks after surgical resection of the lesions, while recurrence of sarcoids were recorded in 16

cases out of 53 (30.2%) cases.

Sarcoids treated by BCG injection revealed complete regression and disappearance of 12 sarcoids out of 20 (60%). Eight sarcoids remained without regression (40%) (Fig. 4).

Discussion

Equine sarcoid is a fibroblastic tumor of the skin. It is the most prevalent equine skin tumor and can affect all equidae (Vanselow *et al.*, 1988). Sarcoids are considered to be common affection of donkeys. In the present study, sarcoids were recorded and diagnosed in 100 donkeys. The mean age of sarcoids development is 3.5 to 4 years (Studer *et al.*, 2007). A gradual increase in incidence is observed up to the age of 15 years, followed by a decreasing incidence (Mohammed *et al.*, 1992). In the present study, the highest incidence of sarcoids was

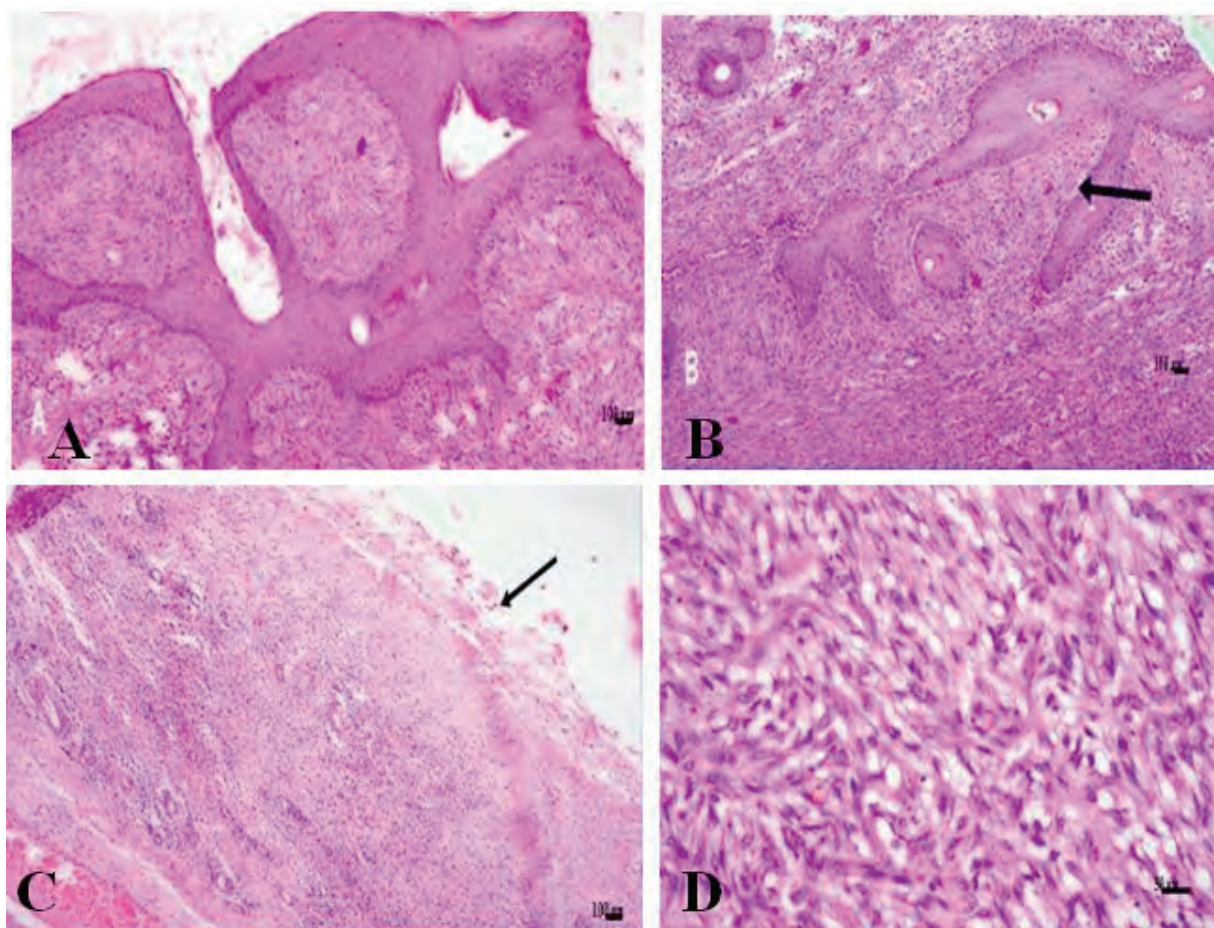


Fig. 3. Micrograph for sarcoids in donkeys A) Hyperplasia of the epithelium. B) Elongation of rete pegs. C) Ulceration of the epithelium (arrow) inflammatory cell infiltration and thrombosis. D) Fibromatous growth in the dermis.

recorded in donkeys of 3 – 7 years old and the lowest incidence was observed in donkeys less than three years old. An obvious reason for this age distribution has not been demonstrated yet (Torrontegui and Reid, 1994). Although recent studies suggest that there is no significant sex or age predilection for sarcoids predispositions (Knottenbelt, 2005), in the present study female animals were more represented than males. Equine sarcoids have six distinct clinically recognizable types including occult, verrucous, nodular, mixed and malevolent sarcoids (Martens *et al.*, 2000; Knottenbelt, 2005; Bogaert *et al.*, 2008). In the current study, four types of sarcoids were diagnosed and recorded in donkeys. These included; fibroblastic, nodular, verrucous and mixed sarcoids. Fibroblastic sarcoid was the most common type recorded in the present study. This may be due to this type of sarcoids occurs at sites of previous trauma (Knottenbelt, 2005) and can evolve from any other type after accidental or iatrogenic manipulation, including biopsy (Knottenbelt *et al.*, 1995, Foy *et al.*, 2002). Mixed sarcoid was less common type affecting donkeys in this study. This type of sarcoid can

represent transient state between the verrucous/occult types and fibroblastic/ nodular types (Pascoe and Knottenbelt, 1999).

Predilection sites of fibroblastic sarcoids include the groin, eyelids, lower limbs, coronet and sites of other sarcoids lesions subjected to trauma or insult (Knottenbelt, 2005). In the present study, fibroblastic sarcoids were detected on limbs, head, neck, chest, Abdomen, wither, genital and paragenital regions. Nodular sarcoids were most commonly observed at the eyelids and groin region (Hamann and Garbner, 2005). In the investigated donkeys, nodular sarcoids were recorded on periocular, nose, mandible, elbow, abdomen, penis and perineal region. Typical locations of verrucous sarcoids are the face, neck, groin and axilla (Yu, 2006). They rarely occur on the distal extremities but may sometimes affect the coronary band (Knottenbelt 2005). In the present study verrucous sarcoids were recorded on chin, neck, chest, shoulder, fore limb, and metacarpal region. Mixed sarcoids are a mixture of two or more types that can develop at any site especially on the head, axilla and groin (Knottenbelt, 2001). In the present study, mixed sarcoids

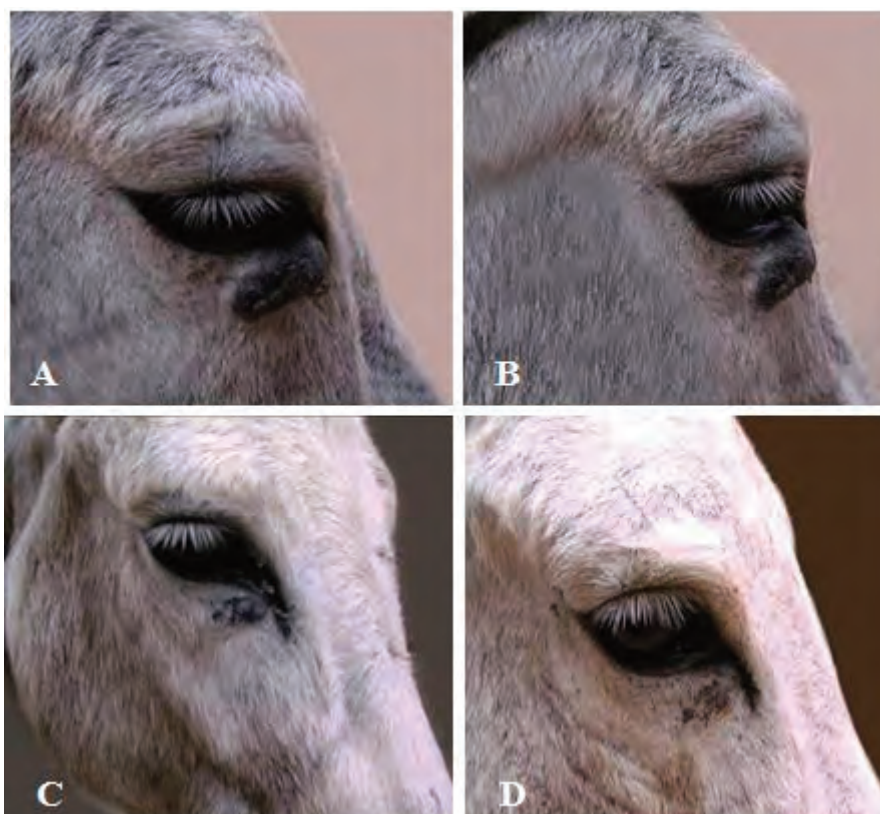


Fig. 4. Effect of BCG injection on sarcoids. A) Periocular nodular sarcoid, before the first BCG injection (Day 1). B) The lesion just before the second BCG injection (Day 16). C) The sarcoid was regressed and the fourth BCG injection was administered (Day 46). D) Complete regression of sarcoid (Day 76).

recorded affecting cheek, neck, axilla, fore limb and ventral abdomen.

Histopathological characters of sarcoids had been previously described and characterized by dermal proliferation of fusi form or spindle shaped fibroblasts forming whorls or interlacing bundles. The epidermis was reported to show hyperplasia and hyperkeratosis as well as rete pegs formation in the majority of the cases (Pulley and Stannard, 1990; Marti *et al.*, 1993). Ulceration and inflammation of the epidermis were seen in equine sarcoids (Williams *et al.*, 1982).

Histopathological examination of the stained sections in this study revealed typical characters of equine sarcoids represented by epidermal hyperplasia, hyperkeratosis, ulceration and elongation of rete pegs. Moreover, fibroblast cells were found in different areas of the slides and inflammatory cell infiltration was extended to underlying muscles.

There is a wide range of treatment methods available for equine sarcoids. None of these methods has shown to be universally effective in eliminating sarcoids. The treatment modality selected is determined by location, size and aggressiveness of the sarcoid as well as by clinical experience, and the availability of services, equipment, and facilities (Marti *et al.*, 1993; Carstanjen and Lepage

1998). Different surgical approaches had been reported, including excision, cryosurgery and CO₂ laser surgery. Other common non surgical treatment methods of equine sarcoids were chemotherapy, radiotherapy and local immunotherapy (Bogaert *et al.*, 2008). According to size, characters, location of the swelling as well as the available equipment, treatment of sarcoids in the present study was performed by surgical excision of the swelling with or without suture of the wound after excision and by injection of BCG intra-lesion.

In the cases treated surgically, 69.8 % – 78 % of the treated sarcoids did not recurrent throughout the time of follow up. This was considered a satisfactory success rate. However, this success rate could probably due to the seat of the sarcoid and removal of a wide margin of normal tissues around the sarcoid to avoid the recurrence of the lesion. This was in agreement with previous results obtained by (Martens *et al.*, 2001). In 22 – 30.2 % of the sutured wounds, recurrence of sarcoids during the period of follow up has been observed. This could be attributed to the infiltrative nature of the sarcoid and auto- transplantation of tumor cells during the surgical procedure as well as proliferation and expression of latent virus resulting in growth of the tumor (Bogaert *et al.*, 2008).

Bacille Calmette-Guérin is an attenuated strain of *Mycobacterium bovis* that has the ability to stimulate the immune system to induce phagocytic activity, and to initiate an antibody response to heterologous antigens in various tumors (Marti *et al.*, 1993; Komaromy *et al.*, 2004). Periocular sarcoids are most responsive to BCG treatment with local control rates up to 100 % while sarcoids on the limbs respond poorly to BCG treatment. (Theon, 1998). In cases treated by BCG injection in the present study, all periocular sarcoids and sarcoids of chin and cheek showed regression and disappearance while all sarcoids affecting limbs and trunk were not responding to BCG treatment. The success rate is mainly depend on tumor size and localization as reported by Klein (1986), and on the type of sarcoids. The periocular sarcoids of the present study were of the nodular type, which was respond to BCG injection. Other types of sarcoids as fibroblastic, verrucous and mixed are poorly respond to treatment by BCG (Knottenbelt, 2003). In the present study, although sarcoid of chin was of verrucous type and sarcoids of cheek was of mixed type, they respond to BCG treatment, this may be due to small sized of these swellings (Klein *et al.*, 1986).

Conclusion

No great difference was observed between donkeys and horses in their affection with Sarcoid. Different types of sarcoids (Fibroblastic, nodular, verrucous and mixed) were diagnosed and recorded in this study. The most common affected body areas were the abdomen, periocular region and genitalia. Surgical excision of the swelling and BCG injection intralesionally were used as available treatment of sarcoids with satisfactory results. BCG injection is highly effective treatment for periocular sarcoids.

Acknowledgement

The authors would like to express their grateful thanks for all members of the department of Animal Surgery, Faculty of Veterinary Medicine, Assiut University for their help and support

References

- Bancroft, T.D., Stevens, A., Turner, D.R., 1996. Theory and practice of histological technique, 4th ed. ; Churchill, Livingstone, New York.
- Bogaert, L., Martens, A., Van Poucke, M., Ducatelle, R., De-cock, H., Dewulf, J., De Baere, C., Peelman, L., Gasthuys, F., 2008. Therapy of equine sarcoid. Research in Veterinary Science 83; 106-109.
- Brandt, S., Haralampus, R., Shafti Keramate, S., Schaster, A., Stanek, C., Hinterhofer, C., Kirnbauer, R., 2007. Bovine Papilloma viruses in Equine: New Data. Proceedings of the talk BEVA congress, Edinburg, September 12 –15, pp. 273 –277.
- Carstanjen, B., Lepage, O.M., 1998. Equine sarcoid (partII): Treatment regimes and prognosis. Der Praktische Tierarzt 79, 730-742.
- Chambers G., Ellsmore, V.A., Brien, P.M., Reid, S.W., Love, S., Nasir, L., 2003. Association of bovine papilloma virus with the equine sarcoid. Journal of Virology 84, 1055-1062.
- Foy, J.M., Rashmi Raven, A.M., Brashier, M.K., 2002/ Common equine skin tumor. Equine Compendium 24, 242-253.
- Goodrich, L., Gerber, A.H., Marti, E., Antezak, D.F., 1998/ Equine Sarcoids. Veterinary Clinics of North America: Equine Practice 14, 607-623.
- Hall, L.W., Clark, K.W., Trim, C.M., 2001. Veterinary Anesthesia. 10th Edition; W.B. Saunders Company; Philadelphia London Tokyo, pp. 844-846.
- Hamann, J., Grabner, A., 2005. Das Equine Sarkoid - der häufigste Hauttumor beim Pferd. Pferde Heilkunde 21, 273-279.
- Jackson, C., 1936. The incidence and pathological of tumor of domestic animals in South Africa. On derstepoort journal of Veterinary Research 6.1-460.
- Klein, W.R., Bras, G.E., Misdorp, W., Steerenberg, P.A., De-jong, W.H., Tiesjema, R.H., Kersjes, A.W., Ruitenber, E.J., 1986. Equine sarcoid -bcg immunotherapy compared to cryosurgery in a prospective randomized clinical-trial. Cancer Immunology Immunotherapy 21, 133-140.
- Knottenbelt, D.C., Edwards, S., Daniel E., 1995. Diagnosis and treatment of equine sarcoid. In Practice 17, 123-129.
- Knottenbelt, D.C., Kelly, D.F., 2000. The diagnosis and treatment of periorbital sarcoids in the horse: 445 cases from 1974 to 1999. Veterinary Ophthalmology 3, 169-191.
- Knottenbelt, D.C., 2001. Facts you need to know about sarcoid. Proceeding of the 3rd Annual Congress of the equine practioners group of the SAVA, South Africa; 18-22 February, pp. 33-42.
- Knottenbelt, D.C., 2003. Skin Neoplasia: Sarcoid, proceedings of 9th Congresso Nazionale Multisala SIVE, Pisa.
- Knottenbelt, D.C., 2005. A Suggested Clinical Classification for the Equine Sarcoid. Clinical Techniques in Equine Practice 4, 278-295.
- Komaromy, A.M., Andrew, S.E., Brooks, D.E., Detrisac, C.J., Gelatt, K.N., 2004. Periocular sarcoid in a horse. Veterinary Ophthalmology 7, 141-146.
- Martens, A., De Moor, A., Demeulemeester J., Ducatelle, R., 2000. Histopathological characteristics of five clinical types of equine sarcoid. Research in Veterinary Science 69, 295-300.

- Martens, A., De Moor, A., Vlaminck, L., Pille, F., Steenhaut, M., 2001. Evaluation of excision, cryosurgery and local BCG vaccination for the treatment of equine sarcoids. *The Veterinary Record* 149, 665-669.
- Marti, E., Lazary, S., Antczak, D.F., Gerber, H., 1993. Report of the 1st International Workshop on Equine Sarcoid. *Equine Veterinary Journal* 25, 397-407.
- McConaghy, F.F., Davis, R.E., Reppas, G.P., Rawlinson, R.J., McClintock, S.A., Hutchins, D.R., Hodgson, D.R., 1994. Management of equine sarcoids (1975-93). *New Zealand Veterinary Journal* 42, 180-184.
- Mohammed, H.O., Rebhun, W.C., Antczak, D.F., 1992. Factors associated with risk of developing sarcoid tumor in horses. *Equine Veterinary Journal* 24, 165-168.
- Pascoe, R.R., Knottenbelt, D.C., 1999. Neoplastic conditions. In: Pascoe, R.R., Knottenbelt, D.C. (Editors). *Manual of Equine Dermatology*. Saunders, London, pp. 244-252.
- Pulley, L.T., Stannard, A.A., 1990. Skin and soft tissues In: Moulton J.E. (editors). *Tumors in domestic animals*; University of California Press, Loss Angeles. pp. 27-31.
- Reid, S.W., Smith, K.T., Jarret, W.F.H., 1994. Detection, cloning and characterization of papilloma viral DNA present in sarcoid tumor. *The Veterinary Record* 135, 430-432.
- Studer, S., Gerber, V., Straub, R., Brehm, W., Gaillard, C., Luth, A., Burger, D., 2007. Prevalence of hereditary diseases in three-year-old Swiss Warmblood horses. *Schweizer Archiv Fur Tierheilkunde* 149, 161-171.
- Teifke, J.P., Lohr, C.V., 1996. Immuno histochemical detection of P53 in squamous cell carcinoma in cattle. *Journal of Comparative Pathology* 114, 205-210.
- Theon, A.P., 1998. Intralesional and topical chemotherapy and immunotherapy. *Journal of the American Veterinary Medical Association* 205, 1170- 1176.
- Torrontigui, B.O., Reid, S.J., 1994. Clinical and pathological epidemiology of the equine sarcoid in a population. *Equine Veterinary Education* 6, 85-88.
- Vanselow, B.A., Abetz, I., Jackson, A.R.B., 1988. BCG emulsion. Immune therapy of equine sarcoid. *Equine Veterinary Journal* 6, 444-447.
- Williams, I.F., Heaton, A., McCullagh, K.G., 1982. Connective tissue composition of the equine sarcoid. *Equine Veterinary Journal* 14, 305-310.
- Yu, A.A., 2006. Sarcoids, *AAEP Proceedings* 52, 478-483.