

Scalene Myofascial Pain Syndrome Mimicking Cervical Disc Prolapse: A Report of Two Cases

Nizar ABD JALIL¹, Mohammad Saufi AWANG², Mahamarowi OMAR¹

Submitted: 29 May 2009

Accepted: 2 Aug 2009

¹ Department of Anaesthesiology and Intensive Care, School of Medical Sciences, Universiti Sains Malaysia, 16150 Kubang Kerian, Kelantan, Malaysia

² Department of Neurosciences, School of Medical Sciences, Universiti Sains Malaysia, 16150 Kubang Kerian, Kelantan, Malaysia

Abstract

Scalene myofascial pain syndrome is a regional pain syndrome wherein pain originates over the neck area and radiates down to the arm. This condition may present as primary or secondary to underlying cervical pathology. Although scalene myofascial pain syndrome is a well known medical entity, it is often misdiagnosed as being some other neck pain associated with radiculopathy, such as cervical disc prolapse, cervical spinal stenosis and thoracic outlet syndrome. Because scalene myofascial pain syndrome mimics cervical radiculopathy, this condition often leads to mismanagement, which can, in turn, result in persistent pain and suffering. In the worst-case scenarios, patients may be subjected to unjustifiable surgical intervention. Because the clinical findings in scalene myofascial pain syndrome are “pathognomonic”, clinicians should be aware of ways to recognize this disorder and be able to differentiate it from other conditions that present with neck pain and radiculopathy. We present two cases of unilateral scalene myofascial pain syndrome that significantly impaired the patients’ functioning and quality of life. This case report serves to create awareness about the existence of the syndrome and to highlight the potential morbidity due to clinical misdiagnosis.

Keywords: cervical radiculopathy, myofascial pain syndrome, pain radiation, Scalene muscle, trigger point, medical sciences

Introduction

Myofascial Pain Syndrome (MPS) is a medical term used to describe chronic regional pain syndrome that presents with hyperirritable spots called trigger points (TPs) and/or tender spots (TSs) that arise from taut bands (TB) in the skeletal muscle. This chronic pain syndrome is often accompanied by a bizarre referred pain pattern that is specific to the muscle involved (1). Functionally, MPS causes the muscle to become weak and stiff, leading to reductions in range of movement. Thus, MPS is known as a major cause of morbidity, with a significant impact on daily activity, function and quality of life (1-6). Myofascial pain is treatable but is often under-treated due to lack of awareness among clinicians (3).

Scalene myofascial pain is a relatively common myofascial pain syndrome; however, it is commonly under-diagnosed or misdiagnosed as being some other neck pain-associated radiculopathy (2,3,4). The most preferred diagnoses among clinicians are cervical disc herniation/prolapse, cervical stenosis and

thoracic outlet syndrome (TOS), as most of these conditions are associated with neck pain and pain radiation to the arm (3,4). In other situations, the neurological symptom associated with scalene myofascial pain syndrome may either present with referred pain to the distal arm mimicking other well known causes of neuropathies, such as Carpal Tunnel Syndrome and peripheral polyneuropathy (2,4,5). These situations often lead to mismanagement and contribute to persistent pain and extra suffering (4,7). Because the clinical findings in scalene myofascial pain syndrome are pathognomonic, clinicians are expected to be able to make the diagnosis clinically in order to carry out effective management. These case reports serve to create awareness about the existence of the condition and to emphasize the relative ease of making the correct diagnosis, which can lead to successful treatments.

Case Report

Case 1

A 50-year-old Chinese woman presented to the orthopaedic clinic with neck pain associated with radiating pain and numbness over the radial distribution of her left hand. These symptoms persisted for three months without progression of neurological symptoms. She was a healthy person without any medical problems. Upon evaluation by the orthopaedic team, she was diagnosed with cervical spondylosis, presented with multiple cervical facet joint arthritis along with C6, C7 posterior cervical disc prolapse, which was confirmed by MRI. There was also minimal evidence of co-existing 6th nerve root impingement on her left side. Cervical X-rays showed no evidence of an accessory cervical rib, distorted clavicle bone fracture or elongated transverse process of C7. She was scheduled for several courses of cervical traction, in addition to being given a soft collar to prevent her from engaging in neck extension. Oral medications consisting of etoricoxib 60 mg daily (OD), gabapentin 300 mg three times a day (TDS), baclofen 10 mg TDS and neurobion 1 tablet twice a day (BD) were commenced. She was referred to the pain clinic because the pain persisted following the treatments, and she refused surgery as proposed by the orthopaedic surgeon. Cervical epidural steroid injection was also recommended by the managing team and she agreed.

In the pain clinic, the patient was re-evaluated and was found to have cervical facet joint tenderness bilaterally over the C2, C3 and C3, C4 level, in addition to pain and stiffness during both lateral flexion and extension of her neck. Neck flexion, however, did not aggravate her pain. Her left shoulder range of movement showed limited internal rotation due to pain. Tendon reflexes in the biceps (C5), supinator (C5, C6) and triceps (C7) were normal. Spurling's Test was negative for both sides of the neck. On further examination, she was found to have scattered TPs around her neck and shoulder arising from the left scalene, upper trapezius and supraspinatus muscles. She also displayed evidence of a classical 'jump sign' during digital compression over those muscles. The scalene TPs were typically reproducible during repeated digital compression with concomitant referred pain into the left hand side. The Scalene Cramp Test and Scalene Relief Test were positive. There were no trigger points found on the serratus anterior and pectoralis minor muscles. A diagnosis of secondary MPS of the left scalene anterior muscles, upper trapezius

and supraspinatus was made. There was no sign of dilatation of the subcutaneous collateral veins, oedema or cyanosis of the hands and fingers on the affected side to suggest subclavian vein thrombosis.

In the pain clinic, the patient was given a trigger point injection of 1 mL of 0.5% bupivacaine over the trapezius and supraspinatus muscles in a fan-shaped manner. TP injection of the anterior scalene muscle was performed in the operating room under nerve stimulator and fluoroscopy guidance. She received immediate pain relief following these TP injections; for long-term pain relief, she was scheduled for several courses of active stretching exercise and heat therapy by a physiotherapist. Amitriptyline 25mg ON and baclofen 10mg TDS were added to her treatment regiment. Her symptoms were dramatically relieved during the next visit to the pain clinic.

Case 2

A 36-year-old Thai woman came to the orthopaedic clinic with complaints of chronic right-sided neck pain with referred pain down to her right hand over the past four months. Initially, the pain started around the interscapular region and later extended to the posterior part of the neck and right shoulder. On further questioning, she admitted to having pain that radiated down to the radial side of her right hand with numbness over the fingers. She had neither any underlying medical problems nor a history of neck trauma. She worked as a clerk, which routinely required her to be at a desk for prolonged periods of time (i.e., throughout office hours).

On physical examination, she had good posture with no structural asymmetry. Extension, flexion and rotation of the neck were within the normal range. Palpation revealed tenderness over the right upper trapezius muscle. There were neither motor nor sensory deficits over the upper limbs. Tendon reflexes in the biceps (C5), supinator (C5, C6) and triceps (C7) were normal. Spurling's Test was negative for both sides of the neck. Cervical X-rays showed no evidence of accessory cervical rib, distorted clavicle bone fracture or elongated transverse process of C7. MRI revealed neither evidence of cervical spondylosis nor disc prolapse. A diagnosis of muscle strain of trapezius muscle was made. The patient was prescribed celecoxib 200mg BD, tramadol 50mg TDS and neurobion 1 tablet BD. The physiotherapist prescribed a few courses of deep heat therapy with shortwave diathermy. Active stretching and behavioural modification at her work place were also instituted. She was referred to the pain clinic as her pain had become

refractory and her Visual Analogue Pain Score (VAS) remained at 7/10.

In the pain clinic, she was found to have reproducible TPs over her right upper trapezius and right scalene muscles. Gentle digital pressure over the right scalene anterior muscle simply produced the 'jump sign' with referred pain to the radial distribution of her right hand side. The Scalene Cramp Test and the Scalene Relief Test were found to be positive. There were no trigger points found on the serratus anterior and pectoralis minor muscles. Diagnoses of MPS of the right scalene anterior and upper trapezius muscles were made. Nevertheless, there were no signs of subclavian vein thrombosis, such as dilatation of subcutaneous veins, oedema or cyanosis of the hands and fingers, and she was subjected to a few courses of scalene and upper trapezius active muscle stretching by a corresponding physiotherapist, in addition to shortwave diathermy heat treatment. With regard to pharmacological treatment, she was given amitriptyline 10 mg daily and eperison sodium 50 mg BD. Her symptoms improved gradually within one month, as she had been re-evaluated during follow up to the pain clinic.

Discussion

Cervical disc prolapse or cervical stenosis is often the primary concern when making a clinical diagnosis for a patient with neck pain and radiculopathy. Although TOS (including scalene muscle disorder) is an established clinical entity, scalene MPS is seldom included in the differential when making the diagnosis. Muscle pain in the neck, shoulder and arm caused by MPS often resembles cervical radiculopathy. The types of MPS that resemble cervical radiculopathy are those caused by MPS of pectoralis minor, scalene and serratus anterior, which need to be ruled out individually when assessing patients with symptoms of neck pain and "cervical radiculopathy" (4,5). For instance, MPS of the pectoralis minor causes neck and shoulder pain, which may radiate along the arm, simulating C7, C8 radiculopathy. Arm abduction often may add a neurovascular syndrome to pain due to the compression of the axillary artery and brachial plexus close to its insertion at the coracoid process. Serratus anterior usually causes pain in the chest under the axilla and sometimes causes dyspnea, especially during deep breathing. The pain may radiate down to the ulnar part of the arm, simulating C7, C8 radiculopathy (1,5).

MPS of scalene usually presents with unilateral neck and shoulder pain associated with

typical referred pain in the radial distribution of the affected arm/hand, simulating C6 radicular pain (Figure 1)(4). When the referred pain is due to MPS of the scalene muscle, the referred pain and numbness can be due to brachial plexus irritation as a result of direct compression between two scalene muscles (3,5). This phenomenon justifies the established fact that MPS of the scalene muscle is one of the causes of TOS. Therefore, it is prudent for clinicians to be able to distinguish the cause of "cervical radiculopathy", whether it is purely from MPS of the scalene (compression syndrome) or from a genuine cervical disc prolapse with nerve root impingement. In other words, one should be able to precisely differentiate whether the pain is 'radicular' or 'muscular' in origin or both (3,4).

The aetiology of MPS of the scalene muscle can be primary or secondary to other medical problems known as precipitating and perpetuating factors. Chronic muscle overuse, poor posture and repetitive microtrauma are the leading causes for the primary aetiology of this condition (1,6). This is clearly seen in case two, as the patient's desk job resulted in prolonged time at her work station, which resulted in the overuse of certain groups of muscles leading to MPS of the supraspinatus, upper trapezius and scalene muscles. Secondary MPS of scalene muscle is known to be associated with other medical problems such as osteoarthritis, trauma, complex regional pain syndrome (CRPS) and various systemic medical illnesses (1,5). It is not uncommon for scalene MPS to present as secondary to cervical spine diseases, such as cervical stenosis, disc prolapse, facet joint arthritis and post whiplash injury (1,5). As illustrated in case 1, the MPS of the scalene was secondary to facet joint arthropathy and cervical disc prolapse. In an extreme situation, the "radiculopathy" symptom can be a result either of secondary MPS of the scalene muscle or from the coexisting cervical disc prolapse with nerve root impingement. In this situation, one should be able to find the main pain generator that gives rise to the cervical "radiculopathy". Is it MPS of the scalene or cervical disc prolapse with nerve root impingement that is giving rise to the symptom of cervical radiculopathy?

As MPS of the scalene mimics cervical disc prolapse, the actual diagnosis of neck pain with radiculopathy can be misleading. For instance, in Case 1, MPS of the scalene muscle presented as the main pain generator in the presence of coexisting facet joint arthropathy and cervical disc prolapse; the significance of the former was not given due to recognition, while the diagnosis of cervical disc prolapse was preferred as it was consistent with the MRI findings. Unknowingly,

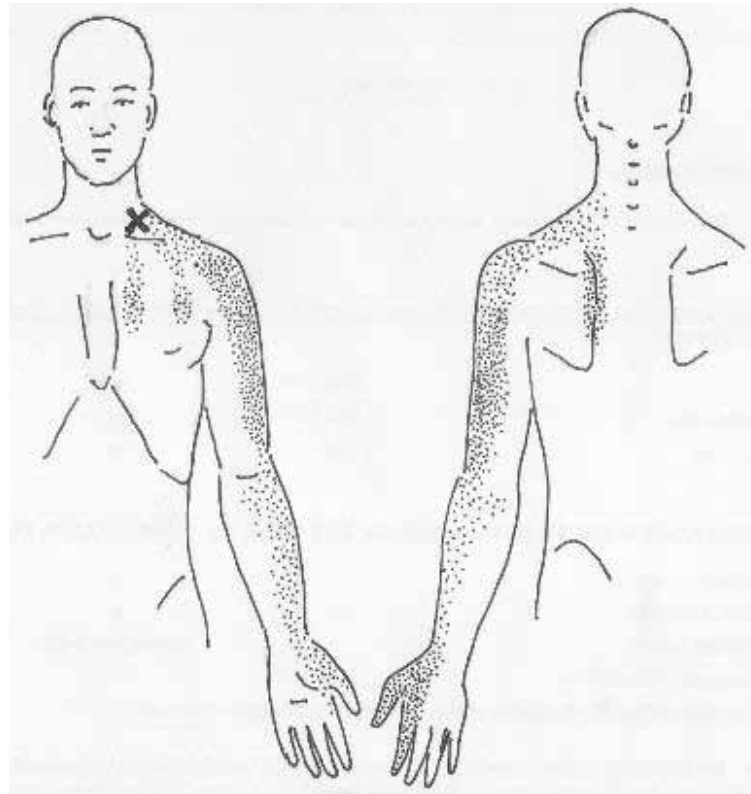


Figure 1: Location of pain and referred pain pattern in scalene MPS

the false positive from the MRI report had been cited, even though evidence of nerve root impingement from the MRI finding was trivial. After all, cervical disc prolapse/stenosis is often the more sought-after diagnosis. In addition, abnormal imaging findings are frequently found among asymptomatic individuals and may not necessarily be the cause of the pain (8). As a result, patients may be subjected to unnecessary surgery if the pain persists following conservative therapy failure (7). Therefore, it is prudent to identify and rule-in other possible causes of neck pain with ‘radiculopathy’ instead of ruling out cervical disc prolapse/stenosis as the first provisional diagnosis. With regard to this issue, TOS, including myofascial pain syndrome around the neck and shoulder, is the most sensible differential diagnosis to be entertained (2,3).

TOS may present as one of three different types, arterial, venous or neurogenic; each of these can be easily identified clinically. Neurogenic TOS is the most common, comprising over 90% of all TOS. Symptoms include extremity paraesthesia, pain and weakness as well as neck pain due to brachial plexus compression (1,3). The most common cause of neurogenic TOS originates from the scalene muscle. The scalene muscle could have been injured and scarred from

a previous injury (whiplash injury), development of tight congenital band or simply scalene MPS (3). Other causes of TOS that need to be ruled out include cervical rib syndrome, subclavian vein thrombosis, congenital band of scalene muscle, distorted clavicle bone fracture and an elongated transverse process of C7 (2,3,4).

Clinical diagnosis and management of MPS of scalene

Diagnosis of MPS of scalene is often considered after diagnosis of cervical disc prolapse has been ruled out. Diagnosis of cervical disc prolapse is often made from the typical history of neck pain that is made worse on neck flexion associated with cervical radiculopathy. This finding should be supported with a positive Spurling’s test during physical examination, in addition to significant evidence from MRI findings (10). Both of our cases were inconsistent with cervical disc prolapse, as the Spurling’s test was unremarkable. Once cervical disc prolapse is excluded, diagnosis of TOS-origin neck pain (including scalene) can then be evaluated. In our cases, the diagnosis was initially performed by a few provocation/relieving tests.

The Elevated Arm Stress Test is a sensitive screening test in TOS and, if positive, is suggestive

for TOS in origin. The test is done by asking the patient to elevate his/her arm with a flexed elbow to shoulder level for three minutes. This test is considered positive if the patient complains of an uncomfortable feeling, including pain and paraesthesia along the arm after less than three minutes (9). In order to determine if the scalene muscle is responsible, the above test should be followed by the Scalene Cramp Test and the Scalene Relief Test, which are pathognomonic for scalene MPS. A positive Scalene Cramp Test is appreciated when neck pain and radiculopathy are aggravated by placing the patient's chin over the ipsilateral supraclavicular groove for 60 seconds. Neck pain with radiculopathy or a tingling sensation on the lateral aspect of the hand is expected to be reproducible, as the anterior scalene muscle being compressed irritates the brachial plexus (9). This pain can be inhibited by performing the Scalene Relief Test, wherein the clinician asks the patient to bring his or her forearm up to the forehead and to rotate the shoulder forward on the symptomatic side. The cessation of pain and tingling sensation experienced during this manoeuvre is perceived as a positive Scalene Relief Test (9).

The principal management of MPS is performed by trigger point elimination, which corrects the perpetuating factors. Eradication of trigger points can be performed in combination with trigger point injection, stretching exercises, massage, deep heat therapy and oral medications (1,5). Active stretching exercises are the most fundamental of all, as they allow patients to be independent and to actively participate in the long-term management of their chronic pain (1). Pharmacologic treatment of patients with chronic musculoskeletal pain includes analgesia and medications to induce sleep and to relax the muscles. Antidepressants, narcotic analgesics, neuroleptics and non steroidal anti-inflammatory agents are often prescribed for these patients (1,5). Predisposing and perpetuating factors in chronic overuse or stress injuries of the muscles must be eliminated as they will increase the efficacy of other modalities and speed the process of recovery. Known perpetuating factors include biochemical, mechanical, metabolic, physiological, psychological and infectious factors. Such an evaluation is strongly indicated if appropriate treatment provides little or no pain relief from MPS. In primary MPS, correction of posture, an ergonomic human-machine system (Case 2) and structural realignment are of paramount importance in order for the positive effects to last beyond the treatment (1,5).

Conclusion

Myofascial pain syndrome of the scalene muscle may present with neck pain and cervical radiculopathy, which has been frequently underdiagnosed. A lack of awareness among physicians may lead to misdiagnosis and thus to inappropriate management.

Author's contributions

Conception and design, data analysis and interpretation, drafting of the article: NAJ
Critical revision of the article: NAJ, MSA
Provision of study materials or patients: MSA
Administrative, technical or logistic support: MA

Correspondence

Dr Nizar Abd. Jalil
MD (UKM), MMed Anaesthesiology (HUSM),
Coordinator of Multidisciplinary Pain Management
Unit
Department of Anaesthesiology and Intensive Care,
School of Medical Sciences
Universiti Sains Malaysia
16150 Kubang Kerian
Kelantan, Malaysia
Tel: +609-767 6095
Fax: +609-765 3370
Email: nizar@kb.usm.my

References

1. Simons DG, Travell JG, Simons LS. Travell & Simons' Myofascial Pain and Dysfunction: The Trigger Point Manual. 2nd ed. Baltimore: William & Wilkins. 1999; p. 94-173.
2. Flax HJ. Myofascial Pain Syndrome: The Great Mimicker. *Bol Assoc Med PR*. 1995;**87**:167-170.
3. Roos DB. Thoracic Outlet Syndrome is Underdiagnosed. *Muscle Nerve*. 1999;**22**(1):137-138.
4. Facco E, Ceccherelli F. Myofascial Pain Mimicking Radicular Syndromes. *Acta Neurochir*. 2005;(Suppl) **92**:147-150.
5. Yap EC. Myofascial Pain—An Overview. *Ann Acad Med Singapore*. 2007;**36**:43-48.
6. Lin TY, Teixeira MJ, Fischer AA, Barboza HFG, Imamura ST, Matter R, et al. Work-related Musculoskeletal Disorders. *Phys Med Rehabil Clin North Am*. 1997;**83**:113-119.
7. Marcus NJ. Failure to Diagnose Pain of Muscular Origin Leads to Unnecessary Surgery. *Pain Medicine*. 2002;**3**:2.

8. Boden SD, Davis DO, Dina TS, Patronas NJ, Wiesel SW. Abnormal Magnetic-resonance Scan of the Lumbar Spine in Asymptomatic Subjects. A Prospective Investigation. *J Bone Joint Surg Am.* 1990;**72**:403–408.
9. Richard F, Shifflet CM. Range of Motion Testing. [Internet]. Pittsburgh: Round Earth Publishing. [cited 2009 June 12]. Available from: <http://www.round-earth.com/CervicalTests.html>.
10. Shah KC, Rajshekhar V. Reliability of Diagnosis of Soft Cervical Disc Prolapse Using Spurling's Test. *Br J Neurosurg.* 2004;**18(5)**:480–483.