

 Open access • Posted Content • DOI:10.1097/CM9.0000000000001799

## **Schroth exercises improve health-related quality of life and radiographic parameters in adolescent idiopathic scoliosis patients. — [Source link](#)**

Ang Gao, Jun-Yu Li, Rui Shao, Tong-Xuan Wu ...+3 more authors

**Institutions:** Peking University

**Published on:** 13 Oct 2021 - Chinese Medical Journal (Ovid Technologies (Wolters Kluwer Health))

**Topics:** Cobb angle and Scoliosis

Related papers:

- [Relationship between cervical sagittal alignment and health-related quality of life in adolescent idiopathic scoliosis.](#)
- [Association Between Radiographic Spinopelvic Parameters and Health-related Quality of Life in De Novo Degenerative Lumbar Scoliosis and Concomitant Lumbar Spinal Stenosis.](#)
- [Discrimination validity of the scoliosis research society – 22 patient questionnaire: relationship to idiopathic scoliosis curve pattern and curve size](#)
- [Clinical Relevance of the SRS-Schwab Classification for Degenerative Lumbar Scoliosis.](#)
- [Validity of the Walter Reed Visual Assessment Scale to measure subjective perception of spine deformity in patients with idiopathic scoliosis](#)

Share this paper:    

View more about this paper here: <https://typeset.io/papers/schroth-exercises-improve-health-related-quality-of-life-and-2ci4fmsz0e>

# Improvement of health-related quality of life and radiographic parameters in adolescent idiopathic scoliosis patients after Schroth exercises

**Ang Gao**

Peking University Third Hospital

**Junyu Li**

Peking University Third Hospital

**Rui Shao**

Peking University Third Hospital

**Miao Yu** (✉ [miltonyupku@163.com](mailto:miltonyupku@163.com))

Peking University Third Hospital <https://orcid.org/0000-0002-9728-7997>

**Tongxuan Wu**

Peking University Third Hospital

**Yongqiang Wang**

Peking University Third Hospital

**Xiaoguang Liu** (✉ [puthliu@126.com](mailto:puthliu@126.com))

Peking University Third Hospital

---

## Research article

**Keywords:** Adolescent idiopathic scoliosis; Schroth exercises; health-related quality of life; Curve progression; Cervical alignment

**Posted Date:** July 1st, 2020

**DOI:** <https://doi.org/10.21203/rs.3.rs-33670/v1>

**License:** © ⓘ This work is licensed under a Creative Commons Attribution 4.0 International License.

[Read Full License](#)

---

**Version of Record:** A version of this preprint was published at Chinese Medical Journal on October 13th, 2021. See the published version at <https://doi.org/10.1097/CM9.0000000000001799>.

# Abstract

**Background** Finding an optimal treatment strategy for adolescent idiopathic scoliosis (AIS) patients remains challenging because of its intrinsic complexity. For mild to moderate scoliosis patients with lower skeletal growth potential (Risser 3–5), most clinicians agree with observation treatment; however, the curve progression that occurs during puberty, the adolescent period, and even in adulthood, remains a challenging issue for clinicians. The aim of study is to investigate the efficacy of Schroth exercise in adolescent idiopathic scoliosis (AIS) patients with lower skeletal growth potential (Risser 3-5) and moderate scoliosis (Cobb angle 20-40°).

**Methods** Data from 43 patients diagnosed with AIS and performed Schroth exercise were reviewed, and outcomes were measured by health-related quality of life (HRQOL) and radiographic parameters. HRQOL was assessed using the visual analog scale (VAS) scores for back, Scoliosis Research Society-22 (SRS-22) patient questionnaire. Radiographic spinopelvic parameters were obtained from anteroposterior and lateral X-rays. The pre-treatment and post-treatment HRQOL and radiographic parameters were tested to validate Schroth exercise efficacy.

**Results** Vas back score, SRS-22 pain and SRS-22 self-image domain domain were significantly improved from pre-treatment  $3.0\pm 0.8$ ,  $3.6\pm 0.5$  and  $3.5\pm 0.7$  to post-treatment  $1.6\pm 0.6$ ,  $4.0\pm 0.3$  and  $3.7\pm 0.4$ , respectively. No significant improvement of SRS-22 function domain and mental health domain. The mean Cobb angle decreased from  $28.9\pm 5.5^\circ$  to  $26.3\pm 5.2^\circ$  at the final follow-up, despite no statistical significance was observed. The mean C2-C7 sagittal vertical axis (SVA) value decreased from  $21.7\pm 8.4$  mm to  $17.0\pm 8.0$ mm and mean T1 tilt decreased from  $4.9\pm 4.2^\circ$  to  $3.5\pm 3.1^\circ$ . No other significant improvement of radiographic parameters was observed.

**Conclusions** For AIS patients with a Risser 3–5 and a Cobb angle 20°–40°, Schroth exercises improved HRQOL and halted curve progression during the follow-up period. Both cervical spine alignment and shoulder balance were also significantly improved after Schroth exercises. We recommend Schroth exercises for patients with AIS.

## Background

Adolescent idiopathic scoliosis (AIS) is the most common type of scoliosis. However, finding an optimal treatment strategy remains challenging because of its intrinsic complexity. Age, sex, skeletal maturity, Cobb angle, menarche status, and other factors should be considered during clinical evaluation [1]. Non-operative treatment is recommended for patients with a major curve less than 45° according to the Scoliosis Research Society (SRS) criteria, and brace treatment is strongly recommended to halt curve progression in patients with a Risser sign 0–2 with moderate scoliosis due to its rapid skeletal growth [2].

For mild to moderate scoliosis patients with lower skeletal growth potential (Risser 3–5), most clinicians agree with observation treatment; however, the curve progression that occurs during puberty, the adolescent period, and even in adulthood, remains a challenging issue for clinicians [3–5]. Watanabe et

al. further validated this viewpoint in a mean 25-year follow-up, and provide an explicit value – 0.5° per year [6]. Moreover, decline of health-related quality of life (HRQOL) was also observed, indicating that a strategy with the possibility of long-term sustainability is needed to eliminate this concern.

The effectiveness physical therapy for improving HRQOL and halting curve progression has been well established in AIS patients with mild scoliosis [7–9]. However, its outcomes in patients with lower skeletal growth potential (Risser 3–5) and larger curvatures remain unknown. Schreiber investigated Schroth exercises—physiotherapeutic scoliosis-specific exercises in patients with curve angles from 10° to 45°, and found improvements in HRQOL [10]. Nevertheless, Schroth exercises were unable to reduce the Cobb angle in this study. A limitation of Schreiber’s study was the lack of a Risser sign description, which is important for skeletal growth potential evaluation, Therefore, our study attempted to validate the effectiveness of Schroth exercises in patients with lower skeletal growth potential (Risser 3–5) and moderate scoliosis (20°–40°).

## **Methods**

### **Inclusion criteria**

Our hospital’s electronic database was retrospectively reviewed. Patients treated between January 2015 and December 2017 were enrolled. The inclusion criteria were as follows: 1) a primary diagnosis of AIS in patients aged between 10 and 17 years; 2) a Risser sign of 3, 4, or 5; 3) a Cobb angle between 20° and 40°; 4) performance of Schroth exercises during intensive training, and adherence to a home exercise program; 5) a minimum 2-year follow-up was achieved; and 6) the availability of complete radiographs.

### **Exclusion criteria**

The exclusion criteria were as follows: 1) prior brace treatment history; 2) prior physical exercise history; 3) prior surgical treatment; 4) cardiac and/or respiratory dysfunction; 5) other types of scoliosis; and 6) psychiatric disease (hysteria, psychosis, and others).

### **Schroth exercise treatment**

The Schroth exercises were performed according to the Barcelona Scoliosis Physical Therapy School protocol. Auto elongation, asymmetrical sagittal straightening, frontal plane correction, rotational angular breathing, and stabilization variations were the primary outcome variables. During winter vacation/summer vacation, patients first underwent a 14-day intensive training program supervised by certificated physical therapists (Fig. 1). After intensive training, patients continued self-exercise through a home exercise program that was supervised by parents. The training frequency was set to two or three times per week for 1 hour.

### **Assessments**

HRQOL was assessed using the Scoliosis Research Society-22 (SRS-22) patient questionnaire which consists of 5 domains: function, pain, mental health, self-image, and satisfaction with management. The results were expressed as the mean score for each domain. Visual Analog Scale (VAS) scores for back pain were also noted. Data were extracted from the electronic database containing original medical records.

Scoliosis progression was evaluated using the Cobb angle. Radiographic parameters were as follows:

- 1) global spine parameters: coronal vertical axis (CVA) and sagittal vertical axis (SVA);
- 2) cervical spine parameters: C2-C7 Cobb angle and C2-7 SVA (Fig. 2);
- 3) thoracic and lumbar spine parameters: lumbar lordosis (LL), thoracic kyphosis (TK), and thoracolumbar kyphosis (TLK); and
- 4) shoulder balance parameters: coracoid height difference (CHD), clavicular angle (Cla-A), and T1 tilt (Fig. 2).

All parameters were obtained from anteroposterior and lateral X-rays that were obtained from the electronic database. The parameters were measured independently by two spine surgeons using the Picture Archiving and Communication System (PACS system, GE, Waukesha, WI, USA), and the mean values were recorded.

## Statistical analysis

Clinical and radiographic data were analysed using the Statistical Package for the Social Sciences version 22.0 (SPSS, Inc., Chicago, IL, USA). The inter-rater reliability of the radiographic parameters was tested using the interclass correlation coefficient (ICC). The paired t-test was used to compare the pre- and post-treatment SRS pain domain, SVA, Cobb angle, C2-C7 Cobb angle, C2-C7 SVA, LL, TK, CHD, Cla-A, and T1 tilt. The Wilcoxon signed-rank test was used to examine other pre- and postoperative HRQOL (VAS back score, SRS-22 function domain, SRS-22 mental health domain, and SRS-22 self-image domain) and radiographic parameters (TLK and CVA). Clinical relevance between C2-C7 SVA and TK was analyzed using Spearman's correlation. Statistical significance was considered at a  $p$  value  $< 0.05$ .

## Results

### Patient characteristics

Between January 2015 and December 2017, 43 patients (7 boys, 36 girls) with a mean age of  $15.1 \pm 1.6$  (range, 13–17) years were enrolled. The mean follow-up period was  $31.9 \pm 8.2$  (range, 25–52) months.

Among this population, the apical vertebra was T7 in five cases, T8 in four cases, T9 in three cases, T10 in two cases, T11 in five cases, T12 in seven cases, L1 in six cases, L1/2 in five cases, and L2 in six cases.

Risser sign was recorded as follows: Risser sign 3 was observed in nine patients, Risser sign 4 in 19, and Risser sign 5 in 15 patients.

## Effect of Schroth exercises on HRQOL

VAS back and SRS-22 pain domain scores were significantly improved after the Schroth exercise program (Table 1) as evidenced by decreases in the mean VAS scores (pretreatment:  $3.0 \pm 0.8$  [range, 2–4]; post-treatment:  $1.6 \pm 0.6$  [range, 1–3];  $p = 0.013$ ) and improvements in the mean SRS-22 pain scores (pretreatment:  $3.6 \pm 0.5$  [range, 3.0–4.2]; post-treatment:  $4.0 \pm 0.3$  [range, 3.4–4.4];  $p = 0.001$ ). The SRS self-image scores improved (Table 1) from  $3.5 \pm 0.7$  (range, 2.8–4.0) pretreatment to  $3.7 \pm 0.4$  (range, 3.0–4.4) post-treatment ( $p < 0.001$ ) (Table 1).

Table 1  
HRQOL before exercise and at final follow-up

Parameters	Pre-exercise	Final follow-up	Statistical analysis
VAS Back	$3.0 \pm 0.8$	$1.6 \pm 0.6$	0.013*
SRS-22 Pain	$3.6 \pm 0.5$	$4.0 \pm 0.3$	0.001**
SRS-22 Function	$3.9 \pm 0.2$	$4.1 \pm 0.2$	0.088
SRS-22 Mental Health	$4.0 \pm 0.3$	$4.1 \pm 0.2$	0.061
SRS-22 Self-Image	$3.5 \pm 0.7$	$3.7 \pm 0.4$	$<0.001$ **
SRS-22 Satisfaction		$4.3 \pm 0.3$	
** $p < 0.01$ , * $p < 0.05$			

The SRS-22 mental health (pretreatment:  $4.0 \pm 0.3$  [range, 3.2–4.4]; post-treatment:  $4.1 \pm 0.2$  [range, 3.6–4.4]) and function scores (pretreatment:  $3.9 \pm 0.2$  [range, 3.4–4.4]; post-treatment:  $4.1 \pm 0.2$  [range, 3.6–4.4]) improved after the Schroth exercise program; however, the differences were not statistically significant ( $p = 0.061$  and  $p = 0.088$ , respectively) (Table 1).

## Effect of Schroth exercises on radiographic parameters

The inter-rater ICC values of the radiographic parameters are shown in Table 2. After Schroth exercise treatment, the average Cobb angle decreased from  $28.9^\circ \pm 5.5^\circ$  (range,  $21.1^\circ$ – $36.4^\circ$ ) to  $26.3^\circ \pm 5.2^\circ$  (range,  $19.8^\circ$ – $36.3^\circ$ ) at the final follow-up (Fig. 3), but the difference was not statistically significant ( $p = 0.084$ ) (Table 2). Six patients experienced curve progression with a mean curve progression of  $1.2^\circ \pm 1.1^\circ$  (range,  $0.3^\circ$ – $2.4^\circ$ ) per year. No patient was the candidate of surgery during the follow-up period.

Table 2  
Radiographic parameters before exercise and at final follow-up

Parameters	Pre-exercise	Inter-rater ICC	Final follow-up	Inter-rater ICC	Statistical analysis
Cobb angle (°)	28.9 ± 5.5	0.913	26.3 ± 5.2	0.922	0.084
SVA (mm)	-13.08 ± 22.3	0.881	-11.47 ± 22.2	0.901	0.802
CVA (mm)	15.6 ± 10.7	0.931	12.7 ± 8.3	0.921	0.215
C2-C7 Cobb angle (°)	-6.5 ± 11.4	0.873	-3.5 ± 7.6	0.832	0.240
C2-C7 SVA (mm)	21.7 ± 8.4	0.852	17.0 ± 8.0	0.864	0.049*
LL (°)	48.7 ± 8.0	0.926	52.0 ± 13.3	0.931	0.224
TK (°)	17.9 ± 7.1	0.910	19.7 ± 5.6	0.873	0.316
TLK (°)	10.1 ± 7.8	0.857	7.8 ± 5.8	0.878	0.127
CHD (mm)	5.6 ± 4.2	0.821	7.2 ± 5.6	0.819	0.355
Cla-A (°)	2.0 ± 1.6	0.813	1.7 ± 1.2	0.821	0.493
T1 tilt (°)	4.9 ± 4.2	0.926	3.5 ± 3.1	0.934	0.011*
** $p \leq 0.01$ , * $p \leq 0.05$					

After Schroth exercises, the average C2-C7 SVA value decreased significantly from 21.7 ± 8.4 mm (range, 11.7– 42.2 mm) to 17.0 ± 8.0 mm (range, 10.7– 35.5 mm) at the final follow-up ( $p = 0.049$ ); however, the C2-C7 Cobb angle values were not significantly different before and after Schroth exercises ( $p = 0.240$ ) (Table 2). The correlation between C2-C7 SVA value variation and TK value variation was not confirmed by Spearman's correlation analysis ( $p = 0.991$ ).

Among parameters of shoulder balance, the mean T1 tilt decreased from 4.9° ± 4.2° (range, 0.4°– 14.7°) to 3.5° ± 3.1° (range, 0.3°– 11.9°) at the final follow-up ( $p = 0.011$ ); however, CHD and Cla-A values were not significantly different before and after Schroth exercises ( $p = 0.355$  and  $p = 0.493$ , respectively) (Table 2).

The differences between pre- and post-treatment SVA, CVA, TK, TLK, and LL values were not statistically significant ( $p = 0.802$ ,  $p = 0.215$ ,  $p = 0.316$ ,  $p = 0.127$ , and  $p = 0.224$ , respectively) (Table 2).

## Discussion

The decline in HRQOL and curve progression were two major concerns in previous publications on AIS conservative treatment, and a strategy with long-term sustainability was needed to dispel these concerns. Both improvements of HRQOL and halt of curve progression after Schroth exercises were validated in this preliminary study, providing some new viewpoints concerning AIS conservative treatment.

# Effect of Schroth exercises on HRQOL improvement

Multiple strategies are used to manage non-surgery candidate AIS patients, including observation, bracing, and physical exercise, and the effectiveness of physical exercise is ambiguous [11]. Kuru reported that no definite HRQOL (SRS-23) improvement was observed in patients with a wide range of scoliosis severity ( $10^{\circ}$ – $60^{\circ}$ ) and Risser sign 0–3 [12]. However, Monticone et al. reported better satisfying HRQOL improvements with physical exercise in mild scoliosis patients, and Schreiber et al. also advocated that mild to moderate scoliosis patients with all grades of Risser sign could benefit from Schroth exercises, with SRS-22 pain and self-image domains improvements [13]. We speculated that the causes of the discrepancy were the scoliosis severity of the cohorts included in previous studies and the heterogeneity of the growth potential.

To reduce the potential bias of a heterogeneous cohort, we set thresholds for the Cobb angle between  $20^{\circ}$ – $40^{\circ}$  and only included patients with lower skeletal growth potential (Risser 3–5), which ruled out patients strongly recommended for brace treatment by the SRS and the International Society on Scoliosis Orthopaedic and Rehabilitation Treatment guidelines. In our study, good outcomes were observed: VAS scores for back pain decreased notably, while the mean SRS-22 pain and self-image domains improved significantly after treatment.

Although mild pain is reported in mild to moderate scoliosis [11, 13], relatively higher pain values were observed in this study, and pain values (VAS back score and SRS-22 pain domain) improved successfully after treatment. We speculated that one possible reason was the onset of long sitting study time in AIS patients. Shan investigated the neck and shoulder pain (NSP) in high school teenagers, and more than 40% adolescents reported NSP resulting from schooling factors related to study [14]. Based on the relatively similar age onset to this study, we speculated that relatively higher pain values resulted not only from scoliosis, but also their fatigue postures related to study, indicating some social factors should also be taken into consideration for improving HRQOL of AIS patients, not only deformity itself. Thus, we considered Schroth exercises rather than observation-only to strengthen and balance their muscles which may have contributed to their pain relief.

Aiming to investigate self-image assessment in adulthood, Watanabe found significantly worse scores for the SRS-22 self-image domain in all types of scoliosis groups [6]. Yet, Schreiber was the first to validate SRS-22 self-image domain improvements with Schroth exercises [13]. A similar finding was observed in our study, i.e., the mean SRS-22 self-image domain also improved after Schroth exercises, indicating that such exercises were effective for correcting the appearances of both sagittal and frontal asymmetries. We assumed that the latent worse self-image scores in the previous study originated from scoliosis, indicating that a treatment strategy is required to provide long-term sustainability. Schroth exercises were proven to be effective for the early treatment of scoliosis; however, a long-term follow-up study is still necessary.

# Effect of Schroth exercises on preventing curve progression



Bracing is not recommended for patients with a Risser sign of 3–5 due to their lower skeletal growth potential. Moreover, the effectiveness of further treatment strategies for patients with a Cobb angle  $< 45^\circ$  is ambiguous [11], and observation is recommended for most patients. However, curve progression was reported to be inevitable after skeletal maturity, with a mean Cobb angle progression from baseline  $29.2^\circ$ – $29.3^\circ$  to  $35.0^\circ$ – $37.8^\circ$  in adulthood [4, 15].

Monticone et al. [9] found that the Cobb angle decreased from  $19.3^\circ$  to  $14.3^\circ$  in patients with skeletal immaturity (Risser 0–2) after physical exercise. Although the Cobb angle at the last follow-up was lower than the baseline value, no statistical significance was observed. We speculated that the real value of Schroth exercises for moderate AIS patients was to halt curve progression rather than reduce the curve, but a further study was needed to validate this viewpoint.

## **Effect of Schroth exercises on shoulder balance and cervical sagittal alignment parameters**

Regarding shoulder balance, few studies have clarified its relationship with AIS after physical therapy [16]. Zheng found no statistically significant improvements in shoulder balance parameters (CHD, Cla-A, and T1 tilt) in the exercise group, whereas the bracing group experienced significant improvements [16]. Notably, in our study, T1 tilt was significantly improved whereas CHD and Cla-A were not. Kwan advocated that T1 tilt was a parameter associated with neck tilt rather than shoulder balance [17], and our findings indicated that neck tilt was improved rather than shoulder balance in this hypothesis. However, this theory was not supported by other authors. Chiu reported that conformity values varied for different shoulder balance statuses, and T1 tilt showed the best conformity with shoulder balance [18]. We inferred that shoulder balance status could be improved by the identification of T1 tilt value variation, and the finding that CHD and Cla-A values were not significantly improved was attributed to its intrinsic conformity. Thus, further studies are needed to clarify this issue.

Few investigators have studied cervical sagittal alignment and physical exercise. This study is the first to report that C2-C7 SVA could be significantly improved by Schroth exercises. Akabar [19] demonstrated that cervical kyphosis is associated with hypokyphotic thoracic alignment, and Neuman [20] further validated that reciprocal changes in cervical alignment are associated with TK. In contrast to their findings, no correlation between the improvements in C2-C7 SVA and TK values and significant changes in TK values were detected in our study. Consequently, we speculated that the improvement in cervical alignment resulted from the cumulative exercise effects of asymmetrical sagittal straightening and muscle strength improvement rather than as a result of reciprocal changes in TK. Accordingly, cervical spine malalignment may be corrected using Schroth exercises, and we advocate Schroth exercises as an ideal treatment strategy for AIS patients.

## **Limitations**

This study has several limitations. Firstly, it was retrospective and conducted at a single centre. Secondly, this was a preliminary study of Schroth exercises with a minimum 2-year follow-up, and a study with a

10-year follow-up is still needed to validate its effectiveness. Finally, some other physical exercises should also be studied in further investigations.

## **Conclusion**

For AIS patients with a Risser 3–5 and a Cobb angle 20°–40°, Schroth exercises improved HRQOL and halted curve progression during the follow-up period. Both cervical spine alignment and shoulder balance were also significantly improved after Schroth exercises. We recommend Schroth exercises for patients with AIS.

## **Declarations**

### **Ethics approval and consent to participate**

A positive vote of the ethics committee of Peking University Third Hospital, was obtained for the study (ethics committee approval number: RB00006761–2012033)

### **Consent to publish**

Not applicable.

### **Availability of data and materials**

The datasets used and/or analysed for the current study can be provided by the corresponding author on reasonable request.

### **Competing interests**

The authors declare that they have no competing interests.

### **Funding**

Not applicable.

### **Authors' Contributions**

YM and LXG conceived and designed the study. GA wrote the manuscript with contributions by YM, LJY, and WTX. WTX, SR and WYQ performed the radiographic measurements and assessed clinical outcomes. LJY and SR performed the statistical analysis. All authors analysed and interpreted the data. All authors discussed, revised, and approved the final manuscript.

### **Acknowledgements**

We thank the Editage for language editing.

## References

1. Negrini S, Hresko TM, O'Brien JP, et al (2015) Recommendations for research studies on treatment of idiopathic scoliosis: Consensus 2014 between SOSORT and SRS non-operative management committee. *Scoliosis*. <https://doi.org/10.1186/s13013-014-0025-4>.
2. Richards BS, Bernstein RM, D'Amato CR, et al. Standardization of criteria for adolescent idiopathic scoliosis brace studies: SRS Committee on bracing and non-operative management. *Spine*. 2005;30(18):2068–75. <https://doi.org/10.1097/01.brs.0000178819.90239.d0>.
3. Danielsson AJ, Hasserius R, Ohlin A, et al. Health-related quality of life in untreated versus brace-treated patients with adolescent idiopathic scoliosis: a long-term follow-up. *Spine*. 2010;35(2):199–205. <https://doi.org/10.1097/BRS.0b013e3181c89f4a>.
4. Danielsson AJ, Hasserius R, Ohlin A, et al. Body appearance and quality of life in adult patients with adolescent idiopathic scoliosis treated with a brace or under observation alone during adolescence. *Spine*. 2012;37(9):755–62. <https://doi.org/10.1097/BRS.0b013e318231493c>.
5. Cheung JPY, Cheung PWH, Samartzis D, et al. Curve progression in adolescent idiopathic scoliosis does not match skeletal growth. *Clin Orthop Relat Res*. 2018;476(2):429–36. <https://doi.org/10.1007/s11999-0000000000000027>.
6. Watanabe K, Ohashi M, Hirano T, et al. Health-Related Quality of Life in non-operated patients With adolescent idiopathic scoliosis in the middle years: A mean 25-year follow-up study. *Spine*. 2020;45(2):E83–9. <https://doi.org/10.1097/BRS.00000000000003216>.
7. Negrini S, Donzelli S, Negrini A, et al. Specific exercises reduce the need for bracing in adolescents with idiopathic scoliosis: A practical clinical trial. *Ann Phys Rehabil Med*. 2019;62(2):69–76. <https://doi.org/10.1016/j.rehab.2018.07.010>.
8. Zapata KA, Sucato DJ, Jo CH. Physical therapy scoliosis-specific exercises may reduce curve progression in mild adolescent idiopathic scoliosis curves. *Pediatr Phys Ther*. 2019;31(3):280–5. <https://doi.org/10.1097/PEP.0000000000000621>.
9. Monticone M, Ambrosini E, Cazzaniga D, et al. Active self-correction and task-oriented exercises reduce spinal deformity and improve quality of life in subjects with mild adolescent idiopathic scoliosis. Results of a randomised controlled trial. *Eur Spine J*. 2014;23(6):1204–14. <https://doi.org/10.1007/s00586-014-3241-y>.
10. Schreiber S, Parent EC, Hill DL, et al. Patients with adolescent idiopathic scoliosis perceive positive improvements regardless of change in the Cobb angle - Results from a randomized controlled trial comparing a 6-month Schroth intervention added to standard care and standard care alone. SOSORT 2018 Award winner. *BMC Musculoskelet Disord*. 2019;20(1):319–29. <https://doi.org/10.1186/s12891-019-2695-9>.
11. Negrini S, Donzelli S, Aulisa A, et al. SOSORT Guidelines: Orthopaedic and rehabilitation treatment of idiopathic scoliosis during growth. *Scoliosis Spinal Disord*. 2016. <https://doi.org/10.1186/s13013-017-0145-8>.

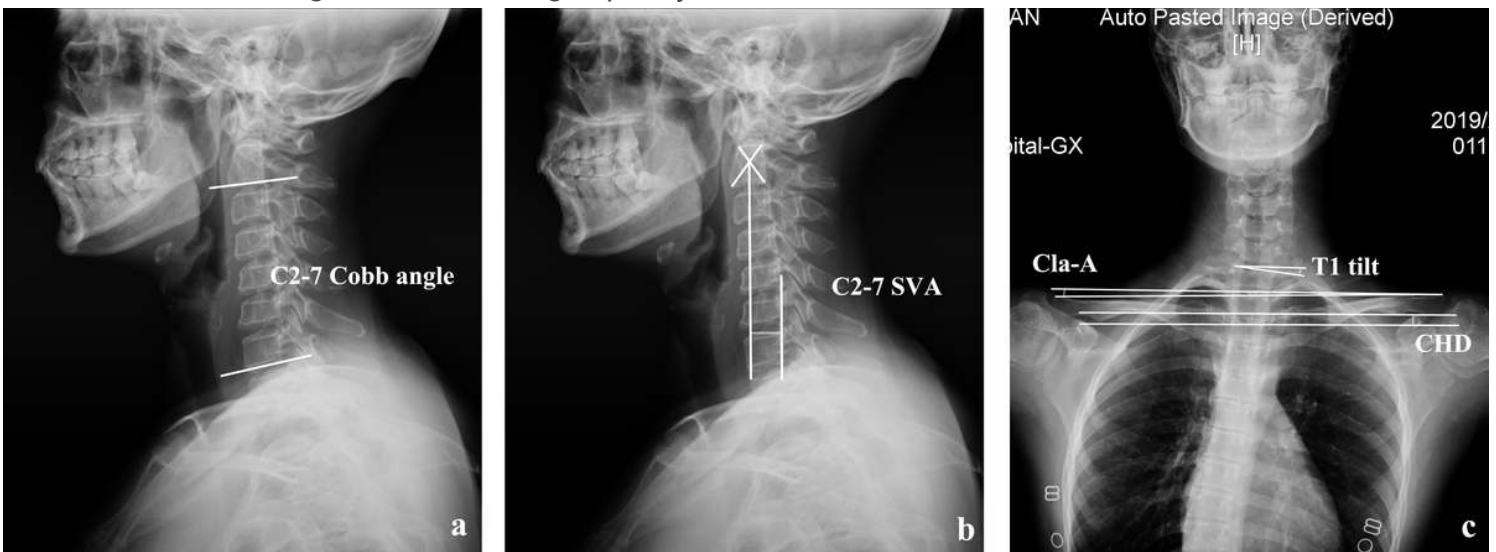12. Kuru T, Yeldan I, Dereli E, et al. The efficacy of three-dimensional Schroth exercises in adolescent idiopathic scoliosis: A randomised controlled clinical trial. *Clin Rehabil.* 2016;30(2):181–90. <https://doi.org/10.1177/0269215515575745>.
13. Schreiber S, Parent E, Moez E, et al (2015) The effect of Schroth exercises added to the standard of care on the quality of life and muscle endurance in adolescents with idiopathic scoliosis-An assessor and statistician blinded randomized controlled trial: "SOSORT 2015 Award Winner". *Scoliosis.* <https://doi.org/10.1186/s13013-015-0048-5>.
14. Shan Z, Deng G, Li J, et al. How schooling and lifestyle factors effect neck and shoulder pain? A cross-sectional survey of adolescents in China. *Spine.* 2014;39(4):E276–83. <https://doi.org/10.1097/BRS.000000000000124>.
15. Schwieger T, Campo S, Weinstein S, et al. Body image and Quality-of-Life in untreated versus brace-treated females with adolescent idiopathic scoliosis. *Spine.* 2016;41(4):311–9. <https://doi.org/10.1097/BRS.0000000000001210>.
16. Zheng Y, Dang Y, Yang Y, et al. Whether orthotic management and exercise are equally effective to the patients with adolescent idiopathic scoliosis in mainland china?: A randomized controlled trial study. *Spine.* 2018;43(9):E494–503. <https://doi.org/10.1097/BRS.0000000000002412>.
17. Kwan M, Wong K, Lee C, et al. Is neck tilt and shoulder imbalance the same phenomenon? A prospective analysis of 89 adolescent idiopathic scoliosis patients (Lenke type 1 and 2). *Eur Spine J.* 2016;25(2):401–8. <https://doi.org/10.1007/s00586-015-4016-9>.
18. 10.1097/BRS.0000000000003275  
Chiu C, Chan C, Tan P, et al (2018) Conformity and changes in the radiological neck and shoulder balance parameters throughout 3 years Follow-up period: Do they remain the same? *Spine* 15;45(6): 319–328. <https://doi.org/10.1097/BRS.0000000000003275>.
19. Akbar M, Almansour H, Lafage R, et al. Sagittal alignment of the cervical spine in the setting of adolescent idiopathic scoliosis. *J Neurosurg Spine.* 2018;29(5):506–14. <https://doi.org/10.3171/2018.3.SPINE171263>.
20. Neuman B, Harris A, Jain A, et al. Reciprocal Changes in Cervical Alignment After Thoracolumbar Arthrodesis for Adult Spinal Deformity. *Spine.* 2019;44(22):1311–6. <https://doi.org/10.1097/BRS.0000000000003159>.

## Figures



**Figure 1**

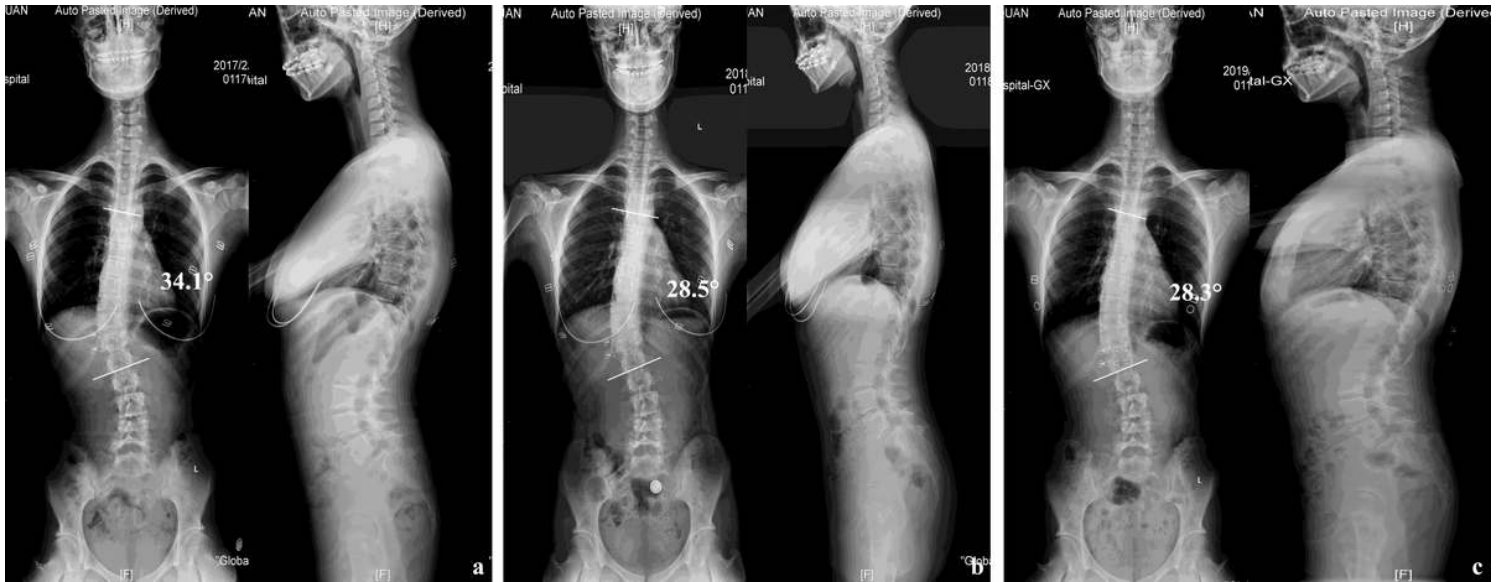
Illustration of Schroth exercises. (a) patients received breath-training exercise; (b) patients received muscle strength control exercise; (c) patients received active body-shape correction exercise; (d) patients received muscle strength and balancing capacity exercise.



**Figure 2**

Illustration of radiographic parameters. (a) C2-7 Cobb angle is defined as Cobb angle measurement between the inferior end plate of the C2 and C7; (b) C2-7 SVA is defined as the distance between the C2 plumb line and C7 supero-posterior corner; (c) T1 tilt is defined as the angle between the upper margin of T1 and horizontal line; Cla-A is defined as angle between the line connecting the highest points of the

clavicles and the horizontal line; and CHD is defined as height difference between the horizontal lines through the upper margin of each coracoid process.



**Figure 3**

A 15-year-old girl with Risser 3 performed Schroth exercises. (a) Pre-treatment Cobb angle was  $34.1^\circ$  on X-ray; (b) After one-year Schroth exercise, Cobb angle decreased to  $28.5^\circ$  on X-ray; (c) After 28-month Schroth exercise, Cobb angle was  $28.3^\circ$ .

## Supplementary Files

This is a list of supplementary files associated with this preprint. Click to download.

- [Titlepage.docx](#)
- [Reference.docx](#)