

Should a hysterosalpingogram be a first-line investigation to diagnose female tubal subfertility in the modern subfertility workup?

Chou Phay Lim¹, Zaid Hasafa¹, S. Bhattacharya², and A. Maheshwari^{3,*}

¹Obstetrics and Gynaecology, Aberdeen Maternity Hospital, NHS Grampian, Aberdeen AB25 2ZL, UK ²Division of Applied Health Sciences, School of Medicine, University of Aberdeen, Aberdeen AB25 2ZD, UK ³Reproductive Medicine, Division of Applied Health Sciences, University of Aberdeen, Aberdeen Maternity Hospital, Aberdeen AB25 2ZL, UK

*Correspondence address. Reproductive Medicine, Division of Applied Health Sciences, University of Aberdeen, Aberdeen Maternity Hospital, Aberdeen AB25 2ZL, UK. E-mail: abha.maheshwari@abdn.ac.uk

Submitted on November 27, 2010; resubmitted on January 19, 2011; accepted on February 1, 2011

ABSTRACT: Tubal assessment is an integral part of female fertility evaluation. While diagnostic laparoscopy is gold standard, it is not suitable to be used as a screening test. Hysterosalpingogram (HSG) has been advocated as first-line investigation historically. With advances in diagnostics, more tests are available, such as hysterosalpingo contrast sonography (HyCoSy) and Chlamydia antibody titre (CAT) are available. The CAT test is much cheaper, less invasive and can be performed at any time during the cycle. The CAT test can also be used as a means of identifying which patients need further evaluation. HyCoSy has same diagnostic accuracy as HSG, without exposing women to radiation. We argue that HSG is out of date and has no place in a modern infertility evaluation. We also suggest a pathway (based on history, clinical and ultrasound evaluation) for investigations to screen for and diagnose tubal pathology.

Key words: tubal patency test / hysterosalpingogram / hysterosalpingo contrast sonography / Chlamydia antibody titre / infertility

Background

Fallopian tube abnormalities account for up to 40% of female subfertility (Snick *et al.*, 1997; Steinkeler *et al.*, 2009). Assessment of tubal patency is one of the first steps in fertility investigations. Hysterosalpingography (HSG) is the most common first-line diagnostic test used for this purpose (Crosignani and Rubin, 2000; National Collaborating Centre for Women's and Children's Health, 2004; Lanzani *et al.*, 2009). In addition to assessing tubal patency, HSG also provides an image of the outline of the uterine cavity. It has also been suggested that HSG has a therapeutic role in enhancing subfertility (Mackey *et al.*, 1971; DeCherney *et al.*, 1980; Schwabe *et al.*, 1983; Rasmussen *et al.*, 1987; Yaegashi *et al.*, 1987). As a relatively inexpensive outpatient procedure, HSG fulfils many attributes of a first-line test for tubal patency (Siegler, 1983; Nielsen *et al.*, 1987; National Collaborating Centre for Women's and Children's Health, 2004). Nevertheless HSG has certain limitations, which have prompted us to query its present role when newer modalities, such as the Chlamydia antibody titre (CAT) test and hysterosalpingo contrast sonography (HyCoSy), are readily available.

Diagnostic accuracy

Laparoscopy is commonly viewed as the gold standard in diagnosing tubal patency. It also provides an opportunity to diagnose and treat endometriosis and peritubal adhesions. However, it is an invasive and expensive procedure requiring general anaesthesia with a 0.13% risk of surgical complications (Chapron *et al.*, 1998). Furthermore, facilities for surgery may not be readily available in every clinic. Hence, laparoscopy is unsuitable for routine use in subfertile women on a large-scale. Obtaining a reliable estimate of the risk of tubal pathology by another method, prior to proceeding with laparoscopy, would allow only high-risk patients to be selected for this procedure. Hence, HSG and CAT have been suggested for the initial investigation.

HSG has been reported to have a sensitivity and specificity of 53 and 87%, respectively, for any tubal pathology and 46 and 95%, respectively, for bilateral tubal pathology when compared with laparoscopy (Broeze *et al.*, 2010). The discriminatory capacity of CAT is comparable with that of HSG in the diagnosis of tubal occlusion (Mol *et al.*, 1997), while HyCoSy is as accurate as HSG in terms of

establishing tubal patency (Campbell et al., 1994; Heikkinen et al., 1995) (Table I) when compared with laparoscopy. HyCoSy has the additional advantage of allowing an ultrasound assessment of the pelvis at the same time and is superior in detection of intrauterine abnormalities (Alatas et al., 1997), such as endometrial polyps, submucosal fibroids, synechiae as well as hydrosalpinges and abnormal ovaries (Steinkeler et al., 2009).

Hence, laparoscopy remains the gold standard for those who wish to have a definitive diagnosis. However, all three (CAT, HSG and HyCoSy) tests are proved to have similar accuracy in terms of identifying women who should have laparoscopy.

Radiation exposure

Women undergoing HSG are exposed to pelvic radiation. The mean dose-area product (DAP) for a complete HSG examination is 2.05 Gy cm². In comparison, the mean DAP for a single posterior–anterior chest X-ray examination is 0.09 Gy cm² (Hart et al., 2009). In contrast, there is no exposure to radiation associated with HyCoSy and CAT.

Use of contrast media

HSG is performed by the passage of a radio-opaque dye from the cervical canal into the uterine cavity under fluoroscopic guidance (Bendick, 1947). HSG can be performed using water or oil-soluble contrast medium (OSCM). Although there are reports that the use of OSCM in HSG increases the chance of spontaneous pregnancy (Luttjeboer et al., 2007), they are associated, rarely, with oil embolism and granulomatous inflammation in the presence of obstructed or inflamed Fallopian tubes. Water-soluble contrast medium, which produces superior radiographic images, is currently seen as the preferred medium (Mackey et al., 1971; Soules and Spadoni, 1982; Schwabe et al., 1983). However, water-soluble contrast materials have been linked with an increased frequency and duration of bleeding after HSG (Lindequist et al., 1991) and higher post-HSG miscarriage rates (Rasmussen et al., 1991; Spring et al., 2000). It has been suggested that we should use water-soluble contrast media to demonstrate tubal patency followed by OSCM for its therapeutic advantage; however, this will increase the cost, time and discomfort associated with the procedure (DeCherney et al., 1980). Nevertheless, all types of media contain iodine, and hence are not suitable for use in women who are sensitive to iodine. HyCoSy does not require the use of iodine or involve exposure to radiation. HyCoSy has traditionally been performed using ultrasound contrast media; however, saline and air have been suggested as alternatives (Spalding et al., 1997; Boudghene et al., 2001).

Organization of procedures

HyCoSy can be carried out as an office procedure by specialists in reproductive medicine without the input from radiology services (as for HSG) (Schlief and Deichert., 1991; Deichert et al., 1992; Campbell et al., 1994), while CAT is a blood test that can be arranged from primary care. Both HyCoSy and HSG can only be performed at a certain time in the menstrual cycle. Alternatively, patients are advised to use contraception, which means that they loose at least

Table I Comparisons of three methods of screening for tubal disease in women.

Assesses	Fallopian tubes	Uterine cavity	Peritubular adhesions	Adnexae	Pain	Outpatient procedure	Operator skills	Need to avoid intercourse	Cost per patient (range)	Sensitivity	Specificity
Hysterosalpingogram	Yes	Yes	No	No	++	Yes	Yes	Yes	£108 (£76–£130)	0.53 ^b	0.87 ^b
Hysterosalpingo-contrast Sonography	Yes	Yes	No	Yes	+	Yes	Yes	Yes	£53 (£39–£60) + ^a £100 (Echovist)	0.80 ^c	0.84 ^c
Chlamydia antibody titre	No	No	No	No	0	Yes	No	No	£7 (£5–£9)	0.21–0.90 ^d	0.29–1 ^d

Costs are taken from UK Department of Health websites 2008, based on the cost of various procedures in 2008–2009 (http://www.dh.gov.uk/prod_consum_dh/groups/dh_digitalassets/@dh/@en/@ps/documents/digitalasset/dh_118322.xls). HSG—based on cost of a procedure using contrast fluoroscopy (RA 16Z) for < 20 min. HyCoSy—based on cost of ultrasound procedure < 20 min (RA23Z). CAT—from average cost of microbiology/virology service (DAP 831). Sensitivity and specificity are according to laparoscopy as the gold standard.

^aDoes not need to be added if saline/air is used.

^bBased on individual patient meta-analysis (Broeze et al., 2010).

^cTanawattanacharoen et al. (2000).

^dBased on meta-analysis (Mol et al., 1997).

1 month in terms of trying for pregnancy. However, CAT determination from a blood test can be performed at any time during the cycle, without the need to avoid pregnancy.

Cost

CAT, being a blood test, is much less expensive than HyCoSy or HSG (Table I). The costs of HSG and HyCoSy are similar. The cost of HyCoSy can be further reduced by using air/saline as a medium rather than sonographic contrast media (Spalding *et al.*, 1997), although some authors believe that the physician learning curve for air/saline is longer when compared with the ultrasound contrast.

There are no studies in the literature to determine whether initial investigation with CAT followed by further investigations is a cost-effective approach when compared with using HSG or HyCoSy in all women followed by laparoscopy.

Patient comfort

Although there are no differences in patient preference for both the procedures, HyCoSy is associated with less pain (Skinner *et al.*, 2000; Ahinko-Hakamaa *et al.*, 2007) and is better tolerated when compared with HSG (Ayida *et al.*, 1996).

Discussion

Tubal damage can have various causes, including pelvic infection (most commonly *Chlamydia trachomatis*), endometriosis and fibroids. A detailed history, examination and pelvic ultrasound should raise suspicion of the presence of fibroids and or significant endometriosis. Further pelvic evaluation in these cases is needed by laparoscopy +/- hysteroscopy. Most asymptomatic tubal pathology is mainly attributed to the history of pelvic inflammatory disease (PID),

(Trimbos-Kemper *et al.*, 1982), the main agent being *C. trachomatis* (Anonymous, 1979, 1982). There is a strong association between CATs and tubal subfertility (Punnonen *et al.*, 1979; Simmons *et al.*, 1979; Treharne *et al.*, 1979; Malik *et al.*, 2009). As significant cross reactivity with *Chlamydia pneumoniae* is encountered, CAT does not provide 100% sensitivity and specificity (Land *et al.*, 2003). However, evidence of past Chlamydia infection using serology is readily available and the test is simple and quick to perform. Micro-immunofluorescence (MIF) is widely used for CAT testing and recently a species-specific MIF and ELISA test have been introduced.

While CAT does not provide any detail on the anatomy of the uterus and tubes, it should be able to identify women who need further tubal or pelvic evaluation. So while a negative CAT can be reassuring, a positive test would warrant more invasive diagnostic procedures, such as laparoscopy, to assess the severity of the disease even if there is no history of chlamydial PID. CAT testing adds valuable information to a woman's risk profile based on her medical history. The combination of medical history and CAT testing has a better yield for diagnosing tubal disease than either of these alone (Coppus *et al.*, 2007). The decision for laparoscopy should take the woman's age and duration of subfertility into consideration. Above a certain age, laparoscopy would be neither meaningful to the patient nor cost-effective as her naturally reduced fertility means she would not have the time to await spontaneous conception. In those circumstances, it might be preferable to proceed to IVF directly.

The Dutch Society for Obstetrics and Gynaecology (NVOG) recommends the use of CAT as a first-line test in the basic work-up of subfertile couples, with a fixed cut-off level (immunoglobulin G MIF 1:32 or ELISA 1.1) above which post-infectious pelvic disease should be ruled out with laparoscopy and chromotubation (Swart *et al.*, 1995; Coppus *et al.*, 2007).

In CAT-positive patients, HSG should be omitted to avoid the 10% risk of post-HSG complications (den Hartog *et al.*, 2008). Although

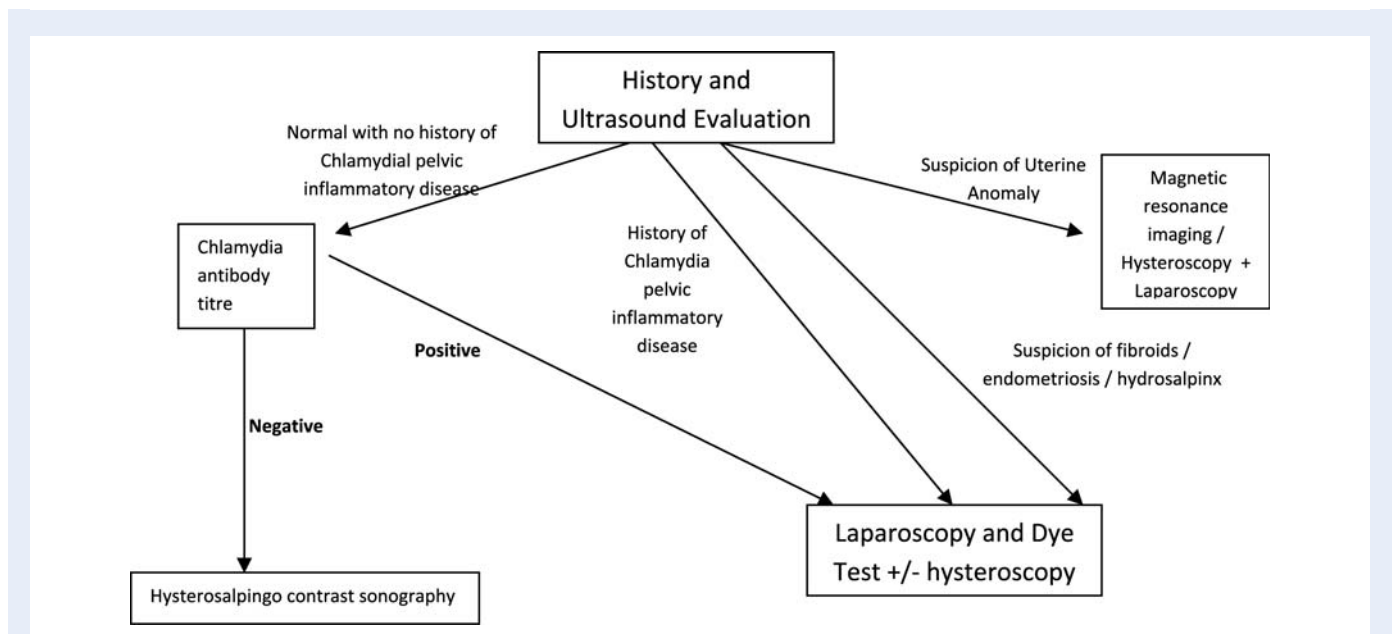


Figure 1 Recommended flow chart for investigations for determining tubal pathology in women.

there are no data in the literature to suggest that there are complications following HyCoSy in CAT-positive women, one would assume that the same principles, as for HSG, should apply. Of the 669 subfertile women undergoing HyCoSy, 2.0% required post-procedural drug treatment for pain relief, mild vasovagal reactions were experienced in 4.1%, 0.8% had a severe vasovagal reaction but no late complications were reported (Savelli et al., 2009). Dessole et al. (2003) have described a series of HyCoSy in, among others, subfertile women: of the 313 subfertile women undergoing HyCoSy, the risk of complications was 4% (fever, PID); two women even required surgery for infectious complications. Although the Chlamydia antibody status was not mentioned, it is plausible that the women harboured Chlamydia and had a (relative) contra-indication for HyCoSy.

In CAT-negative patients, HyCoSy should be recommended. Proponents of HSG would argue that HSG can be performed in a low-resource setting and does not need the availability of ultrasound. However, one still needs X-ray and fluoroscopic equipment as a minimum. Moreover, most subfertility clinics in the developed world have access to ultrasound as part of the basic workup. The need for liaison with another department and exposure to pelvic radiation can be avoided if HyCoSy is advocated instead of HSG.

Conclusion

CAT is comparatively inexpensive, less invasive and can be performed at any time during the menstrual cycle and can identify patients who need further evaluation. Laparoscopy remains the gold standard in diagnosing tubal pathology. We question whether HSG should still be performed as part of modern fertility investigations.

We also suggest a flow chart of investigations for determining tubal pathology in women with subfertility as a compromise between invasiveness and diagnostic accuracy (Fig. 1), rather than a blanket policy of using HSG. For CAT-positive patients, laparoscopy may be warranted, whereas CAT-negative patients should have a HyCoSy that carries a similar cost and has at least the same accuracy as HSG while avoiding radiation. We feel that HSG is out of date and has no place in modern evidence-based fertility investigations.

Authors' roles

C.P.L. and Z.H. did the systematic searches of the literature and wrote the initial draft. A.M. conceptualized the idea for the manuscript and corrected the drafts. S.B. provided the intellectual input in write up of manuscript.

References

- Ahinko-Hakamaa K, Huhtala H, Tinkanen H. The validity of air and saline hysterosalpingo-contrast sonography in tubal patency investigation before insemination treatment. *Eur J Obstet Gynecol Reprod Biol* 2007; **132**:83–87.
- Alatas C, Aksoy E, Akarsu C, Yakin K, Aksoy S, Hayran M. Evaluation of intrauterine abnormalities in infertile patients by sonohysterography. *Hum Reprod* 1997; **12**:487–490.
- Anonymous. Pathogenesis of pelvic inflammatory disease. *Br Med J* 1979; **1**:1588–1589.
- Anonymous. The bacteriology of acute pelvic inflammatory disease. *Lancet* 1982; **1**:431–432.
- Ayida G, Kennedy S, Barlow D, Chamberlain P. A comparison of patient tolerance of hysterosalpingo-contrast sonography (HyCoSy) with Echovist-200 and x-ray hysterosalpingography for outpatient investigation of infertile women. *Ultrasound Obstet Gynecol* 1996; **7**:201–204.
- Bendick AJ. Present status of hysterosalpingography. *J Mt Sinai Hosp N Y* 1947; **14**:739–742.
- Boudghene FP, Bazot M, Robert Y, Perrot N, Rocourt N, Antoine JM, Morris H, Leroy JL, Uzan S, Bigot JM. Assessment of Fallopian tube patency by HyCoSy: comparison of a positive contrast agent with saline solution. *Ultrasound Obstet Gynecol* 2001; **18**:525–530.
- Broeze KA, Opmeer BC, Van Geloven N, Coppus SFPJ, Collins JA, Den Hartog JE, Van der Linden PJQ, Marianowski P, Ng EHY, Van der Steeg JW et al. Are patient characteristics associated with the accuracy of hysterosalpingography in diagnosing tubal pathology? An individual patient data meta-analysis. *Hum Reprod* 2010; Update first published online December 8, 2010 doi:10.1093/humupd/dmq056.
- Campbell S, Bourne TH, Tan SL, Collins WP. Hysterosalpingo contrast sonography (HyCoSy) and its future role within the investigation of infertility in Europe. *Ultrasound Obstet Gynecol* 1994; **4**:245–253.
- Chapron C, Querleu D, Bruhat MA, Madelenat P, Fernandez H, Pierre F, Dubuisson JB. Surgical complications of diagnostic and operative gynaecological laparoscopy: a series of 29,966 cases. *Hum Reprod* 1998; **13**:867–872.
- Coppus SFPJ, Opmeer BC, Logan S, van der Veen F, Bhattacharya S, Mol BWJ. The predictive value of medical history taking and Chlamydia IgG ELISA antibody testing (CAT) in the selection of subfertile women for diagnostic laparoscopy: a clinical prediction model approach. *Hum Reprod* 2007; **22**:1353–1358.
- Crosignani PG, Rubin BL. Optimal use of infertility diagnostic tests and treatments. The ESHRE Capri Workshop Group. *Hum Reprod* 2000; **15**:723–732.
- DeCherney AH, Kort H, Barney JB, DeVore GR. Increased pregnancy rate with oil-soluble hysterosalpingography dye. *Fertil Steril* 1980; **33**:407–410.
- Deichert U, Schlieff R, van de Sandt M, Daume E. Transvaginal hysterosalpingo-contrast sonography for the assessment of tubal patency with gray scale imaging and additional use of pulsed wave Doppler. *Fertil Steril* 1992; **57**:62–67.
- den Hartog JE, Lardenoije CM, Severens JL, Land JA, Evers JL, Kessels AG. Screening strategies for tubal factor subfertility. *Hum Reprod* 2008; **23**:1840–1848.
- Dessole S, Farina M, Rubattu G, Cosmi E, Ambrosini G, Nardelli GB. Side effects and complications of Sonohysterosalpingography. *Fertil Steril* 2003; **80**:620–624.
- Hart D, Hillier MC, Wall BF. HPA-RPD-029—doses to patients from radiographic and fluoroscopic X-ray imaging procedures in the UK—2005. *Review* 2009; **2010**:95.
- Heikkinen H, Tekay A, Volpi E, Martikainen H, Jouppila P. Transvaginal salpingosonography for the assessment of tubal patency in infertile women: methodological and clinical experiences. *Fertil Steril* 1995; **64**:293–298.
- Land JA, Gijzen AP, Kessels AGH, Slobbe MEP, Bruggeman CA. Performance of positive serological Chlamydia antibody tests in subfertile women. *Hum Reprod* 2003; **18**:2621–2627.
- Lanzani C, Savasi V, Leone FP, Ratti M, Ferrazzi E. Two-dimensional HyCoSy with contrast tuned imaging technology and a second-generation contrast media for the assessment of tubal patency in an infertility program. *Fertil Steril* 2009; **92**:1158–1161.
- Lindequist S, Justesen P, Larsen C, Rasmussen F. Diagnostic quality and complications of hysterosalpingography: oil- versus water-soluble

- contrast media—a randomized prospective study. *Radiology* 1991; **179**:69–74.
- Luttjeboer F, Harada T, Hughes E, Johnson N, Lilford R, Mol BW. Tubal flushing for subfertility. *Cochrane Database Syst Rev* 2007; **3**:CD003718.
- Mackey RA, Glass RH, Olson LE, Vaidya R. Pregnancy following hysterosalpingography with oil and water soluble dye. *Fertil Steril* 1971; **22**:504–507.
- Malik A, Jain S, Rizvi M, Shukla I, Hakim S. *Chlamydia trachomatis* infection in women with secondary infertility. *Fertil Steril* 2009; **91**: 91–95.
- Mol BW, Dijkman B, Wertheim P, Lijmer J, van der Veen F, Bossuyt PM. The accuracy of serum Chlamydial antibodies in the diagnosis of tubal pathology: a meta-analysis. *Fertil Steril* 1997; **67**:1031–1037.
- National Collaborating Centre for Women's and Children's Health. *Fertility: Assessment and Treatment for People with Fertility Problems*, 2009. London: RCOG press, 2004, p. 236.
- Nielsen DT, Rasmussen F, Justesen P. A comparative study of hysterosalpingography and endoscopy/laparotomy in infertile patients. *Eur J Radiol* 1987; **7**:260–262.
- Punnonen R, Terho P, Nikkanen V, Meurman O. Chlamydial serology in infertile women by immunofluorescence. *Fertil Steril* 1979; **31**:656–659.
- Rasmussen F, Justesen P, Tonner Nielsen D. Therapeutic value of hysterosalpingography with lipiodol ultra fluid. *Acta Radiol* 1987; **28**:319–322.
- Rasmussen F, Lindequist S, Larsen C, Justesen P. Therapeutic effect of hysterosalpingography: oil- versus water-soluble contrast media—a randomized prospective study. *Radiology* 1991; **179**:75–78.
- Savelli L, Pollastri P, Guerrini M, Villa G, Manuzzi L, Mabrouk M, Rossi S, Seracchioli R. Tolerability, side effects, and complications of hysterosalpingocontrast sonography (HyCoSy). *Fertil Steril* 2009; **92**: 1481–1486.
- Schlief R, Deichert U. Hysterosalpingo-contrast sonography of the uterus and fallopian tubes: results of a clinical trial of a new contrast medium in 120 patients. *Radiology* 1991; **178**:213–215.
- Schwabe MG, Shapiro SS, Haning RV Jr Hysterosalpingography with oil contrast medium enhances fertility in patients with infertility of unknown etiology. *Fertil Steril* 1983; **40**:604–606.
- Siegler A. Hysterosalpingography. *Fertil Steril* 1983; **40**:139–158.
- Simmons PD, Forsey T, Thin RN, Treharne JD, Darougar S, Langlet F, Pandhi RK. Antichlamydial antibodies in pelvic inflammatory disease. *Br J Vener Dis* 1979; **55**:419–421.
- Skinner J, Leavy J, Stuart BJ, Turner MJ. Hysterosalpingocontrastsonography in clinical practice. *J Obstet Gynaecol* 2000; **20**:171–174.
- Snick HK, Snick TS, Evers JL, Collins JA. The spontaneous pregnancy prognosis in untreated subfertile couples: the Walcheren primary care study. *Hum Reprod* 1997; **12**:1582–1588.
- Soules MR, Spadoni LR. Oil versus aqueous media for hysterosalpingography: a continuing debate based on many opinions and few facts. *Fertil Steril* 1982; **38**:1–11.
- Spalding H, Martikainen H, Tekay A, Jouppila P. A randomized study comparing air to Echovist as a contrast medium in the assessment of tubal patency in infertile women using transvaginal salpingosonography. *Hum Reprod* 1997; **12**:2461–2464.
- Spring DB, Barkan HE, Pruyn SC. Potential therapeutic effects of contrast materials in hysterosalpingography: a prospective randomized clinical trial. Kaiser Permanente Infertility Work Group. *Radiology* 2000; **214**:53–57.
- Steinkeler JA, Woodfield CA, Lazarus E, Hillstrom MM. Female infertility: a systematic approach to radiologic imaging and diagnosis. *Radiographics* 2009; **29**:1353–1370.
- Swart P, Mol BW, van der Veen F, van Beurden M, Redekop WK, Bossuyt PM. The accuracy of hysterosalpingography in the diagnosis of tubal pathology: a meta-analysis. *Fertil Steril* 1995; **64**:486–491.
- Tanawattanacharoen S, Suwajanakorn S, Uerpaiojkit B, Boonkasemsanti W, Virutamasen P. Transvaginal hysterosalpingo-contrast sonography (HyCoSy) compared with chromolaparoscopy. *J Obstet Gynaecol Res* 2000; **26**:71–75.
- Treharne JD, Ripa KT, Mardh PA, Svensson L, Westrom L, Darougar S. Antibodies to *Chlamydia trachomatis* in acute salpingitis. *Br J Vener Dis* 1979; **55**:26–29.
- Trimbos-Kemper T, Trimbos B, van Hall E. Etiological factors in tubal infertility. *Fertil Steril* 1982; **37**:384–388.
- Yaegashi N, Kuramoto M, Nakayama C, Nakano M, Hoshiai H. Pregnancy rates after hysterosalpingography—comparing water soluble contrast medium with oily contrast medium. *Nippon Sanka Fujinka Gakkai Zasshi* 1987; **39**:1812–1814.