

Sialendoscopy for the Management of Obstructive Salivary Gland Disease

A Systematic Review and Meta-analysis

Julie E. Strychowsky, MD; Doron D. Sommer, MD, FRCSC; Michael K. Gupta, MD, FRCSC; Natasha Cohen, MD; Oded Nahlieli, DMD

Objective: To conduct a systematic review with meta-analysis to determine the efficacy and safety of sialendoscopy in the treatment of obstructive diseases of the salivary glands in adults.

Data Sources: MEDLINE, EMBASE, and the Cochrane Library (no lower limit to October 2010). Reference lists were searched for identification of relevant studies.

Study Selection: Prospective or retrospective studies of adult patients treated with interventional sialendoscopy for the management of salivary gland obstruction were selected. Outcome measures included rates of success (symptom-free and absence of residual obstruction), sialadenectomy, and complications. Non-English publications were excluded.

Data Extraction: Two independent review authors screened eligible studies, extracted relevant data, and resolved discrepancies by consensus when applicable.

Weighted pooled proportion, 95% confidence intervals, and test results for heterogeneity are reported.

Data Synthesis: Twenty-nine studies were included in the analysis. The weighted pooled proportion of success rates were 0.86 (95% CI, 0.83-0.89) for studies involving 1213 patients undergoing sialendoscopy alone and 0.93 (95% CI, 0.89-0.96) for the 374 patients undergoing sialendoscopy with a combined surgical approach. Outcomes following interventional sialendoscopy for radioiodine-induced sialadenitis were reported in 3 studies, and success rates were variable. Rates of sialadenectomy were low, and few major complications were reported.

Conclusion: Findings from the present systematic review and meta-analysis suggest that sialendoscopy is efficacious, safe, and gland preserving for the treatment of obstructive major salivary gland disease.

Arch Otolaryngol Head Neck Surg. 2012;138(6):541-547

OBSTRUCTIVE SIALADENITIS represents approximately one-half of benign salivary gland disease.¹ Submandibular gland obstruction accounts for 80% to 90% of cases followed by obstruction of the parotid (5%-10%) and sublingual (<1%) glands.² The common causes comprise sialolithiasis, stenosis, mucus plugs, polyps, foreign bodies, external compression, or variations in anatomical ductal systems. Patients often present with recurrent and painful glandular swelling, which can be complicated by purulent discharge, bacterial superinfection,³ cellulitis, or abscess. Traditional management involves a conservative approach; however, refractory cases may require surgery ranging from pilolotomy to complete gland extirpation.³

Surgical complications following sialadenectomy result in varying amounts of morbidity. These are well reported in the lit-

erature. Capaccio and colleagues⁴ reviewed complications following parotidectomy and described the incidence of permanent facial nerve injury (1%-3%), sensory loss in the distribution of the greater auricular nerve (2%-100%), and Frey syndrome (8%-33%). For submandibular gland resection, the incidence of permanent marginal mandibular nerve injury (1%-8%), hypoglossal nerve injury (3%), and lingual nerve injury (2%) are documented. Other potential complications include aesthetic sequelae, salivary fistulas, sialoceles, hematomas, and wound infection.⁴

Sialendoscopy offers a minimally invasive approach to disease management. This technique allows endoscopic intraluminal visualization and offers a mechanism to treat diseases of the ductal system, ultimately reducing or eliminating the need for sialadenectomy and obviating related surgical risks.

Author Affiliations: Division of Otolaryngology–Head and Neck Surgery, Department of Surgery, McMaster University, Hamilton, Ontario, Canada (Drs Strychowsky, Sommer, Gupta, and Cohen); and Department of Oral and Maxillofacial Surgery, Barzilai Medical Center, Ashkelon, Israel (Dr Nahlieli).

Katz⁵ pioneered the first flexible sialendoscope in 1993, and Nahlieli et al,⁶ the rigid sialendoscope in 1994. Endoscopes with working channels allow for concomitant use of instrumentation to assist in sialolith removal or stricture dilation. In some centers, lithotripsy or laser devices may be used to facilitate stone fragmentation prior to removal. For stones not amenable to endoluminal removal, a combined approach using a limited incision in combination with sialendoscopy to localize and stabilize the stone can portend minimal surgical morbidity.

There is a paucity of published data evaluating the efficacy and safety of interventional sialendoscopy. The purpose of this systematic review with meta-analysis was to summarize the current literature and determine the efficacy and safety of sialendoscopy in the treatment of obstructive diseases of the salivary glands in adults.

METHODS

This review was performed in accordance with the Preferred Reporting Items for Systematic Reviews and Meta-Analyses (PRISMA)⁷ guideline that prescribed search strategy, study selection criteria, outcomes, and statistical analysis.

LITERATURE SEARCH STRATEGY

The literature was searched using OVID MEDLINE (1966 to October 2010), EMBASE (1980 to October 2010), and the Cochrane Library (Cochrane Database of Systematic Reviews, 2010, Issue 1) by 2 independent review authors (J.E.S. and N.C.). The literature search of electronic databases combined intervention-specific terms (*sialendoscopy*, *sialoendoscopy*, *sialoscopy*, *endoscopy*) with disease-specific terms (*salivary gland*, *sialolithiasis*, *submandibular*, *parotid*, *calculus*, *stone*, *sialadenitis*) for the following study designs and publication types: meta-analyses, systematic reviews, randomized controlled trials, and retrospective studies. To ensure that all relevant published articles were captured, the literature search was not limited for study design or publication date. Relevant articles and abstracts were selected and reviewed, and the reference lists from these sources and recent review articles were searched for additional publications.

STUDY SELECTION CRITERIA

Articles were included in this review of the evidence if they were fully published peer-reviewed reports that reported success rates, defined as symptom-free and absence of residual obstruction, for interventional sialendoscopy for the management of obstructive disease of major salivary glands in adult patients with or without a combined surgical approach. Non-English publications were excluded.

DATA EXTRACTION

Relevant data were extracted from fully published reports by 2 independent review authors (J.E.S. and N.C.) following prescribed tables. Relevant outcomes included stone location, size, use of supportive devices, success rates, incidence of sialadenectomy, and other complications. Success rate was defined as symptom-free and absence of residual obstruction. Disagreement was resolved by consensus. When data in published reports were incomplete, authors were contacted by electronic mail to provide additional information.

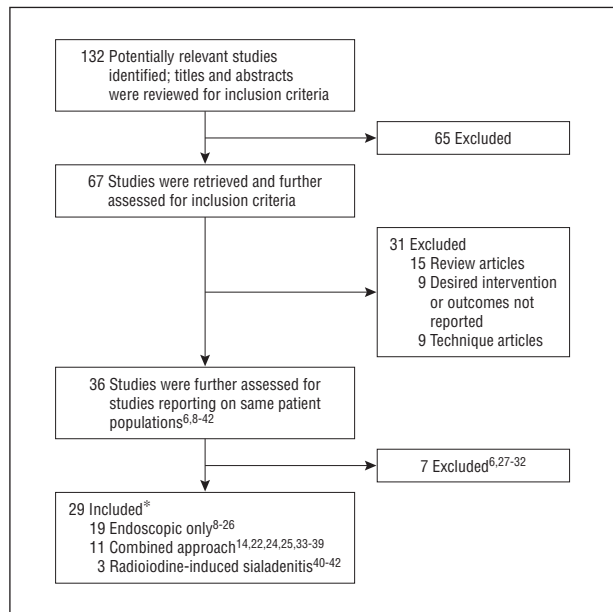


Figure 1. Identification of relevant studies. *Four publications included patients who satisfied 2 analysis groups.

STATISTICAL ANALYSIS

Meta-analysis was performed by calculating pooled proportion of the weighted mean for success rates using DerSimonian-Laird weights for the random-effects model. Heterogeneity between studies was tested using the Q statistic, with the χ^2 approach. StatsDirect software 2.7.8 (StatsDirect Limited) was used for the statistical analysis.

RESULTS

Thirty-six studies that satisfied the inclusion criteria were identified (Figure 1). The most complete data set^{23,24} was included when authors had multiple publications on the same set of patients.^{6,23,24,27-32} Therefore, results from 29 distinct studies were included in the final analysis.^{8-26,33-42} Studies were arranged in 3 groups: sialendoscopy alone (19 studies),⁸⁻²⁶ sialendoscopy with a combined surgical approach (11 studies),^{14,22,24,25,33-39} and sialendoscopy for radioiodine-induced sialadenitis (3 studies).⁴⁰⁻⁴² Four publications included patients who satisfied 2 analysis groups^{14,22,24,25}; the relevant data were abstracted and analyzed with the appropriate group.

SIALENDOSCOPY ALONE

This group comprised 19 studies involving 1213 patients for analysis.⁸⁻²⁶ There were 2 studies by Nahlieli and colleagues^{23,24} published in 2009 and 2010, and 3 groups were used in the analysis (Nahlieli 1, 2, and 3). The use of supportive devices was variable between studies and included balloon dilation, grasping instruments (basket or forceps), or fragmentation (laser or lithotripsy) when reported. **Table 1** provides detailed descriptions of patient population, site (ie, submandibular, parotid), cause of obstruction (ie, sialolithiasis, stenosis, polyps), the use of supportive devices, and success and complications rates for these studies. The

Table 1. Success Rates After Sialendoscopy Alone (Without a Combined Surgical Approach)

Source, Country (Type of Scope)	No. of Pts	No. and Site of Sialendoscopies	Type of Obstruction (No. and Site)	Size, mm	Supportive Devices	Success Rate ^a	Residual Obstruction Rate ^a	No. of Sialadenotomies	Complications
Königsberger et al, ⁸ 1993 Germany (flexible)	29	29 SM	Sialoliths (29)	NR	Electrohydraulic intracorporeal shockwave lithotripsy	20/29	9/29	NR	None
Arzoz et al, ⁹ 1996 Spain (rigid)	39	23 SM; 4 P	Sialoliths (16 SM, 2 P); other (7 SM, 2 P)	NR	Laser energy (3 Pts); pneumobalistic energy (9 Pts); forceps alone (6 Pts)	24/27	3/18 SM	2/18 SM	Symptoms of mild sialadenitis
Marchal et al, ¹⁰ 2001 France (flexible, semirigid)	55	55 P	Sialoliths (50); stenoses (6); polyps (2)	NR	Fragmentation	47/55	8/55	1	7 Pts (12%)
Marchal et al, ¹¹ 2002 France (flexible, semirigid)	110	110 SM	Sialoliths (106); stenoses (4)	mean (SD), 4.9 (2.9)	Fragmentation	90/110	20/110	5	Ductal wall perforation (11 Pts); wire basket blockages (2 Pts)
Chu et al, ¹² 2003 Hong Kong (rigid)	13	13 SM	Sialoliths (11); nonsialoliths (2)	3-11	Laser + forceps (3 Pts); laser + basket (2 Pts); forceps + basket (2 Pts); basket only (1 Pt); forceps only (3 Pts)	11/11	1/11	1	Persistent swelling (2 Pts); stricture (1 in first patient, then stent placed in remaining cases)
Zenk et al, ¹³ 2004 Germany (semirigid)	22	13 SM; 9 P	Sialoliths (13 SM); stenosis (3 P); sialodochitis (3 P); FB (1 P)	NR	Grasping instruments	12/12	NR	NR	False passage at Stensen duct (1 Pt)
Ziegler et al, ¹⁴ 2004 Germany (NR)	72	23 P; 45 SM	Sialoliths (54); intraluminal adhesions (11 [7 SM, 4 P]); sphincter-like obstruction (2 SM, 2 P)	>4 (11 Pts); ≤10 (6 Pts)	Grasping instruments	47/54	11/54 Sialoliths; 1/15 other	6/72 SM only	None
Koch et al, ¹⁵ 2005 Germany (semirigid)	36	28 P; 13 SM	Sialoliths (36)	NR	Basket or grasping instruments (6 P, 5 SM); ESWL (6 P)	31/36	NR	2 (1 P, 1 SM)	Perforation of Warthin duct with introduction of the endoscope in 1 Pt with stenosis
Raif et al, ¹⁶ 2006 Israel (rigid, semirigid)	17	16 SM; 2 P	Sialoliths (21)	1-15	Er:YAG laser ± grasping instruments	18/18	0	0	Nonfunctional but asymptomatic glands (2 Pts)
Koch et al, ¹⁷ 2008 Germany (semirigid)	39	29/P	Strictures (29 P)	NA	Dilation and irrigation; intraductal injections of prednisolone weekly for 6-10 wk	22/29	NA	1	None
Papadaki et al, ¹⁸ 2008 USA (semirigid)	94	17 P; 77 SM	Sialoliths (73); other (18)	NR	Basket or grasping instruments (34 Pts); lithotripsy (18 Pts); laser (62 Pts)	81/91	11/73, average size, 14 mm	5	Temporary lingual nerve paresthesia (2 Pts); excess extravasation of irrigation fluid, intubation overnight (1 Pt); Post-op TMJ arthralgia (1 Pt)
Walvekar et al, ¹⁹ 2008 USA (semirigid)	56	26 SM; 27 P; 3 both	Sialoliths (11 P, 18 SM); swelling (9); sialadenitis (8); radioactive iodine (6)	2-12	NR	14/19	NR	2 P	25% (2% major, 23% minor)
Yu et al, ²⁰ 2008 China (semirigid)	23	21 P	Sialoliths (4); polyps (5); stenosis (3); mucus plug (9)	NR	Grasping instruments; electrohydraulic Calculript (Karl Storz GmbH & Co) (1 Pt); balloon dilation	17/21	1/29	NR	Swelling requiring steroid and antibiotics (5 Pts)
Yu et al, ²¹ 2008 China (semirigid)	68	37 SM	Sialoliths (27); nonsialoliths (10)	2-18	Grasping instruments	31/37	5/37	NR	Sublingual cyst (1 Pt); swelling requiring steroid and antibiotics (5 Pts)
Liu et al, ²² 2009 China (semirigid)	90	78 SM; 12 P	Sialoliths (90)	NR	Basket retrieval (9 P)	87/90	NR	1	Post-op infection (1 Pt); ranula (1 Pt)
Nahlieli ¹ , ²³ 2009 Israel (semirigid)	1589	722 SM; 347 P; 9 SL	Sialolithiasis (736); sialadenitis (140)	NR	Fragmentation/grasping instruments	189/217	NR	2/151 SM; 1/65 P	Immediate failure (0.8% SM, 0.3% P); intraoperative failure (1.4% SM, 3% P); late failures (2.6% SM, 2.1% P); temporary lingual nerve paresthesia (0.4%); Post-op infection (1.6%); postoperative bleeding (0.5%); traumatic ranula (0.7%); ductal strictures (2.5%)
Nahlieli ² , ²³ 2009 Israel (semirigid)	1589	208	Strictures (136 P, 68 SM)	NR	NA	168/208	NR	NR	Same as the study by Nahlieli ^{1,23}
Nahlieli et al ^{3,24} 2010 Israel (semirigid)	64	51 SM; 20 P	Sialoliths (19)	Variable	Lithotripsy assisted	19/19	NR	NR	None
Serbetci and Sengor, ²⁵ 2010 Turkey (rigid, semirigid)	54	33 SM; 27 P	Sialoliths (28 SM, 10 P); nonsialolith (15)	Variable	ESWL; holmium:YAG	44/53	NR	3 SM	None
Yu et al, ²⁶ 2010 China (semirigid)	128	77 SM	Sialoliths (63); nonsialolith (14)	NR	Grasping instruments; lithotripsy; stretching	64/77	NR	NR	Results include 51 Pts also treated with surgery alone: sublingual cyst (1 Pt); significant swelling treated with steroids and antibiotics (5 Pts)

Abbreviations: ESWL, extracorporeal shockwave lithotripsy; NA, not applicable; NR, not reported; P, parotid gland; Post-op, postoperative; Pts, patients; SL, sublingual gland; SM, submandibular gland; TMJ, temporomandibular joint; USA, United States of America.

^aSuccess rate and residual obstruction rate refer to number of successes or residual obstructions/number of sialendoscopies. This number might not correlate with either the reported number of patients or the reported number of sialendoscopies because not all patients necessarily underwent sialendoscopies and because some of the patients who underwent sialendoscopies might have been excluded from analysis by the authors of the individual studies for various reasons (eg, sialendoscopy attempted but unsuccessful because of inability to cannulate duct and therefore not reflected in the denominator).

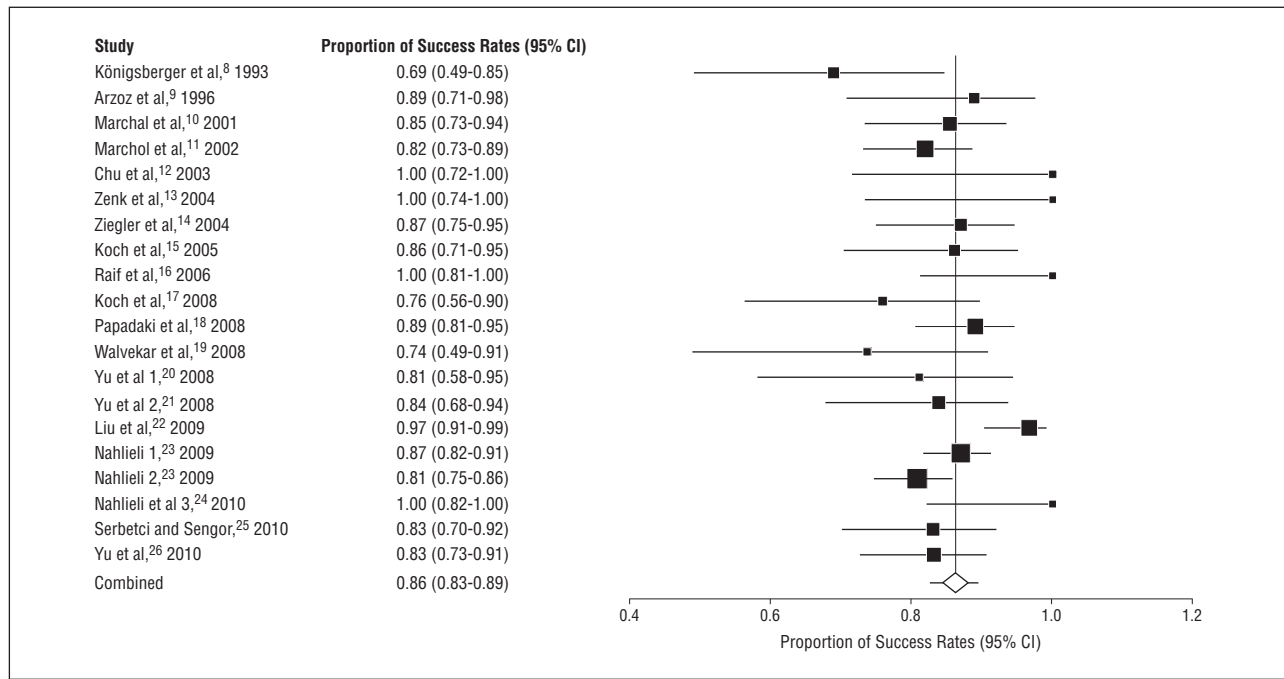


Figure 2. Pooled analysis for success rates after sialendoscopy alone (without a combined surgical approach).

weighted pooled proportion of success rates was 0.86 (95% CI, 0.83-0.89) (**Figure 2**). Heterogeneity analysis measured a Cochrane Q of 48.7 ($df=19$) ($P<.002$), and an I^2 (inconsistency) of 61% (95% CI, 29.4%-74.9%)—the percentage of variation across studies that is due to heterogeneity rather than chance. Incidence of sialadenectomy was 0% to 11%, with a trend for fewer cases in more recent publications. Few complications were reported and included symptoms of mild sialadenitis, ductal wall perforation, temporary lingual nerve paresthesia, postoperative infection, and traumatic ranula. There was no permanent nerve injury reported.

SIALENDOSCOPY WITH COMBINED SURGICAL APPROACH

Eleven studies involving 374 patients were included in the analysis.^{14,22,24,25,33-39} **Table 2** provides detailed descriptions of patient population, site and cause of obstruction, combination with minimally invasive external surgical approaches, and success and complication rates. Surgical approaches ranged from small transmuscular incisions to larger transoral incisions to preauricular cheek incisions. The weighted pooled proportion of success rates was 0.93 (95% CI, 0.89-0.96) (**Figure 3**). Heterogeneity analysis calculated a Cochran Q of 13.8 ($df=9$) ($P<.18$) and I^2 (inconsistency) of 27.7% (95% CI, 0%-63.8%). Sialadenectomy was necessary in 0% to 11% of cases (0 to 2 cases per case series). Complications included temporary lingual nerve paresthesia, minor glandular swelling, postoperative infection, and ductal stenosis. One retrospective case series of giant sialoliths (diameter >15 mm, with a mean diameter of 19 mm) reported a single case of iatrogenic partial transection of the lingual nerve.³⁹

SIALENDOSCOPY FOR RADIOIODINE-INDUCED SIALADENITIS

Three studies described 33 patients treated with sialendoscopy for radioiodine-induced sialadenitis.⁴⁰⁻⁴² Outcomes are detailed in **Table 3**. Techniques used a variety of supportive devices, and success rates ranged from 50% to 100%. No sialadenectomy or major complications were reported.

COMMENT

To our knowledge, this is the first systematic review and meta-analysis that evaluates the efficacy and safety of interventional sialendoscopy. Based on the pooled analysis, the pooled success rates for interventional sialendoscopy was 86% for sialendoscopy alone and 93% when combined with a minimally invasive surgical approach. A low incidence of major complications was reported.

The inherent weakness of our study is secondary to the heterogeneity that is introduced when pooling studies with nonuniform populations and methodology. Variability in the use of instrumentation and ancillary devices both between and within studies where instruments changed or evolved over time contributes to this weakness. The senior author (O.N.) has nearly 18 years of experience with this technique and has previously reported 13-year overall success rates of 86% for parotid endoscopic sialolithotomy, 89% for submandibular endoscopic sialolithotomy, and 81% for stricture treatment.³² Therefore, it must be recognized that our pooled success rate of 86% includes all 3 subgroups, which may either augment or decrease the true rates of success.

Table 2. Success Rates After Sialendoscopy With a Combined Surgical Approach

Source, Country (Type of Scope)	No. of Pts	No. and Site of Sialendoscopies	Size, mm	Surgical Approach (Sialendoscopy With Surgery)	Success Rate ^a	Residual Obstruction Rate ^a	No. of Sialadenectomies	Complications
Ziegler et al. ¹⁴ 2004 Germany (NR)	72	11 SM	>4 (11 Pts); ≤10 (6 Pts)	Small transmucosal incision	11/11	0	0	None
McGurk et al. ³³ 2006 UK (semirigid)	8	8 P	11	Preauricular skin flap and incision through parotid fascia	7/8	1/8	None	Duct ligation (2 Pts)
Nahlieli et al. ³⁴ 2007 Israel (semirigid)	172	172 SM	NR	Ductal stretching and transoral incision	140/159	7/159	4	Temporary lingual nerve paresthesia (1 Pts)
Liu et al. ²² 2009 China [subgroup] (semirigid)	90	33 SM; 1 P	NR	Intramucosal dissection or cheek incision	33/34	1/34	For entire series: 1	For entire series: Post-op infection (1 Pt); ranula (1 Pt)
Walvekar et al. ³⁵ 2009 USA (semirigid)	20	14 SM; 6 P	5-23 (SM) 5-13 (P)	Intraoral incision	18/20	2/20	1 SM; 1 P	Minor complications (4 Pts) (temporary lingual nerve paresthesia, recurrent swelling resolved with conservative measures)
Karavidas et al. ³⁶ 2010 UK/Israel/USA (NR)	70	69 P; 2 mucus plugs	7.2 (3-15)	Preauricular incision (41 Pts); cheek incision (25 Pts)	66/67	1/67	0	Minor gland swelling; perforated duct (1 Pt); ducts ligated (2 Pts); acute parotitis (2 Pts); persistent problems Post-op (3 Pts)
Koch et al. ³⁷ 2010 Germany (semirigid)	9	9 P	NR	Incision along skin fold or preauricular (parotid) skin incision	8/9	0	1	Damage to anatomical structures and duct reconstruction not possible (1 Pt)
Nahlieli et al. ²⁴ 2010 Israel (semirigid)	94	60 SM; 34 P	Variable	Stretching procedure for SM stones or extraoral incision for P	35/37	NR	NR	None
Su et al. ³⁸ 2010 China (semirigid)	18	18 SM	15 (range, 8-25)	Sialendoscopically assisted open sialolithectomy	17/18	1/18	1	Post-op infection (1 Pt); temporary lingual nerve paresthesias (3 Pts)
Serbetci and Sengor. ²⁵ 2010 Turkey (rigid, semirigid)	54	4 SM	Variable	Intraoral duct dissection	3/4	NR	1 SM	None
Wallace et al. ³⁹ 2010 USA (semirigid)	7	2 P; 5 SM	15-25	Limited transoral incision (SM), external parotid approach	7/7	0	1	Partial transection of lingual nerve (1 Pt); recurrent symptoms of stenosis (1 Pt)

Abbreviations: NA, not applicable; NR, not reported; P, parotid gland; Post-op, postoperative; Pts, patients; SM, submandibular gland; UK, United Kingdom; USA, United States of America.

^aFor an explanation of success and residual obstruction rates, see footnote to Table 1.

Management algorithms based on sialolith size, orientation, and shape have been published in the literature.^{43,44} Marchal and Dulguerov⁴³ suggested that the removal of submandibular stones smaller than 4 mm and parotid stones smaller than 3 mm is amenable to sialendoscopy with basket or forceps retrieval, whereas larger stones may require the use of ancillary techniques such as fragmentation. Walvekar and colleagues⁴⁴ reported similar size recommendations and found retrieval success to be dependent on the stone's largest dimension being oriented favorably in the duct. It was not possible to perform a meta-analysis by stone size in the present study because the data were not uniformly published in the included studies.

Several controversies exist within the field. These are addressed in the subsequent discussion and include the use of extracorporeal shockwave lithotripsy, postoperative stenting and corticosteroid use, functional gland recovery, and operator learning curves.

Extracorporeal shockwave lithotripsy is commonly used alone or in combination with sialendoscopy in Europe and Israel; however, its use for this indication has not been approved in North America. A multicentered prospective observational study evaluated outcomes of minimally invasive management of salivary calculi in 4691 patients.⁴⁵ When this technique was used alone or in conjunction with sialendoscopy or other minimally invasive surgical approaches, success rates (total clearance and partial clearance) were approximately 97% and the incidence of sialadenectomy was 2.9%. This large trial was not eligible for inclusion in this systematic review because not all patients underwent sialendoscopy and first-line treatment was with extracorporeal shockwave lithotripsy or basket/ or microforceps retrieval under fluoroscopic, radiographic, or sialendoscopic guidance.

The use of postoperative stenting and corticosteroid injection through a stent or duct to prevent stricture or stenosis was variable among the studies. To our knowl-

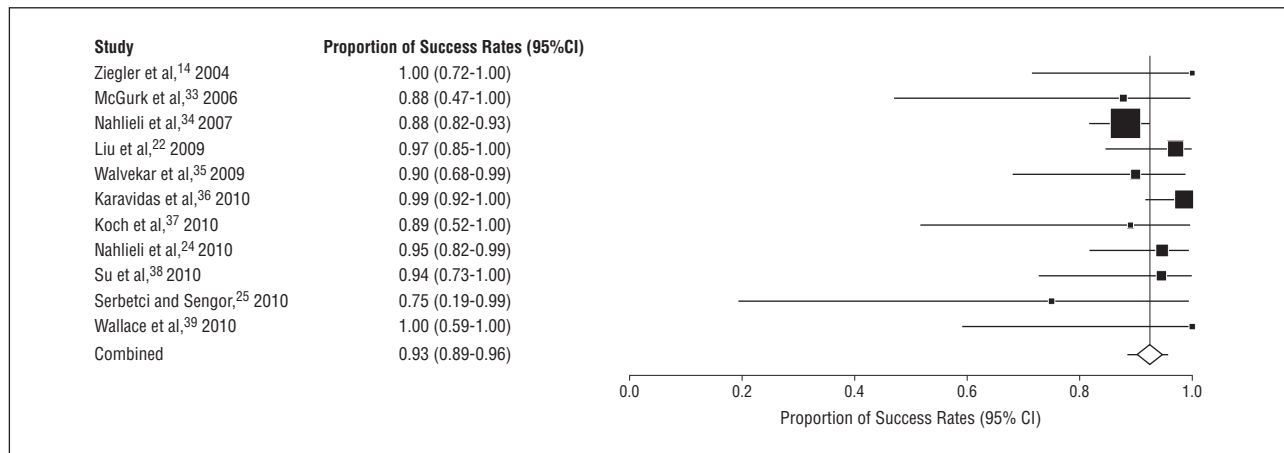


Figure 3. Pooled analysis for success rates after sialendoscopy with a combined surgical approach.

Source, Country (Type of Scope)	No. of Pts	No. and Site of Sialendoscopies	Type of Obstruction	Supportive Devices	Success Rate	Residual Obstruction Rate	No. of Sialadenotomies	Complications
Nahlieli and Nazarian, ⁴⁰ 2006 Israel (semirigid)	15	15 (NS)	Avascular lining mucosa; multiple mucus plaques and strictures	Dilation	15/15	None	None	None
Kim et al, ⁴¹ 2007 China (NR)	21 (15 improved with conservative management)	6 (NS)	Stenosis	Balloon dilation; endoscopic sheath	3/6	3/6	NR	NR
Bomeli et al, ⁴² 2009 USA (semirigid)	9 (P); 6 (SM); 3 (both)	20 P 12 SM	Ductal stenosis (30%); mucus plugs (44%)	Dilation; wire basket	10/12 SM; 17/20 P	3/12	NR	Minor complications (5 Pts)

Abbreviations: NR, not reported; NS, site not specified; P, parotid gland; Pts, patients; SM, submandibular gland; USA, United States of America.

edge, no randomized controlled trials or formal studies have investigated the outcomes following either technique. The use of stenting is surgeon dependent in practice. In our center at McMaster University, we use intraductal corticosteroid injection routinely intraoperatively and use stenting occasionally after stricture dilation or if significant ductal trauma was encountered during stone removal. The senior author (O.N.) uses stents (Sialo-drain; Sialotechnology LTD) for 4 weeks in any case of surgical endoscopy for sialolith removal and submandibular stricture dilatation. Systemic dexamethasone is given preoperatively and postoperatively. Postoperative antibiotics are prescribed, and patients are encouraged to drink 2 L of water per day and to massage the affected gland 3 times daily. Future directions should focus on refinement of techniques surrounding intraoperative and postoperative care.

Functional gland recovery after sialendoscopy has been examined. Su and colleagues⁴⁶ published a consecutive series of 17 patients (15 with calculi and 2 with stenosis) who were followed for a mean (SD) of 14 (8) months. They illustrated a statistically significant functional glandular recovery as measured by sialometric and scintigraphic assessment in the affected glands after sialen-

doscopy and an absence of difference when compared with the contralateral gland.

The present analysis does not consider the operator learning curve that is integral to all surgical techniques. Luers and colleagues⁴⁷ assessed this notion for both diagnostic and interventional sialendoscopy in a prospective case series of 50 patients based on operative parameters and a postoperative performance rating. There was a statistically significant improvement in mean operative time and mean performance rating ($P < .001$ and $P = .007$, respectively) after the first 10 patients and again after the first 30 patients ($P = .003$ and $P = .01$, respectively), and performance ratings achieved a level of excellence among the last group of patients.

The use of sialendoscopy for the treatment of radioiodine-induced sialadenitis is relatively novel. The 3 published reports in this review are small in patient numbers. Studies with larger patient populations and follow-up time are needed to elucidate the true utility of this interventional modality. Recent applications of this technique also include the treatment of inflammatory diseases such as Sjögren syndrome and juvenile recurrent parotitis.⁴⁸⁻⁵⁰

In conclusion, the present systematic review and meta-analysis, which provides a summary of the best avail-

able evidence, suggests that sialendoscopy is efficacious, safe, and gland preserving for the treatment of patients with major salivary gland obstructive disease. It is a novel and powerful minimally invasive treatment modality that is relevant to all physicians and surgeons who treat patients with obstructive salivary gland disease.

Submitted for Publication: September 19, 2011; final revision received February 21, 2012; accepted April 2, 2012.

Correspondence: Julie Strychowsky, MD, Division of Otolaryngology–Head and Neck Surgery, Department of Surgery, McMaster University, 1200 Main St W, Hamilton, ON L8N 3Z5, Canada, (ulie.strychowsky@medportal.ca).

Author Contributions: Dr Strychowsky had full access to all the data in the study and takes responsibility for the integrity of the data and the accuracy of the data analysis. *Study concept and design:* Strychowsky, Sommer, and Nahlieli. *Acquisition of data:* Strychowsky, Sommer, and Cohen. *Analysis and interpretation of data:* Strychowsky and Gupta. *Drafting of the manuscript:* Strychowsky, Sommer, and Nahlieli. *Critical revision of the manuscript for important intellectual content:* Strychowsky, Sommer, and Gupta, and Cohen. *Statistical analysis:* Strychowsky and Gupta. *Administrative, technical, and material support:* Strychowsky, Sommer, and Cohen. *Study supervision:* Sommer and Nahlieli.

Financial Disclosure: Dr Nahlieli is a consultant for Sialotechnology LTD Israel.

Previous Presentation: This study was presented at the Canadian Society of Otolaryngology–Head and Neck Surgery Annual Meeting; May 23, 2011; Victoria, British Columbia, Canada.

REFERENCES

- Epker BN. Obstructive and inflammatory diseases of the major salivary glands. *Oral Surg Oral Med Oral Pathol.* 1972;33(1):2-27.
- Bodner L. Salivary gland calculi: diagnostic imaging and surgical management. *Compendium.* 1993;14(5):572, 574-576, 578.
- Marchal F, Kurt AM, Dulguerov P, Lehmann W. Retrograde theory in sialolithiasis formation. *Arch Otolaryngol Head Neck Surg.* 2001;127(1):66-68.
- Capaccio P, Torretta S, Pignataro L. The role of adenectomy for salivary gland obstructions in the era of sialendoscopy and lithotripsy. *Otolaryngol Clin North Am.* 2009;42(6):1161-1171.
- Katz P. New treatment method for salivary lithiasis. *Rev Laryngol Otol Rhinol (Bord).* 1993;114(5):379-382.
- Nahlieli O, Neder A, Baruchin AM. Salivary gland endoscopy. *J Oral Maxillofac Surg.* 1994;52(12):1240-1242.
- Liberati A, Altman DG, Tetzlaff J, et al. The PRISMA statement for reporting systematic reviews and meta-analyses of studies that evaluate health care interventions: explanation and elaboration. *J Clin Epidemiol.* 2009;62(10):e1-e34.
- Königsberger R, Feyh J, Goetz A, Kastenbauer E. Endoscopically-controlled electrohydraulic intracorporeal shock wave lithotripsy (EISL) of salivary stones. *J Otolaryngol.* 1993;22(1):12-13.
- Arzoz E, Santiago A, Esnal F, Palomero R. Endoscopic intracorporeal lithotripsy for sialolithiasis. *J Oral Maxillofac Surg.* 1996;54(7):847-852.
- Marchal F, Dulguerov P, Becker M, Barki G, Disant F, Lehmann W. Specificity of parotid sialendoscopy. *Laryngoscope.* 2001;111(2):264-271.
- Marchal F, Dulguerov P, Becker M, Barki G, Disant F, Lehmann W. Submandibular diagnostic and interventional sialendoscopy: new procedure for ductal disorders. *Ann Otol Rhinol Laryngol.* 2002;111(1):27-35.
- Chu DW, Chow TL, Lim BH, Kwok SP. Endoscopic management of submandibular sialolithiasis. *Surg Endosc.* 2003;17(6):876-879.
- Zenk J, Koch M, Bozzato A, Iro H. Sialoscopy—initial experiences with a new endoscope. *Br J Oral Maxillofac Surg.* 2004;42(4):293-298.
- Ziegler CM, Steveling H, Seubert J. Endoscopy: a minimally invasive procedure for diagnosis and treatment of diseases of the salivary glands: six years of practical experience. *Br J Oral Maxillofac Surg.* 2004;42(1):1-7.
- Koch M, Zenk J, Bozzato A, Bumm K, Iro H. Sialoscopy in cases of unclear swelling of the major salivary glands. *Otolaryngol Head Neck Surg.* 2005;133(6):863-868.
- Raif J, Vardi M, Nahlieli O, Gannot I. An Er:YAG laser endoscopic fiber delivery system for lithotripsy of salivary stones. *Lasers Surg Med.* 2006;38(6):580-587.

- Koch M, Iro H, Zenk J. Role of sialoscopy in the treatment of Stensen's duct strictures. *Ann Otol Rhinol Laryngol.* 2008;117(4):271-278.
- Papadakis ME, McCain JP, Kim K, Katz RL, Kaban LB, Troulis MJ. Interventional sialoendoscopy: early clinical results. *J Oral Maxillofac Surg.* 2008;66(5):954-962.
- Walvekar RR, Razfar A, Carrau RL, Schaitkin B. Sialendoscopy and associated complications: a preliminary experience. *Laryngoscope.* 2008;118(5):776-779.
- Yu CQ, Yang C, Zheng LY, Wu DM, Zhang J, Yun B. Selective management of obstructive submandibular sialadenitis. *Br J Oral Maxillofac Surg.* 2008;46(1):46-49.
- Yu C, Zheng L, Yang C, Shen N. Causes of chronic obstructive parotitis and management by sialoendoscopy. *Oral Surg Oral Med Oral Pathol Oral Radiol Endod.* 2008;105(3):365-370.
- Liu DG, Zhang ZY, Zhang Y, Zhang L, Yu GY. Diagnosis and management of sialolithiasis with a semirigid endoscope. *Oral Surg Oral Med Oral Pathol Oral Radiol Endod.* 2009;108(1):9-14.
- Nahlieli O. Endoscopic surgery of the salivary glands. *Alpha Omegan.* 2009;102(2):55-60.
- Nahlieli O, Shacham R, Zaguri A. Combined external lithotripsy and endoscopic techniques for advanced sialolithiasis cases. *J Oral Maxillofac Surg.* 2010;68(2):347-353.
- Serbetci E, Sengor GA. Sialendoscopy: experience with the first 60 glands in Turkey and a literature review. *Ann Otol Rhinol Laryngol.* 2010;119(3):155-164.
- Yu C, Yang C, Zheng L, Wu D. Endoscopic observation and strategic management of obstructive submandibular sialadenitis. *J Oral Maxillofac Surg.* 2010;68(8):1770-1775.
- Nahlieli O, Baruchin AM. Sialoendoscopy: three years' experience as a diagnostic and treatment modality. *J Oral Maxillofac Surg.* 1997;55(9):912-920.
- Nahlieli O, Baruchin AM. Endoscopic technique for the diagnosis and treatment of obstructive salivary gland diseases. *J Oral Maxillofac Surg.* 1999;57(12):1394-1402.
- Nahlieli O, Baruchin AM. Long-term experience with endoscopic diagnosis and treatment of salivary gland inflammatory diseases. *Laryngoscope.* 2000;110(6):988-993.
- Nahlieli O, Shacham R, Yoffe B, Eliav E. Diagnosis and treatment of strictures and kinks in salivary gland ducts. *J Oral Maxillofac Surg.* 2001;59(5):484-492.
- Nahlieli O, Shacham R, Bar T, Eliav E. Endoscopic mechanical retrieval of sialoliths. *Oral Surg Oral Med Oral Pathol Oral Radiol Endod.* 2003;95(4):396-402.
- Nahlieli O, Nakar LH, Nazarian Y, Turner MD. Sialoendoscopy: a new approach to salivary gland obstructive pathology. *J Am Dent Assoc.* 2006;137(10):1394-1400.
- McGurk M, MacBean AD, Fan KF, Sproat C, Darwish C. Endoscopically assisted operative retrieval of parotid stones. *Br J Oral Maxillofac Surg.* 2006;44(2):157-160.
- Nahlieli O, Shacham R, Zagury A, Bar T, Yoffe B. The ductal stretching technique: an endoscopic-assisted technique for removal of submandibular stones. *Laryngoscope.* 2007;117(6):1031-1035.
- Walvekar RR, Bomeli SR, Carrau RL, Schaitkin B. Combined approach technique for the management of large salivary stones. *Laryngoscope.* 2009;119(6):1125-1129.
- Karavidas K, Nahlieli O, Fritsch M, McGurk M. Minimal surgery for parotid stones: a 7-year endoscopic experience. *Int J Oral Maxillofac Surg.* 2010;39(1):1-4.
- Koch M, Bozzato A, Iro H, Zenk J. Combined endoscopic and transcutaneous approach for parotid gland sialolithiasis: indications, technique, and results. *Otolaryngol Head Neck Surg.* 2010;142(1):98-103.
- Su YX, Liao GQ, Zheng GS, Liu HC, Liang YJ, Ou DM. Sialoendoscopically assisted open sialolithotomy for removal of large submandibular hilar calculi. *J Oral Maxillofac Surg.* 2010;68(1):68-73.
- Wallace E, Tauzin M, Hagan J, Schaitkin B, Walvekar RR. Management of giant sialoliths: review of the literature and preliminary experience with interventional sialendoscopy. *Laryngoscope.* 2010;120(10):1974-1978.
- Nahlieli O, Nazarian Y. Sialadenitis following radioiodine therapy—a new diagnostic and treatment modality. *Oral Dis.* 2006;12(5):476-479.
- Kim JW, Han GS, Lee SH, Lee DY, Kim YM. Sialoendoscopic treatment for radioiodine induced sialadenitis. *Laryngoscope.* 2007;117(1):133-136.
- Bomeli SR, Schaitkin B, Carrau RL, Walvekar RR. Interventional sialendoscopy for treatment of radioiodine-induced sialadenitis. *Laryngoscope.* 2009;119(5):864-867.
- Marchal F, Dulguerov P. Sialolithiasis management: the state of the art. *Arch Otolaryngol Head Neck Surg.* 2003;129(9):951-956.
- Walvekar RR, Carrau RL, Schaitkin B. Endoscopic sialolith removal: orientation and shape as predictors of success. *Am J Otolaryngol.* 2009;30(3):153-156.
- Iro H, Zenk J, Escudier MP, et al. Outcome of minimally invasive management of salivary calculi in 4,691 patients. *Laryngoscope.* 2009;119(2):263-268.
- Su YX, Xu JH, Liao GQ, et al. Salivary gland functional recovery after sialendoscopy. *Laryngoscope.* 2009;119(4):646-652.
- Luers JC, Damm M, Klussmann JP, Beutner D. The learning curve of sialendoscopy with modular sialoscopes: a single surgeon's experience. *Arch Otolaryngol Head Neck Surg.* 2010;136(8):762-765.
- Nahlieli O, Shacham R, Shlesinger M, Eliav E. Juvenile recurrent parotitis: a new method of diagnosis and treatment. *Pediatrics.* 2004;114(1):9-12.
- Shacham R, Droma EB, London D, Bar T, Nahlieli O. Long-term experience with endoscopic diagnosis and treatment of juvenile recurrent parotitis. *J Oral Maxillofac Surg.* 2009;67(1):162-167.
- Martins-Carvalho C, Plouin-Gaudon I, Quenin S, et al. Pediatric sialendoscopy: a 5-year experience at a single institution. *Arch Otolaryngol Head Neck Surg.* 2010;136(1):33-36.