

Simple method of open skin wound healing model in corticosteroid-treated and diabetic rats: standardization of semi-quantitative and quantitative histological assessments

P. GAL^{1,2}, R. KILIK³, M. MOKRY¹, B. VIDINSKY¹, T. VASILENKO¹, S. MOZES⁴, N. BOBROV¹, Z. TOMORI⁵, J. BOBER³, L. LENHARDT²

¹Pavol Jozef Safarik University, Kosice, Slovak Republic

²University of Veterinary Medicine, Kosice, Slovak Republic

³1st Clinic of Surgery, Pavol Jozef Safarik University and L. Pasteur Faculty Hospital, Kosice, Slovak Republic

⁴Institute of Animal Physiology, Slovak Academy of Sciences, Kosice, Slovak Republic

⁵Institute of Experimental Physics, Slovak Academy of Sciences, Kosice, Slovak Republic

ABSTRACT: The use of a simple and reproducible model is inevitable for objective statement of the effects of external factors on wound healing. Hence, present study was conducted to establish an excisional model of skin wound healing in corticosteroid treated, and streptozotocine induced diabetic rats as well as to standardized the semi-quantitative and quantitative evaluation of selected parameters. Round full thickness skin wounds were performed on the back of male Sprague-Dawley rats. Animals were sacrificed two, six, and fourteen days after surgery. Sections were stained with hematoxylin-eosin and van Gieson. Both semi-quantitative (wound reepithelization; presence of: inflammatory cells, fibroblasts, new vessels, and collagen) and quantitative methods (polymorphonuclear leucocytes/tissue macrophages ratio, percentage of re-epithelization, area of the granulation tissue) were used to evaluate the histological changes during wound healing. As compared to the control group the wound healing process of both experimental groups was decelerated. Interestingly, wound reepithelization and angiogenesis were significantly inhibited only in the steroid rats while epithelization was accelerated in diabetic rats. In conclusion, when compared to primary sutured wound healing it can be concluded that the excisional model is more appropriate for histological assessment of the effect of various factors on wound healing. In addition, administration of corticosteroids represents simple and inexpensive model of a complex skin wound healing impairment.

Keywords: repair; regeneration; scar tissue; insulin dependent diabetes mellitus

The use of a simple and reproducible model is a basic requirement inevitable for objective statement of the effects of different external factors on skin wound healing. In general, there exist two main models, i.e. incisional and excisional (Dorsett-Martin, 2004), allowing determination of three basic phases which occur during wound healing (inflammation, proliferation, and maturation) (Barbul and Regan,

1993). Whereas the incisional (sutured) skin healing model is preferred for wound tensile strength measurement (Davidson, 1998), the excisional model is more appropriate for histological evaluation due to significantly broader morphological changes which occur during the healing process.

At present time, there exist many factors which may negatively affect wound healing. Among these

Supported by Scientific Grant Agency (VEGA) of the Ministry of Education of the Slovak Republic and the Slovak Academy of Sciences (Grants No. 1/4228/07 and No. 2/0164/08).

diabetes mellitus is characterized by enhanced glycemia and micro- and macroangiopathy. In addition, wound healing in diabetic animals is characterized mainly by stagnation of granulation tissue formation. The importance of the effect of diabetes on wound healing is documented by the fact that over 50 percent of all non-traumatic lower-leg amputations are caused by diabetic foot ulcers (Spollett, 1998). Similarly, systemic administration of corticosteroids, which is frequently used as non-specific anti-inflammatory therapy in various diseases or traumas (Barnes, 2006; Baptiste and Fehlings, 2007), may result in poor wound healing due to its catabolic effects in skin.

Moreover, some excisional as well as incisional wound healing studies were done only in a descriptive manner, making a qualitative assessment either of the modulation of various cells or of the ECM remodeling (do Nascimento et al., 2004; Pessoa et al., 2004). However, by using this method is not possible to evaluate precisely the range of changes induced by tested therapy. Therefore, for objective evaluation the effects of various external factors on wound healing semi-quantitative or quantitative assessments are needed allowing statistical comparison between experimentally treated and control wounds.

Hence, this study was aimed to establish an excisional model of skin wound healing in normal healthy, corticosteroid treated, and streptozotocine induced diabetic rats as well as to standardized the semi-quantitative and quantitative evaluation of selected parameters. The use of a model is necessary to obtain information on the multifactorial nature of the wound healing process, which may be influenced by externally introduced factors (Gottrup et al., 2000).

MATERIAL AND METHODS

Animal models

The experimental conditions were in compliance with the requirements of the Ethics Committee of the Faculty of Medicine of P. J. Safarik University in Kosice and approved by the State Veterinary Administration of the Slovak Republic.

Ten-months-old male Sprague-Dawley rats ($n = 54$) weighing 500–550 g were included into the experiment and randomized into three groups of six animals.

(1) Control group (C) – non-treated animals.

(2) Steroid group (S) – animals received intramuscularly a bolus dose of 20 mg/kg of methyl-prednisolone (Depo-Medrol, Pharmacia & Upjohn Inc., Bridgewater, NJ, USA) immediately prior surgery.

(3) Diabetic group (D) – six weeks prior the wound healing experiment animals received 60 mg/kg of streptozotocine (Streptozotocin, Sigma-Aldrich, Prague, Czech Republic). For intraperitoneal administration 15 mg of streptozotocine was prepared in 1 ml phosphate buffer (pH = 5.5). Only rats with glycemia higher than 12 mmol/l (during three consecutive days) were included into the experiment.

In general anesthesia induced by intramuscular administration of ketamin (33 mg/kg; Narkamon a.u.v., Spofa a.s., Prague, Czech Republic), xylazine (11 mg/kg; Rometar a.u.v., Spofa a.s., Prague, Czech Republic), and tramadol (5 mg/kg; Tramadol-K, Krka d.d., Novo Mesto, Slovenia) a small incision was made above the spine through which the lower part of the belt punch pliers were slide beneath the skin. Consecutively, four round full thickness excision, 4 mm in diameter, were performed on back of each rat (Figure 1). The incision was then sutured.

Histological evaluation

Six rats from each group were sacrificed two, six, and fourteen days after surgery. Skin wounds removed and were processed routinely for light microscopy (fixating, dehydrating, embedding, and cutting). Two sections were made from each wound and stained with hematoxylin-eosin (HE – basic staining) and van Gieson (VG – collagen staining), respectively.

Semi-quantitative method was used to evaluate following histological processes and structures: reepithelization, PMNL (polymorphonuclear leucocytes), fibroblasts, new vessels, and new collagen. Sections were evaluated according to the scale: 0, 1, 2, 3, 4 (Table 1, Figure 2) by two independent observers. The mean value was used for statistical comparison.

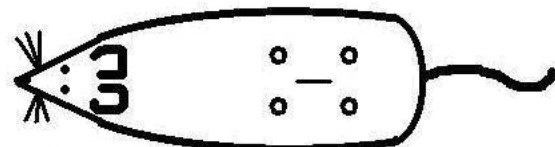


Figure 1. A small incision was made through which the lower part of the belt punch pliers were slide beneath the skin. Consecutively, four round, 4 mm in diameter, full thickness excisions were made on the back of each rat

Table 1. Explanation of used scale in the semi-quantitative evaluation of histological sections (ST – surrounding tissue, i.e. tissue out of GT; DL – demarcation line; SCT – subcutaneous tissue; GT – granulation tissue)

Scale	Epithelization	PMNL	Fibroblasts	New vessels	Collagen
0	thickness of cut edges	absent	absent	absent	absent
1	migration of cells (< 50%)	mild ST	mild-ST	mild-SCT	minimal-GT
2	migration of cells (\geq 50%)	mild DL/GT	mild-GT	mild-GT	mild-GT
3	bridging the excision	moderate DL/GT	moderate-GT	moderate-GT	moderate-GT
4	keratinization	marked DL/GT	marked-GT	marked-GT	marked-GT

Quantification of three parameters was used in this study using the Ellipse 2.0.7.1. (ViDiTo, Kosice, Slovak Republic) software. (i) To determine the stadium of inflammatory phase PMNL/TM (tissue macrophages) ratio was calculated in specimens removed from animals killed two days after surgery. The number of PMNL and TM was counted in one high resolution field of each section. (ii) The length of epithelial sheet was morphometrically evaluated in sections removed from animals killed six days post surgery and expressed as percentage covering

whole wound surface. (iii) Area of the granulation tissue (GT) was measured in sections made from animals killed six and fourteen days after surgery.

Statistical analysis

For each parameter mean values \pm SEM were calculated. Data from the semi-quantitative evaluation were compared using the non-parametric Kruskal-Wallis test. ANOVA followed by Tuckey-Kramer

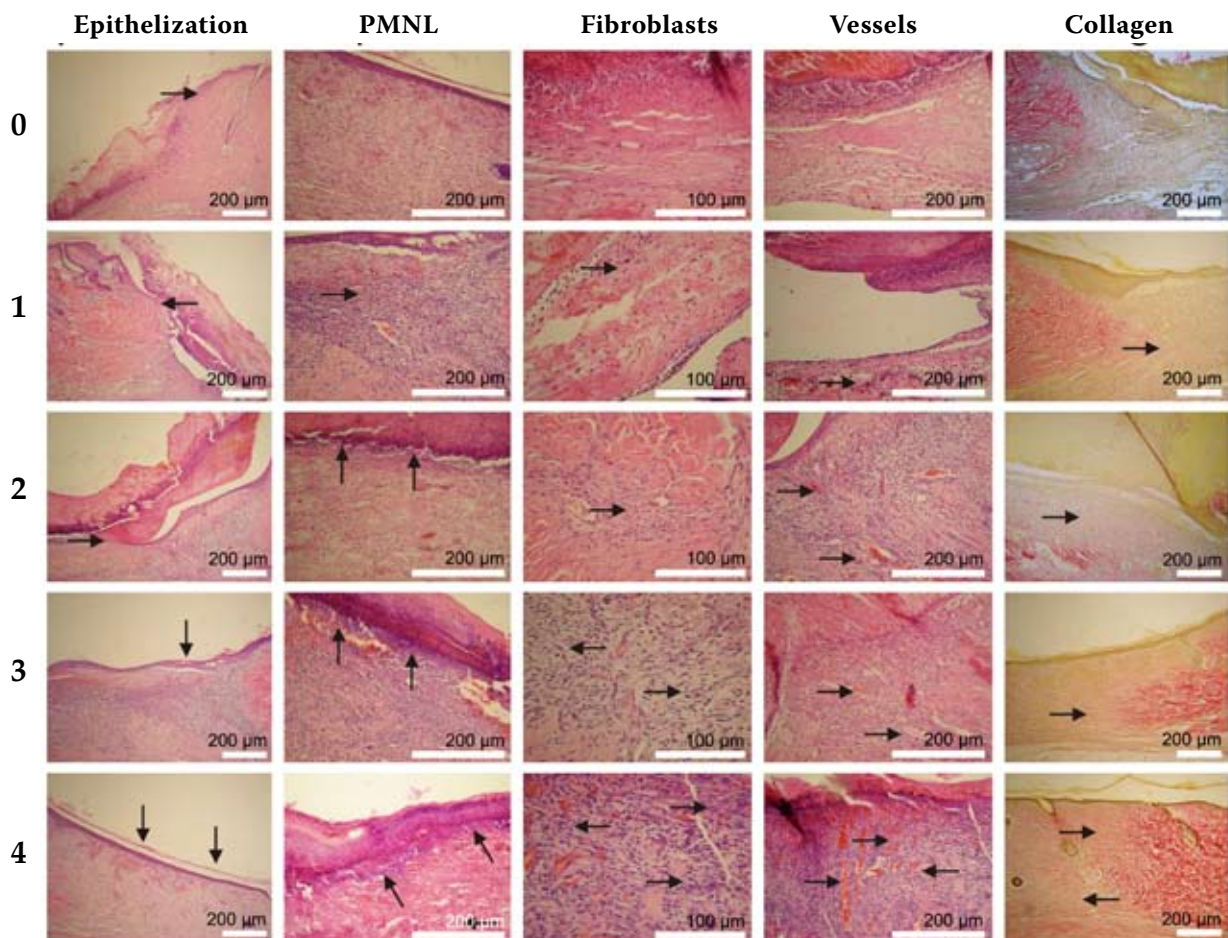


Figure 2. Examples for the 5-point scale of the semi-quantitative evaluation scale (see Table 1).

multiple comparison test were used to compare the PMNL/TM ratios, percentage of re-epithelization, and granulation tissue areas.

RESULTS

The results from our histological examination are summarized in Figure 4 and 5.

2 days post surgery

Control animals showed that the epidermis was thickened at its cut edges (Figure 3a). The dermis near the excision was rich on inflammatory cells (PMNL), thus the demarcation line was formed and separated

the necrosis from vital tissue (Figure 3a). The number of fibroblasts slightly increased in the dermis near the wounded area. Beneath the dermis was possible to observe the beginning of neo-angiogenesis, but presence of new collagen was not recorded.

In the S Group the forming of the demarcation line was slightly inhibited, but the fibrin net was rich on PMNL. The regeneration of the epidermis was completely inhibited. Nevertheless, the proliferation and migration of fibroblasts was not inhibited. Similarly as in the C Group, no new collagen and minimal new vessels were observed in the dermis of S rats.

In addition, in the D Group a significant inhibition of the inflammatory phase associated with delayed formation of the demarcation line was seen. On the other hand the regeneration of epidermis

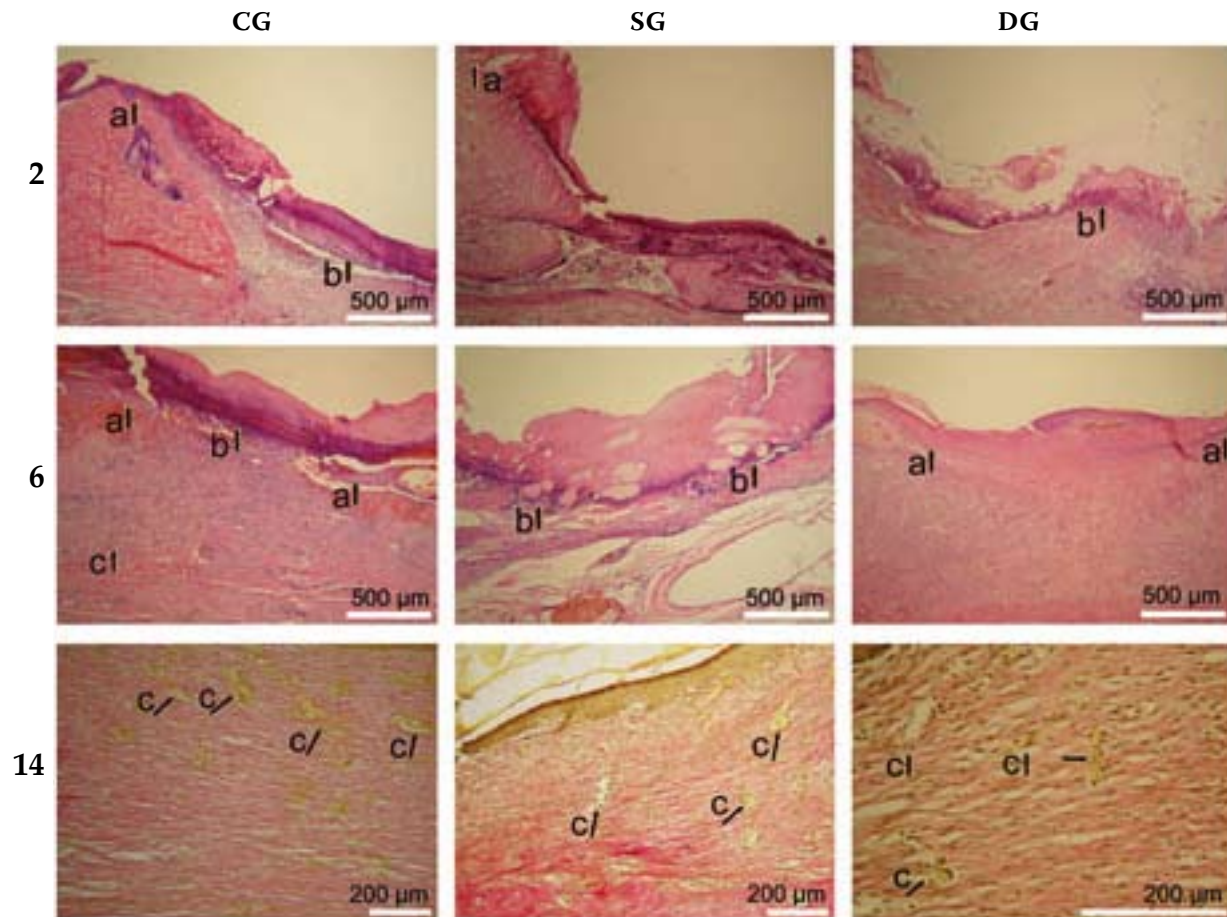


Figure 3. CG-control group: 2a = thickness of cut edges of the epidermis, 2b = demarcation line consisted mainly from PMNL and completely separates necrosis from the vital tissue; 6a = epithelization, 6b = beneath the demarcation line a complete layer of epithelial cells still not present, 6c = new vessel in the granulation tissue; 14c = vessels in the granulation tissue. SG-steroid group: 2a = forming of the demarcation line still not finished; 6b = demarcation line completely separates necrosis from the vital tissue; 14c = higher number of vessels in the granulation tissue. DG-diabetic group: 2b = forming of the demarcation line still not finished, 6a = accelerated process of reepithelization, 14c = vessels in the granulation tissue

was not delayed. However, the proliferation of fibroblasts was slightly inhibited and no new collagen was observed in wounds. Similar number of new vessels beneath the injured skin was observed.

6 days post surgery

By six days after surgery the open wounds of control animals were not yet completely bridged by a new layer of epithelial cells (Figure 3a). The tissue was only lightly infiltrated with PMNL, thus the inflammatory phase was almost finished (Figure 3b).

At the bottom of wounds newly created granulation tissue was observed (Figure 3c). The GT consisted from fibroblasts, endothelial cells, and newly synthesized non-organized collagen.

The S Group demonstrated that the administration of corticosteroids resulted in significantly slowed inflammatory process. This effect was demonstrated by increased infiltration of wounds with PMNL. Moreover, the epidermis regeneration was significantly inhibited. In addition, the proliferation and migration of fibroblasts was decelerated as well. The GT included a fewer amount of collagen as well as a significantly lower number of new vessels.

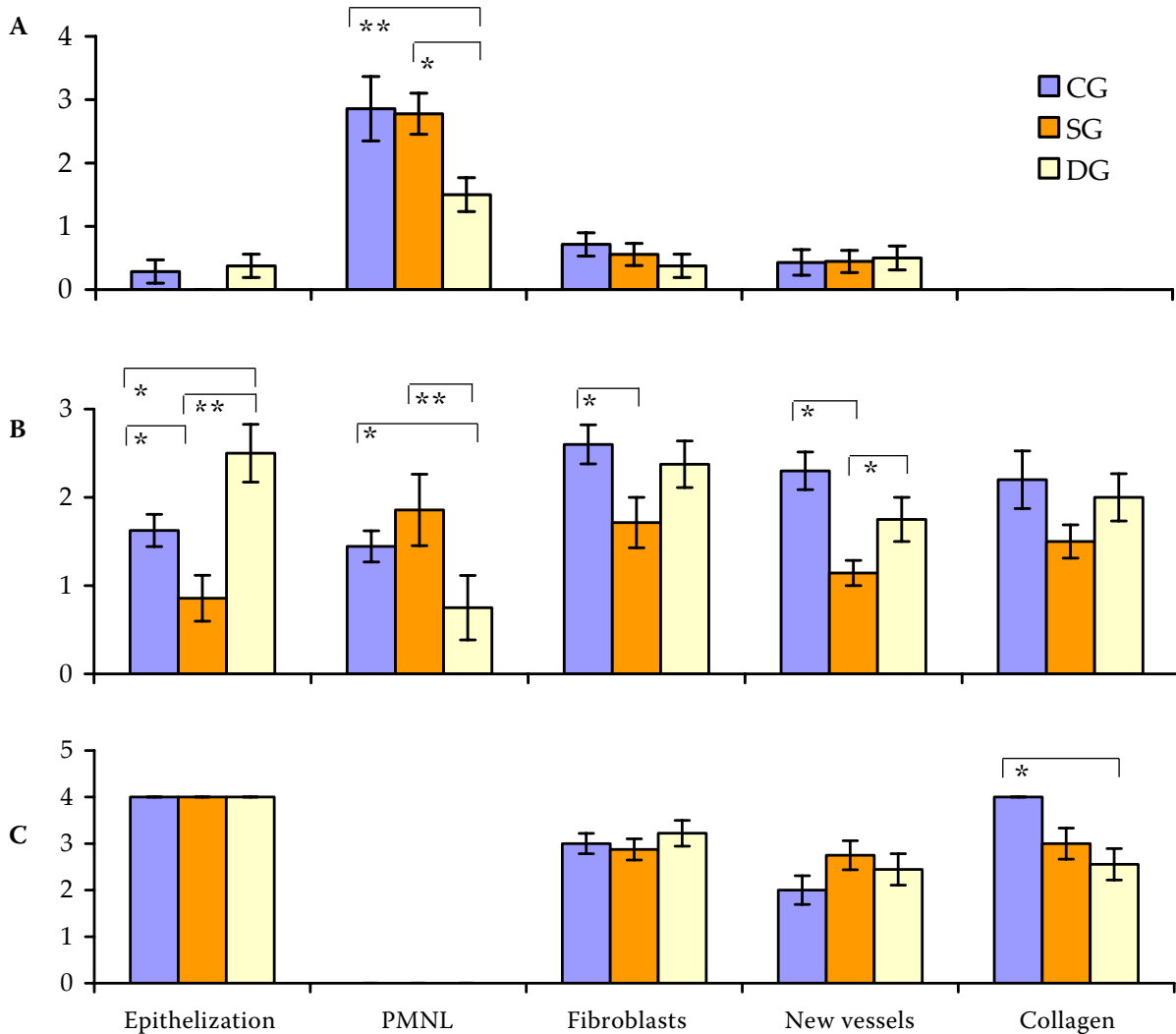


Figure 4. Semi-quantitative analysis of histological structures/changes (A – 2 days after surgery; B – 6 days after surgery; C – 14 days after surgery)

CG = control group, SG = corticosteroid treated group, DG = diabetic group

Data are presented as mean ± SEM; *P < 0.05, **P < 0.01

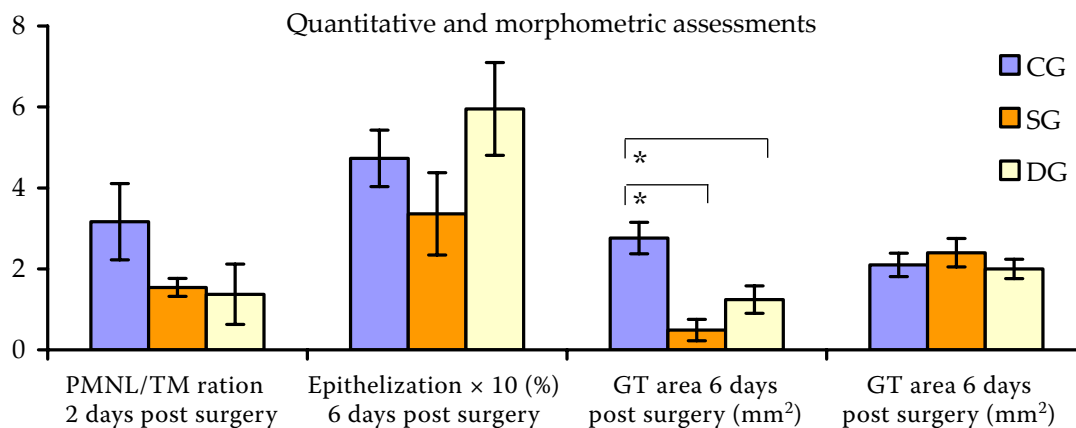


Figure 5. Quantitative and morphometric analysis of histological structures/changes

CG = control group, SG = corticosteroid treated group, DG = diabetic group

Data are presented as mean ± SEM; * $P < 0.05$

As compared to the control group in the D Group the process of epidermis regeneration was significantly accelerated and the inflammatory phase was in its final phase. Nevertheless, the general picture of healing was delayed due to a slightly inhibited both fibroblast and endothelial cells proliferation which resulted in an altered formation of the GT.

14 days post surgery

Finally, fourteen days post surgery the regeneration of the epidermis was finished. In the samples the differentiation process of keratinocytes was confirmed by the normal process of the keratinization. During this time period the tissue macrophages dominated from the inflammatory cell's population. The number of fibroblasts and endothelial cells in the GT decreased and simultaneously the amount of collagen increased (Figure 3c). Moreover, the organization of collagen into newly formed fibrils was observed, thus the scar was created.

In both experimental groups the regeneration of the epidermis was finished. PMNL were only randomly dispersed in the GT and a significant predominance of tissue macrophages was present. Hence, in both experimental groups the inflammatory phase was finished. A regress in the number of fibroblasts, but not in the number of endothelial cells in the GT was seen. Nevertheless, as compared to the control group the amount and organization of collagen were impaired in both experimental groups.

DISCUSSION

In general, it may be suggested that due to the different experimental approaches and models used, investigations have sometimes yielded different results. Hence, the use of a standardized and reproducible model is inevitable to obtain objective information of the wound healing process as well as to better understand the pathological process and to improve medical technologies (Motlik et al., 2007). When compared with our previous histological study, in which we have elaborated a detailed biomechanical and histological model of primary sutured wound healing (Gal et al., 2006; Vidinsky et al., 2006), our current work shows that there are only quantitative differences between primary and secondary wound healing. This observation was previously shown by numerous authors (Barbul and Regan, 1993; Cotran et al., 1999). Such a difference allows a better quantification of occurring morphological changes or processes. Therefore, we have expanded the 4-point scale of the semi-quantitative analysis described in our previous study to a new 5-point scale.

Moreover, it has to be mentioned that data from the semi-quantitative and quantitative assessments of re-epithelization at day six did not correlate. In contrast to morphometry the semi-quantitative scoring system evaluates epithelial keratinization as well. Since keratinocyte differentiation plays an important role in wound healing (Motlik et al., 2007) it may be suggested that the length of epithelial

sheet alone is not sufficient to express significant differences in wound healing.

In addition, to create round full thickness wounds in our study a “belt punch pliers” were used. The use of such a simple technique saves money and time since no suturing was needed for wound closure. Recent studies have evaluated the influence on healing of the diameter, length and composition of suture, as well as its physical construction, and ischemia caused by suture knotting (Boothe, 1998). However, none of many suturing techniques provides such a high reproducibility of healing conditions as it can be achieved by using a standardized open healing model. Moreover, this excisional wound healing model reduces the risk of self-induced trauma, since there is no protruding material for the animal to lick or scratch. On the other hand, there is a higher risk of infection by using an open wound healing model. Nevertheless, this side effect was not observed in our study.

The corticosteroid-treatment resulted in decelerated process of inflammation. The most affected cells in this period were the PMNL and TM. This is in agreement with previously published studies (Leibovich and Ross, 1975; Anstead, 1998). In contrast, our results of the PMNL/TM ratios point on corticosteroids-induced increased number of macrophages. Interestingly, the process of inflammatory inhibition was seen rather by prolonged presence of leucocytes during the sixth evaluated day then by inhibition of the demarcation line formation two days post-surgery. In addition, administration of corticosteroids resulted in an impaired process of reepithelization. This can be explained by glucocorticoid-inhibited keratinocyte growth factor production by fibroblasts (Chedid et al., 1996). Later, six days post surgery in steroid-treated rats a significant negative impact of methyl-prednisolone on the formation of the granulation tissue has been demonstrated due to significantly decreased process of neoangiogenesis. This is in agreement with study in which daily local injection of dexamethasone inhibited a basal sponge-induced angiogenesis (Hori et al., 1996). Moreover, previously was shown that during wound healing corticosteroids decreased the expression of transforming growth factor β (TGF- β) (Frank et al., 1996) and exogenous administration of this factor improved wound healing (Beck et al., 1993).

In contrast to the S Group, in the D Group the inflammation inhibition was based on selective inhibition of PMNL presence which was demonstrated by both semi-quantitative analysis and PMNL/TM ratio determination in present experiment.

Interestingly, the epidermis regenerated faster in diabetic group when compared with both other groups. This is in agreement with study published by Dovi et al. (2003) in which was demonstrated that the epidermis in neutrophil depleted mice regenerated faster. Moreover, in this study was shown that neutrophil depletion did not influence the number of macrophages and had no effect on dermis healing, neither on collagen deposition nor on wound stiffness. Nevertheless, previously was shown that induction of chemokines in genetically diabetic mice led to prolonged persistence of neutrophils and macrophages during later phases of wound healing (Wetzler et al., 2000). Interestingly, the expected negative impact of insulin dependent diabetes mellitus (IDDM) on neoangiogenesis during wound healing was not observed in this study. Nevertheless, on day 14 significantly lower amount of new collagen was present in the wounds of DG animals when compared to the controls.

In conclusion, during all investigated time intervals in the present experiment it was possible to record all three phases of wound healing. Our results showed that two days post-surgery allow to evaluate the acute inflammatory reaction and the beginning of re-epithelization. Six days are suitable for the assessment of the proliferative phase and reepithelization as well. Finally, fourteen days after surgery is possible to evaluate wound maturation and scar formation. In addition, our study clearly demonstrates that administration of corticosteroids represents simple and inexpensive model of a complex wound healing impairment.

Acknowledgement

We thank Professors Jozef Laurincik, Karel Smetana Jr., and Imrich Maracek for critical reading of our manuscript and for their useful comments. Also we thank M. Majnusova for preparing the histological sections as well as M. Vidova, K. Laciakova, A. Vascakova, M. Handzak, J. Sunavsky, and M. Vantrobova for their useful technical assistance. We are grateful to U.S. Steel Kosice and Tatra Bank for buying us the Olympus BX51 fluorescence microscope.

REFERENCES

- Anstead G.M. (1998): Steroids, retinoids, and wound healing. *Advances in Skin and Wound Care*, 11, 277–285.

- Baptiste D.C., Fehlings M.G. (2007): Update on the treatment of spinal cord injury. *Progress in Brain Research*, 161, 217–233.
- Barbul A., Regan M.C. (1993): Biology of wound healing. In: Fischer J.A. (ed.): *Surgical Basic Science*. Mosby Yearbook, St. Louis. 68–88.
- Barnes P.J. (2006): How corticosteroids control inflammation: Quintiles Prize Lecture 2005. *British Journal of Pharmacology*, 148, 245–254.
- Beck L.S., DeGuzman L., Lee W.P., Xu Y., Siegel M.W., Amento E.P. (1993): One systemic administration of transforming growth factor-beta 1 reverses age- or glucocorticoid-impaired wound healing. *Journal of Clinical Investigation*, 92, 2841–2849.
- Boothe H.W. (1998): Selecting suture materials for small animal surgery. *Compendium on Continuing Education for the Practicing Veterinarian*, 20, 155–162.
- Chedid M., Hoyle J.R., Csaky K.G., Rubin J.S. (1996): Glucocorticoids inhibit keratinocyte growth factor production in primary dermal fibroblasts. *Endocrinology*, 137, 2232–2237.
- Cotran R.S. (1999): Tissue repair: cellular growth, fibrosis and wound healing. In: Cotran R.S., Kumar V., Collins T. (eds.): *Robbins Pathologic Basis of Disease*. 6th ed. WB Saunders Co., Philadelphia, London, New York, St. Louis, Sydney, Toronto. 89–112.
- Davidson J.M. (1998): Animal models for wound repair. *Archives of Dermatological Research*, 290, S1–11.
- do Nascimento P.M., Pinheiro A.L., Salgado M.A., Ramalho L.M. (2004): A preliminary report on the effect of laser therapy on the healing of cutaneous surgical wounds as a consequence of an inversely proportional relationship between wavelength and intensity: histological study in rats. *Photomedicine and Laser Surgery*, 22, 513–518.
- Dorsett-Martin W.A. (2004): Rat models of skin wound healing: A review. *Wound Repair and Regeneration*, 12, 591–599.
- Dovi J.V., He L.K., DiPietro L.A. (2003): Accelerated wound closure in neutrophil-depleted mice. *Journal of Leukocytes Biology*, 73, 448–455.
- Frank S., Madlener M., Werner S. (1996): Transforming growth factors beta1, beta2, and beta3 and their receptors are differentially regulated during normal and impaired wound healing. *Journal of Biological Chemistry*, 271, 10188–10193.
- Gal P., Toporcer T., Vidinsky B., Mokry M., Novotny M., Kilik R., Smetana K. Jr., Gal T., Sabo J. (2006): Early changes in the tensile strength and morphology of primary sutured skin wounds in rats. *Folia Biologica (Prague)*, 52, 109–115.
- Gottrup F., Agren M.S., Karlsmark T. (2000): Models for use in wound healing research: A survey focusing on *in vitro* and *in vivo* adult soft tissue. *Wound Repair and Regeneration*, 8, 81–82.
- Hori Y., Hu D.E., Yasui K., Smither R.L., Gresham G.A., Fan T.P. (1996): Differential effects of angiostatic steroids and dexamethasone on angiogenesis and cytokine levels in rat sponge implants. *British Journal of Pharmacology*, 118, 1584–1591.
- Leibovich S.J., Ross R. (1975): The role of the macrophage in wound repair. A study with hydrocortisone and antimacrophage serum. *American Journal of Pathology*, 78, 71–100.
- Motlik J., Klima J., Dvorankova B., Smetana K. Jr. (2007): Porcine epidermal stem cells as a biomedical model for wound healing and normal/malignant epithelial cell propagation. *Theriogenology*, 67, 105–111.
- Pessoa E.S., Melhado R.M., Theodoro L.H., Garcia V.G. (2004): A histologic assessment of the influence of low-intensity laser therapy on wound healing in steroid-treated animals. *Photomedicine and Laser Surgery*, 22, 199–204.
- Spollett G.R. (1998): Preventing amputations in the diabetic population. *Nursing Clinics of North America*, 33, 629–641.
- Vidinsky B., Gal P., Toporcer T., Longauer F., Lenhardt L., Bobrov N., Sabo J. (2006): Histological study of the first seven days of skin wound healing in rats. *Acta Veterinaria Brno*, 75, 197–202.
- Wetzler C., Kampfer H., Stallmeyer B., Pfeilschifter J., Frank S. (2000): Large and sustained induction of chemokines during impaired wound healing in the genetically diabetic mouse: prolonged persistence of neutrophils and macrophages during the late phase of repair. *Journal of Investigative Dermatology*, 115, 245–253.

Received: 2008–03–15

Accepted after corrections: 2008–12–04

Corresponding Author:

Assoc. Prof. Ludovit Lenhardt, D.V.M., Ph.D., University of Veterinary Medicine in Kosice, Department of Pathological Anatomy, Komenskeho 73, 041 81 Kosice, Slovak Republic
Tel. +421 915 984 706, e-mail: lenhardt@uvm.sk