

Simultaneous Sinus Floor Elevation and Implant Placement Using Leukocyte- and Platelet-Rich Fibrin as a Sole Graft Material

Bo Molemans, DDS¹/Simone Cortellini, DDS¹/Reinhilde Jacobs, Prof Dr, DDS, PhD²/
Wim Teughels, Prof Dr, DDS, PhD¹/Nelson Pinto, DDS³/Marc Quirynen, Prof Dr, DDS, PhD¹

Purpose: Sinus floor elevation (SFE) and simultaneous implant placement is predictable and reproducible. However, the graft material for the antral cavity remains a topic of debate. Considering the high osteogenic potential of the sinus membrane, most graft materials are generally accepted. This study aimed to assess the outcome of simultaneous SFE and implant placement, using leukocyte- and platelet-rich fibrin (L-PRF) as a sole graft material. **Materials and Methods:** This study was designed as a single cohort prospective study. Clinical and radiographic measurements (cone beam computed tomography [CBCT]) were performed immediately after implant placement and at abutment connection (6 months later). The amount of newly formed bone was linearly recorded on cross-sectional images. Four measurements (mesial, distal, buccal, palatal) were registered with the axis of the implant as reference. **Results:** Six lateral and 22 transalveolar SFEs were performed in 26 patients with simultaneous implant placement. Six months after surgery, 27/29 implants were clinically integrated. The mean vertical bone gain was 3.4 ± 1.2 mm and 5.4 ± 1.5 mm for transalveolar SFE and lateral SFE, respectively. The level of the new sinus floor was in all cases in continuation with the apex of the implant, and the peri-implant crestal bone height was stable. **Conclusion:** L-PRF as a sole graft material during simultaneous SFE and implant placement proved to be a practical, safe, and economical subsinus graft material, resulting in natural bone formation. *INT J ORAL MAXILLOFAC IMPLANTS* 2019;34:1195–1201. doi: 10.11607/jomi.7371

Keywords: bioactive growth factors, bone graft, bone substitute, leucocyte and platelet rich fibrin, sinus lift, surgery

Even though the resorption of the alveolar ridge after tooth extraction can partially be overcome by ridge preservation techniques, insufficient vertical bone height in the posterior maxilla is often a challenge in implant surgery.¹ The most common causes

of loss in bone height in the maxilla are pneumatization of the sinus, ridge resorption after extraction, and periodontal diseases.^{2,3} To overcome this lack in vertical bone height, either a sinus floor elevation (SFE), a guided bone regeneration, or an onlay graft can be performed. The first description of the use of a SFE was by Boyne and James.⁴ They proposed the lateral window sinus floor elevation (LSFE) based on the Caldwell-Luc sinus revision and autogenous bone as graft material. Since the first SFE, different techniques and graft materials have been proposed. In 1986, Tatum Jr proposed the transalveolar sinus floor elevation (TSFE) in order to reduce postoperative pain and discomfort.⁵ Summers modified this TSFE in 1994.⁶ The technique of choice depends mainly on the residual bone height (RBH), the anatomy of the sinus floor, and the anatomy of the lateral wall of the sinus including the course of the posterior superior alveolar artery.⁷ Both techniques show similar results,⁸ even though the LSFE is often applied in conditions with less RBH. The long-term success rate of SFE is superior to that of onlay grafts in the maxilla.⁹

¹Department of Oral Health Sciences, Department of Periodontology, KU Leuven & University Hospitals Leuven, Leuven, Belgium.

²OMFS-Impath Research Group; Department of Oral & Maxillofacial Surgery, University Hospitals, KU Leuven, Leuven, Belgium.

³Department of Oral Implantology, University De Los Andes, Santiago, Chile.

Correspondence to: Dr Bo Molemans, Catholic University Leuven, UZ St. Raphael, Department of Periodontology, Kapucijnenvoer 33, B-3000 Leuven, Belgium.
Email: bo.molemans@kuleuven.be

Submitted September 23, 2018; accepted April 5, 2019.

©2019 by Quintessence Publishing Co Inc.

Careful visualization of septa in the sinus, using cone beam computed tomography (CBCT), is important to prevent complications.¹⁰ The presence of septa in the lateral wall of the sinus may complicate the procedure of a LSFE and could be an indication for a different technique or a procedure aiming at preventing contact with the septum. The course and diameter of the posterior superior alveolar artery has to be taken into account. A rupture of this artery could lead to difficult-to-control bleeding because the artery is located inside the bone of the lateral wall of the sinus.¹¹ Therefore, a crestal course of the artery should be interpreted as a potential contraindication for a LSFE.

Ever since the first SFE, there has been a quest for safe and less-invasive graft materials to replace autogenous bone from the oral cavity as described by Boyne and James.⁴ Because the sinus membrane has a high osteogenic potential, most graft materials result in bone gain.^{12–14} Even without a graft material, it is possible to perform a SFE and reach sufficient bone formation and implant survival.^{15–17} Some authors, however, report that without graft material, bone formation might be limited and the implant apices could be enmeshed in the sinus membrane.¹⁸ As was shown by Tajima et al¹⁹ and Toffler et al,²⁰ the use of L-PRF as a sole graft material for SFE and simultaneous implant placement can be successful. Moreover, this gain in bone height stays stable up to 6 years.²¹ However, a recent systematic review showed that studies on this subject are heterogenous and that more studies are needed.²² L-PRF might just be the perfect graft material because it is autogenous, minimally invasive, economical, and easy to apply. This study aims to assess the outcome of simultaneous SFE and implant placement, using L-PRF as a sole graft material.

MATERIALS AND METHODS

This study was designed as a case series, single cohort prospective study. The study protocol was approved by the Ethical Committee of the KU Leuven (reference S58612, UZ Leuven University Hospitals, Belgium) and was in accordance with the Helsinki Declaration of 1975, and revised in 2008.

Study Design and Patient Selection

The patients selected for this study were in need of SFE and simultaneous implant placement. In all cases, L-PRF has been used as the sole graft material. An informed consent form had to be signed by the patients, and they had to be able to understand the essence of the proposed surgery. The exclusion criteria were as follows: history of malignancy, current or previous use of bisphosphonates, use of corticosteroids, uncontrolled

diabetes, untreated periodontal disease, history of radiation on the head and neck region, history of metabolic bone disease, and psychiatric disorders.

The treatments were performed at the Department of Periodontology, Catholic University Leuven from 2015 to 2016. A presurgical CBCT was taken to estimate the RBH from the alveolar crest to the sinus floor.

Patient Allocation

Either the LSFE or TSFE treatment option was chosen based on the RBH, the anatomy of the sinus floor, and the anatomy of the lateral wall of the sinus. If possible, a TSFE was preferred over a LSFE. Whenever the RBH was < 5 mm or the course of the sinus floor was oblique, LSFE was the treatment of choice.

Preparation of the L-PRF

Preceding surgery, a venepuncture was performed. Eight plastic sterile 9-mL tubes without anticoagulant were drawn with venous blood from median basilica vein, median cubital vein, or median cephalic vein. Preparation of the L-PRF clots and membranes was performed as described by Choukroun and coworkers.²³ Briefly, within 60 seconds after blood was drawn, the tubes were centrifuged at 408 g RCF for 12 minutes using a tabletop centrifuge (IntraSpin, IntraLock). Following centrifugation, L-PRF clots were removed from the tube and separated from the red element phase at the base with pliers and gently compressed into membranes using a metal rack and a metal plate (Xpression kit, IntraLock). Only these L-PRF membranes were used to graft the sinus floor.

Surgical Technique: Transalveolar Sinus Elevation

All SFEs were executed in a sterile environment and under local anesthesia. The TSFE procedures were performed as follows: after crestal incision, including the adjacent teeth, a mucoperiosteal flap was elevated. Preparation of the osteotomy was executed as prescribed by the implant manufacturer guidelines (Astra EV, Dentsply Implants, Astra Tech), keeping a safe distance of approximately 1 mm from the sinus cavity to prevent perforation. Afterward, a L-PRF membrane was inserted into the osteotomy to act as a cushion between the osteotome and the sinus floor. Elevation of the sinus membrane to the desired height was performed by gently tapping osteotomes with a hand mallet. By simply applying L-PRF membranes in the osteotomy and inserting them into the sinus using the osteotome, the subsinus cavity was grafted. Once the L-PRF membranes were inserted, the implant could be placed and either a cover screw or an abutment was connected.

Surgical Technique: Lateral Window Sinus Elevation

When a TSFE was not possible due to previous mentioned criteria, a LSFE was performed. Execution of the LSFE procedures occurred using the following protocol: after crestal incision, with one or two releasing incisions, the lateral wall of the maxillary sinus was visualized after raising a mucoperiosteal flap. Preparation of the lateral window was done using Piezosurgery (Acteon, Satelec, Piezotome II). When the bony window was prepared, it was either removed or pushed into the sinus (trapped door technique) with the sinus membrane, following separation of the sinus membrane from the inner maxillary sinus walls with hand instruments. After the membrane was sufficiently elevated, preparation of the implant osteotomy, as prescribed by the implant manufacturer guidelines (Astra EV, Dentsply Implants, Astra Tech), was performed. Care must be taken not to harm the sinus membrane with the implant drills when perforating the sinus floor. Thereafter, L-PRF membranes (usually at least 5 L-PRF membranes) were placed against the palatal side of the sinus and directly underneath the sinus membrane to protect it from the implant when inserted. Consequently, the implant was inserted and either a cover screw or an abutment placed. On the buccal side of the implant, additional L-PRF membranes were added to fill the remnant space in the sinus. When removed, the bony window was repositioned over the window and a double layer of L-PRF membranes were used to cover the lateral osteotomy. Sutures (Prolene 4.0 or Vicryl 4.0, Ethicon, Johnson & Johnson) were placed and removed after 10 to 14 days.

Postoperative Management

All patients were advised to take paracetamol 1,000 mg 4/day and/or ibuprofen 600 mg 3/day if necessary. Also, a nasal spray containing corticosteroids (Nasonex 50 µg, mometasone furoate) to be used once a day, for 7 days, was prescribed. Brushing at the treated site was forbidden, and rinsing with an antiseptic mouthrinse twice a day (PerioAid Spray 0.12%, DentaAid) was advised until suture removal.

Outcome Assessment

Clinical and radiographic follow-up on CBCT (NewTom, QR s.r.l.) was performed at the time of implant placement and at abutment connection 6 months later. Measurements of the RBH and the newly formed bone were done to an accuracy of 0.1 mm using Impax 6 (AGFA Healthcare). The RBH (at the day of surgery) as well as the bone gain were measured at four locations (mesial, distal, buccal, and palatal) parallel to the long axis of the implant using the center of the implant as a reference. Resonance frequency analysis (RFA) was

Table 1 Patient Demographics

	Total	LSFE	TSFE
Sex			
Men	14	3	12
Women	12	3	10
Age			
Mean ± SD	55 ± 10.1	56 ± 9.5	53 ± 10
Minimum	38	41	38
Maximum	78	68	78
Smokers			
	0	0	0
Previous periodontal treatment			
	6	2	4
Implant Astra EV			
8 mm	2	0	2
9 mm	16	4	12
11 mm	11	3	8

performed (Osstell system, Osstell) to measure the implant stability quotient (ISQ values) at implant placement and 6 months later at abutment connection.

Statistical Analysis

For each of the four locations per implant, bone gain was analyzed using S-plus 8.0 for Linux. Boxplots, functions, mean, standard deviation, minimum, and maximum were calculated.

RESULTS

Patient Demographics

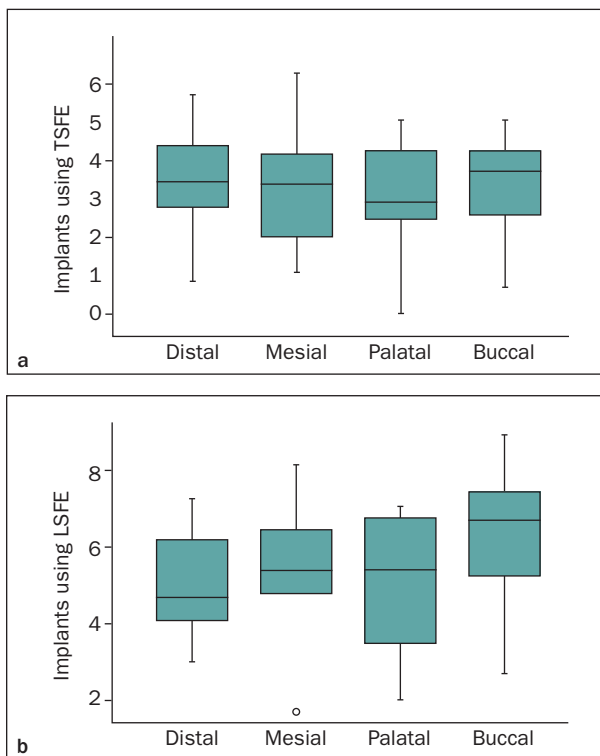
A total of 26 patients with 28 SFEs were enrolled, and 29 implants were simultaneously placed. Of those 28 SFEs, 22 were performed using the TSFE and 6 using the LSFE approach. Of the 29 implants, 22 were placed using the TSFE and 7 using the LSFE approach. The interventions were performed by second- and third-year postgraduate students in periodontology. All of the implants were Astra EV (Dentsply Implants, Astra Tech). The mean age of the patients was 55 years and ranged from 38 to 78. Fourteen (54%) of the 26 patients were men (Table 1). None of the patients declared smoking at the time of the surgery. All patients had a periodontally stable situation even though 6 (23%) of 26 patients had a history of periodontitis. In all cases, L-PRF membranes were used as the sole graft material.

Implant Outcome

The implant length ranged from 8 to 11 mm. Mean implant length for the TSFE was 9.61 ± 1.02 mm and for the LSFE 10 ± 1 mm. The implant diameter ranged

Table 2 Mean Bone Height (mm) at Respective Sites at Implant Insertion (Residual) and After 6 Months at Abutment Connection (After)

Site	Timing	n = 20 implants using TSFE		n = 7 implants using LSFE	
		Mean	SD	Mean	SD
Mesial	Residual	6.2	1.8	4.3	2.6
	After	9.6	1.6	9.8	1.5
	Δ	3.3	1.4	5.5	2.0
Distal	Residual	5.5	1.6	4.4	1.3
	After	9.1	1.7	9.5	1.7
	Δ	3.6	1.4	5.1	1.4
Buccal	Residual	6.5	1.6	4.5	2.0
	After	9.9	1.6	10.7	1.8
	Δ	3.4	1.2	6.2	2.0
Palatal	Residual	6.3	1.6	5.2	1.9
	After	9.6	1.4	10.0	1.0
	Δ	3.2	1.3	4.9	1.9

**Fig 1** Boxplot of the mean gain in bone height in millimeters at the respective sites 6 months after implant insertion at abutment connection.

from 4.2 to 4.8 mm. The ISQ values at abutment connection had to be above 65 to reach survival. Of 29 inserted implants, two implants placed with the TSFE did not osseointegrate and were removed. Consequently, 27 implants were included in the statistical analysis.

Outcome of SFE

Mean RBH was 6.2 ± 1.5 mm and 4.6 ± 1.8 mm, respectively, for the TSFE and the LSFE. The alveolar ridge was always wide enough to place an implant with a diameter of at least 4.2 mm. Mean bone gain was 3.4 ± 1.2 mm and 5.4 ± 1.5 mm, respectively, for the TSFE and the LSFE. Table 2 and Fig 1 show the mean bone height at the respective sites at implant insertion and after 6 months at abutment connection. The level of the newly formed sinus floor was in all cases in continuation with the apex of the implant, and the peri-implant crestal bone was stable. The CBCT directly postoperatively showed the apices of the implants in the sinus with a wide border of “soft tissue” around them and in the case of a LSFE a radiolucent area at the location of the lateral window. CBCT after 6 months at abutment connection showed bone formation around the apices and an intact lateral sinus wall (Fig 2).

DISCUSSION

The objective of this study was to assess the outcome of simultaneous SFE and implant placement, using L-PRF as a sole graft material. This case series demonstrates that this technique results in natural bone formation with the level of the new sinus floor in all cases in continuation with the apex of the implant and stable peri-implant bone level.

The reported bone gain and success rates using either the TSFE or the LSFE are comparable with similar studies such as the studies from Tajima et al¹⁹ and Toffler et al.²⁰ Those studies reported a mean bone gain of 3.4 mm and 7.5 mm, respectively, and the level of the newly formed sinus floor was in all cases in continuation with the apex of the implant. Also, they showed that the peri-implant crestal bone was stable, and success rates ranged from 97.8% to 100%, respectively.

A quest for safe, economical, and practical graft materials pushes research to look for alternatives. Since the first SFE,⁴ many graft materials have successfully been proposed. However, many of these graft materials are expensive, invasive, and require extensive treatment time. Conversely, even without graft material, successful results have been reported.^{15–17} In those studies, the gain in bone height relies on the tenting effect of

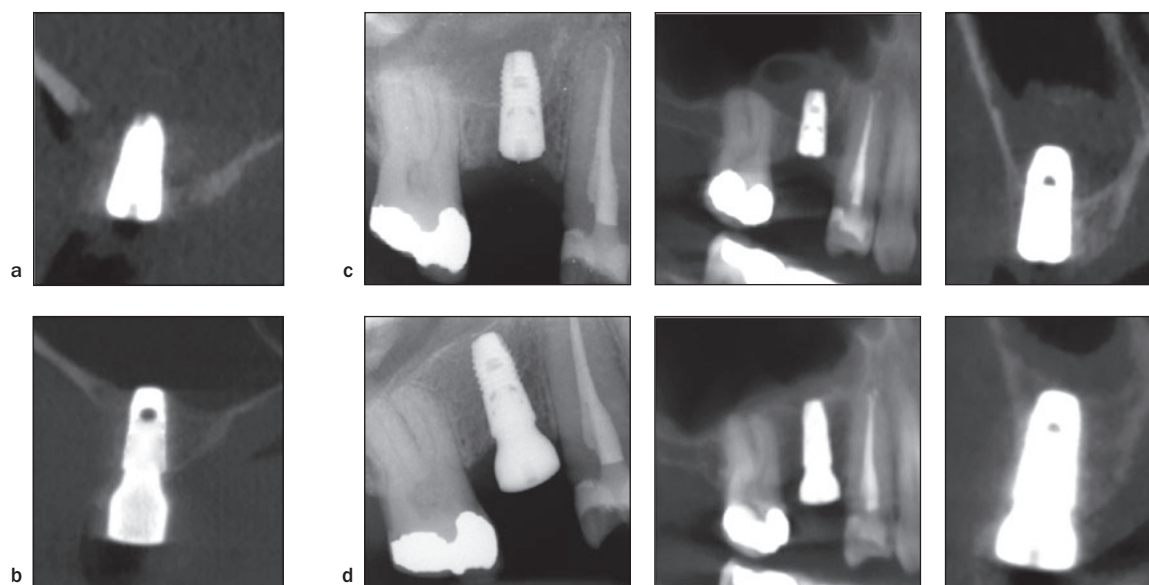


Fig 2 Cross-sectional CBCT slices and periapical radiographs. (a) Directly after implant insertion using the LSFE. (b) Six months after LSFE at abutment connection. (c) Directly after implant insertion using the TSFE. (d) Six months after TSFE at abutment connection.

the implants on the sinus membrane.²⁴ Because L-PRF is a compressible graft material, this tenting effect of the implants is necessary to resist the pneumatizing effect of the sinus. Some authors, however, report that without graft material, bone formation might be limited and the implant apices could be enmeshed in the sinus membrane.¹⁸ The number of L-PRF membranes needed depended on the desired gain in bone height; usually, between three and five were used. Sufficient grafting is important since it is known that the grafted volume using both the TSFE and LSFE, with the use of deproteinized bovine bone matrix and L-PRF as graft material, decreases 23.13% and 24.55%, respectively, over a 6-week period.²⁵

The technique of choice, either transalveolar or lateral, depends mainly on the RBH, the anatomy of the sinus floor, and the anatomy of the lateral wall of the sinus including the course of the posterior superior alveolar artery. The LSFE was the first described SFE technique and can be seen as the gold standard.²⁶ Both techniques show similar results⁸ and better long-term success compared with onlay grafts in the maxilla.⁹ According to certain studies, a TSFE is preferred since it is less invasive, faster, and less prone to complications compared with the LSFE.^{27,28} In this study, all failed implants came from the TSFE group. One of the possible

reasons for nonintegration of the implant might be a perforation of the sinus membrane. Using the TSFE, perforations are difficult to detect unless they are quite large.²⁹ Moreover, it is known that osteotome-mediated SFE causes an existing perforation to rupture even further.³⁰ This is in sharp contrast to the LSFE, where greater per-operative visibility, further ease in complication management, and the possibility to graft larger volumes are its greatest advantages. In one patient, a rupture of the sinus membrane occurred during LSFE; however, placing a L-PRF membrane over it treated the rupture. Once the L-PRF membrane was in place, the sinus membrane would again go up and down during breathing. The procedure was continued in the conception that L-PRF could provide protection against further rupturing of the sinus membrane and would aid the wound healing of the perforation.³¹ An oblique course of the sinus floor complicates the use of an osteotome to elevate the sinus floor and could increase the chance of perforation due to increased tearing forces on a small surface.³² Consequently, this was an indication for a LSFE. Successful TSFEs have been reported in cases with < 5 mm RBH.³³ However, since in this study the interventions were done by postgraduate students in periodontology, a RBH of 5 mm was taken as the minimum height to perform a predictable

and safe TSFE with osteotomes, as has been advised in the literature.^{8,34} Because of the preparation of the lateral osteotomy during a LSFE, certain anatomical structures have to be taken into account. Visualization of septa in the sinus, using CBCT, is important to prevent complications.¹⁰ The presence of septa in the lateral wall of the sinus may complicate the procedure of a LSFE and could be an indication for a different technique or a procedure aiming at avoiding the septum. The course and diameter of the posterior superior alveolar artery, a branch of the infraorbital artery, has to be taken into account.³⁵ A rupture of this artery should be avoided since it could lead to difficult-to-control bleeding because the artery is located inside the bone of the lateral wall of the sinus.¹¹ Therefore, a crestal course of the artery should be interpreted as a potential contraindication for a LSFE. In order to cover the lateral osteotomy, the bony window, if removed, was repositioned over the window and a double layer of L-PRF membranes was used to seal it.³⁶

Another explanation for the loss of two implants might be the lack of experience of the different surgeons. All SFEs were performed by surgeons in a postgraduate training program. Like with any other type of surgery, practice makes perfect, and thus, the lack of experience of the postgraduate students could have played a role in the outcome. The osteotomy was prepared to a minimal diameter of 4 mm since this has certain advantages. First, a wider diameter reduces the tear forces on the sinus membrane during elevation of the sinus floor using the osteotome compared with a smaller diameter.³² Another advantage of a wider-diameter osteotomy is the improved ease of insertion of the L-PRF membranes into the sinus.

Because of rising bacterial resistance against antibiotics and no clear evidence in the literature to support the use of antibiotic prophylaxis in conjunction with SFE, no systemic or local antibiotics were standardly prescribed. Since L-PRF is an autogenous graft material in a sterile environment, antibiotics might be unnecessary. Besides, as stated by Lund et al in 2015, the reduction of implant loss caused by antibiotic prophylaxis in healthy patients and uncomplicated implant placement is only 2%.³⁷ However, in the event of a perforation, bacteria from the sinus cavity could have caused an infection around the implant and thus prevented proper healing. In this light, one could consider prescribing a prophylactic dose of systemic or local³⁸ antibiotics when performing a SFE. Further research is necessary; in particular, a randomized controlled trial, preferably split mouth between L-PRF and other graft materials or no graft material, would be interesting.

CONCLUSIONS

L-PRF as a sole graft material during simultaneous SFE and implant placement proved to be a practical, safe, and economical subsinus graft material, resulting in natural bone formation.

ACKNOWLEDGMENTS

The authors would like to acknowledge Wim Coucke for his support in the statistical analysis. All (co)-authors report no conflicts of interest related to this study. The authors would like to acknowledge Intra-Lock International Inc. for the Chair in Optimized Osseointegration at Leuven University.

REFERENCES

1. Tan WL, Wong TL, Wong MC, Lang NP. A systematic review of post-extraction alveolar hard and soft tissue dimensional changes in humans. *Clin Oral Implants Res* 2012;23(suppl 5):1–21.
2. Pietrokovski J, Massler M. Alveolar ridge resorption following tooth extraction. *J Prosthet Dent* 1967;17:21–27.
3. Wagner F, Dvorak G, Nemeč S, Pietschmann P, Figl M, Seemann R. A principal components analysis: How pneumatization and edentulism contribute to maxillary atrophy. *Oral Dis* 2017;23:55–61.
4. Boyne PJ, James RA. Grafting of the maxillary sinus floor with autogenous marrow and bone. *J Oral Surg* 1980;38:613–616.
5. Tatum H Jr. Maxillary and sinus implant reconstructions. *Dent Clin North Am* 1986;30:207–229.
6. Summers RB. A new concept in maxillary implant surgery: The osteotome technique. *Compend* 1994;15:152, 154–156, 158 passim; quiz 162.
7. Temmerman A, Hertelé S, Teughels W, Dekeyser C, Jacobs R, Quirynen M. Are panoramic images reliable in planning sinus augmentation procedures? *Clin Oral Implants Res* 2011;22:189–194.
8. Del Fabbro M, Corbella S, Weinstein T, Ceresoli V, Taschieri S. Implant survival rates after osteotome-mediated maxillary sinus augmentation: A systematic review. *Clin Implant Dent Relat Res* 2012;14(suppl 1):e159–e168.
9. Wiltfang J, Schultze-Mosgau S, Nkenke E, Thorwarth M, Neukam FW, Schlegel KA. Onlay augmentation versus sinuslift procedure in the treatment of the severely resorbed maxilla: A 5-year comparative longitudinal study. *Int J Oral Maxillofac Surg* 2005;34:885–889.
10. Dragan E, Odri GA, Melian G, Haba D, Olszewski R. Three-dimensional evaluation of maxillary sinus septa for implant placement. *Med Sci Monit* 2017;23:1394–1400.
11. Varela-Centelles P, Loira-Gago M, Seoane-Romero JM, Takkouche B, Monteiro L, Seoane J. Detection of the posterior superior alveolar artery in the lateral sinus wall using computed tomography/cone beam computed tomography: A prevalence meta-analysis study and systematic review. *Int J Oral Maxillofac Surg* 2015;44:1405–1410.
12. Geurs NC, Wang IC, Shulman LB, Jeffcoat MK. Retrospective radiographic analysis of sinus graft and implant placement procedures from the Academy of Osseointegration Consensus Conference on Sinus Grafts. *Int J Periodontics Restorative Dent* 2001;21:517–523.
13. Shulman LB, Jensen OT. Sinus graft consensus conference. Introduction. *Int J Oral Maxillofac Implants* 1998;13(suppl):5–6.
14. Chen MH, Shi JY. Clinical and radiological outcomes of implants in osteotome sinus floor elevation with and without grafting: A systematic review and a meta-analysis. *J Prosthodont* 2018;27:394–401.
15. Lundgren S, Cricchio G, Palma VC, Salata LA, Sennerby L. Sinus membrane elevation and simultaneous insertion of dental implants: A new surgical technique in maxillary sinus floor augmentation. *Periodontol* 2000 2008;47:193–205.

16. Lundgren S, Cricchio G, Hallman M, Jungner M, Rasmusson L, Sennerby L. Sinus floor elevation procedures to enable implant placement and integration: Techniques, biological aspects and clinical outcomes. *Periodontol* 2000 2017;73:103–120.
17. Moraschini V, Uzeda MG, Sartoretto SC, Calasans-Maia MD. Maxillary sinus floor elevation with simultaneous implant placement without grafting materials: A systematic review and meta-analysis. *Int J Oral Maxillofac Surg* 2017;46:636–647.
18. Sul SH, Choi BH, Li J, Jeong SM, Xuan F. Effects of sinus membrane elevation on bone formation around implants placed in the maxillary sinus cavity: An experimental study. *Oral Surg Oral Med Oral Pathol Oral Radiol Endod* 2008;105:684–687.
19. Tajima N, Ohba S, Sawase T, Asahina I. Evaluation of sinus floor augmentation with simultaneous implant placement using platelet-rich fibrin as sole grafting material. *Int J Oral Maxillofac Implants* 2013;28:77–83.
20. Toffler M, Toscano N, Holtzclaw D. Osteotome-mediated sinus floor elevation using only platelet-rich fibrin: An early report on 110 patients. *Implant Dent* 2010;19:447–456.
21. Simonpieri A, Choukroun J, Del Corso M, Sammartino G, Dohan Ehrenfest DM. Simultaneous sinus-lift and implantation using microthreaded implants and leukocyte- and platelet-rich fibrin as sole grafting material: A six-year experience. *Implant Dent* 2011;20:2–12.
22. Castro AB, Meschi N, Temmerman A, et al. Regenerative potential of leukocyte- and platelet-rich fibrin. Part B: Sinus floor elevation, alveolar ridge preservation and implant therapy. A systematic review. *J Clin Periodontol* 2017;44:225–234.
23. Choukroun J, Adda F, Schoeffler C, Vervelle A. An opportunity in perioimplantology: The PRF (In French). *Implantodontie* 2001;42:55–62.
24. Jung UW, Unursaikhan O, Park JY, Lee JS, Otgonbold J, Choi SH. Tenting effect of the elevated sinus membrane over an implant with adjunctive use of a hydroxyapatite-powdered collagen membrane in rabbits. *Clin Oral Implants Res* 2015;26:663–670.
25. Temmerman A, Van Dessel J, Cortellini S, Jacobs R, Teughels W, Quirynen M. Volumetric changes of grafted volumes and the Schneiderian membrane after transcrestal and lateral sinus floor elevation procedures: A clinical, pilot study. *J Clin Periodontol* 2017;44:660–671.
26. Del Fabbro M, Wallace SS, Testori T. Long-term implant survival in the grafted maxillary sinus: A systematic review. *Int J Periodontics Restorative Dent* 2013;33:773–783.
27. Tan WC, Lang NP, Zwahlen M, Pjetursson BE. A systematic review of the success of sinus floor elevation and survival of implants inserted in combination with sinus floor elevation. Part II: Transalveolar technique. *J Clin Periodontol* 2008;35(suppl):241–254.
28. Pjetursson BE, Tan WC, Zwahlen M, Lang NP. A systematic review of the success of sinus floor elevation and survival of implants inserted in combination with sinus floor elevation. *J Clin Periodontol* 2008;35(suppl):216–240.
29. Ferrigno N, Laureti M, Fanali S. Dental implants placement in conjunction with osteotome sinus floor elevation: A 12-year life-table analysis from a prospective study on 588 ITI implants. *Clin Oral Implants Res* 2006;17:194–205.
30. Jank S, Kurrek A, Wainwright M, Bek VE, Troedhan A. Rupture length of the sinus membrane after 1.2 mm puncture and surgical sinus elevation: An experimental animal cadaver study. *Oral Surg Oral Med Oral Pathol Oral Radiol Endod* 2011;112:568–572.
31. Diss A, Dohan DM, Mouhyi J, Mahler P. Osteotome sinus floor elevation using Choukroun's platelet-rich fibrin as grafting material: A 1-year prospective pilot study with microthreaded implants. *Oral Surg Oral Med Oral Pathol Oral Radiol Endod* 2008;105:572–579.
32. Troedhan A, Kurrek A, Wainwright M, Jank S. Schneiderian membrane detachment using transcrestal hydrodynamic ultrasonic cavitation sinus lift: A human cadaver head study and histologic analysis. *J Oral Maxillofac Surg* 2014;72:1503.e1–1503.e10.
33. Gonzalez S, Tuan MC, Ahn KM, Nowzari H. Crestal approach for maxillary sinus augmentation in patients with ≤ 4 mm of residual alveolar bone. *Clin Implant Dent Relat Res* 2014;16:827–835.
34. Wang HL, Katranji A. ABC sinus augmentation classification. *Int J Periodontics Restorative Dent* 2008;28:383–389.
35. Traxler H, Windisch A, Geyerhofer U, Surd R, Solar P, Firbas W. Arterial blood supply of the maxillary sinus. *Clin Anat* 1999;12:417–421.
36. Gassling V, Purcz N, Braesen JH, et al. Comparison of two different absorbable membranes for the coverage of lateral osteotomy sites in maxillary sinus augmentation: A preliminary study. *J Craniomaxillofac Surg* 2013;41:76–82.
37. Lund B, Hultin M, Tranaeus S, Naimi-Akbar A, Klinge B. Complex systematic review - Perioperative antibiotics in conjunction with dental implant placement. *Clin Oral Implants Res* 2015;26(suppl 11):1–14.
38. Choukroun J, Simonpieri A, Del Corso M, Mazor Z, Sammartino G, Dohan Ehrenfest DM. Controlling systematic perioperative anaerobic contamination during sinus-lift procedures by using metronidazole: An innovative approach. *Implant Dent* 2008;17:257–270.