

CASE REPORT

Shrinking lung syndrome in systemic lupus erythematosus*

CÍNTIA ANDRADE COSTA, DÁLVARO OLIVEIRA DE CASTRO JR.,
SÉRGIO JEZLER^(TE SBPT), MITTERMAYER SANTIAGO

Systemic lupus erythematosus (SLE) may involve the respiratory tract in several ways, such as through pleuritis, pneumonitis, interstitial disease or pulmonary hypertension. In rare cases, SLE patients present a syndrome characterized by dyspnea, chest pain and abnormalities in pulmonary function testing, although there may be no evidence of major parenchymal lung disease on computed tomography scans. This condition has come to be known as shrinking lung syndrome. We report a case that meets these diagnostic criteria, emphasizing the pathogenesis proposed, as well as the therapeutic options available.

Key words: Lupus Erythematosus/Systemic, Respiratory System, Shrinking Lung Syndrome

* Study carried out in the Rheumatology Department of the Hospital Santa Izabel (HSI)/Escola Bahiana de Medicina e Saúde Pública (EBMSP)

Correspondence to: Mittermayer Santiago. Núcleo de Reumatologia do Hospital Santa Izabel: Praça Almeida Couto 500, Nazaré, Salvador, Bahia. CEP 40000-000. E-mail: mitter@svn.com.br
Submitted: 12 May 2003. Accepted, after revision: 3 September 2003.

Abbreviations used in this paper:

SLE – Systemic lupus erythematosus
SLS – Shrinking lung syndrome

INTRODUCTION

Systemic lupus erythematosus (SLE) is a diffuse disease that affects conjunctive tissues and presents innumerable clinical manifestations. More than 50% of patients present respiratory involvement at some stage of the progression of the disease. It may affect the upper airways, pleura, parenchyma and pulmonary vessels. A rare manifestation of the disease is called shrinking lung syndrome (SLS), characterized by the dysfunction of respiratory muscles, especially the diaphragm, by mechanisms not yet well defined, resulting in dyspnea.¹

We report a case of SLE with respiratory manifestations, whose investigation led to a diagnosis of SLS. We discuss pathogenic, diagnostic, and therapeutic aspects of this syndrome. We also conducted a review of the literature on this topic.

CASE REPORT

A 36-year-old woman presented with arthralgia in her ankles, knees, wrists and hands. She also reported dyspnea upon exertion for about 6 years. She was submitted to tests and exams, which revealed slight left pleural effusion. She was given prednisone (20 mg/day) and chloroquine diphosphate (250 mg/day) because of the presumptive diagnosis of SLE. Later, when the corticosteroid dosage was decreased, she presented chest pain upon breathing, worsening of dyspnea, fever, and alopecia, and she was referred to our clinic. Physical examination revealed no fever, jaundice, cyanosis or lymph node enlargement, and the patient was breathing normally. Thoracic examination revealed normal chest expansion, vocal fremitus and reduced vesicular murmur at the base of the right hemithorax, but no corresponding breath sounds. No abdominal or cardiovascular abnormalities were found. Examination of the osteoarticular system revealed slight edema around the ankles. The patient was submitted to a thorough investigation that revealed a normal complete blood count, urea at 37 mg%, creatinine at 0.9 mg%, no abnormalities in the urine test, antinuclear factor by indirect immunofluorescence at 1/2560 with a homogeneous pattern,

positive results for lens epithelial cells, negative results for native anti-DNA and rheumatoid factor, and normal results for C3 and C4. Testing for anticardiolipin antibodies using ELISA was negative, as was testing for anti-Ro/SSA antibodies using counter-electrophoresis. Chest X-ray revealed elevated hemidiaphragm, reduced lung fields, and laminar atelectasis (Figure 1). Atelectasis was confirmed by high-resolution computer tomography, which showed no interstitial involvement (Figure 2). Arterial blood gas tests were normal and spirometry revealed moderate restrictive ventilatory distress, with forced vital capacity of 58%, maximal inspiratory pressure at -40 cm H₂O and maximal expiratory pressure at $+60$ cm H₂O. Echocardiogram revealed mild pericardial effusion, mitral regurgitation and mild pulmonary hypertension (38 mmHg). The patient was treated with 20 mg of prednisone combined with pulse therapy cyclophosphamide (1 g/month) for 6 months. Although there was partial improvement of dyspnea, radiographic and spirometric characteristics remained unchanged (Table 1).

DISCUSSION

The appearance of SLS is a very rare clinical condition that is classically described in patients diagnosed with SLE² and seldom seen in patients suffering from other diseases³. It is characterized by dyspnea, chest pain upon deep breathing, and disproportionality between alterations seen in pulmonary function test results (which revealed restrictive, occasionally severe, respiratory distress) and radiographic findings (which showed only unilateral or bilateral elevated hemidiaphragm and an absence of parenchymal involvement). All of these characteristics were present in our patient, and a diagnosis of SLS was therefore made.

Using MEDLINE, Warrington et al.² reviewed data in the literature published between 1965 and 1977 and found 49 well-documented cases of SLE-related SLS. Mean age of patients was 40, and the proportion of females and males was 5.5 to 1. Curiously, 20% of the reported cases presented some evidence of myopathy. Using the same database, we reviewed the literature from 1977 until the present and identified another 11 cases of SLS in patients with SLE.^{1,4,5,6,7} If we include another case reported in a non-indexed journal⁸ and the present case, the total number of reported cases comes to 62.

The pathogenesis of SLS is under debate. Some suggest that it results primarily from a dysfunction of the diaphragm muscles⁹, but other authors do not accept this hypothesis¹⁰. Other hypotheses include diaphragmatic paralysis secondary to phrenic nerve injury⁶, diffuse fibrosis in the diaphragm¹¹ and limited chest wall expansion¹⁰. It has been proposed, although not very convincingly, that autoantibodies such as anti-phospholipids¹² and anti-Ro/SSA⁷ antibodies participate in SLS pathogenesis. In the present case, tests for these antibodies were negative.

Another complicating factor is that treatment for SLS has not been well defined. In the cases described in the literature, several pharmacological agents have been used to treat the condition. These include corticosteroids^{13,14}, immunosuppressants¹, inhaled beta-agonists (which have a positive inotropic on beta-receptors in the diaphragm muscle)¹⁵, xanthines¹⁶, and even digitalis (based on the argument that diaphragm responds to this drug similarly to the heart muscle)⁸.

In the present case, clinical improvement was achieved by increasing the prednisone dosage from 5 mg to 20 mg, although there was no improvement in spirometric or radiographic parameters. The use of cyclophosphamide was an attempt to revert pulmonary hypertension, as was suggested in a recent study¹⁷. As a matter of fact, a second echocardiogram performed after the sixth month of pulse therapy revealed no signs of pulmonary hypertension. Therefore, the clinical improvement seen may be attributable to the reduction in pulmonary hypertension and not to reversion of the SLS.

In conclusion, SLS, despite being rare, must be considered as a diagnostic possibility when patients diagnosed with SLE present dyspnea without heart insufficiency, anemia or diseases of the lung parenchyma. Although there is no specific treatment, the empirical use

of xanthines, beta-agonists, corticosteroids, or even immunosuppressants may be beneficial.

REFERENCES

1. Karim MY, Miranda LC, Tench CM, Gordon PA, D'cruz DP, Khamashta MA, Hughes GR. Presentation and prognosis of the shrinking lung syndrome in systemic lupus erythematosus. *Semin Arthritis Rheum* 2002;31(5):289-98.
2. Warrington KJ, Moder KG, Brutinel WM. The shrinking lungs syndrome in systemic lupus erythematosus. *Mayo Clin Proc* 2000;75(5):467-72
3. Tavoni A, Vitali C, Cirigliano G, Frigelli S, Stampacchia G, Bombardieri S Shrinking lung in primary Sjogren's syndrome. *Arthritis Rheum.* 2001;44(1):243-5.
4. Martusewicz-Boros M, Wiatr E, Plodziszewska M, Gawryluk D, Opoka L, Zaleska J. Lung involvement in systemic lupus erythematosus (SLE)—own experience. *Pneumonol Alergol Pol.* 2002;70(1-2):12-24.
5. Hawkins P, Davison AG, Dasgupta B, Moxham J. Diaphragm strength in acute systemic lupus erythematosus in a patient with paradoxical abdominal motion and reduced lung volumes. *Thorax* 2001;56(4):329-30
6. Hardy K, Herry I, Attali V, Cadranel J, Similowski T. Bilateral phrenic paralysis in a patient with systemic lupus erythematosus. *Chest* 2001;119(4):1274-7
7. Ishii M, Uda H, Yamagami T, Katada Y. Possible association of "shrinking lung" and anti-Ro/SSA antibody. *Arthritis Rheum* 2000;43(11):2612-3.
8. Medeiros, MR; Balthazar, AB; Camino, AM; Costallat, LTL; Bértolo, MB; Samara, AM: Síndrome dos pulmões encolhidos no lúpus eritematoso sistêmico: melhora clínica com o uso de digoxina via oral. *Rev Bras Reumatol.* 1996; 36:97-99.
9. Jacobelli S, Moreno R, Massardo L, Rivero S, Lisboa C. Inspiratory muscle dysfunction and unexplained dyspnea in systemic lupus erythematosus. *Arthritis Rheum.* 1985;28(7):781-8.
10. Laroche CM, Mulvey DA, Hawkins PN, Walport MJ, Strickland B, Moxham J, Green M. Diaphragm strength in the shrinking lung syndrome of systemic lupus erythematosus. *Q J Med.* 1989;71(265):429-39.
11. Rubin LA, Urowitz MB. Shrinking lung syndrome in SLE—a clinical pathologic study. *J Rheumatol* 1983;10(6):973-6.
12. Hoffbrand BI, Vianna J, Khamashta M, Hughes GR, Walters DV. Antiphospholipid antibodies and shrinking lungs in SLE. *Lupus* 1992;1(6):408
13. Walz-Leblanc BA, Urowitz MB, Gladman DD, Hanly PJ. The "shrinking lungs syndrome" in systemic lupus erythematosus—improvement with corticosteroid therapy. *J Rheumatol* 1992;19(12):1970-2
14. Fornis X, Font J, Montserrat JM, Ingelmo M. Functional abnormality of the diaphragm in the "shrinking lung" in systemic lupus erythematosus *Rev Clin Esp* 1993;193(4):176-8
15. Munoz-Rodriguez FJ, Font J, Badia JR, Miret C, Barbera JA, Cervera R, Ingelmo M. Shrinking lungs syndrome in systemic lupus erythematosus: improvement with inhaled beta-agonist therapy. *Lupus* 1997;6(4):412-4
16. Van Veen S, Peeters AJ, Sterk PJ, Breedveld FC. The "shrinking lung syndrome" in SLE, treatment with theophylline. *Clin Rheumatol* 1993;12(4):462-5
17. Tanaka E, Harigai M, Tanaka M, Kawaguchi Y, Hara M, Kamatani N. Pulmonary hypertension in systemic lupus erythematosus: evaluation of clinical characteristics and response to immunosuppressive treatment. *J Rheumatol.* 2002;29(2):282-7.

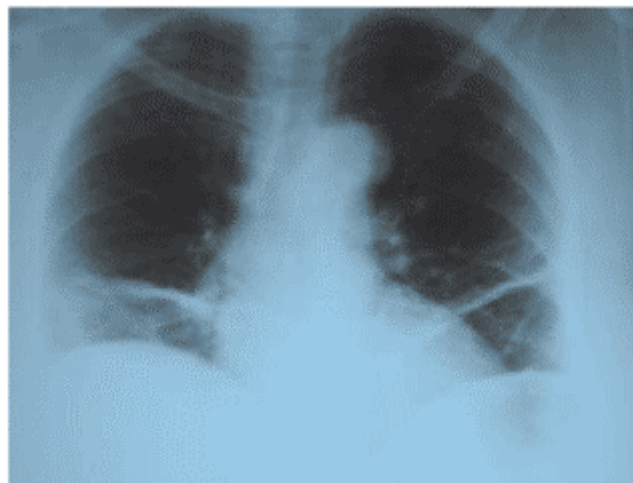


Figure 1. Shrinking Lung Syndrome: chest X-ray showing elevated hemidiaphragm and areas of atelectasis

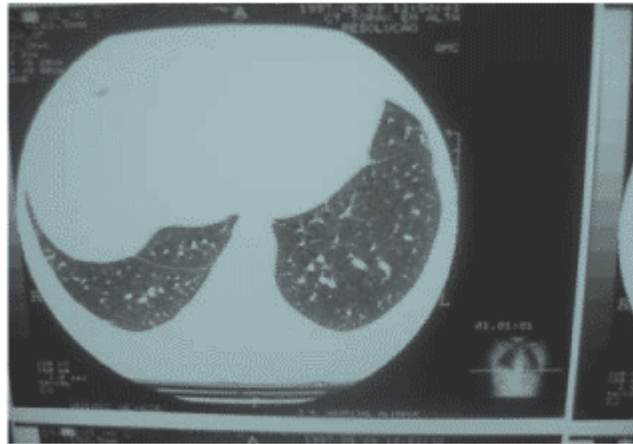


Figure 2. Shrinking Lung Syndrome: lower cross-sectional view from chest computed tomography revealing no evidence of interstitial alterations

TABLE 1
Evolution of pulmonary function (simple spirometry) before and after treatment

	Before	After
FVC (liters)	1.27	1.35
FVC (%)	56	58
FEV ₁ (liters)	1.13	1.25
FEV ₁ (%)	56	62
FEV ₁ /FVC (%)	88	92

FVC: forced vital capacity; FEV₁: forced expiratory volume in one second