

Single port access laparoscopic right hemicolectomy

BUCHER, Pascal, PUGIN, François, MOREL, Philippe

Abstract

BACKGROUND: Single port access (SPA) surgery is a rapidly evolving field as it combines some of the cosmetic advantage of the Natural Orifice Transluminal Endoscopic Surgery (NOTES) and allows performing surgical procedure with standard surgical instruments. We report in this paper a new technique of umbilical SPA right hemicolectomy with conventional surgical oncologic principle and technique of minimally invasive colectomy. **METHODS:** Preliminary experience with umbilical SPA right hemicolectomy in a patient with degenerated ascending colon polyp. **RESULTS:** Umbilical SPA right hemicolectomy was feasible with conventional laparoscopic instruments. Carcinologic surgical principle can be respected using this technique as pathological specimen had sufficient surgical margins (>10 cm) and lymph nodes (33). Operative time was 158 min. No peroperative or postoperative complications were recorded. **CONCLUSION:** SPA right hemicolectomy is feasible and safe when performed by experienced laparoscopic surgeons. SPA right hemicolectomy may have the advantage over NOTES approach to offer the safety of laparoscopic colectomy especially for [...]

Reference

BUCHER, Pascal, PUGIN, François, MOREL, Philippe. Single port access laparoscopic right hemicolectomy. *International journal of colorectal disease*, 2008, vol. 23, no. 10, p. 1013-6

DOI : 10.1007/s00384-008-0519-8

PMID : 18607608

Available at:

<http://archive-ouverte.unige.ch/unige:1081>

Disclaimer: layout of this document may differ from the published version.



UNIVERSITÉ
DE GENÈVE

Single port access laparoscopic right hemicolectomy

Pascal Bucher · François Pugin · Philippe Morel

Accepted: 5 June 2008 / Published online: 8 July 2008
© Springer-Verlag 2008

Abstract

Background Single port access (SPA) surgery is a rapidly evolving field as it combines some of the cosmetic advantage of the Natural Orifice Transluminal Endoscopic Surgery (NOTES) and allows performing surgical procedure with standard surgical instruments. We report in this paper a new technique of umbilical SPA right hemicolectomy with conventional surgical oncologic principle and technique of minimally invasive colectomy.

Methods Preliminary experience with umbilical SPA right hemicolectomy in a patient with degenerated ascending colon polyp.

Results Umbilical SPA right hemicolectomy was feasible with conventional laparoscopic instruments. Carcinologic surgical principle can be respected using this technique as pathological specimen had sufficient surgical margins (>10 cm) and lymph nodes (33). Operative time was 158 min. No peroperative or postoperative complications were recorded.

Conclusion SPA right hemicolectomy is feasible and safe when performed by experienced laparoscopic surgeons. SPA right hemicolectomy may have the advantage over NOTES approach to offer the safety of laparoscopic

colectomy especially for haemostasis and anastomosis. It has to be determined whether or not this approach would offer benefit to patients, except in cosmesis, compared to standard laparoscopic right hemicolectomy.

Keywords Single port access (SPA) · Colectomy · Laparoscopy · NOTES · Minimally invasive surgery · Technique · Scarless surgery

Introduction

Laparoscopic right hemicolectomy has been shown to ameliorate patient recovery compared to open approach while being a carcinologically safe option for cancer of the right colon [1–4]. Recently, multiple attempts to decrease parietal trauma and visible scar during laparoscopic colectomies have illustrated patient's satisfaction with these approaches [5–7]. These advantages are some of the fundamental of the Natural Orifice Transluminal Endoscopic Surgery (NOTES) approach. Recently, surveys have shown that patients would largely favour NOTES compared to standard laparoscopy, except if the risk of NOTES drastically outpassed those of the laparoscopic approach [8, 9]. This confirms the importance of cosmesis and body image trauma associated with surgical procedure and warrants us to look for a “scarless” surgical procedure.

Single port access (SPA) surgery is a rapidly evolving field [10]. SPA, as NOTES offer cosmetic advantage compared to standard multiple access laparoscopic procedure. SPA laparoscopy is look as a possible derivative of NOTES, and that umbilical SPA could be the route of choice for complex scarless laparoscopic procedure in the

P. Bucher · F. Pugin · P. Morel
Department of Surgery, University Hospital Geneva,
Geneva, Switzerland

P. Bucher (✉)
Visceral and Transplantation Surgery, Department of Surgery,
University Hospital Geneva,
24 rue Micheli-du-Crest,
1211 Geneva, Switzerland
e-mail: pascal.bucher@hcuge.ch

future [11, 12]. NOTES colectomy, at less non-hybrid procedure are far from clinical application [7, 13]. At this time, SPA has the advantage of a lower complexity than NOTES for clinical application as it allows the use of standard laparoscopic instruments [10, 14–17]. Its only complexity is represented by the necessity to operate with a low possibility of triangulation and off-axis vision, which is similar to NOTES until now [14, 18–21].

We report in this paper the first cases SPA right hemicolectomy complying with conventional surgical oncological principle and technique of minimally invasive colectomy.

Materials and methods

Case report

We report our preliminary experience of single port access right colectomy in an 81-year-old patient with degenerated ascending colon polyp not amenable to endoscopic approach. The patient was offered this approach after having given her informed consent. Through single port access right hemicolectomy, a 5-cm polyp with high-grade dysplasia was removed. Carcinologic surgical principle was respected using this technique and pathological specimen (38 cm) had sufficient surgical margins (>10 cm) and lymph nodes (33). Operative time was 158 min. No perioperative or postoperative complications were recorded. Normal low residue diet was started on day 1.

Surgical technique

Single port access (SPA) right hemicolectomy was performed using a surgical technique similar to standard laparoscopy with medial-to-lateral approach, except that it was conducted through a single umbilical port. A single 12-mm umbilical port (Endopath Xcel Trocar, Ethicon Endo-surgery, Spreitenbach, Switzerland) was placed through open approach. A 10-mm laparoscope (Ref: S26034AA; Richard Wolf GmbH, Knittlingen, Germany) with a 6-mm working channel was used. First, right colon suspension and exposition was achieved by placing trans-parietal stitches anchored to colon wall a 5-mm Johann grasper (Ref: CEV 9625–1B, MicroFrance, Saint Aubin le Monial, France), Fig. 1. In order to performed a medial-to-lateral approach the ileo-colic pedicle was exposed with a suspending trans-parietal stitch anchored to distal pedicle. Mesocolic dissection and ileo-colic pedicle isolation was achieved using a 5-mm laparoscopic monopolar hook dissector (Ref: 8384.423, Richard Wolf GmbH, Knittlingen, Germany), scissor (Ref: 3152, Microline PENTAX, Beverly, MA, USA), Ultracision Harmonic scalpel (Ethicon Endo-

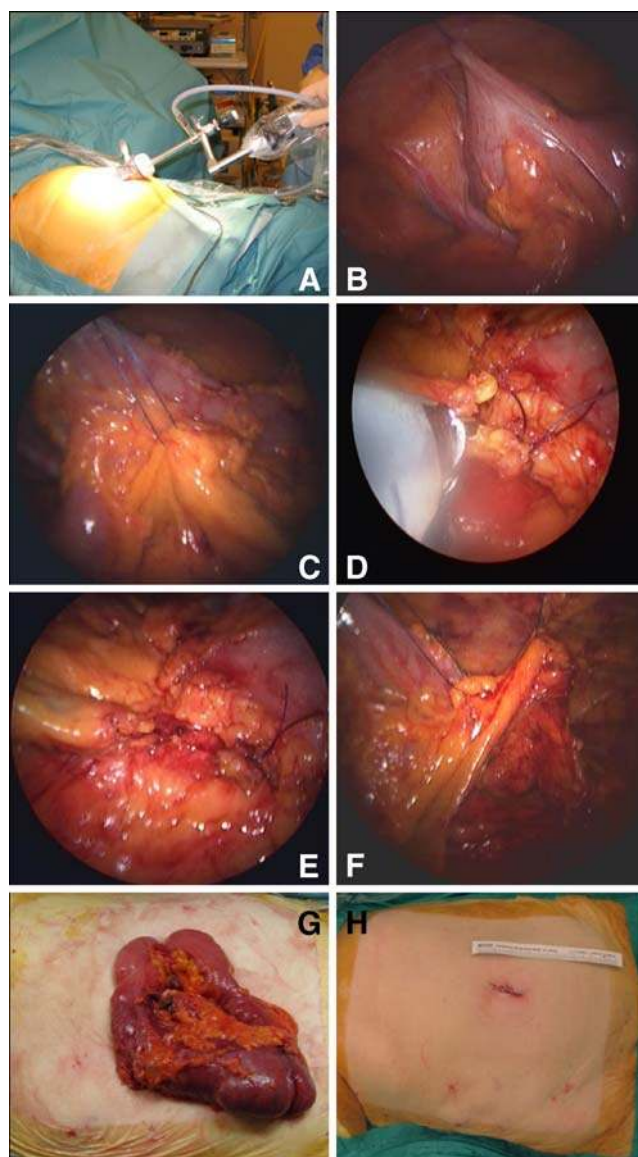


Fig. 1 Intra-operative views of single port access right hemicolectomy. **a** Operative installation. **b** Caecum suspension with trans-parietal stitch. **c** Ileo-colic vascular pedicle suspension through trans-parietal stitch. **d** Section of ileo-colic pedicle at its origin with harmonic scalpel after having tied proximally vascular pedicle. **e** Transected vascular pedicle and mesocolon. **f** Exposition of the retroperitoneal space through colon and mesocolon suspension with transparietal stitches for medial-to-lateral approach. **g** Specimen extraction through umbilical incision (resected specimen length was 38 cm). **h** Skin incision at the end of procedure

surgery, Spreitenbach, Switzerland) and right-angle dissector (Ref: 52155-07, Elmed Inc, Addison, IL, USA) were used. Vascular control was achieved by ligation through extra-corporeal knotting. Complete retroperitoneal, parietal peritoneal refection, omental and right-angle ligament dissection was performed using a hook dissector, a pair of scissors and a Harmonic scalpel. The specimen was exposed through

umbilical port, and extracorporeal anastomosis was completed using an endo-stapler. The operation resulted in a 3-cm umbilical incision.

Discussion

We describe a new surgical technique for single port access laparoscopic right oncologic hemicolectomy. Single umbilical port access right hemicolectomy was feasible using standard laparoscopic instruments and offers cosmetic advantage compared to standard laparoscopic approach. This surgical procedure only reproduced standard right colectomy, with adjunction of some artifacts, and seems to be safe and oncologically satisfying.

Umbilical SPA right hemicolectomy could be performed using standard straight laparoscopic instruments. This represents a safety concern, as the use of standard laparoscopic instruments enables to conform to standard surgical principle,; while for the NOTES procedure there is an urge for adapted instrumentation to be developed [7, 13, 14, 22, 23]. According to the present report, SPA right hemicolectomy could be performed using a medial-to-lateral approach with safe oncological results [1, 24].

Among the potential advantage of SPA right colectomy compared to standard laparoscopic colectomy, cosmesis is an important factor [3, 25]. However, postoperative pain and recovery could be improved by this approach [10, 26]. Moreover, the risk associated with port placement and the incidence of incisional hernia may be reduced to the use of a single access [26–29]. However, SPA right colectomy is a challenging procedure that merits technical improvement before being recognised as a standard and even valid approach. Future development of multiport single access will facilitate SPA approach, which would be of value for SPA right colectomy to enable to perform safe intracorporeal anastomose [30]. And allow specimen extraction in a bag, which may be of importance for cancer cases [5, 6].

While we develop techniques for scarless colectomies either through the NOTES or the SPA approach, our concern should focus on the safety of these new surgical procedures [7, 17, 23, 31]. In this regard, SPA right hemicolectomy, according to the present technique, is safer but may represent a step toward NOTES right colectomy.

Conclusion

Single port access right hemicolectomy is feasible and safe using the described technique when performed by experienced laparoscopic surgeons. SPA right hemicolectomy can be performed respecting oncologic principle.

Material development, especially multichannel single port, will improve the feasibility of this technique. However, it has to be determined whether or not this approach would offer any benefit, except in cosmesis, compared to the standard surgical technique of right colectomy.

References

- Liang J, Lai H, Lee P (2007) Laparoscopic medial-to-lateral approach for the curative resection of right-sided colon cancer. *Ann Surg Oncol* 14:1878–1879
- Kim J, Edwards E, Bowne W, Castro A, Moon V, Gadangi P, Ferzli G (2007) Medial-to-lateral laparoscopic colon resection: a view beyond the learning curve. *Surg Endosc* 21:1503–1507
- Braga M, Frasson M, Vignali A, Zuliani W, Di Carlo V (2007) Open right colectomy is still effective compared to laparoscopy: results of a randomized trial. *Ann Surg* 246:1010–1014
- Tong D, Law W (2007) Laparoscopic versus open right colectomy for carcinoma of the colon. *J Soc Laparoendosc Surg* 11:76–80
- Bucher P, Wuthrich P, Pugin F, Gonzalez M, Gervaz P, Morel P (2008) Totally intracorporeal laparoscopic colorectal anastomosis using circular stapler. *Surg Endosc* 22:1278–1282
- Wilson J, Dogiparthi K, Hebblethwaite N, Clarke M (2007) Laparoscopic right hemicolectomy with posterior colpotomy for transvaginal specimen retrieval. *Colorectal Dis* 9:662
- Lacy A, Delgado S, Rojas O, Almenara R, Blasi A, Llach J (2008) MA-NOS radical sigmoidectomy: report of a transvaginal resection in the human. *Surg Endosc* 22:1717–1723
- Varadarajulu S, Tamhane A, Drelichman E (2008) Patient perception of natural orifice transluminal endoscopic surgery as a technique for cholecystectomy. *Gastrointest Endosc* 67:854–860
- Li W, Xiao J (2008) Investigation for acceptance of natural orifice Transluminal Endoscopic surgery by inpatients with digestive disease. *Gastrointest Endosc* 67:AB120
- Kaouk J, Haber G, Goel R, Desai M, Aron M, Rackley R, Moore C, Gill I (2008) Single-port laparoscopic surgery in urology: initial experience. *Urology* 71:3–6
- Zhu J (2007) Scarless endoscopic surgery: NOTES or TUES. *Surg Endosc* 21:1898–1899
- Pearl J, Ponsky J (2007) Natural orifice transluminal endoscopic surgery: a critical review. *J Gastrointest Surg* Dec 5 Epub ahead of print
- Whiteford M, Denk P, Swanstrom L (2007) Feasibility of radical sigmoid colectomy performed as natural orifice transluminal endoscopic surgery (NOTES) using transanal endoscopic microsurgery. *Surg Endosc* 21:1870–1874
- Bucher P, Pugin F, Morel P (2008) Minimally invasive necrosectomy for infected necrotizing pancreatitis. *Pancreas* 36:113–119
- Ponsky J, Cherullo E, Sawyer M, Hartke D (2008) Single access site laparoscopic radical nephrectomy: initial clinical experience. *J Endourol* 22:663–666
- Gettman M, Box G, Averch T, Cadeddu J, Cherullo E, Clayman R, Desai M, Frank I, Gill I, Gupta M, Haber G, Humphreys M, Kaouk J, Landman J, Lima E, Ponsky L (2008) Consensus statement on Natural Orifice Transluminal Endoscopic Surgery and Single-Incision Laparoscopic Surgery: heralding a new era in urology. *Eur Urol* 53:1117–1120
- Pomp A (2008) Notes on NOTES: the emperor is not wearing any clothes. *Surg Endosc* 22:283–284
- Kaouk J, Palmer J (2008) Single-port laparoscopic surgery: initial experience in children for varicelectomy. *BJU* 102:97–99

19. Desai M, Rao P, Aron M, Pascal-Haber G, Desai M, Mishra S, Kaouk J, Gill I (2008) Scarless single port transumbilical nephrectomy and pyeloplasty: first clinical report. *BJU Int* 101:83–88
20. Ates O, Hakguber G, Olguner M, Akgur F (2007) Single-port laparoscopic appendectomy conducted intracorporeally with the aid of a transabdominal sling suture. *J Pediatr Surg* 42:1071–1074
21. Swanstrom L, Zheng B (2008) Spatial orientation and Off-Axis challenges for NOTES. *Gastrointest Endosc Clin N Am* 18:315–324
22. Mintz Y, Horgan S, Cullen J, Ramamoorthy S, Chock A, Savu M, Easter D, Talamini M (2007) NOTES: the hybrid technique. *J Laparoendosc Adv Surg Tech A* 17:402–406
23. ASGE., SAGES (2006) ASGE/SAGES Working Group on Natural Orifice Translumenal Endoscopic Surgery White Paper 2005. *Gastrointest Endosc* 63:199–203
24. Pigazzi A, Hellan M, Ewing D, Paz B, Ballantyne G (2007) Laparoscopic medial-to-lateral dissection: how and why. *J Gastrointest Surg* 11:778–782
25. Dunker M, Stiggelbout A, Van Hogezaand R, Ringers J, Griffioen G, Bemelman W (1998) Cosmesis and body image after laparoscopic-assisted and open ileocolic resection for Crohn's disease. *Surg Endosc* 12:1334–1340
26. Cuesta M, Berends F, Veenhof A (2008) The "invisible cholecystectomy": a transumbilical laparoscopic operation without a scar. *Surg Endosc* 22:1211–1213
27. Bhoyrul S, Payne J, Steffes B, Swanstrom L, Way L (2000) A randomized prospective study of radially expanding trocars in laparoscopic surgery. *J Gastrointest Surg* 4:392–397
28. Loriau J, Manaouil D, Verhaeghe P (2002) Celioscopie: les éventration sur orifice de trocars. *Ann Chir* 127:252–256
29. Lewis J (1995) A simple technique for anticipating and managing secondary puncture site hemorrhage during laparoscopic surgery. A report of two cases. *J Reprod Med* 40:729–730
30. Rane A, Rao P, Rao P (2008) Single-Port-Access Nephrectomy and other laparoscopic urologic procedure using a novel laparoscopic port (R-Port). *Urology* May 9 Epub ahead of print
31. Buess G, Cuschieri A (2007) Raising our heads above the parapet: ES not NOTES. *Surg Endosc* 21:835–837