

Skin anti-aging strategies

Ruta Ganceviciene,^{1,†} Aikaterini I. Liakou,^{2,†} Athanasios Theodoridis,^{2,†} Evgenia Makrantonaki² and Christos C. Zouboulis^{2,*}

¹Centre of Dermatovenereology; Vilnius University Hospital Santariskiu Klinikos; Vilnius, Lithuania; ²Departments of Dermatology, Venereology, Allergology and Immunology; Dessau Medical Center; Dessau, Germany

[†]These authors contributed equally to this work.

Keywords: aging, anti-aging, antioxidants, laser, peeling, fillers, botulinum toxin, hormone replacement therapy, cell regulators, prevention

Skin aging is a complex biological process influenced by a combination of endogenous or intrinsic and exogenous or extrinsic factors. Because of the fact that skin health and beauty is considered one of the principal factors representing overall “well-being” and the perception of “health” in humans, several anti-aging strategies have been developed during the last years. It is the intention of this article to review the most important anti-aging strategies that dermatologists have nowadays in hand, including including preventive measurements, cosmetological strategies, topical and systemic therapeutic agents, and invasive procedures.

Introduction

Skin aging is a part of a natural human “aging mosaic” which becomes evident and follows different trajectories in different organs, tissues and cells with time. While the aging signs of internal organs are masked from the ambient “eyes,” the skin provides first obvious marks of the passing time.

Skin aging is a complex biological process influenced by combination of endogenous or intrinsic (genetics, cellular metabolism, hormone and metabolic processes) and exogenous or extrinsic (chronic light exposure, pollution, ionizing radiation, chemicals, toxins) factors.¹ These factors lead together to cumulative structural and physiological alterations and progressive changes in each skin layer as well as changes in skin appearance, especially, on the sun-exposed skin areas.^{2–12} In contrast to thin and atrophic, finely wrinkled and dry intrinsically aged skin, premature photoaged skin typically shows a thickened epidermis, mottled discoloration, deep wrinkles, laxity, dullness and roughness.^{13–18} Gradual loss of skin elasticity leads to the phenomenon of sagging.¹⁹ Slowing of the epidermal turnover rate and cell cycle lengthening coincides with a slower wound healing and less effective desquamation in older adults. This fact is important when esthetic procedures are scheduled.²⁰ On the other side, many of these features are targets to product application or procedures to accelerate the cell cycle, in the belief that a faster turnover rate

will yield improvement in skin appearance and will speed wound healing.²¹ A marked loss of fibrillin-positive structures²² as well as a reduced content of collagen type VII (Col-7), may contribute to wrinkles by weakening the bond between dermis and epidermis of extrinsically age skin.²³ Sun-exposed aged skin is characterized by the solar elastosis. The sparse distribution and decrease in collagen content in photoaged skin can be due to increased collagen degradation by various matrix metalloproteinases, serine, and other proteases irrespective of the same collagen production.^{24–28} In older skin, collagen looks irregular and disorganized, the ratio of Col-3, to Col-1 has been shown to increase, due, significantly, to a loss of Col-1.²⁹ The overall collagen content per unit area of the skin surface is known to decline approximately 1%/year.³⁰ Glycosaminoglycans (GAGs) are among the primary dermal skin matrix constituents assisting in binding water. In photo-aged skin, GAGs may be associated with abnormal elastotic material and thus be unable to function effectively.³¹ The total hyaluronic acid (HA) level in the dermis of skin that age intrinsically remains stable; however, epidermal HA diminishes markedly.³²

Three primary structural components of the dermis, collagen, elastin and GAGs have been the subjects of the majority of anti-aging research and efforts for aesthetic-anti-aging strategies pertaining to the skin, from “anti-wrinkle creams” to various filling agents.²¹

Presentation of aging of the entire face is associated with the gravity impact, muscles action, loss of volume, diminishing and redistribution of superficial and deep fat, loss of bony skeleton support what all together lead to the face sagging, changes in shape and contour. Regardless of the fact that aging is a biological inevitable process and not a pathological condition it is correlated with various skin and body pathologies, including degenerative disorders, benign and malignant neoplasms.

The ‘successful aging’ paradigm, focuses on health and active participation in life, counters traditional conceptualizations of aging as a time of disease and is increasingly equated with minimizing age signs on the skin, face and body.^{33–35} From this perspective, preventative aesthetic dermatology might supplement the request for healthy aging, treat or prevent certain cutaneous disorders, notably skin cancer, and delay skin aging combining local and systemic methods of therapy, instrumental devices and invasive procedures.^{36,37} The mainspring of any skin anti-aging therapy is to achieve a healthy, smooth, blemish-free, translucent

*Correspondence to: Christos C. Zouboulis;
Email: christos.zouboulis@klinikum-dessau.de
Submitted: 10/03/12; Accepted: 10/16/12
<http://dx.doi.org/10.4161/derm.22804>

Table 1. Skin antiaging approaches

Cosmetological care	Daily skin care
	Correct sun protection
	Aesthetic non-invasive procedures
Topical medical agents or topical agents	Antioxidants
	Cell regulators
Invasive procedures	Chemical peelings
	Visible light devices
	Intense pulsed light (IPL)
	Ablative and nonablative laser photo-rejuvenation
	Radiofrequency (RF)
	Injectable skin biostimulation and rejuvenation
	Prevention of dynamic wrinkles
	Correction of static, anatomical wrinkles
Restoration (redistribution) of fat and volume loss, skin augmentation and contouring	
Systemic agents	Hormone replacement therapy
	Antioxidants
Avoiding of exogenous factors of aging, correction of life style and habits	Smoking
	Pollution
	Solar UV irradiation
	Stress
	Nutrition, diet restriction and alimentary supplementation
	Physical activity
Preventive medicine	Control of general health

and resilient skin.³⁸ In clinical practice, “to look better” doesn’t mean to “look younger.” That is why it is so important to understand patients’ wishes and to orientate them to the treatment modality that will give the most satisfying results whereas knowing all available treatment techniques.³⁹ The age, previous procedures or surgery, general health status, type of the skin, style of life and many other factors should be taken into consideration before choosing the strategy for the individual case. The desired therapeutic anti-aging effect of the skin is continuous, step-by-step process, which combines various methods of the skin bio-revitalization and rejuvenation, augmentation, restoration of each skin layer individually and in the light of many other factors—from a style of the life to the immune, genetic, emotional and health status in general. This review will emphasize the most important topical and systemic therapeutic agents and trends in the use of invasive procedures.

Skin Aging Prevention and Therapy

The skin anti-aging strategies attempted to reverse the dermal and epidermal signs of photo- and chronological aging can be grouped under the following approaches (Table 1).

Skin Care

Healthy and functioning skin barrier is important protector against dehydration, penetration of various microorganisms,

allergens, irritants, reactive oxygen species and radiation. The skin barrier may be specifically adjusted to allow penetration. For this reason daily skin care may increase skin regeneration, elasticity, smoothness, and thus temporarily change the skin condition.^{40,41} However, it is necessary to stop the degradation of the skin primary structural constituents, such as collagen, elastin, to prevent the formation of wrinkles. Although the technology required to suitably deliver these compounds into the skin has not yet been developed, some products do promote the natural synthesis of these substances except elastin enhancing.⁴²⁻⁴⁵ Another integral approach preventing wrinkle formation is the reduction of inflammation by topical or systemic antioxidants which should be used in combination with sunscreens and retinoids to enhance their protective effects.²¹

Photoprotection and Systemic Antioxidants

Chronic photodamage of the skin manifests itself as extrinsic skin aging (photoageing). DNA photodamage and UV-generated reactive oxygen species (ROS) are the initial molecular events that lead to most of the typical histological and clinical manifestations of chronic photodamage of the skin. Wrinkling and pigmentary changes are directly associated with premature photo-aging and are considered its most important cutaneous manifestations. The strategies aimed at preventing photo-aging include sun avoidance, sun protection using sunscreens to block or reduce skin exposure to UV radiation, retinoids in order to

inhibit collagenase synthesis and to promote collagen production, and anti-oxidants, particularly in combination, to reduce and neutralize free radicals (FR).^{21,46}

Interventional studies indicate that it is in fact possible to delay skin aging and to improve skin conditions through administration of selected nutritional supplements. Nutritional antioxidants act through different mechanisms and in different compartments, but are mainly FR scavengers: (1) they directly neutralize FRs, (2) they reduce the peroxide concentrations and repair oxidized membranes, (3) they quench iron to decrease ROS production, (4) via lipid metabolism, short-chain free fatty acids and cholesteryl esters neutralize ROS.⁴⁷ Endogenous antioxidant defenses are both non-enzymatic (e.g., uric acid, glutathione, bilirubin, thiols, albumin, and nutritional factors, including vitamins and phenols) and enzymatic [e.g., superoxide dismutases, glutathione peroxidases (GSHPx), and catalase]. The most important source of antioxidants is provided by nutrition. To the most known systemic antioxidants belong vitamin C, vitamin E, carotenoids, and from the trace elements copper and selenium.⁴⁸⁻⁵⁰ There are also studies demonstrating that vitamins C and E combined with ferulic acid impart both a sunscreen and an anti-oxidant effect.⁵¹

Topical Pharmacological Agents With Anti-Aging Properties

There are two main groups of agents that can be used as anti-aging cream components, the antioxidants and the cell regulators. The antioxidants, such as vitamins, polyphenols and flavonoids, reduce collagen degradation by reducing the concentration of FR in the tissues. The cell regulators, such as retinols, peptides and growth factors (GF), have direct effects on collagen metabolism and influence collagen production.

Vitamins C, B₃, and E are the most important antioxidants because of their ability to penetrate the skin through their small molecular weight.⁵² The water-soluble, heat-labile local L-ascorbic acid (vitamin C) in concentrations between 5 and 15% was proven to have a skin anti-aging effect by inducing the production of Col-1, and Col-3, as well as enzymes important for the production of collagen, and inhibitors of matrix metalloproteinase (MMP) 1 (collagenase 1).^{43,53} Clinical studies have proven that the antioxidative protection is higher with the combination of vitamins C and E than with the vitamin C or E alone.^{54,55} Niacinamide (vitamin B₃) regulates cell metabolism and regeneration, and it is used in 5% concentration as an anti-aging agent.⁵⁶ In some studies, improvement of skin elasticity, erythema and pigmentations after 3 mo of topical treatment has been observed.^{52,54} Vitamin E (α -tocopherol) used as a component of skin products has anti-inflammatory and antiproliferative effects in concentrations between 2 and 20%. It acts by smoothing the skin and increasing the ability of the stratum corneum to maintain its humidity, to accelerate the epithelialization, and contribute to photoprotection of the skin. The effects are not as strong as with vitamins C and B₃.⁵⁷

An in vivo study has proven that the topical application of green tea polyphenols before UV exposure leads to an increase of

the minimal erythema dose, decreases the number of Langerhans cells and reduces DNA damage in the skin.⁵⁸ Other botanicals that act as antioxidants are for example the isoflavones from soya.

Cell regulators, such as vitamin A derivatives, polypeptides and botanicals, act directly on the collagen metabolism and stimulate the production of collagen and elastic fibers.

Vitamin A (retinol) and its derivatives (retinaldehyde and tretinoin) are a group of agents that also have antioxidant effects. They can induce the biosynthesis of collagen and reduce the expression of MMP 1 (collagenase 1). Retinol is, at the moment, the substance that is most often used as an anti-aging compound and, compared with tretinoin, causes less skin irritation.^{59,60} It has been shown that retinol has positive effects not only on extrinsic but also on intrinsic skin aging and has a strong positive effect on collagen metabolism.^{60,61} Tretinoin, a nonaromatic retinoid of the first generation, is approved for application as an anti-aging treatment in a concentration of 0.05% in the United States. It has been shown to be able to reduce the signs of UV-induced early skin aging, such as wrinkles, loss of skin elasticity and pigmentation.

Polypeptides or oligopeptides are composed of amino acids and can imitate a peptide sequence of molecules such as collagen or elastin. Through topical application, polypeptides have the ability to stimulate collagen synthesis and activate dermal metabolism.⁶²

Invasive Procedures

There are various in-office procedures, most of which are intended to 'resurface' the epidermis: to remove the damaged epidermis and replace the tissue with remodeled skin layers and sometimes spur the formation of new collagen.^{21,63} It is possible that the potential of GF, cytokines and telomerase will eventually be harnessed via technological advancement and innovation in the burgeoning fields of tissue engineering and gene therapy in the nearest future.⁶⁴

Chemical Peels

Chemical peels are methods to cause a chemical ablation of defined skin layers to induce an even and tight skin as a result of the regeneration and repair mechanisms after the inflammation of the epidermis and dermis. Chemical peels are classified into three categories.^{65,66} Superficial peels [α - β -, lipo-hydroxy acids (HA), trichloroacetic acid (TCA) 10–30%] exfoliate epidermal layers without going beyond the basal layer; medium-depth peels (TCA above 30 to 50%) reach the upper reticular dermis; deep peels (TCA > 50%, phenol) penetrate the lower reticular dermis. The depth of peeling depends not on the substance used only, but on its concentration, pH of the solution and time of application.⁶⁶ A number of skin modifications have been reported after several weeks: epidermal architecture returns to normal, melanocytes are present and distributed uniformly, basal cells contain small melanin grains distributed homogeneously, the thickness of the basal membrane is homogeneous, in the dermis, a new sub epidermal band of collagen appears, elastic fibers form a new network, often

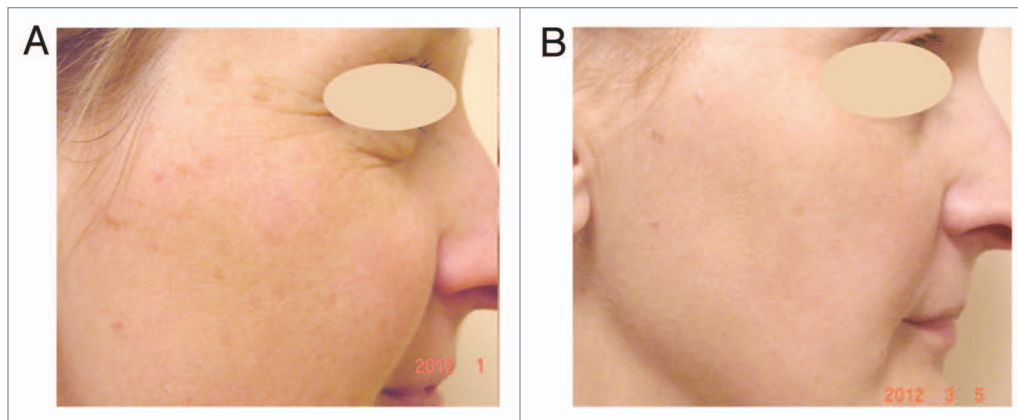


Figure 1. 45-y-old female with signs of photoaged skin: dyschromia of the skin, multiple lentiginos. (A) before, (B) after one treatment with IPL with 550 nm cut-off filter.

parallel to those of collagen.⁶⁷ If superficial peelings target the corneosomes, cause desquamation, increase epidermal activity of enzymes, lead to epidermolysis and exfoliation,^{68,69} medium-depth peels cause coagulation of membrane proteins, destroy living cells of the epidermis and, depending on the concentration, the dermis. Deep peels coagulate proteins and produce complete epidermolysis, restructure of the basal layer and restoration of the dermal architecture.⁶⁹ The depth of peel correlates with the potential side-effects, like hyperpigmentation, solar lentiginos, risk of post-operative infections, especially herpetic ones.^{66,70} The mechanism by which the chemical peel takes effect is not clearly elucidated. An increase in collagen fiber content, water and GAG in the dermis has been reported.^{71,72} There is a suggestion that improvements in skin elasticity and wrinkles after chemical peeling can be attributed to increase of Col-1 with or without Col-3, elastic fibers, as well of a dense rearrangement of collagen fibers.⁷³⁻⁷⁶

Visible Light Devices: IPL, Lasers, RF for the Skin Rejuvenation, Resurfacing and Tightening

Nonablative skin rejuvenation or “subsurfacing” comes as a low risk and short downtime technology which can improve aging structural changes without disruption of cutaneous integrity.⁷⁷ The mechanism of action is supposed to be a selective, heat induced denaturalization of dermal collagen that leads to subsequent reactive synthesis. Nonablative skin rejuvenation is not a precise term since rejuvenation is a controlled form of skin wounding aimed at achieving a more youthful appearance after the wound heals.³⁹

Treatment of photoaged skin has been divided into treatment of ectatic vessels and erythema, irregular pigmentation, and pilo-sebaceous changes (Type I) and into the improvement of the dermal and subcutaneous senescence (Type II).⁷⁷ The epidermis and superficial dermis can be selectively damaged by two basic mechanisms: (a) by targeting discrete chromophores in the dermis or at the dermal-epidermal junction or (b) by utilizing mid infrared (IR) lasers.⁷⁸

The devices for treatment of vascular and/or pigment irregularities include lasers emitting light at 532-, 585-, 595-, 755-,

800-, and 1064-nm wavelengths as well as filtered light generated by IPL systems equipped with different cut-off filters^{39,79} (Fig. 1). Lasers emitting 1,320,⁸⁰ 1,450,⁸¹ and 1,540 nm⁸² using interstitial and intracellular water as target chromophores and pulsed dye lasers (PDL)⁸³ using oxyhemoglobin as the primary chromophore are now employed for Type II photo rejuvenation only. The clinical efficacy of these nonablative modalities are weaker than that of the ablative methods, however, new collagen formation and clinically observable improvement in wrinkles can be observed.^{84,85} Reduction of facial wrinkles by using IPL devices has shown less effect comparing to laser technology,⁸⁶ but for type I photo rejuvenation, IPL systems have in general shown considerably better results than laser systems operating at sub-purpuric energy levels.⁸⁷⁻⁹⁰ Ultrastructural and histological analysis confirmed effectiveness of absorption of light (532, 585, 595, with or without 1064-nm Nd:YAG laser) in the blood vessels of the superficial dermis, resulting in the release of inflammatory mediators and GF into the interstitium followed by stimulated fibroblast activity and initiation of tissue repair and enhanced collagen and elastin neof ormation replacing the originally damaged elastic tissue.^{84,91,92} An increase in grenz zone thickness,⁹¹ monoclonal chondroitin sulfate and III procollagen staining as well as quantification of Col-1⁹³ was measured after couple of treatments with PDL. The increase in dermal collagen has also been confirmed by noninvasive ultrasonographic analysis⁹⁴ and radioimmunoassay.⁹⁵ Nonablative skin rejuvenation should not yet be considered an alternative for laser resurfacing.³⁹ However there are interesting data showing comparative histological changes between the ablative and nonablative modalities.⁹⁶

Histological sections of skin before and after treatment with the different IPL devices have shown the formation of new collagen in the papillary and reticular dermis, as well as an increase in the number of fibroblasts and proportional decrease in the amount of solar elastosis is also usually found.^{92,97-99} If vascular and/or pigment disturbances improvement are immediate, the collagen remodeling response is delayed and maximum results are seen only between 3 and 12 mo after treatment.³⁹

Laser resurfacing has been shown to be effective in counteracting photoaging through entire epidermal ablation,

collagen shrinkage, stimulation of neocollagenesis, extensive dermal remodeling, regeneration of cellular organelles and intercellular attachments¹⁰⁰ but parallelly, results in long recovery time are associated with risks of severe long lasting side effects, such as persistent erythema, hypo- or hyperpigmentation, infection or scarring.¹⁰¹⁻¹⁰⁴

Recently, fractionated CO₂-, erbium glass or erbium-YAG lasers have been introduced to reduce downtime and side effects.¹⁰⁵ These devices emit light in a pixilated fashion onto the skin, producing an array of microthermal zones in the dermis.¹⁰⁵⁻¹⁰⁸ The controlled thermal stress to the epidermis and the dermal compartment is followed by a wound healing response ultimately leading to re-epithelization and dermal remodeling.¹⁰⁹

Although the underlying molecular changes induced by different ablative and non-ablative as well as thermal and non-thermal skin rejuvenation treatments are not fully understood, there are investigations suggesting important roles of heat shock proteins (HSP), transforming growth factor β (TGF- β), different MMPs, synthetases, hyals and hyaluronic acid (HA).¹⁰⁹⁻¹¹³ Type I and type III procollagen mRNA was also elevated for at least 6 mo.¹¹⁴

Monopolar RF is a noninvasive way to obtain skin tightening³⁹ and immediate collagen contraction with a single treatment. Unlike lasers, the RF technology produces electric current, which generates heat through resistance in the dermis and as deep as the subcutaneous fat.⁷⁸ Unfortunately there is a lack of long-term studies of efficacy and analysis of side effects for the skin using this method of skin rejuvenation.

It is obvious that different treatment modalities using visible light devices have resulted in varying clinical effects and allow to select individual treatment parameters for different indications.¹¹⁵ For this reason, careful simultaneous evaluation of any pigment disturbances, vascular abnormalities, wrinkles, and cutaneous sagging as skin layers are all linked is highly recommended.

Injectable Skin Rejuvenation and Dermal Fillers

The goal of skin biorejuvenation is to increase the biosynthetic capacity of fibroblasts, inducing the reconstruction of an optimal physiologic environment, the enhancement of cell activity, hydration, and the synthesis of collagen, elastin, and HA (hyaluronic acid). The desired effect could be achieved by the microinjections in the superficial dermis of products containing only one active ingredient or cocktails of different compounds which are perfectly biocompatible and totally absorbable: HA, vitamins, minerals, nutrients, hormones, GF, amino acids, autologous cultured fibroblasts, homeopathic products, etc.¹¹⁶⁻¹²¹ The distinct formulations can induce strikingly divergent molecular and cellular processes in fibroblasts in vitro.¹²² However, more detailed studies are required to elucidate whether and how the cellular and molecular processes are involved in facial skin rejuvenation in vivo, whether these processes are similarly efficient, independent of the age of the patients. The proof of concept, including long-term efficiency, optimal injecting protocols are still lacking too.^{123,124}

Products injected within or beneath the skin to improve its physical features by soft tissue augmentation are known as

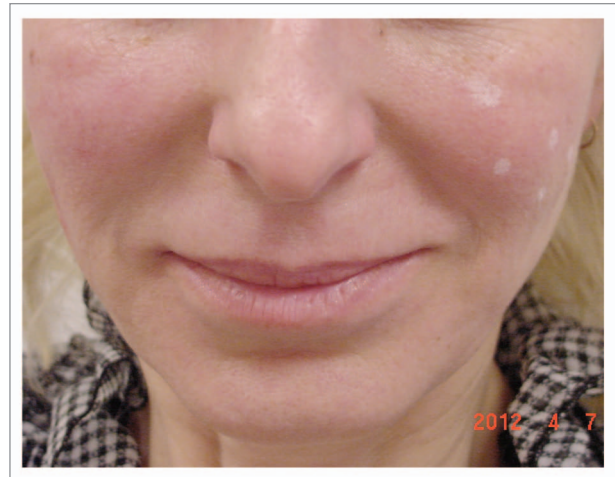

Figure 2. Patient showing the difference of the nasolabial fold: non-treated left side (with site marks for planned HA injection) and right side straight after injection of only 0.5 ml of nonanimal stabilized cross-linked HA ("Stalagmite" technique on the right cheek).

fillers.¹²⁵⁻¹²⁹ There are autologous (fat, cultured human fibroblasts), collagen (bovine-derived, human-derived from tissue culture), HA (nonanimal stabilized or viscoelastic HA from bacterial fermentation), synthetic or pseudo-synthetic implants (silicone, polymethacrylate microspheres, poly-L-lactic acid, calcium hydroxylapatite microspheres suspended in aqueous polysaccharide gel, alkyl-imide gel polymer). These may be grouped into temporary, semipermanent (lasting between 1–2 y), or permanent materials (lasting longer than 2 y).

GAG and particularly HA or hyaluronan are major components of the cutaneous extracellular matrix involved in tissue repair of all animal tissues.¹³⁰⁻¹³² HA exhibits no species or tissue specificity. As a physical background material, it has functions in space filling, lubrication, shock absorption, and protein exclusion. In addition, HA has been implicated as a regulator of cell proliferation and locomotion.¹³³⁻¹³⁵ Injection of HA is thought to promote skin rejuvenation by increasing both hydration and fibroblast activation.¹³⁶⁻¹⁴⁰ HA injected into the skin can stimulate fibroblasts to express Col-1, MMP-1 and tissue inhibitor of matrix metalloproteinase-1 (TIMP-1)^{122,141} as well as is participating in wound healing, modulation of inflammatory cells, interaction with proteoglycans of the extracellular matrix, and scavenging of FR.¹⁴² All these features of HA have made it to be useful as an ideal structural compound and have raised injections of HA products to the most acceptable and scientifically investigated "gold standard" procedures for skin rejuvenation and augmentation (Fig. 2).

Natural HA has a half-life in tissue of only 1 to 2 d before undergoing aqueous dilution and enzyme degradation in the liver to carbon dioxide and water.¹⁴³ Produced from bacterial (*Staphylococcus equine*) fermentation and modified by chemical cross-linking to improve their resistance to enzymatic degradation and prolong their effect, non-animal reticulated HA fillers are more pure, more viscous, usually well tolerated and rarely elicit adverse and immunological reactions.^{130,144-146} The duration

of effect for HA fillers ranges from 3 to 12 mo. The long-lasting dermal fillers maintain the position 1–2 y or even more.¹⁴⁷ Modern HA fillers differ in the particulate size, cross-linking and the type of cross-linking agent used in the HA; phasic structure—mono/biphasic, concentration of HA and presence of an anesthetic agent in each syringe.^{148–151} Besides composition, currently available products differ based on approved indications, duration of aesthetic effect, putative mode of operation, recommended depth of product placement, injection technique, suitability for different facial areas, and common adverse events.¹⁵²

One of long-lasting synthetic semi-permanent dermal fillers is calcium hydroxyl apatite based filler (CaHA) suspended in an aqueous carboxymethylcellulose gel carrier.^{150–155} The CaHA particles act as a scaffold for new tissue formation and stimulate collagen formation around the microspheres leading to a thickening of the dermis over time.¹⁴⁷ The spherical CaHA particles are gradually phagocytosed, degraded as calcium and phosphate and eliminated via the renal system. CaHA is biocompatible with an identical composition to bones with a low potential for antigenicity, foreign body reaction, and minimal inflammatory response. No osteoblast activity has been observed in soft tissue.¹⁵⁵

The application of poly-L-lactic acid (PLA) in soft tissue augmentation exploits a mechanism of action not seen in any other soft tissue filler like a treatment plan, preparation of injection material, and injection technique is distinct as well.¹⁵⁶ After the initial response lasting one week or less a delayed but progressive volumizing effect begins.¹⁵⁷ The process of hydration, loss of cohesion and molecular weight, and solubilization and phagocytosis of PLA by the host's macrophages, degrades PLA into lactic acid microspheres and eliminates CO₂ by way of respiratory excretion. Crystals are left behind to stimulate collagen and a granulomatous reaction. This inflammatory reaction elicits resorption and the formation of fibrous connective tissue about the foreign body, causing dermal fibroplasia that leads to the desired cosmetic effect.¹⁵⁸

Although subjective patient satisfaction is high in many of the studies with skin fillers and skin thickness as measured using wrinkle scale ratings of appearance, long-term efficacy and clinical safety data are lacking because patients are likely to continue to undergo subsequent cosmetic interventions.¹⁵⁹

Autologous Platelet-Rich Plasma (PRP)

Autologous Platelet-rich Plasma (PRP) has attracted attention for skin rejuvenation. PRP is derived from fresh whole blood, which contains a high concentration of platelets.¹⁶⁰ Various GF, including platelet-derived growth factor (PDGF), transforming growth factor (TGF), vascular endothelial growth factor (VEGF), and insulin-like growth factor (IGF), are secreted from the α -granules of concentrated platelets activated by aggregation inducers.¹⁶¹ These factors are known to regulate processes including cell migration, attachment, proliferation and differentiation, and promote extracellular matrix (ECM) accumulation by binding to specific cell surface receptors.^{162,163} It has been shown that PRP may induce the synthesis of collagen and other

matrix components by stimulating the activation of fibroblasts, thus, rejuvenating the skin.^{164–167} However, the molecular mechanisms underlying PRP-inducing wound healing processes are still largely unknown and experimental studies confirming the effects of PRP on aged fibroblasts are very limited.

Botulinum Toxin

Botulinum toxin (BTX) has no effect on skin texture and cannot discontinue the skin aging process. However, regular BTX injections can slow down the visible aging process by helping in the management of certain dynamic facial lines and wrinkles^{168–170} (Fig. 3). Current treatment options of exaggerated frown lines, glabellar lines or crow feet such as surgery or implants, do not address the underlying cause of these lines, namely the excessive nerve stimulation. The mechanism of action of BTX makes it an ideal agent to target the major cause of these dynamic lines.¹⁷¹

Seven constitutionally similar but antigenically distinct subtypes of neurotoxin (A–G) are produced by different strains of the anaerobic, gram-positive bacterium *Clostridium botulinum*.^{172–177} BTX-subtype A (BTX-A) is the most potent. BTX-A produces temporary chemical denervation by blocking the presynaptic release of acetylcholine (Ach) at the neuromuscular junction (NMJ).¹⁷⁸ The specific heavy chain is associated with the internalization of the toxin and binds it irreversibly to the motor nerve end-plates with a high affinity to specific receptors (sialoglycoproteins) in the plasma membrane of cholinergic nerve endings. This induces receptor-mediated endocytosis of the toxin. The light chain that is responsible for the toxicity splits off in the cell, and inactivates a synapse-specific protein synaptosomal-associated protein of 25 kDa (SNAP-25) which is one of several proteins required for Ach exocytosis and release into the NMJ.¹⁷⁹

The toxin binds to presynaptic neurons of selected muscles rapidly (under an hour) and specifically. Clinically reversible chemical denervation and selective muscle relaxation or paralysis starts after 24 to 48 h and may not be completed for up to 2 weeks.^{173–177} In muscle, approximately on day 28, nerve sprouts mediate a partial restoration and new neuromuscular junctions are formed in the vicinity of the old junctions. Another factor explaining the regaining of muscle function could be an increase in the area of muscle membrane sensitive to acetylcholine.¹⁸⁰ On days 62–91, complete muscle function recovery can be demonstrated.^{179,181}

Muscular changes in the form of atrophy were demonstrated in animal studies, and were completely reversible after 4–6 mo. In human muscle, no lasting atrophy could be detected even after repeated injections, only a predominance of type I fibers.¹⁷⁹ The usual duration of effect is 3–6 mo with individual variations.^{173–177}

Dosing of BTX-A is essential in achieving precise and predictable effects. The biological activity given in mouse units (MU) and the weight of the molecule is not associated with the dosage. One MU is equivalent to the amount of toxin at which, after intraperitoneal administration, half of the poisoned Swiss-Webster mice die (50% lethal dose; LD50).¹⁸² The amounts of BTX-A used for the treatment are 25–100 times less than the

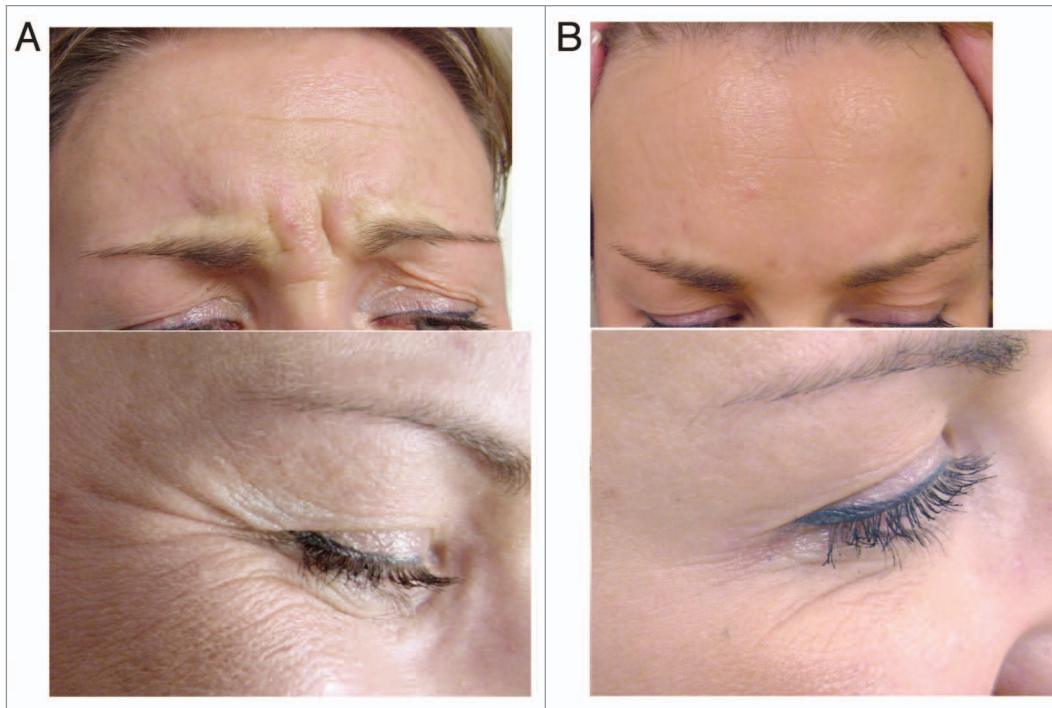

Figure 3. Patient showing glabellar and crow's feet wrinkles. (A) pre-injection, (B) after injection with botulinum toxin.

LD50, so that the FDA classifies BTX-A as therapeutically safe.¹⁸³ BTX-A does not cross the blood-brain barrier or pass through the skin.¹⁷⁹

Several commercial preparations of BTX-A products which are produced from different strains of bacteria by different purification methods and therefore have distinct components and properties, requirements of storage, shelf-life, and dose are currently available for aesthetic uses.^{184,185}

A thorough understanding and evaluation of the relevant anatomy and physiology of the muscles and possible alterations in the area to be injected is essential. Dosage for the patients depends on the area, muscle mass, gender and other factors individually. Contraindications include conditions of peripheral motor neuropathic diseases or neuromuscular functional disorders, coadministration with aminoglycoside antibiotics or other agents that interfere with neuromuscular transmission and may potentiate general weakness, treatment of patients with inflammatory skin disorders at the injection site, history of reaction to toxin, pregnancy and lactation, age younger than 12 y, participation in occupations that necessitate a wide range of facial expressions.^{171,186-188}

Given the short-term and localized effects of BTX-A injections, it is reassuring that any potential adverse reactions known to date may also be short lived, localized, and reversible in a dose-dependent period of 6–8 weeks. Systemic or serious side effects in general are rare, immune-mediated disorders or other idiosyncratic reactions are unknown.^{189,190} The development of antibodies to BTX-A may be related to exposure to high doses of toxin and seems to be related to decreased BTX-A efficacy.^{191,192} Current batches of BTX-A (manufactured after 1997) have

lower albumin concentration and higher toxin-specific activity, which may contribute to reduced clinical antigenicity.^{182,193,194}

The incidence of complications in many cases depends on the proper application and the qualification of the physician. However, it has always to be considered that the benefits of this treatment are transient and repeated injections are necessary for a long-term effect.¹⁹⁵

Hormone Replacement Therapy (HRT)

It is well known that there is a progressive decrease of hormone synthesis with age. Levels of growth hormone (GH) and insulin-like growth factor-1 (IGF-1), melatonin (nocturnal), TSH, thyroid hormones (T3), dehydroepiandrosterone (DHEA) (sulphated form and its urinary 17-keto-metabolites), estrogens and testosterone are progressively decreasing. The main hormonal deficits in humans are menopause, andropause and partial androgen deficiency of the aging male.¹⁹⁶⁻¹⁹⁹ DHEA substitution has been proven to lead to an improvement of body condition, sexual activity, bone density, and well-being.²⁰⁰

In a randomized and placebo-controlled study of 280 older men and women (60–79 y of age), each subject received 50 mg of DHEA daily for a year. The women showed an improvement of the libido, skin health, and osseous density.²⁰¹⁻²⁰³ Furthermore, another study conducted by Rudman et al. has pointed out that the application of GH decreased the signs of biological aging. The treatment led to an improved body condition, with an increase of muscle mass and osseous density and a decrease of adipose tissue. Moreover, an increase of skin thickness was observed.¹⁹⁹

Melatonin has been shown to have a favorable influence on the aging process, because it has an inverse effect with regard to body weight; food restriction raises the levels of melatonin and decreases its age-related decrease. With increasing age comes a decrease of melatonin production, which may have a connection to sleep disorders suffered by elderly people. It also has been shown that melatonin can prevent tumor development and growth. Interestingly, a study showed that patients with tumors had decreased levels of melatonin compared with healthy individuals.²⁰⁴⁻²⁰⁷

HRT with testosterone is absolutely indicated in older men who are either symptomatic or have a low serum testosterone level. Either a decrease of testosterone or a loss of the circadian rhythm of testosterone secretion has been observed in a high percentage of older men. Clinical symptoms include general weakness, sexual dysfunction, diminished muscle and bone mass, and decreased erythropoiesis. A low testosterone level has been shown in epidemiological studies to lead to a higher morbidity and mortality rate and to a higher prevalence of depression, coronary heart disease, and osteoporosis. Insulin resistance has been shown to play an important role in the development of hypogonadism in older men. Thus, obese men and men with type 2 diabetes, show significantly lower testosterone levels compared with subjects in control groups.¹⁹⁹

References

- Cevenini E, Invidia L, Lescai F, Salvioli S, Tieri P, Castellani G, et al. Human models of aging and longevity. *Expert Opin Biol Ther* 2008; 8:1393-405; PMID:18694357; <http://dx.doi.org/10.1517/14712598.8.9.1393>
- Uitto J. Understanding premature skin aging. *N Engl J Med* 1997; 337:1463-5; PMID:9358147; <http://dx.doi.org/10.1056/NEJM199711133372011>
- Scaffidi P, Misteli T. Lamin A-dependent nuclear defects in human aging. *Science* 2006; 312:1059-63; PMID:16645051; <http://dx.doi.org/10.1126/science.1127168>
- Fisher GJ. The pathophysiology of photoaging of the skin. *Cutis*, 75, 5-9 (2005)58-69
- Schmuth M, Watson RE, Deplewski D, Dubrac S, Zouboulis CC, Griffiths CE. Nuclear hormone receptors in human skin. *Horm Metab Res* 2007; 39:96-105; PMID:17326005; <http://dx.doi.org/10.1055/s-2007-961808>
- Reichrath J, Lehmann B, Carlberg C, Varani J, Zouboulis CC. Vitamins as hormones. *Horm Metab Res* 2007; 39:71-84; PMID:17326003; <http://dx.doi.org/10.1055/s-2007-958715>
- Verdier-Sévrain S, Bonté F, Gilchrist B. Biology of estrogens in skin: implications for skin aging. *Exp Dermatol* 2006; 15:83-94; PMID:16433679; <http://dx.doi.org/10.1111/j.1600-0625.2005.00377.x>
- Hall G, Phillips TJ. Estrogen and skin: the effects of estrogen, menopause, and hormone replacement therapy on the skin. *J Am Acad Dermatol* 2005; 53:555-68, quiz 569-72; PMID:16198774; <http://dx.doi.org/10.1016/j.jaad.2004.08.039>
- Brincat MP, Baron YM, Galea R. Estrogens and the skin. *Climacteric* 2005; 8:110-23; PMID:16096167; <http://dx.doi.org/10.1080/13697130500118100>
- Draeos ZD. Topical and oral estrogens revisited for antiaging purposes. *Fertil Steril* 2005; 84:291-2, discussion 295; PMID:16084864; <http://dx.doi.org/10.1016/j.fertnstert.2005.03.033>
- Kanda N, Watanabe S. Regulatory roles of sex hormones in cutaneous biology and immunology. *J Dermatol Sci* 2005; 38:1-7; PMID:15795118; <http://dx.doi.org/10.1016/j.jdermsci.2004.10.011>
- Shin MH, Rhie GE, Park CH, Kim KH, Cho KH, Eun HC, et al. Modulation of collagen metabolism by the topical application of dehydroepiandrosterone to human skin. *J Invest Dermatol* 2005; 124:315-23; PMID:15675949; <http://dx.doi.org/10.1111/j.0022-202X.2004.23588.x>
- Kligman LH. Photoaging. Manifestations, prevention, and treatment. *Clin Geriatr Med* 1989; 5:235-51; PMID:2646001
- El-Domyati M, Attia S, Saleh F, Brown D, Birk DE, Gasparro F, et al. Intrinsic aging vs. photoaging: a comparative histopathological, immunohistochemical, and ultrastructural study of skin. *Exp Dermatol* 2002; 11:398-405; PMID:12366692; <http://dx.doi.org/10.1034/j.1600-0625.2002.110502.x>
- Moragas A, Castells C, Sans M. Mathematical morphologic analysis of aging-related epidermal changes. *Anal Quant Cytol Histol* 1993; 15:75-82; PMID:8318130
- Lock-Andersen J, Therkildsen P, de Fine Olivarius F, Gniadecka M, Dahlström K, Poulsen T, et al. Epidermal thickness, skin pigmentation and constitutive photosensitivity. *Photodermatol Photoimmunol Photomed* 1997; 13:153-8; PMID:9453085; <http://dx.doi.org/10.1111/j.1600-0781.1997.tb00220.x>
- Makrantonaki E, Zouboulis CC, William J. Cunliffe Scientific Awards. Characteristics and pathomechanisms of endogenously aged skin. *Dermatology* 2007; 214:352-60; PMID:17460411; <http://dx.doi.org/10.1159/000100890>
- Makrantonaki E, Zouboulis CC. Molecular mechanisms of skin aging: state of the art. *Ann N Y Acad Sci* 2007; 1119:40-50; PMID:18056953; <http://dx.doi.org/10.1196/annals.1404.027>
- Escoffier C, de Rigo J, Rochefort A, Vasselet R, Lévêque JL, Agache PG. Age-related mechanical properties of human skin: an in vivo study. *J Invest Dermatol* 1989; 93:353-7; PMID:2768836; <http://dx.doi.org/10.1111/1523-1747.ep12280259>
- Yaar M, Gilchrist BA. Aging of skin. In *Fitzpatrick's Dermatology in General Medicine* Vol 2, 5th edn. McGraw-Hill:New York, 1999; 1697-1706
- Baumann L. Skin ageing and its treatment. *J Pathol* 2007; 211:241-51; PMID:17200942; <http://dx.doi.org/10.1002/path.2098>
- Watson RE, Craven NM, Kang S, Jones CJ, Kiely CM, Griffiths CE. A short-term screening protocol, using fibrillin-1 as a reporter molecule, for photoaging repair agents. *J Invest Dermatol* 2001; 116:672-8; PMID:11348454; <http://dx.doi.org/10.1046/j.1523-1747.2001.01322.x>
- Contet-Audonnet JL, Jeanmaire C, Pauly G. A histological study of human wrinkle structures: comparison between sun-exposed areas of the face, with or without wrinkles, and sun-protected areas. *Br J Dermatol* 1999; 140:1038-47; PMID:10354068; <http://dx.doi.org/10.1046/j.1365-2133.1999.02901.x>
- Varani J, Spearman D, Perone P, Fligel SE, Datta SC, Wang ZQ, et al. Inhibition of type I procollagen synthesis by damaged collagen in photoaged skin and by collagenase-degraded collagen in vitro. *Am J Pathol* 2001; 158:931-42; PMID:11238041; [http://dx.doi.org/10.1016/S0002-9440\(10\)64040-0](http://dx.doi.org/10.1016/S0002-9440(10)64040-0)
- Brenneisen P, Oh J, Wlaschek M, Wenk J, Briviba K, Hommel C, et al. Ultraviolet B wavelength dependence for the regulation of two major matrix-metalloproteinases and their inhibitor TIMP-1 in human dermal fibroblasts. *Photochem Photobiol* 1996; 64:877-85; PMID:8931389; <http://dx.doi.org/10.1111/j.1751-1097.1996.tb01851.x>
- Fisher GJ, Datta SC, Talwar HS, Wang ZQ, Varani J, Kang S, et al. Molecular basis of sun-induced premature skin ageing and retinoid antagonism. *Nature* 1996; 379:335-9; PMID:8552187; <http://dx.doi.org/10.1038/379335a0>
- Fisher GJ, Wang ZQ, Datta SC, Varani J, Kang S, Voorhees JJ. Pathophysiology of premature skin aging induced by ultraviolet light. *N Engl J Med* 1997; 337:1419-28; PMID:9358139; <http://dx.doi.org/10.1056/NEJM199711133372003>
- Scharfetter-Kochanek K, Wlaschek M, Briviba K, Sies H. Singlet oxygen induces collagenase expression in human skin fibroblasts. *FEBS Lett* 1993; 331:304-6; PMID:8375513; [http://dx.doi.org/10.1016/0014-5793\(93\)80357-Z](http://dx.doi.org/10.1016/0014-5793(93)80357-Z)
- Oikarinen A. The aging of skin: chronoaging versus photoaging. *Photodermatol Photoimmunol Photomed* 1990; 7:3-4; PMID:2371168

Conclusions

While natural aging is genetically determined, extrinsic aging can be prevented. Aesthetic dermatology should contribute to "healthy aging" not only in cosmetic means by trying to erase time vestiges in skin but by also playing a significant part in prevention, regeneration, and delaying of skin aging combining knowledge of possible local and systemic therapy, instrumental devices and invasive procedures, filling the lack of scientific investigations and becoming one of the important focuses of the aging research.

Disclosure of Potential Conflicts of Interest

No potential conflicts of interest were disclosed.

179. Becker-Wegerich P, Rauch L, Ruzicka T. Botulinum toxin A in the therapy of mimic facial lines. *Clin Exp Dermatol* 2001; 26:619-30; PMID:11696067; <http://dx.doi.org/10.1046/j.1365-2230.2001.00901.x>
180. Ganong WF. Review of Medical Physiology, 16th edn. East Norwalk, Connecticut: Appleton and Lange, 1993; 99±102
181. de Paiva A, Meunier FA, Molgó J, Aoki KR, Dolly JO. Functional repair of motor endplates after botulinum neurotoxin type A poisoning: biphasic switch of synaptic activity between nerve sprouts and their parent terminals. *Proc Natl Acad Sci U S A* 1999; 96:3200-5; PMID:10077661; <http://dx.doi.org/10.1073/pnas.96.6.3200>
182. Product Information Package Insert. (71390US12J). Irvine, CA: Allergan, Inc.; 2002
183. Hatheway CG. Immunology of Botulinum Toxin. New York: Marcel-Dekker; 1993
184. Huang W, Foster JA, Rogachefsky AS. Pharmacology of botulinum toxin. *J Am Acad Dermatol* 2000; 43:249-59; PMID:10906647; <http://dx.doi.org/10.1067/mjd.2000.105567>
185. Rzany B, Ascher B, Monheit GD. Treatment of glabellar lines with botulinum toxin type A (Speywood Unit): a clinical overview. *J Eur Acad Dermatol Venerol* 2010; 24(Suppl 1):1-14; PMID:19930409; <http://dx.doi.org/10.1111/j.1468-3083.2009.03475.x>
186. Botox (Package Insert). Allergan, Inc
187. Carruthers J, Fagien S, Matarasso SL. the Botox Consensus Group. Botulinum toxin and facial aesthetics. *Plast Reconstr Surg* 2004; 114:1S-22S; PMID:15507786; <http://dx.doi.org/10.1097/01.PRS.0000144795.76040.D3>
188. Shetty MK; IADVL Dermatotomy Task Force. Guidelines on the use of botulinum toxin type A. *Indian J Dermatol Venereol Leprol* 2008; 74(Suppl):S13-22; PMID:18688099
189. Sommer B, Sattler G. Botulinumtoxin in der aEsthetischen Medizin. Berlin; Blackwell Wissenschafts-Verlag, 2001
190. Carruthers J, Carruthers A. Cosmetic use of botulinum A exotoxin. In: *Advances in Dermatology* (Dzubow L, ed.) 1996; 280-303
191. Lange DJ, Rubin M, Greene PE, Kang UJ, Moskowitz CB, Brin MF, et al. Distant effects of locally injected botulinum toxin: a double-blind study of single fiber EMG changes. *Muscle Nerve* 1991; 14:672-5; PMID:1922173; <http://dx.doi.org/10.1002/mus.880140711>
192. Goschel H, et al. Botulinum toxin therapy, neutralizing and non-neutralizing antibodies. *Exp Neurol* 1997; 147:96; PMID:9294406; <http://dx.doi.org/10.1006/exnr.1997.6580>
193. Blitzer A, Binder WJ, Boyd JB, Carruthers A. Management of Facial Lines and Wrinkles. Philadelphia, PA: Lippincott Williams & Wilkins; 2000
194. Matarasso A, Deva AK; American Society of Plastic Surgeons DATA Committee. Botulinum toxin. *Plast Reconstr Surg* 2002; 109:1191-7; PMID:11884859; <http://dx.doi.org/10.1097/00006534-200203000-00066>
195. Fagien S. Botox for the treatment of dynamic and hyperkinetic facial lines and furrows: adjunctive use in facial aesthetic surgery. *Plast Reconstr Surg* 1999; 103:701-13; PMID:9950563; <http://dx.doi.org/10.1097/00006534-199902000-00055>
196. Hertoghe T. The "multiple hormone deficiency" theory of aging: is human senescence caused mainly by multiple hormone deficiencies? *Ann N Y Acad Sci* 2005; 1057:448-65; PMID:16399912; <http://dx.doi.org/10.1196/annals.1322.035>
197. Cranney A, Papaioannou A, Zytaruk N, Hanley D, Adachi J, Goltzman D, et al.; Clinical Guidelines Committee of Osteoporosis Canada. Parathyroid hormone for the treatment of osteoporosis: a systematic review. *CMAJ* 2006; 175:52-9; PMID:16818910; <http://dx.doi.org/10.1503/cmaj.050929>
198. Vitetta L, Anton B. Lifestyle and nutrition, caloric restriction, mitochondrial health and hormones: scientific interventions for anti-aging. *Clin Interv Aging* 2007; 2:537-43; PMID:18225453
199. Heutling D, Lehnert H. [Hormone therapy and anti-aging: is there an indication?]. *Internist (Berl)* 2008; 49:570-80, 572-6, 578-9; PMID:18389196; <http://dx.doi.org/10.1007/s00108-008-2110-3>
200. Morales AJ, Nolan JJ, Nelson JC, Yen SS. Effects of replacement dose of dehydroepiandrosterone in men and women of advancing age. *J Clin Endocrinol Metab* 1994; 78:1360-7; PMID:7515387; <http://dx.doi.org/10.1210/jc.78.6.1360>
201. Baulieu EE, Thomas G, Legrain S, Lahlou N, Roger M, Debuire B, et al. Dehydroepiandrosterone (DHEA), DHEA sulfate, and aging: contribution of the DHEAge Study to a sociobiomedical issue. *Proc Natl Acad Sci U S A* 2000; 97:4279-84; PMID:10760294; <http://dx.doi.org/10.1073/pnas.97.8.4279>
202. Jankowski CM, Gozansky WS, Schwartz RS, Dahl DJ, Kittelson JM, Scott SM, et al. Effects of dehydroepiandrosterone replacement therapy on bone mineral density in older adults: a randomized, controlled trial. *J Clin Endocrinol Metab* 2006; 91:2986-93; PMID:16735495; <http://dx.doi.org/10.1210/jc.2005-2484>
203. Nair KS, Rizza RA, O'Brien P, Dhataria K, Short KR, Nehra A, et al. DHEA in elderly women and DHEA or testosterone in elderly men. *N Engl J Med* 2006; 355:1647-59; PMID:17050889; <http://dx.doi.org/10.1056/NEJMoa054629>
204. Wetterberg L, Bergiannaki JD, Paparrigopoulos T, von Knorring L, Eberhard G, Bratlid T, et al. Normative melatonin excretion: a multinational study. *Psychoneuroendocrinology* 1999; 24:209-26; PMID:10101729; [http://dx.doi.org/10.1016/S0306-4530\(98\)00076-6](http://dx.doi.org/10.1016/S0306-4530(98)00076-6)
205. Roth GS, Lesnikov V, Lesnikov M, Ingram DK, Lane MA. Dietary caloric restriction prevents the age-related decline in plasma melatonin levels of rhesus monkeys. *J Clin Endocrinol Metab* 2001; 86:3292-5; PMID:11443203; <http://dx.doi.org/10.1210/jc.86.7.3292>
206. Ferrari E, Cravello L, Falvo F, Barili L, Solerte SB, Fioravanti M, et al. Neuroendocrine features in extreme longevity. *Exp Gerontol* 2008; 43:88-94; PMID:17764865; <http://dx.doi.org/10.1016/j.exger.2007.06.010>
207. Blask DE, Dauchy RT, Sauer LA. Putting cancer to sleep at night: the neuroendocrine/circadian melatonin signal. *Endocrine* 2005; 27:179-88; PMID:16217131; <http://dx.doi.org/10.1385/ENDO:27:2:179>
208. Heutling D, Lehnert H. Hormone therapy and menopause. *Dtsch Med Wochenschr* 2005; 130:829-34; PMID:15789305; <http://dx.doi.org/10.1055/s-2005-865097>