

Case report

Open Access

Small bowel gastrointestinal stromal tumours and ampullary cancer in Type I neurofibromatosis

Kasim A Behranwala*¹, Duncan Spalding¹, Andrew Wotherspoon², Cyril Fisher² and Jeremy N Thompson¹

Address: ¹Gastrointestinal Surgery Unit, Royal Marsden NHS Trust, 203 Fulham Road, London SW3 6JJ, UK and ²Department of Pathology, Royal Marsden NHS Trust, 203 Fulham Road, London SW3 6JJ, UK

Email: Kasim A Behranwala* - kbehranwala@hotmail.com; Duncan Spalding - duncan.spalding@virgin.net; Andrew Wotherspoon - Andrew.Wotherspoon@rmh.nthames.nhs.uk; Cyril Fisher - cfisher@icr.ac.uk; Jeremy N Thompson - Jeremy.Thompson@rmh.nthames.nhs.uk

* Corresponding author

Published: 07 January 2004

Received: 25 August 2003

World Journal of Surgical Oncology 2004, 2:1

Accepted: 07 January 2004

This article is available from: <http://www.wjso.com/content/2/1/1>

© 2004 Behranwala et al; licensee BioMed Central Ltd. This is an Open Access article: verbatim copying and redistribution of this article are permitted in all media for any purpose, provided this notice is preserved along with the article's original URL.

Abstract

Background: Type I neurofibromatosis (NF-1) is an autosomal dominant disorder with variable penetrance; approximately 50% of cases present as new mutations

Case report: We report a case of a 56 year-old man with Von Recklinghausen's disease, carcinoma of the ampulla of Vater and incidental benign gastrointestinal stromal tumours of the jejunum.

Conclusions: Coexistence between ampullary carcinoid, ectopic pancreatic tissue in the jejunum and neurofibroma of the jejunum in NF-1 has been previously described however; the association of synchronous carcinoma of the ampulla of Vater and gastrointestinal stromal tumour of the jejunum in NF-1 has not been previously reported.

Background

Type 1 neurofibromatosis (NF-1) is an autosomal dominant disorder with variable penetrance; approximately 50% of the cases present as new mutations. The major diagnostic criterion includes multiple cutaneous neurofibromas, axillary or inguinal freckling, *café au lait* spots, Lisch nodules (pigmented iris hamartomas) and a first-degree family history of NF-1 [1]. The gene for NF-1 has been identified on chromosome 17. NF-1 gene encodes a GTPase activating protein that has the potential to regulate the activity of the p21 product of the ras oncogene and the gene has been suggested to play an important role in controlling cell proliferation and differentiation in a

wide range of tissues [2]. Gastrointestinal tract lesions are not uncommon in NF-1, and typically vary from gut neural tissue hyperplasia to gastrointestinal stromal and endocrine cell tumours; there are only rare reports of a miscellaneous group of other malignant neoplasms [3]. Gastrointestinal stromal tumours (GIST) have been histologically identified as neurofibromas, leiomyomas, leiomyosarcomas, schwannomas, autonomic nerve tumours (GANT) and stromal tumours without any definite nerve or muscular differentiation, which have been hypothesised as originating from interstitial cells of Cajal (ICC) [3-6]. Gastrointestinal lesions associated with NF-1, although usually asymptomatic, may present as

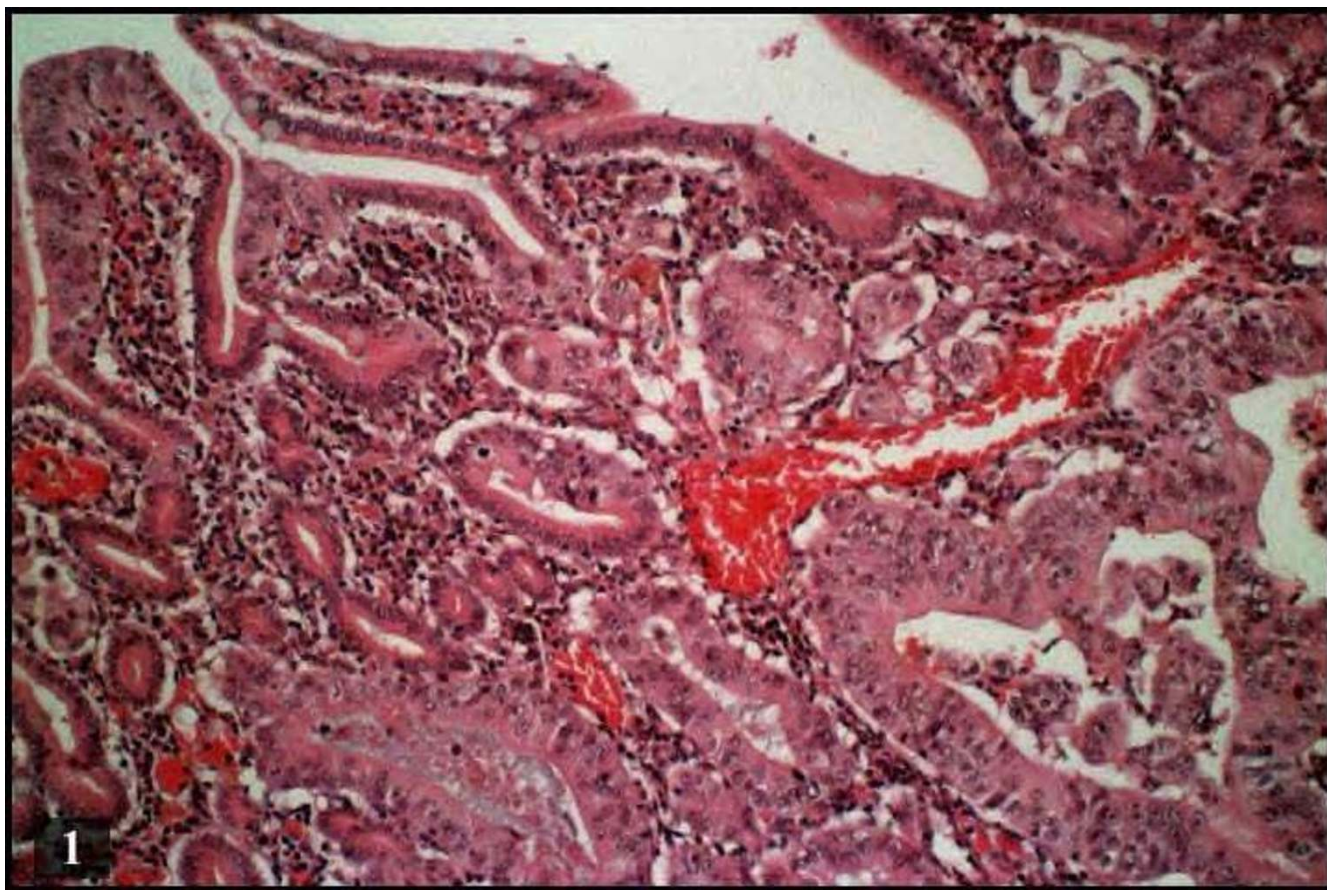


Figure 1
Photomicrograph showing pancreatic adenocarcinoma (Haematoxylin and Eosin × 100)

abdominal pain, dyspepsia, vomiting, anaemia, melaena, haematemesis, haematochezia, intussusception, volvulus, small bowel obstruction, fever and abdominal mass. The case reported by Karatzas *et al.*, [7] mentions the coexistence between ampullary carcinoid, ectopic pancreatic tissue in the jejunum and neurofibroma of the jejunum in NF-1. The association of synchronous carcinoma of the ampulla of Vater and gastrointestinal stromal tumour of the jejunum in NF-1 has not been previously described.

Case Report

A 56-year-old man presented with history of obstructive jaundice. ERCP done two months earlier at the referring hospital showed a distal bile duct stricture that was stented. Jaundice had initially improved but recurred due to stent occlusion. Skin examination was remarkable for diffuse cutaneous neurofibromas and *café au lait* spots. CT scan showed a mass lesion in pancreatic head with no evidence of metastatic disease elsewhere. There was no histological/cytological diagnosis before the operation. With a

provisional diagnosis of carcinoma head of the pancreas patient underwent laparotomy. At laparotomy, several nodules were seen on the serosal surface of the small bowel of which three yellowish serosal nodules from the jejunum were excised. A pylorus-preserving proximal pancreatic-duodenectomy was performed. Pathological examination of the resected pancreas showed a 33 mm, moderately differentiated invasive adenocarcinoma (Figure 1), arising from a severely dysplastic villous adenoma of the ampulla. Two intra-pancreatic lymph nodes showed metastatic carcinoma with extranodal spread (pT4N1bM0). The three small bowel serosal nodules were less than 5 mm in size and had similar appearances. Microscopically the lesions were composed of bland spindle cells arranged in a storiform pattern set within muscle wall (Figure 2a). No necrosis, mitotic figures or pleomorphism was seen. Tumour cells were positive for CD117 (Figure 2b) and CD34 (Figure 2d) but were negative for S100 protein (Figure 2c), neurofilament, synaptophysin,

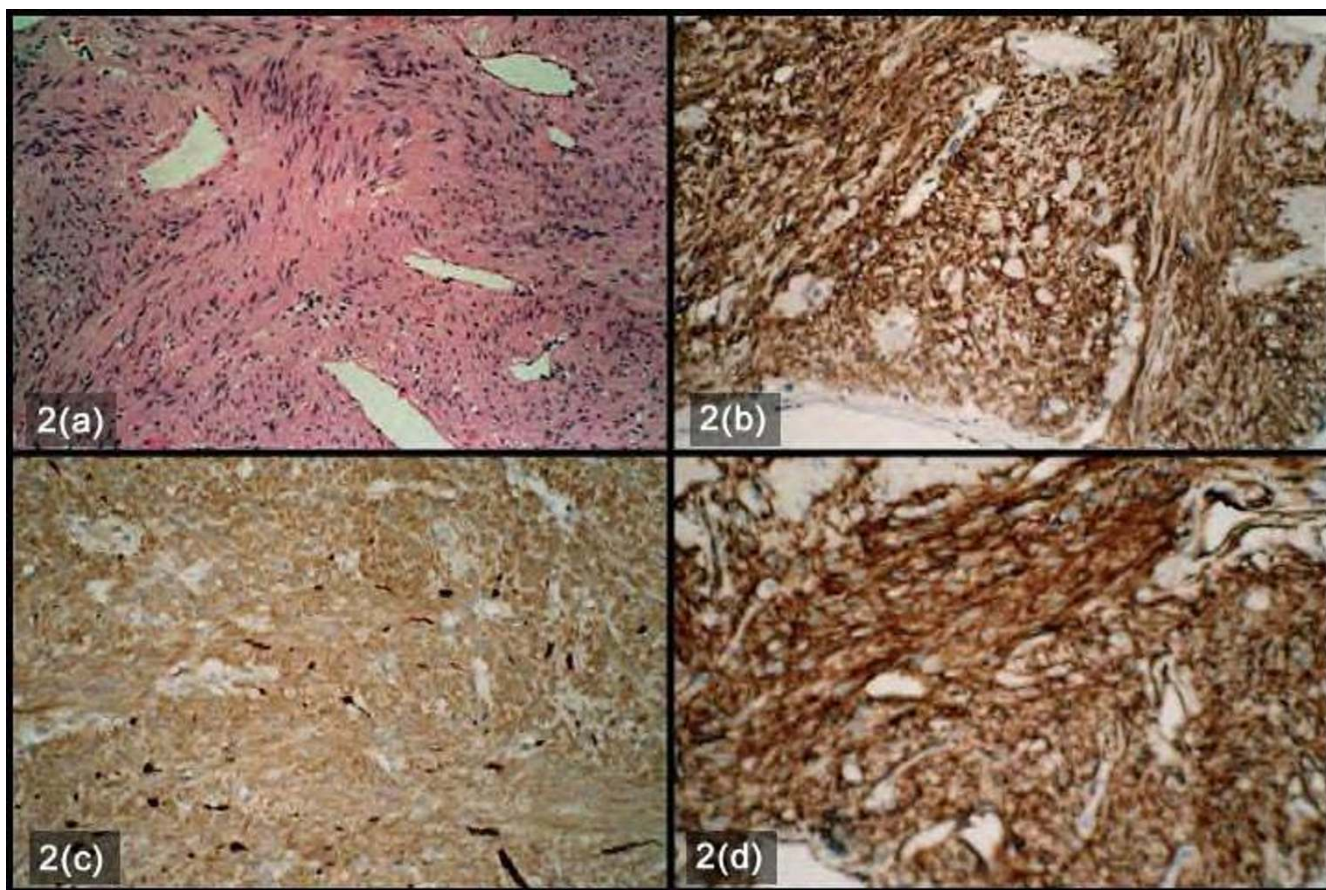


Figure 2

Photomicrograph showing Gastrointestinal stromal tumours a) Bland spindle cells arranged in a storiform pattern set within muscle wall with no necrosis, mitotic figures or pleomorphism seen. (Haematoxylin and Eosin $\times 100$) b) Positive staining with CD 117 ($\times 100$) c) Negative staining with S100 ($\times 100$) d) Positive staining with CD34 ($\times 100$)

desmin, smooth muscle actin and calponin. These features were of benign gastrointestinal stromal tumours.

Postoperative period was uneventful. The patient was offered adjuvant therapy but refused it. Local recurrence was detected at one-year follow-up.

Discussion

Gastrointestinal (GI) involvement in von Recklinghausen's disease occurs in three principal forms i) hyperplasia of the submucosal and myenteric nerve plexuses and mucosal ganglioneuromatosis, which leads to disordered gut motility; ii) gastrointestinal stromal tumours showing varying degrees of neural or smooth muscle differentiation; and iii) a distinctive glandular, somatostatin-rich carcinoid in periampullary region of the duodenum that contains psammoma bodies and may be associated with pheochromocytoma. NF-1 gene mutations involve

GTPase activating protein-coding sequences. Aberrations in other parts of NF1 gene, or in other genes, may also be involved in the development of the varied clinical manifestations.

GISTs are the most common mesenchymal tumours of the gastrointestinal (GI) tract. They are defined as c-kit (CD117, stem cell/ mast cell growth factor receptor)-positive mesenchymal spindle cell, epithelioid or rarely pleomorphic neoplasms arising primarily in the gastrointestinal tract, omentum, and mesentery [8]. A distinctive histological finding, principally in lesions of the small intestine, is presence of scattered eosinophilic bodies that range from 35 to 50 μm in size. These stain with PAS and Masson's trichrome, and are interpreted as skeinoid fibres, the distinctive extracellular collagen globules originally described by Min [9]. Tumours with a high mitotic index (>5 mitoses/10 HPF), measuring more than

5 cms in diameter and extra-gastrointestinal spread are considered malignant [10,11]. DNA studies show benign tumours to be euploid while the malignant tumours are aneuploid [12]. Intra-abdominal spread or liver metastasis occurs in 10%–30%.

The association of GIST with NF-1, skeinoid fibres and an ultrastructure suggestive of partial neural differentiation, could indicate a mixed neural ICC related phenotype or the possibility of ICC having neural phenotype [4]. GISTs differ clinically and pathogenetically from true leiomyosarcomas (rare in the GI tract) and leiomyomas. The latter occur in the GI tract, predominantly in the oesophagus (intramural tumours) and the colon and rectum (muscularis mucosae tumours). GISTs differ histologically, immunohistochemically and genetically from typical (oesophageal) leiomyomas that are negative for c-kit and CD34 and show neither DNA-loss at 14q, nor c-kit mutations. Schwannomas on the other hand are S100-positive benign spindle cell tumours and usually occur in stomach. GI autonomic nerve tumours (GANTs) are probably a subset of GIST, while angiosarcomas and metastatic melanomas, both of which are often c-kit positive should not be confused with GISTs [13].

Niv Y *et al* have reported a case of pancreatic cancer, duodenal cancer and liver metastasis in a patient with neurofibromatosis [14]. Though biopsies from all these lesions showed adenocarcinoma, the organ of origin could not be ascertained in their study [14]. Management of synchronous tumours present as a diagnostic and therapeutic dilemma, it is important to accurately distinguish between GIST, carcinoid tumours, and adenocarcinoma as the prognosis of these tumours differs significantly. Small benign tumours are often found incidentally during unrelated surgery or autopsy [15] as in the present case. As the occurrence is rare the optimal management still eludes surgeons.

References

- Riccardi VM: **Von Recklinghausen neurofibromatosis.** *N Engl J Med* 1981, **305**:1617-1627.
- Martin GA, Viskochil D, Bollag G, McCabe PC, Crosier WJ, Haubruck H, Conroy L, Clark R, O'Connell P, Cawthon RM: **The GAP-related domain of the neurofibromatosis type I gene product interacts with ras p21.** *Cell* 1990, **63**:843-890.
- Fuller CE, Williams GT: **Gastrointestinal manifestations of type I neurofibromatosis (von Recklinghausen's disease).** *Histopathology* 1991, **19**:1-11.
- Boldorini R, Tosoni A, Leutner M, Ribaldone R, Surico N, Comello E, Min KW: **Multiple small intestinal stromal tumours in a patient with previously unrecognised neurofibromatosis type I: immunohistochemical and ultrastructural evaluation.** *Pathology* 2001, **33**:390-395.
- Sircar K, Hewlett BR, Huizinga JD, Chorneyko K, Berezin I, Riddell RH: **Interstitial cells of Cajal as precursors of gastrointestinal stromal tumours.** *Am J Surg Pathol* 1999, **23**:377-389.
- Hirota S, Koji I, Moriyama Y, Hashimoto K: **Gain of function mutations of c-kit in human gastrointestinal stromal tumors.** *Science* 1998, **279**:577-580.
- Karatzas G, Kouraklis G, Karayiannakis A, Patapis P, Givalos N, Kaperonis E: **Ampullary carcinoid and jejunal stromal tumour associated with von Recklinghausen's disease presenting as gastrointestinal bleeding and jaundice.** *Eur J Surg Oncol* 2000, **26**:428-429.
- Miettinen M, Lasota J: **Gastrointestinal stromal tumours (GISTs): definition, occurrence, pathology, differential diagnosis and molecular genetics.** *Pol J Pathol* 2003, **54**:3-24.
- Min KW: **Small intestinal stromal tumours with skeinoid fibres: clinicopathologic, immunohistochemical, and ultrastructural investigations.** *Am J Surg Pathol* 1992, **16**:145-155.
- Adani GL, Marcello D, Sanna A, Mazzetti J, Anania G, Donini A: **Gastrointestinal stromal tumours: evaluation of biological and clinical current opinions.** *Chir Ital* 2002, **54**:127-131.
- Fletcher CD, Berman JJ, Corless C, Gorstein F, Lasota J, Longley BJ, Miettinen M, O'Leary TJ, Remotti H, Rubin BP, Shmookler B, Sobin LH, Weiss SW: **Diagnosis of gastrointestinal stromal tumours: a consensus approach.** *Int J Surg Pathol* 2002, **10**:81-89.
- Sapi Z, Kovacs RB, Bodo M: **Gastrointestinal stromal tumours. Observations on the basis of 29 cases.** *Orv Hetil [Hungarian]* 2001, **142**:2479-2485.
- Miettinen M, Lasota J: **Gastrointestinal stromal tumours – definition, clinical, histological, immunohistochemical, and molecular genetic features and differential diagnosis.** *Virchows Arch* 2001, **438**:1-12.
- Niv Y, Abu-Avid S, Oren M: **Adenocarcinoma of pancreas and duodenum associated with cutaneous neurofibromatosis.** *Am J Med* 1987, **82**:384-385.
- Miettinen M, Majidi M, Lasota J: **Pathology and diagnostic criteria of gastrointestinal stromal tumours (GISTs): a review.** *Eur J Cancer* 2002, **38**(Suppl 5):S39-S51.

Publish with **BioMed Central** and every scientist can read your work free of charge

"BioMed Central will be the most significant development for disseminating the results of biomedical research in our lifetime."

Sir Paul Nurse, Cancer Research UK

Your research papers will be:

- available free of charge to the entire biomedical community
- peer reviewed and published immediately upon acceptance
- cited in PubMed and archived on PubMed Central
- yours — you keep the copyright

Submit your manuscript here:
http://www.biomedcentral.com/info/publishing_adv.asp

