

Small Mouths ... Big Problems? A Review of Scleroderma and its Oral Health Implications

Jonathan B. Albilis, DMD; David K. Lam, DDS; Nick Blanas, BSc, DDS, FRCD(C); Cameron M.L. Clokie, DDS, PhD, FRCD(C); George K.B. Sándor, MD, DDS, PhD, FRCD(C), FRCSC, FACS

Contact Author

Dr. Sándor
Email: george.sandor@utoronto.ca



ABSTRACT

Scleroderma, or progressive systemic sclerosis (PSS), an autoimmune rheumatic condition affecting the connective tissues, has a profound impact on oral health. Common orofacial findings include xerostomia, gastroesophageal reflux disease and limited mouth opening. This review article describes scleroderma, or PSS, and its various manifestations. The features of CREST syndrome and morphea are reviewed. Concerns relevant to the prevention of dental disease and the safe delivery of dental care in this group of challenging patients are emphasized.

For citation purposes, the electronic version is the definitive version of this article: www.cda-adc.ca/jcda/vol-73/issue-9/831.html

Scleroderma originates from the Greek words *skleros*, meaning “hard,” and *derma*, meaning “skin.” Scleroderma is the initial manifestation of a disease process better described as progressive systemic sclerosis (PSS), which was named by Goetz in 1945.¹ PSS, one of a group of chronic autoimmune diseases that includes systemic lupus erythematosus and Sjögren’s syndrome, can be subdivided into systemic sclerosis (SS) and localized sclerosis. PSS occurs more commonly in women (estimated female to male ratio, 4:1), and the age of peak onset is 30 to 50 years.² In the United States, the estimated prevalence of SS is 400 per million women between the ages of 35 and 65 years.² Although SS is an uncommon autoimmune rheumatic condition affecting connective tissues, it presents great challenges to both medical and dental professionals and has a profound impact on oral health. The current article reviews the important features of PSS, including its patho-

genesis and clinical findings, and recommends ways dental practitioners can manage their patients with this disease.

Pathogenesis

PSS is a systemic disease that affects many organ systems, including the skin, gastrointestinal tract, and respiratory, renal, cardiovascular and genitourinary systems. The onset of the subtype SS is usually insidious; its most dramatic effects are cutaneous changes. Progressive tissue fibrosis ensues as normal types I and III collagen are deposited in extraordinary amounts, likely because of immunologically overactivated fibroblasts in various locations. There is a quantitative increase in the amorphous ground substance, glycosaminoglycans and fibronectin, within the connective tissues.³ Vascular alterations may affect the small arteries and arterioles, resulting in thickening of the vessel walls and reduction of the diameter of the lumen.

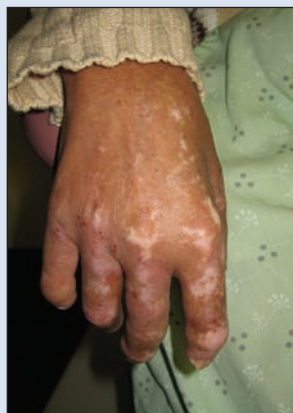

Figure 1: Hand sclerosis with associated hypopigmentation. Also noticeable are telangiectasias.

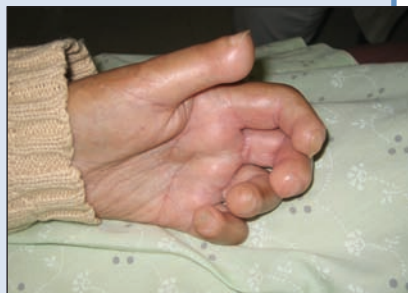

Figure 2: Sclerodactyly with fusiform swelling of the thumb and flexion contractures of fingers.

and slightly pigmented skin. These skin patches can be localized, limited to one or several well-circumscribed plaques; or generalized, symmetrically involving the trunk and limbs.⁵ Involvement of visceral organs is uncommon. However, Raynaud’s phenomenon, a vasoconstrictive event that may be triggered by emotional upset or exposure to cold, is quite common and accounts for the initial presentation of 70% of all patients with localized scleroderma. In comparison, in 95% of cases of PSS, Raynaud’s phenomenon occurs at some point in the disease process.

PSS and SS

The extent of skin and internal organ involvement forms the basis of the classification of PSS.⁶ The skin sclerosis score is key to the classification of the subtype SS.⁷ SS is generally subdivided into limited and diffuse cutaneous subtypes. Patients with limited cutaneous SS typically have skin sclerosis that is restricted to the hands, and sometimes the face and neck (Fig. 1). They also have prominent vascular manifestations and frequently exhibit features of CREST syndrome (Fig. 2; Table 2).

Patients with diffuse cutaneous SS have extensive skin indurations and are at greater risk for developing significant renal, lung and cardiac fibroses. Cutaneous sclerosis proximal to the wrists, also involving the proximal limbs and torso, but sparing the upper back, is central to the diagnosis of the diffuse form. In addition, any of the 5 features of the CREST syndrome may be present.

For a diagnosis of SS, a patient must fulfill either the 1 major criterion or 2 minor criteria outlined by the American College of Rheumatology for the classification of SS⁸ (Table 3).

All in all, the spectrum of severity and prognosis for this disease process, worsening from left to right, is as follows:

Localized SS ⇒ CREST syndrome or limited SS ⇒ diffuse SS

An exceedingly rare form, SS sine scleroderma, spares the skin, but is characterized by typical vascular features and fibrosis of the visceral organs. Environmental triggers such as vinyl chloride, epoxy resins, pesticides and paint solvents, or drugs such as bleomycin, are responsible for diffuse cutaneous sclerosis.⁷ Whether withdrawal of the causative agent resolves the scarring in this environmentally induced subtype is questionable.

Patients who have features of SS and other rheumatic diseases, such as systemic lupus erythematosus or

Table 1 Classification system for scleroderma, or progressive systemic sclerosis

Localized scleroderma
Linear scleroderma
Localized morphea
Generalized morphea
Systemic sclerosis (SS)
Limited cutaneous SS
Diffuse cutaneous SS
SS sine scleroderma
Environmentally induced scleroderma
Overlap syndromes

Vascular dysfunction is one of the earliest alterations found in those with PSS and may represent the initiating event in its pathogenesis, similar to that of many other rheumatic diseases.⁴

Clinical Presentation

Classification

Patients with PSS may have a wide array of clinical presentations. The current classification of PSS is based on the extent and pattern of skin sclerosis and reflects the extent of the involvement of organ systems; however this is not highly specific (Table 1). Future classification systems may correlate serologic predictors of disease manifestation with prognosis.

Localized Scleroderma

Localized scleroderma may be linear and is typically located on the midline of the forehead. Often resembling a healed scar from the strike of a sword, this form of scleroderma is commonly called the “coup de sabre.” Morphea are sclerotic patches of hardened, dry, smooth

Table 2 Features of CREST syndrome

Characteristic	Description
Calcinosis cutis	Calcific deposits, usually within the dermis in the extremities and bony prominences, also in deeper periarticular tissues around or within the joints
Raynaud's phenomenon	Triphasic colour changes in the following order: pallor, cyanosis and erythema, representing vasoconstriction, reduced blood flow and reperfusion, respectively
Esophageal dysmotility	Earliest change in the distal esophagus (primarily smooth muscle); an uncoordinated disorganized pattern of contractions resulting in low amplitude or no peristalsis
Sclerodactyly	Fibrosis of the skin of the fingers or toes, commonly associated with atrophy and ulcerations of the fingertips
Telangiectasias	Nonpulsatile macular areas of hemorrhage, representing close approximation of small vessels

rheumatoid arthritis, have an overlap syndrome. This heterogeneous group of patients suggests that common etiologic and pathogenetic processes underlie several rheumatic diseases.⁹

Physical Findings

Esophageal Dysmotility

Esophageal dysmotility is the most prominent visceral manifestation of PSS, predisposing these persons to gastroesophageal reflux disease (GERD), which may be diagnosed first by a dental practitioner. The dental practitioner may then refer the patient to a gastroenterologist for a ph-Probe Test.¹⁰ A barium swallow test is then used to identify hypomotility of the esophagus. Chronic GERD is an important risk factor for aspiration pneumonitis, and potentially pneumonia, and increases the risk of Barrett metaplasia, which in turn increases the risk of esophageal cancer.¹⁰ The resultant acidic environment within the oral cavity erodes enamel and dentin, making the dentition highly susceptible to caries. In extreme end-stage cases, when deglutition is impossible, a gastrostomy or percutaneous endogastric tube may be necessary for life-sustaining feeding.

Table 3 Criteria of the American College of Rheumatology for the classification of progressive systemic sclerosis⁸

Major criterion
Scleroderma proximal to the fingers (metacarpophalangeal joints) or toes (metatarsophalangeal joints)
Minor criteria
Sclerodactyly
Digital pitting or necrosis at the fingertips
Bibasilar pulmonary fibrosis

Pulmonary Disease

Pulmonary disease, the second-most common systemic manifestation of PSS, is documented in over 70% of these patients. Mortality from PSS-associated lung disease has surpassed that of renal disease.¹¹ Pulmonary changes in persons with PSS are consistent with those of restrictive lung disease. Typical changes include interstitial lung disease, which results in irreversible alveolar scarring very similar to that seen in patients with pneumoconiosis or miner's lung. Eventually pulmonary vascular disease develops and results in pulmonary arterial hypertension and subsequent right-sided myocardial hypertrophy (cor pulmonale). For reasons that are unclear, the incidence of lung cancer is higher in patients with PSS.¹²

Physical findings in a person with "stiff" lungs or restrictive lung disease include shortness of breath or dyspnea initially upon exertion, fatigue and dry cough. On auscultation, crackles that are Velcro-like sounds may be heard across both lung bases on inspiration.¹³ A pre-operative chest radiograph may show diffuse and symmetric opacities in a reticulonodular pattern. Pulmonary function tests will confirm PSS-associated lung damage with reduced lung volumes, including reduced functional residual capacity, residual volume and total lung capacity. In well-established disease, spirometric testing will show a reduction in the forced expiratory volume in one second, or FEV_{1.0}, and forced vital capacity.

Renal Disease

Severe and life-threatening renal disease develops in 10% to 15% of patients with PSS. This form of renal involvement is called "scleroderma renal crisis" and is characterized by significant arteriole thickening and constriction, and interstitial collagen deposition, resulting in acute renal failure, marked hypertension and mild proteinuria. Patients who have scleroderma without acute renal failure also have physiologic evidence of compromised renal function,¹⁴ which can be estimated readily from the measurement of serum creatinine levels.

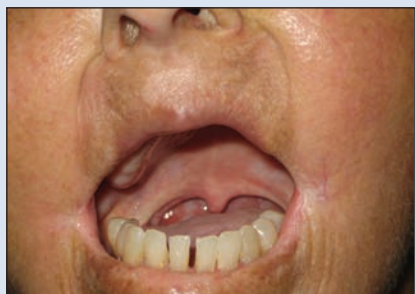

Figure 3a: Patients in Figs. 3a and 3b have varying degrees of microstomia and mask-like facies. Note upward retraction and shortening of uvula from underlying scar tissue in this patient.

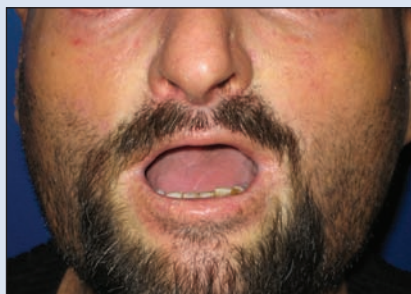


Figure 3b: Dense perioral fibrosis causes severe trismus and microstomia, which make the provision of oral care in this group of patients extremely challenging for the dental professional.

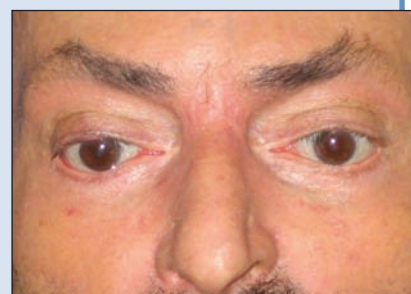

Figure 4: Widened palpebral fissures that the patient is unable to close, causing lagophthalmus, which contributes to further drying of the eyes.

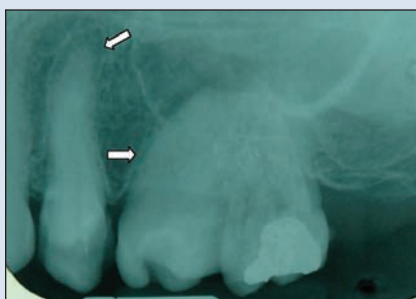

Figure 5a: Signs of early widening of the periodontal ligament space is noticeable around tooth 25.

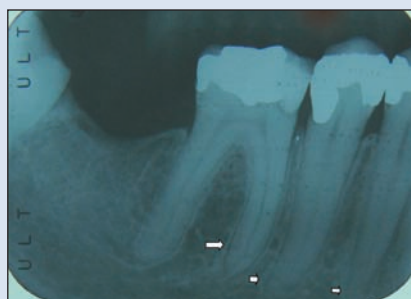


Figure 5b: Widening of the periodontal ligament space is noticeable around the distal root of tooth 46.

Musculoskeletal

Patients may have generalized arthralgias and morning stiffness that may mimic other systemic autoimmune diseases. Hand and joint function may decline over time because of skin tightening, rather than arthropathy, and may have a negative impact on daily activities, including maintenance of oral hygiene.

Orofacial Findings

Common orofacial findings are summarized in **Box 1**. Subcutaneous collagen deposition in facial skin results in a characteristic smooth, taut, mask-like facies (**Figs. 3a** and **3b**). Nasal alae may become atrophied and result in “mouse-like” facies and a nose that appears pinched. Other important orofacial manifestations include fibrosis of the salivary and lacrimal glands, and symptoms consistent with dry mouth or xerostomia. Patients may develop dry eyes with keratoconjunctivitis sicca or xerophthalmia. This is particularly problematic because scarring of the eyelids results in a chronic widening of the palpebral fissures and inadequate closure of the eyelid, which causes further drying of already dry eyes (**Fig. 4**). Inadequate salivary flow compro-

ises buffering within the oral cavity and allows the acidity produced by bacterial metabolism and GERD to erode the dentition. Classic dental radiographic findings of PSS show a thickening of the periodontal ligament or periodontal ligament space (**Figs. 5a** and **5b**). A blunting of the angles of the mandible, resembling a “tail of the whale,” may be seen on an orthopantomograph (**Fig. 6**). Infrequently, pathologic fractures of the mandible may develop from the mandibular resorption.

Further, facial and mucosal fibrosis compromises oral access because of microstomia (**Figs. 3a** and **3b**), which limits mouth opening in 70% of these patients.¹⁵ As a consequence, oral hygiene and fabrication of removable dentures are difficult because of limited access and the obliteration or shallowing of the mucobuccal folds.

Histopathologic Features

Histologic Findings

Microscopy reveals diffuse deposition of dense collagen within and around the normal structures of patients with PSS. This abnormal collagen replaces and

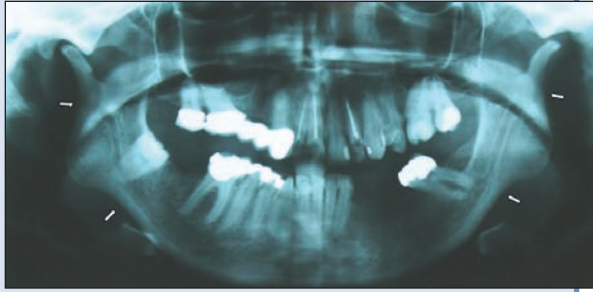


Figure 6: Although blunting of the angles (typical of the “tail of the whale” pattern) of the mandible is not present in this case, there is prominent resorption of the posterior border of the rami and condyles, as well as increased prominence of the antegonial notches.

Box 1 Common orofacial findings for scleroderma, or progressive systemic sclerosis

- Mask-like or “mouse” facies
- Widened palpebral fissures
- Xerophthalmia
- Xerostomia
- Gastroesophageal reflux disease
- Thickened periodontal ligament and blunting of mandibular angles on dental radiographs
- Microstomia
- Poor oral hygiene
- Pathologic mandibular fracture

destroys normal tissue and results in the loss of normal tissue function.¹⁵

Laboratory Investigations

Anticentromere antibodies are associated with more limited forms of scleroderma or CREST syndrome, and anti-Scl 70 (topoisomerase I) antibodies are seen more often with PSS.¹⁵ Increasing levels of endothelial-cell autoantibodies correlate with disease severity.

Differential Diagnosis

Since PSS is often difficult to diagnose during the early phases of the disease, a number of conditions must be considered in the differential diagnosis of scleroderma, or PSS, that may cause similar clinical features. In general, conditions that may mimic PSS can be grouped as immunological or inflammatory (e.g., chronic graft-versus-host disease, eosinophilic fasciitis), metabolic (e.g., acromegaly, amyloidosis), inherited (e.g., phenylketonuria, porphyrias) or localized (e.g., idiopathic pulmonary fibrosis, sarcoidosis, esophageal hypomotility syndromes).⁸

Treatment

Although much of the fibrosis caused by the disease process of PSS is irreversible, current therapies are aimed at halting or limiting further progression.

Skin sclerosis is often treated with D-penicillamine, a chelating agent that affects unknown mechanisms of collagen formation. Experimental drugs, such as interferon-gamma and cyclophosphamide, and photophoresis have been used with varying degrees of success. Management of the systemic effects of this disease is not well established, although some large uncontrolled series suggest that D-penicillamine has beneficial effects.¹⁶ Interferon-gamma is effective, but its use is limited because of inflammatory sequelae.

Raynaud’s phenomenon can be treated with calcium channel blockers, prazosin, prostaglandin derivatives such as prostaglandin E1, aspirin and topical nitrates. In uncontrollable cases when digital loss is plausible, patients may benefit from pharmacologic cervical sympathectomy or from surgical digital sympathectomy to ablate sympathetic innervation to these end arterioles. Amputation of the involved digits may be indicated if severe ischemia and infection occur. Control of operatory temperature and patient comfort are crucial for preventing cold- or stress-induced vasospasm in the dental setting.¹⁶

GERD is managed with antacids, H2 blockers, proton-pump inhibitors, prokinetic agents, smaller meals and laxatives.¹⁰

Pulmonary alveolitis or fibrosis is sometimes treated with cyclophosphamide. When pulmonary function is compromised, supplemental oxygenation is indicated during dental procedures. Bosentan, a vasodilator, is effective for treatment of pulmonary hypertension associated with PSS, and has resulted in substantial clinical and hemodynamic improvement in patients with SS-associated pulmonary hypertension.¹⁷

Renal crises are managed with aggressive use of angiotensin-converting enzyme inhibitors at the earliest signs of hypertension.

Hand surgery may be done to correct severe sclerodactyly or flexion contractures. Removal of severely painful, draining or infected calcinotic deposits is occasionally required.

Large dietary doses of vitamin C (> 1 g/day) should be avoided by patients with PSS since vitamin C is integral to collagen formation and deposition.

Patients with limited range of motion and mouth opening can benefit from regular physical and occupational therapy to maintain range of motion and to minimize or delay contractures. Rarely, patients may benefit from bilateral commissurotomy to increase the width of their mouth.

Instruction in and reinforcement of oral hygiene, along with frequent dental checkups and oral hygiene

appointments, are vital for the maintenance of oral health. Depending on the extent of the disease process and the organs affected, modifications of local anesthetics, prescription medications and treatment techniques may be necessary.

Prognosis

Survival of people with PSS mainly depends on the subtype of the disease. Limited cutaneous SS has a 10-year survival rate of 71%; diffuse cutaneous SS, 21%.¹⁸ Pulmonary hypertension and scleroderma renal crisis are important prognostic predictors.¹⁹

Conclusion

Since the mouth is often a mirror of the systemic health of the rest of the body, dental practitioners may be the first to note some of the signs of PSS. The concomitant presence of GERD, xerostomia and limited mouth opening may alert practitioners to the possibility of scleroderma. Instruction in and reinforcement of oral hygiene, along with frequent dental assessment and management by the dental practitioner are essential measures to preserve the oral health of those affected with PSS. Special care and attention must be paid to keeping the surrounding environment in the dental operatory warm for patients who have vasospasms to help avoid a vascular crisis. Patients with severe restrictive lung disease may require supplemental oxygen. Dentists must react decisively when they see signs of GERD, especially in combination with xerostomia and limited mouth opening, because the remaining dentition is particularly at risk. ♦

THE AUTHORS



Dr. Albilá is a resident in the division of oral and maxillofacial surgery and anesthesia, Mount Sinai Hospital, University of Toronto, Toronto, Ontario.



Dr. Lam is senior resident, division of oral and maxillofacial surgery and anesthesia, Mount Sinai Hospital; PhD Harron Scholar, Collaborative Program in Neuroscience; clinician-scientist fellow, University of Toronto Centre for the Study of Pain; University of Toronto, Toronto, Ontario.



Dr. Blanas is staff oral and maxillofacial surgeon, Sunnybrook Health Sciences Centre and faculty of dentistry, University of Toronto, Toronto, Ontario.



Dr. Clokie is professor and head, oral and maxillofacial surgery and anesthesia, University of Toronto, Toronto, Ontario.



Dr. Sándor is clinical director, graduate program in oral and maxillofacial surgery and anesthesia, Mount Sinai Hospital; coordinator, pediatric oral and maxillofacial surgery, The Hospital for Sick Children and Bloorview Kids Rehab; professor of oral and maxillofacial surgery, University of Toronto, Toronto, Ontario; professor, Regea Institute for Regenerative Medicine, University of Tampere, Tampere, Finland; and docent in oral and maxillofacial surgery, University of Oulu, Oulu, Finland.

Correspondence to: Dr. George K.B. Sándor, The Hospital for Sick Children, S-525, 555 University Ave., Toronto ON M5G 1X8.

The authors have no declared financial interests.

This article has been peer reviewed.

References

- Goetz RH. Pathology of progressive systemic sclerosis with special reference to changes in the viscera. *Clin Proc (S. Africa)* 1945; 4(6):337–42.
- Steen VD, Medsger TA Jr. Epidemiology and natural history of systemic sclerosis. *Rheum Dis Clin North Am* 1990; 16(1):1–10.
- Kuroda K, Shinkai H. Decorin and glycosaminoglycan synthesis in skin fibroblasts from patients with systemic sclerosis. *Arch Dermatol Res* 1997; 289(8):481–5.
- Kowal-Bielecka O. Targeting vascular disease in systemic sclerosis. *Endocr Metab Immune Disord Drug Targets* 2006; 6(4):401–7.
- Falanga V. Localized scleroderma. *Med Clin North Am* 1989; 73(5):1143–56.
- Black CM. Scleroderma — clinical aspects. *J Intern Med* 1993; 234(2):115–8.
- Black CM. Measurement of skin involvement in scleroderma. *J Rheumatol* 1995; 22(7):1217–9.
- American Rheumatism Association Diagnostic and Therapeutic Criteria Committee. Preliminary criteria for the classification of systemic sclerosis (scleroderma). Subcommittee for scleroderma criteria of the American Rheumatism Association Diagnostic and Therapeutic Criteria Committee. *Arthritis Rheum* 1980; 23(5):581–90.
- Ramos-Casals M, Brito-Zeron P, Font J. The overlap of Sjogren's syndrome with other systemic autoimmune diseases. *Semin Arthritis Rheum* 2007; 36(4):246–55. Epub 2006 Sep 22.
- Barron RP, Carmichael RP, Marcon MA, Sandor GK. Dental erosion in gastroesophageal reflux disease. *J Can Dent Assoc* 2003; 69(2):84–9.
- Ferri C, Valentini G, Cozzi F, Sebastiani M, Michelassi C, La Montagna G, and others. Systemic sclerosis: demographic, clinical, and serologic features and survival in 1,012 Italian patients. *Medicine (Baltimore)* 2002; 81(2):139–53.
- Winkelmann RK, Flach DB, Unni KK. Lung cancer and scleroderma. *Arch Dermatol Res* 1988; 280 Suppl:S15–8.
- Zeuner M, Muller-Ladner U, Mohr VD, Lang B. Spontaneous pneumothorax in a patient with systemic sclerosis. *Clin Rheumatol* 1996; 15(2):211–3.
- Livi R, Teghini L, Pignone A, Generini S, Matucci-Cerinic M, Cagnoni M. Renal functional reserve is impaired in patients with systemic sclerosis without clinical signs of kidney involvement. *Ann Rheum Dis* 2002; 61(8):682–6.
- Neville BW, Damm DD, Allen CM, Bouquet JE. *Oral and maxillofacial pathology*. 2nd ed. Philadelphia: W.B. Saunders Co.; 2002. p. 137.
- Stone JH, Wigley FM. Management of systemic sclerosis: the art and science. *Semin Cutan Med Surg* 1998; 17(1):55–64.
- Hachulla E, Coghlan JG. A new era in the management of pulmonary arterial hypertension related to scleroderma: endothelin receptor antagonism. *Ann Rheum Dis* 2004; 63(9):1009–14.
- Barnett AJ, Miller MH, Littlejohn GO. A survival study of patients with scleroderma diagnosed over 30 years (1953-1983): the value of a simple cutaneous classification in the early stages of the disease. *J Rheumatol* 1988; 15(2):276–83.
- Trad S, Amoura Z, Beigelman C, Haroche J, Costedoat N, Boutin le TH, and others. Pulmonary arterial hypertension is a major mortality factor in diffuse systemic sclerosis, independent of interstitial lung disease. *Arthritis Rheum* 2006; 54(1):184–91.