

Small Symptomatic Pericardial Diverticula Treated by Video-Assisted Thoracic Surgical Resection

Tadashi Akiba, MD, PhD,¹ Hideki Marushima, MD,¹ Masataka Masubuchi, MD, PhD,² Susumu Kobayashi, MD, PhD,¹ and Toshiaki Morikawa, MD, PhD³

There have been few reports about symptomatic pericardial diverticula. We describe 2 patients of symptomatic pericardial diverticula whose symptoms were relieved after surgery. The first patient complained of severe left anterior chest pain for a period of 6 months, and a pericardial diverticulum 4 × 3 cm in size was detected on the right side of the ascending aorta opposite the symptomatic side. The second patient complained of right anterior chest pain for a few months, and a pericardial diverticulum 6 × 2 cm in size was detected on the right side of the heart. Although these cysts did not appear large enough to cause symptoms, the patients underwent thoracoscopic resection. The postoperative course in each patient was uneventful, and the symptoms were relieved. We recommend that a symptomatic anterior mediastinal cyst be completely resected even if it does not appear large enough to compress the neighboring organs. (Ann Thorac Cardiovasc Surg 2009; 15: 123–125)

Key words: pericardial diverticulum, pericardial cyst, video-assisted thoracic surgery, symptomatic

Introduction

Pericardial cysts are a relatively rare disease entity, which are reported to be asymptomatic or to have fewer symptoms than other mediastinal tumors. We report 2 cases of pericardial cysts that did not appear to be large enough to cause symptoms. However, both patients complained of chest pain and had opted for surgical treatment. After video-assisted thoracic surgery (VATS), their symptoms were unexpectedly relieved. Here, we report these 2 cases and review the literature of pericardial diverticula.

From ¹Department of Surgery, Kashiwa Hospital, Jikei University School of Medicine, Kashiwa; ²Atsugi City Hospital, Atsugi; and ³Division of General Thoracic Surgery, Jikei University School of Medicine, Tokyo, Japan

Received February 20, 2008; accepted for publication March 18, 2008

Address reprint requests to Tadashi Akiba, MD, PhD: Department of Surgery, Kashiwa Hospital, Jikei University School of Medicine, 163-1 Kashiwashita, Kashiwa, Chiba 277-8567, Japan.
©2009 The Editorial Committee of *Annals of Thoracic and Cardiovascular Surgery*. All rights reserved.

Case Reports

Case 1

A 75-year-old male suffering from hypertension and angina pectoris for 10 years was referred to our hospital for an abnormal chest shadow. He complained of severe left parasternal chest pain, persisting for 5 months; however, physical examination showed no abnormal findings. Stress electrocardiogram and echocardiogram also showed no abnormalities. A chest roentgenogram revealed a protruding shadow on the right side of the heart opposite his symptom. A chest computed axial tomography (CAT) scan with contrast medium revealed a mediastinal tumor 4 × 3 cm in size without enhancement on the right side of the ascending aorta (Fig. 1). A magnetic resonance imaging (MRI) scan revealed bright signal intensity in T2-weighted images, which was then radiologically diagnosed as an anterior mediastinal cyst. The patient underwent VATS; the cyst was located posterior to the right thymus and was communicated to the pericardium at the right side of the ascending aorta. It was pathologically diagnosed as a pericardial diverticulum whose wall was thickened and contained inflamma-

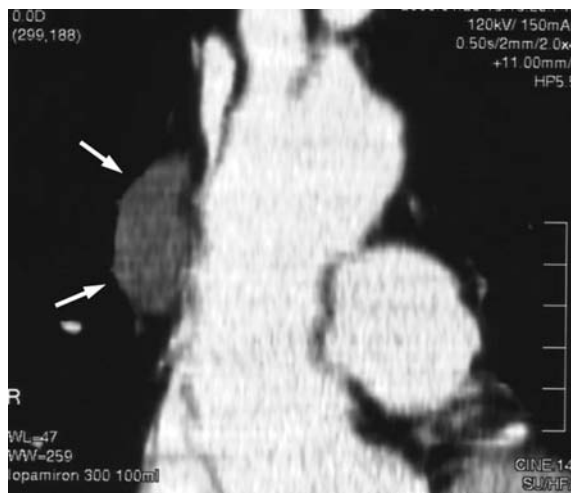

Fig. 1. Case 1.
Chest axial tomography with enhancement shows a semicircular cyst on the right side of the ascending aorta.

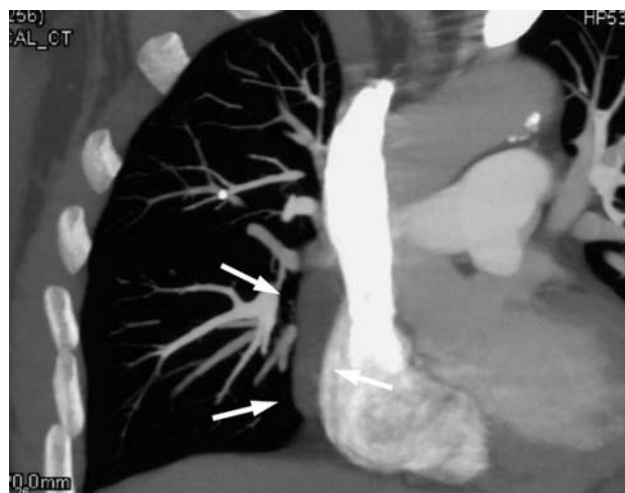


Fig. 2. Case 2.
Chest axial tomography with enhancement shows a flat cyst on the right side of the right atrium.

tory cells. The postoperative course was uneventful, and the patient was discharged on the eighth postoperative day. His symptoms were relieved after the surgery.

Case 2

A 55-year-old male was referred to our hospital for an abnormal chest shadow. He complained of chest discomfort and pain persisting for 3 months. Physical examination revealed no abnormal findings, and blood and laboratory examinations were within normal limits except for a slightly elevated C-reactive protein level (1.1 mg/dL). Chest roentgenogram showed no abnormal shadow, but a CAT scan revealed a flat shadow on the right side of the heart (Fig. 2). An MRI confirmed the presence of a pericardial cyst. The patient underwent VATS, and a pericardial cyst 6 × 2 cm in size was found adhered to the pericardium and the upper lung and also communicating with the pericardium. It was completely resected and diagnosed as a pericardial diverticulum with infiltration of inflammatory cells. The postoperative course was uneventful, and the patient was discharged on the fifth postoperative day. His symptoms were completely relieved after the surgery.

Discussion

Pericardial cysts are formed secondary to persistence of the ventral parietal recess. Constriction of the diverticular neck of the recess or complete obliteration of the neck

results in a mesothelial lined cyst.¹⁾ Persistence of the parietal recess during development results in aberrant recess fusion; therefore the pericardial diverticulum, which communicates with the pericardial cavity, is regarded as an incomplete form of a pericardial cyst in terms of its embryonic development.²⁾

Mesothelial cysts, including pericardial and pleural cysts, are estimated to occur in approximately 1 in 100,000 cases.³⁾ Cysts of the mediastinum, which are benign masses, represent 12%–18% of all primary mediastinal tumors, and pericardial cysts represent 13%–17% of all mediastinal cysts.^{2,4)}

There have been some reports of symptomatic pericardial cysts with recurrent chest pain,⁵⁾ cough and dyspnea,⁶⁾ and odynophagia.⁷⁾ Pericardial cysts usually follow a benign course, though complications have been reported, such as cyst rupture, cardiac tamponade, and even sudden death.⁸⁾ le Roux et al. reported that only 20% of all pericardial cysts are symptomatic, usually with dyspnea or chest discomfort.⁹⁾ Interestingly, it has been observed that symptoms rarely dissipate following excision unless the cyst is of a significant size.⁹⁾ Takeda et al. reported that only 36% of all mediastinal cysts were symptomatic, and that pericardial cysts had a lower incidence of symptoms than other mediastinal cysts; however, 2 of 12 patients in that report had symptoms of chest pain.²⁾ In our experience, 10 of 24 patients with mediastinal cysts were symptomatic, and the symptoms of all 10 were relieved after surgery. Furthermore, 2 of 4

pericardial cysts were symptomatic with dysphagia and fever.⁴⁾ We have reported 2 cases here, each with a relatively small cyst, and related symptoms, of which 1 case experienced symptoms on the opposite side of the cyst. These 2 patients requested surgical resection of their cysts with the hope of relieving these symptoms. Since these cysts were too small to compress the neighboring organs, i.e., heart, lung, and chest wall, we doubted the likelihood of any relief. However, following surgery these symptoms were relieved completely.

MRI showed bright signal intensity in T2-weighted images and was useful in diagnosing cystic lesions. We are adopting CAT and MRI scans for diagnosing mediastinal cysts, even though MRI scans can sometimes be misleading in cases where the cyst contains mucinous fluid. In our cases, we could not preoperatively predict the cyst or diverticulum by use of the imaging technique, and the pericardial cysts were diagnosed when the cyst orifices to the pericardium were not detected.

Surgical intervention is not indicated for asymptomatic mediastinal cysts. The reason why a small cyst would cause symptoms remains elusive, especially because reports rarely confirm whether symptoms are relieved following an operation.¹⁰⁾ We suggest following up on the asymptomatic cases, and we suggest operations for symptomatic cases of pericardial cyst. A case of intermittent chest pain because of a volvulus was reported,⁵⁾ but our cases did not relate to this. We could not determine the etiology of pain in these patients, but suspected the likelihood of inflammation and adhesion of the mediastinal cyst to be responsible.

In terms of surgical procedures, thoracoscopic surgery has been adopted by many institutes. According to a report by Takeda et al., 68% of cysts since 1993 have been treated with VATS resection, and 3 patients with pericardial diverticula have undergone thoracoscopic fenestration.²⁾ According to the available records since 1995, 93% of mediastinal cysts have been resected thoracoscopically, and all 3 pericardial cysts were completely

resected.⁴⁾ If the patient is asymptomatic, fenestration could be used to reduce cyst volume, but we would prefer complete resection of the entire cyst, which should be excised after separation of the adhesions, especially for patients with symptoms whose etiologies are unclear.

Acknowledgment

This research was supported by the Jikei University Research Fund.

References

1. Lillie WI, McDonald JR, Clagett OT. Pericardial celomic cysts and pericardial diverticula; a concept of etiology and report of cases. *J Thorac Surg* 1950; **20**: 494–504.
2. Takeda S, Miyoshi S, Minami M, Ohta M, Masaoka A, et al. Clinical spectrum of mediastinal cysts. *Chest* 2003; **124**: 125–32.
3. Hynes JK, Tajik AJ, Osborn MJ, Orszulak TA, Seward JB. Two-dimensional echocardiographic diagnosis of pericardial cyst. *Mayo Clin Proc* 1983; **58**: 60–3.
4. Akiba T, Yamashita M, Noda T, Kurihara H, Sato S, et al. Mediastinal cyst resected with thoracotomy or thoracoscopy. *Jikeikai Med J* 2002; **49**: 121–5.
5. Waterbolk TW, Henkens CA, Remmert DG, van der Jagt EJ, Postmus PE. Pericardial diverticulum with unusual symptomatology. *Eur Respir J* 1991; **4**: 232–4.
6. Hanada S, Shirasawa B, Harada M, Ohnishi H, Tomozawa N, et al. Surgery for a pericardial diverticulum; report of a case. *Kyobu Geka* 2005; **58**: 487–90. (in Jpse.)
7. Santoro MJ, Ford LJ, Chen YK, Solinger MR. Odynophagia caused by a pericardial diverticulum. *Am J Gastroenterol* 1993; **88**: 943–4.
8. Patel J, Park C, Michaels J, Rosen S, Kort S. Pericardial cyst: case reports and a literature review. *Echocardiography* 2004; **21**: 269–72.
9. le Roux BT, Kallichurum S, Shama DM. Mediastinal cysts and tumors. *Curr Probl Surg* 1984; **21**: 1–77.
10. Ponn RB. Simple mediastinal cysts: resect them all? *Chest* 2003; **124**: 4–6.