

# Sodium/iodide symporter is expressed in the majority of seminomas and embryonal testicular carcinomas

S Micali<sup>1</sup>, V Maggisano<sup>3</sup>, A Cesinaro<sup>2</sup>, M Celano<sup>3</sup>, A Territo<sup>1</sup>, L Reggiani Bonetti<sup>2</sup>, M Sponziello<sup>4</sup>, M Migaldi<sup>2</sup>, M Navarra<sup>5,6</sup>, G Bianchi<sup>1</sup>, S Filetti<sup>4</sup> and D Russo<sup>3</sup>

Departments of <sup>1</sup>Urology and <sup>2</sup>Pathology, University of Modena and Reggio Emilia, 41100 Modena, Italy

<sup>3</sup>Department of Health Sciences, University of Catanzaro 'Magna Graecia', Viale Europa, Loc. Germaneto, 88100 Catanzaro, Italy

<sup>4</sup>Department of Internal Medicine and Medical Specialties, University of Rome 'Sapienza' 00161 Rome, Italy

<sup>5</sup>Pharmaco-Biological Department and <sup>6</sup>IRCCS Centro Neurolesi 'Bonino-Pulejo', 98100 Messina, Italy

Correspondence should be addressed to D Russo

**Email**  
d.russo@unicz.it

## Abstract

Testicular cancer is the most frequent cancer in young men. The large majority of patients have a good prognosis, but in a small group of tumors, the current treatments are not effective. Radioiodine is routinely used in the treatment of thyroid cancer and is currently investigated as a potential therapeutic tool even for extra-thyroid tumors able to concentrate this radioisotope. Expression of Na<sup>+</sup>/I<sup>-</sup> symporter (NIS (SLC5A5)), the glycoprotein responsible for iodide transport, has been demonstrated in normal testicular tissue. In this study, we analyzed NIS expression in a large series of testicular carcinomas. Our retrospective series included 107 patients operated for testicular tumors: 98 typical seminomas, six embryonal carcinomas, one mixed embryonal choriocarcinoma, and two Leydig cells tumors. Expression and regulation of NIS mRNA and protein levels were also investigated in human embryonal testicular carcinoma cells (NTERA) by real-time RT-PCR and western blotting respectively. Immunohistochemical analysis showed the presence of NIS in the large majority of seminomas (90/98) and embryonal carcinomas (5/7) of the testis but not in Leydig cell carcinomas. Expression of NIS protein was significantly associated with lymphovascular invasion. In NTERA cells treated with the histone deacetylase inhibitors SAHA and valproic acid, a significant increase in NIS mRNA (about 60- and 30-fold vs control,  $P < 0.001$  and  $P < 0.01$  respectively) and protein levels, resulting in enhanced ability to uptake radioiodine, was observed. Finally, NIS expression in testicular tumors with the more aggressive behavior is of interest for the potential use of targeting NIS to deliver radioiodine in malignant cells.

## Key Words

- ▶ testicular tumors
- ▶ seminoma
- ▶ embryonal carcinoma
- ▶ sodium iodide symporter

*Journal of Endocrinology*  
(2013) 216, 125–133

## Introduction

Testicular cancer represents about 1–1.5% of all human neoplasias and is the most frequent malignancy in young adult men between 15 and 40 years, representing the leading cause of cancer-related mortality and morbidity in

this age group (Winter & Albers 2011). Although conventional treatments or high-dose chemotherapy are able to treat ~80% of these patients, it is highly desirable to identify novel effective therapeutic options provided

with minimal side effects (Sonpavide *et al.* 2007, Schrader *et al.* 2009).

Radioiodine ( $I^{131}$ ), used in the treatment of thyroid cancer, has recently been proposed as a novel therapeutic tool even for extra-thyroid tumors, if able to concentrate this radioisotope (Kogai *et al.* 2006, Riesco-Eizaguirre & Santisteban 2006). Radioiodine concentration requires the presence and function of the  $Na^+/I^-$  symporter (NIS (SLC5A5)), the glycoprotein responsible for iodide transport across the basal membrane of the thyrocytes (Dohán *et al.* 2003). Thus, stimulation of NIS expression by TSH is adopted in the radioiodine-based treatment of thyroid recurrent and metastatic cancer and defects in its functional expression are a major cause of failure of such a treatment (Arturi *et al.* 2000, Schlumberger *et al.* 2007). Similarly, attempts to induce/enhance NIS expression in extra-thyroid tumor cells, to make them able to concentrate the radioisotope, may offer the opportunity of using the same therapeutic approach adopted for thyroid tumors. NIS expression has been recently demonstrated in normal testicular tissue both at transcript and protein levels (Russo *et al.* 2011a), while only one study, analyzing a small number of samples, has been performed on neoplastic testicular tissues, showing NIS expression in one of 11 malignant cores examined (Wapnir *et al.* 2003).

In this study, NIS expression was investigated in 98 typical seminomas, seven embryonal testicular carcinomas (including one mixed embryonal choriocarcinoma), and two Leydig cell tumors. In addition, we attempted to stimulate *in vitro* NIS gene and protein expression and iodide uptake in testicular tumor cells. For this purpose, we used an experimental model of embryonal testicular cancer, known for its high aggressiveness, to test the effects of a series of stimulators in NTERA human cells.

## Materials and methods

### Materials

DMEM, fetal bovine serum (FBS), penicillin, streptomycin, and amphotericin B were purchased from Lonza (Milan, Italy). Suberoylanilide hydroxamic acid (SAHA), decitabine, bortezomib, and rapamycin were obtained from Aurogene (Rome, Italy); valproic acid, forskolin, 5-azacytidine, mevinolin, Apha compound 8, Hepes,  $KClO_4$ , NaI, and monoclonal anti  $\beta$ -actin antibody were from Sigma-Aldrich S.r.l. Monoclonal anti-NIS antibody MAB3562 was purchased from Prodotti Gianni (Milan, Italy), anti-human NIS MAB N2750 was from United States

Biological (Swampscott, MA, USA), PVDF membrane and ECL Plus were from VWR (Milan, Italy), TRIzol was from Invitrogen, nuclease-free  $H_2O$  was from Gibco, and HRP-conjugated anti-mouse antibody was from Transduction Laboratories (Lexington, KY, USA). The High-Capacity cDNA RT kit, TaqMan Fast Universal PCR master mix, FAM dye-labeled probes, Assay-on-Demand Gene Expression Products, and  $\beta$ -actin were obtained from Applied Biosystems. Hank's balanced salt solution (HBSS) was obtained from EuroClone (Celbio, Pero, Milan, Italy), and carrier-free NaI was obtained from PerkinElmer (Monza, Milan, Italy).

### Cell culture

NTERA cells, the only commercially available cell line of human embryonal testicular carcinoma, were purchased from LGC Standards (Sesto San Giovanni, Milan, Italy); cultured in DMEM containing FBS 10% (v/v), penicillin (0.1 mg/ml), streptomycin (2.5  $\mu$ g/ml), and amphotericin B (2.5  $\mu$ g/ml); and were maintained at 37 °C in a humidified atmosphere (5%  $CO_2$ ).

### Tissue samples

A retrospective series of 107 patients operated at the Policlinic of Modena for testicular tumors who underwent inguinal orchifuniclectomy was analyzed: 98 seminomatous tumors (typical seminomas) and nine non-seminomatous tumors including six embryonal carcinomas, one mixed embryonal choriocarcinoma, and two Leydig cells tumors. Tumors were histologically classified according to WHO criteria (Eble *et al.* 2004). The tumor staging (tumor node metastases (TNM)), which represents the validated standard tool to describe tumor extent and includes prognostic information on the probability of disease control, was assigned using the current guidelines (Edge *et al.* 2009). Specimens' aliquots were fixed in Bouin's fixative overnight for histological studies. Review of patients' charts was carefully performed to collect the clinical features of each case, as described in Table 1.

### Ethics statement

All human tissue samples used in the study were collected with full patients' informed written consent and approval from the Policlinic of Modena Ethic Committee.

### Immunohistochemistry

The presence of NIS in testicular tumor tissues was analyzed by immunohistochemistry as described

**Table 1** Clinical and pathological features of the 107 patients with testicular tumors analyzed

Characteristics	Values
Age	
Mean $\pm$ s.d.	37.24 $\pm$ 11.4
Median	35
Range	18–73
Size	
Middle $\pm$ s.d.	4.68 $\pm$ 2.69
Median	4
Range	1.5–13
Histology	
Typical seminoma	98 (91.6%)
Embryonal carcinoma	6 (5.5%)
Mixed <sup>a</sup>	1 (1%)
Leydigoma	2 (1.9%)
Stages	
I	88 (82.3%)
II	10 (9.3%)
III	9 (8.4%)
TNM	
T	
T1	82 (76.6%)
T2	20 (18.7%)
T3	5 (4.7%)
N	
N0	97 (90.7%)
N1–N2	10 (9.3%)
M	
M0	99 (92.5%)
M+	8 (7.5%)
Lymphovascular invasion ( $\pm$ )	18 (17%)/89 (83%)
Follow-up	
Mean	98.4 months
Range	12–144 months
Alive	95 (89%)
Died <sup>b</sup>	4 (4%)
Recurrences	8 (7%)

<sup>a</sup>Embryonal and choriocarcinoma.<sup>b</sup>Deceased for cause unrelated to the tumor.

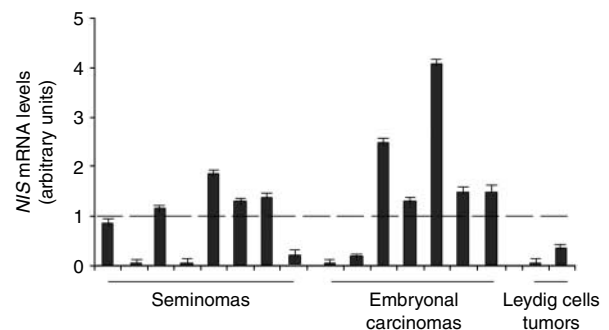
previously (Navarra *et al.* 2010). Dewaxed 4  $\mu$ m sections were first incubated with 6% H<sub>2</sub>O<sub>2</sub> for 10 min at room temperature to block endogenous peroxidase activity. Then, they were immersed in a citrate buffer (pH 6) for 30 min at 98 °C and incubated at room temperature overnight with the monoclonal anti-NIS antibody N2750 diluted 1:100. The avidin–biotin complex was applied using an automatic system (Benchmark, Ventana, Tucson, AZ, USA) and staining was visualized using diaminobenzidine chromogen. The sections were lightly counterstained with Carazzi's hematoxylin and dehydrated, before being mounted and examined by two pathologists, who expressed concordant opinions for all the cases examined. A rate >10% of cells staining associated with at least moderate intensity was used to indicate positivity, 10–50% moderate, and >50% high.

### Analysis of mRNA levels

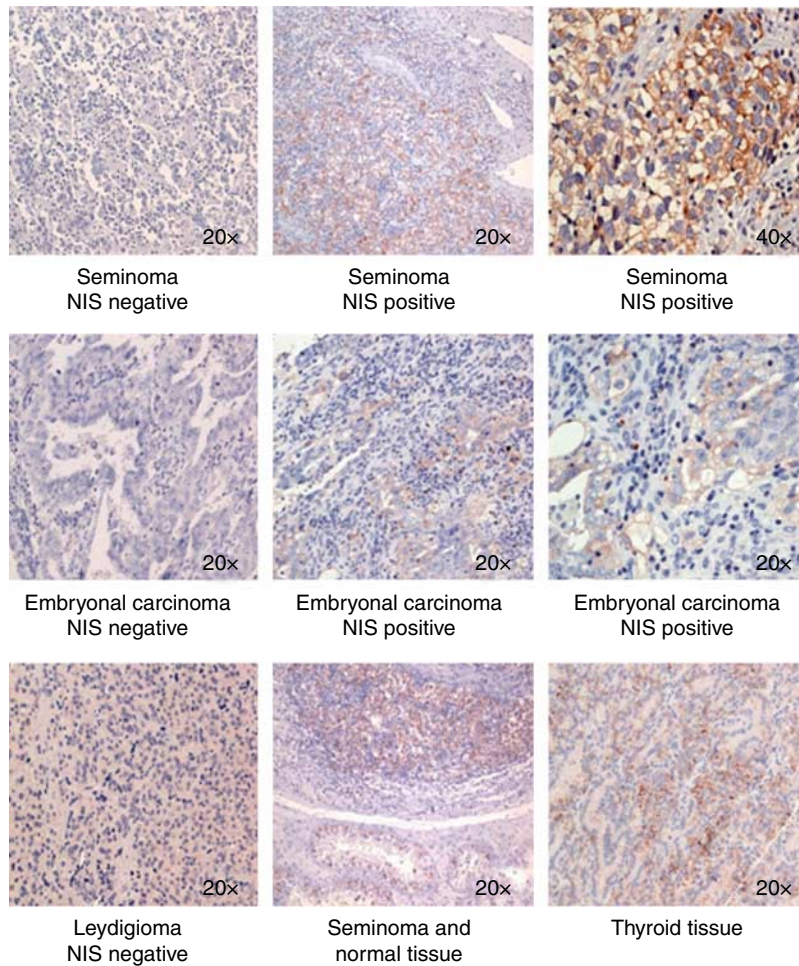
Levels of NIS mRNA were determined with real-time quantitative RT-PCR, as described previously (Sponziello *et al.* 2010). Briefly, total RNA was extracted from cells treated with various compounds at various incubation times using the TRIzol method, according to the manufacturer's instructions. Two micrograms of total RNA were reverse transcribed in a 20  $\mu$ l reaction volume using the High-Capacity cDNA RT kit following the instructions of the manufacturer. After 1:5 dilution, the cDNAs were amplified using an Applied Biosystems 7900HT Fast Real-Time PCR Sequence Detection System and fast quantitative PCR thermal cycler parameters. Each tube contained, in a total of 20  $\mu$ l, 2  $\mu$ l cDNA, 10  $\mu$ l TaqMan Fast Universal PCR master mix, and 1.0  $\mu$ l of a pre-developed primer/probe mixture for each gene to be measured. All values were normalized to  $\beta$ -actin as endogenous control, with similar results. The experiments were repeated at least three times. Reactions, results determination, and expression and normalization were performed as previously reported (Sponziello *et al.* 2010).

### Analysis of protein levels

Extraction of total proteins was performed as described previously (Celano *et al.* 2008). Briefly, 15  $\mu$ g of proteins were run on a 7.5% SDS–PAGE gel and transferred to PVDF membrane with the Mini Trans Blot system (Bio-Rad Laboratories S.r.l.; 2 h at 225 mA). Membranes were blocked with TTBS/milk (TBS, 1% Tween 20, and 5% nonfat dry milk) for 1 h at room temperature and incubated overnight with the affinity-purified anti-NIS monoclonal antibody (MAB) MAB3562 diluted 1:250. The

**Figure 1**

Expression of NIS mRNA in testicular tumors. NIS mRNA levels assayed by RT-PCR in seminomas, embryonal testicular carcinomas, and Leydig cell fresh frozen tumors.

**Figure 2**

Expression of NIS in testicular carcinoma tissues. Immunohistochemistry of NIS in testicular tumors. In seminomas and embryonal carcinomas, NIS staining is detected in both cytosol and plasma membrane of cancer cells. Thyroid hyperfunctioning adenoma is used as positive control; one

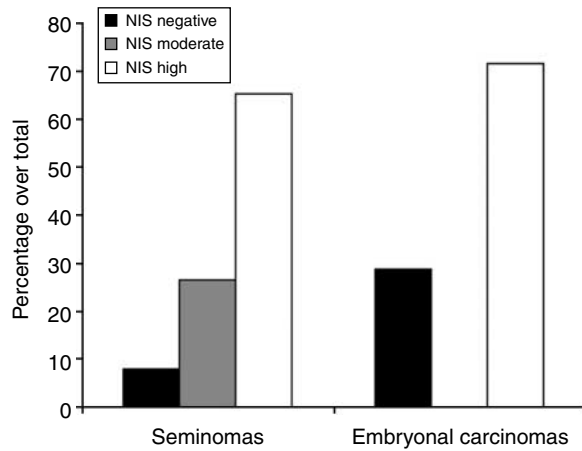
Leydigoma, one embryonal carcinoma, and one seminoma negative for NIS mRNA expression are shown as negative controls. Experiments were performed using a primary monoclonal anti-human NIS antibody diluted 1:100 as described in the Materials and Methods section.

membranes were washed once for 15 min and twice for 5 min in TTBS and incubated with HRP-conjugated anti-mouse antibody diluted 1:10 000 in TTBS/milk. After one 15-min and two 5-min washes in TTBS, the protein was visualized by chemiluminescence using the western blot detection system ECL Plus. Monoclonal mouse  $\beta$ -actin antibody was used as an internal control.

### Iodide uptake

Iodide uptake by NTERA cells was measured as described previously (Weiss *et al.* 1984). Briefly, cells were seeded into 12-well plates and treated with SAHA, 3  $\mu$ M and valproic acid, 3 mM for 48 h. Then, the culture medium was aspirated and cells were washed twice with 1 ml HBSS

supplemented with HEPES (10 mM, pH 7.3).  $^{125}$ I uptake was initiated by adding to each well 500  $\mu$ l HBSS containing 0.1  $\mu$ Ci/ml carrier-free labeled NaI and 10  $\mu$ M NaI. In half of the wells, used as control for specific uptake, this buffer also contained 100  $\mu$ M KClO<sub>4</sub>, a NIS inhibitor. After 30–40 min at 37 °C in a humid atmosphere, the radioactive medium was aspirated and cells were washed twice with 1 ml ice-cold HBSS. The amount of iodide uptake was determined after incubation with 1 ml 95% ethanol to each well for 20 min and transfer into vials for counting with a  $\gamma$ -counter. The NIS-specific radioiodine uptake was normalized using data of cell viability measured with MTT (3-(4,5-dimethylthiazol-2-yl)-2,5-diphenyltetrazolium bromide) assay (data not shown). Each experiment was carried out in triplicate.

**Figure 3**

Immunohistochemical results of NIS intensity in seminoma and embryonal testicular carcinomas. Bars represent the percentage of total seminomas or embryonal carcinomas with absent, moderate, or high-intensity staining, evaluated in immunohistochemical experiments as indicated in the Materials and methods section.

### Statistical analysis

The results are expressed as mean  $\pm$  s.d., and the one-way ANOVA followed by the Tukey–Kramer multiple comparisons test was adopted to determine the significance of differences using the GrafPAD Software for Science (San Diego, CA, USA). Patients were uniformly followed at our Institution. The association between protein NIS expression and clinicopathological parameters was calculated using contingency table methods and tested for significance using the Pearson's  $\chi^2$  test. A probability ( $P$ ) value  $<0.05$  was considered statistically significant.

## Results

### Clinical and pathological features

A total of 107 testicular tumor tissues were evaluated: histological types included 98 seminomatous tumors (90 fixed in formalin specimens and eight fresh/not fixed in formalin tissue), seven embryonal carcinomas (all fresh/not fixed in formalin tissue), and two sex cord/gonadal stromal tumors (Leydig cell tumors, both fresh/not fixed in formalin tissue). Eighty-eight tumors (82.3%) are classified as stage I, 10 (9.3%) as stage II, and nine (8.4%) as stage III. There was a complete accordance of the two pathologists in attributing the grading of each sample. In 18 (17%) cases, we detected lymphovascular invasion. The clinical and pathological findings of the patients are listed in Table 1.

### Expression of NIS in human testicular cancer tissues

Expression of *NIS* mRNA was evaluated in the available samples of fresh frozen testicular tumors. We observed detectable levels of *NIS* mRNA in five of eight seminomas and in five of seven embryonal carcinomas whereas in Leydig cell tumors *NIS* resulted absent (Fig. 1). All tumors were analyzed by immunohistochemistry to evaluate the expression of NIS protein. NIS protein staining was detected in the cell plasma membrane in the majority of the cases with intense staining (Fig. 2). As shown in Fig. 2, in 64 seminomas and five embryonal carcinomas, we observed more than 50% of cells stained. Twenty-six seminomas presented moderate-to-weak staining, while eight seminomas, two embryonal carcinomas, and both Leydig cell tumors were negative (Fig. 3). Interestingly, NIS

**Table 2** Clinicopathological characteristics of NIS+ and NIS– seminomas and embryonal testicular carcinomas

	Seminomas		Embryonal carcinomas		Leydigomas		Total of tumors		P value <sup>a</sup>
	NIS+	NIS–	NIS+	NIS–	NIS+	NIS–	NIS+	NIS–	
<b>TNM</b>									
T1	74 (94.9%)	4 (5.1%)	3 (100%)	0 (0%)	0 (0%)	1 (50%)	77 (94%)	5 (6%)	
T2–T3	16 (80%)	4 (20%)	2 (50%)	2 (50%)	0 (0%)	1 (50%)	18 (72%)	7 (28%)	NS
N0	84 (92.3%)	7 (7.7%)	3 (75%)	1 (25%)	0 (0%)	2 (100%)	87 (90%)	10 (10%)	
N1–N2	6 (85.7%)	1 (14.3%)	2 (66.7%)	1 (33.3%)	0 (0%)	0 (0%)	8 (80%)	2 (20%)	NS
M0	86 (91.5%)	8 (8.5%)	2 (66.7%)	1 (33.3%)	0 (0%)	2 (100%)	88 (89%)	11 (11%)	
M+	4 (100%)	0 (0%)	3 (75%)	1 (25%)	0 (0%)	0 (0%)	7 (87.5%)	1 (12.5%)	NS
<b>Lymphovascular invasion</b>									
Present	10 (83.3%)	2 (16.7%)	3 (60%)	2 (40%)	0 (0%)	1 (50%)	13 (72%)	5 (28%)	
Absent	80 (93%)	6 (7%)	2 (100%)	0 (0%)	0 (0%)	1 (50%)	82 (92%)	7 (8%)	$<0.05$
<b>Recurrence of disease</b>									
Present	5 (100%)	0 (0%)	1 (50%)	1 (50%)	0 (0%)	1 (50%)	6 (75%)	2 (25%)	
Absent	85 (91%)	8 (9%)	4 (80%)	1 (20%)	0 (0%)	1 (50%)	89 (90%)	10 (10%)	NS

NS, not significant.  
<sup>a</sup> $\chi^2$  test.

**Table 3** Compounds used to stimulate NIS expression

Compounds	Maximum concentration tested	Fold of increment of NIS mRNA levels
Histone deacetylase inhibitors		
SAHA	3 $\mu$ M	62.8 $\pm$ 3.5
Valproic acid	3 mM	36 $\pm$ 2.24
Apha compound 8	5 $\mu$ M	5.3 $\pm$ 1.03
Proteasome inhibitor		
Bortezomib	52 nM	2.7 $\pm$ 0.35
Demethylating agent		
5-Azacytidine	5 $\mu$ M	3 $\pm$ 1.1
Decitabine	5 $\mu$ M	1.5 $\pm$ 0.52
Adenylate cyclase stimulator		
Forskolin	10 $\mu$ M	0.8 $\pm$ 0.89
Inhibitor of hydroxymethylglutaryl-coenzyme A reductase		
Mevinolin	50 $\mu$ M	4.7 $\pm$ 1.7
mTOR inhibitor		
Rapamycin	20 nM	0.6 $\pm$ 0.9

protein expression was significantly associated with the lymphovascular invasion ( $P < 0.005$ ) but not with the other clinical and pathological parameters, as reported in Table 2. In the samples in which both RNA levels and tissue slice could be examined, concordance in the positivity of NIS mRNA and protein was observed, except for one seminoma positive for NIS mRNA expression and only weak staining of the protein.

### Stimulation of NIS expression in testicular embryonal carcinoma cells

Expression of NIS mRNA was then evaluated in the embryonal human testicular carcinoma cells NTERA. A series of molecules, including SAHA, decitabine, bortezomib, rapamycin, valproic acid, forskolin, 5-azacytidine, mevinolin, and Apha compound 8, known to stimulate NIS expression in thyroid cells (Frölich *et al.* 2008), was tested at various doses and incubation times (Table 3). The strongest stimulating effect was observed with the histone deacetylase inhibitors (HDACi) SAHA and valproic acid. Subsequently, we conducted dose–response and time-course analysis of selected dosages of SAHA and valproic acid: the greatest increment of the levels of NIS mRNA was observed after 24 h treatment with SAHA, 3  $\mu$ M and valproic acid, 3 mM; about 60- and 30-fold over control respectively (Fig. 4).

We next examined the expression of NIS protein in NTERA cells exposed to the same HDACi. As shown in Fig. 5, a specific band of  $\sim 90$  kDa, corresponding to human NIS protein, was detected in the total protein extracts of NTERA cells in basal condition and after

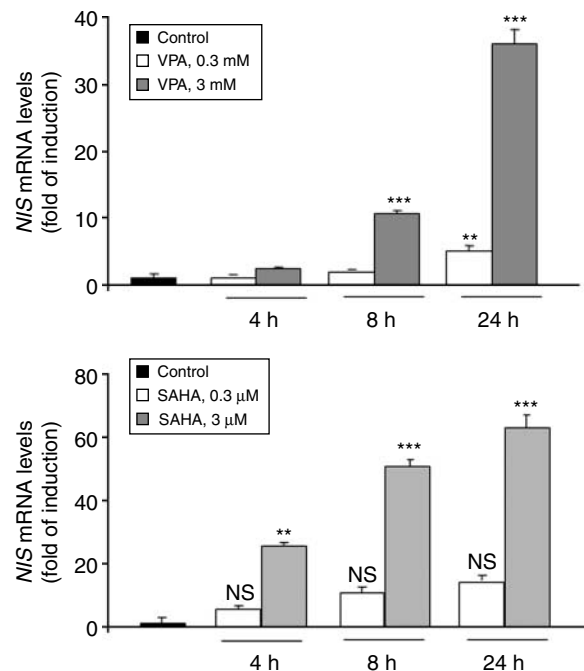
treatment with SAHA, 3  $\mu$ M or valproic acid, 3 mM, with the strongest effect observed in NTERA after 48 h of incubation (Fig. 5).

### Radioiodine uptake in NTERA cells

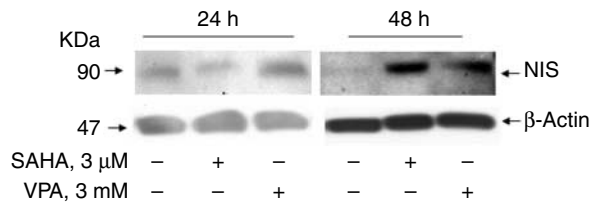
In order to test whether stimulation of NIS protein by HDACi determined an increase of its function, radioiodide uptake experiments were performed in the cells treated with SAHA and valproic acid (3  $\mu$ M and 3 mM respectively). After 48 h of treatment, we observed a significant increase in the uptake with both compounds (Fig. 6).

### Discussion

Testicular cancer, the most common malignancy occurring in young males, is a highly curable tumor even in patients with metastatic disease. Indeed, seminomas, the most frequent histotype, have a high radiosensitivity, so that combination of orchiectomy and adjuvant radiotherapy on the para-aortic and ipsilateral iliac lymph nodes, the standard therapy adopted in the last 60 years,

**Figure 4**

Expression of NIS mRNA in NTERA cells. NIS mRNA levels assayed by RT-PCR in NTERA cells exposed for 4, 8, or 24 h to SAHA 0.3 and 3  $\mu$ M, or valproic acid (VPA) 0.3 and 3 mM (\*\* $P < 0.001$  vs control; \*\* $P < 0.01$  vs control). Data are mean  $\pm$  s.d. of three experiments using ANOVA followed by the Tukey–Kramer multiple comparisons test.



**Figure 5**

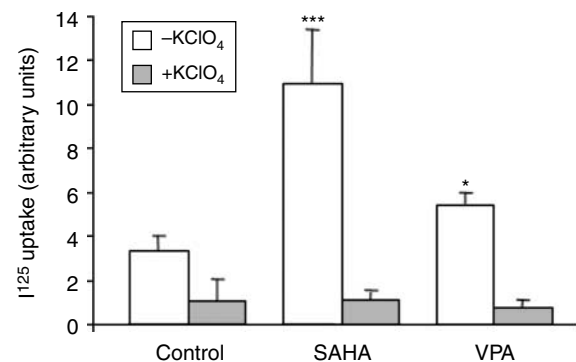
Expression of NIS protein in NTERA cells. Western blot analysis was performed under reducing conditions using a monoclonal anti-NIS antibody and a monoclonal anti-human  $\beta$ -actin antibody. A representative of three separated experiments is shown. A specific band of  $\sim 90$  kDa, corresponding to human NIS protein, was detected in the total protein extracts of carcinoma testicular cells and increased after treatment with HDAC inhibitors.

has reduced the risk of relapse to 1–3%, resulting in a global survival rate close to 100% (Warde *et al.* 2002). In the less radiosensitive nonseminomatous tumors, including embryonal cell carcinomas, yolk sac tumor, choriocarcinoma, and teratoma, the chemotherapy, mainly based on three to four cycles of PEB (cisplatin, etoposide, and bleomycin), is the alternative choice. However, resistance to such a treatment often arises (Krege *et al.* 2001, Castillo-Avila *et al.* 2009). Recently, some molecular mechanisms potentially involved in the pharmacological resistance and developed by the more aggressive tumors of the testis were described (Looijenga 2011). Novel therapeutic strategies are therefore urgently required for those tumors resistant to the current treatment.

Expression of NIS, the protein that actively transports iodide into the thyrocytes, in extra-thyroidal tumor tissues has been exploited for its potential use to target radioiodine in malignant cells for diagnosis and/or treatment of the disease (Kogai *et al.* 2006, Riesco-Eizaguirre & Santisteban 2006). Therefore, induction of NIS expression in cancer cells to deliver radioiodine is currently being explored for many types of extra-thyroid neoplasia (Hingorani *et al.* 2010). While encouraging results have been obtained in some preclinical models, unresolved issues are still present about the feasibility of a gene therapy-based approach in humans (Haberhorn *et al.* 2003). Equally promising are the attempts to stimulate endogenous NIS expression in those tumor cells, from thyroid and non-thyroid cancers, with detectable levels of NIS mRNA (Kogai *et al.* 2006). The feasibility of such an approach has been addressed in various tumors, including prostate cancer. In a previous report, expression of NIS has been detected in the more aggressive forms of prostate tumors, suggesting a potential use as target for a therapy

with radioiodine as well as biomarker for identifying individuals with biologically active disease (Navarra *et al.* 2010). Interestingly, even in breast cancer, NIS expression was detected in the more aggressive ‘triple-negative’ samples (Renier *et al.* 2009), at variance with thyroid cancer, in which lymph node metastatic tissues have usually reduced or lost NIS expression (Arturi *et al.* 2000). In the only other study addressing this issue in testicular tumors, no information was provided according to the histotype, the clinical characteristics of the patient(s), and the localization of NIS in the specimen examined (Wapnir *et al.* 2003).

In this study, we demonstrate that NIS is expressed in the plasma membrane of the large majority of seminomas and embryonal carcinomas of human testis, while is absent in two Leydig cell cancers. Our data also demonstrate a significant association of the expression of NIS protein with lymphovascular invasion, a well-known marker of aggressiveness. We believe that the association between NIS expression in the tumor cells and lymphovascular invasion may reflect the different biological aggressiveness of testis tumors, suggesting the presence of NIS as an unfavorable prognostic factor. Thus, the majority of the aggressive seminomas and embryonal carcinomas express the NIS protein that may be considered, in case of refractoriness to the standard treatment, a potential candidate to an alternative radioiodine-based therapeutic strategy. As the embryonal carcinomas, for their refractoriness to the current treatment, represent potential candidates for such a novel



**Figure 6**

SAHA and valproic acid increase radioiodine uptake in NTERA cells. NTERA cells were treated with SAHA, 3  $\mu$ M and valproic acid, 3 mM for 48 h. Radioiodine uptake was evaluated as described in the Materials and methods section. Each bar represents the mean value ( $\pm$  s.d.) of three different experiments. Statistical significance compared with untreated cells (\* $P$ <0.05; \*\*\* $P$ <0.001).

therapeutic approach, we chose the NTERA cells, the only available commercial human embryonal carcinoma cell line, to attempt to stimulate NIS expression in tumor cells. Our present findings reveal that NIS expression may be enhanced *in vitro* by HDACi. Histone acetylation is a known epigenetic mechanism of regulation of gene expression and its alteration has been reported in many human cancers (Chi *et al.* 2010). In many cell lines of thyroid and non-thyroid cancer, HDACi have been successfully tested to induce radioiodine uptake due to increased NIS expression (Puppini *et al.* 2005, Russo *et al.* 2011b, Liu & Xing 2012). The same result was obtained in the NTERA cells in this study, showing that at least *in vitro* embryonal testicular tumor cell susceptibility to radioiodine administration may occur and suggesting the possibility to use the radioiodine after pharmacological induction of NIS expression even in this rare tumor histotype. It is noteworthy that these drugs are being tested in clinical trials at doses compatible with those effective *in vitro* ([www.clinicaltrials.gov](http://www.clinicaltrials.gov)).

In conclusion, the present data demonstrate that NIS is expressed in the large majority of seminomas and embryonal carcinomas of human testis, including those with a more aggressive phenotype (i.e. with lymphovascular invasion). Its presence in the plasma membrane compartment of the tumor cells suggests that it may serve as potential carrier of radioiodine for an ablative treatment of cancer tissue.

#### Declaration of interest

The authors declare that there is no conflict of interest that could be perceived as prejudicing the impartiality of the research reported.

#### Funding

This work was supported by grants from the Italian Ministry of Instruction, University (PRIN COFIN 2008) to D Russo.

#### References

- Arturi F, Russo D, Giuffrida D, Schlumberger M & Filetti S 2000 Sodium-iodide symporter (NIS) gene expression in lymph node metastases of papillary thyroid carcinomas. *European Journal of Endocrinology* **143** 623–627. (doi:10.1530/eje.0.1430623)
- Castillo-Avila W, Piulats JM, Garcia Del Muro X, Vidal A, Condom E, Casanovas O, Mora J, Germà JR, Capellà G, Villanueva A *et al.* 2009 Sunitinib inhibits tumor growth and synergizes with cisplatin in orthotopic models of cisplatin-sensitive and cisplatin-resistant human testicular germ cell tumors. *Clinical Cancer Research* **15** 3384–3395. (doi:10.1158/1078-0432.CCR-08-2170)
- Celano M, Schenone S, Cosco D, Navarra M, Puxeddu E, Racanicchi L, Brullo C, Varano E, Alcaro S, Ferretti E *et al.* 2008 Cytotoxic effects of a novel pyrazolopyrimidine derivative entrapped in liposomes in anaplastic thyroid cancer cells *in vitro* and in xenograft tumors *in vivo*. *Endocrine-Related Cancer* **15** 499–510. (doi:10.1677/ERC-07-0243)
- Chi P, Allis CD & Wang GG 2010 Covalent histone modifications – miswritten, misinterpreted and mis-erased in human cancers. *Nature Reviews. Cancer* **10** 457–459. (doi:10.1038/nrc2876)
- Dohán O, De la Vieja A, Paroder V, Riedel C, Artani M, Reed M, Ginter CS & Carrasco N 2003 The sodium/iodide symporter (NIS): characterization, regulation, and medical significance. *Endocrine Reviews* **24** 48–77. (doi:10.1210/er.2001-0029)
- Eble JN, Sauter G, Epstein JI & Sesterhenn IA 2004 *The World Health Organization Classification of Tumours. Pathology and Genetics of the tumours of the urinary system and male genital organs*. Eds WD Travis, E Brambilla, HK Müller-Hermelink & CC Harris. Lyon, France: IARC Press.
- Edge SB, Byrd DR, Compton CC, Fritz AG, Greene FL & Trotti A. Eds 2010 *In AJCC Cancer Staging Manual*. 7th Edition, New York, NY, USA: Springer.
- Fröhlich E, Brossart P & Wahl R 2009 Induction of iodide uptake in transformed thyrocytes: a compound screening in cell lines. *European Journal of Nuclear Medicine and Molecular Imaging* **26** 780–790. (doi:10.1007/s00259-008-1024-6)
- Haberkorn U, Kinscherf R, Kissel M, Kübler W, Mahmut M, Sieger S, Eisenhut M, Peschke P & Altmann A 2003 Enhanced iodide transport after transfer of the human sodium iodide symporter gene is associated with lack of retention and low absorbed dose. *Gene Therapy* **10** 774–780. (doi:10.1038/sj.gt.3301943)
- Hingorani M, Spitzweg C, Vassaux G, Newbold K, Melcher A, Pandha H, Vile R & Harrington K 2010 The biology of the sodium iodide symporter and its potential for targeted gene delivery. *Current Cancer Drug Targets* **10** 242–267. (doi:10.2174/156800910791054194)
- Kogai T, Taki K & Brent GA 2006 Enhancement of sodium/iodide symporter expression in thyroid and breast cancer. *Endocrine-Related Cancer* **13** 797–826. (doi:10.1677/erc.1.01143)
- Krege S, Souchon R & Schmoll HJ 2001 Interdisciplinary consensus on diagnosis and treatment of testicular germ cell tumours: result of an updated conference on evidence-based medicine. *European Urology* **40** 373–391. (doi:10.1159/000049804)
- Liu Z & Xing M 2012 Induction of sodium/iodide symporter (NIS) expression and radioiodine uptake in non-thyroid cancer cells. *PLoS ONE* **7** e31729. (doi:10.1371/journal.pone.0031729)
- Looijenga LH 2011 Spermatocytic seminoma: toward further understanding of pathogenesis. *Journal of Pathology* **224** 431–433. (doi:10.1002/path.2939)
- Navarra M, Micali S, Lepore SM, Cesinaro AM, Celano M, Sighinolfi MC, De Gaetani C, Filetti S, Bianchi G & Russo D 2010 Expression of the sodium/iodide symporter in human prostate adenocarcinoma. *Urology* **75** 773–778. (doi:10.1016/j.urol.2009.10.011)
- Puppini C, D'Aurizio F, D'Elia AV, Cesaratto L, Tell G, Russo D, Filetti S, Ferretti E, Tosi E, Mattei T *et al.* 2005 Effects of histone acetylation on NIS promoter and expression of thyroid-specific transcription factors. *Endocrinology* **146** 3967–3974. (doi:10.1210/en.2005-0128)
- Renier C, Yao C, Goris M, Ghosh M, Katznelson L, Nowles K, Gambhir SS & Wapnir I 2009 Endogenous NIS expression in triple-negative breast cancers. *Annals of Surgical Oncology* **16** 962–968. (doi:10.1245/s10434-008-0280-9)
- Riesco-Eizaguirre G & Santisteban P 2006 A perspective view of sodium iodide symporter research and its clinical implications. *European Journal of Endocrinology* **155** 495–512. (doi:10.1530/eje.1.02257)
- Russo D, Scipioni A, Durante C, Ferretti E, Gandini L, Maggiasano V, Paoli D, Verrienti A, Costante G, Lenzi A *et al.* 2011a Expression and localization of the sodium/iodide symporter (NIS) in testicular cells. *Endocrine* **40** 35–40. (doi:10.1007/s12020-011-9469-y)
- Russo D, Damante G, Puxeddu E, Durante C & Filetti S 2011b Epigenetics of thyroid cancer and novel therapeutic targets. *Journal of Molecular Endocrinology* **46** R73–R81. (doi:10.1530/JME-10-0150)



- Schlumberger M, Lacroix L, Russo D, Filetti S & Bidart JM 2007 Defects in iodide metabolism in thyroid cancer and implications for the follow-up and treatment of patients. *Nature Clinical Practice. Endocrinology & Metabolism* **3** 263–269. (doi:10.1038/ncpendmet0449)
- Schrader M, Kempkensteffen C, Christoph F, Hinz S, Weikert S, Lein M, Krause H, Stephan C, Jung K, Hoepfner M *et al.* 2009 Germ cell tumors of the gonads: a selective review emphasizing problems in drug resistance and current therapy options. *Oncology* **76** 77–84. (doi:10.1159/000187426)
- Sonpavide S, Hutson TE & Roth BJ 2007 Management of recurrent testicular germ cell tumors. *Oncologist* **12** 51–61. (doi:10.1634/theoncologist.12-1-51)
- Sponziello ML, Bruno R, Durante C, D'Agostino M, Corradino R, Giannasio P, Ciociola E, Ferretti E, Maranghi M, Verrienti A *et al.* 2010 Growth factor receptors gene expression and Akt phosphorylation in benign human thyroid nodules are unaffected by chronic thyrotropin suppression. *Hormone and Metabolic Research* **43** 22–25. (doi:10.1055/s-0030-1265226)
- Wapnir IL, van de Rijn M, Nowels K, Amenta PS, Walton K, Montgomery K, Greco RS, Dohán O & Carrasco N 2003 Immunohistochemical profile of the sodium/iodide symporter in thyroid, breast, and other carcinomas using high density tissue microarrays and conventional sections. *Journal of Clinical Endocrinology and Metabolism* **88** 1880–1888. (doi:10.1210/jc.2002-021544)
- Warde P, Specht L, Horwich A, Oliver T, Panzarella T, Gospodarowicz M & von der Maase H 2002 Prognostic factors for relapse in stage I seminoma managed by surveillance: a pooled analysis. *Journal of Clinical Oncology* **20** 4448–4452. (doi:10.1200/JCO.2002.01.038)
- Weiss SJ, Philp NJ & Grollman EF 1984 Iodine transport in a continuous line of cultured 23 cells from rat thyroid. *Endocrinology* **114** 1090–1098. (doi:10.1210/endo-114-4-1090)
- Winter C & Albers P 2011 Testicular germ cell tumors: pathogenesis, diagnosis and treatment. *Nature Reviews. Endocrinology* **7** 43–53. (doi:10.1038/nrendo.2010.196)

Received in final form 30 October 2012

Accepted 1 November 2012

Accepted Preprint published online 1 November 2012