

## NCCN

# Soft Tissue Sarcoma, Version 2.2018

## Clinical Practice Guidelines in Oncology

Margaret von Mehren, MD; R. Lor Randall, MD;  
Robert S. Benjamin, MD; Sarah Boles, MD;  
Marilyn M. Bui, MD, PhD; Kristen N. Ganjoo, MD;  
Suzanne George, MD; Ricardo J. Gonzalez, MD;  
Martin J. Heslin, MD; John M. Kane, III, MD;  
Vicki Keedy, MD, MSCI; Edward Kim MD; Henry Koon, MD;  
Joel Mayerson, MD; Martin McCarter, MD;  
Sean V. McGarry, MD; Christian Meyer, MD, PhD;  
Zachary S. Morris, MD, PhD; Richard J. O'Donnell, MD;  
Alberto S. Pappo, MD; I. Benjamin Paz, MD;

Ivy A. Petersen, MD; John D. Pfeifer, MD, PhD;  
Richard F. Riedel, MD; Bernice Ruo, MD;  
Scott Schuetze, MD, PhD; William D. Tap, MD;  
Jeffrey D. Wayne, MD; Mary Anne Bergman;  
and Jillian L. Scavone, PhD

## Overview

Sarcomas constitute a heterogeneous group of rare solid tumors of mesenchymal cell origin with distinct clinical and pathologic features; they are usually divided into 2 broad categories:

- Sarcomas of soft tissues (including fat, muscle, nerve and nerve sheath, blood vessels, and other connective tissues); and
- Sarcomas of bone.

## Abstract

Soft tissue sarcomas (STS) are rare solid tumors of mesenchymal cell origin that display a heterogeneous mix of clinical and pathologic characteristics. STS can develop from fat, muscle, nerves, blood vessels, and other connective tissues. The evaluation and treatment of patients with STS requires a multidisciplinary team with demonstrated expertise in the management of these tumors. The complete NCCN Guidelines for STS provide recommendations for the diagnosis, evaluation, and treatment of extremity/superficial trunk/head and neck STS, as well as intra-abdominal/retroperitoneal STS, gastrointestinal stromal tumors, desmoid tumors, and rhabdomyosarcoma. This portion of the NCCN Guidelines discusses general principles for the diagnosis, staging, and treatment of STS of the extremities, superficial trunk, or head and neck; outlines treatment recommendations by disease stage; and reviews the evidence to support the guidelines recommendations.

*J Natl Compr Canc Netw* 2018;16(5):536–563  
doi: 10.6004/jnccn.2018.0025

## NCCN Categories of Evidence and Consensus

**Category 1:** Based upon high-level evidence, there is uniform NCCN consensus that the intervention is appropriate.

**Category 2A:** Based upon lower-level evidence, there is uniform NCCN consensus that the intervention is appropriate.

**Category 2B:** Based upon lower-level evidence, there is NCCN consensus that the intervention is appropriate.

**Category 3:** Based upon any level of evidence, there is major NCCN disagreement that the intervention is appropriate.

**All recommendations are category 2A unless otherwise noted.**

**Clinical trials:** NCCN believes that the best management for any cancer patient is in a clinical trial. Participation in clinical trials is especially encouraged.

## Please Note

The NCCN Clinical Practice Guidelines in Oncology (NCCN Guidelines®) are a statement of consensus of the authors regarding their views of currently accepted approaches to treatment. Any clinician seeking to apply or consult the NCCN Guidelines® is expected to use independent medical judgment in the context of individual clinical circumstances to determine any patient's care or treatment. The National Comprehensive Cancer Network® (NCCN®) makes no representation or warranties of any kind regarding their content, use, or application and disclaims any responsibility for their applications or use in any way. **The full NCCN Guidelines for Soft Tissue Sarcoma are not printed in this issue of JNCCN but can be accessed online at [NCCN.org](http://NCCN.org).**

© National Comprehensive Cancer Network, Inc. 2018, All rights reserved. The NCCN Guidelines and the illustrations herein may not be reproduced in any form without the express written permission of NCCN.

## Disclosures for the NCCN Soft Tissue Sarcoma Panel

At the beginning of each NCCN Guidelines panel meeting, panel members review all potential conflicts of interest. NCCN, in keeping with its commitment to public transparency, publishes these disclosures for panel members, staff, and NCCN itself.

Individual disclosures for the NCCN Soft Tissue Sarcoma Panel members can be found on page 563. (The most recent version of these guidelines and accompanying disclosures are available on the NCCN Web site at [NCCN.org](http://NCCN.org).)

These guidelines are also available on the Internet. For the latest update, visit [NCCN.org](http://NCCN.org).

## Journal of the National Comprehensive Cancer Network

Sarcomas collectively account for approximately 1% of all adult malignancies and 15% of pediatric malignancies. In 2018, an estimated 13,040 people will be diagnosed with soft tissue sarcoma (STS) in the United States, with approximately 5,150 deaths.<sup>1</sup> The true incidence of STS is underestimated, especially because a large proportion of patients with gastrointestinal stromal tumors (GISTs) may not have been included in tumor registry databases before 2001. A recent SEER database study calculated the annual incidence of GIST in the United States to be 0.78/100,000 in 2011.<sup>2</sup> Prior radiation therapy (RT) to the affected area is a risk factor for the development of STS.<sup>3-5</sup> More than 50 different histologic subtypes of STS have been identified. Common subtypes of STS include undifferentiated pleomorphic sarcoma (UPS), GIST, liposarcoma (LPS), and leiomyosarcoma (LMS).<sup>6</sup> The anatomic site of the

primary disease represents an important variable that influences treatment and outcome. Extremities (43%), the trunk (10%), viscera (19%), retroperitoneum (15%), or head and neck (9%) are the most common primary sites.<sup>7</sup> STS most commonly metastasizes to the lungs; tumors arising in the abdominal cavity more commonly metastasize to the liver and peritoneum. Rhabdomyosarcoma (RMS) is the most common STS of children and adolescents and is less common in adults.

The NCCN Clinical Practice Guidelines in Oncology (NCCN Guidelines) for STS address the management of STS in adult patients from the perspective of the following disease subtypes:

- STS of extremity, superficial/trunk, or head and neck
- Retroperitoneal or intra-abdominal STS

Text cont. on page 552.

## NCCN Soft Tissue Sarcoma Screening Panel Members

\*Margaret von Mehren, MD†/Chair  
Fox Chase Cancer Center

\*R. Lor Randall, MD¶/Vice-Chair  
Huntsman Cancer Institute at the University of Utah

Robert S. Benjamin, MD†  
The University of Texas MD Anderson Cancer Center

Sarah Boles, MD††  
UC San Diego Moores Cancer Center

Marilyn M. Bui, MD, PhD‡  
Moffitt Cancer Center

Kristen N. Ganjoo, MD†  
Stanford Cancer Institute

Suzanne George, MD†  
Dana-Farber/Brigham and Women's Cancer Center

Ricardo J. Gonzalez, MD¶¶  
Moffitt Cancer Center

Martin J. Heslin, MD¶¶  
University of Alabama at Birmingham  
Comprehensive Cancer Center

John M. Kane, III, MD¶¶  
Roswell Park Comprehensive Cancer Center

Vicki Keedy, MD, MSCI†  
Vanderbilt-Ingram Cancer Center

Edward Kim MD§  
Fred Hutchinson Cancer Research Center/  
Seattle Cancer Care Alliance

Henry Koon, MD†  
Case Comprehensive Cancer Center/  
University Hospitals Seidman Cancer Center  
and Cleveland Clinic Taussig Cancer Institute

Joel Mayerson, MD¶¶  
The Ohio State University Comprehensive Cancer Center -  
James Cancer Hospital and Solove Research Institute

Martin McCarter, MD¶¶  
University of Colorado Cancer Center

Sean V. McGarry, MD¶¶  
Fred & Pamela Buffett Cancer Center

Christian Meyer, MD, PhD†

The Sidney Kimmel Comprehensive Cancer Center  
at Johns Hopkins

Zachary S. Morris, MD, PhD§  
University of Wisconsin Carbone Cancer Center

Richard J. O'Donnell, MD¶¶  
UCSF Helen Diller Family Comprehensive Cancer Center

Alberto S. Pappo, MD€  
St. Jude Children's Research Hospital/  
The University of Tennessee Health Science Center

I. Benjamin Paz, MD¶¶  
City of Hope Comprehensive Cancer Center

Ivy A. Petersen, MD§  
Mayo Clinic Cancer Center

John D. Pfeifer, MD, PhD‡  
Siteman Cancer Center at Barnes-Jewish Hospital and  
Washington University School of Medicine

Richard F. Riedel, MD†  
Duke Cancer Institute

Bernice Ruo, MDP  
Robert H. Lurie Comprehensive Cancer Center of  
Northwestern University

Scott Schuetz, MD, PhD†  
University of Michigan Comprehensive Cancer Center

William D. Tap, MD†  
Memorial Sloan Kettering Cancer Center

Jeffrey D. Wayne, MD¶¶  
Robert H. Lurie Comprehensive Cancer Center of  
Northwestern University

NCCN Staff: Mary Anne Bergman, and Jillian L. Scavone, PhD

## KEY:

\*Discussion Section Writing Committee

Specialties: †Medical Oncology; ‡Hematology/Hematologic  
Oncology; ¶Surgery/Surgical Oncology; ¶Internal Medicine;  
†Orthopedics/Orthopedic Oncology; §Radiotherapy/Radiation  
Oncology; €Pediatric Oncology; ‡Pathology

## WORKUP

## ESSENTIAL:

- Prior to the initiation of therapy, all patients should be evaluated and managed by a multidisciplinary team with expertise and experience in sarcoma
  - H&P
  - Adequate imaging of primary tumor<sup>a,b</sup> is indicated for all lesions with a reasonable chance of being malignant
  - Carefully planned core needle [preferred] or incisional biopsy after adequate imaging (see SARC-D\*)<sup>c</sup>
    - ▶ Place biopsy along future resection axis with minimal dissection and careful attention to hemostasis
    - ▶ Biopsy should establish grade and histologic subtype<sup>d</sup>
    - ▶ As appropriate, use ancillary diagnostic methodologies<sup>e</sup>
  - Chest imaging<sup>b</sup>
- USEFUL UNDER CERTAIN CIRCUMSTANCES:<sup>f</sup>
- Additional imaging as indicated see Principles of Imaging (SARC-A)
  - Patients with personal/family history suggestive of Li-Fraumeni syndrome should be considered for further genetics assessment See NCCN Guidelines for Genetic/Familial High-Risk Assessment: Breast and Ovarian<sup>†</sup>
  - Patients with neurofibromatosis See NCCN Guidelines for Central Nervous System Cancers (PSCT-3)<sup>†</sup>

Special considerations for unique histologies<sup>g</sup>

Desmoid tumors (Aggressive fibromatosis)

See DESM-1\*

Ewing sarcoma

See NCCN Guidelines for Bone Cancer<sup>†</sup>

Rhabdomyosarcoma (RMS)

See RMS-1\*

Stage I

See Primary (EXTSARC-2)

Stage II, III resectable disease with acceptable functional outcomes

See Primary (EXTSARC-3)

Stage II, III resectable disease with adverse functional outcomes or Unresectable primary disease

See Primary (EXTSARC-4)

Synchronous Stage IV

See Primary (EXTSARC-5)

Recurrent disease

See Primary (EXTSARC-6)

Other soft tissue sarcomas of the extremity/superficial trunk, head/neck<sup>h</sup>

\*Available online, in the complete version of these guidelines, at NCCN.org.

<sup>†</sup>To view the most recent version of these guidelines, visit NCCN.org.

<sup>a</sup>Imaging studies should include cross-sectional imaging (MRI with and without contrast +/- CT with contrast) to provide details about the size of tumor and contiguity to nearby visceral structures and neurovascular landmarks. Other imaging studies such as angiogram and plain radiograph may be warranted in selected circumstances.

<sup>b</sup>See Principles of Imaging (SARC-A).

<sup>c</sup>In selected institutions with clinical and pathologic expertise, an FNA may be acceptable.

<sup>d</sup>See Principles of Pathologic Assessment of Sarcoma Specimens (SARC-B\*).

<sup>e</sup>See Principles of Ancillary Techniques Useful in the Diagnosis of Sarcomas (SARC-C\*).

<sup>f</sup>Different subtypes have different propensities to spread to various locations.

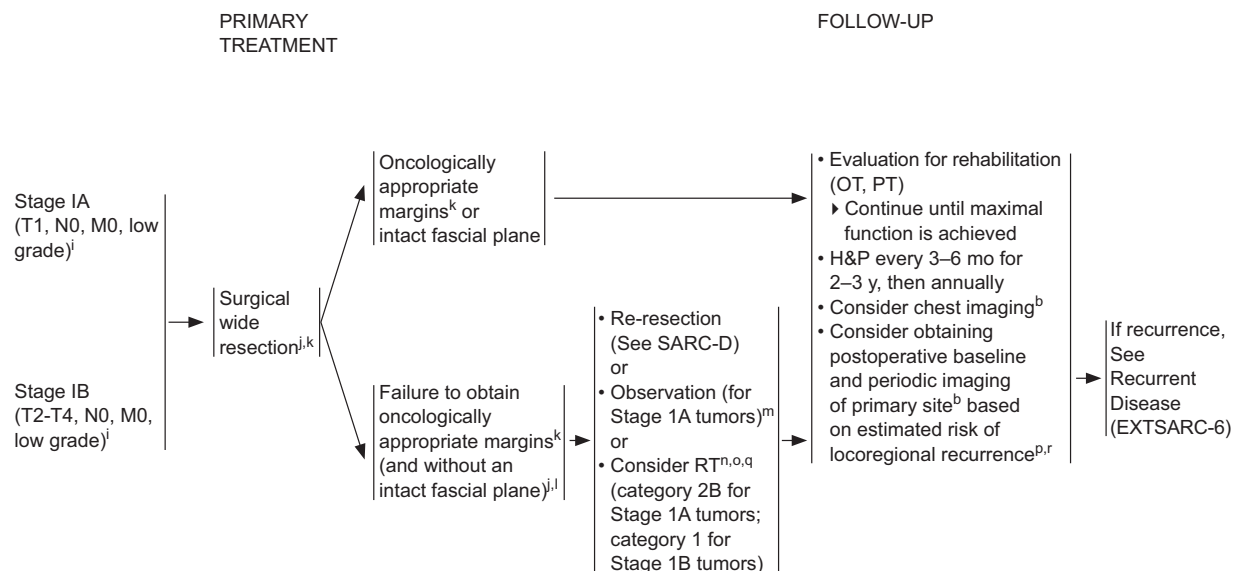
<sup>g</sup>Diagnoses that will impact the overall treatment plan.

<sup>h</sup>Patients with DFSP with fibrosarcomatous changes and/or malignant transformations can be treated according to this algorithm. For DFSP without fibrosarcomatous elements refer to treatment in the NCCN Guidelines for Dermatofibrosarcoma Protuberans<sup>†</sup>.

## EXTSARC-1

## Soft Tissue Sarcoma, Version 2.2018

## EXTREMITY/SUPERFICIAL TRUNK, HEAD/NECK



\*Available online, in the complete version of these guidelines at NCCN.org.

<sup>b</sup>See Principles of Imaging (SARC-A).

<sup>i</sup>See American Joint Committee on Cancer (AJCC) Staging, 8th Edition (ST-3\*).

<sup>j</sup>See Principles of Surgery (SARC-D\*).

<sup>k</sup>Resection should be tailored to minimize surgical morbidity for patients with atypical lipomatous tumor/well-differentiated liposarcoma (ALT/WDLS). En bloc resection with negative margins is generally sufficient to obtain long-term local control.

<sup>l</sup>In selected cases when margin status is uncertain, consultation with a radiation oncologist is recommended. Reresection, if feasible, may be necessary to render margins >1cm.

<sup>m</sup>Treatment options including revision surgery versus observation should be presented at an experienced multidisciplinary sarcoma tumor board to determine advantages and disadvantages of the decision.

<sup>n</sup>Results of a randomized study showed a non-significant trend toward reduced late toxicities (fibrosis, edema, and joint stiffness) with preoperative compared to postoperative radiation and a significant association between these toxicities and increasing treatment field size. Because postoperative radiation fields are typically larger than preoperative fields, the panel has expressed a general preference for preoperative radiation, particularly when treatment volumes are large." (Davis AM, O'Sullivan B, Turcotte R, et al. Late radiation morbidity

following randomization to preoperative versus postoperative radiotherapy in extremity soft tissue sarcoma. *Radiother Oncol* 2005;75(1):48-53 and Nielsen OS, Cummings B, O'Sullivan B, et al. Preoperative and postoperative irradiation of soft tissue sarcomas: effect of radiation field size. *Int J Radiat Oncol Biol Phys* 1991;21(6):1595-1599. See Radiation Therapy Guidelines (SARC-E).

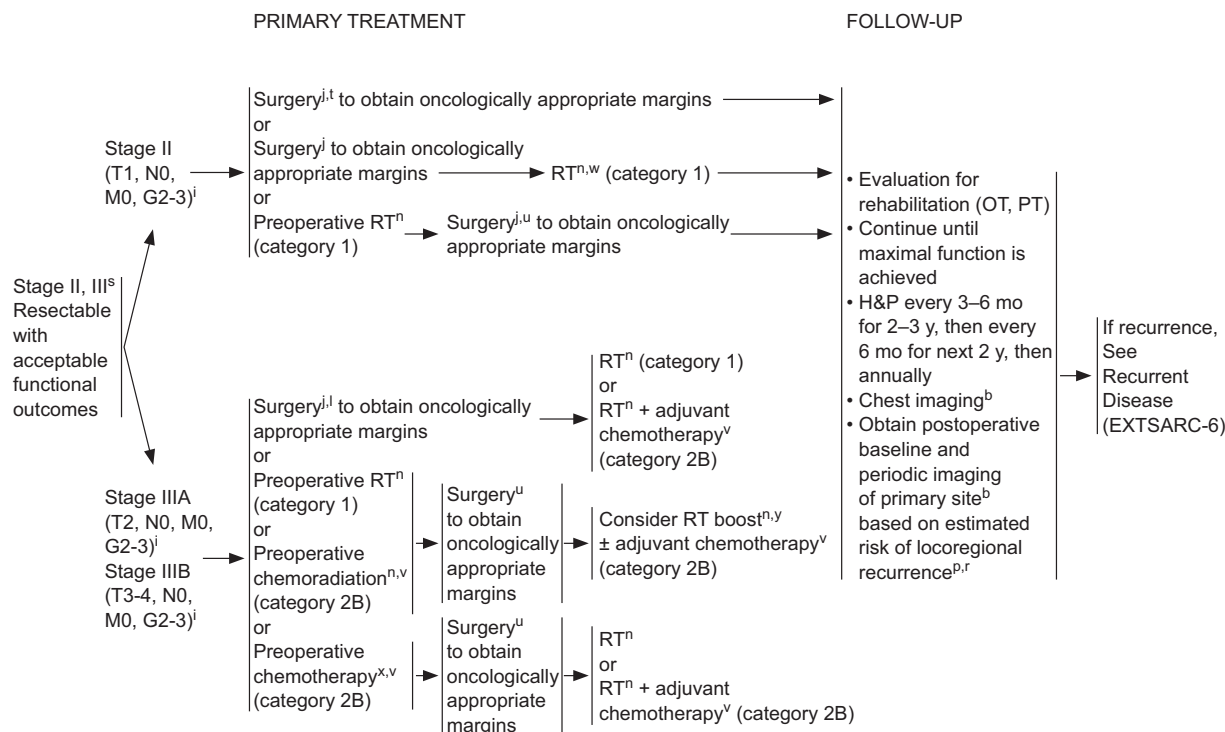
<sup>o</sup>Randomized clinical trial data support the use of radiation therapy as an adjunct to surgery in appropriately selected patients based on an improvement in disease-free survival (although not overall survival). (Yang JC, Chang AE, Baker AR, et al. Randomized prospective study of the benefit of adjuvant radiation therapy in the treatment of soft tissue sarcomas of the extremity. *J Clin Oncol* 1998;16:197-203).

<sup>p</sup>In situations where the area is easily followed by physical examination, imaging may not be required.

<sup>q</sup>For patients with ALT/WDLS, observation is recommended for focally positive margins if re-resection, in the event of recurrence, would not be unduly morbid. RT is reserved for selected patients with recurrent or deeply infiltrative primary lesions with a risk of local recurrence, depending on the tumor location and patient's age.

<sup>r</sup>After 10 years, the likelihood of developing a recurrence is small and follow-up should be individualized.

EXTSARC-2



\*Available online, in the complete version of these guidelines, at NCCN.org.

<sup>b</sup>See Principles of Imaging (SARC-A).

<sup>i</sup>See American Joint Committee on Cancer (AJCC) Staging, 8th Edition (ST-3\*).

<sup>j</sup>See Principles of Surgery (SARC-D\*).

<sup>l</sup>In selected cases when margin status is uncertain, consultation with a radiation oncologist is recommended. Re-resection, if feasible, may be necessary to render margins >1.0 cm.

<sup>n</sup>Results of a randomized study showed a non-significant trend toward reduced late toxicities (fibrosis, edema, and joint stiffness) with preoperative compared to postoperative radiation and a significant association between these toxicities and increasing treatment field size. Because postoperative radiation fields are typically larger than preoperative fields, the panel has expressed a general preference for preoperative radiation, particularly when treatment volumes are large (Davis AM, O'Sullivan B, Turcotte R, et al. Late radiation morbidity following randomization to preoperative versus postoperative radiotherapy in extremity soft tissue sarcoma. *Radiother Oncol* 2005;75(1):48-53 and Nielsen OS, Cummings B, O'Sullivan B, et al. Preoperative and postoperative irradiation of soft tissue sarcomas: effect of radiation field size. *Int J Radiat Oncol Biol Phys* 1991;21(6):1595-1599. See Radiation Therapy Guidelines (SARC-E).

<sup>p</sup>In situations where the area is easily followed by physical examination, imaging may not be required.

<sup>r</sup>After 10 years, the likelihood of developing a recurrence is small and follow-up should be individualized.

<sup>s</sup>Patients with stage III tumors with lymph node involvement should undergo regional lymph node dissection at the time of primary tumor resection ± RT.

<sup>t</sup>Surgery alone may be an option for small tumors resected with wide margins.

<sup>u</sup>Re-imaging using MRI with and without contrast (preferred for extremity imaging) or CT with contrast to assess primary tumor and rule out metastatic disease. See Principles of Imaging (SARC-A).

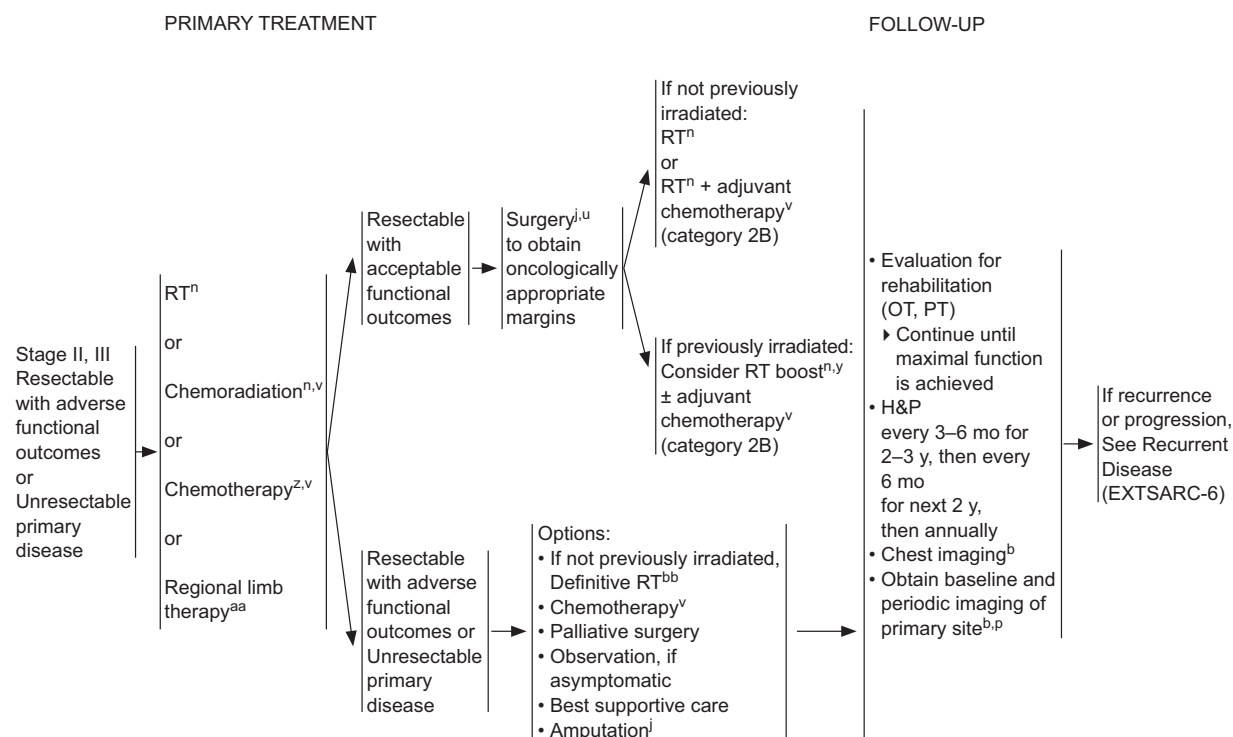
<sup>v</sup>See Systemic Therapy Agents and Regimens with Activity in Soft Tissue Sarcoma (SARC-F).

<sup>w</sup>RT may be used in select circumstances such as close or positive margins where re-excision is not feasible or for functional considerations.

<sup>x</sup>PET/CT may be useful in determining response to chemotherapy (Schuetz SM, Rubin BP, Vernon C, et al. Use of positron emission tomography in localized extremity soft tissue sarcoma treated with neoadjuvant chemotherapy. *Cancer* 2005;103:339-348).

<sup>y</sup>For residual gross disease or microscopically positive margins.

EXTASARC-3



\*Available online, in the complete version of these guidelines, at NCCN.org.

<sup>b</sup>See Principles of Imaging (SARC-A).

<sup>j</sup>See Principles of Surgery (SARC-D\*).

<sup>n</sup>Results of a randomized study showed a non-significant trend toward reduced late toxicities (fibrosis, edema, and joint stiffness) with preoperative compared to postoperative radiation and a significant association between these toxicities and increasing treatment field size. Because postoperative radiation fields are typically larger than preoperative fields, the panel has expressed a general preference for preoperative radiation, particularly when treatment volumes are large." (Davis AM, O'Sullivan B, Turcotte R, et al. Late radiation morbidity following randomization to preoperative versus postoperative radiotherapy in extremity soft tissue sarcoma. *Radiother Oncol* 2005;75(1):48-53 and Nielsen OS, Cummings B, O'Sullivan B, et al. Preoperative and postoperative irradiation of soft tissue sarcomas: effect of radiation field size. *Int J Radiat Oncol Biol Phys* 1991;21(6):1595-1599. See Radiation Therapy Guidelines (SARC-E).

<sup>Pl</sup>In situations where the area is easily followed by physical examination, imaging may not be required.

<sup>u</sup>Re-imaging using MRI with and without contrast (preferred for extremity imaging) or CT with contrast to assess primary tumor and rule out metastatic disease. See Principles of Imaging (SARC-A).

<sup>v</sup>See Systemic Therapy Agents and Regimens with Activity in Soft Tissue Sarcoma (SARC-F).

<sup>y</sup>For residual gross disease or microscopically positive margins.

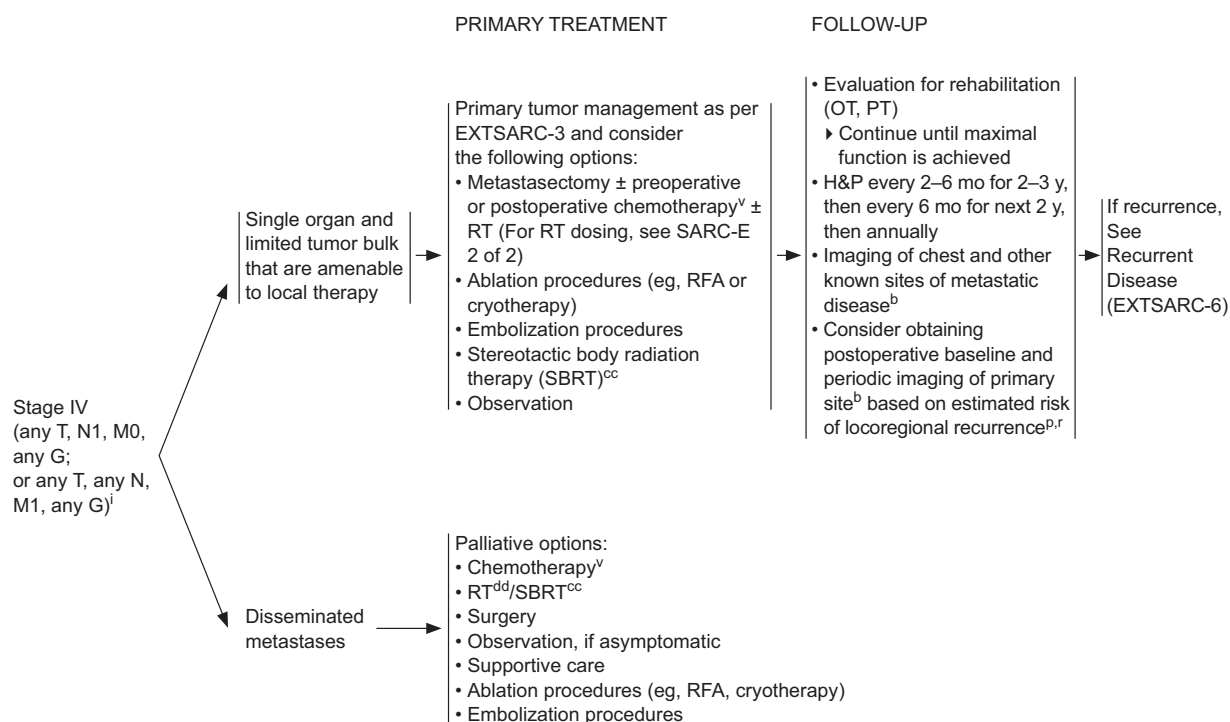
<sup>z</sup>PET/CT may be useful in determining response to chemotherapy. (Schuetz SM, Rubin BP, Vernon C, et al. Use of positron emission tomography in localized extremity soft tissue sarcoma treated with neoadjuvant chemotherapy. *Cancer* 2005;103:339-348).

<sup>aa</sup>Should only be done at institutions with experience in regional limb therapy.

<sup>bb</sup>Definitive RT entails delivering the maximal local dose compatible with known normal tissue tolerance, typically in the range of 70–80 Gy with sophisticated treatment planning techniques being a necessity in this setting.

EXTSARC-4





<sup>b</sup>See Principles of Imaging (SARC-A).

<sup>i</sup>See American Joint Committee on Cancer (AJCC) Staging, 8th Edition (ST-3), available online, in the complete version of these guidelines, at NCCN.org.

<sup>p</sup>In situations where the area is easily followed by physical examination, imaging may not be required.

<sup>r</sup>After 10 years, the likelihood of developing a recurrence is small and follow-up should be individualized.

<sup>v</sup>See Systemic Therapy Agents and Regimens with Activity in Soft Tissue Sarcoma (SARC-F).

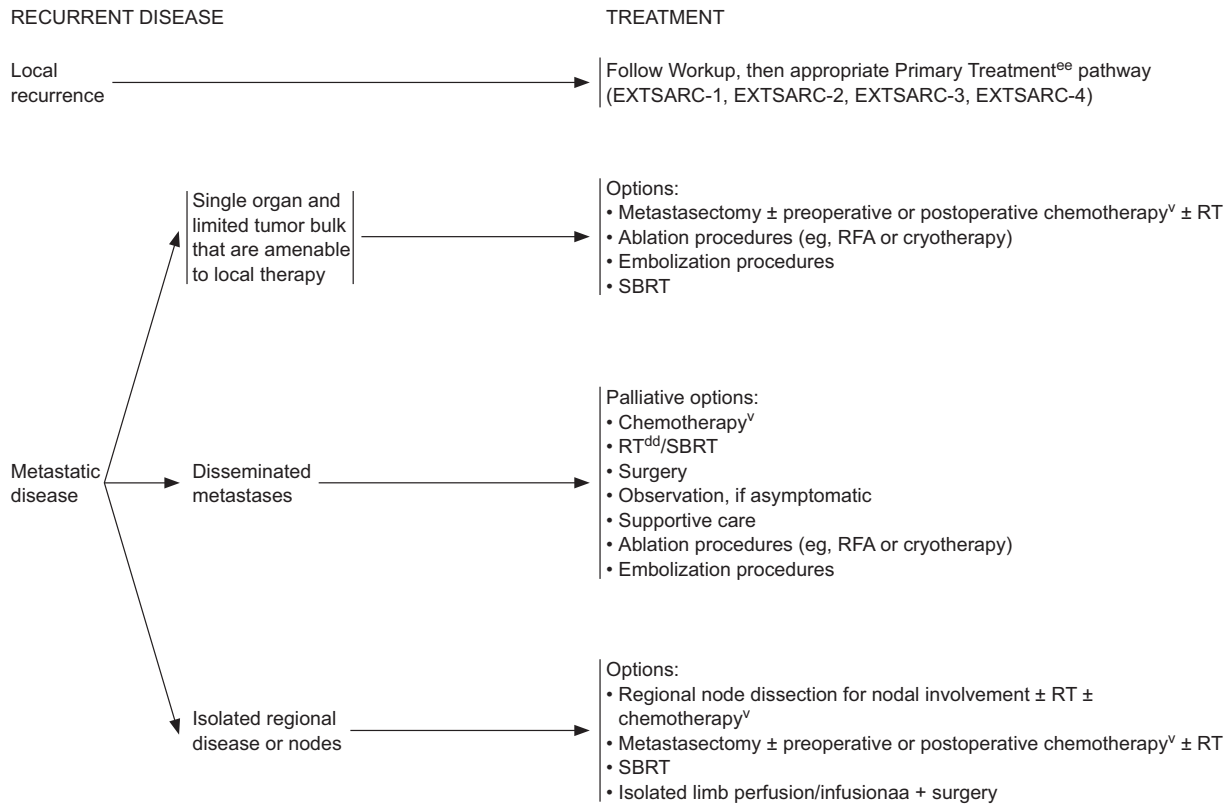
<sup>cc</sup>In retrospective studies, various SBRT dosing regimens have been reported to be effective for treatment of sarcoma metastases. Dose and fractionation should be determined by an experienced radiation oncologist based on normal tissue constraints. (Dhakal S, Corbin KS, Milano MT, et al. Stereotactic body radiotherapy for pulmonary metastases from soft-tissue sarcomas: excellent local lesion control and improved patient survival. *Int J Radiat Oncol Biol Phys* 2012;82(2):940-945. Navarria P, Ascolese AM, Cozzi L, et al. Stereotactic body radiation therapy for lung metastases from soft tissue sarcoma. *Eur J Cancer* 2015;51(5):668-674).

<sup>dd</sup>Palliative RT requires balancing expedient treatment with sufficient dose expected to halt the growth of or cause tumor regression. Numerous clinical issues regarding rapidity of growth, the status of systemic disease, and the use of chemotherapy must be considered. Recommended only for palliative therapy in patients with synchronous stage IV or recurrent disease with disseminated metastases.

EXTSARC-5

## Soft Tissue Sarcoma, Version 2.2018

## EXTREMITY/SUPERFICIAL TRUNK, HEAD/NECK



<sup>v</sup>See Systemic Therapy Agents and Regimens with Activity in Soft Tissue Sarcoma (SARC-F).

<sup>aa</sup>Should only be done at institutions with experience in regional limb therapy.

<sup>dd</sup>Palliative RT requires balancing expedient treatment with sufficient dose expected to halt the growth of, or cause tumor regression. Numerous clinical issues regarding rapidity of growth, the status of systemic disease, and the use of chemotherapy must be considered. Recommended only for palliative therapy in patients with synchronous stage IV or recurrent disease with disseminated metastases.

<sup>ee</sup>If local recurrence can be excised, a decision will need to be made on a case-by-case basis whether re-irradiation is possible. Some case series suggest benefit with re-irradiation [Catton C, Davis A, Bell R, et al. Soft tissue sarcoma of the extremity. Limb sparing after failure of combined conservative therapy. Radiother Oncol 41:209, 1996] while others do not [Torres MA, Ballo MT, Butler CE, et al. Management of locally recurrent soft-tissue sarcoma after prior surgery and radiation therapy. Int J Radiat Oncol Biol Phys 67:1124, 2007], likely reflecting differences in selection of patients for treatment with surgery and radiotherapy or surgery alone. Traditionally, the re-irradiation has been done with postoperative adjuvant brachytherapy but may now be able to be done as a combination of brachytherapy and IMRT to reduce the risks of morbidity with re-irradiation.

EXTSARC-6



## PRINCIPLES OF IMAGING

### GENERAL

- CT and MRI performed with contrast is recommended throughout the guideline unless contraindicated or otherwise noted.
- As appropriate, abdominal/pelvic MRI with contrast can be substituted for abdominal/pelvic CT if contraindicated (ie, due to dye allergy).
- If obtaining abdominal/pelvic CT, chest CT may be performed without contrast unless simultaneously attained with contrast-enhanced abdominal/pelvic CT.
- Chest imaging without contrast preferred unless contrast is needed for mediastinal imaging.

### EXTREMITY/SUPERFICIAL TRUNK, HEAD/NECK

#### Workup

- Primary tumor imaging using MRI with and without contrast ± CT with contrast is recommended. Other imaging studies such as angiogram and plain radiograph may be warranted in certain circumstances.
- Chest imaging
  - ▶ X-ray or CT without contrast (preferred)
- Additional imaging studies as indicated:
  - ▶ PET/CT scan may be useful in staging, prognostication, and grading.
  - ▶ Consider abdominal/pelvic CT for myxoid/round cell liposarcoma, epithelioid sarcoma, angiosarcoma, and leiomyosarcoma.
  - ▶ Consider MRI of total spine for myxoid/round cell liposarcoma.
  - ▶ Consider CNS imaging with MRI (or CT if MRI is contraindicated) for alveolar soft part sarcoma and angiosarcoma.

#### Follow-up

##### Stage I

- Consider chest imaging every 6–12 months. X-ray or CT is preferred. Contrast may be used if also imaging abdomen/pelvis.
- Consider postoperative baseline and periodic imaging of primary site based on estimated risk of locoregional recurrence.
  - ▶ MRI with and without contrast and/or CT with contrast is recommended. Consider ultrasound for small lesions that are superficial. Ultrasound should be done by an ultrasonographer experienced in musculoskeletal disease.<sup>1</sup>

##### Stage II/III

- PET/CT may be useful in determining response to neoadjuvant chemotherapy for lesions that are larger than 3 cm, firm, and deep (not superficial).<sup>2</sup>
- Re-imaging is recommended after surgery using MRI with and without contrast (preferred for extremity imaging) or CT with contrast to assess primary tumor and rule out metastatic disease.
- Chest imaging using x-ray or CT is recommended every 3–6 months for 2–3 years, then every 6 months for next 2 years, then annually.
- Resectable disease: postoperative baseline and periodic imaging of primary site based on estimated risk of locoregional recurrence
  - ▶ MRI with and without contrast and/or CT with contrast is recommended. Consider ultrasound for small lesions that are superficial. Ultrasound should be done by an ultrasonographer experienced in musculoskeletal disease.<sup>1</sup>
- Unresectable disease or resectable disease with adverse functional outcomes: Obtain postoperative baseline and periodic imaging of primary site based on estimated risk of locoregional recurrence.
  - ▶ MRI with and without contrast and/or CT with contrast is recommended. Consider ultrasound for small lesions that are superficial. Ultrasound should be done by an ultrasonographer experienced in musculoskeletal disease.<sup>1</sup>

##### Synchronous Stage IV

- Imaging of chest and other known sites of metastatic disease (x-ray or CT) is recommended every 2–6 months for 2–3 years, then every 6 months for next 2 years, then annually.
- Consider postoperative baseline and periodic imaging of the primary site based on estimated risk of locoregional recurrence.
  - ▶ MRI with and without contrast and/or CT with contrast is recommended. Consider ultrasound for small lesions that are superficial. Ultrasound should be done by an ultrasonographer experienced in musculoskeletal disease.<sup>1</sup>

##### Recurrent Disease

- Follow imaging recommendations for Workup, then use Follow-Up recommendations per appropriate primary treatment pathway.

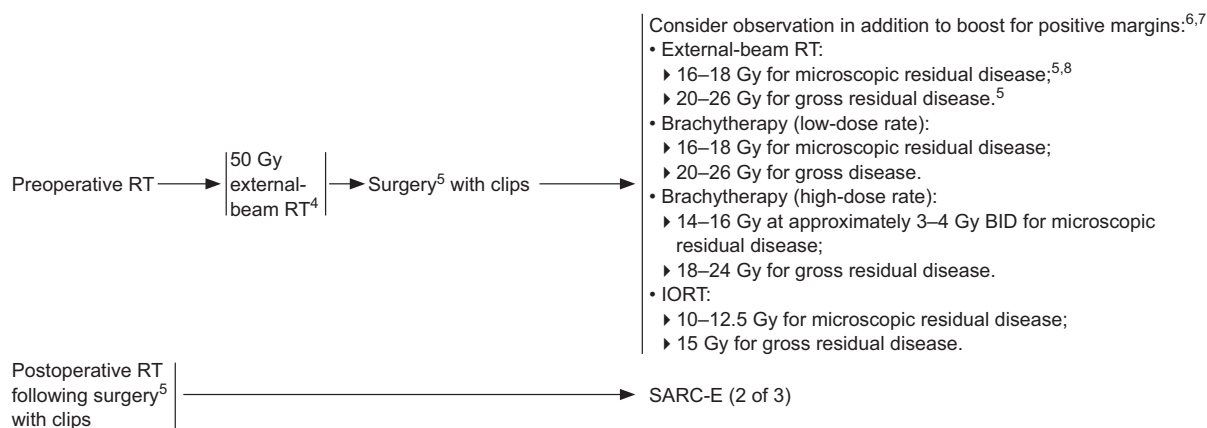
<sup>1</sup>Choi H, Varma DGK, Fornage BD, et al. Soft-tissue sarcoma: MR imaging vs sonography for detection of local recurrence after surgery. *AJR Am J Roentgenol* 1991;157:353-358.

<sup>2</sup>Schuetze SM, Rubin BP, Vernon C, et al. Use of positron emission tomography in localized extremity soft tissue sarcoma treated with neoadjuvant chemotherapy. *Cancer* 2005;103:339-348.

### SARC-A

1 AND 2 OF 3

## Soft Tissue Sarcoma, Version 2.2018

RADIATION THERAPY GUIDELINES FOR SOFT TISSUE SARCOMA OF EXTREMITY/TRUNK/HEAD-NECK<sup>1,2,3</sup>

\*Available online, in the complete version of these guidelines, at NCCN.org.

†To view the most recent version of these guidelines, visit NCCN.org.

<sup>1</sup>If an R1 or R2 resection is anticipated, clips to high-risk areas for recurrence is encouraged. When external beam RT is used, sophisticated treatment planning with IMRT, and/or protons can be used to improve the therapeutic ratio:

- Alektiar KM, et al. Impact of intensity-modulated radiation therapy on local control in primary soft-tissue sarcoma of the extremity. *J Clin Oncol* 2008;26:3440-3444;
- Kraybill WG, Harris J, Spiro IJ, et al. Phase II study of neoadjuvant chemotherapy and radiation therapy in the management of high-risk, high-grade, soft tissue sarcomas of the extremities and body wall: Radiation Therapy Oncology Group Trial 9514. *J Clin Oncol* 2006;24:619-625.

<sup>2</sup>Haas RL, DeLaney TF, O'Sullivan B, et al: Radiotherapy for management of extremity soft tissue sarcomas: why, when, and where? *Int J Radiat Oncol Biol Phys* 2012; 84:572-580.

<sup>3</sup>These guidelines are intended to treat the adult population. For adolescent and young adult patients, refer to the NCCN Guidelines for Adolescent and Young Adult (AYA) Oncology.<sup>†</sup>

<sup>4</sup>External-beam RT in 1.8 to 2.0 Gy per fraction.

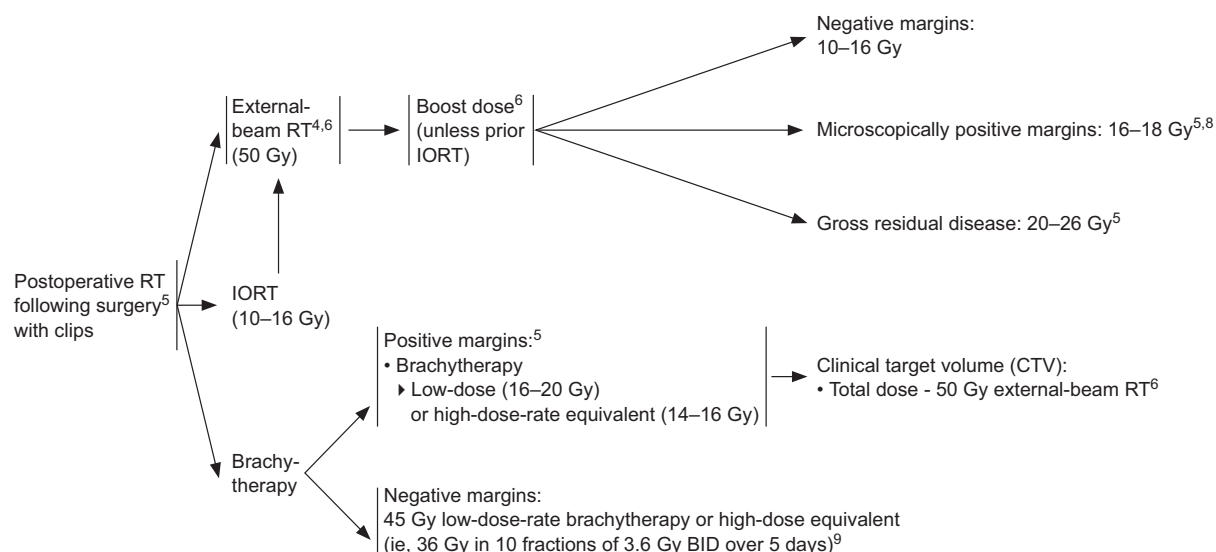
<sup>5</sup>See Resection Margins on Principles of Surgery (SARC-D\*).

<sup>6</sup>Total doses should always be determined by normal tissue tolerance. There are data to suggest that some patients with positive margins following preoperative RT such as those with low-grade, well-differentiated liposarcoma and a focally, "planned" positive margin on an anatomically fixed critical structure may do well without a boost. (Gerrand et al. *J Bone Joint Surg* 2001;83-B:1149-1155.)

<sup>7</sup>There are also data to suggest that delivery of a boost for positive margins does not improve local control. Since delivery of a post-op boost does not clearly add benefit, the decision should be individualized and the potential toxicities should be carefully considered. (Al Yami, et al. *Int J Radiat Oncol Biol Phys* 2010;77:1191-1107; Pan, et al. *J Surg Oncol* 2014;110:817-822.)

<sup>8</sup>RT does not substitute for definitive surgery with negative margins; re-resection may be necessary.

SARC-E  
1 OF 3

RADIATION THERAPY GUIDELINES FOR SOFT TISSUE SARCOMA OF EXTREMITY/TRUNK/HEAD-NECK<sup>1,2,3</sup>

\*Available online, in the complete version of these guidelines, at NCCN.org.

†To view the most recent version of these guidelines, visit NCCN.org.

<sup>1</sup>If an R1 or R2 resection is anticipated, clips to high-risk areas for recurrence is encouraged. When external beam RT is used, sophisticated treatment planning with IMRT, and/or protons can be used to improve the therapeutic ratio:

- Alektiar KM, et al. Impact of intensity-modulated radiation therapy on local control in primary soft-tissue sarcoma of the extremity. J Clin Oncol 2008;26:3440-3444;

- Kraybill WG, Harris J, Spiro IJ, et al. Phase II study of neoadjuvant chemotherapy and radiation therapy in the management of high-risk, high-grade, soft tissue sarcomas of the extremities and body wall: Radiation Therapy Oncology Group Trial 9514. J Clin Oncol 2006;24:619-625.

<sup>2</sup>Haas RL, DeLaney TF, O'Sullivan B, et al: Radiotherapy for management of extremity soft tissue sarcomas: why, when, and where? Int J Radiat Oncol Biol Phys. 2012; 84:572-580.

<sup>3</sup>These guidelines are intended to treat the adult population. For adolescent and young adult patients, refer to the NCCN Guidelines for Adolescent and Young Adult (AYA) Oncology†.

<sup>4</sup>External-beam RT in 1.8 to 2.0 Gy per fraction.

<sup>5</sup>See Resection Margins on Principles of Surgery (SARC-D\*).

<sup>6</sup>Total doses should always be determined by normal tissue tolerance.

<sup>8</sup>RT does not substitute for definitive surgery with negative margins; re-resection may be necessary.

<sup>9</sup>Data are still limited on the use of HDR brachytherapy for sarcomas. Until more data are available, HDR fraction sizes are recommended to be limited to 3-4 Gy (Nag et al, Int J Radiat Oncol Biol Phys 2001;49:1033-1043, 2001).

## Soft Tissue Sarcoma, Version 2.2018

SYSTEMIC THERAPY AGENTS AND REGIMENS WITH ACTIVITY IN SOFT TISSUE SARCOMA SUBTYPES (NON-SPECIFIC)<sup>a,b,c</sup>

| Soft Tissue Sarcoma Subtypes with Non-Specific Histologies <sup>d,e</sup>  |   | GIST <sup>k</sup>  | Desmoid Tumors (Aggressive fibromatosis)  |
|--|---|--|---|
| <u>Combination regimens</u> <ul style="list-style-type: none"> <li>• AD (doxorubicin, dacarbazine)<sup>1-4</sup></li> <li>• AIM (doxorubicin, ifosfamide, mesna)<sup>3-6</sup></li> <li>• MAID (mesna, doxorubicin, ifosfamide, dacarbazine)<sup>3,4,7,8</sup></li> <li>• Ifosfamide, epirubicin, mesna<sup>9</sup></li> <li>• Gemcitabine and docetaxel<sup>10,11</sup></li> <li>• Gemcitabine and vinorelbine<sup>f,12</sup></li> <li>• Gemcitabine and dacarbazine<sup>13</sup></li> <li>• Doxorubicin and olaratumab<sup>g,14</sup></li> </ul> | <u>Single agents</u> <ul style="list-style-type: none"> <li>• Doxorubicin<sup>3,4,15</sup></li> <li>• Ifosfamide<sup>9,16</sup></li> <li>• Epirubicin<sup>17</sup></li> <li>• Gemcitabine</li> <li>• Dacarbazine</li> <li>• Liposomal doxorubicin<sup>18</sup></li> <li>• Temozolomide<sup>f,19</sup></li> <li>• Vinorelbine<sup>f,20</sup></li> <li>• Eribulin<sup>f,h,21</sup></li> <li>• Trabectedin<sup>f,i,22,23,24</sup></li> <li>• Pazopanib<sup>f,j,25</sup></li> </ul> | <ul style="list-style-type: none"> <li>• Imatinib<sup>26,27</sup></li> <li>• Sunitinib<sup>28</sup></li> <li>• Regorafenib<sup>29</sup></li> </ul> <u>Disease progression after imatinib, sunitinib, and regorafenib</u> <ul style="list-style-type: none"> <li>• Sorafenib<sup>30-32</sup></li> <li>• Nilotinib<sup>33,34</sup></li> <li>• Dasatinib<sup>35</sup> (for patients with D842V mutation)</li> <li>• Pazopanib<sup>36</sup></li> <li>• Everolimus + TKI<sup>l</sup></li> </ul> | <ul style="list-style-type: none"> <li>• Sulindac<sup>37</sup> or other non-steroidal anti-inflammatory drugs (NSAIDs), including celecoxib</li> <li>• Tamoxifen ± sulindac<sup>38,39</sup></li> <li>• Toremifene<sup>40</sup></li> <li>• Methotrexate and vinblastine<sup>41</sup></li> <li>• Low-dose interferon<sup>42</sup></li> <li>• Doxorubicin-based regimens<sup>43-45</sup></li> <li>• Imatinib<sup>46,47</sup></li> <li>• Sorafenib<sup>48</sup></li> <li>• Methotrexate and vinorelbine<sup>49</sup></li> <li>• Liposomal doxorubicin<sup>50</sup></li> </ul> |

Non-Pleomorphic RhabdomyosarcomaCombination regimens

- Vincristine, dactinomycin, cyclophosphamide<sup>51</sup>
- Vincristine, doxorubicin, cyclophosphamide<sup>52</sup>
- Vincristine, doxorubicin, and cyclophosphamide alternating with ifosfamide and etoposide<sup>53</sup>
- Vincristine, doxorubicin, ifosfamide<sup>54</sup>
- Cyclophosphamide and topotecan<sup>55,56</sup>
- Ifosfamide and doxorubicin<sup>57</sup>
- For Soft Tissue Ewing Sarcoma, see NCCN Guidelines for Bone Cancer<sup>†</sup>

- Ifosfamide and etoposide<sup>58</sup>
- Irinotecan and vincristine<sup>59,60</sup>
- Vincristine and dactinomycin<sup>61</sup>
- Carboplatin and etoposide<sup>62</sup>
- Vinorelbine and low-dose cyclophosphamide<sup>63</sup>
- Vincristine, irinotecan, temozolomide<sup>64</sup>

Single agents

- Doxorubicin<sup>65</sup>
- Irinotecan<sup>56,66</sup>
- Topotecan<sup>67</sup>
- Vinorelbine<sup>f,68</sup>
- High-dose methotrexate<sup>m,69</sup>
- Trabectedin<sup>f,23,24,25</sup>

<sup>†</sup>To view the most recent version of these guidelines, visit NCCN.org.

<sup>a</sup>Prior to the initiation of therapy, all patients should be evaluated and managed by a multidisciplinary team with expertise and experience in sarcoma.

<sup>b</sup>For uterine sarcomas, see the NCCN Guidelines for Uterine Neoplasms<sup>†</sup>.

<sup>c</sup>Alveolar soft part sarcoma (ASPS), well-differentiated liposarcoma/atypical lipomatous tumor, and clear cell sarcomas are generally not sensitive to cytotoxic chemotherapy.

<sup>d</sup>Anthracycline-based regimens are preferred in the neoadjuvant and adjuvant setting.

<sup>e</sup>Regimens appropriate for pleomorphic rhabdomyosarcoma.

<sup>f</sup>Recommended only for palliative therapy.

<sup>g</sup>For use in STS histologies for which an anthracycline-containing regimen is appropriate.

<sup>h</sup>Category 1 recommendation for liposarcoma.

<sup>i</sup>Category 1 recommendation for liposarcoma and leiomyosarcoma (L-Types).

<sup>j</sup>Pazopanib should not be used for lipogenic sarcomas.

<sup>k</sup>Imatinib, sunitinib, and regorafenib are the three FDA agents approved for the treatment of GIST.

<sup>l</sup>TKIs to be considered for use in combination with everolimus include imatinib, sunitinib, or regorafenib.

<sup>m</sup>High-dose methotrexate may be useful for select patients with CNS or leptomeningeal involvement when RT is not feasible.

SARC-F  
1 OF 6

SYSTEMIC THERAPY AGENTS AND REGIMENS WITH ACTIVITY IN SOFT TISSUE SARCOMA<sup>a,c</sup>

|  |  |
|--|--|
| <u>Pigmented Villonodular Synovitis/Tenosynovial Giant Cell Tumor (PVNS/TGCT)</u> <ul style="list-style-type: none"><li>• Imatinib<sup>70</sup></li></ul>  |  |
| <u>Angiosarcoma</u> <ul style="list-style-type: none"><li>• Paclitaxel<sup>71,72</sup></li><li>• Docetaxel</li><li>• Vinorelbine<sup>f</sup></li><li>• Sorafenib<sup>73</sup></li><li>• Sunitinib<sup>74</sup></li><li>• Bevacizumab<sup>75</sup></li><li>• All other systemic therapy options as per Soft Tissue Sarcoma Subtypes with Non-Specific Histologies (SARC-F 1 of 6)</li></ul> | <u>Solitary Fibrous Tumor/Hemangiopericytoma</u> <ul style="list-style-type: none"><li>• Bevacizumab and temozolomide<sup>76</sup></li><li>• Sunitinib<sup>77,78</sup></li><li>• Sorafenib<sup>79</sup></li></ul>      |
| <u>Alveolar Soft Part Sarcoma (ASPS)</u> <ul style="list-style-type: none"><li>• Sunitinib<sup>80,81</sup> (category 2B)</li></ul>   | <u>PEComa, Recurrent Angiomyolipoma, Lymphangioleiomyomatosis</u> <ul style="list-style-type: none"><li>• Sirolimus<sup>82-85</sup></li><li>• Everolimus<sup>86</sup></li><li>• Temsirolimus<sup>87,88</sup></li></ul> |
| <u>Inflammatory Myofibroblastic Tumor (IMT) with Anaplastic Lymphoma Kinase (ALK) Translocation</u> <ul style="list-style-type: none"><li>• Crizotinib<sup>89</sup></li><li>• Ceritinib<sup>90</sup></li></ul>   |  |
| <u>Well-differentiated/Dedifferentiated Liposarcoma (WD-DDLS) for Retroperitoneal Sarcomas</u> <ul style="list-style-type: none"><li>• Palbociclib<sup>91,92</sup></li></ul>   |  |

<sup>a</sup>Prior to the initiation of therapy, all patients should be evaluated and managed by a multidisciplinary team with expertise and experience in sarcoma.  
<sup>c</sup>ASPS, well-differentiated liposarcoma/atypical lipomatous tumor, and clear cell sarcomas are generally not sensitive to cytotoxic chemotherapy.  
<sup>f</sup>Recommended only for palliative therapy.

## Soft Tissue Sarcoma, Version 2.2018

## SYSTEMIC THERAPY AGENTS AND REGIMENS WITH ACTIVITY IN SOFT TISSUE SARCOMA—References

- <sup>1</sup>Zalupski M, Metch B, Balcerzak S, et al. Phase III comparison of doxorubicin and dacarbazine given by bolus versus infusion in patients with soft-tissue sarcomas: A Southwest Oncology Group Study. *J Natl Cancer Inst* 1991;83:926-932.
- <sup>2</sup>Antman K, Crowley J, Balcerzak SP, et al. An intergroup phase III randomized study of doxorubicin and dacarbazine with or without ifosfamide and mesna in advanced soft tissue and bone sarcomas. *J Clin Oncol* 1993;11:1276-1285.
- <sup>3</sup>Adjuvant chemotherapy for localized resectable soft-tissue sarcoma of adults: Meta-analysis of individual data. Sarcoma Meta-analysis Collaboration. *Lancet* 1997;350:1647-1654.
- <sup>4</sup>Pervaiz N, Colterjohn N, Farrokhyar F, et al. A systematic meta-analysis of randomized controlled trials of adjuvant chemotherapy for localized resectable soft-tissue sarcoma. *Cancer* 2008;113:573-581.
- <sup>5</sup>Grobmyer SR, Maki RG, Demetri GD, et al. Neo-adjuvant chemotherapy for primary high-grade extremity soft tissue sarcoma. *Ann Oncol* 2004;15:1667-1672.
- <sup>6</sup>Edmonson J, Ryan L, Blum R, et al. Randomized comparison of doxorubicin alone versus ifosfamide plus doxorubicin or mitomycin, doxorubicin, and cisplatin against advanced soft tissue sarcomas. *J Clin Oncol* 1993;11:1269-1275.
- <sup>7</sup>Elias A, Ryan L, Sulkes A, et al. Response to mesna, doxorubicin, ifosfamide, and dacarbazine in 108 patients with metastatic or unresectable sarcoma and no prior chemotherapy. *J Clin Oncol* 1989;7:1208-1216.
- <sup>8</sup>Kraybill WG, Harris J, Spiro LJ, et al. Long-term results of a phase 2 study of neoadjuvant chemotherapy and radiotherapy in the management of high-risk, high-grade, soft tissue sarcomas of the extremities and body wall: Radiation Therapy Oncology Group Trial 9514. *Cancer* 2010;116:4613-4621.
- <sup>9</sup>Frustaci S, Gherlinzoni F, De Paoli A, et al. Adjuvant chemotherapy for soft tissue sarcomas of the extremities and girdles: results of the Italian randomized cooperative trial. *J Clin Oncol* 2001;19:1238-1247.
- <sup>10</sup>Hensley ML, Maki R, Venkatraman E, et al. Gemcitabine and docetaxel in patients with unresectable leiomyosarcoma: results of a phase II trial. *J Clin Oncol* 2002;20:2824-2831.
- <sup>11</sup>Maki RG, Wathen JK, Patel SR, et al. Randomized phase II study of gemcitabine and docetaxel compared with gemcitabine alone in patients with metastatic soft tissue sarcomas: results of sarcoma alliance for research through collaboration study 002. *J Clin Oncol* 2007;25:2755-2763.
- <sup>12</sup>Dileo P, Morgan JA, Zahrieh D, et al. Gemcitabine and vinorelbine combination chemotherapy for patients with advanced soft tissue sarcomas: results of a phase II trial. *Cancer* 2007;109:1863-1869.
- <sup>13</sup>Garcia-Del-Muro X, Lopez-Pousa A, Maurel J, et al. Randomized phase II study comparing gemcitabine plus dacarbazine versus dacarbazine alone in patients with previously treated soft tissue sarcoma: a Spanish Group for Research on Sarcomas study. *J Clin Oncol* 2011;29:2528-2533.
- <sup>14</sup>Tap WD, Jones RL, Van Tine BA, et al. Olaratumab and doxorubicin versus doxorubicin alone for treatment of soft-tissue sarcoma: an open-label phase 1b and randomised phase 2 trial. *Lancet* 2016;388:488-497.
- <sup>15</sup>Mack LA, Crowe PJ, Yang JL, et al. Preoperative chemoradiotherapy (modified Eilber protocol) provides maximum local control and minimal morbidity in patients with soft tissue sarcoma. *Ann Surg Oncol* 2005;12:646-653.
- <sup>16</sup>Antman KH, Elias A. Dana-Farber Cancer Institute studies in advanced sarcoma. *Semin Oncol* 1990;1(Suppl 2):7-15.
- <sup>17</sup>Petrioli R, Coratti A, Correale P, et al. Adjuvant epirubicin with or without ifosfamide for adult soft-tissue sarcoma. *Am J Clin Oncol* 2002;25:468-473.
- <sup>18</sup>Judson I, Radford J, Harris M, et al. Randomized phase II trial of pegylated liposomal doxorubicin versus doxorubicin in the treatment of advanced or metastatic soft tissue sarcoma: a study by the EORTC Soft Tissue and Bone Sarcoma Group. *Eur J Cancer* 2001; 37:870-877.
- <sup>19</sup>Talbot SM, Keohan ML, Hesdorffer M, et al. A Phase II trial of temozolomide in patients with unresectable or metastatic soft tissue sarcoma. *Cancer* 2003; 98:1942-1946.
- <sup>20</sup>Kuttesch JF Jr, Krailo MD, Madden T, et al. Phase II evaluation of intravenous vinorelbine (Navelbine) in recurrent or refractory pediatric malignancies: a Children's Oncology Group study. *Pediatr Blood Cancer* 2009; 53:590-593.
- <sup>21</sup>Schöffski P, Ray-Coquard IL, Cioffi A, et al. Activity of eribulin mesylate in patients with soft-tissue sarcoma: a phase 2 study in four independent histological subtypes. *Lancet Oncol* 2011;12:1045-1052.
- <sup>22</sup>Demetri GD, von Mehren M, Jones RL, et al. Efficacy and safety of trabectedin or dacarbazine for metastatic liposarcoma or leiomyosarcoma after failure of conventional chemotherapy: results of a phase III randomized multicenter clinical trial. *J Clin Oncol* 2015;33:1-8.
- <sup>23</sup>Kawai A, Araki N, Sugiura H, et al. Trabectedin monotherapy after standard chemotherapy versus best supportive care in patients with advanced, translocation-related sarcoma: a randomised, open-label, phase 2 study. *Lancet Oncol* 2015;16:406-416.
- <sup>24</sup>Samuels BL, Chawla S, Patel S, et al. Clinical outcomes and safety with trabectedin therapy in patients with advanced soft tissue sarcomas following failure of prior chemotherapy: results of a worldwide expanded access program study. *Ann Oncol* 2013;24:1703-1709.
- <sup>25</sup>van der Graaf WT, Blay JY, Chawla SP, et al. Pazopanib for metastatic soft-tissue sarcoma (PALETTE): a randomised, double-blind, placebo-controlled phase 3 trial. *Lancet* 2012;379:1879-1886.
- <sup>26</sup>Demetri GD, von Mehren M, Blanke CD, et al. Efficacy and safety of imatinib mesylate in advanced gastrointestinal stromal tumors. *N Engl J Med* 2002;347:472-480.
- <sup>27</sup>Verweij J, Casali PG, Zalcberg J, et al. Progression-free survival in gastrointestinal stromal tumours with high-dose imatinib: randomized trial. *Lancet* 2004;364:1127-1134.
- <sup>28</sup>Demetri GD, van Oosterom AT, Garrett CR, et al. Efficacy and safety of sunitinib in patients with advanced gastrointestinal stromal tumour after failure of imatinib: a randomised controlled trial. *Lancet* 2006;368:1329-1338.
- <sup>29</sup>Demetri GD, Reichardt P, Kang YK, et al. Efficacy and safety of regorafenib for advanced gastrointestinal stromal tumours after failure of imatinib and sunitinib (GRID): an international, multicentre, randomised, placebo-controlled, phase 3 trial. *Lancet* 2013;381:295-302.

SARC-F  
3 AND 4 OF 6



## SYSTEMIC THERAPY AGENTS AND REGIMENS WITH ACTIVITY IN SOFT TISSUE SARCOMA—References

- <sup>30</sup>Montemurro M, Gelderblom H, Bitz U, et al. Sorafenib as third- or fourth-line treatment of advanced gastrointestinal stromal tumour and pretreatment including both imatinib and sunitinib, and nilotinib: A retrospective analysis. *Eur J Cancer* 2013;49:1027-1031.
- <sup>31</sup>Kindler HL, Campbell NP, Wroblewski K, et al. Sorafenib (SOR) in patients (pts) with imatinib (IM) and sunitinib (SU)-resistant (RES) gastrointestinal stromal tumors (GIST): Final results of a University of Chicago Phase II Consortium trial [abstract]. *J Clin Oncol* 2011;29(Suppl):Abstract 10009.
- <sup>32</sup>Park SH, Ryu MH, Ryoo BY, et al. Sorafenib in patients with metastatic gastrointestinal stromal tumors who failed two or more prior tyrosine kinase inhibitors: a phase II study of Korean gastrointestinal stromal tumors study group. *Invest New Drugs* 2012;30:2377-2383.
- <sup>33</sup>Montemurro M, Schoffski P, Reichardt P, et al. Nilotinib in the treatment of advanced gastrointestinal stromal tumours resistant to both imatinib and sunitinib. *Eur J Cancer* 2009;45:2293-2297.
- <sup>34</sup>Sawaki A, Nishida T, Doi T, et al. Phase 2 study of nilotinib as third-line therapy for patients with gastrointestinal stromal tumor. *Cancer* 2011;117:4633-4641.
- <sup>35</sup>Trent JC, Wathen K, von Mehren M, et al. A phase II study of dasatinib for patients with imatinib-resistant gastrointestinal stromal tumor (GIST) [abstract]. *J Clin Oncol* 2011;29(Suppl):Abstract 10006.
- <sup>36</sup>Ganjoon KN, Villalobos VM, Kamaya A., et al. A multicenter phase II study of pazopanib in patients with advanced gastrointestinal stromal tumors (GIST) following failure of at least imatinib and sunitinib. *Ann Oncol* 2014;25:236-240.
- <sup>37</sup>Tsukada K, Church JM, Jagelman DJ et al. Noncytotoxic therapy for intra-abdominal desmoid tumor in patients with familial adenomatous polyposis. *Dis Colon Rectum* 1992;35:29-33.
- <sup>38</sup>Chao AS, Lai CH, Hsueh S, et al. Successful treatment of recurrent pelvic desmoid tumor with tamoxifen: case report. *Hum Reprod* 2000;15:311-313.
- <sup>39</sup>Hansmann A, Adolph C, Vogel T, et al. High-dose tamoxifen and sulindac as first-line treatment for desmoid tumors. *Cancer* 2004;100:612-620.
- <sup>40</sup>Benson JR MK, Baum M. Management of desmoid tumours including a case report of toremifene. *Ann Oncol* 1994;5:173-177.
- <sup>41</sup>Azzarelli A, Gronchi A, Bertulli R, et al. Low-dose chemotherapy with methotrexate and vinblastine for patients with advanced aggressive fibromatosis. *Cancer* 2001;92:1259-1264.
- <sup>42</sup>Leithner A, Schnack B, Katterschafka T, et al. Treatment of extra-abdominal desmoid tumors with interferon-alpha with or without tretinoin. *J Surg Oncol* 2000;73:21-25.
- <sup>43</sup>Seiter K, Kemeny N. Successful treatment of a desmoid tumor with doxorubicin. *Cancer* 1993;71:2242-2244.
- <sup>44</sup>Patel SR, Evans HL, Benjamin RS. Combination chemotherapy in adult desmoid tumors. *Cancer* 1993;72:3244-3247.
- <sup>45</sup>de Camargo VP, Keohan ML, D'Adamo DR, et al. Clinical outcomes of systemic therapy for patients with deep fibromatosis (desmoid tumor). *Cancer* 2010;116:2258-2265.
- <sup>46</sup>Chugh R, Wathen JK, Patel SR, et al. Efficacy of imatinib in aggressive fibromatosis: Results of a phase II multicenter Sarcoma Alliance for Research through Collaboration (SARC) trial. *Clin Cancer Res* 2010;16:4884-4891.
- <sup>47</sup>Penel N, Le Cesne A, Bui BN, et al. Imatinib for progressive and recurrent aggressive fibromatosis (desmoid tumors): an FNCLCC/French Sarcoma Group phase II trial with a long-term follow-up. *Ann Oncol* 2011;22:452-457.
- <sup>48</sup>Gounder MM, Lefkowitz RA, Keohan ML, et al. Activity of Sorafenib against desmoid tumor/deep fibromatosis. *Clin Cancer Res* 2011;17:4082-4090.
- <sup>49</sup>Weiss AJ, Horowitz S, Lackman RD. Therapy of desmoid tumors and fibromatosis using vinorelbine. *Am J Clin Oncol* 1999;22:193-195.
- <sup>50</sup>Constantinidou A, Jones RL, Scurr M, Al-Muderis O, Judson I. Pegylated liposomal doxorubicin, an effective, well-tolerated treatment for refractory aggressive fibromatosis. *Eur J Cancer* 2009;45:2930-2934.
- <sup>51</sup>Arndt CAS, Stoner JA, Hawkins DS, et al. Vincristine, actinomycin, and cyclophosphamide compared with vincristine, actinomycin, and cyclophosphamide alternating with vincristine, topotecan, and cyclophosphamide for intermediate-risk rhabdomyosarcoma: children's oncology group study D9803. *J Clin Oncol* 2009;27:5182-5188.
- <sup>52</sup>Little DJ, Ballo MT, Zagars GK, et al. Adult rhabdomyosarcoma: outcome following multimodality treatment. *Cancer* 2002;95:377-388.
- <sup>53</sup>Arndt CAS, Hawkins DS, Meyer WH, et al. Comparison of results of a pilot study of alternating vincristine/doxorubicin/cyclophosphamide and etoposide/ifosfamide with IRS-IV in intermediate risk rhabdomyosarcoma: a report from the Children's Oncology Group. *Pediatr Blood Cancer* 2008;50:33-36.
- <sup>54</sup>Ogilvie CM, Crawford EA, Slotcavage RL, et al. Treatment of adult rhabdomyosarcoma. *Am J Clin Oncol* 2010;33:128-131.
- <sup>55</sup>Saylors RL, Stine KC, Sullivan J, et al. Cyclophosphamide plus topotecan in children with recurrent or refractory solid tumors: a Pediatric Oncology Group phase II study. *J Clin Oncol* 2001;19:3463-3469.
- <sup>56</sup>Walterhouse DO, Lyden ER, Breitfeld PP, et al. Efficacy of topotecan and cyclophosphamide given in a phase II window trial in children with newly diagnosed metastatic rhabdomyosarcoma: a Children's Oncology Group study. *J Clin Oncol* 2004;22:1398-1403.
- <sup>57</sup>Sandler E, Lyden E, Ruymann F, et al. Efficacy of ifosfamide and doxorubicin given as a phase II "window" in children with newly diagnosed metastatic rhabdomyosarcoma: a report from the Intergroup Rhabdomyosarcoma Study Group. *Med Pediatr Oncol* 2001;37:442-448.
- <sup>58</sup>Breitfeld PP, Lyden E, Raney RB, et al. Ifosfamide and etoposide are superior to vincristine and melphalan for pediatric metastatic rhabdomyosarcoma when administered with irradiation and combination chemotherapy: a report from the Intergroup Rhabdomyosarcoma Study Group. *J Pediatr Hematol Oncol* 2001;23:225-233.
- <sup>59</sup>Pappo AS, Lyden E, Breitfeld P, et al. Two consecutive phase II window trials of irinotecan alone or in combination with vincristine for the treatment of metastatic rhabdomyosarcoma: the Children's Oncology Group. *J Clin Oncol* 2007;25:362-369.
- <sup>60</sup>Mascarenhas L, Lyden ER, Breitfeld PP, et al. Randomized phase II window trial of two schedules of irinotecan with vincristine in patients with first relapse or progression of rhabdomyosarcoma: a report from the Children's Oncology Group. *J Clin Oncol* 2010;28:4658-4663. Erratum in *J Clin Oncol* 2011;4629:1394.

SARC-F  
4 AND 5 OF 6

## Soft Tissue Sarcoma, Version 2.2018

## SYSTEMIC THERAPY AGENTS AND REGIMENS WITH ACTIVITY IN SOFT TISSUE SARCOMA—References

- <sup>61</sup>Raney RB, Walterhouse DO, Meza JL, et al. Results of the Intergroup Rhabdomyosarcoma Study Group D9602 protocol, using vincristine and dactinomycin with or without cyclophosphamide and radiation therapy, for newly diagnosed patients with low-risk embryonal rhabdomyosarcoma: a report from the Soft Tissue Sarcoma Committee of the Children's Oncology Group. *J Clin Oncol* 2011;29:1312-1318.
- <sup>62</sup>Klingebiel T, Pertl U, Hess CF, et al. Treatment of children with relapsed soft tissue sarcoma: report of the German CESS/CWS REZ 91 trial. *Med Pediatr Oncol* 1998;30:269-275.
- <sup>63</sup>Casanova M, Ferrari A, Bisogno G, et al. Vinorelbine and low-dose cyclophosphamide in the treatment of pediatric sarcomas: pilot study for the upcoming European Rhabdomyosarcoma Protocol. *Cancer* 2004;101:1664-1671.
- <sup>64</sup>McNall-Knapp RY, Williams CN, Reeves EN, et al. Extended Phase I Evaluation of Vincristine, Irinotecan, Temozolomide, and Antibiotic in Children with Refractory Solid Tumors. *Pediatr Blood Cancer* 2010; 54:909-915.
- <sup>65</sup>Bergeron C, Thiesse P, Rey A, et al. Revisiting the role of doxorubicin in the treatment of rhabdomyosarcoma: An up-front window study in newly diagnosed children with high-risk metastatic disease. *Eur J Cancer* 2008; 44:427-431.
- <sup>66</sup>Vassal G, Couanet D, Stockdale E, et al. Phase II trial of irinotecan in children with relapsed or refractory rhabdomyosarcoma: a joint study of the French Society of Pediatric Oncology and the United Kingdom Children's Cancer Study Group. *J Clin Oncol* 2007;25:356-361.
- <sup>67</sup>Pappo AS, Lyden E, Breneman J, et al. Up-front window trial of topotecan in previously untreated children and adolescents with metastatic rhabdomyosarcoma: an intergroup rhabdomyosarcoma study. *J Clin Oncol* 2001;19:213-219.
- <sup>68</sup>Ferrari A, Spreafico F. Vinorelbine in previously treated advanced childhood sarcomas: evidence of activity in rhabdomyosarcoma. *Cancer* 2002;94:3263-3268.
- <sup>69</sup>Pappo AS, Bowman LC, Furman WL, et al. A phase II trial of high-dose methotrexate in previously untreated children and adolescents with high-risk unresectable or metastatic rhabdomyosarcoma. *J Pediatr Hematol Oncol* 1997;19:438-442.
- <sup>70</sup>Cassier PA, Gelderblom H, Stacchiotti S, et al. Efficacy of imatinib mesylate for the treatment of locally advanced and/or metastatic tenosynovial giant cell tumor/pigmented villonodular synovitis. *Cancer* 2012;118:1649-1655.
- <sup>71</sup>Penel N, Bui BN, Bay J-O, et al. Phase II trial of weekly paclitaxel for unresectable angiosarcoma: the ANGIOTAX Study. *J Clin Oncol* 2008;26:5269-5274.
- <sup>72</sup>Schlemmer M, Reichardt P, Verweij J, et al. Paclitaxel in patients with advanced angiosarcomas of soft tissue: a retrospective study of the EORTC soft tissue and bone sarcoma group. *Eur J Cancer* 2008;44:2433-2436.
- <sup>73</sup>Maki RG, D'Adamo DR, Keohan ML, et al. Phase II study of sorafenib in patients with metastatic or recurrent sarcomas. *J Clin Oncol* 2009;27:3133-3140.
- <sup>74</sup>George S, Merriam P, Maki RG, et al. Multicenter phase II trial of sunitinib in the treatment of nongastrointestinal stromal tumor sarcomas. *J Clin Oncol* 2009;27:3154-3160.
- <sup>75</sup>Agulnik M, Yarber JL, Okuno SH, et al. An open-label, multicenter, phase II study of bevacizumab for the treatment of angiosarcoma and epithelioid hemangioendotheliomas. *Ann Oncol* 2013;24:257-263.
- <sup>76</sup>Park MS, Patel SR, Ludwig JA, et al. Activity of temozolomide and bevacizumab in the treatment of locally advanced, recurrent, and metastatic hemangiopericytoma and malignant solitary fibrous tumor. *Cancer* 2011;117:4939-4947.
- <sup>77</sup>Stacchiotti S, Negri T, Libertini M, et al. Sunitinib malate in solitary fibrous tumor (SFT). *Ann Oncol* 2012;23:3171-3179.
- <sup>78</sup>George S, Merriam P, Maki RG, et al. Multicenter Phase II Trial of Sunitinib in the Treatment of Nongastrointestinal Stromal Tumor Sarcomas. *J Clin Oncol* 2009;27:3154-3160.
- <sup>79</sup>Valentin T, Fournier C, Penel N, et al. Sorafenib in patients with progressive malignant solitary fibrous tumors: a subgroup analysis from a phase II study of the French Sarcoma Group (GSF/GETO). *Invest New Drugs* 2013;31:1626-1627.
- <sup>80</sup>Stacchiotti S, Negri T, Zaffaroni N, et al. Sunitinib in advanced alveolar soft part sarcoma: evidence of a direct antitumor effect. *Ann Oncol* 2011;22:1682-1690.
- <sup>81</sup>Stacchiotti S, Tamborini E, Marrari A, et al. Response to sunitinib malate in advanced alveolar soft part sarcoma. *Clin Cancer Res* 2009;15:1096-1104.
- <sup>82</sup>Bissler JJ, McCormack FX, Young LR, et al. Sirolimus for angiomyolipoma in tuberous sclerosis complex or lymphangioleiomyomatosis. *N Engl J Med* 2008;358:140-151.
- <sup>83</sup>Davies DM, de Vries PJ, Johnson SR, et al. Sirolimus therapy for angiomyolipoma in tuberous sclerosis and sporadic lymphangioleiomyomatosis: a phase 2 trial. *Clin Cancer Res* 2011;17:4071-4081.
- <sup>84</sup>Wagner AJ, Malinowska-Kolodziej I, Morgan JA, et al. Clinical activity of mTOR inhibition with sirolimus in malignant perivascular epithelioid cell tumors: targeting the pathogenic activation of mTORC1 in tumors. *J Clin Oncol* 2010;28:835-840.
- <sup>85</sup>McCormack FX, Inoue Y, Moss J, et al. Efficacy and safety of sirolimus in lymphangioleiomyomatosis. *N Engl J Med* 2011;364:1595-1606.
- <sup>86</sup>Gennatas C, Michalaki V, Kairi PV, et al. Successful treatment with the mTOR inhibitor everolimus in a patient with perivascular epithelioid cell tumor. *World J Surg Oncol* 2012;10:181.
- <sup>87</sup>Benson C, Vitell-Rasmussen J, Maruzzo M, et al. A retrospective study of patients with malignant PEComa receiving treatment with sirolimus or temsirolimus: the Royal Marsden Hospital experience. *Anticancer Res* 2014 Jul;34:3663-3668.
- <sup>88</sup>Italiano A, Delcambre C, Hostein I, et al. Treatment with the mTOR inhibitor temsirolimus in patients with malignant PEComa. *Ann Oncol* 2010;21:1135-1137.
- <sup>89</sup>Butrynski JE, D'Adamo DR, Hornick JL, et al. Crizotinib in ALK-rearranged inflammatory myofibroblastic tumor. *N Engl J Med* 2010;363:1727-1733.
- <sup>90</sup>Shaw AT, Kim DW, Mehra R, et al. Ceritinib in ALK-rearranged non-small-cell lung cancer. *N Engl J Med* 2014; 370:1189-97.
- <sup>91</sup>Dickson MA, Tap WD, Keohan ML, et al. Phase II Trial of the CDK4 inhibitor PD0332991 in patients with advanced CDK4-amplified well differentiated or dedifferentiated liposarcoma. *J Clin Oncol* 2013;31:2024-2028.
- <sup>92</sup>Dickson MA, Tap WD, Keohan ML, et al. Phase II Trial of the CDK4 inhibitor PD0332991 in patients with advanced CDK4-amplified liposarcoma [abstract]. *J Clin Oncol* 2013;27:31(Suppl):Abstract 10512.

SARC-F  
5 AND 6 OF 6

Cont. from page 537.

Soft Tissue Sarcoma, Version 2.2018

- GISTs
- Desmoid tumors (aggressive fibromatoses)
- RMS

Before treatment initiation, all patients should be evaluated and managed by a multidisciplinary team with extensive expertise and experience in the treatment of STS.<sup>8</sup> Because STS is rare and often complex, adherence to evidence-based recommendations is particularly important. Analysis of data from 15,957 patients with STS in the National Cancer Database (NCDB) showed that NCCN Guidelines–adherent treatment was associated with improved survival outcomes.<sup>9</sup>

This portion of the NCCN Guidelines discusses general principles and evidence for diagnosis and treatment of STS of the extremities, superficial trunk, or head and neck in adult patients. For treatment recommendations for intra-abdominal/retroperitoneal STS, GISTs, desmoid tumors, or RMS, please refer to the complete guidelines at [NCCN.org](http://NCCN.org).

## STS of the Extremities, Superficial Trunk, or Head and Neck

### Evaluation and Workup

The differential diagnosis of STS of the extremities includes ruling out desmoid tumors (aggressive fibromatosis), as well as the other malignant and benign lesions. An essential element of the workup is a history and physical (H&P) examination, imaging of the primary tumor and distant metastases, and a carefully planned biopsy (core needle or incisional biopsy). Adequate and high-quality imaging studies are crucial to good clinical management of patients, because the presence of metastatic disease may change the management of the primary lesion and the overall approach to the patient's disease management. The propensities to spread to various locations vary between the subtypes of sarcoma. Therefore, imaging should be individualized based on the subtype of sarcoma. Laboratory tests have a limited role.

Imaging studies should include cross-sectional imaging to provide details about tumor size and contiguity to nearby visceral structures and neurovascular landmarks. The panel recommends MRI with contrast, with or without CT with contrast. Other imaging studies such as CT angiogram and plain radiograph may be warranted in selected circumstances. Given the risk for hematogenous spread

from a high-grade sarcoma to the lungs, imaging of the chest (CT without contrast [preferred] or radiograph) is essential for accurate staging. Abdominal/pelvic CT should be considered for angiosarcoma, LMS, myxoid/round cell LPS, or epithelioid sarcoma as well as STS without definitive pathology prior to final resection. MRI of the total spine should be considered for myxoid/round cell LPS due to the higher risk of metastasis to the spine compared to other STSs.<sup>10–12</sup> Alveolar soft part sarcoma has a relatively increased propensity to metastasize to the brain, especially in patients with stage IV disease in the presence of pulmonary metastases.<sup>13</sup> Central nervous system MRI (or CT if MRI is contraindicated) should be considered for patients with alveolar soft part sarcoma and angiosarcoma.

PET scans may be useful in staging, prognostication, grading, and determining histopathologic response to chemotherapy.<sup>14–19</sup> The maximum standardized uptake value (SUVmax) of F18-deoxyglucose has been shown to correlate with tumor grade and prognostication.<sup>20,21</sup> In a retrospective study, tumor SUVmax determined by PET was an independent predictor of survival and disease progression.<sup>14</sup> Schuetze et al<sup>15</sup> reported that the pretreatment SUVmax and change in SUVmax after preoperative chemotherapy independently identified patients with a high risk of recurrence. The value of combined PET/CT in predicting disease-free survival (DFS) in patients receiving preoperative chemotherapy for STS is being evaluated in an ongoing large prospective study.

Based on the initial workup, the patients are assigned to one of the following categories<sup>22</sup>:

- Stage I
- Stage II–III
- Unresectable disease
- Stage IV (synchronous metastatic disease)
- Recurrent disease

## General Principles

### Surgery

Positive surgical margin is a strong predictor of local recurrence (LR) for patients with extremity STS.<sup>23–28</sup> Microscopically positive margins are associated with a higher rate of LR and a lower rate of DFS in patients with extremity sarcomas.<sup>23,24,26</sup> In a large cohort study (1,668 patients) that exam-

ined the clinical significance of the main predictors of LR in patients with STS of the extremity and trunk, the 10-year cumulative possibility of LR was significantly higher for patients with positive surgical margins (23.9 vs 9.2 for those with negative margins;  $P < .001$ ).<sup>27</sup> In a recent retrospective study that evaluated 278 patients with STS of the extremities treated between 2000 and 2006, patients with a positive margin were 3.76 times more likely to develop LR than those with negative margins (38% risk of LR after 6 years if the margins were positive vs 12% if the margins were negative).<sup>28</sup> Careful preoperative planning by an experienced sarcoma surgical team may enable anticipated planned positive margins in order to save critical structures without affording a worse oncologic outcome.<sup>29</sup>

Amputation was once considered the standard treatment to achieve local control in patients with extremity sarcomas.<sup>30</sup> Technical advances in reconstructive surgical procedures, implementation of multimodality therapy, and improved selection of patients for adjuvant therapy have minimized the functional deficits in patients who might otherwise require amputation. In 1982, a randomized control study of 43 patients showed that limb-sparing surgery with RT was an effective treatment in patients with high-grade STS of the extremities, with a LR rate of 15% and no difference in overall survival (OS) and DFS compared with amputation.<sup>31</sup> In another series of 77 patients treated with limb-sparing surgery without RT, the LR rate was only 7% and resection margin status was a significant predictor of LR.<sup>32</sup> The LR rate was 13% when the resection margin was  $\leq 1$  cm compared with 0% when the resection margin was  $\geq 1$  cm. In a retrospective study of 115 patients with an STS of hand or foot, radical amputation as an initial treatment did not decrease the probability of regional metastasis and also did not improve the disease-specific survival.<sup>33</sup>

Collectively, the data suggest that limb-sparing surgery with or without postoperative RT is an effective treatment option for extremity STS, and amputation should be reserved only for cases in which resection or resection with adequate margins cannot be performed without sacrificing the functional outcome. The guidelines recommend that the goal of surgery for patients with STS of extremities should be functional limb preservation, if possible, within the realm of an appropriate oncologic resection.

Limb-sparing surgery is recommended for most patients with STS of extremities to achieve local tumor control with minimal morbidity. Amputation may improve local control in patients who might not be candidates for limb-sparing surgery and should be considered with patient preference, or if the gross total resection of the tumor is expected to render the limb nonfunctional.<sup>34–37</sup> Before considering amputation, the patient should be evaluated by a surgeon with expertise in the treatment of STS. Evaluation for postoperative rehabilitation is recommended for all patients with extremity sarcoma. If indicated, rehabilitation should be continued until maximum function is achieved.

### Radiation Therapy

Data from randomized studies<sup>38–40</sup> and retrospective analyses<sup>41–45</sup> support the use of preoperative or postoperative external-beam RT (EBRT) in appropriately selected patients. Brachytherapy (alone or in combination with EBRT)<sup>42,46,47</sup> and intensity-modulated RT (IMRT)<sup>48,49</sup> have also been evaluated as an adjunct to surgery.

**Preoperative Versus Postoperative EBRT:** Various studies have examined the benefits and risks for preoperative and postoperative RT in treating STS of the extremity, head and neck, or superficial trunk.

Recently, examination of data from 27,969 patients with extremity STS in the NCDB identified both preoperative and postoperative RT as factors associated with increased OS.<sup>45</sup> However, that data showed that preoperative RT was predictive of achieving R0 resection.<sup>45</sup> In a phase III randomized study conducted by the Canadian Sarcoma Group, local control and progression-free survival (PFS) rates were similar in patients receiving either preoperative or postoperative RT in patients with localized primary or recurrent disease.<sup>40,50</sup> However, preoperative RT was associated with a greater incidence of acute wound complications (35% vs 17% for postoperative RT), especially in lower-extremity tumors (43% vs 5% for upper extremity tumors). Late-treatment-related side effects were more common in patients receiving postoperative RT, which is believed to be related to the higher RT dose (66 vs 50 Gy for preoperative RT) and the larger treatment volume.<sup>40,51</sup>

The efficacy of postoperative EBRT following limb-sparing surgery was demonstrated in a prospec-



tive randomized study (91 patients with high-grade lesions and 51 patients with low-grade lesions).<sup>39,52</sup> Postoperative RT significantly reduced the 10-year LR rate among patients with high-grade lesions (no LRs in patients who underwent surgery plus RT vs 22% in those who underwent surgery alone;  $P=.0028$ ). Among patients with low-grade lesions, the corresponding recurrence rates were 5% and 32%, respectively.<sup>39</sup> The probability of reduction in the LR rate in patients receiving EBRT was not significant in patients with low-grade lesions, suggesting postoperative RT after limb-sparing surgery may not be necessary for this group of patients. Outcomes at 20-year follow-up favored patients who received EBRT, but differences were not statistically significant. Ten-year OS was 82% and 77% for patients who received surgery alone versus surgery plus EBRT, and 20-year OS was 71% and 64% for these groups, respectively ( $P=.22$ ).<sup>52</sup>

The French Sarcoma Group recently reported on a cohort of 283 patients with resectable atypical lipomatous tumor (ALT)/well-differentiated liposarcoma (WDLS) of the extremity or superficial trunk from the Conticabase database. In these patients, postoperative RT significantly improved 5-year local relapse-free survival (98.3% vs 80.3%, with and without adjuvant RT, respectively;  $P<.001$ ).<sup>53</sup> Along with RT, tumor site and resection margin status were predictors of time to LR, but no difference in OS was seen.

In a report from the Memorial Sloan Kettering Cancer Center that reviewed the long-term outcomes of 200 patients treated with limb-sparing surgery, pathologically negative re-resection without RT was associated with a 5-year overall LR rate of 9%, at a median follow-up of 82 months.<sup>54</sup> Old age and/or stage III disease were associated with a higher rate of LR. Therefore, treatment decisions regarding the use of postoperative RT should be individualized and should not be solely based on the findings of margin-negative re-resection.

**Brachytherapy:** In a prospective randomized study, 164 patients with completely resected STS of the extremity or superficial trunk were randomized intraoperatively to receive either brachytherapy or no brachytherapy.<sup>46</sup> With a median follow-up time of 76 months, the 5-year local control rates were 82% and 69% in the brachytherapy and no brachytherapy groups, respectively. Patients with high-grade lesions

who received brachytherapy had higher local control rates compared with those who received no brachytherapy (89% and 66%, respectively). However, brachytherapy had no impact on local control in patients with low-grade lesions. The 5-year freedom-from-distant-recurrence rates were 83% and 76%, respectively, in the 2 groups. In a retrospective analysis of 202 adult patients with primary high-grade STS of the extremity, brachytherapy after limb-sparing surgery resulted in lower rates of wound complications, favorable 5-year local control, and distant relapse-free survival and OS rates (84%, 63%, and 70%, respectively).<sup>47</sup>

**IMRT:** In a retrospective analysis of 41 patients with STS of extremity treated with limb-sparing surgery, postoperative IMRT resulted in a 5-year local control rate of 94% in patients with negative as well as positive or close margins, in selected patients with high-risk features.<sup>48</sup> The risk of complications such as edema and joint stiffness were also favorable when compared with conventional RT. In a more recent phase II study, O'Sullivan et al<sup>55</sup> reported that preoperative IMRT resulted in lower wound complication rates in patients with high-grade lesions (30.5% vs 43% reported in an earlier study using conventional EBRT). In a nonrandomized comparison of IMRT and brachytherapy in patients with high-grade, primary, nonmetastatic STS of extremity, local control was significantly better with IMRT than with brachytherapy (5-year local control rates were 92% and 81%, respectively;  $P=.04$ ) despite higher rates of adverse features for IMRT.<sup>49</sup>

**Intraoperative RT (IORT):** Recent reports from a retrospective study suggest that IORT provides excellent local control for STS of the extremity.<sup>56,57</sup> Call et al<sup>57</sup> recently reported long-term outcomes for patients with STS of upper extremity treated with EBRT, surgery, and IORT. The 10-year local control and OS rates were 88% and 58%, respectively.<sup>57</sup> The 10-year local control rates were 89% and 86%, respectively, after margin-negative (R0) and margin-positive (R1 and R2) resections. IORT was also retrospectively examined in cohorts of patients with STS of the superficial trunk or extremity who received surgery, IORT, and EBRT at 3 Spanish institutions.<sup>58,59</sup> Five-year IORT in-field control was 86% and 70% for extremity and trunk wall STS, respectively. However, 5-year DFS was 62% in the ex-

tremity STS cohort and 45% in the trunk wall STS. Incomplete resection significantly impacted in-field control in both cohorts, and higher IORT dose was positively associated with in-field disease control in extremity STS.

Although the use of IMRT and IORT has resulted in excellent clinical outcomes, their efficacy needs to be confirmed in larger cohorts of patients with longer follow-up. Additionally, image guidance may continue to improve RT outcomes for patients with STS of the extremity. In a recent phase II trial (RTOG-0630; n=86), the use of preoperative image-guided RT to a reduced target volume resulted in significantly reduced late toxicity without any marginal field recurrences.<sup>60</sup> Additional studies will be required.

### Panel Recommendations

When EBRT is used, sophisticated treatment planning with IMRT, tomotherapy, and/or proton therapy can be used to improve therapeutic effect. RT is not a substitute for definitive surgical resection with negative margins, and re-resection to negative margins is preferable.

The usual dose of preoperative RT is 50 Gy in 1.8 to 2.0 Gy per fraction. If the patient has not previously received RT, one could attempt to control microscopic residual disease with postoperative RT if re-resection is not feasible. If wide margins are obtained, postoperative RT may not be necessary. For patients treated with preoperative RT followed by surgery, the guidelines recommend consideration of observation in addition to postoperative RT boost for patients with positive margins. There are data to suggest that boost for positive margins does not improve local control.<sup>61,62</sup> Given no clear evidence to suggest added benefit, the panel recommends that the decision to provide boost be individualized with careful consideration of potential toxicities.

The recommended EBRT boost doses are 16 to 18 Gy for microscopic residual disease and 20 to 26 Gy for macroscopic residual disease. Brachytherapy boosts should be delivered several days after surgery, through catheters placed at surgery, with doses of 16 to 26 Gy for low dose-rate (LDR) brachytherapy and 14 to 24 Gy for high-dose rate (HDR) brachytherapy, based on the margin status. Alternatively, IORT (10–12.5 Gy for microscopic residual disease and 15 Gy for gross residual disease) can be delivered im-

mediately after resection to the area at risk, avoiding the uninvolved organs.<sup>56</sup>

For patients who have not received preoperative RT, the postoperative choices include EBRT (50 Gy irrespective of surgical margins in 1.8–2.0 Gy per fraction), Intraoperative RT (IORT)<sub>w</sub> (10–16 Gy followed by 50 Gy EBRT), or brachytherapy. The guidelines recommend 45 Gy LDR brachytherapy or HDR equivalent for patients with negative margins. LDR brachytherapy (16–20 Gy) or HDR equivalent is recommended for patients with positive margins followed by EBRT. EBRT after IORT or brachytherapy is delivered to the target volume to a total dose of 50 Gy, after surgical healing is complete (3–8 weeks).

For patients treated with postoperative EBRT, the guidelines recommend an additional EBRT boost (unless prior IORT) to the original tumor bed based on the margin status (10–16 Gy for negative surgical margin; 16–18 Gy for microscopic residual disease; and 20–26 Gy for grossly positive margins). However, many institutions are no longer giving a boost after preoperative RT to patients who have widely negative margins, based on local control rates approaching 95% with preoperative RT at 50 Gy and negative margins. The panel also emphasizes that RT is not a substitute for suboptimal surgical resection and re-resection is preferred for patients with positive surgical margins.

### Treatment Guidelines by Stage

**Stage I:** Surgical wide resection (with intent to obtain negative margins) is the primary treatment for stage IA (T1, N0, M0, G1) and IB (T2–4, N0, M0, G1) tumors and is considered definitive if margins are greater than 1 cm or the fascial plane is intact.<sup>63,64</sup> If the surgical margins are 1.0 cm or less and without an intact fascial plane, re-resection may be necessary.<sup>54</sup> Treatment options including revision surgery versus observation should be presented at an experienced multidisciplinary sarcoma tumor board to determine advantages and disadvantages of the decision.

Data from prospective studies support the use of RT as an adjunct to surgery in appropriately selected patients based on an improvement in DFS although not OS.<sup>24,26,46</sup> Postoperative RT is recommended for patients with final surgical margins of 1.0 cm or less and without an intact fascial plane (category 2B for stage IA tumors and category 1 for stage IB). RT may



not be necessary in patients with small low-grade lesions (5 cm or less), because these tumors are less frequently associated with LR.<sup>39</sup> Therefore, observation is included as an option for patients with stage IA disease with final surgical margins of 1.0 cm or less and with an intact fascial plane.

En bloc resection with negative margins is generally sufficient to obtain long-term local control in patients with ALT/WDLS; RT is not indicated in most cases.<sup>65,66</sup> In a report that reviewed information for 91 patients with ALT/WDLS of the extremity and trunk, positive surgical margins were associated with reduced local RFS, suggesting that function-preserving re-resection when possible or adjuvant RT could be considered for selected patients with positive surgical margins.<sup>67</sup> RT may also be an appropriate treatment option for selected patients with recurrent disease or deeply infiltrative primary lesions with a risk of LR, depending on tumor location and patient age.<sup>68</sup>

**Stage II-III:** Treatment options should be decided by a multidisciplinary team with extensive experience in the treatment of patients with STS, based on the patient's age, performance status, comorbidities, location, and histologic subtype of the tumor.

Preoperative chemotherapy has been shown to improve OS, DFS, and local control rates in patients with high-grade STS of extremity and trunk, although acute reactions must be considered.<sup>69,70</sup> An earlier randomized study showed that preoperative chemotherapy was not associated with a major survival benefit for patients with high-grade tumors.<sup>71</sup> Histotype-specific neoadjuvant chemotherapy was examined in a recent international randomized controlled trial of patients with high-risk STS (n=287; ISG-STS, 1001).<sup>72</sup> Standard neoadjuvant chemotherapy (epirubicin/ifosfamide) was compared with histotype-specific regimens for myxoid LPS (trabectedin), LMS (gemcitabine/dacarbazine), synovial sarcoma (high-dose ifosfamide), MPNST (etoposide/ifosfamide), and UPS (gemcitabine/docetaxel). At 46 months, DFS was 62% for standard chemotherapy versus 38% for the histotype-tailored regimens (hazard ratio, 2.00; 95% CI, 1.22–3.26;  $P=.006$ ). Trial enrollment was closed due to futility.

Available evidence, although underpowered, suggests that anthracycline-based postoperative chemotherapy (now most commonly given as doxorubicin and ifosfamide or epirubicin and ifosfamide)

would improve DFS in selected patients with good performance status who are at high risk of recurrence.<sup>73–77</sup> Preoperative or postoperative EBRT has been shown to improve local control in patients with high-grade lesions.<sup>39,42,78</sup>

Large stage II or III high-grade extremity resectable tumors (greater than 8–10 cm) that are at high risk for LR and metastases should be considered for preoperative and postoperative therapy. However, data are available supporting surgery alone as an adequate treatment option in selected patients with high-grade lesions. Long-term results of a prospective study showed that selected patients with high-grade T1 lesions can be treated using surgery alone (R0 resection) with acceptable local control and excellent long-term survival.<sup>79</sup> In the surgery alone arm, the cumulative incidence rates of LR at 5 and 10 years were 7.9% and 10.6%, respectively, in patients who underwent R0 resection, and the 5- and 10-year sarcoma-specific death rates were 3.2%. In an analysis of 242 patients with localized STS of the trunk and extremity treated with limb-sparing surgery, the 10-year local control rate was 87% to 93% for patients with resection margins of <1 cm compared with 100% for those with resection margins of  $\geq 1$  cm ( $P=.04$ ).<sup>32</sup> Al-Refaie et al<sup>80</sup> also reported that the addition of RT did not result in any significant difference in OS or sarcoma-specific survival in patients with early-stage STS of the extremity.

Surgery preceded or followed by RT is recommended for patients with stage II tumors (T1, N0, M0, G2-3) that are resectable with acceptable functional outcomes (category 1 for preoperative or postoperative RT).<sup>39,40,50</sup> Surgery alone may be an option for patients with small tumors that can be resected with wider surgical margins.

Surgery followed by RT (category 1) with or without postoperative chemotherapy is the primary treatment for patients with stage IIIA (T2, N0, M0, G2-3) or IIIB (T3-4, N0, M0, G2-3) tumors that are resectable with acceptable functional outcomes. The impact of RT was analyzed in a SEER cohort of 2,606 patients with stage III soft-tissue extremity sarcoma. Similarly to smaller prospective studies and reviews, RT was associated with a significant 5-year survival benefit (65% vs 60%,  $P=.002$ ). However, the timing of RT (ie, preoperative vs postoperative) was not a significant factor for survival.<sup>81</sup> Because only limited and conflicting data are available regarding the

potential benefits of postoperative chemotherapy for patients with stage II or III disease, postoperative chemotherapy is included as a category 2B recommendation.<sup>73–77</sup> Preoperative RT (category 1), preoperative chemotherapy (category 2B), or chemoradiation (category 2B) are also included as options for this group of patients.

Radical lymphadenectomy may provide long-term survival benefit for patients with isolated lymph node involvement. In a study that examined the natural history of lymph node metastasis in patients with STS, the median survival was 4.3 months for patients not treated with radical lymphadenectomy compared with 16.3 months for patients who underwent radical lymphadenectomy.<sup>82</sup> The 5-year survival rate for the latter group of patients was 46%. The guidelines recommend regional lymph node dissection at the time of primary surgery for patients with stage III tumors with lymph node involvement.

Patients with stage II or III tumors that are resectable with adverse functional outcomes should be managed as described in the subsequent section for unresectable disease.

**Unresectable Disease:** Patients with unresectable tumors can be treated primarily with RT, chemoradiation, chemotherapy, or regional limb therapy. Tumors that become resectable with acceptable functional outcomes after primary treatment can be treated with surgery followed by RT (if not previously irradiated) with or without postoperative chemotherapy. Because only limited and conflicting data exist regarding the potential benefits of postoperative chemotherapy, it is included as a category 2B recommendation. For patients whose tumors remain resectable with adverse functional outcomes or unresectable after primary treatment, a subsequent distinction is made between patients who are asymptomatic and those who are symptomatic. Observation is an option for patients who are asymptomatic. For patients who are symptomatic, the treatment options include chemotherapy, palliative surgery, amputation, or best supportive care.

A randomized phase III trial examining intensified doxorubicin plus ifosfamide versus doxorubicin alone did not find an OS benefit for combination therapy in patients with unresectable, advanced, or metastatic STS (14.3 vs 12.8 months;  $P=.076$ ). However, response rates and PFS were improved for doxorubicin/ifosfamide compared with doxorubicin

alone (26% vs 14%;  $P=.0006$ ; 7.4 vs 4.6 months;  $P=.003$ ).<sup>83</sup> However, subset analyses ( $n=310$ ) indicated an OS benefit for doxorubicin/ifosfamide versus single-agent doxorubicin in patients with UPS.<sup>84</sup>

Definitive RT (70–80 Gy) can be considered for selected patients with unresectable tumors after primary treatment. In a single-institution study (112 patients, 43% extremity STS), tumor size and the dose of RT influenced local control and survival in patients with unresectable STS.<sup>85</sup> The local control rate was 51% for tumors  $<5$  cm and 9% for tumors  $>10$  cm. Patients who received 63 Gy or more had better 5-year local control, DFS, and OS rates (60%, 36%, and 52%, respectively) compared with patients who received  $<63$  Gy (22%, 10%, and 14%, respectively). Local control for patients receiving  $>63$  Gy was 72% for lesions  $\leq 5$  cm, 42% for lesions 5 to 10 cm, and 25% for lesions  $>10$  cm.

Regional limb therapy (isolated limb perfusion [ILP] and isolated limb infusion [ILI]) has been evaluated as a limb-sparing treatment for unresectable intermediate or high-grade extremity STS. ILP requires the use of tumor necrosis factor- $\alpha$  (TNF- $\alpha$ ) along with chemotherapy, which is not approved in the United States. ILI is a less invasive alternative to ILP for patients with unresectable STS of the extremities and can be used without TNF- $\alpha$ . Data from clinical trials suggest that ILP with melphalan or doxorubicin in combination with TNF- $\alpha$ <sup>86–89</sup> or ILI with doxorubicin or melphalan and dactinomycin<sup>90–94</sup> may be effective in the treatment of patients with unresectable STS of extremity.<sup>95</sup> Further prospective clinical trials are needed to better define the role for ILP or ILI in the management of patients with unresectable STS of the extremity.<sup>95</sup> The panel recommends that ILP for isolated regional or nodal disease be accompanied by surgical resection. ILP for recurrent disease should only be performed at institutions with experience in regional limb therapy.

**Stage IV (Synchronous Metastatic Disease):** Patients with metastatic stage IV disease (any T, N1, M0, any G; or any T, any N, M1, any G) have a poor prognosis with no disease-free interval.<sup>96,97</sup> Conflicting data exist on the potential survival benefit of metastasectomy. In a retrospective study of 48 patients with synchronous metastases, no improvement was seen in OS for patients treated with metastasectomy compared with those with unresectable disease.<sup>96</sup> In a more recent retrospective study involving 112 pa-

tients with metastatic disease at presentation, resection of metastatic disease, less than 4 pulmonary metastases, and the presence of lymph node metastases versus pulmonary metastases were identified as statistically significant variables for improved OS. The 5-year survival rate was 59% and 8%, respectively, for patients presenting with lymph node metastases and pulmonary metastases.<sup>97</sup> Pulmonary metastasectomy resulted in a median OS of 25.5 months in a retrospective analysis of 66 patients with sarcoma; however, recurrent metastasis was associated with poor prognosis.<sup>98</sup> Although recurrence is common after initial metastasectomy, data from a prospective review (n=539) suggested a potential survival benefit for repeat pulmonary metastasectomy in appropriately selected patients.<sup>99</sup>

Because no data are available to support the optimal management of patients presenting with metastatic disease, the guidelines are intentionally non-specific about the treatment options for this group. Referral to a medical oncologist with extensive experience in the treatment of STS is recommended. Treatment options should be based on many factors, including performance status, patient preferences, specific clinical problems from the metastases, and treatment availability. In addition, clinical trial is the preferred treatment option for patients with metastatic disease.

**Limited Metastases:** Patients with limited metastasis confined to a single organ and limited tumor bulk who are amenable to local therapy should receive primary tumor management as described for stage II or III tumors. Another option is to consider metastasectomy with or without chemotherapy with or without RT. The guidelines do not specify rules governing metastasectomy, which remains controversial.<sup>96,98,99</sup> Several variables, including tumor resectability, number and location of metastases, and performance status, influence the decision to use metastasectomy.<sup>97</sup> In addition, patients can also receive stereotactic body RT (SBRT) or chemotherapy as an alternate method for control of metastatic lesions. Several recent reviews and case series support the use of SBRT for local control, with potential survival benefits in selected patients.<sup>100–102</sup>

**Disseminated Metastases:** For patients presenting with disseminated disease, a subsequent distinction is made between asymptomatic and symptomatic pa-

tients. Observation with a “watchful waiting” strategy is a reasonable management option for asymptomatic patients, especially if patients have only a minimal burden of metastases (eg, subcentimeter pulmonary nodules). Symptomatic patients can be treated with palliative RT, surgery, or chemotherapy. Palliative RT involves expedient treatment with sufficient dose to halt tumor growth or cause tumor regression. The outcome of this approach depends on the rapidity of growth and the status of systemic disease. In addition, the guidelines have included ablation procedures (eg, radiofrequency ablation [RFA] or cryotherapy) or SBRT as options for symptomatic patients.

**Surveillance:** Surveillance is deemed important to detect recurrences that might still be potentially curable. However, very limited data are available in the literature on effective surveillance strategies.<sup>103–106</sup> Because patient risk never returns to zero, long-term follow-up is indicated, including consideration of MRI or CT scan.<sup>107</sup> There has never been a study to prove that the use of more sensitive CT scans in routine surveillance would improve clinical outcomes. According to a report from MD Anderson Cancer Center, routine use of chest CT adds little clinical benefit when risk of pulmonary metastases is low.<sup>108</sup> However, in certain subsets of patients in whom chest radiographs are difficult to interpret because of anatomic considerations (eg, scarring, emphysema), chest CT may be indicated. A retrospective review examined surveillance imaging in 94 patients with intermediate or high-grade localized extremity/trunk STS who underwent radical resection and RT.<sup>106</sup> Thirty patients (32%) experienced recurrence after a median follow-up of 60 months (5 local, 26 distant). Surveillance imaging led to the detection of LR in 2 of 5 cases and distant recurrence (lung) in 22 of 26 cases. The authors concluded that surveillance chest imaging may be most useful for the detection of asymptomatic distant recurrence (ie, in the lung), while primary site imaging may only be useful for patients at high risk of LR.

Ultrasound has been used for the detection of early LRs and for the detection of micronodules >0.5 cm in diameter.<sup>109–111</sup> In a retrospective analysis that evaluated the value of MRI and ultrasound for the detection of LR after surgery in 21 patients with STS of extremities, the sensitivity of ultrasound was

slightly higher than that of MRI (100% vs 83%) and the specificity was slightly lower than that of MRI (79% vs 93%).<sup>109</sup> However, the differences were not statistically significant, suggesting that both MRI and ultrasound were equally useful in the detection of LR after surgery. In a subsequent report, Arya et al<sup>110</sup> also reported that ultrasound is associated with high sensitivity and specificity (92% and 94%, respectively) in the detection of early LR in patients with STS. These results confirm that ultrasound can be useful for the detection of LR. However, as reported by Choi et al,<sup>109</sup> ultrasound may be more difficult to interpret than MRI during the early postoperative period. Therefore, MRI should be used if ultrasound results are inconclusive.

The guidelines outline a prudent follow-up schedule by disease stage that avoids excessive testing. Higher grade and larger tumors have a higher risk of dissemination; therefore, the surveillance recommendations for patients with these tumors are somewhat more intensive, particularly for the first 3 years after resection. After 10 years, the likelihood of developing a recurrence is small and follow-up should be individualized.

Patients with stage I tumors are routinely followed up with H&P every 3 to 6 months for 2 to 3 years and then annually. Chest imaging is recommended every 6 to 12 months by CT (preferred) or radiograph. Postoperative baseline and periodic imaging of the primary tumor site is recommended based on estimated risk of locoregional recurrence. MRI with and without contrast and/or CT with contrast is recommended; ultrasound can be considered for the detection of LR in patients with smaller, superficial lesions and should be performed by an ultrasonographer with experience in musculoskeletal disease.<sup>109,110</sup> However, in situations in which the area is easily followed up using physical examination, imaging may not be required.<sup>112</sup>

For stage II-III and synchronous stage IV disease, postoperative re-imaging using MRI with and without contrast (preferred) or CT with contrast should be used to assess the primary tumor site and rule out metastatic disease. Baseline and periodic imaging of the primary site are recommended based on risk of locoregional recurrence; ultrasound can be considered for small, superficial lesions. H&P and imaging of the chest and other known sites of metastatic disease should be performed every 2 to 6 months for 2

to 3 years, then every 6 months for the next 2 years, and then annually.

**Recurrent Disease:** The management of recurrent disease encompasses a heterogeneous group of patients and clinical scenarios. In retrospective studies, isolated LR at sites other than the head and neck and deep trunk, resectability of recurrent and metastatic disease, disease-free interval, and number of metastases were identified as important predictive factors for long-term survival.<sup>113–115</sup>

For a patient with LR, treatment decisions should be made using the same algorithm as for patients with a new primary lesion.<sup>116</sup> In patients with LR, some case series suggest that combined conservative surgery and re-irradiation provide superior local control compared with local re-excision alone.<sup>117</sup> However, others have reported that conservative surgery alone results in local control in a minority of patients with locally recurrent disease after previous excision and EBRT,<sup>118</sup> likely reflecting differences in patient selection for surgery and RT or surgery alone. Therefore, the guidelines recommend that if LR can be excised, a decision regarding the use of re-irradiation will need to be made on a case-by-case basis. Traditionally, the re-irradiation has been done with postoperative brachytherapy, but now brachytherapy may be used in combination with IMRT to reduce the risks of morbidity with re-irradiation.

For patients with metastatic recurrences, the guidelines distinguish between limited metastases confined to a single organ, disseminated metastases, and isolated regional disease with nodal involvement. The treatment options for patients with limited metastases confined to a single organ or disseminated metastases are similar to that described for stage IV disease at presentation. In patients with isolated regional disease or nodal involvement, options include (1) regional node dissection with or without RT or chemotherapy; (2) metastasectomy with or without pre- or postoperative chemotherapy and/or RT; (3) SBRT; or (4) ILP/ILI with surgery. Limited data are available on the use of chemotherapy in patients undergoing metastasectomy. Results from a recent retrospective analysis suggest that chemotherapy has minimal impact on the survival of patients with metastatic extremity STS undergoing pulmonary metastasectomy.<sup>119</sup>



## References

- Siegel RL, Miller KD, Jemal A. Cancer statistics, 2018. *CA Cancer J Clin* 2018;68:7–30.
- Ma GL, Murphy JD, Martinez ME, Sicklick JK. Epidemiology of gastrointestinal stromal tumors in the era of histology codes: results of a population-based study. *Cancer Epidemiol Biomarkers Prev* 2015;24:298–302.
- Brady MS, Gaynor JJ, Brennan MF. Radiation-associated sarcoma of bone and soft tissue. *Arch Surg* 1992;127:1379–1385.
- Zahm S, Fraumeni JJ. The epidemiology of soft tissue sarcoma. *Semin Oncol* 1997;24:504–514.
- Penel N, Grosjean J, Robin YM, et al. Frequency of certain established risk factors in soft tissue sarcomas in adults: a prospective descriptive study of 658 cases. *Sarcoma* 2008;2008:459386.
- Cancer Facts & Figures 2018. Atlanta: American Cancer Society; 2018. Available at: <https://www.cancer.org/research/cancer-facts-statistics/all-cancer-facts-figures/cancer-facts-figures-2018.html>. Accessed April 25, 2018.
- Pisters PWT, Weiss M, Maki R. Soft-Tissue sarcomas In: Haller DG, Wagman LD, Camphausen C, Hoskins WJ, eds. *Cancer Management: A Multidisciplinary Approach Medical, Surgical, & Radiation Oncology* (ed 14): UBM Medica LLC; 2011.
- Clasby R, Tilling K, Smith MA, Fletcher CD. Variable management of soft tissue sarcoma: regional audit with implications for specialist care. *Br J Surg* 1997;84:1692–1696.
- Voss RK, Chiang YJ, Torres KE, et al. Adherence to National Comprehensive Cancer Network Guidelines is associated with improved survival for patients with stage 2A and stages 2B and 3 extremity and superficial trunk soft tissue sarcoma. *Ann Surg Oncol* 2017;24:3271–3278.
- Schwab JH, Boland P, Guo T, et al. Skeletal metastases in myxoid liposarcoma: an unusual pattern of distant spread. *Ann Surg Oncol* 2007;14:1507–1514.
- Schwab JH, Boland PJ, Antonescu C, et al. Spinal metastases from myxoid liposarcoma warrant screening with magnetic resonance imaging. *Cancer* 2007;110:1815–1822.
- Tateishi U, Hasegawa T, Beppu Y, et al. Prognostic significance of MRI findings in patients with myxoid-round cell liposarcoma. *AJR Am J Roentgenol* 2004;182:725–731.
- Portera CA, Jr, Ho V, Patel SR, et al. Alveolar soft part sarcoma: clinical course and patterns of metastasis in 70 patients treated at a single institution. *Cancer* 2001;91:585–591.
- Eary JF, O'Sullivan F, Powitan Y, et al. Sarcoma tumor FDG uptake measured by PET and patient outcome: a retrospective analysis. *Eur J Nucl Med Mol Imaging* 2002;29:1149–1154.
- Schuetz SM, Rubin BP, Vernon C, et al. Use of positron emission tomography in localized extremity soft tissue sarcoma treated with neoadjuvant chemotherapy. *Cancer* 2005;103:339–348.
- Schuetz SM. Utility of positron emission tomography in sarcomas. *Curr Opin Oncol* 2006;18:369–373.
- Evilevitch V, Weber WA, Tap WD, et al. Reduction of glucose metabolic activity is more accurate than change in size at predicting histopathologic response to neoadjuvant therapy in high-grade soft-tissue sarcomas. *Clin Cancer Res* 2008;14:715–720.
- Benz MR, Czernin J, Allen-Auerbach MS, et al. FDG-PET/CT imaging predicts histopathologic treatment responses after the initial cycle of neoadjuvant chemotherapy in high-grade soft-tissue sarcomas. *Clin Cancer Res* 2009;15:2856–2863.
- Quak E, van de Luijngaarden AC, de Geus-Oei LF, et al. Clinical applications of positron emission tomography in sarcoma management. *Expert Rev Anticancer Ther* 2011;11:195–204.
- Folpe AL, Lyles RH, Sprouse JT, et al. (F-18) fluorodeoxyglucose positron emission tomography as a predictor of pathologic grade and other prognostic variables in bone and soft tissue sarcoma. *Clin Cancer Res* 2000;6:1279–1287.
- Schwarzbach MH, Dimitrakopoulou-Strauss A, Willeke F, et al. Clinical value of [18-F] fluorodeoxyglucose positron emission tomography imaging in soft tissue sarcomas. *Ann Surg* 2000;231:380–386.
- Amin MB, Edge SB, Greene FL, et al. *AJCC Cancer Staging Manual*, 8th edition. New York: Springer; 2017.
- Pisters PW, Leung DH, Woodruff J, et al. Analysis of prognostic factors in 1,041 patients with localized soft tissue sarcomas of the extremities. *J Clin Oncol* 1996;14:1679–1689.
- Fleming JB, Berman RS, Cheng SC, et al. Long-term outcome of patients with American Joint Committee on Cancer stage IIB extremity soft tissue sarcomas. *J Clin Oncol* 1999;17:2772–2780.
- Gerrand CH, Wunder JS, Kandel RA, et al. Classification of positive margins after resection of soft-tissue sarcoma of the limb predicts the risk of local recurrence. *J Bone Joint Surg Br* 2001;83:1149–1155.
- McKee MD, Liu DF, Brooks JJ, et al. The prognostic significance of margin width for extremity and trunk sarcoma. *J Surg Oncol* 2004;85:68–76.
- Biau DJ, Ferguson PC, Chung P, et al. Local recurrence of localized soft tissue sarcoma: a new look at old predictors. *Cancer* 2012;118:5867–5877.
- Alamanda VK, Crosby SN, Archer KR, et al. Predictors and clinical significance of local recurrence in extremity soft tissue sarcoma. *Acta Oncol* 2013;52:793–802.
- O'Donnell PW, Griffin AM, Eward WC, et al. The effect of the setting of a positive surgical margin in soft tissue sarcoma. *Cancer* 2014;120:2866–2875.
- Clark MA, Thomas JM. Amputation for soft-tissue sarcoma. *Lancet Oncol* 2003;4:335–342.
- Rosenberg SA, Tepper J, Glatstein E, et al. The treatment of soft-tissue sarcomas of the extremities: prospective randomized evaluations of (1) limb-sparing surgery plus radiation therapy compared with amputation and (2) the role of adjuvant chemotherapy. *Ann Surg* 1982;196:305–315.
- Baldini EH, Goldberg J, Jenner C, et al. Long-term outcomes after function-sparing surgery without radiotherapy for soft tissue sarcoma of the extremities and trunk. *J Clin Oncol* 1999;17:3252–3259.
- Lin PP, Guzel VB, Pisters PW, et al. Surgical management of soft tissue sarcomas of the hand and foot. *Cancer* 2002;95:852–861.
- Williard WC, Hajdu SI, Casper ES, Brennan MF. Comparison of amputation with limb-sparing operations for adult soft tissue sarcoma of the extremity. *Ann Surg* 1992;215:269–275.
- Stojadinovic A, Jaques DP, Leung DH, et al. Amputation for recurrent soft tissue sarcoma of the extremity: indications and outcome. *Ann Surg Oncol* 2001;8:509–518.
- Ghert MA, Abudu A, Driver N, et al. The indications for and the prognostic significance of amputation as the primary surgical procedure for localized soft tissue sarcoma of the extremity. *Ann Surg Oncol* 2005;12:10–17.
- Alamanda VK, Crosby SN, Archer KR, et al. Amputation for extremity soft tissue sarcoma does not increase overall survival: a retrospective cohort study. *Eur J Surg Oncol* 2012;38:1178–1183.
- Wilson AN, Davis A, Bell RS, et al. Local control of soft tissue sarcoma of the extremity: the experience of a multidisciplinary sarcoma group with definitive surgery and radiotherapy. *Eur J Cancer* 1994;30A:746–751.
- Yang JC, Chang AE, Baker AR, et al. Randomized prospective study of the benefit of adjuvant radiation therapy in the treatment of soft tissue sarcomas of the extremity. *J Clin Oncol* 1998;16:197–203.
- O'Sullivan B, Davis AM, Turcotte R, et al. Preoperative versus postoperative radiotherapy in soft-tissue sarcoma of the limbs: a randomised trial. *Lancet* 2002;359:2235–2241.
- Cheng EY, Dusenbery KE, Winters MR, Thompson RC. Soft tissue sarcomas: preoperative versus postoperative radiotherapy. *J Surg Oncol* 1996;61:90–99.
- Alekhtiar KM, Velasco J, Zelefsky MJ, et al. Adjuvant radiotherapy for margin-positive high-grade soft tissue sarcoma of the extremity. *Int J Radiat Oncol Biol Phys* 2000;48:1051–1058.
- Jebsen NL, Trovik CS, Bauer HC, et al. Radiotherapy to improve local control regardless of surgical margin and malignancy grade in extremity and trunk wall soft tissue sarcoma: a Scandinavian sarcoma group study. *Int J Radiat Oncol Biol Phys* 2008;71:1196–1203.
- Kim B, Chen YL, Kirsch DG, et al. An effective preoperative three-dimensional radiotherapy target volume for extremity soft tissue sarcoma and the effect of margin width on local control. *Int J Radiat Oncol Biol Phys* 2010;77:843–850.
- Gingrich AA, Batani SB, Monjazeb AM, et al. Neoadjuvant Radiotherapy is Associated with R0 Resection and Improved Survival for Patients with Extremity Soft Tissue Sarcoma Undergoing Surgery: A National Cancer Database Analysis. *Ann Surg Oncol* 2017;24:3252–3263.
- Pisters PW, Harrison LB, Leung DH, et al. Long-term results of a prospective randomized trial of adjuvant brachytherapy in soft tissue sarcoma. *J Clin Oncol* 1996;14:859–868.
- Alekhtiar KM, Leung D, Zelefsky MJ, et al. Adjuvant brachytherapy for primary high-grade soft tissue sarcoma of the extremity. *Ann Surg Oncol* 2002;9:48–56.

## Soft Tissue Sarcoma, Version 2.2018

48. Alektiar KM, Brennan MF, Healey JH, Singer S. Impact of intensity-modulated radiation therapy on local control in primary soft-tissue sarcoma of the extremity. *J Clin Oncol* 2008;26:3440–3444.
49. Alektiar KM, Brennan MF, Singer S. Local control comparison of adjuvant brachytherapy to intensity-modulated radiotherapy in primary high-grade sarcoma of the extremity. *Cancer* 2011;117:3229–3234.
50. O'Sullivan B, Davis A, Turcotte R, et al. Five-year results of a randomized phase III trial of pre-operative vs post-operative radiotherapy in extremity soft tissue sarcoma [abstract]. *J Clin Oncol* 2004;22(14\_Suppl):Abstract 9007.
51. Davis AM, O'Sullivan B, Turcotte R, et al. Late radiation morbidity following randomization to preoperative versus postoperative radiotherapy in extremity soft tissue sarcoma. *Radiother Oncol* 2005;75:48–53.
52. Beane JD, Yang JC, White D, et al. Efficacy of adjuvant radiation therapy in the treatment of soft tissue sarcoma of the extremity: 20-year follow-up of a randomized prospective trial. *Ann Surg Oncol* 2014;21:2484–2489.
53. Cassier PA, Kantor G, Bonvalot S, et al. Adjuvant radiotherapy for extremity and trunk wall atypical lipomatous tumor/well-differentiated LPS (ALT/WD-LPS): a French Sarcoma Group (GSF-GETO) study. *Ann Oncol* 2014;25:1854–1860.
54. Cahlon O, Spierer M, Brennan MF, et al. Long-term outcomes in extremity soft tissue sarcoma after a pathologically negative re-resection and without radiotherapy. *Cancer* 2008;112:2774–2779.
55. O'Sullivan B, Griffin AM, Dickie CI, et al. Phase 2 study of preoperative image-guided intensity-modulated radiation therapy to reduce wound and combined modality morbidities in lower extremity soft tissue sarcoma. *Cancer* 2013;119:1878–1884.
56. Tran QNH, Kim AC, Gottschalk AR, et al. Clinical outcomes of intraoperative radiation therapy for extremity sarcomas. *Sarcoma* 2006;2006:91671–91671.
57. Call JA, Stafford SL, Petersen IA, Haddock MG. Use of intraoperative radiotherapy for upper-extremity soft-tissue sarcomas: analysis of disease outcomes and toxicity. *Am J Clin Oncol* 2014;37:81–85.
58. Calvo FA, Sole CV, Polo A, et al. Limb-sparing management with surgical resection, external-beam and intraoperative electron-beam radiation therapy boost for patients with primary soft tissue sarcoma of the extremity: a multicentric pooled analysis of long-term outcomes. *Strahlenther Onkol* 2014;190:891–898.
59. Sole CV, Calvo FA, Cambeiro M, et al. Intraoperative radiotherapy-containing multidisciplinary management of trunk-wall soft-tissue sarcomas. *Clin Transl Oncol* 2014;16:834–842.
60. Wang D, Zhang Q, Eisenberg BL, et al. Significant reduction of late toxicities in patients with extremity sarcoma treated with image-guided radiation therapy to a reduced target volume: Results of Radiation Therapy Oncology Group RTOG-0630 Trial. *J Clin Oncol* 2015;33:2231–2238.
61. Al Yami A, Griffin AM, Ferguson PC, et al. Positive surgical margins in soft tissue sarcoma treated with preoperative radiation: is a postoperative boost necessary? *Int J Radiat Oncol Biol Phys* 2010;77:1191–1197.
62. Pan E, Goldberg SI, Chen YL, et al. Role of post-operative radiation boost for soft tissue sarcomas with positive margins following pre-operative radiation and surgery. *J Surg Oncol* 2014;110:817–822.
63. Geer RJ, Woodruff J, Casper ES, Brennan MF. Management of small soft-tissue sarcoma of the extremity in adults. *Arch Surg* 1992;127:1285–1289.
64. Karakousis CP, Emrich LJ, Rao U, Khalil M. Limb salvage in soft tissue sarcomas with selective combination of modalities. *Eur J Surg Oncol* 1991;17:71–80.
65. Billing V, Mertens F, Domanski HA, Rydholm A. Deep-seated ordinary and atypical lipomas: histopathology, cytogenetics, clinical features, and outcome in 215 tumours of the extremity and trunk wall. *J Bone Joint Surg Br* 2008;90:929–933.
66. Somerville SMM, Patton JT, Luscombe JC, et al. Clinical outcomes of deep atypical lipomas (well-differentiated lipoma-like liposarcomas) of the extremities. *ANZ J Surg* 2005;75:803–806.
67. Kooby DA, Antonescu CR, Brennan MF, Singer S. Atypical lipomatous tumor/well-differentiated liposarcoma of the extremity and trunk wall: importance of histological subtype with treatment recommendations. *Ann Surg Oncol* 2004;11:78–84.
68. Kang J, Botros M, Goldberg S, et al. The use of radiation therapy in the management of selected patients with atypical lipomas. *Sarcoma* 2013;2013:485483–485483.
69. Kraybill WG, Harris J, Spiro IJ, et al. Long-term results of a phase 2 study of neoadjuvant chemotherapy and radiotherapy in the management of high-risk, high-grade, soft tissue sarcomas of the extremities and body wall: Radiation Therapy Oncology Group Trial 9514. *Cancer* 2010;116:4613–4621.
70. Mullen JT, Kobayashi W, Wang JJ, et al. Long-term follow-up of patients treated with neoadjuvant chemotherapy and radiotherapy for large, extremity soft tissue sarcomas. *Cancer* 2012;118:3758–3765.
71. Gortzak E, Azzarelli A, Buesa J, et al. A randomised phase II study on neo-adjuvant chemotherapy for 'high-risk' adult soft-tissue sarcoma. *Eur J Cancer* 2001;37:1096–1103.
72. Gronchi A, Ferrari S, Quagliuolo V, et al. Histotype-tailored neoadjuvant chemotherapy versus standard chemotherapy in patients with high-risk soft-tissue sarcomas (ISG-STSS 1001): an international, open-label, randomised, controlled, phase 3, multicentre trial. *Lancet Oncol* 2017;18:812–822.
73. Bramwell V, Rouesse J, Steward W, et al. Adjuvant CYVADIC chemotherapy for adult soft tissue sarcoma—reduced local recurrence but no improvement in survival: a study of the European Organization for Research and Treatment of Cancer Soft Tissue and Bone Sarcoma Group. *J Clin Oncol* 1994;12:1137–1149.
74. Frustaci S, Gherlinzoni F, De Paoli A, et al. Adjuvant chemotherapy for adult soft tissue sarcomas of the extremities and girdles: results of the Italian randomized cooperative trial. *J Clin Oncol* 2001;19:1238–1247.
75. Petrioli R, Coratti A, Correale P, et al. Adjuvant epirubicin with or without ifosfamide for adult soft-tissue sarcoma. *Am J Clin Oncol* 2002;25:468–473.
76. Woll PJ, van Glabbeke M, Hohenberger P, et al. Adjuvant chemotherapy (CT) with doxorubicin and ifosfamide in resected soft tissue sarcoma (STS): Interim analysis of a randomised phase III trial [abstract]. *J Clin Oncol* 2002;25(18\_Suppl):Abstract 10008.
77. Fakhrai N, Ehm C, Kostler WJ, et al. Intensified adjuvant IFADIC chemotherapy in combination with radiotherapy versus radiotherapy alone for soft tissue sarcoma: long-term follow-up of a prospective randomized feasibility trial. *Wien Klin Wochenschr* 2010;122:614–619.
78. Albertsmeier M, Rauch A, Roeder F, et al. External Beam Radiation Therapy for Resectable Soft Tissue Sarcoma: A Systematic Review and Meta-Analysis. *Ann Surg Oncol* 2018;25:754–767.
79. Pisters PW, Pollock RE, Lewis VO, et al. Long-term results of prospective trial of surgery alone with selective use of radiation for patients with T1 extremity and trunk soft tissue sarcomas. *Ann Surg* 2007;246:675–681; discussion 681–682.
80. Al-Rafeie WB, Habermann EB, Jensen EH, et al. Surgery alone is adequate treatment for early stage soft tissue sarcoma of the extremity. *Br J Surg* 2010;97:707–713.
81. Kachare SD, Brinkley J, Vohra NA, et al. Radiotherapy associated with improved survival for high-grade sarcoma of the extremity. *J Surg Oncol* 2015;112:338–343.
82. Fong Y, Coit DG, Woodruff JM, Brennan MF. Lymph node metastasis from soft tissue sarcoma in adults. Analysis of data from a prospective database of 1772 sarcoma patients. *Ann Surg* 1993;217:72–77.
83. Judson I, Verweij J, Gelderblom H, et al. Doxorubicin alone versus intensified doxorubicin plus ifosfamide for first-line treatment of advanced or metastatic soft-tissue sarcoma: a randomised controlled phase 3 trial. *Lancet Oncol* 2014;15:415–423.
84. Young RJ, Litiere S, Lia M, et al. Predictive and prognostic factors associated with soft tissue sarcoma response to chemotherapy: a subgroup analysis of the European Organisation for Research and Treatment of Cancer 62012 study. *Acta Oncol* 2017;56:1013–1020.
85. Kepka L, DeLaney TF, Suit HD, Goldberg SI. Results of radiation therapy for unresected soft-tissue sarcomas. *Int J Radiat Oncol Biol Phys* 2005;63:852–859.
86. Grunhagen DJ, de Wilt JHW, Graveland WJ, et al. Outcome and prognostic factor analysis of 217 consecutive isolated limb perfusions with tumor necrosis factor-alpha and melphalan for limb-threatening soft tissue sarcoma. *Cancer* 2006;106:1776–1784.
87. Wray CJ, Benjamin RS, Hunt KK, et al. Isolated limb perfusion for unresectable extremity sarcoma: Results of 2 single-institution phase 2 trials. *Cancer* 2011;117:3235–3241.
88. Deroose JP, Eggermont AMM, van Geel AN, et al. Long-term results of tumor necrosis factor alpha- and melphalan-based isolated limb perfusion in locally advanced extremity soft tissue sarcomas. *J Clin Oncol* 2011;29:4036–4044.
89. Bhanu A, Broom L, Nepogodiev D, et al. Outcomes of isolated limb perfusion in the treatment of extremity soft tissue sarcoma: a systematic review. *Eur J Surg Oncol* 2013;39:311–319.



## Soft Tissue Sarcoma, Version 2.2018

90. Hegazy MAF, Koth SZ, Sakr H, et al. Preoperative isolated limb infusion of doxorubicin and external irradiation for limb-threatening soft tissue sarcomas. *Ann Surg Oncol* 2007;14:568–576.
91. Moncrieff MD, Kroon HM, Kam PC, et al. Isolated limb infusion for advanced soft tissue sarcoma of the extremity. *Ann Surg Oncol* 2008;15:2749–2756.
92. Brady MS, Brown K, Patel A, et al. Isolated limb infusion with melphalan and dactinomycin for regional melanoma and soft-tissue sarcoma of the extremity: final report of a phase II clinical trial. *Melanoma Res* 2009;19:106–111.
93. Turaga KK, Beasley GM, Kane JM, et al. Limb preservation with isolated limb infusion for locally advanced nonmelanoma cutaneous and soft-tissue malignant neoplasms. *Arch Surg* 2011;146:870–875.
94. Mullinax JE, Kroon HM, Thompson JF, et al. Isolated limb infusion as a limb salvage strategy for locally advanced extremity sarcoma. *J Am Coll Surg* 2017;224:635–642.
95. Neuwirth MG, Song Y, Sinnamon AJ, et al. Isolated limb perfusion and infusion for extremity soft tissue sarcoma: a contemporary systematic review and meta-analysis. *Ann Surg Oncol* 2017;24:3803–3810.
96. Kane JM, Finley JW, Driscoll D, et al. The treatment and outcome of patients with soft tissue sarcomas and synchronous metastases. *Sarcoma* 2002;6:69–73.
97. Ferguson PC, Deheshi BM, Chung P, et al. Soft tissue sarcoma presenting with metastatic disease: outcome with primary surgical resection. *Cancer* 2011;117:372–379.
98. Okiror L, Peleki A, Moffat D, et al. Survival following pulmonary metastasectomy for sarcoma. *Thorac Cardiovasc Surg* 2016;64:146–149.
99. Chudgar NP, Brennan ME, Tan KS, et al. Is repeat pulmonary metastasectomy indicated for soft tissue sarcoma? *Ann Thorac Surg* 2017;104:1837–1845.
100. Baumann BC, Nagda SN, Kolker JD, et al. Efficacy and safety of stereotactic body radiation therapy for the treatment of pulmonary metastases from sarcoma: a potential alternative to resection. *J Surg Oncol* 2016;114:65–69.
101. Dhakal S, Corbin KS, Milano MT, et al. Stereotactic body radiotherapy for pulmonary metastases from soft-tissue sarcomas: excellent local lesion control and improved patient survival. *Int J Radiat Oncol Biol Phys* 2012;82:940–945.
102. Navarria P, Ascolese AM, Cozzi L, et al. Stereotactic body radiation therapy for lung metastases from soft tissue sarcoma. *Eur J Cancer* 2015;51:668–674.
103. Whooley BP, Mooney MM, Gibbs JF, Kraybill WG. Effective follow-up strategies in soft tissue sarcoma. *Semin Surg Oncol* 1999;17:83–87.
104. Whooley BP, Gibbs JF, Mooney MM, et al. Primary extremity sarcoma: what is the appropriate follow-up? *Ann Surg Oncol* 2000;7:9–14.
105. Kane JM, 3rd. Surveillance strategies for patients following surgical resection of soft tissue sarcomas. *Curr Opin Oncol* 2004;16:328–332.
106. Patel SA, Royce TJ, Barysaukas CM, et al. Surveillance imaging patterns and outcomes following radiation therapy and radical resection for localized extremity and trunk soft tissue sarcoma. *Ann Surg Oncol* 2017;24:1588–1595.
107. Lewis JJ, Leung D, Casper ES, et al. Multifactorial analysis of long-term follow-up (more than 5 years) of primary extremity sarcoma. *Arch Surg* 1999;134:190–194.
108. Fleming JB, Cantor SB, Varma DG, et al. Utility of chest computed tomography for staging in patients with T1 extremity soft tissue sarcomas. *Cancer* 2001;92:863–868.
109. Choi H, Varma DG, Fornage BD, et al. Soft-tissue sarcoma: MR imaging vs sonography for detection of local recurrence after surgery. *AJR Am J Roentgenol* 1991;157:353–358.
110. Arya S, Nagarkatti DG, Dudhat SB, et al. Soft tissue sarcomas: ultrasonographic evaluation of local recurrences. *Clin Radiol* 2000;55:193–197.
111. Briccoli A, Galletti S, Salone M, et al. Ultrasonography is superior to computed tomography and magnetic resonance imaging in determining superficial resection margins of malignant chest wall tumors. *J Ultrasound Med* 2007;26:157–162.
112. Cheney MD, Giraud C, Goldberg SI, et al. MRI surveillance following treatment of extremity soft tissue sarcoma. *J Surg Oncol* 2014;109:593–596.
113. Billingsley KG, Burt ME, Jara E, et al. Pulmonary metastases from soft tissue sarcoma: analysis of patterns of diseases and postmetastasis survival. *Ann Surg* 1999;229:602–610.
114. Zagars GK, Ballo MT, Pisters PWT, et al. Prognostic factors for disease-specific survival after first relapse of soft-tissue sarcoma: analysis of 402 patients with disease relapse after initial conservative surgery and radiotherapy. *Int J Radiat Oncol Biol Phys* 2003;57:739–747.
115. Kim S, Ott HC, Wright CD, et al. Pulmonary resection of metastatic sarcoma: prognostic factors associated with improved outcomes. *Ann Thorac Surg* 2011;92:1780–1786.
116. Singer S, Antman K, Corson JM, Eberlein TJ. Long-term salvageability for patients with locally recurrent soft-tissue sarcomas. *Arch Surg* 1992;127:548–553.
117. Catton C, Davis A, Bell R, et al. Soft tissue sarcoma of the extremity. limb salvage after failure of combined conservative therapy. *Radiother Oncol* 1996;41:209–214.
118. Torres MA, Ballo MT, Butler CE, et al. Management of locally recurrent soft-tissue sarcoma after prior surgery and radiation therapy. *Int J Radiat Oncol Biol Phys* 2007;67:1124–1129.
119. Canter RJ, Qin LX, Downey RJ, et al. Perioperative chemotherapy in patients undergoing pulmonary resection for metastatic soft-tissue sarcoma of the extremity: a retrospective analysis. *Cancer* 2007;110:2050–2060.

## Soft Tissue Sarcoma, Version 2.2018

| Individual Disclosures for Soft Tissue Sarcoma Panel |   |   |  |                |
|--|---|---|--|----------------|
| Panel Member   | Clinical Research Support/Data Safety Monitoring Board  | Scientific Advisory Boards, Consultant, or Expert Witness   | Promotional Advisory Boards, Consultant, or Speakers Bureau  | Date Completed |
| Robert S. Benjamin, MD <sup>b</sup>                  | Eli Lilly and Company, and Johnson & Johnson  | Eli Lilly and Company, and Karyopharm Therapeutics, Inc.  | None   | 3/15/17        |
| Sarah Boles, MD                                      | None  | None  | None   | 7/24/17        |
| Marilyn M. Bui, MD, PhD                              | None  | None  | None   | 12/5/17        |
| Kristen N. Ganjoo, MD                                | None  | Daiichi- Sankyo Co., and Novartis Pharmaceuticals Corporation   | None   | 7/14/17        |
| Suzanne George, MD                                   | Bayer HealthCare; Deciphera Pharmaceuticals, Inc.; Novartis Pharmaceuticals Corporation; and Pfizer Inc.  | None  | None   | 1/22/17        |
| Ricardo J. Gonzalez, MD                              | None  | None  | None   | 1/10/17        |
| Martin J. Heslin, MD                                 | None  | BestDoctors   | None   | 9/15/17        |
| John M. Kane, III, MD                                | None  | None  | None   | 8/30/17        |
| Vicki Keedy, MD, MSCI                                | Arog Pharmaceuticals, Inc.; AstraZeneca Pharmaceuticals LP; CytRx Corporation; Daiichi- Sankyo Co.; Eli Lilly and Company; GlaxoSmithKline; Immune Design; Janssen Pharmaceutica Products, LP; Karyopharm Therapeutics, Inc.; MedPacto, Inc.; Pfizer Inc.; Plexxikon, Inc.; Threshold Pharmaceuticals; and TRACON Pharmaceuticals | Janssen Pharmaceutica Products, LP  | None   | 7/7/17         |
| Edward Kim, MD                                       | Johnson & Johnson; Merck & Co., Inc.; Morphotek, Inc.; and Novartis Pharmaceuticals Corporation   | None  | None   | 11/1/17        |
| Henry Koon, MD                                       | Bristol-Myers Squibb Company, and Merck & Co., Inc.   | None  | Bristol-Myers Squibb Company   | 4/14/17        |
| Joel Mayerson, MD                                    | None  | Onkos Surgical, Inc.  | Johnson & Johnson  | 2/26/18        |
| Martin McCarter, MD                                  | None  | Debbie's Dream Foundation - Curing Stomach Cancer   | None   | 3/29/18        |
| Sean V. McGarry, MD                                  | None  | Musculoskeletal Transplant Foundation   | None   | 3/21/18        |
| Christian Meyer, MD, PhD                             | Eisai Inc., and Janssen Pharmaceutica Products, LP  | Eisai Inc., and Janssen Pharmaceutica Products, LP  | None   | 3/27/17        |
| Zachary S. Morris MD, PhD                            | None  | None  | None   | 1/8/17         |
| Richard J. O'Donnell, MD                             | None  | None  | None   | 8/5/17         |
| Alberto S. Pappo, MD                                 | None  | None  | None   | 2/20/18        |
| I. Benjamin Paz, MD <sup>a</sup>                     | None  | None  | None   | 6/13/17        |
| Ivy A. Petersen, MD                                  | None  | None  | None   | 6/13/17        |
| John D. Pfeifer, MD, PhD <sup>a</sup>                | illumina  | PierianDx, and Strand Analytical Laboratories   | None   | 11/26/17       |
| R. Lor Randall, MD, FACS <sup>a</sup>                | Children's Oncology Group   | Alan B. Slifka Foundation; Biomet, Inc.; International Society of Pediatric Oncology; Musculoskeletal Transplant Foundation; and Sarcoma Foundation of America        | Biomet, Inc.; Daiichi- Sankyo Co.; Gerson Lehrman Group; Musculoskeletal Transplant Foundation; and OnLive | 8/30/17        |
| Richard F. Riedel, MD <sup>b</sup>                   | Aadi; Arog Pharmaceuticals, Inc.; Daiichi-Sankyo Co.; Ignyta, Inc.; Immune Design Karyopharm Therapeutics, Inc.; Lilly; Plexxikon Inc.; Threshold Pharmaceuticals; Tokalas, Inc.; and TRACON Pharmaceuticals  | Daiichi- Sankyo Co.; Eisai Inc.; Eli Lilly and Company Ignyta, Inc.; Janssen Pharmaceutica Products, LP; and Lilly  | None   | 9/18/17        |
| Bernice Ruo, MD                                      | None  | None  | None   | 7/7/16         |
| Scott Schuetz, MD, PhD                               | AB Science; Amgen Inc.; CytRx Corporation; Daiichi- Sankyo Co.; and Eli Lilly and Company   | Janssen Pharmaceutica Products, LP  | None   | 3/24/17        |
| William D. Tap, MD                                   | Adaptimmune; Agios, Inc.; Blueprint Medicines; Daiichi- Sankyo Co.; Eli Lilly and Company; Immune Design; Millennium Pharmaceuticals, Inc.; Novartis Pharmaceuticals Corporation; Plexxikon Inc.; and TRACON Pharmaceuticals  | Blueprint Medicines; Eisai Inc.; Eli Lilly and Company; EMD Serono, Inc.; Immune Design; Janssen Pharmaceutica Products, LP; and Novartis Pharmaceuticals Corporation | None   | 8/31/17        |
| Margaret von Mehren, MD                              | Arog Pharmaceuticals, Inc.; Arqule, Inc.; Blueprint Medicines; CytRx Corporation; Immune Design; Karyopharm Therapeutics; and Sarcoma Alliance for Research Through Collaboration   | Deciphera Pharmaceuticals, Inc., and Janssen Pharmaceutica Products, LP   | None   | 3/25/17        |
| Jeffrey D. Wayne, MD                                 | None  | None  | None   | 8/17/17        |

The NCCN Guidelines Staff have no conflicts to disclose.

<sup>a</sup>The following individuals have disclosed that they have an Employment/Governing Board, Patent, Equity, or Royalty:

I. Benjamin Paz MD: LS Biopath, Inc.

John Pfeifer, MD, PhD: PierianDX, an NGS software vendor that currently has no cash value

R. Lor Randall MD, FACS: Association of Bone and Joint Surgeons

<sup>b</sup>The following individuals have disclosed that they have a spouse/domestic partner/dependent potential conflict:

Robert Benjamin, MD: Gilead Sciences, Inc.; Johnson & Johnson; Merck & Co., Inc.; and Pfizer Inc.

Richard Riedel, MD: Limbguard, LLC