

Sparing the anterior cruciate ligament remnant: is it worth the hassle?

Rocco Papalia[†], Francesco Franceschi[†], Sebastiano Vasta[†], Alberto Di Martino[†], Nicola Maffulli^{*†}, and Vincenzo Denaro[†]

[†]Department of Orthopaedic and Trauma Surgery, Campus Biomedico University of Rome, Via Alvaro del Portillo 200, Rome, Italy, and [‡]Centre for Sports and Exercise Medicine, Barts and The London School of Medicine and Dentistry, Mile End Hospital, 275 Bancroft Road, London E1 4DG, UK

Introduction: Anterior cruciate ligament (ACL) rupture is the most common surgically treated ligament injury. Many efforts have been taken to reconstruct it as anatomically as possible to restore knee stability and, possibly, prevent knee osteoarthritis.

Sources of data: A literature search was performed using the isolated or combined keywords 'ACL augmentation remnant', 'ACL reconstruction and remnant and stump', 'ACL reconstruction and remnant and stump preserving and stability' and 'ACL remnant complete tear' with no limit regarding the year of publication. We identified seven published studies.

Areas of agreement: The ACL remnant might accelerate the vascularization and the ligamentization of the graft and contribute to faster graft innervation leading to a better proprioception.

Areas of controversy: The role of the ACL remnant is debated, because, although it may increase the risk of impingement and the formation of cyclops lesion, its preservation can improve proprioception, biomechanical functions and vascularity. However, the current assessment methods to assess proprioception, vascularization and the ligamentization do not lead to hard evidence that preservation of the remnant confers clinically relevant advantages over its excision.

Growing points: The ACL remnant has been demonstrated in experimental studies to have a role in improving revascularization, ligamentization and reinnervation of the graft, but these findings are still not supported by clinical findings. A more direct way to assess proprioceptive function after ACL reconstruction and appropriately conducted powered and rigorously prospective randomized double-blind studies comparing the clinical outcomes of excising the remnant to leaving it *in situ* are necessary.

Keywords: anterior cruciate ligament injury/remnant/proprioception/reconstruction

Accepted: December 5, 2011

*Correspondence address.
Centre for Sports and
Exercise Medicine, Barts
and The London School
of Medicine and
Dentistry, Mile End
Hospital, 275 Bancroft
Road, London E1 4DG,
UK. E-mail: n.maffulli@
qmul.ac.uk

Introduction

The anterior cruciate ligament (ACL) is a restraint to anterior tibial displacement and a stabilizer of tibial rotation.^{1,2} Of the 200 000 ACL tears occurring each year in the USA,³ ~50% undergo arthroscopic reconstruction.⁴ The goal of management of ACL insufficiency is to restore knee function, primarily to allow patients to return to pre-injury activity levels and possibly to prevent meniscal tears to avoid the onset and progression of knee osteoarthritis (OA).^{5,6} The ACL is often described as composed of two bundles, namely the antero-medial bundle (AM) and the postero-lateral bundle (PL). The functional tensioning of the two bundles depends on the position of the knee. Close to extension, the AM bundle is relatively loose and the PL bundle is tight. When the knee is flexed, the AM bundle is tight and the PL bundle is loose.^{7,8} Recently, several authors have proposed anatomical reconstruction of the AM and PL bundles (double-bundle reconstruction) as to obtain optimal anterior–posterior and rotational stability. The concept of double-bundle ACL reconstruction arises from biomechanical studies^{8,9–11} demonstrating the inability of some single-bundle techniques, reconstructing only the AM bundle, to fully restore knee stability and longitudinal studies showing the development of OA in patients who received single-bundle ACL reconstruction.¹² The knee joint works in an optimal fashion through the precise complex interaction of the nervous and musculoskeletal systems.¹³ However, these mechanical concepts do not translate into superior clinical performance of double-bundle reconstruction over traditional single-bundle reconstruction.¹⁴

Proprioceptive afferent neural input is at the basis of neuromuscular coordination that influences the biomechanical behaviour of the knee, including the ACL.¹⁵ In essence, restoration of stability of the ACL deficient knee does not depend only on a surgical technique, but is also affected by anatomical, biomechanical and functional (neuromuscular) factors. Recently, there has been a great interest on the possible role of the remnant of the ACL following its tear. Although the preservation of the remnant may increase the risk of impingement and the formation of cyclops lesion,^{16–18} it can improve proprioceptive, biomechanical functions and vascularity. The aim of our study is to understand whether preserving the remnant of the injured cruciate ligaments can improve knee proprioception reaching better results in terms of knee stability using a systematic review approach.

Search and study selection

A literature search was performed using the isolated or combined, 'ACL reconstruction and remnant', 'ACL reconstruction and remnant and stump preserving and stability' and 'ACL remnant complete tear' with no limit regarding the year of publication.

PubMed (<http://www.ncbi.nlm.nih.gov/sites/entrez/>), Google Scholar (<http://scholar.google.it/>), CINAHL (<http://www.ebscohost.com/cinahl/>), Cochrane Central (<http://www.thecochranelibrary.com/view/0/index.html>) and Embase Biomedical (<http://www.embase.com/>) databases were accessed on 23 July 2011 to search English, Spanish, French, Portuguese and Italian publications.

At the first electronic search, 816 articles were identified. Two authors (RP and AT) independently reviewed the text of each abstract. Full-text versions were obtained to include or exclude the study. The reference lists of the selected articles were reviewed by hand to identify articles not identified at the electronic search. All journals were considered and all relevant articles were retrieved. Studies focusing on clinical status of patients who had undergone ACL reconstruction with a preserving stump were selected. Biomechanical reports, studies on animals, cadavers, *in vitro*, case reports, literature reviews, technical notes, letters to editors and instructional course were also excluded. Thirty-two articles investigating outcomes following ACL reconstruction with or without preservation of the ACL remnant were identified. To avoid bias, all these articles were reviewed and discussed by all the authors: 25 articles were excluded because either they did not report clinical data or reported data on the reconstruction of the one ruptured bundle in the case of isolated antero-medial or postero-lateral ACL tears. Finally, seven publications relevant to the topic at hand were included (Fig. 1).

Quality assessment

Two investigators (RP and AT) separately evaluated each article using the Coleman Methodology Score (CMS), a 10 criteria validated scoring system assessing the study methodological quality, with a final score ranging from 0 to 100. An investigation scoring 100 would represent a perfect study design with no influence of chance, various biases and confounding factors. The two investigators discussed scores where more than a two point difference was evident, until consensus was reached.

Process of inclusion of the studies

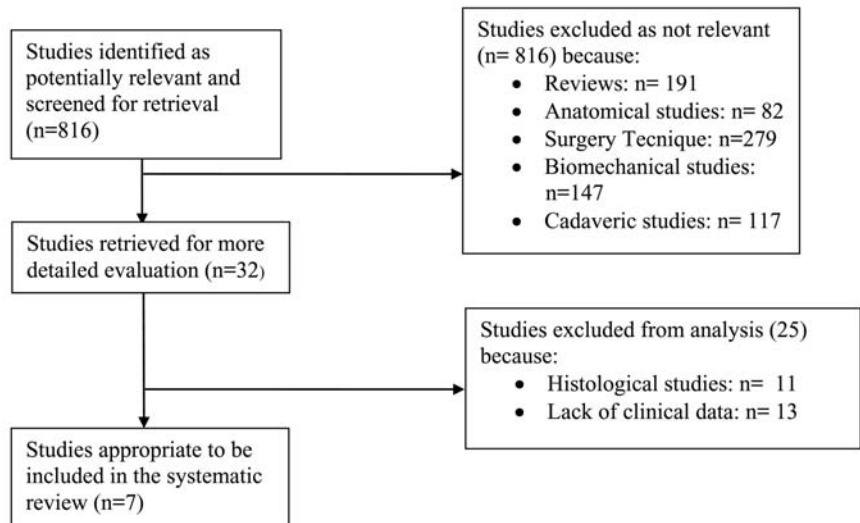


Fig. 1 Process of inclusion of the studies.

Additionally, data on gender, age, types of surgery, comorbidities and complications and scores were assessed.

Results

Seven studies (one randomized controlled clinical trial¹⁹ and six retrospective^{20–24} studies) were evaluated in the present review.

Pre-operative features

The mean age at surgery was 28.32 years, ranging from 20.6²² to 32.2 years.²¹

Study size and follow-up

A total of 369 patients who had undergone ACL surgery were involved (250 males and 119 females). The mean follow-up of these patients was 22.6 months (ranging from 12^{19,25} to 50²⁴; Table 1). The average modified CMS was 67.9 (range: 56^{22,25}–86¹⁹; Table 2).

Table 1 Sample data and study evidence level.

Study and year	Type of study	Level of evidence (Av. 3.14; SD 1.07)	No. patient recruited (Av. 85.71, SD 71.58)	No. of effective patients (Av. 58.57, SD 49.66)	M (Av. 35.71, SD 32.61)	W (Av. 17.71, SD 17.77)	Mean follow-up (months) (Av. 22.63, SD 15.69)	Mean age at surgery (years) (Av. 28.32, SD 5.23)
Anh <i>et al.</i> ²⁰	Retrospective cohort study	3	68	41 (remnant) + 41 (control group)	35	6	6.3 ± 0.7	NA
Anh <i>et al.</i> ²¹	Case series	4	63	53	42	11	27.7	32.2
Gao <i>et al.</i> ²⁴	Retrospective cohort study	4	235	159	105	54	50	30 +/- 7
Gohil <i>et al.</i> ¹⁹	Randomized controlled clinical trial	1	49	25 (control group) + 24 (remnant)	13 + 14	12 + 13	12	30.50
Kim <i>et al.</i> ²⁵	Retrospective cohort study	3	27	21	14	7	12	NA
Lee <i>et al.</i> ²³	Retrospective cohort study	4	42	16	12	4	35.1	NA
Nakamae <i>et al.</i> ²²	Diagnostic study of non-consecutive patients	3	116	30	15	15	15.3	20.6

Av., average; NA, not available; SD, standard deviation.

Table 2 CMS system.

Study and year	(1) Size of the study	(2) Mean follow-up	(3) Number of different surgical procedures	(4) Type of study	(5) Diagnostic certainty	(6) Description of surgical technique	(7) Description of post-operative rehabilitation	(8) Outcome criteria	(9) Procedure for outcome	(10) Description of subject selection process	Coleman Score
Anh <i>et al.</i> ²⁰	7	0	10	0	5	5	0	10	12	13	62
Anh <i>et al.</i> ²¹	7	5	10	0	0	5	10	10	12	10	69
Gao <i>et al.</i> ²⁴	0	5	10	0	5	5	10	10	9	12	66
Gohil <i>et al.</i> ¹⁹	7	5	10	15	0	5	10	10	12	12	86
Kim <i>et al.</i> ²⁵	10	5	10	0	5	5	10	10	12	13	80
Lee <i>et al.</i> ²³	4	2	10	0	0	5	10	10	8	7	56
Nakamae <i>et al.</i> ²²	4	2	10	0	5	5	0	10	12	8	56

Year of publication

There was no evidence of a statistically significant association between the year of publication and CMS data (R: 0.04), and more recently published investigations did not score better than older studies.

Subject selection

A satisfying description of the patient's selection criteria was described in five of the seven (71.4%)^{19–21,23,24} studies.

Surgical description and post-operative rehabilitation

The description of the surgical technique was adequately given in all studies, and five of seven studies reported exhaustively (10/10 at the Coleman Score) on post-operative rehabilitation.^{21,25,19,23,24} In the other two studies, the description of the rehabilitation programme was incomplete or not reported.^{22,20}

Surgical technique

ACL reconstructions are performed using different techniques (Table 3).

Table 3 Type of surgical procedure.

Study and year	Coleman Score	Type of surgery
Anh <i>et al.</i> ²⁰	62	ACL reconstruction using quadrupled hamstring tendon autografts: remnant bundle preservation versus standard technique
Anh <i>et al.</i> ²¹	69	ACL reconstruction using remnant preservation and a femoral tensioning technique
Gao <i>et al.</i> ²⁴	66	ACL reconstruction with LARS artificial ligament
Gohil <i>et al.</i> ¹⁹	86	ACL reconstruction with autologous double hamstring: conventional clearance of inter-condylar notch or minimal debridement leaving the ACL remnant
Kim <i>et al.</i> ²⁵	80	ACL reconstruction remnant-preserving technique, using a quadrupled hamstring graft
Lee <i>et al.</i> ²³	56	Remnant-preserving technique in a modified arthroscopic ACL double-bundle reconstruction technique with an autogenous quadriceps tendon graft
Nakamae <i>et al.</i> ²²	56	ACL reconstruction with a remnant-preserving technique

Outcome measures

The scores used to collect the outcome measures, the assessment time and whether the assessors were blinded or not are reported in Table 4.

The most frequently used tests are the Lachman test, the pivot shift and the IKDC score. Five studies^{19,21,23–25} used the Lachman test; the pivot shift test was used in four studies;^{21,23–25} the IKDC score was administered in five studies.^{19,21,23–25} Two studies^{21–23} used KT-2000 and other two studies^{19,24} used KT-1000; two^{24,25} studies used the Lysholm score and one used the Tegner score;²⁴ the results of each study are collected in Table 5.

Outcome data

Three^{19,20,23} of the seven studies compared the remnant-preserving technique with a standard (non-preserving) technique, giving clinical and/or MRI data. Anh *et al.*²⁰ studied the following variables at MRI: the dimension of the ACL graft (significantly larger in the group in whom the stump had been preserved than in the control group); the signal/noise quotient (SNQ) values of the ACL graft (which showed as the remnant bundle preservation group got values not significantly lower than those of the standard reconstruction group); the MRI signal intensity and continuity of the preserved remnant bundle [which showed 14 knees with a Grade I signal (homogeneous low intensity) and a Grade II signal (a portion of the preserved bundle was oedematous) in 21 knees]; the orientation of the ACL (without significant differences between the two groups in the mean ACL angle, ACL-Blumensaat line angle and mean coronal ACL angle).

Lee *et al.*²³ compared objective, subjective and functional outcomes in two groups of patients, divided on the basis of the extent of ACL remnant, $\geq 20\%$. No significant differences were found in all objective tests (including Lachman test, pivot shift test and manual maximum displacement test by the use of KT-2000 arthrometer). The Hospital for Special Surgery (HSS) score improved from the pre- to the post-operative assessment, without significant differences between groups, as did the IKDC score. For the single-legged hop test, a significant post-operative improvement was obtained in the group with the preserved stump $>20\%$. The same group reached better and statistically significant results at 15 and 30° in the reproduction of passive positioning (RPP) test, compared with the other group which achieved lower but no statistically significantly different values at 45°. The threshold to detection of passive motion (TTDPM) test at 15, 30 and 45° showed statistically significant better result only at 30° for the group where the

Table 4 Outcome measurement.

Study	Assessment method	Assessment time	Assessors: blinded or not
Anh <i>et al.</i> ²⁰	MRI	5–7 months after surgery	Assessors were blinded to clinical and arthroscopic findings
Anh <i>et al.</i> ²¹	MRI, HSS, IKDC, Lysholm score	6.9 months after surgery for MRI; last follow-up for subjective assessments	Assessors were blinded to clinical and arthroscopic findings
Gao <i>et al.</i> ²⁴	MRI; Lachman, pivot shift, KT-1000, Lysholm, Tegner, IKDC	Last follow-up (50 ± 6 months)	
Gohil <i>et al.</i> ¹⁹	MRI; Lachman, KT-1000, IKDC, one-legged hop test	2, 6 and 12 months post-operatively for MRI; 2 weeks, 2, 6 and 12 months post-operatively for all the other tests	Blinded assessors
Kim <i>et al.</i> ²⁵	Lachman, pivot shift, Lysholm, IKDC		
Lee <i>et al.</i> ²³	Lachman, pivot shift, KT-2000, HSS, IKDC, one-legged hop test, reproduction passive positioning, threshold to detection of passive motion, single limb standing test	Last follow-up (35.1 months)	

Table 5 Study results.

Study	Static stability measures	Functional scores	MRI
Ahn et al. ²⁰			<p>ACL graft: remnant group: $293.4 \pm 73.6 \text{ mm}^2$; standard group: $219 \pm 51.7 \text{ mm}^2$</p> <p>MRI signals: remnant group: Grade I 14 patients, Grade II 21 patients, Grade III 6 patients; standard group: Grade I or II 35 patients (85%).</p> <p>MRI continuity: remnant group: complete 20 patients, partial 17 patients; standard group: partial or complete 37 patients (90%)</p> <p>Mean ACL angle: remnant group: $61.4 \pm 10.6^\circ$; standard group: $63.7 \pm 10.4^\circ$</p> <p>Mean ACL-Blumensaat: remnant group: $13.8 \pm 7.3^\circ$; standard group: $15.2 \pm 5.9^\circ$</p> <p>Coronal ACL angle: remnant group: $76.7 \pm 5.8^\circ$; standard group: $78.9 \pm 6.1^\circ$</p> <p>Mean centre of ACL graft in sagittal plane at tibial insertion: remnant group: $38.2 \pm 5.8\%$; standard group: $42.5 \pm 4.3\%$</p> <p>Mean centre of ACL graft in coronal plane at tibial insertion: remnant group: $46.7 \pm 2.1\%$; standard group: $47.3 \pm 2.4\%$</p>

Ahn *et al.*²¹

KT-2000: <3 mm: pre-operative 2, post-operative 33; 3–5 mm: pre-operative 3, post-operative 15; 5–10 mm: pre-operative 35, post-operative 2; >10 mm: pre-operative 13, post-operative 3

Lachman test: pre-operative negative: 0 patients; 1+, 2 patients; 2+, 38 patients; 3+, 13 patients; post-operative negative: 32 patients; 1+, 18 patients; 2+, 1 patient; 3+, 2 patients

Pivot shift: pre-operative negative, 0 patients; 1+, 31 patients; 2+/3+, 22 patients, negative post-operative, 47 patients; 1+, 4 patients; 2+/3+, 2 patients

IKDC A: pre-operative 0, post-operative 32, B: pre-operative 4, post-operative 15; C: pre-operative 31, post-operative 4; D: pre-operative 18, post-operative 2

Lysholm score: preoperative, 56.2 ± 18.6 ; postoperative, 92.8 ± 5.9

HSS score: preoperative, 79.5 ± 12.3 ; postoperative, 98.8 ± 2.0

Graft incorporation: fair in 27 cases and poor in 21

Tibial tunnel placement: the mean sagittal and coronal centers of the ACL graft were $38.8 \pm 5.9\%$ (range, 25.2–43.6%) and $45.1 \pm 2.3\%$ (range, 40.7–49.1%), respectively

Gao
K. *et al.*²⁴

KT-1000: <3 mm: pre-operative 0, post-operative 121; 3–5 mm: pre-operative 42, post-operative 31; >5 mm: pre-operative, 114 post-operative 4

Lachman test: pre-operative 0, 0 patients; 1+ 49 patients; 2+ 107 patients; 3+ 0 patients. Post-operative 0, 135 patients; 1+, 17 patients; 2+, 4 patients; 3+ 0 patients

Pivot shift: pre-operative: 0, 0 patients; 1+, 61 patients; 2+, 95 patients; 3+, 0 patients; post-operative: 0, 138 patients; 1+, 14 patients; 2+, 4 patients; 3+, 0 patients

Isokinetic strength quadriceps: 93.6 ± 10.7 and hamstring 95.8 ± 12

IKDC A: pre-operative 0, post-operative 81; B: pre-operative 0, post-operative 65; C: pre-operative 126, post-operative 9; D: pre-operative 30, post-operative 1

Lysholm score: pre-operative, 65.1 ± 12.3 ; post-operative, 94.5 ± 7.0

Tegner score: pre-operative, 3.1 ± 1.6 ; post-operative, 6.1 ± 1.6

Synovitis: one patient showed obvious synovitis of the knee

Tunnel positioning: tibial tunnel and femoral tunnel were found to be too anterior in two patients, and the tibial tunnel was too anterior in another patient

Continued

Table 5 *Continued*

Study	Static stability measures	Functional scores	MRI
Gohil et al. ¹⁹	<p><i>Results 2 month</i></p> <p>Extension (°): normal 1.4 (0–5), minimal debridement 0.8 (0–5); flexion (°): normal 113 (90–135), minimal debridement 120 (85–130), anterior translation (mm): normal 3.1 (2–7), minimal debridement 3.5 (2–6)</p> <p><i>Results 6 month</i></p> <p>Extension (°): normal 0.6 (0–5), minimal debridement 0.7 (0–5); flexion (°): normal 130.7 (120–145), minimal debridement 135.5 (120–140); anterior translation (mm): normal 2.8 (2–6), minimal debridement 3.2 (2–5)</p> <p><i>Results 12 month</i></p> <p>Extension (°): normal 0.3 (0–5), minimal debridement 0.5 (0–5); flexion (°): normal 138.5 (120–150), minimal debridement 137.6 (120–145); anterior translation (mm): normal 2.75 (2–5), minimal debridement 3.2 (2–5)</p>		<p>Mean signal/noise quotient readings at different time intervals for each region of interest:</p> <p><i>Results 2 month</i></p> <p>Near femoral insertion: normal, 2.71 (0.79–6.99); minimal debridement, 3.05 (0.58–4.65)</p> <p>Mid-substance ACL: normal, 3.07 (0.79–7.25); minimal debridement, 4.82 (1.55–11.2)</p> <p>Near tibial insertion: normal, 3.53 (0.96–7.33); minimal debridement, 4.76 (2.2–10.82)</p> <p>Within tibial tunnel: normal, 4.56 (0.96–7.46); minimal debridement, 7.12 (2.6–15.41)</p> <p>Mid-substance PCL: normal, 4.1 (0.42–9.39); minimal debridement, 6.13 (2.54–13.08)</p> <p><i>Results 6 month</i></p> <p>Near femoral insertion: normal, 3.75 (1.22–8.31); minimal debridement, 2.69 (1.32–6.21)</p> <p>Mid-substance ACL: normal, 4.72 (0.87–8.02), , 2.45 (1.06–4.22)</p> <p>Near tibial insertion: normal, 4.61 (0.86–8.55); minimal debridement, 3.63 (0.98–9.71)</p> <p>Within tibial tunnel: normal, 4.79 (0.8–12.02); minimal debridement, 4.66 (1.2–10.47)</p> <p>Mid-substance PCL: normal, 7 (1.1–10.37); minimal debridement, 3.3 (0.64–8.64)</p> <p><i>Results 12 month</i></p> <p>Near femoral insertion: normal, 2.45 (1.1–4.58); minimal debridement, 2.17 (1.01–4.34)</p> <p>Mid-substance ACL: normal, 3.49 (0.86–11.28); minimal debridement, 2.53 (0.97–4.03)</p> <p>Near tibial insertion: normal, 3.48 (1.0–7.37); minimal debridement, 3.09 (0.8–9.65)</p> <p>Within tibial tunnel normal, 3.64 (1.58–8.42); minimal debridement, 3.35 (1.6–8.23)</p> <p>Mid-substance PCL: normal, 3.47 (0.98–8.42); minimal debridement, 2.22 (0.63–5.23)</p>

Kim *et al.*²⁵

Lachman test: pre-operative: 2+ 15 patients; 3+ 6 patients.
 Post-operative: 1+, 3 patients; 2+, 0 patient; 3+ 0 patients
 pivot shift: pre-operative: 1+, 1 patient; 2+, 17 patients; 3+, 3 patients; post-operative: no abnormal test

IKDC: pre-operative: Grade A or B 4 patients; post-operative: Grade A or B 18 patients
 LYSHOLM score: pre-op: 74.6; post-op: 94.2

Lee *et al.*²³

Lachman test: 4 case +, 1 case ++ in Group 1 (remnant >20%), 3+ and 1++ in Group 2 (remnant <20%)
 pivot shift: 1+ Groups 1 and 2
 KT-2000: Group 1 2.33 ± 0.32 mm; Group 2 2.43 ± 0.36 mm

HSS score: improved from 62.7 to 95.4, Group 1; from 69.7 to 94.8, Group 2
 IKDCG: Group 1: normal 2, nearly normal 6, abnormal 1, severely abnormal 0, Tot 9; Group 2: normal 1, nearly normal 6, abnormal 0, severely abnormal 0, Tot 7
 RPP test angle: Group 1: 15°, $3.48 \pm 0.83^\circ$; 30°, $4.76 \pm 1.9^\circ$; 45°, $7.41 \pm 0.78^\circ$. Group 2: 15°, $7.38 \pm 1.53^\circ$; 30°, $9.09 \pm 1.32^\circ$; 45°, $6.43 \pm 1.33^\circ$. *P* value 0.032, 0.024, 0.739
 TTDPM test: 15° and 30° better results in Group 1, 45° no difference

Nakamae *et al.*²²

Group 1: no. patients 18; KT-2000 6.14 ± 1.76 mm; AP displacement of tibia (mm): 30° of knee flexion, 11.17 ± 3.63 60° of knee flexion, 6.94 ± 2.24 ; total range of tibial rotation (°): 30° of knee flexion, 13.94 ± 5.43 ; 60° of knee flexion, 15.28 ± 6.42

Continued

Table 5 *Continued*

Study	Static stability measures	Functional scores	MRI
	Group 2: no. patients 12; KT-2000 5.69 ± 2.48 mm; AP displacement of tibia (mm): 30° of knee flexion, 11.00 ± 4.11 ; 60° of knee flexion, 7.92 ± 3.99 ; total range of tibial rotation (°): 30° of knee flexion, 15.67 ± 7.87 60° of knee flexion, 17.08 ± 6.64		
	Group 3: no. patients 14; KT-2000 3.28 ± 1.77 mm; AP displacement of tibia (mm): 30° of knee flexion, 9.71 ± 3.00 ; 60° of knee flexion, 7.14 ± 2.51 ; total range of tibial rotation (°): 30° of knee flexion, 12.79 ± 5.59 ; 60° of knee flexion, 14.07 ± 5.50		
	Group 4: no. patients 6; KT-2000 2.97 ± 1.14 mm; AP displacement of tibia (mm): 30° of knee flexion, 8.67 ± 2.94 ; 60° of knee flexion, 7.67 ± 1.97 ; total range of tibial rotation (°): 30° of knee flexion, 14.00 ± 5.62 ; 60° of knee flexion, 13.33 ± 5.20		
	Group 5: no. patients 50; KT-2000 6.77 ± 1.90 mm; AP displacement of tibia (mm): 30° of knee flexion, 11.56 ± 2.88 ; 60° of knee flexion, 8.82 ± 2.57 ; total range of tibial rotation (°): 30° of knee flexion, 16.28 ± 5.54 ; 60° of knee flexion, 14.82 ± 4.66		
	Changes in AP knee laxity after resection of ACL remnant at 30° of knee flexion		
	ACL scar pattern (mm)		
	Group 1 chronicity: ≤ 1 year, 1.40 ± 1.58 ; > 1 year, 0.25 ± 0.46 ; total, 0.89 ± 1.32		
	Group 2 chronicity: ≤ 1 year, 3.25 ± 2.44 ; > 1 year, 0; total, 2.17 ± 2.52		
	Total chronicity: ≤ 1 year, 2.22 ± 2.16 ; > 1 year, 0.17 ± 0.39		

Changes in AP knee laxity after resection of ACL remnant at 60° of knee flexion

ACL scar pattern (mm)

Group 1 chronicity: ≤ 1 year, 0.70 ± 0.82 ; > 1 year, 0.38 ± 0.74 ;
total, 0.56 ± 0.78

Group 2 chronicity: ≤ 1 year, 0.63 ± 1.06 ; > 1 year, 0.5 ± 1.00 ;
total, 0.58 ± 1.00

Total chronicity: ≤ 1 year, 0.67 ± 0.91 ; > 1 year, 0.42 ± 0.79

Changes in rotational knee laxity after resection of ACL remnant at 30° of knee flexion

ACL scar pattern (°)

Group 1 chronicity: ≤ 1 year, -0.60 ± 2.22 ; > 1 year, -0.25 ± 1.04 ;
total, -0.44 ± 1.76

Group 2 chronicity: ≤ 1 year, 2.13 ± 5 ; > 1 year, -0.25 ± 1.71 ;
total, 1.33 ± 4.25

Total chronicity: ≤ 1 year, 0.61 ± 3.85 ; > 1 year, -0.25 ± 1.22

Changes in rotational knee laxity after resection of ACL remnant at 60° of knee flexion

ACL scar pattern (°)

Group 1 chronicity: ≤ 1 year, 1.10 ± 2.03 ; > 1 year, 0.13 ± 2.70 ;
total, 0.67 ± 2.33

Group 2 chronicity: ≤ 1 year, 0.00 ± 4.07 ; > 1 year, 0.25 ± 3.10 ;
total, 0.08 ± 3.63

Total chronicity: ≤ 1 year, 0.61 ± 3.05 ; > 1 year, 0.17 ± 2.69

remnant had been preserved. Gohil *et al.*¹⁹ compared standard versus minimal debridement techniques: at MRI, the SNQ values were significantly higher in the minimal debridement group at 6 months, while after 1 year significance was lost. On the contrary, no statistically significant differences were found in tunnel placement, blood loss, IKDC scores, range of movement or results of the Lachman test between the two groups.

Four^{21,22,24,25} of the seven studies evaluated the potential benefits that the preserved remnant could have on revascularization, on the ligamentization of the intra-articular graft and on improved knee stability. Gao *et al.*²⁴ reported on 159 patients in whom the ACL was reconstructed with a ligament advanced reinforced system (LARS) artificial ligament. The knee stability measured by the KT-1000 arthrometer, the Lachman test and the pivot shift test improved significantly after surgery. Similarly, knee function evaluated by Lysholm, Tegner and IKDC scores achieved significantly better values post-operatively compared with pre-operative ones. Of the patients, 81% (127/159) were highly satisfied, while eight required a second operation. Nakamae *et al.*²² evaluated the biomechanical properties of different patterns of ACL remnants. Comparing patients in whom the remnant bridges between the posterior cruciate ligament and the tibia (Group 1) or the intercondylar notch and the tibia (Group 2), the authors outlined how the remnant contributed to the antero-posterior knee stability at 30° for the first year after injury, while beyond that time this effect was lost. Kim *et al.*²⁵ reported on the outcomes of a new technique in which a double-bundle ACL is reconstructed using an autogenous quadriceps tendon graft and preserving the remnant. Both knee stability tests (Lachman test, pivot shift test and KT-2000 arthrometer) and knee function tests (IKDC and Lysholm) improved after surgery. The authors suggest that their remnant-preserving technique may be effective in promoting vascularization, stability and proprioception.

Ahn *et al.*²¹ evaluated a new ACL reconstruction technique with preservation and femoral tensioning of the ACL remnant. Statistically significant post-operative improvements in all the clinical scores (Lachman tests, pivot shift tests and KT-2000 arthrometer measurements) were achieved. Post-operative MRI assessment, available in 48 of 53 patients, showed an intact graft in 45 patients, 2 partial tears and 1 complete loss of graft.

Complications

Cyclops lesions and extension loss were the main complications. The rate per each study is reported in Table 6.

Table 6 Type and rate of complication.

Study	Complication: type and rate
Anh <i>et al.</i> ²⁰	Extension loss of 5° in two patients of the remnant-preserving group and in two of the standard technique group; cyclops lesion in two patients of the remnant group and in three of the standard technique group with extension loss in one patient per group
Anh <i>et al.</i> ²¹	Five cyclops-like lesions, without any clinical symptoms or extension limitation
Gao <i>et al.</i> ²⁴	Not reported
Gohil <i>et al.</i> ¹⁹	Cyclops lesion: in 9 patients treated with normal debridement and in 13 patients treated with minimal debridement
Kim <i>et al.</i> ²⁵	Extension deficit >5° in one patient
Lee <i>et al.</i> ²³	Not reported
Nakamae <i>et al.</i> ²²	Not reported

Discussion

An important role has been attributed to the preservation of the remnant in ACL reconstruction. However, its actual effectiveness is still controversial. For example, we do not know whether it really accelerates vascularization and ligamentization of the graft, or whether it improves proprioception compared with standard techniques. We wished to review in a systematic fashion the currently available literature on this issue, assessing the methodological quality and the clinical outcomes of the seven studies investigating the role of the ACL remnant in ACL reconstruction. The CMS was used. Although it was developed to assess the methodological quality for studies investigating surgical management of patellar tendinopathy, it has been largely used for Achilles tendinopathy,²⁶ patellar tendinopathy,²⁷ cartilage injuries,²⁸ posterior cruciate ligament treatment,²⁹ cervical spine fractures,³⁰ rotator cuff partial thickness management³¹ and knee arthroplasty.³² The average Coleman' score value was 67.8, showing overall a moderate methodological quality. All but one study¹⁹ are retrospective with a low level of evidence (Level IV), and the only prospective randomized controlled study¹⁹ has a short follow-up (1 year). Of the seven studies analysed, only three^{19,22,23} included a control group, while the others report on the clinical and the MRI post-operative results of a single technique. The size of the studies was generally small, with only one study reporting on >60 patients²⁴ and 3 of the studies^{19,20,25} did not specify the diagnostic process, introducing potential biases. Although the clinical and functional outcome assessments were methodologically satisfying (each study achieved the maximum score at the 'Outcome procedure' section of the Coleman), the heterogeneity of the scores used does not allow to statistically analyse and compare the relevant outcomes.

Preserving the remnant in ACL reconstruction surgery may have potential benefits. The remnant tissue might accelerate the vascularization and the ligamentization process of the graft, improving its incorporation.^{33,34–36} Moreover, the proprioceptive structures of the distal tibial remnant fibres may contribute to faster graft innervation leading to a better proprioception.^{23,37–39} Ligamentous branches originate from the middle genicular artery, forming a synovial network from which a periligamentous net of vessels that transversely cross the ACL and anastomose with longitudinally oriented intraligamentous vessels provide most of the vascular supply to the ACL fibres.⁴⁰ Preserving the remnant and its synovial sheet may accelerate the process of vascularization. Gohil *et al.*¹⁹ showed that the signal intensity at MRI was higher in the minimal debridement group compared with the standard group up to the first 6 months. After 1 year, no differences were found, supporting the idea that the revascularization process occurred earlier in the debridement group. Ahn *et al.*²⁰ found larger ACL graft in the remnant-preserving group at MRI assessment, but the clinical significance of these data is not clear. At immunohistology, the presence of proprioceptive structures such as Golgi tendon organs, Pacinian corpuscles and Ruffini endings within the ACL fibre structures within the remnant has been demonstrated. The shorter the time between the injury and the surgery, the greater the presence of proprioceptive structure and the longer the remnant adherent to the posterior cruciate ligament.⁴¹ These findings support the idea that preserving the remnant may allow the retention of proprioceptive function, and that the stump may be a source for graft innervations, contributing to better clinical and functional outcomes. However, we lack studies comparing the number and the quality of mechanoreceptors in reconstructed ACL with and without preservation of the remnant. Lee *et al.*²³ found that the remnant-preserving technique obtained statistically better proprioceptive and functional outcomes compared with the standard technique. The authors used the single-legged hop test, the RPP, the TTDPM and the single-limb standing test for the functional assessments, but these tests are not specific and validated for a proprioceptive assessment. The same authors proposed that appropriate proprioception testing should include pre-operative proprioception assessment and comparison with uninjured subjects to reach a more accurate cause–effect analysis.

Although there are no studies investigating the role of remnant in preventing tibial tunnel widening, preservation of the ACL remnant may result in decreased post-operative arthroscopic and synovial fluid leakage into the tibial tunnel. Given the close adhesion between graft and remnant, cytokines scattering may be reduced and their osteolytic effects could be avoided.⁴² On the other hand, the advantages of a

traditional ACL reconstruction technique with complete debridement of the remnant fibres are a clearer vision and a more evident landmark and a decreased risk of cyclops formation or impingement,⁴³ even though the latter point is controversial.⁴⁴ However, the studies analysed reported no tunnel misplacements, and the rates of cyclop lesions and loss of extension in the remnant-preserving technique are comparable with those observed in the remnant excision technique.^{19,21}

Establishing the real advantages of preserving the remnant is necessary to support its use despite the disadvantages and its technical difficulties. Comparing the outcomes of the standard and the remnant-preserving techniques is the only way to prove its potential effectiveness. However, it is difficult to report on the benefits of leaving the ACL remnant using only clinical scores. Experimental studies demonstrated a role for the ACL remnant in improving revascularization, ligamentization and reinnervation of the graft, but these findings are still not supported by clinical findings. A more direct way to assess proprioceptive function after ACL reconstruction and appropriately conducted powered and rigorously prospective randomized double-blind studies comparing the clinical outcomes of excising the remnant to leaving it *in situ* are necessary. The present published evidence does not support, or refute, the benefits of ACL remnant sparing.

Funding

None.

References

- 1 Beynnon BD, Johnson RJ, Abate JA *et al*. Treatment of anterior cruciate ligament injuries, part 2. *Am J Sports Med* 2005;**33**:1751–67.
- 2 Kumar K, Maffulli N. The ligament augmentation device: an historical perspective. *Arthroscopy* 1999;**15**:422–32.
- 3 Sommerlath K, Lysholm J, Gillquist J. The long-term course after treatment of acute anterior cruciate ligament ruptures. A 9 to 16 year followup. *Am J Sports Med* 1991;**19**:156–62.
- 4 Griffin LY, Agel J, Albohm MJ *et al*. Noncontact anterior cruciate ligament injuries: risk factors and prevention strategies. *J Am Acad Orthop Surg* 2000;**8**:141–50.
- 5 Beynnon BD, Johnson RJ, Fleming BC *et al*. Anterior cruciate ligament replacement: comparison of bone-patellar tendon-bone grafts with two-strand hamstring grafts. A prospective, randomized study. *J Bone Joint Surg Am* 2002;**84-A**:1503–13.
- 6 Ramjug S, Ghosh S, Walley G *et al*. Isolated anterior cruciate ligament deficiency, knee scores and function. *Acta Orthop Belg* 2008;**74**:643–51.
- 7 Dienst M, Burks RT, Greis PE. Anatomy and biomechanics of the anterior cruciate ligament. *Orthop Clin North Am* 2002;**33**:605–20.
- 8 Zelle BA, Brucker PU, Feng MT *et al*. Anatomical double-bundle anterior cruciate ligament reconstruction. *Sports Med* 2006;**36**:99–108.

- 9 Morimoto Y, Ferretti M, Ekdahl M *et al.* Tibiofemoral joint contact area and pressure after single- and double-bundle anterior cruciate ligament reconstruction. *Arthroscopy* 2009;**25**:62–9.
- 10 Yasuda K, Ichiyama H, Kondo E *et al.* An in vivo biomechanical study on the tension-versus-knee flexion angle curves of 2 grafts in anatomic double-bundle anterior cruciate ligament reconstruction: effects of initial tension and internal tibial rotation. *Arthroscopy* 2008;**24**:276–84.
- 11 Zaffagnini S, Bruni D, Martelli S *et al.* Double-bundle ACL reconstruction: influence of femoral tunnel orientation in knee laxity analysed with a navigation system—an in-vitro biomechanical study. *BMC Musculoskelet Disord* 2008;**9**:25.
- 12 Irrgang JJ, Bost JE, Fu FH. Re: outcome of single-bundle versus double-bundle reconstruction of the anterior cruciate ligament: a meta-analysis. *Am J Sports Med* 2009;**37**:421–2; author reply 422.
- 13 Markolf KL, Wascher DC, Finerman GA. Direct in vitro measurement of forces in the cruciate ligaments. Part II: the effect of section of the posterolateral structures. *J Bone Joint Surg Am* 1993;**75**:387–94.
- 14 Longo UG, King JB, Denaro V *et al.* Double-bundle arthroscopic reconstruction of the anterior cruciate ligament: does the evidence add up? *J Bone Joint Surg Br* 2008;**90**:995–9.
- 15 Andriacchi TP, Birac D. Functional testing in the anterior cruciate ligament-deficient knee. *Clin Orthop Relat Res* 1993;**288**:40–7.
- 16 McMahan PJ, Dettling JR, Yocum LA *et al.* The cyclops lesion: a cause of diminished knee extension after rupture of the anterior cruciate ligament. *Arthroscopy* 1999;**15**:757–61.
- 17 Tonin M, Saciri V, Veselko M *et al.* Progressive loss of knee extension after injury. Cyclops syndrome due to a lesion of the anterior cruciate ligament. *Am J Sports Med* 2001;**29**:545–9.
- 18 Crawford R, Walley G, Bridgman S *et al.* Magnetic resonance imaging versus arthroscopy in the diagnosis of knee pathology, concentrating on meniscal lesions and ACL tears: a systematic review. *Br Med Bull* 2007;**84**:5–23.
- 19 Gohil S, Annear PO, Breidahl W. Anterior cruciate ligament reconstruction using autologous double hamstrings: a comparison of standard versus minimal debridement techniques using MRI to assess revascularisation. A randomised prospective study with a one-year follow-up. *J Bone Joint Surg Br* 2007;**89**:1165–71.
- 20 Ahn JH, Lee SH, Choi SH *et al.* Magnetic resonance imaging evaluation of anterior cruciate ligament reconstruction using quadrupled hamstring tendon autografts: comparison of remnant bundle preservation and standard technique. *Am J Sports Med* 2010;**38**:1768–77.
- 21 Ahn JH, Wang JH, Lee YS *et al.* Anterior cruciate ligament reconstruction using remnant preservation and a femoral tensioning technique: clinical and magnetic resonance imaging results. *Arthroscopy* 2011;**27**:1079–1089.
- 22 Nakamae A, Ochi M, Deie M *et al.* Biomechanical function of anterior cruciate ligament remnants: how long do they contribute to knee stability after injury in patients with complete tears? *Arthroscopy* 2010;**26**:1577–85.
- 23 Lee BI, Kwon SW, Kim JB *et al.* Comparison of clinical results according to amount of preserved remnant in arthroscopic anterior cruciate ligament reconstruction using quadrupled hamstring graft. *Arthroscopy* 2008;**24**:560–8.
- 24 Gao K, Chen S, Wang L *et al.* Anterior cruciate ligament reconstruction with LARS artificial ligament: a multicenter study with 3- to 5-year follow-up. *Arthroscopy* 2010;**26**:515–23.
- 25 Kim SJ, Jo SB, Kim TW *et al.* A modified arthroscopic anterior cruciate ligament double-bundle reconstruction technique with autogenous quadriceps tendon graft: remnant-preserving technique. *Arch Orthop Trauma Surg* 2009;**129**:403–7.
- 26 Tallon C, Coleman BD, Khan KM *et al.* Outcome of surgery for chronic Achilles tendinopathy. A critical review. *Am J Sports Med* 2001;**29**:315–20.
- 27 Coleman BD, Khan KM, Maffulli N *et al.* Studies of surgical outcome after patellar tendinopathy: clinical significance of methodological deficiencies and guidelines for future studies. Victorian Institute of Sport Tendon Study Group. *Scand J Med Sci Sports* 2000;**10**:2–11.
- 28 Jakobsen RB, Engebretsen L, Slauterbeck JR. An analysis of the quality of cartilage repair studies. *J Bone Joint Surg Am* 2005;**87**:2232–9.
- 29 Watsend AM, Osestad TM, Jakobsen RB *et al.* Clinical studies on posterior cruciate ligament tears have weak design. *Knee Surg Sports Traumatol Arthrosc* 2009;**17**:140–9.

- 30 Denaro V, Papalia R, Di Martino A *et al.* The best surgical treatment for type II fractures of the dens is still controversial. *Clin Orthop Relat Res* 2011;**469**:742–50.
- 31 Papalia R, Franceschi F, Del Buono A *et al.* Results of surgical management of symptomatic shoulders with partial thickness tears of the rotator cuff. *Br Med Bull* 2011;**99**:141–54.
- 32 Papalia R, Del Buono A, Zampogna B *et al.* Sport activity following joint arthroplasty: a systematic review. *Br Med Bull* 2011 May 12. [Epub ahead of print].
- 33 Amiel D, Kleiner JB, Roux RD *et al.* The phenomenon of ‘ligamentization’: anterior cruciate ligament reconstruction with autogenous patellar tendon. *J Orthop Res* 1986;**4**:162–72.
- 34 Arnoczky SP, Tarvin GB, Marshall JL. Anterior cruciate ligament replacement using patellar tendon. An evaluation of graft revascularization in the dog. *J Bone Joint Surg Am* 1982;**64**:217–24.
- 35 Marumo K, Saito M, Yamagishi T *et al.* The ‘ligamentization’ process in human anterior cruciate ligament reconstruction with autogenous patellar and hamstring tendons: a biochemical study. *Am J Sports Med* 2005;**33**:1166–73.
- 36 Tohyama H, Yoshikawa T, Ju YJ *et al.* Revascularization in the tendon graft following anterior cruciate ligament reconstruction of the knee: its mechanisms and regulation. *Chang Gung Med J* 2009;**32**:133–9.
- 37 Adachi N, Ochi M, Uchio Y *et al.* Anterior cruciate ligament augmentation under arthroscopy. A minimum 2-year follow-up in 40 patients. *Arch Orthop Trauma Surg* 2000;**120**:128–33.
- 38 Adachi N, Ochi M, Uchio Y *et al.* Mechanoreceptors in the anterior cruciate ligament contribute to the joint position sense. *Acta Orthop Scand* 2002;**73**:330–4.
- 39 Reider B, Arcand MA, Diehl LH *et al.* Proprioception of the knee before and after anterior cruciate ligament reconstruction. *Arthroscopy* 2003;**19**:2–12.
- 40 Toy BJ, Yeasting RA, Morse DE *et al.* Arterial supply to the human anterior cruciate ligament. *J Athl Train* 1995;**30**:149–52.
- 41 Dhillon MS, Bali K, Vasistha RK. Immunohistological evaluation of proprioceptive potential of the residual stump of injured anterior cruciate ligaments (ACL). *Int Orthop* 2010;**34**:737–41.
- 42 Junkin DM Jr, Johnson DL. ACL tibial remnant, to save or not. *Orthopedics* 2008;**31**:154–9.
- 43 Delince P, Krallis P, Descamps PY *et al.* Different aspects of the cyclops lesion following anterior cruciate ligament reconstruction: a multifactorial etiopathogenesis. *Arthroscopy* 1998;**14**:869–76.
- 44 Lee BI, Min KD, Choi HS *et al.* Arthroscopic anterior cruciate ligament reconstruction with the tibial-remnant preserving technique using a hamstring graft. *Arthroscopy* 2006;**22**:340 e1–7.