

Spatial frames of reference and somatosensory processing: a neuropsychological perspective

GIUSEPPE VALLAR^{1*,2}

¹*Dipartimento di Psicologia, Università di Roma 'La Sapienza', Via dei Marsi 78, 00185 Rome, Italy
(givallar@imiucca.csi.unimi.it)*

²*IRCCS Clinica S. Lucia, Rome, Italy*

SUMMARY

In patients with lesions in the right hemisphere, frequently involving the posterior parietal regions, left-sided somatosensory (and visual and motor) deficits not only reflect a disorder of primary sensory processes, but also have a higher-order component related to a defective spatial representation of the body. This additional factor, related to right brain damage, is clinically relevant: contralesional hemianaesthesia (and hemianopia and hemiplegia) is more frequent in right brain-damaged patients than in patients with damage to the left side of the brain. Three main lines of investigation suggest the existence of this higher-order pathological factor. (i) Right brain-damaged patients with left hemineglect may show physiological evidence of preserved processing of somatosensory stimuli, of which they are not aware. Similar results have been obtained in the visual domain. (ii) Direction-specific vestibular, visual optokinetic and somatosensory or proprioceptive stimulations may displace spatial frames of reference in right brain-damaged patients with left hemineglect, reducing or increasing the extent of the patients' ipsilesional rightward directional error, and bring about similar directional effects in normal subjects. These stimulations, which may improve or worsen a number of manifestations of the neglect syndrome (such as extrapersonal and personal hemineglect), have similar effects on the severity of left somatosensory deficits (defective detection of tactile stimuli, position sense disorders). However, visuospatial hemineglect and the somatosensory deficits improved by these stimulations are independent, albeit related, disorders. (iii) The severity of left somatosensory deficits is affected by the spatial position of body segments, with reference to the midsagittal plane of the trunk. A general implication of these observations is that spatial (non-somatotopic) levels of representation contribute to corporeal awareness. The neural basis of these spatial frames includes the posterior parietal and the premotor frontal regions. These spatial representations could provide perceptual–premotor interfaces for the organization of movements (e.g. pointing, locomotion) directed towards targets in personal and extrapersonal space. In line with this view, there is evidence that the sensory stimulations that modulate left somatosensory deficits affect left motor disorders in a similar, direction-specific, fashion.

1. A HEMISPHERIC DIFFERENCE

One basic difference between elementary sensory and motor processes and higher-order mental functions concerns the hemispheric lateralization of their neural basis. The cerebral correlates of language and visuo-spatial processing are largely asymmetric, with the well-known specialization of the left hemisphere for many linguistic processes, and of the right hemisphere for a variety of spatial processes. By contrast, the neurological organization of sensory–motor systems has a 'contralateral' architecture, so that each hemisphere is primarily concerned with the opposite side of personal (i.e. the body) and extrapersonal space (for example, visual or auditory objects). This state of affairs has implications in the domain of clinical

neurology. It is a current view that damage to the specifically committed regions of each cerebral hemisphere brings about somatosensory (hemianaesthesia), visual (hemianopia), and motor (hemiplegia) deficits, contralateral to the side of the lesion (contralesional) with no relevant left–right asymmetries (Rowland 1995; Adams *et al.* 1997).

There is also, however, some evidence of such asymmetries for sensory and motor deficits associated with unilateral lesions. A community-based epidemiological survey has shown that somatosensory, visual half-field, and motor deficits are more frequent after lesions in the right hemisphere, compared with left brain damage (Sterzi *et al.* 1993). In a continuous series of 154 left and 144 right brain-damaged stroke patients the incidence of contralateral somatosensory deficits (position sense) was 37% after damage to the right hemisphere, and 25% after damage to the left hemisphere. The incidence of

*Address for correspondence.

deficits of sense of pain was 57% in right and 45% in left brain-damaged patients. Similarly, the incidence of contralesional visual half-field deficits was 18% in right brain-damaged patients and 7% in left brain-damaged patients. Finally, 95% of right brain-damaged patients exhibited motor deficits, which were found in only 85% of left brain-damaged patients.

If an analogy is drawn with disorders of linguistic and spatial cognition, this asymmetry may be explained by the existence of a higher-order pathological factor, related to right brain damage, which increases the incidence, and possibly the severity, of left-sided sensory and motor deficits. A plausible candidate is the syndrome of *spatial hemineglect*, which refers to the defective ability of patients with unilateral cerebral lesions to explore the contralesional side and to report stimuli presented in that side. The common trait of the different manifestations of hemineglect is *spatial*: in any given domain (extrapersonal and personal space, internally generated images, etc.) the deficit concerns the contralesional part, with reference to a given coordinate system (Vallar 1994). Hemineglect, being more frequent and more severe after lesions in the right hemisphere (reviews in Bisiach & Vallar 1988; Vallar 1993), shows a hemispheric asymmetry in the same direction as that found in sensory and motor disorders. Furthermore, clinical descriptions of the syndrome include component deficits such as *négligence motrice* or *motor neglect* (the patients' inability to move spontaneously the contralesional arm in the absence of major primary motor deficits: see Garcin *et al.* (1938), Critchley (1953), Castaigne *et al.* (1970) and Mark *et al.* (1996) for a discussion of the terminology), and *sensory inattention* (a deficit in awareness of contralesional stimuli: see Heilman *et al.* (1993)), which may mimic primary motor, somatosensory and visual half-field deficits.

2. PRESERVED SENSORY PROCESSES IN NEGLECT-RELATED SENSORY HEMI-SYNDROMES

These hemispheric asymmetries imply that left-sided sensory disorders may be produced by two, possibly additive, pathological factors: (i) a primary sensory component, as maintained by classic neurological views; and (ii) a higher-order deficit, such as spatial hemineglect. Their relative contribution may vary across patients but in at least some cases the latter may be the main, if not the only, factor underlying the patients' sensory disorder.

In line with this two-component view, there is evidence that in right brain-damaged patients with visuospatial hemineglect primary sensory processes may be largely preserved, even though awareness of contralesional stimuli is defective. One brain-damaged patient with left hemianaesthesia showed skin conductance responses to stimuli, delivered to the left hand, that he was unable to perceive, as witnessed by a defective verbal report (Vallar *et al.* 1991a). Three right brain-damaged patients showed preserved early somatosensory evoked potentials to undetected stimuli (Vallar *et al.* 1991b). A similar dissociation between

defective phenomenal experience and physiological evidence of preserved perceptual processing has been found in the visual domain. Two right brain-damaged patients with left homonymous hemianopia (Vallar *et al.* 1991b) showed largely preserved early visual evoked potentials, in terms of both latency and amplitude, to stimulation of the left visual half-field, that they failed to report and denied perceiving (see also Angelelli *et al.* (1996) for related evidence). These observations suggest that, in at least some patients, the higher-order pathological factor accounts entirely for the somatosensory or visual impairment. These findings also provide a neurophysiological basis to the behavioural evidence, now confirmed many times, of *processing without awareness* in patients with left hemineglect, who have proved to be able to analyse material presented in the left side of space, up to the semantic level (see, for example, Marshall & Halligan 1988; Berti & Rizzolatti 1992; Ládavas *et al.* 1993; McGlinchey-Berroth *et al.* 1993; Vallar *et al.* 1994, 1996a). The core finding of these studies is that patients with hemineglect may show relatively preserved *perception* of sensory inputs, but *sensation* (i.e. the phenomenal, conscious, experience of what is perceived) is defective (see the philosophical discussion of the distinction between perception and sensation in Chalmers (1996), p. 18).

The localization of lesions in patients with left visuospatial hemineglect provides a neural substrate to these preserved levels of analysis. Figure 1 shows the more frequent anatomical correlate of visuospatial hemineglect in humans: damage to the supramarginal gyrus (Brodmann's area 40) of the inferior parietal lobule, at the temporoparietal junction (Vallar & Perani 1986). Neglect is much less frequent after frontal damage, but a number of reports suggest that damage to both the dorsolateral premotor and the medial (anterior cingulate region, supplementary motor area) frontal regions may be associated with hemineglect (Heilman & Valenstein 1972; Damasio *et al.* 1980). Recently, the suggestion has been made that damage to the dorsal aspect of the right inferior frontal gyrus (Brodmann's area 44, premotor cortex) may be specifically associated with hemineglect (Husain & Kennard 1996). The lesions may also be confined to subcortical structures such as the basal ganglia, the thalamus and (but much less frequently) the white matter. By contrast, the primary motor, somatosensory and visual cortices are usually spared. In addition, patients with lesions confined to the latter regions usually do not show evidence of spatial hemineglect (see Vallar (1993) and Heilman *et al.* (1994) for reviews of the anatomical correlates of the neglect syndrome).

The lesions of individual patients with left visuospatial hemineglect, as assessed by visuomotor exploratory tasks, and left visual half-field deficits associated with neurophysiological evidence of relatively preserved basic sensory processing largely spare the primary visual cortex (Vallar *et al.* (1991b), two patients). By contrast, in patients with contralesional hemianopia not associated with hemineglect the lesions, as expected on the basis of classic neurological notions (Rowland 1995; Adams *et al.* 1997),

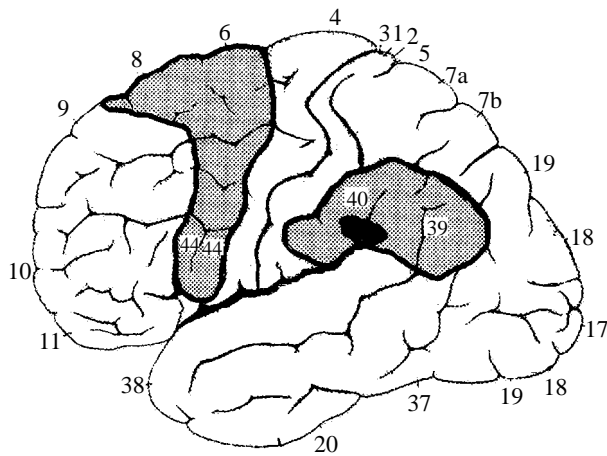


Figure 1. The syndrome of spatial hemineglect: anatomical correlates (grey areas). In the majority of patients the lesion involves the supramarginal gyrus in the inferior parietal lobule, at the temporoparietal junction (black area) (Vallar & Perani 1986). Neglect after frontal damage is much less frequent and is usually associated with dorsolateral lesions of the premotor cortex.

involved the primary visual cortex and early visual evoked potentials were grossly abnormal or absent (Vallar *et al.* 1991b; Angelelli *et al.* 1996). In the somatosensory domain, the empirical evidence is less clear-cut. The patient of Vallar *et al.* (1991a) who showed skin conductance responses to unreported tactile stimuli had extensive damage to the right frontotemporoparietal-occipital regions, including the primary somatosensory cortex. In two out of the three patients of Vallar *et al.* (1991b) the right primary somatosensory cortex was unaffected, wholly or in part. The neurophysiological evidence of processing without awareness in patients with lesions involving the primary somatosensory cortex is consistent, however, with a positron emission tomography (PET) activation study in one patient with left somatosensory deficits produced by a lesion involving a large portion of the right primary somatosensory and motor areas, the supramarginal gyrus, and, possibly, somatosensory area II (Bottini *et al.* 1995). This patient, during the temporary recovery of left hemianaesthesia after vestibular caloric stimulation (irrigation of the left external ear canal with iced water), showed the activation of the right inferior frontal gyrus, the insula and the putamen. In normal subjects, the two latter areas were activated by both tactile stimulation of the left hand, and by vestibular stimulation. These findings suggest that other brain areas in addition to the primary somatosensory cortex may contribute, in relation to their capacities, to the processing of somatosensory stimuli and to perceptual awareness.

3. DEFECTIVE SENSATION AND SPATIAL HEMINEGLECT: MODULATION BY PERIPHERAL SENSORY STIMULATION

The observations discussed above do not provide any *direct* indication as to the mechanisms whereby patients with hemineglect fail to be phenomenally aware of

stimuli they are able to process. The preservation of primary sensory processes suggests that the retinotopic (in the visual domain) and the somatotopic (in the tactile domain) levels of representation may be unaffected, and that the patients' defective awareness of contralesional stimuli may be produced by a disorder of higher-order spatial representations. In line with this view, the main anatomical correlates of hemineglect in humans are lesions of the posterior parietal (inferior parietal lobule) and, although much less frequently, of the premotor regions (Vallar 1993). In the monkey, cells that encode visual stimuli in spatial, body part (head-, arm-centred) coordinates have been described in the posterior parietal and in the premotor cortex (Fogassi *et al.* 1992; Galletti *et al.* 1993; Graziano *et al.* 1994; Battaglini *et al.* 1996).

A major source of evidence for the view that the defective perceptual awareness of contralesional stimuli of patients with hemineglect reflects the disorder of higher-order spatial (e.g. egocentric, with reference to the midsagittal plane of the trunk) representations has been the investigation of the effects of direction-specific sensory stimulations. In recent years, many studies from different laboratories have shown that many manifestations of the neglect syndrome are modulated by vestibular (see, for example, Rubens 1985; Cappa *et al.* 1987), visual (optokinetic) (Pizzamiglio *et al.* 1990), and proprioceptive or somatosensory stimulations (Karnath *et al.* 1993; Vallar *et al.* 1995d). Vestibular stimulation has been extensively used, but the results obtained by using other stimulations are similar. In right brain-damaged patients, the modulatory effects concern neglect for objects in extrapersonal space (Rubens 1985; Pizzamiglio *et al.* 1990; Karnath *et al.* 1993), neglect for personal space (the left side of the body: Cappa *et al.* 1987), disorders of monitoring processes, such as anosognosia for hemiplegia (Cappa *et al.* 1987; Vallar *et al.* 1990; Rode *et al.* 1992), and delusional beliefs concerning the left side of the body (somatoparaphrenia (Bisiach *et al.* 1991; Rode *et al.* 1992)). Vestibular and optokinetic stimulations producing a nystagmus with a slow phase towards the left, contralesional side, and left-sided transcutaneous mechanical vibration and electrical nervous stimulations temporarily improve these disorders. By contrast, vestibular and optokinetic stimulations producing a nystagmus with a slow phase towards the right, ipsilesional side, and right-sided transcutaneous vibration and electrical stimulations worsen the deficits, or are ineffective (see review in Vallar *et al.* (1997b)).

Within the somatosensory system, similar results have been obtained by using three types of stimulation: vestibular, electrical transcutaneous and optokinetic. The effects of vestibular stimulation on the deficit of tactile perception of patients with unilateral lesions of the left and of the right hemisphere are shown in figure 2 (Vallar *et al.* 1993b). The irrigation of the left external ear canal with iced water, which produces a nystagmus with a slow phase towards the left side, temporarily improved detection of tactile stimuli, delivered to the left contralesional hand by a von Frey's hair, in 15 out of 17 right brain-damaged

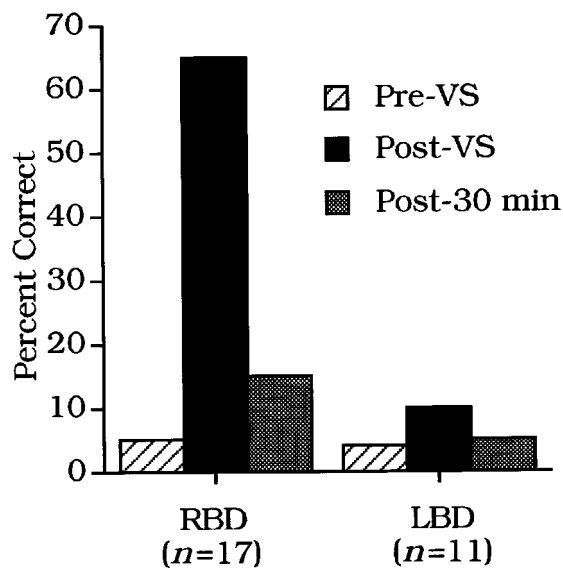


Figure 2. Contralesional somatosensory deficits and vestibular stimulation. Percentage of single tactile stimuli, delivered to the hand contralateral to the hemispheric lesion, detected by right (RBD) and left (LBD) brain-damaged patients, before (Pre) and after (Post) vestibular stimulation (VS), and at a 30 min delay assessment (redrawn from Vallar *et al.* (1993b), figure 1, by permission of Oxford University Press).

patients. Fourteen such patients showed also evidence of left visuospatial hemineglect, which was absent in three cases. Similarly, in three right brain-damaged patients this vestibular stimulation (douching of the left canal with iced water) temporarily improved left tactile extinction to double symmetrical (left and right-sided) touches (figure 3). In nine out of eleven left brain-damaged patients, by contrast, vestibular stimulation (irrigation of the right external ear canal with iced water, which produces a nystagmus with a slow phase towards the right side) was ineffective. This vestibular stimulation, however, produced a substantial temporary improvement of the tactile deficit in the right hand in the two left brain-damaged patients, who also showed right visuospatial hemineglect: the patients' performance improved from 2.5% correct responses before stimulation to 37.5% after treatment, with 5% correct responses at the 30 min delay assessment. The effects of vestibular stimulation are related to the direction of the slow phase of the nystagmus and not to the stimulated side (ear). Both irrigation of the left external ear canal with cold water, and of the right canal with warm water, which produce a nystagmus with a slow phase towards the left side, temporarily improve visuospatial hemineglect (Rubens (1985), 17 patients) and left hemianaesthesia (Vallar *et al.* 1990, patient no. 2). By contrast irrigation of the left external ear canal with warm water, and of the right canal with iced water, which produce a nystagmus with a slow phase towards the right side, temporarily worsened left visuospatial hemineglect in all 17 patients of Rubens' (1985) series.

Transcutaneous electrical nervous stimulation of the left neck improved contralesional left hemianaesthesia

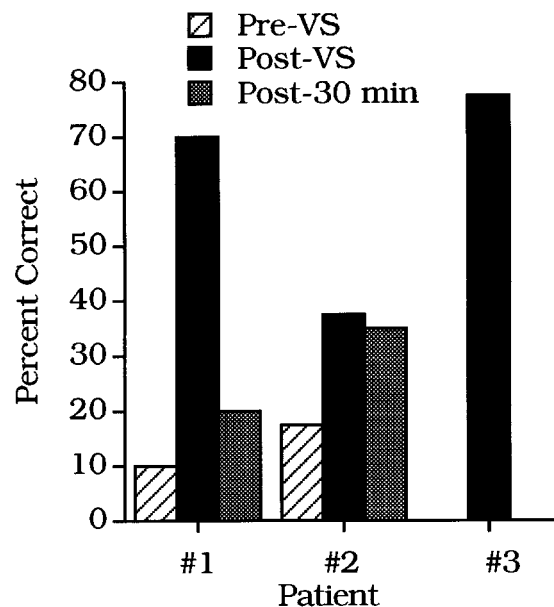


Figure 3. Contralesional tactile extinction to double simultaneous stimulation of the left and of the right hand and vestibular stimulation. Percentage of tactile stimuli delivered to the left hand, detected by three right brain-damaged patients before (Pre) and after (Post) vestibular stimulation (VS) and at a 30 min delay assessment (data from Vallar *et al.* (1993b), table 3).

in ten right brain-damaged patients, both with and without visuospatial hemineglect (figure 4) (Vallar *et al.* 1996b). In one right brain-damaged patient with a moderate left somatosensory deficit, the effects of both left- and right-sided transcutaneous electrical stimulation were assessed. Figure 5 shows that left-sided stimulation temporarily decreased the somatosensory threshold in the left hand, improving the disorder, whereas right-sided stimulation had negative effects, increasing the threshold. This directional pattern of results is similar to the effects of transcutaneous electrical stimulation on left visuospatial hemineglect (Vallar *et al.* 1995d). Finally, out of the four patients with left hemisphere damage and right-sided somatosensory deficits, stimulation of the right side of the neck reduced the threshold only in the one patient who exhibited also right visuospatial hemineglect.

Finally, two studies investigated the effects of optokinetic stimulation with horizontally moving luminous dots on deficits of position sense in right and left brain-damaged patients in the horizontal (Vallar *et al.* 1993a) and the vertical (Vallar *et al.* 1995a) plane. A baseline assessment, without optokinetic stimulation, showed, in right and left brain-damaged patients without visuospatial hemineglect, a position sense disorder confined to the contralesional forearm, in line with the traditional neurological views (Rowland 1995; Adams *et al.* 1997). Right brain-damaged patients with visuospatial hemineglect, by contrast, had a much more severe deficit of position sense, which involved not only the contralesional left, but also the ipsilesional right forearm, even though in the latter the disorder was milder. Optokinetic stimulation modulated the severity of the deficit only in right brain-damaged patients with

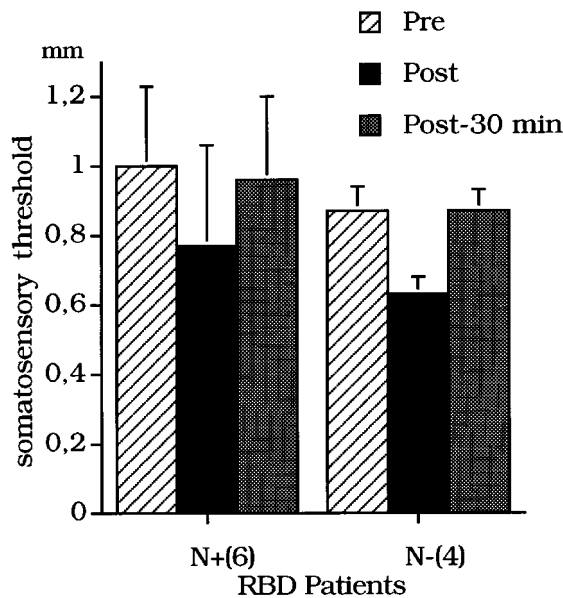


Figure 4. Contralesional somatosensory deficits and transcutaneous electrical nervous stimulation. Average somatosensory thresholds (diameter in millimetres of von Frey's hair) in the contralesional left hand of ten right brain-damaged (RBD) patients (N+ or N-: with or without visuospatial hemineglect) on three successive assessments: before transcutaneous electrical nervous stimulation (Pre); immediately after stimulation of the contralesional left side of the neck (Post); or 30 min after stimulation (Post-30 min) (redrawn from Vallar *et al.* (1996b), figure 1, by permission of Cambridge University Press).

visuospatial hemineglect. Stimulation with a leftward direction of the movement of the luminous dots (contralateral to the side of the lesion) temporarily improved the disorder, in both the left and the right forearms, in both the vertical and the horizontal planes (figure 6). Stimulation with a rightward direction of the movement (ipsilateral to the side of the lesion) worsened the deficit. No effects of optokinetic stimulation were found, in both right and left brain-damaged patients without visuospatial hemineglect.

These studies provide a convergent pattern of results, which may be summarized as two main points. (i) There is a hemispheric asymmetry in the effects of sensory stimulations on the contralesional somatosensory deficits of patients with unilateral lesions. In most patients with right brain damage, the severity of the left-sided impairment was modulated by sensory stimulations in a direction-specific fashion; by contrast, the right-sided deficits of left brain-damaged patients were largely unaffected. (ii) There is an association between visuospatial hemineglect and the somatosensory deficits modulated by these stimulations. Most right brain-damaged patients and all of the few left brain-damaged patients who showed temporary recovery of contralesional somatosensory disorders also exhibited visuospatial hemineglect. However, the sensory stimulations also improved detection of left-sided tactile stimuli in a number of right brain-damaged patients without evidence of left visuospatial hemineglect. This finding, together with the long-known observation that visuospatial hemineglect may

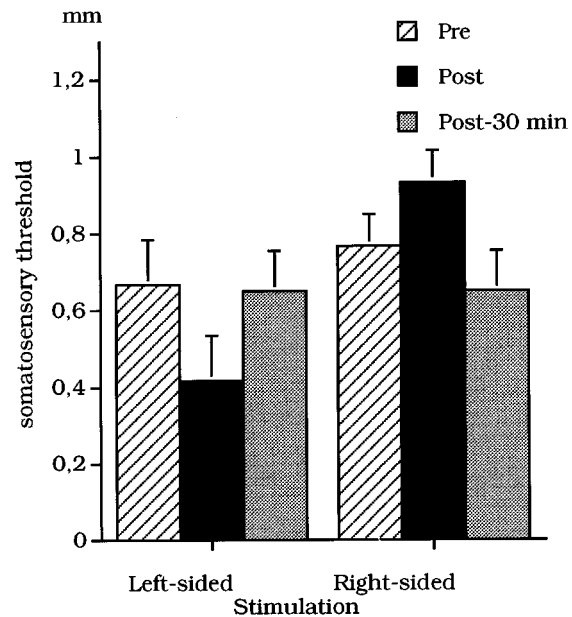


Figure 5. Contralesional somatosensory deficits and transcutaneous electrical nervous stimulation. Average somatosensory thresholds in the contralesional left hand of a right brain-damaged patient with left visuospatial hemineglect, on three successive assessments (see caption to figure 4). The contralesional (left) and the ipsilesional (right) sides of the neck were stimulated in successive sessions (redrawn from Vallar *et al.* (1996b), figure 3, by permission of Cambridge University Press).

occur without associated somatosensory deficits (Bisiach & Vallar 1988; Vallar *et al.* 1993b), constitutes a double dissociation. This dissociation suggests that the systems concerned with awareness of somatosensory stimuli, modulated by sensory stimulations, are independent of those subserving the representation of objects in extrapersonal space. All of them, however, share the characteristic of being modulated in a directionally similar fashion by vestibular, optokinetic and proprioceptive or somatosensory stimuli.

These findings provide an explanation, based on experimental studies, of the clinical observation that somatosensory deficits are more frequent after lesions in the right hemisphere than after left brain damage (Sterzi *et al.* 1993). In line with these results, contralesional somatosensory deficits have also been reported to be more severe after lesions (position sense (Vallar *et al.* 1993a, 1995a)) or temporary dysfunction (detection of single and double tactile stimuli (Meador *et al.* 1988)) of the right hemisphere (review in Vallar *et al.* (1993b)). Finally, the observation that also the modulatory effects of direction-specific sensory stimulations occur much more frequently in patients with lesions in the right hemisphere concur to suggest the existence of a specific additional pathological factor associated with right brain damage, over and above the primary somatosensory disorder. The size of the recovery brought about by some treatments, such as vestibular stimulation (see figures 2 and 3), suggests that the relative contribution of this factor may be quite substantial.

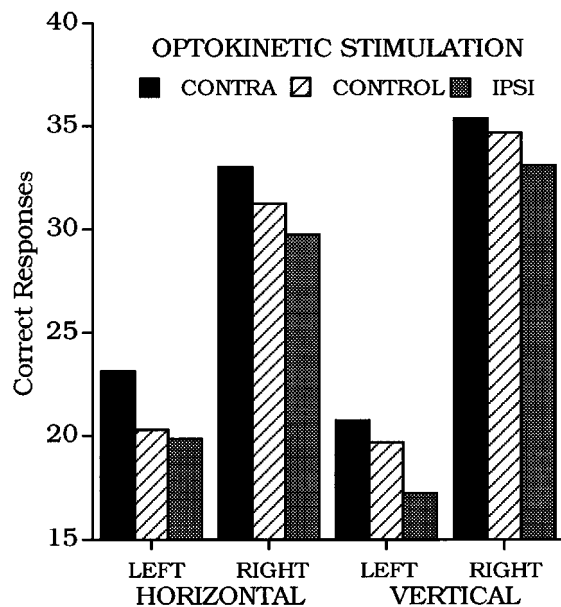


Figure 6. Deficits of position sense of right brain-damaged patients with visuospatial hemineglect and optokinetic stimulation. Mean correct responses in the LEFT and RIGHT forearms, contralateral and ipsilateral to the side of the lesion, by stimulation condition (baseline (CONTROL), optokinetic stimulation with a direction of the movement of the luminous dots contralateral or ipsilateral (CONTRA or IPSI) to the side of the lesion) and by assessed plane (HORIZONTAL or VERTICAL) (redrawn from Vallar *et al.* (1995a), figure 2, by permission of Masson).

4. INTERPRETATION

This pattern of results supports the view that contralesional somatosensory disorders are produced by two discrete, possibly additive, pathological factors: (i) a primary sensory deficit, which may occur after lesions of either hemisphere, without left–right asymmetries, and (ii) a higher-order disorder, closely associated with right brain damage, which is modulated by a number of sensory afferents. The similarity of the effects of sensory stimulations on both left somatosensory deficits and a number of components of the syndrome of left spatial hemineglect suggests that the higher-order pathological factor underlying the greater frequency and severity of left-sided somatosensory deficits may be spatial in nature.

Before accepting this interpretation, however, the possibility that the effects of the modulatory sensory stimulations take place at the level of defective primary sensory processes (in the somatosensory and visual domains, somatotopic and retinotopic levels of representation) should be taken into account. This interpretation is unlikely: there is electrophysiological and, at least in part, anatomical evidence that primary sensory processes may be largely preserved in these patients (Vallar *et al.* 1991a,b; Angelelli *et al.* 1996). In addition, the existence of a hemispheric asymmetry argues against the view that primary sensory processes are the main target of this sensory modulation. Furthermore, damage confined to the anterior parietal region, including the primary somatosensory cortex,

brings about deficits of tactile perception, which do not differ according to the side of the hemispheric lesion (Corkin *et al.* 1970; Pause *et al.* 1989). Finally, as shown in figure 5, right brain-damaged patients with left hemineglect show a deficit of position sense, modulated by optokinetic stimulation, which also involves the right forearm (Vallar *et al.* 1993a, 1995a). This ipsilesional deficit, which was not found in right and left brain-damaged patients without visuospatial hemineglect, cannot be ascribed to a primary sensory disorder, but is likely to reflect a higher-order impairment.

The related account of the effects of sensory stimulations in terms of non-specific cerebral or hemispheric activation is also implausible. In addition to the hemispheric asymmetry mentioned above, the effects are direction-specific, related to the direction of the slow phase of nystagmus (vestibular and optokinetic stimulations) or to the side of the transcutaneous (mechanical or electrical) stimulation. These treatments may bring about a temporary recovery, but may also cause a worsening of the disorder, or be ineffective (review in Vallar *et al.* (1997b), see also examples in figures 5 and 6). The latter effects are not compatible with the hypothesis of a general cerebral activation. Finally, vestibular stimulation temporarily improves a number of components of the neglect syndrome, but not other cognitive disorders, such as aphasia. The observation of these dissociated effects in one left brain-damaged patient with right visuospatial hemineglect and dysphasia makes an interpretation in terms of general hemispheric activation much unlikely (Vallar *et al.* 1995c).

The modulatory effects of direction-specific sensory stimulations may then occur at the level of a spatial, non-somatotopic, representation of the body. It has long been known that patients with right hemisphere damage and hemineglect show a pathological displacement of egocentric frames of reference, with the midsagittal plane of the trunk (the subjective ‘straight ahead’) being lateralized towards the side of the lesion, with a rightward directional error (Heilman *et al.* 1983; Mark & Heilman 1990). This disorder may be conceived in terms of either a rightward pathological translation or, alternatively, a clockwise rotation of egocentric coordinate systems (see a discussion of hemineglect in terms of ‘rotation’ in Ventre *et al.* (1984), see also Karnath (this volume)). Vallar *et al.* (1995b) investigated these hypotheses by requiring patients to report whether sound sources in the front or in the back half of extrapersonal space were perceived to the left or to the right of the subjective midsagittal plane. In right brain-damaged patients with visuospatial hemineglect the subjective midsagittal plane was found to be displaced rightwards in both half-spaces, consistent with an account in terms of a rightward ipsilesional translation of egocentric coordinates. Clockwise rotation around the vertical axis, by contrast, would involve an ipsilesional rightward displacement in the front half-space, but a contralesional leftward displacement in the back half-space. The translation hypothesis is also consistent with the results of early studies based on auditory lateralization paradigms, where subjects localized, in the frontal

plane passing through the ears, the perceived position of fused sound images generated by dichotic stimuli. Right brain-damaged patients showed a systematic directional error for all stimuli, also when the interaural intensity or time differences (D) were zero, whereas normal subjects localized the fused sound images in the intersection between the midfrontal and the midsagittal planes (the midbody axis) (Teuber 1962; Altman *et al.* 1979; Bisiach *et al.* 1984). The hypothesis of a rightward rotation of the egocentric coordinate system, by contrast, would predict a normal localization of dichotic stimuli with $D=0$, because the vertical axis of the body would be unaffected.

Optokinetic and vestibular stimulations modulate this ipsilesional displacement, reducing or increasing the rightward error of patients with left hemineglect, and have similar directional effects in normal subjects (review in Vallar *et al.* 1997b). The computation of spatial frames of reference involves the continuous integration of signals from different sensory sources (visual, vestibular, proprioceptive or somatosensory) from the two sides of space and the body (Andersen 1995, and this volume). Unilateral cerebral lesions may bring about an unbalanced activity of the bilateral set of cerebral structures concerned with the building up and operating spatial representations (Ventre *et al.* 1984; Kinsbourne 1993; for a related functional account, see Vallar *et al.* (1993b)). In patients with lesions in the right hemisphere, one effect of this unbalanced activity is the comparatively minor weight given to left-sided sensory signals. This, in turn, results in impoverished spatial representations, with a left-right gradient, or a rightward distortion (discussion in Vallar *et al.* 1997b). The unilateral or direction-specific stimulations discussed above provide a supplementary lateralized signal, which modulates the rightward distortion, restoring, at least in part, or further disrupting the defective spatial representation of the contralesional side.

The view that the contralesional somatosensory deficits of right brain-damaged patients have a spatial component is supported by a number of studies based on an approach complementary to that adopted by the stimulation experiments reviewed above. According to the 'spatial' hypothesis discussed previously, direction-specific stimulations may improve, or worsen, somatosensory deficits of patients with right-sided lesions, reducing, or increasing, the rightward distortion of a spatial representation of the body. Because, however, the ipsilesional right side of such spatial representations is relatively preserved, as suggested by the normal detection of tactile stimuli delivered to the right hand (Vallar *et al.* 1990, 1993b) and by the minor deficit of position sense in the right forearm (Vallar *et al.* 1993a, 1995a), the prediction can be made that left-sided sensory deficits may also be improved by manoeuvres whereby the stimulus is presented in the ipsilesional space, dissociating retinotopic and somatotopic from egocentric (with reference to the midsagittal plane of the trunk) frames of reference. Kooistra & Heilman (1989) found that the left hemianopia of their patient, who had a right thalamic and medial temporo-

occipital lesion, improved when her eyes were directed 30° towards the right side. In this condition, where left visual half-field testing fell in the right half-space, the patient's left hemianopia improved significantly. Applying the same logic to left hemianaesthesia, Smania & Aglioti (1995) found that the detection of left-sided tactile stimuli by patients with lesions in the right hemisphere improved when the forearms were crossed, with the left hand being placed in the ipsilesional right half-space. This effect was present during both single and double (two stimuli simultaneously delivered to the left and the right hand) stimulation (see also Moscovitch & Behrmann (1994) for related evidence on tactile extinction).

The results discussed so far provide converging evidence to the effect that spatial egocentric representations contribute to awareness of somatosensory and visual stimuli, and to the perception of the spatial position of body parts (position sense). This perceptual role of spatial frames of reference may be related to their involvement in the conscious organization of movements (for example, of the arm, or of the whole body through locomotion) directed towards specific targets in extrapersonal space, or on the subject's body (review in Andersen 1995). Seen from this perspective, spatial coordinate systems may represent an interface, in which spatial codes are available to both perceptual and premotor representations. If this is the case, the sensory stimulations that modulate spatial frames of reference (review in Vallar *et al.* 1997b) and the severity of left somatosensory deficits in right brain-damaged patients may be expected to affect the motor aspects of the syndrome of spatial hemineglect in a similar fashion. In line with this view contralesional hemiplegia, like hemianaesthesia and hemianopia, is more frequent after lesions in the right hemisphere, compared with left brain damage (Sterzi *et al.* 1993). If an analogy is drawn with the hemispheric asymmetry of sensory deficits, this finding suggests that a pathological factor, spatial in nature, may also account for the hemispheric asymmetry of contralesional motor disorders. Were this the case, the direction-specific stimulations that improve left somatosensory deficits would be expected to affect left motor deficits in a similar fashion. The clinical observation in one right brain-damaged patient that vestibular stimulation temporarily improved left hemiplegia supports this hypothesis (Rode *et al.* 1992).

In a recent experimental study (Vallar *et al.* 1997a), two right brain-damaged patients with left visuospatial hemineglect were required to flex the fingers of the contralesional paretic hand against a handle, in a baseline condition and during optokinetic stimulation. In line with the results of previous investigations (Pizzamiglio *et al.* 1990; Vallar *et al.* 1993a, 1995a), optokinetic stimulation with a leftward direction of the movement of the luminous dots improved muscle strength in the left contralesional hand, whereas stimulation with a rightward direction was ineffective. In patient number 1, magnetic resonance imaging (MRI) showed extensive corticosubcortical damage to the right frontotemporoparietal-occipital cortex. In patient number 2 the MRI-assessed lesion involved the

right inferior parietal lobule, the superior-posterior temporal region, and the occipital cortex. This lesional pattern is frequently associated with hemineglect (see figure 1). Optokinetic stimulation had no effects on the right-sided motor deficit of two left brain-damaged patients without hemineglect, independent of the direction of the movement. These results suggest that the human ability to organize and produce motor outputs, even as simple as flexing the fingers, requires the availability of an internal representation of the space where movements are to be performed. This spatial medium, which may include the posterior-inferior parietal and premotor frontal regions, may be damaged by brain damage, and restored, at least in part, by optokinetic stimulation.

This work was supported in part by grants from CNR, MURST, and Ministero della Sanità.

REFERENCES

- Adams, R. D., Victor, M. & Ropper, A. H. (eds) 1997 *Principles of neurology*, 6th edn. New York: McGraw-Hill.
- Altman, J. A., Balonov, L. J. & Deglin, V. L. 1979 Effects of unilateral disorder of the brain hemisphere function in man on directional hearing. *Neuropsychologia* **17**, 295–301.
- Andersen, R. A. 1995 Coordinate transformations and motor planning in posterior parietal cortex. In *The cognitive neurosciences* (ed. M. S. Gazzaniga), pp. 519–548. Cambridge, MA: MIT Press.
- Angelelli, P., De Luca, M. & Spinelli, D. 1996 Early visual processing in neglect patients: a study with steady-state VEPs. *Neuropsychologia* **34**, 1151–1157.
- Battaglini, P. P., Galletti, C. & Fattori, P. 1996 Cortical mechanisms for visual perception of object motion and position in space. *Behav. Brain Res.* **76**, 143–154.
- Berti, A. & Rizzolatti, G. 1992 Visual processing without awareness: evidence from unilateral neglect. *J. Cogn. Neurosci.* **4**, 345–351.
- Bisiach, E., Cornacchia, L., Sterzi, R. & Vallar, G. 1984 Disorders of perceived auditory lateralization after lesions of the right hemisphere. *Brain* **107**, 37–52.
- Bisiach, E., Rusconi, M. L. & Vallar, G. 1991 Remission of somatoparaphrenic delusion through vestibular stimulation. *Neuropsychologia* **29**, 1029–1031.
- Bisiach, E. & Vallar, G. 1988 Hemineglect in humans. In *Handbook of neuropsychology* (ed. F. Boller & J. Grafman), vol. 1, pp. 195–222. Amsterdam: Elsevier.
- Bottoni, G., Paulesu, E., Sterzi, R., Warburton, E., Wise, R. J. S., Vallar, G., Frackowiak, R. S. J. & Frith, C. D. 1995 Modulation of conscious experience by peripheral stimuli. *Nature* **376**, 778–781.
- Cappa, S., Sterzi, R., Vallar, G. & Bisiach, E. 1987 Remission of hemineglect and anosognosia during vestibular stimulation. *Neuropsychologia* **25**, 775–782.
- Castaigne, P., Laplane, D. & Degos, J.-D. 1970 Trois cas de négligence motrice par lésion rétro-rolandique. *Rev. Neurol.* **122**, 234–242.
- Chalmers, D. J. 1996 *The conscious mind. In search of a fundamental theory*. New York: Oxford University Press.
- Corkin, S., Milner, B. & Rasmussen, T. 1970 Somatosensory thresholds. *Archs Neurol.* **23**, 41–58.
- Critchley, M. 1953 *The parietal lobes*. New York: Hafner.
- Damasio, A. R., Damasio, H. & Chang Chui, H. 1980 Neglect following damage to frontal lobe or basal ganglia. *Neuropsychologia* **18**, 123–132.
- Fogassi, L., Gallese, V., di Pellegrino, G., Fadiga, L., Gentilucci, M., Luppino, G., Matelli, M., Pedotti, A. & Rizzolatti, G. 1992 Space coding by premotor cortex. *Expl Brain Res.* **89**, 686–690.
- Galletti, C., Battaglini, P. P. & Fattori, P. 1993 Parietal neurons encoding spatial locations in craniotopic coordinates. *Expl Brain Res.* **96**, 221–229.
- Garcin, R., Varay, A. & Hadji-Dimo 1938 Document pour servir a l'étude des troubles du schema corporel. *Rev. Neurol.* **69**, 498–510.
- Graziano, M. S. A., Yap, G. S. & Gross, C. G. 1994 Coding of visual space by premotor neurons. *Science* **266**, 1054–1057.
- Heilman, K. M., Bowers, D. & Watson, R. T. 1983 Performance on hemispacial pointing task by patients with neglect syndrome. *Neurology* **33**, 661–664.
- Heilman, K. M. & Valenstein, E. 1972 Frontal lobe neglect in man. *Neurology* **22**, 660–664.
- Heilman, K. M., Watson, R. T. & Valenstein, E. 1993 Neglect and related disorders. In *Clinical neuropsychology* (ed. K. M. Heilman & E. Valenstein), pp. 279–336. New York: Oxford University Press.
- Heilman, K. M., Watson, R. T. & Valenstein, E. 1994 Localization of lesions in neglect and related disorders. In *Localization and neuroimaging in neuropsychology* (ed. A. Kertesz), pp. 495–524. San Diego: Academic Press.
- Husain, M. & Kennard, C. 1996 Visual neglect associated with frontal lobe infarction. *J. Neurol.* **243**, 652–657.
- Karnath, H. O., Christ, K. & Hartje, W. 1993 Decrease of contralateral neglect by neck muscle vibration and spatial orientation of trunk midline. *Brain* **116**, 383–396.
- Kinsbourne, M. 1993 Orientational bias model of unilateral neglect: evidence from attentional gradients within hemispace. In *Unilateral neglect: clinical and experimental studies* (ed. I. H. Robertson & J. C. Marshall), pp. 63–86. Hove: Erlbaum.
- Kooistra, C. A. & Heilman, K. M. 1989 Hemispacial visual inattention masquerading as hemianopia. *Neurology* **39**, 1125–1127.
- Làdavas, E., Paladini, R. & Cubelli, R. 1993 Implicit associative priming in a patient with left visual neglect. *Neuropsychologia* **31**, 1307–1320.
- Mark, V. W. & Heilman, K. M. 1990 Bodily neglect and orientational biases in unilateral neglect syndrome and normal subjects. *Neurology* **40**, 640–643.
- Mark, V. W., Heilman, K. M. & Watson, R. 1996 Motor neglect: what do we mean? *Neurology* **46**, 1492–1493.
- Marshall, J. C. & Halligan, P. 1988 Blindsight and insight in visuo-spatial neglect. *Nature* **336**, 766–767.
- McGlinchey-Berroth, R., Milberg, W. P., Verfaellie, M., Alexander, M. & Kilduff, P. 1993 Semantic processing in the neglected visual field: evidence from a lexical decision task. *Cogn. Neuropsychol.* **10**, 79–108.
- Meador, K. J., Loring, D. W., Lee, G. P., Brooks, B. S., Thompson, E. E., Thompson, W. O. & Heilman, K. M. 1988 Right cerebral specialization for tactile attention as evidenced by intracarotid sodium amytal. *Neurology* **38**, 1763–1766.
- Moscovitch, M. & Behrmann, M. 1994 Coding of spatial information in the somatosensory system: evidence from patients with neglect following parietal lobe damage. *J. Cogn. Neurosci.* **6**, 151–155.
- Pause, M., Kunesch, E., Binkofsky, F. & Freund, H. J. 1989 Sensorimotor disturbances in patients with lesions of the parietal cortex. *Brain* **112**, 1599–1625.
- Pizzamiglio, L., Frasca, R., Guariglia, C., Incoccia, C. & Antonucci, G. 1990 Effect of optokinetic stimulation in patients with visual neglect. *Cortex* **26**, 535–540.
- Rode, G., Charles, N., Perenin, M. T., Vighetto, A., Trillet, M. & Aimard, G. 1992 Partial remission of hemiplegia and somatoparaphrenia through vestibular stimulation in a case of unilateral neglect. *Cortex* **28**, 203–208.
- Rowland, L. P. (ed.) 1995 *Merritt's textbook of neurology*, 9th edn. Baltimore: Williams & Wilkins.
- Rubens, A. B. 1985 Caloric stimulation and unilateral visual neglect. *Neurology* **35**, 1019–1024.

- Smania, N. & Aglioti, S. 1995 Sensory and spatial components of somesthetic deficits following right brain damage. *Neurology* **45**, 1725–1730.
- Sterzi, R., Bottini, G., Celani, M. G., Righetti, E., Lamassa, M., Ricci, S. & Vallar, G. 1993 Hemianopia, hemianaesthesia, and hemiplegia after left and right hemisphere damage: a hemispheric difference. *J. Neurol. Neurosurg. Psychiatr.* **56**, 308–310.
- Teuber, H. L. 1962 Effects of brain wounds implicating right or left hemisphere in man: hemisphere differences in vision, audition and somesthesia. In *Interhemispheric relations and cerebral dominance* (ed. V. B. Mountcastle), pp. 131–157. Baltimore: Johns Hopkins Press.
- Vallar, G. 1993 The anatomical basis of spatial hemineglect in humans. In *Unilateral neglect: clinical and experimental studies* (ed. I. H. Robertson & J. C. Marshall), pp. 27–59. Hove: Erlbaum.
- Vallar, G. 1994 Left spatial hemineglect: an unmanageable explosion of dissociations? *Neuropsychol. Rehabil.* **4**, 209–212.
- Vallar, G., Antonucci, G., Guariglia, C. & Pizzamiglio, L. 1993a Deficits of position sense, unilateral neglect, and optokinetic stimulation. *Neuropsychologia* **31**, 1191–1200.
- Vallar, G., Bottini, G., Rusconi, M. L. & Sterzi, R. 1993b Exploring somatosensory hemineglect by vestibular stimulation. *Brain* **116**, 71–86.
- Vallar, G., Bottini, G., Sterzi, R., Passerini, D. & Rusconi, M. L. 1991a Hemianesthesia, sensory neglect and defective access to conscious experience. *Neurology* **41**, 650–652.
- Vallar, G., Guariglia, C., Magnotti, L. & Pizzamiglio, L. 1995a Optokinetic stimulation affects both vertical and horizontal deficits of position sense in unilateral neglect. *Cortex* **31**, 669–683.
- Vallar, G., Guariglia, C., Nico, D. & Bisiach, E. 1995b Spatial hemineglect in back space. *Brain* **118**, 467–472.
- Vallar, G., Guariglia, C., Nico, D. & Pizzamiglio, L. 1997a Motor deficits and optokinetic stimulation in patients with left hemineglect. *Neurology*. (In the press.)
- Vallar, G., Guariglia, C., Nico, D. & Tabossi, P. 1996a Left neglect dyslexia and the processing of neglected information. *J. Clin. Exp. Neuropsychol.* **18**, 733–746.
- Vallar, G., Guariglia, C. & Rusconi, M. L. 1997b Modulation of the neglect syndrome by sensory stimulation. In *Parietal lobe contributions to orientation in 3D space* (ed. P. Thier & H.-O. Karnath), pp. 555–578. Heidelberg: Springer.
- Vallar, G., Papagno, C., Rusconi, M. L. & Bisiach, E. 1995c Vestibular stimulation, spatial hemineglect and dysphasia. Selective effects? *Cortex* **31**, 589–593.
- Vallar, G. & Perani, D. 1986 The anatomy of unilateral neglect after right hemisphere stroke lesions. A clinical CT/Scan correlation study in man. *Neuropsychologia* **24**, 609–622.
- Vallar, G., Rusconi, M. L., Barozzi, S., Bernardini, B., Ovidia, D., Papagno, C. & Cesarani, A. 1995d Improvement of left visuo-spatial hemineglect by left-sided transcutaneous electrical stimulation. *Neuropsychologia* **33**, 73–82.
- Vallar, G., Rusconi, M. L. & Bernardini, B. 1996b Modulation of neglect hemianesthesia by transcutaneous electrical stimulation. *J. Int. Neuropsychol. Soc.* **2**, 452–459.
- Vallar, G., Rusconi, M. L. & Bisiach, E. 1994 Awareness of contralesional information in unilateral neglect: effects of verbal cueing, tracing and vestibular stimulation. In *Attention and performance. XV. Conscious and nonconscious information processing* (ed. C.A. Umiltà & M. Moscovitch), pp. 377–391. Cambridge, MA: MIT Press.
- Vallar, G., Sandroni, P., Rusconi, M. L. & Barbieri, S. 1991b Hemianopia, hemianesthesia and spatial neglect. A study with evoked potentials. *Neurology* **41**, 1918–1922.
- Vallar, G., Sterzi, R., Bottini, G., Cappa, S. & Rusconi, M. L. 1990 Temporary remission of left hemianaesthesia after vestibular stimulation. *Cortex* **26**, 123–131.
- Ventre, J., Flandrin, J. M. & Jeannerod, M. 1984 In search for the egocentric reference. A neurophysiological hypothesis. *Neuropsychologia* **22**, 797–806.

