

Original Research Article

Spectrum of pathologies on FNAC evaluation of peripheral lymph nodes at a tertiary care center in hyderabad: a retrospective study

Ramanan Duraishwami*, Sujatha Margam, Priya Chandran, Akina Prakash

Department of Pathology, Mallareddy Institute of Medical Sciences, Suraram, Hyderabad - 500055, Telangana, India

Received: 22 November 2016

Accepted: 10 December 2016

*Correspondence:

Dr. Ramanan Duraishwami,

E-mail: daru_r@rediffmail.com

Copyright: © the author(s), publisher and licensee Medip Academy. This is an open-access article distributed under the terms of the Creative Commons Attribution Non-Commercial License, which permits unrestricted non-commercial use, distribution, and reproduction in any medium, provided the original work is properly cited.

ABSTRACT

Background: The aim of the study was to study the pattern of pathologies identified on FNA of superficial lymph nodes in a tertiary hospital in Hyderabad during the period January 2014 to August 2016, as well as to identify the profile of patients undergoing the procedure at our Hospital.

Methods: The data pertaining to the details of the patients who underwent FNA evaluation of superficial lymph nodes from the period January 2014 to 31 August 2016 at a tertiary hospital located in Hyderabad, Telangana, was analysed to determine the age and sex distribution of the patients and the distribution of pathologies diagnosed on FNA evaluation of the lymph nodes.

Results: The female gender was predominant (61%; 156 out of 253 patients) among the patients who underwent FNA evaluation of lymph nodes. A majority of the patients were in the age group of 20 to 50 years. Reactive lymph node hyperplasia was the predominant diagnosis in our series (49.8 %; 126 cases out of 253 FNA evaluations). Granulomatous lymphadenitis was the second most common diagnosis (37.15%; 94 out of 253 FNA evaluations).

Conclusions: Fine Needle Aspiration evaluation is a quick, easy, relatively non - traumatic, and, in expert hands, a reliable method of diagnosing the pathology underlying enlarged superficial lymph nodes. Reactive lymph node hyperplasia and granulomatous lymphadenitis were the two most common causes of lymph node enlargement in our series.

Keywords: FNAC, Granulomatous lymphadenitis, Incidence of pathologies, Reactive hyperplasia

INTRODUCTION

Fine needle aspiration (FNA) [fine needle aspiration Cytology (FNAC)] technique was first introduced by Greig and Grey.¹ Since the 1960's, it has been used extensively as a diagnostic tool for rapid evaluation of mainly superficial lesions, especially of lymph nodes. It is cost effective, relatively less traumatic, and enables the pathologist to provide the clinician with a diagnosis in a very short time, and hence is ideal especially for OP patients.² Lymphadenopathy is a commonly encountered clinical entity. The diagnosis of the cause underlying the enlarged lymph node(s) enables the clinician to plan

appropriate management for each patient. Enlarged superficial lymph nodes are easily amenable to evaluation by FNA technique and hence FNAC forms an important diagnostic tool in the armamentarium of the pathologist.³ While histopathological evaluation of surgically excised lymph nodes is a more specific and accurate diagnostic parameter, it is relatively more costly, time consuming and discomfiting to the patient, and may not be warranted in every patient. FNAC is more cost effective and relatively non - invasive.⁴ FNAC evaluation may prevent a patient having to undergo unnecessary surgery and permit the treating clinician to offer conservative therapy instead.

This study was undertaken to identify the causes of lymphadenopathy amongst patients referred for FNAC evaluation of their enlarged lymph nodes to the laboratory of our tertiary care hospital located in Hyderabad, India.

METHODS

The study was undertaken as a retrospective systematic study using existing patient data retrieved from the records of the Department of Pathology, Mallareddy Hospital.

During the period 01 January 2014 to 31 August 2016, a total of 253 patients were referred to the cytopathology department of the Central Laboratory of Mallareddy Hospital, Suraram, Hyderabad for FNAC evaluation of superficial enlarged lymph nodes, which were either single or multiple. All patients who were referred for FNAC of enlarged superficial lymph nodes were included in the study.

Consequent to studying the clinical profile of each patient, including perusing relevant investigation results in each case, the patients underwent FNAC evaluation of the enlarged lymph node(s), using a 22 or 23 gauge needle attached to a 10 cc disposable syringe. Consent of the patients was obtained in each case. Smears were prepared on clean glass slides as per standard techniques, and the smears either wet fixed by immersing the slides in 95% methanol or air dried. Where aspirate was scanty, all slides were wet - fixed only. Wet fixed smears were stained by Hematoxylin and Eosin (H and E) and Papanicolaou's (Pap) stains. Air dried smears were stained by Giemsa stain.

All slides after staining were mounted using standard cover slips and then analyzed by standard microscopy. No special stains were used on the slides. Diagnosis was made by either a single cytopathologist or, where mandated, by two or more cytopathologists. A turnaround time of two hours was maintained while reporting the slides. In cases where malignant deposits or lymphoproliferative disorders were diagnosed on FNAC, it was recommended that the patients be referred to a cancer center for immunocytochemistry/biopsy and HPE of the lesions.

At the end of the study period, the results of the FNAC analyses were retrieved from the Laboratory archives and analyzed to establish the spectrum of pathologies reported on FNAC during the period under study. The age and gender profile of the patients was also studied. Data was analyzed using MS Excel sheet and calculations of incidence made from the same.

No correlation with biopsy reports was undertaken during this study, as in the majority of cases excised lymph nodes were not received for histopathological evaluation.

RESULTS

A total of 253 patients reported for FNAC evaluation of enlarged superficial lymph nodes during the period January 2014 to 31 August 2016. The distribution of lesions diagnosed each year is given in Figures 1 to 3. During the entire study period, a diagnosis of reactive lymph node hyperplasia was given in 126 aspirates out of 253 (49.8% of cases) and was the most common diagnosis offered. Granulomatous lymphadenitis, caseating or non - caseating, was diagnosed in 94 aspirates out of 253 (37.15%) and was the second most common diagnosis offered.

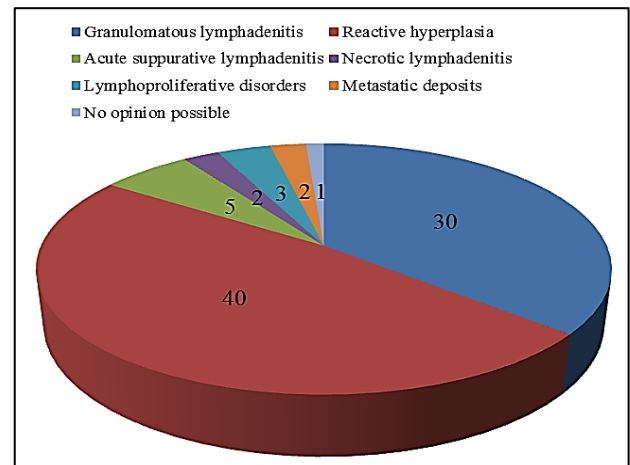


Figure 1: Distribution of lesions on lymph node FNAC - 2014 (total = 83).

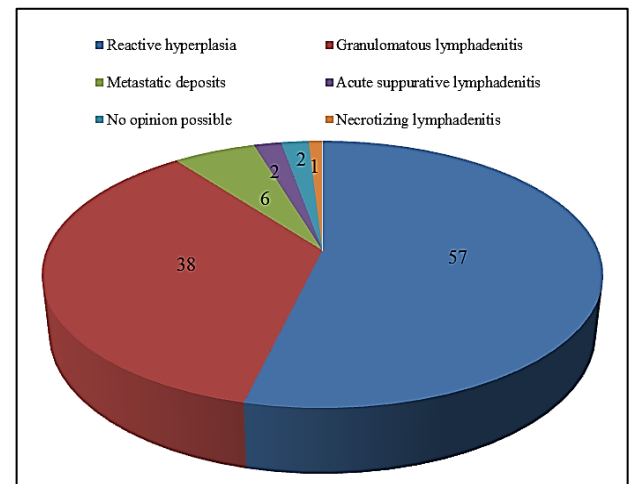


Figure 2: Distribution of lesions on lymph node FNAC - 2015 (total = 105).

The age and gender distribution of all the cases, year wise, is given in Tables 1 to 3. Female patients constituted 61% of the cases overall (156 out of 253 aspirates). Most of the patients were in the age group 10 - 50 years. No age or gender specific predilection was seen for any of the pathologies reported.

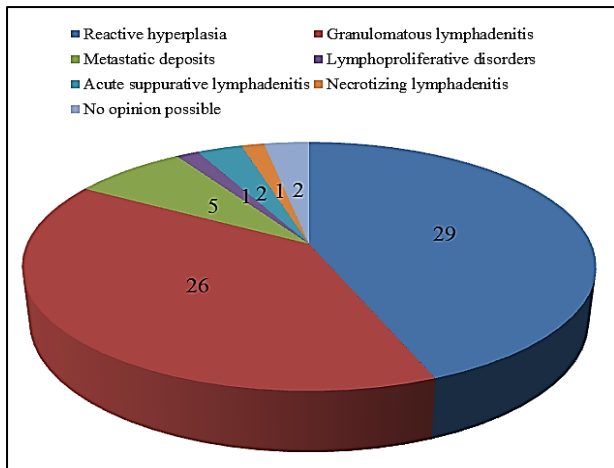


Figure 3: Distribution of lesions on lymph node FNAC - 2016 (till 31 August) (total 65).

A diagnosis of metastatic deposits in the lymph node was offered on 13 aspirates. The morphological distribution of the lesions is given in Table 4. Eight out of thirteen patients were above 50 years of age (61%). Metastatic adenocarcinoma was the most common diagnosis offered, but the distribution of lesions was fairly equal among all morphologies.

Granulomatous lymphadenitis was diagnosed by the presence of epithelioid cell granulomas, with or without caseating necrosis (Figure 4 and 5). We do not routinely do AFB stain on such smears in our laboratory.

Reactive lymph node hyperplasia was diagnosed by the presence of a polymorphous population of lymphoid cells and tingible body macrophages (Figure 6 and 7). This formed the predominant pathology in our series of FNAC's.

Table 1: Distribution of lesions according to age and sex year 2014.

Age (years)	Granulomatous lymphadenitis		Reactive hyperplasia		Acute suppurative lymphadenitis		Necrotic lymph adenitis		Lympho proliferative disorder		Metastases		No opinion possible	
≤ 10	3	1	3	1	2	0	0	0	0	1	0	0	0	0
11 - 20	1	7	3	11	0	1	0	0	0	0	0	0	0	0
21 - 30	4	4	2	4	1	0	0	1	1	1	1	0	0	0
31 - 40	0	3	1	6	0	0	0	0	0	0	0	1	0	0
41 - 50	1	2	1	3	0	0	0	0	0	0	0	0	0	0
51 - 60	1	1	1	3	1	0	0	0	0	0	0	0	0	0
≥ 60	1	1	0	1	0	0	0	1	0	0	0	0	0	0
Total	11	19	11	29	4	1	0	2	1	2	1	1	0	1
Total	30 (36%)		40 (48%)		5 (6%)		2 (3%)		3 (3.6%)		2 (3%)		1 (0.4%)	

Grand total = 83.

Table 2: Distribution of lesions according to age and sex year 2015.

Age (years)	Granulomatous lymphadenitis		Reactive hyperplasia		Acute suppurative lymphadenitis		Necrotic lymph adenitis		Lympho proliferative disorder		Metastases		No opinion possible	
≤ 10	1	0	7	3	0	0	0	0	0	0	0	0	0	0
11 - 20	1	6	11	6	1	1	0	0	0	0	0	0	0	0
21 - 30	6	7	6	12	1	1	0	0	0	0	0	1	0	1
31 - 40	0	6	3	3	0	0	0	0	0	0	0	0	0	0
41 - 50	1	2	0	3	0	0	0	0	0	0	0	1	0	1
51 - 60	3	1	1	2	0	0	0	0	0	0	0	0	0	0
≥ 60	1	1	0	0	0	0	0	0	0	0	4	0	0	0
Total	13	23	28	29	2	2	0	0	0	0	4	2	0	2
Total	36 (34%)		57 (54%)		4 (4%)		0		0		6 (6%)		2 (2%)	

Grand total = 105.

Necrotic lymphadenitis was diagnosed by the presence of necrotic material in the aspirated material with insufficient cellular content in the smears to ascribe any etiology for the necrosis. Suppurative lymphadenitis, or

lymph node draining a septic focus, was diagnosed by the presence of a predominantly neutrophilic inflammatory component in the aspirate against a background of lymphoid cells.

Lymphoproliferative disorders were diagnosed in only 4 out of 253 aspirates analyzed (1.6%); three cases were diagnosed as non - Hodgkin's lymphoma and one as Hodgkin's lymphoma.

Non - Hodgkin's lymphoma was diagnosed by the presence of a monotonously uniform population of lymphocytic cells scattered singly in a highly cellular smear and the absence of Reed Sternberg cells (Figure 8 and 9).

Metastatic deposits were diagnosed based upon morphological patterns and cellular details. Papillary carcinoma metastases are shown in Figure 10 and 11. Well - formed papillary structures composed of malignant cells were seen against a background of lymphoid cells. No opinion was possible in 4 out of 253 cases (1.6%) due to inadequate aspirated material on the smears. This was due to the extremely small size of the lymph nodes accessed.

Table 3: Distribution of lesions according to age and sex year 2016 (till 31 August).

Age (years)	Granulomatous lymphadenitis		Reactive hyperplasia		Acute suppurative lymphadenitis		Necrotic lymph adenitis		Lympho proliferative disorder		Metastases		No opinion possible	
≤ 10	0	0	4	2	0	0	0	0	0	0	0	0	0	0
11 - 20	2	2	0	2	0	0	0	0	0	0	0	1	0	0
21 - 30	4	6	0	6	1	0	0	1	0	0	0	0	0	1
31 - 40	3	2	1	8	0	0	0	0	0	0	0	0	0	0
41 - 50	3	4	0	3	0	0	0	0	1	0	0	1	0	0
51 - 60	0	0	1	5	0	0	0	0	0	0	1	1	0	0
≥ 60	0	0	0	0	0	1	0	0	0	0	1	0	0	0
Total	12	14	6	23	1	1	0	1	1	0	2	3	0	1
Total	26 (40%)		29 (44%)		2 (3%)		1 (1.6%)		1 (1.6%)		5 (8%)		1 (1.6%)	

Grand total = 65.

Table 4: Morphological pattern of metastatic deposits during the period under study (total = 13).

Type of metastatic deposit	Total number	Male	Female	Age < 50 years	Age ≥ 50 years
Squamous cell carcinoma	2	1	1	0	2
Undifferentiated carcinoma	3	1	2	1	2
Adenocarcinoma (NOS)	4	2	2	2	2
Papillary carcinoma	3	2	1	1	2
Seminoma	1	1	0	1	0
Total	13	7	6	5	8

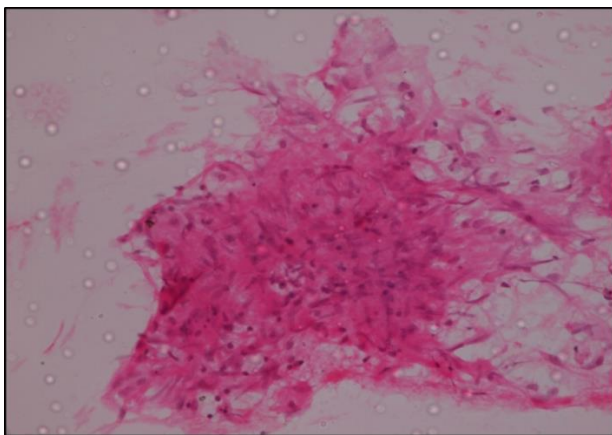


Figure 4: Granulomatous lymphadenitis: Smear showing epithelioid cell granuloma with caseation H and E; x 100.

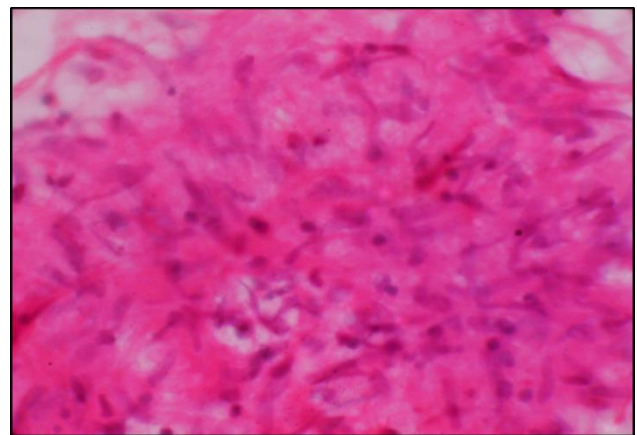


Figure 5: Granulomatous lymphadenitis: Smear showing epithelioid cell granuloma with caseation H and E; x 400.

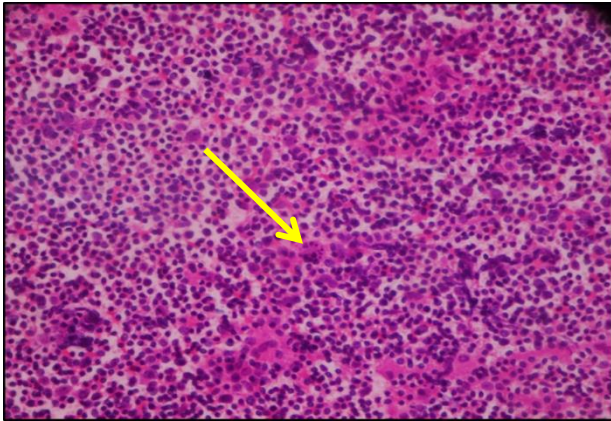


Figure 6: Reactive lymph node hyperplasia: Smear showing a polymorphous population of lymphoid cells and a tingible body macrophage (arrow) H and E x 100.

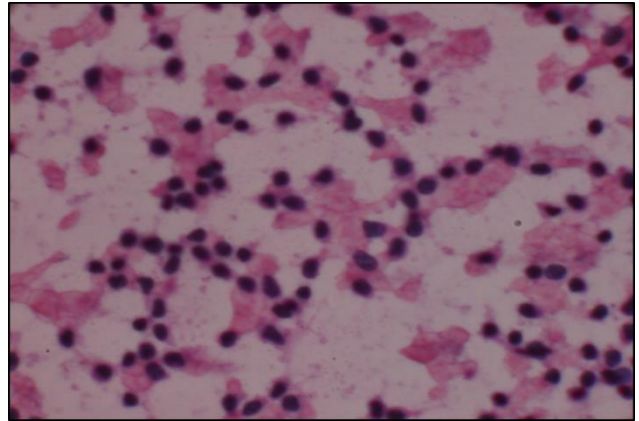


Figure 9: Lymphoproliferative disorder (NHL): Highly cellular smear showing a monomorphic population of lymphoid cells against a background of necrotic material PAP x 400.

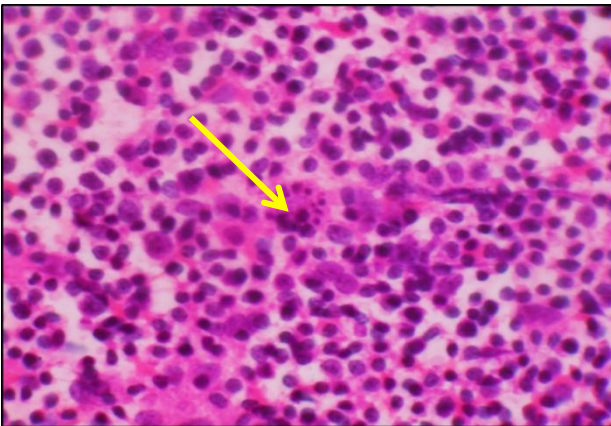


Figure 7: Reactive lymph node hyperplasia: Smear showing a polymorphous population of lymphoid cells and a tingible body macrophage (arrow) H and E x 400.

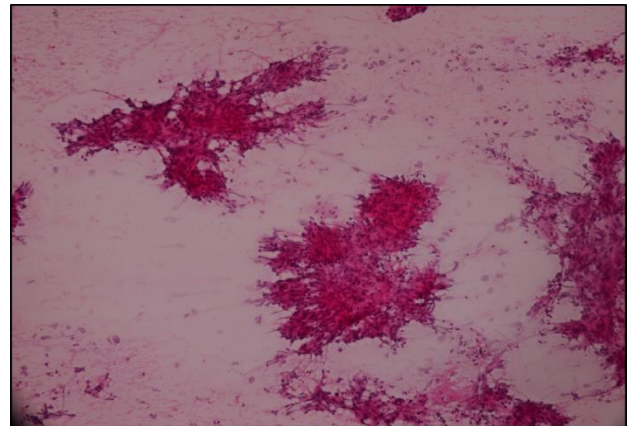


Figure 10: Metastatic deposits of a papillary carcinoma. Smear showing malignant cells in well - formed papillary structures against a background of a few lymphoid cells H and E x 100.

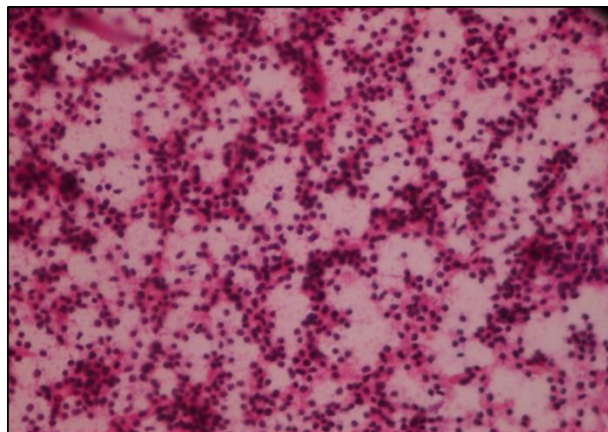


Figure 8: Lymphoproliferative disorder (NHL): Highly cellular smear showing a monomorphic population of lymphoid cells against a background of necrotic material PAP x 100.

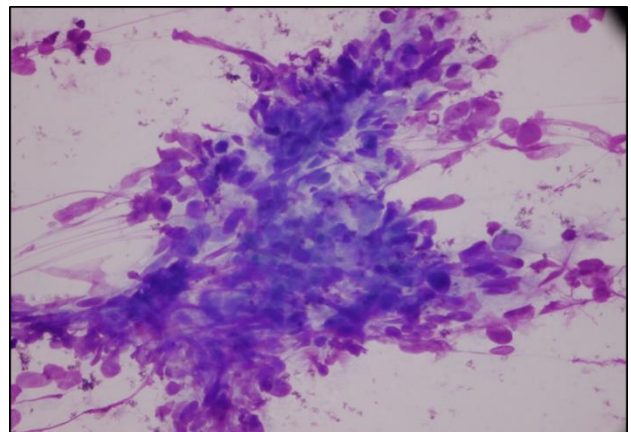


Figure 11: Metastatic deposits of a papillary carcinoma. Smear showing malignant cells in well - formed papillary structures against a background of a few lymphoid cells Giemsa x 400.

DISCUSSION

FNAC is a valuable diagnostic tool for establishing a diagnosis in cases of superficial lymphadenopathy.¹ The use of this technique has limited the need for excision of enlarged lymph nodes, especially in cases of reactive and tubercular lymphadenitis. However grey areas still exist in the establishment of an exact diagnosis especially in the case of primary lymphoproliferative disorders, where distinguishing low grade non - Hodgkin's lymphoma from a reactive hyperplasia may pose a diagnostic conundrum even in experienced hands.^{5,6}

In this series of cases, reactive lymph node hyperplasia was the most common diagnosis. Similar findings were noted by Shrivastav A et al, Mohanty R et al and Pandey P et al.⁷⁻⁹ This is in contrast to the series of Shah et al where tubercular lymphadenitis was the most common diagnosis.² In this series granulomatous lymphadenitis was the second most common diagnosis offered; in the series of Kumar H et al and Shilpa G et al, reactive lymph node hyperplasia was the second most common diagnosis.¹⁰⁻¹² The relative frequency of pathologies varies with the type of hospital and the demographics of the dependent population.^{13,14}

In this study there was a preponderance of female patients (61%) in contrast to other studies where male preponderance was noted.^{1,15-17} No reason for this difference can be ascribed.

Metastatic deposits in the enlarged lymph nodes were diagnosed in 11 cases (4.34%). Among the metastatic lesions diagnosed, metastatic adenocarcinoma was the most common microscopic variant seen. A similar finding was reported by Ghartimagar D et al.¹⁸ Other series showed a higher incidence of squamous cell carcinoma.^{2,13,14} There was no significantly higher incidence of any particular microscopic variant amongst the metastatic deposits reported in our study.

Lymphoproliferative disorders were diagnosed in only 4 out of 253 aspirates (1.6%), and formed a very small percentage of the total pathologies reported, a finding which correlates with other studies.^{2,7,11} Dowerah S et al, however, reported an incidence of 10.6% cases of lymphomas in their series. Study diagnosed three cases as non - Hodgkin's lymphoma and one case as Hodgkin's lymphoma. Excision biopsy of the affected lymph node was done in one case of non - Hodgkin's lymphoma and histopathological evaluation of the excised node confirmed the diagnosis.

Other pathologies in our series were acute suppurative lymphadenitis and necrotic lymphadenitis which were found in 11 (4.34%) and 3 (1.1%) aspirates respectively. Shah et al reported 30 cases of acute lymphadenitis in their series of 555 aspirates analyzed (5.4%) which is similar to our findings.²

CONCLUSION

FNAC is a convenient, relatively non - traumatic and speedy (TAT < 2 hours) method of diagnosing the underlying pathology in cases of superficial enlarged lymph nodes. We found that the majority of patients had reactive lymph node hyperplasia in our series; granulomatous lymphadenitis was the second most common pathology. Metastatic deposits constituted 4.34% of the pathologies; acute suppurative lymphadenitis, lymphoproliferative disorders and necrotic lymphadenitis were the other diagnoses given on FNAC evaluation of the superficial lymph nodes in our series. FNAC continues to be an important diagnostic tool in the evaluation of superficial lymph nodes.

Funding: No funding sources

Conflict of interest: None declared

Ethical approval: Not Required

REFERENCES

1. Malaker D, Jajoo ILN, Swarup K, Gupta OP, Jain AP, Poflee VW. A clinical evaluation of fine Needle aspiration cytology in the diagnosis of lymphadenopathy. *Ind J Tub.* 1991:17-9.
2. Shah PC, Patel CB, Bhagat V, Modi H. Evaluation of peripheral lymphadenopathy by fine needle aspiration cytology; a one year study at a tertiary centre. *Int J Res Med Sci.* 2016;4(1):120-5.
3. Wilkinson AR, Mahore SD, Maimoon SA. FNAC in the diagnosis of lymph node malignancies. A simple and sensitive tool. *Indian J Med Pediatr Oncol.* 2012;33(1):21-4.
4. Kumar N, Gupta BB, Sharma B, Kaushal M, Rewari BB, Sundriyal D. Role of fine needle aspiration cytology in human immunodeficiency virus - associated lymphadenopathy: a cross - sectional study from Northern India. *Hong Kong Med J.* 2015;21(1):39-44.
5. Arif SH, Hassan MJ, Jain M, Verma AK, Naim M. Role of imprint cytology in diagnosis of lymph node lesions. *Indian Medical Gazette.* 2011:385-90.
6. Stewart CJR, Duncan JA, Farquharson M, Richmond J. Fine needle aspiration diagnosis of malignant lymphomas and reactive lymphoid hyperplasia. *J Clin Pathol.* 1998;51:197-203.
7. Shrivastav A, Shah HA, Agarwal NM, Santwani PM, Srivastava G. Evaluation of peripheral lymphadenopathy by fine needle aspiration cytology. A three year study at tertiary center. *Journal of Dr NTR University of Health Sciences.* 2014;3(2):86-91.
8. Mohanty R, Wilkinson A. Utility of fine needle aspiration cytology of lymph nodes. *IOSR J Dent Med Sci.* 2013;8(5):13-8.
9. Pandey P, Dixit A, Mahajan NC. The diagnostic value of FNAC in assessment of superficial palpable lymph nodes: a study of 395 cases. *Al Ameen J Med Sci.* 2013;6(4):320-7.

10. Kumar H, Chandanwale SS, Gore CR, Buch AC, Satav VH, Pagaro PM. Role of fine needle aspiration cytology in assessment of cervical lymphadenopathy. *Med J Dr DY Patil University.* 2013;6(4):400-4.
11. Shilpa G, Nataraju G. Pattern of lymph node diseases in a tertiary level referral center: a cytological study of 943 cases. *Inter Biol Med Res.* 2013;4(3):3448-52.
12. Wahid FI, Rehman H, Khan Q. Diagnostic value of fine needle aspiration cytology in diagnosis of non - thyroidal neck mass. *JPMI.* 2010;224(4):289-94.
13. Mamatha K, Arakuru SU. Clinicocytological study in evaluating the primary site of tumor in patients presenting with metastatic tumors in lymph nodes. *Asian J Pharma Health Sci.* 2014;4(2):1001-5.
14. Mohan A, Thakral R, Kaur S, Singh S. Fine needle aspiration in metastatic lymphadenopathy - a five year experience in Muzzafarnagar region. *J Adv Res Biol Sci.* 2013;5(2):172-6.
15. Kumar N, Gupta BB, Sharma B, Kaushal M, Rewari BB, Sundriyal D. Role of fine needle cytology in human immune - deficiency virus - associated lymphadenopathy: a cross sectional study from northern India. *Hong Kong Med J.* 2015; 21(1): 39-44.
16. Patel MM, Italiya SL, Patel RD, Dudhat RB, Kaptan KR, Baldwa VM. Role of fine needle aspiration cytology to analyze various causes of lymphadenopathy. *Natl J Community Med.* 2013;4(3):489-92.
17. Hemalatha A, Udhay Kumar M, Harendar Kumar ML. Fine needle cytology of lymph node: a mirror in the diagnosis of lymph node lesions. *J Clin Biomed Sci.* 2011;1(4):164-72.
18. Ghartimagar D, Ghosh A, Ranabhat S, Shrestha MK, Narasimhan R, Talwar OP. Utility of fine needle aspiration cytology in metastatic lymph nodes. *J Pathol Nepal.* 2011;1:92-5.
19. Dowerah S, Kouli R, Karmakar T. A study of FNA findings of malignancy in lymph nodes with special emphasis on metastatic malignancy. *Inter J Bas Med Scie.* 2014;5(4):68-71.

Cite this article as: Duraiswami R, Margam S, Chandran P, Prakash A. Spectrum of pathologies on FNAC evaluation of peripheral lymph nodes at a tertiary care center in hyderabad: a retrospective study. *Int J Adv Med* 2017;4:27-33.