

Speech Disorders in Cerebellar Disease

Richard Lechtenberg, MD, and Sid Gilman, MD

The areas of cerebellar damage most commonly associated with dysarthria were sought by reviewing the clinical, radiographic, surgical, and autopsy findings in patients with nondegenerative cerebellar disease. Case histories on 162 patients with focal cerebellar lesions were reviewed. All but 15 of the patients underwent surgery, and 28 had autopsies. Thirty-one of the 122 patients with adequate descriptions of speech had dysarthria. Twenty-two of these 31 dysarthric patients had exclusively or predominantly left cerebellar hemisphere disease; 7 had right hemisphere disease; and 2 had vermal disease. Only 19 of 41 patients with exclusively or predominantly left hemisphere disease had had normal speech before surgery. Dysarthria developed in isolated cases following cerebellar resections extending into the paravermal segments of the left hemisphere. There was no correlation between the extent of vermal damage and development of abnormal speech. Cerebellar speech function was most commonly affected with damage to the superior portion of the left cerebellar hemisphere.

Lechtenberg R, Gilman S: Speech disorders in cerebellar disease. *Ann Neurol* 3:285-290, 1978

Dysarthria has been described with cerebellar disease since the nineteenth century [9], but the sites responsible for the development of abnormal speech have not been defined. Mills and Weisenburg [17] introduced the notion that dysarthria results from injury to the superior cerebellar vermis. They based this impression on their experience with 1 patient who had dysarthria for more than a year prior to death in whom destruction of the superior vermis was found at autopsy. Gordon Holmes' initial report [13] of his experience in World War I with patients suffering posterior fossa wounds supported this view of the vermal origin of cerebellar speech disorders. Despite his apparent agreement with the localization of Mills and Weisenburg, Holmes provided little confirmatory evidence and, in fact, noted that lesions in the hemispheres alone were associated with dysarthria. Almost all of the 21 men he studied at length had hemispheric damage, most with multiple cerebellar lesions. Four patients had extensive cerebellar damage bilaterally, and in these patients speech was "very much disturbed." None of his patients had isolated vermal lesions, but he offered his impression that patients with hemisphere and vermal damage had more difficulty with speech than those with hemisphere lesions alone.

Since the classic reviews of cerebellar signs by Gordon Holmes [13, 14], his localization of speech function to the vermis has been questioned rarely. Brown [7] included dysarthria as a characteristic of two of his cerebellar syndromes, that with bilateral hemisphere

damage and that with generalized damage. He gave no special status to the midline cerebellar structures in speech. Dow and Moruzzi [10] reiterated Holmes' view in their discussion of cerebellar pathology, but they noted, as had Holmes, that disease of the hemispheres could disturb speech. In a review of more than 250 patients with cerebellar tumors studied prior to surgery, Amici, Avanzini, and Pacini [4] found the highest incidence of dysarthria with lesions in the paravermal and lateral elements of the hemispheres. Disordered speech was notably uncommon with vermal destruction.

The low probability of recognizing and studying a patient with a cerebellar lesion before much of the cerebellum is involved probably accounts for the inconsistencies in many of the early studies. In addition, little attention was given to the locations of lesions associated with dysarthria, especially with reference to the side of the damage. Recent advances in diagnostic techniques, particularly in radiographic procedures, have increased the likelihood of finding patients with small cerebellar lesions. Accordingly, we sought to determine what areas of damage in the cerebellum are most commonly associated with disordered speech. We reviewed the case histories of 162 patients with nondegenerative cerebellar disease evaluated over the past 30 years.

Methods and Materials

Cases were collected from autopsy files, hospital admission lists, neurosurgical procedure records, brain biopsy reports,

From the Departments of Neurology, Downstate Medical Center, Brooklyn, NY, and the University of Michigan Medical Center, Ann Arbor, MI.

Accepted for publication Nov 2, 1977.

Address reprint requests to Dr Lechtenberg, Box 35, Department of Neurology, Downstate Medical Center, 450 Clarkson Ave, Brooklyn, NY 11203.

and personal consultations. Autopsy information was retrieved on patients catalogued as having focal cerebellar disease. The pathologists' original description of the central nervous system lesions and color slides of the original cerebellar slices were reviewed. Biopsy files provided the largest proportion of the patients, but almost all the patients in this group had tumors. A more diverse group was obtained by reviewing records of patients with cerebellar disease as an admitting diagnosis, filed with the chief of the neurology service or the admitting office. Sixteen patients were seen by one of us at some time in their course. Disorders included tumor, infarction, hemorrhage, abscess, granuloma, and vascular malformation (Table 1). Autopsy material was available on 28 patients, 18 of whom had had prior surgery. Surgery on 147 of the patients provided descriptions of the cerebellum, including notations on the appearance and firmness of grossly uninvolved structures. Bilateral occipital craniectomy was the standard operation done in all but 6 cases; hemisuboccipital craniotomy and transaural procedures accounted for the remaining cases. The usual surgical technique involved sampling cerebellar tissue for histological examination at the margins of the visible lesion. When a lesion such as a tumor was suspected of extending into the vermis, the vermis was biopsied and frequently divided.

Localization of damage was assisted in almost all cases by radiographic procedures. Sixty-five patients were investigated with computerized tomography, and all but 4 of them underwent subsequent surgery or autopsy. Angiography alone defined the areas involved by a vascular malformation in 1 case.

We considered a patient dysarthric if the speech was described as abnormal and the abnormality was consistent with a cerebellar disturbance as outlined by Brown, Darley, and Aronson [8]. Specific mention of slurred speech, scanning speech, or an abnormal rhythm was sought in the

record and in discussions with physicians who cared for the patients. Slowing of speech was not considered adequate grounds for designating a patient dysarthric. Other attributes such as hoarseness, monotony, variability of volume, elevation of pitch, or hesitancy of speech were noted in a few records, but these were accepted as indicative of a cerebellar disturbance only when mentioned in association with more common signs of cerebellar speech disturbance. Thirty-six cases were excluded because the descriptions were absent, inadequate, or ambiguous, or because speech was described postoperatively but not preoperatively. Whether a patient had normal or dysarthric speech was determined before surgical or radiation treatment. Three patients who had abnormal speech on admission for cerebellar lesions also were excluded from the series because, according to the histories available, speech had not changed in character with the onset of other symptoms of cerebellar disease. The only other patient excluded had a coincident expressive aphasia. With these 4 additional cases, a total of 40 of the 162 cases reviewed were eliminated from the study.

Using all descriptive material available, we defined the extent of the cerebellar involvement. The cerebellum was divided into three major regions: the left hemisphere, the right hemisphere, and the vermis. Each of these regions was subdivided into superior and inferior elements, centering about Larsell's lobule VII. Further differentiation between involvement of medial, lateral, anterior, and posterior segments of each region was attempted when the available descriptions were adequate. Descriptions from operative notes rarely established more than the region predominantly involved and the regions secondarily involved. A lesion was considered to be limited exclusively to one of the three major regions if damage in the remaining two regions, discounting distortion from mass effect, was inapparent at a gross level. When damage extended beyond a hemisphere

Table 1. Diagnoses in 162 Patients According to Location of Major Extent of Disease and Incidence of Dysarthria before Treatment

Diagnosis	Left Hemisphere		Right Hemisphere		Vermis	
	Total	Dysarthric	Total	Dysarthric	Total	Dysarthric
Metastatic carcinoma	19	5	26	2	5	1
Astrocytoma	17	5	8	0	15	1
Medulloblastoma	5	2	4	1	14	0
Schwannoma	5	1	1	0	0	0
Meningioma	1	0	4	0	0	0
Ependymoma	0	0	0	0	2	0
Hemangioblastoma	1	0	4	1	1	0
Other tumors (undifferentiated or rare)	3	2	1	1	5	0
Infarction	3	3	3	2	0	0
Hemorrhage	3	2	6	0	1	0
Abscess	1	1	2	0	0	0
Granuloma	0	0	0	0	1	0
Vascular malformation	1	1	0	0	0	0
Total	59 (41)	22	59 (47)	7	44 (34)	2

Numbers in parentheses are patients for whom speech was adequately described.

or the vermis, a distinction was made between the region predominantly involved and that less involved.

Results

Thirty-one patients had disease exclusively in the left cerebellar hemisphere; 40, exclusively in the right; and 25, exclusively in the vermis; 10 patients had disease predominantly in the left cerebellar hemisphere; 7, predominantly in the right; and 9, predominantly in the vermis.

Dysarthria occurred in 31 patients before surgical or radiation therapy; 22 of them (71%) had disease exclusively or predominantly in the left cerebellar hemisphere, 7 (23%) in the right hemisphere, and 2 (6%) in the vermis. Tumors, infarctions, hemorrhages, an abscess, and the vascular malformation were all found in association with disordered speech. Patients with cerebellar hemorrhage commonly lapsed into coma too rapidly for adequate assessment of speech. Autopsies were obtained on 28 patients, 13 of whom had had dysarthria at some time in their course. Ten of the 13 had exclusive or predominant involvement of the left hemisphere with dysarthria evident before surgery; 1 had exclusive involvement of the left hemisphere with dysarthria noted only after operation. The other 2 dysarthric patients autopsied had predominantly right hemisphere disease with abnormal speech after surgery in 1 case and exclusively right hemisphere damage with dysarthria preoperatively in 1 case. The latter patient was left-handed. In the 18 cases in which radiographic procedures, surgical exploration, and autopsy examination were all performed, there was close agreement between the postmortem descriptions of cerebellar destruction and the premortem impressions of the sites of destructive lesions.

Of the 22 patients with left hemisphere disease and abnormal speech before treatment, 15 had exclusively left-sided disease, 2 had extension to the vermis, 1 had disease involving the right hemisphere, and 4 had involvement of both the right hemisphere and the vermis. Autopsies were obtained on 16 patients with lesions extending into the left hemisphere. Thirteen of these 16 had disease exclusively or predominantly in the left hemisphere, and 3 had encroachment from lesions in the right hemisphere or vermis. Twelve of the 16 patients with left hemisphere damage had dysarthria at some time in their course. Only 19 of the 41 patients with major left hemisphere destruction had had normal speech prior to surgery. These cases included 16 patients with lesions exclusively in the left hemisphere, 2 with extension to the vermis, and 1 with involvement of both the vermis and the right hemisphere. Two of these patients developed dysarthria shortly after surgery.

Among the 18 patients with left-sided disease who

were excluded from the analysis, there were 2 with abnormal speech allegedly antedating the onset of their cerebellar damage and 3 others with speech noted to be abnormal but without adequate description of the abnormality. Two additional patients with no descriptions of speech before surgery were noted by several observers to have slurred and scanning speech after resection of exclusively left hemisphere lesions. Considering only the adequately described cases, 22 of 41 patients (54%) with predominantly or exclusively left hemisphere disease had had disordered speech prior to operation (see Table 1).

In 13 patients with left hemisphere disease and dysarthria, there was adequate information to establish whether superior, inferior, or both segments of the hemispheres were damaged. The only area of damage common to all 13 of these patients was the superior portion of the left hemisphere (Figure).

Only 10 of the 122 patients analyzed were known to be left-handed. Three of these 10 had left cerebellar hemisphere disease. Two had normal speech and 1 was dysarthric (Table 2).

Seven patients with exclusively or predominantly right hemisphere disease developed dysarthria before surgical or radiation therapy. The lesions in 2 of these patients were delimited by computerized tomography alone. Both were infarcts and the lesions could not be confidently limited to the right hemisphere, but in the absence of additional information they were considered exclusively right hemisphere lesions. Three additional cases of disordered speech associated with right hemisphere disease involved tumors extending beyond the limits of the resection. Demonstration of tumor boundaries was lacking. The remaining 2 dysarthric patients had tumors; 1 of these patients with exclusively right hemisphere destruction involving the superior aspect of that hemisphere was left-handed.

All but 6 of the 40 patients with right hemisphere

Superior aspect of the cerebellum. Diagonal lines indicate the area most commonly damaged in patients with dysarthria.

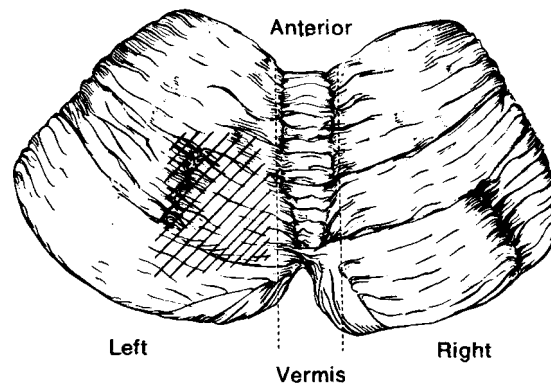


Table 2. Incidence of Left-Handedness According to Site of Major Lesion and Speech Function

Site of Lesion	No. of Patients	Speech	
		Dysarthric	Normal
Left hemisphere	3	1	2
Right hemisphere	5	1	4
Vermis	2	0	2

disease and normal speech had exclusively right hemisphere disease. Four of these 6 patients had lesions extending into the vermis and 2 had extension into the left hemisphere and the vermis. Two patients with normal speech prior to surgical treatment developed abnormal speech shortly after operation. In both cases the resections extended into the medial portion of the left hemisphere. Five patients were left-handed and had right hemisphere disease. Four of these 5 had normal speech.

Dysarthria occurred in only 2 of the 25 patients with exclusively vermal disease and in none of the 9 patients with predominantly vermal disease. Both dysarthric patients had large tumors of the vermis, with deformity of the medial aspects of both hemispheres described at surgery. One of these patients had normal speech documented by several examiners within a few days of surgery. Three additional patients had disordered speech immediately after surgery, and each of these had superior vermal tumors which were removed with wide resections extending into the medial portions of the hemispheres. The remaining patients with normal speech and predominantly vermal disease had damage to the left hemisphere in 4 cases, the right hemisphere in 2, and both hemispheres in 3. Twelve patients had tumors largely replacing the vermis, and all but 2 of them had normal speech. The vermis was split entirely or partially in 26 cases as part of the surgical resection or as a maneuver to explore the fourth ventricle. Surgical injury to the vermis was not followed by disordered speech except in 3 patients who had resections extending into the medial hemispheres.

Chi-square analysis of the distribution of the dysarthric cases indicated a highly significant ($p < 0.001$) difference between the left hemisphere group and both the right hemisphere and vermal groups. This level of significance persisted with a continuity correction included in the analysis. There was no significant difference in the incidence of dysarthria in the right hemisphere and vermal groups, even without application of a continuity correction. Statistical analysis supported the impression that a significant association existed between left cerebellar hemisphere disease and dysarthria.

Left hemisphere involvement was also characteris-

tic of patients with initially normal speech who developed dysarthria while under observation. The following 3 cases demonstrated this progression.

Patient 1

A 63-year-old right-handed woman had progressive difficulty with gait for six weeks before hospital admission. She developed vomiting, headache, and "confusion" but was alert on initial examination. Despite a poor fund of knowledge and recent memory impairment, she could retain six digits forward. Writing and constructions were intact. Speech was slow but otherwise normal. Her comprehension was good, but repetition was slightly impaired. The only cranial nerve deficits were a slightly widened right palpebral fissure and decreased auditory acuity in the left ear. Tandem gait and hopping were unsteady. Sensory and motor functions were intact. Although there was little evidence of dysmetria or past-pointing, she was "clumsy" on performing simple tasks. An angiogram revealed a posterior fossa mass, and on radionuclide brain scan there was uptake primarily on the right. A computerized tomogram confirmed the presence of a mass on the right side of the cerebellum. At surgical resection the mass was found in the right paravermian area 7 mm below the cortex of the right hemisphere. A tumor nodule measuring $3 \times 2.5 \times 2.5$ cm was resected and identified as metastatic carcinoma.

After surgery her symptoms resolved for seven months. Subsequently she had recurrence of gait and memory difficulties. On readmission her speech was slurred, and over the ensuing six weeks dysarthria became increasingly prominent. No aphasia was present. She died nine months after her initial admission. At autopsy the original operative site was evident in the posterior paravermal aspect of the right cerebellar hemisphere, and the underlying white matter and deep gray structures of that hemisphere were remarkably intact. Only a small residue of tumor cells was evident in the right hemisphere. Extending medially and superiorly, a mass of tumor cells coursed along the surface of the posterior vermis and invaded the paravermal segment of the midposterior left hemisphere to about the level of Larsell's lobule VI.

Patient 2

A 50-year-old woman was admitted for evaluation of progressive obtundation. She had had several years' history of recurrent osteomyelitis of the left petrous pyramid that had necessitated surgical intervention on at least one prior occasion. After initial improvement in the hospital on antibiotics, she developed increasing stupor, left lateral rectus palsy, ataxia on finger-to-nose testing primarily on the left, and confabulation. A vertebral arteriogram revealed a 2×2 cm mass near the left acoustic meatus that appeared to be extradural. On approaching this mass through the mastoid area, the surgeon encountered a small abscess immediately subdurally on the anterior aspect of the left hemisphere.

Postoperatively the patient was more alert, but ten days after surgery she was noted to be dysarthric. Her speech was nasal, but clinical examination of the palate and of larynx function failed to reveal any abnormality to account for the

alteration in voice. Phonation became more impaired, and concern that medullary compression might account for the dysarthria prompted another vertebral study. A mass in the area of the prior operation was suspected, and consequently she was reexplored. The old abscess cavity was reentered but no abnormality was found. The exit zones of cranial nerves IX and X were inspected, and here too no disease was found. A suspicious area on the anterior aspect of the left cerebellar hemisphere led to probing of this structure medial to the site of the old subdural abscess, and a large collection of necrotic tissue was encountered. The abscess in the medial segment of the left hemisphere was evacuated, and postoperatively the patient's speech improved.

Patient 3

A 22-year-old right-handed man complained of double vision, most marked on leftward gaze, for one year prior to his admission. Clinical examination revealed no visual disorder or other neurological deficits. A large midline cerebellar mass appeared on computerized tomography, and at surgery a cystic astrocytoma was found in the superior vermis. The tumor was excised, and resection about the margins of the tumor was continued into the medial aspects of both hemispheres. The only cranial nerve disturbance evident after surgery was transient weakness of the muscles innervated by the right III and left IV cranial nerves. Soon after recovering from anesthesia, the patient was noted to have abnormal speech. At first this was characterized as "reticence" and "poor phonation," but within a few days it was evident that he had slow, slurred speech. Additional deficits included dysmetria and past-pointing, primarily in the left arm and, to a lesser extent, in the left leg. A speech therapist described the patient's deficits six weeks after surgery as including decreased prosody, run-on phrases, and decreased vocal variety. In addition to some hoarseness, the patient's speech volume trailed off to a whisper as he spoke. These deficits persisted over the next two months. During this time samples of the patient's writing revealed marked deterioration of his signature and constructions, although his coordination deficits on clinical examination were all on the left.

Discussion

This study strongly implicated the left cerebellar hemisphere in the development of dysarthria. Fifty-four percent (22) of the 41 patients with exclusively or predominantly left hemisphere disease had had disordered speech prior to surgery, a strikingly higher incidence than the 15% of patients (7 of 47) with right hemisphere disease and the 6% (2 of 34) with vermal disease who had dysarthria. The development of dysarthria after surgical resections involving the medial portion of the left hemisphere, whether the initial lesion was on the left, the right, or the vermis, supports the role of the left hemisphere in speech disorders. The extent of cerebellar damage had no evident relation to the development of dysarthria. There was no correlation between the occurrence of vermal damage and the development of abnormal speech. Tumors most commonly caused the damage in dysarthric pa-

tients, but this was in proportion to their incidence in the population studied.

The effect of left-handedness on speech lateralization in the cerebellum can only be speculated upon. The finding of a well-documented superomedial right cerebellar hemisphere tumor in a left-handed man with dysarthria as a major symptom of his disease conforms well to the notion that lateralization of speech function is reversed. There were too few left-handed patients in this series to draw conclusions, but the finding of normal speech in 2 left-handed patients with left hemisphere damage and abnormal speech in 1 with right hemisphere disease would be explicable if dominance were reversed in these patients.

Past studies may well have reflected the importance of the left cerebellar hemisphere in dysarthria, but there has been no systematic attempt to relate the side of the lesion to the development of dysarthria. In a review of patients with cerebellar hemorrhages, Fisher et al [11] found specific mention of dysarthria in the records of 7 out of 21 patients reported on. They considered this incidence of abnormal speech to be an underestimate because of lapses in documentation, but compared to other series [15, 20, 21] this was a remarkably high incidence. The major site of bleeding in 11 of 18 patients for whom the site was known was on the left. This predominance of left hemisphere lesions might have been responsible for the high incidence of dysarthria (33%). Abnormal speech was found in 8 of 9 patients with cerebellar hemorrhages in a series of 12 cases [6], but all patients described had rapidly evolving hemorrhages with multiple cranial nerve deficits characteristically present.

In another instance in which a predominance of left hemisphere lesions coincided with the appearance of dysarthria, Sybert and Alvord [24] found disordered speech in 14 of 21 patients with cerebellar infarctions. The sample of 28 patients they drew upon included 19 cases of left-sided disease.

It is not surprising that a cerebellar function should be asymmetrically distributed between the hemispheres. Cerebral cortical functions, especially those dealing with speech, have long been recognized as unequally represented in the cerebral hemispheres [12], and massive anatomical connections between individual cerebellar and cerebral hemispheres have been well demonstrated [2]. Moreover, studies of auditory evoked potentials in the cerebellar vermis of cats have shown asymmetries in responsiveness to monaural stimulation [3]. Neither ear was consistently dominant, but in individual animals inputs to one ear evoked cerebellar potentials significantly more readily than inputs to the other ear. Whether this resulted from processing of signals en route to the cerebellum or within the cerebellum is unclear but of less consequence than the demonstration of asymmetry in func-

tion, even in the midline portion of the cerebellum.

That speech, a phylogenetically recent acquisition, is represented in the cerebellar hemisphere rather than the vermis concurs with the classic view of the vermis as a phylogenetically more ancient structure [22]. Early experiments on retrograde stimulation of the superior laryngeal nerve with cerebellar recordings of evoked potentials showed four paravermal sites of evoked activity in the experimental animals [16]. Processing of sound occurs in the paravermal segments of the hemispheres [18], and the lobules with the highest reactivity to auditory stimuli coincide with the areas implicated in our study of dysarthria-related sites, Larsell's lobules VI and VII. Interspecies comparisons are, of course, not always valid, but if speech and hearing have the same close relationship in the cerebellum as in the cerebrum, sites of auditory evoked potentials should approximate areas subserving speech.

Left cerebral hemisphere dominance for speech functions in right-handed individuals suggested the right cerebellar hemisphere as the most likely site for cerebellar speech function since cerebrocerebellar connections are predominantly contralateral [2]. A left cerebellar locus affecting speech would be expected to communicate primarily with the right cortex. Since the major components of cerebellar dysarthria relate to prosody [8, 25], it may be that this more harmonic than sequential function of speech would best be served by mechanisms with access to the right cerebral hemisphere. Appreciation of melody, rather than the symbolic meaning of sounds, appears to be a function of the nondominant hemisphere [23] except in professional musicians [5]. Aphasic patients regained significant verbal ability when melodic intonation of phrases was used [1], a finding which further implicates the nondominant hemisphere in harmonic aspects of speech.

It is generally accepted that the nondominant cerebral hemisphere plays a substantial role in processing nonverbal auditory stimuli [19]. A cerebellar locus for adjusting the melody and continuity of speech might rely on this cerebral hemisphere for monitoring speech character without reference to its content. This study has not excluded other sites in the cerebellum as important in normal speech. It does suggest that there is lateralization of function—at least with regard to speech—similar to that seen in the cerebral cortex. Dominance of the left cerebellar hemisphere in the regulation of speech may derive from access of this hemisphere to the nondominant cerebral hemisphere.

Dr Philip Duffy of the Neuropathology Division at Columbia-Presbyterian Medical Center provided invaluable cooperation in the collection of biopsy and autopsy material. Ms Linda Rolnitzky performed the statistical analyses and offered advice on methods of

analysis. Ms Beverly Green provided the illustration. The physicians and supporting staff of the Neurological Institute of New York, with special assistance from the Department of Neuroradiology and particularly Ms Sharon Fast, made this study possible.

References

1. Albert M, Sparks RW, Helm NA: Melodic intonation therapy for aphasia. *Arch Neurol* 29:130-131, 1973
2. Allen GI, Tsukahara N: Cerebrocerebellar communication systems. *Physiol Rev* 54:957-1006, 1974
3. Altman JA, Bechterev NN, Radionova EA, et al: Electrical responses of the auditory area of the cerebellar cortex to acoustic stimulation. *Exp Brain Res* 26:285-298, 1976
4. Amici R, Avanzini G, Pacini L: Cerebellar tumors, in *Monographs in Neural Sciences*, vol 4. Basel, Karger, 1976
5. Bever TG, Chiariello RJ: Cerebral dominance in musicians. *Science* 185:537-539, 1974
6. Brennan RW, Berglam RM: Acute cerebellar hemorrhage: analysis of clinical findings and outcome in 12 cases. *Neurology (Minneapolis)* 27:527-532, 1977
7. Brown JR: Localizing cerebellar syndromes. *JAMA* 141:518-521, 1949
8. Brown JR, Darley FL, Aronson AE: Ataxic dysarthria. *Int J Neurol* 7:302-318, 1970
9. Charcot JM: *Lectures on the Diseases of the Nervous System*. London, The New Sydenham Society, 1877, vol 72, pp 192-193
10. Dow RS, Moruzzi G: *The Physiology and Pathology of the Cerebellum*. Minneapolis, University of Minnesota Press, 1958
11. Fisher CM, Picard EH, Polak A, et al: Acute hypertensive cerebellar hemorrhage: diagnosis and surgical treatment. *J Nerv Ment Dis* 140:38-57, 1965
12. Geschwind N: Disconnexion syndromes in animals and man. *Brain* 88:237-294, 585-644, 1965
13. Holmes G: The symptoms of acute cerebellar injuries due to gunshot injuries. *Brain* 40:461-535, 1917
14. Holmes G: The Croonian lectures on the clinical symptoms of cerebellar disease and their interpretation. *Lancet* 1:1177-1182, 1231-1237; 2:59-65, 111-115, 1922
15. Keschner M, Grossman M: Cerebellar symptomatology evaluation on the basis of intracerebellar and extracerebellar lesions. *Arch Neurol Psychiatry* 19:78-94, 1928
16. Lam RL, Ogura JH: An afferent representation of the larynx in the cerebellum. *Laryngoscope* 62:486-495, 1952
17. Mills CK, Weisenburg TH: Cerebellar symptoms and cerebellar localization. *JAMA* 63:1813-1818, 1914
18. Mortimer JA: Cerebellar responses to teleceptive stimuli in alert monkeys. *Brain Res* 83:369-390, 1975
19. Oscar-Berman M, Goodglass H, Donnenfeld H: Dichotic ear-order effects with non-verbal stimuli. *Cortex* 10:270-277, 1974
20. Ott KH, Kase CS, Ojemann RG, et al: Cerebellar hemorrhage: diagnosis and treatment. *Arch Neurol* 31:160-167, 1974
21. Rey-Bellet J: Cerebellar hemorrhage: a clinicopathologic study. *Neurology (Minneapolis)* 10:217-222, 1960
22. Sarnat HB, Netsky MG: *Evolution of the Nervous System*. New York, Oxford University Press, 1974
23. Shankweiler D: Effects of temporal lobe lesions on recognition of dichotically presented melodies. *J Comp Physiol Psychol* 62:115-119, 1966
24. Sybert GW, Alvord AC: Cerebellar infarction: a clinicopathological study. *Arch Neurol* 32:357-363, 1975
25. Zentay PJ: Motor disorders of the nervous system and their significance for speech: I. Cerebral and cerebellar dysarthrias. *Laryngoscope* 47:147-156, 1937