

Sperm transport in the human female genital tract and its modulation by oxytocin as assessed by hysterosalpingoscintigraphy, hystero-tonography, electrohysterography and Doppler sonography

L.Wildt^{1,4}, S.Kissler¹, P.Licht¹ and W.Becker^{2,3}

¹ Division of Gynecological Endocrinology & Reproductive Medicine, Department of Obstetrics and Gynecology, and

²Department of Nuclear Medicine, University of Erlangen, 91054 Erlangen, Germany and ³Present address: Department of Nuclear Medicine, University of Göttingen, Göttingen, Germany

TABLE OF CONTENTS

Introduction	656
Fallopian tube function in infertile patients	656
Particle distribution in the uterus	658
Measurement of intrauterine pressure	660
Normal and disturbed function of the uterus and Fallopian tubes	661
Acknowledgements	665
References	665

The transport function of the uterus and oviducts and its modulation by oxytocin has been examined using hysterosalpingoscintigraphy, recording of intrauterine pressure, electrohysterography and Doppler sonography of the Fallopian tubes. After application to the posterior vaginal fornix, a rapid (within minutes) uptake of the labelled particles into the uterus was observed during the follicular and during the luteal phase of the cycle in all patients. Transport into the oviducts, however, could only be demonstrated during the follicular phase. Transport was directed predominantly into the tube ipsilateral to the ovary bearing the dominant follicle; the contralateral oviduct appeared to be functionally closed. The proportion of patients exhibiting ipsilateral transport did increase concomitant with the increase of the diameter of the dominant follicle. That ipsilateral transport has biological significance is suggested by the observation that the pregnancy rate following spontaneous intercourse or insemination was significantly higher in those women in whom ipsilateral transport could be demonstrated than in those who failed to exhibit lateralization. Oxytocin

administration was followed by a dramatic increase in the amount of material transported to the ipsilateral tube, as demonstrated by radionuclide imaging and by Doppler sonography following instillation of ultrasound contrast medium. Continuous recording of intrauterine pressure before and after oxytocin administration did show an increase in basal tonus and amplitude of contractions and a reversal of the pressure gradient from a fundus–cervical to a cervico–fundal direction. These actions of oxytocin were accompanied by an increase in amplitude of potentials recorded by electrohysterography. These data support the view that uterus and Fallopian tubes represent a functional unit that is acting as a peristaltic pump and that the increasing activity of this pump during the follicular phase of the menstrual cycle is reflected by an increased transport into the oviduct ipsilateral to the ovary bearing the dominant follicle. In addition, they strongly suggest a critical role of oxytocin in this process. Failure of this mechanism appears to be a cause of subfertility or infertility, as indicated by the low pregnancy rate following intrauterine insemination or normal intercourse in the presence of patent Fallopian tubes. It may be regarded as a new nosological entity for which we propose the term tubal transport disorder (TTD). Since pregnancy rate of such patients is normal when treated with in-vitro fertilization (IVF), hysterosalpingoscintigraphy seems to be useful for the choice of treatment modalities in patients with patent Fallopian tubes suffering from infertility.

Key words: Doppler sonography/electrohysterography/hysterosalpingoscintigraphy/hystero-tonography/oxytocin

⁴To whom correspondence should be addressed

Introduction

Transport of spermatozoa from the vagina to the site of fertilization in the pars ampullaris of the Fallopian tube represents one of the critical steps in the process of reproduction. Mechanical patency, as well as functional integrity, of the uterus and the oviducts are required for its successful completion (Harper, 1994; Pulkkinen, 1995). The procedures widely in use for clinical evaluation of uterus and oviduct, e.g. hysterosalpingography (HSG), laparoscopy with chromopertubation (LSCP) and hystero-ultrasonography (HSU), are based on the infusion of liquid media into the uterus, using pressure to force their passage through the Fallopian tubes into the abdominal cavity and, hence, mainly assess mechanical patency (Adelusi *et al.*, 1995; Karande *et al.*, 1995). That mechanical patency does not necessarily mean functional integrity has rarely been appreciated. Development and clinical application of methods for the assessment of functional aspects of the genital tract with regard to transport processes have, therefore, received little attention up to now (Lang, 1991). This negligence may have been caused by the unavailability of appropriate diagnostic tools for evaluation of transport mechanisms, but may also reflect our lack of understanding of the physiology and physiopathology, as well as the biological significance, of transport function in contrast to mechanical patency of the female genital tract. Here we present the results of studies designed to characterize some aspects of the function of transport mechanisms of the uterus and the Fallopian tubes using hysterosalpingoscintigraphy (HSS) extended by biophysical and pharmacological methods that offer some new insights into the physiopathology of the female genital tract. In addition, we provide evidence that tubal transport disorders (TTD) may represent a hitherto unrecognized cause of infertility in a substantial number of women that can be diagnosed by HSS.

Fallopian tube function in infertile patients

Data were collected from 580 women, aged 20–46 years, suffering from primary or secondary infertility of various origin in whom HSS was performed, in addition to other procedures, to evaluate uterine and Fallopian tube function. Informed consent was given to this and to the additional diagnostic procedures described below.

For intrauterine application of contrast medium, 6 or 8 gauge urinary silastic catheters fitted with an inflatable balloon, were purchased from Uromed Kurt Drews GmbH (Oststeinbeck, Germany). Cephalic electrodes for preparing the recording electrodes for electrohysterography were from Hewlett Packard Medical Products Group (Waltham, MA, USA). Silastic tubing, polyethylene tubing and teflon

tubing was obtained from Reichelt Chemietechnik (Heidelberg, Germany).

Follicular development was monitored by ultrasonography on a Siemens Sonoline AC and a Siemens Versa Pro ultrasound apparatus (Siemens AG, Erlangen, Germany), both equipped with 5.0–7.5 MHz vaginal probes. A dominant follicle was defined as a follicle with a diameter of >10 mm. Luteinizing hormone (LH), oestradiol and progesterone concentrations were determined in blood samples collected once daily beginning on day 10 of the cycle using commercially-available immunoassays (Boehringer Mannheim, Mannheim, Germany). The luteal phase was assessed by the determination of progesterone in blood samples taken 2–5 days apart during 2 weeks after the beginning of the LH surge until the onset of menstruation.

Hysterosalpingoscintigraphy (HSS)

HSS was performed in the follicular phase of the cycle in 570 patients. A total of 10 patients were examined inadvertently during the early to mid-luteal phase. On the day of examination, the largest follicle was identified by ultrasonography and its localization (left or right ovary) and diameter were determined. For HSS, 10 ± 2 MBq-TC-99m-labelled macroaggregates of human serum albumin (SolcoMAA; Solco Basel AG, Birsfelden, Switzerland) with a size of 5–20 μm , corresponding roughly to the size of spermatozoa, were applied in a volume of 1–2 ml via a catheter to the posterior vaginal fornix with the patient in a supine position. Scans with a γ -camera were obtained immediately after application and at various time intervals up to 4 h later, as previously described by Becker *et al.* (1988) and Steck *et al.* (1989). Data were stored on a PC and colour printouts of the scans were used for evaluation. The results were rated as: (i) radioactivity within the cavum uteri; (ii) radioactivity within the Fallopian tubes; and (iii) radioactivity within the abdominal cavity. Taking into account the findings obtained by ultrasonography, the results were further classified as: ipsilateral when radioactivity concentrated predominantly within the Fallopian tube on the side of the dominant follicle; as contralateral when radioactivity was detected predominantly in the tube opposite to the side of the dominant follicle; as bilateral when activity was found equally distributed within both tubes; and as unilateral when activity was found within one tube only, but no dominant follicle was identified by ultrasound. For topographical identification, a small mark was set on the skin between pubic symphysis and the umbilicus.

Validation of HSS

To ascertain that the labelled material had remained in an intrauterine or intratubal position, a bladder catheter was

placed into the uterus in four patients after the examination was completed and flushed with 3 ml of saline. After flushing, an additional scan was made and the amount of radioactivity present in the region of the uterus was determined and compared with that in the abdominal cavity. Fluid from the Pouch of Douglas was collected from three patients in whom laparoscopy was performed on the same day and radioactivity was counted in a well-type γ -counter. The fluid was divided into two aliquots; the first aliquot (0.5 ml) was mixed with 3 ml 20% trichloroacetic acid. The sample was centrifuged, the supernatant removed and the radioactivity in the precipitate was counted. The second aliquot was centrifuged, the pellet washed once with saline and counted after recentrifugation for 10 min. The pellet was examined microscopically.

Effects of oxytocin

The effects of oxytocin on transport of radiolabelled microspheres were examined in 50 patients. The first scan was performed immediately after application of the microspheres to the vagina, followed 8–10 min later by a second scan. 3 IU oxytocin (Syntocinon; Sandoz AG, Nürnberg, Germany) were then administered i.v. and two additional scans were carried out, one immediately after oxytocin injection, the second scan 8–10 min later. For quantitative evaluation, regions of interest (ROI) were placed on both sides of the uterus in the area of the Fallopian tubes and the radioactivity per unit time within these areas was recorded and plotted.

Measurement of intrauterine pressure (hysterotonography)

Intrauterine pressure was recorded in 25 patients during the follicular phase of the cycle using either a catheter fitted with two Millar microtip transducers positioned 6 cm apart or with two catheters filled with sterile water, each connected to a Gould–Statham element as pressure recorder. The catheters were made from teflon or polypropylene tubing with an outer diameter of 1 mm and fitted at the tip with a small, inflatable rubber balloon as a pressure sensor (Hugo Sachs Elektronik, March-Hugstetten, Germany). The catheters were placed into the cavum uteri with the tip of the first catheter at the fundus (position I), the tip of the second catheter was placed just behind the internal os (position II). Positioning was done under ultrasonographic control. To avoid expulsion of the catheters, they were either connected with an 8 gauge bladder catheter that could be blocked by an inflatable balloon or held in place by a wire clip attached to the cervix. Intrauterine pressure

was recorded for 10–20 min using a multichannel recorder providing in a separate channel the differential between the pressure measured at positions I and II. After recording of the baseline, oxytocin was administered either i.v. (3 IU) or as nasal spray (4 IU) and recording continued for another 10–20 min. Frequency and amplitude of contractions and the pressure gradients between the fundus and the uterine cervix were determined using calipers.

Electrohysterography

Uterine electrical activity was recorded in 20 patients. Two silver electrodes made from a cephalic electrode were used for recording. The wires were immersed repeatedly into a solution prepared by mixing 1 ml medical grade silastic adhesive with 5 ml *n*-hexan and allowed to dry at room temperature under a light stream of air for insulation. The insulating silastic layer was then removed carefully with a scalpel at a length of 2 mm from the tip of the wires. One electrode was placed into the uterine fundus, the second electrode was fixed at the external os or within the cervix; electrical potentials were measured continuously and recorded with a Biofeedback system (SOM Biofeedback, Murrhardt, Germany) connected to a computer. Data were analysed by calculating the variability from point to point and by determining the amplitude and frequency of spikes as identified by a computer program adapted from a program for detection of pulses of hormones in plasma (Merriam and Wachter, 1982).

Doppler sonography of the Fallopian tubes

To determine flow through the Fallopian tubes, Doppler sonography was performed in 30 patients who underwent HSU; details of this method will be published elsewhere. Briefly, a small volume of contrast medium (Echovist 300; Schering AG, Berlin, Germany) was infused into the uterus via a catheter until the uterine cavity and the Fallopian tubes could be visualized either by vaginal or by transvesical ultrasonography. After removal of the catheter, a pulsed Doppler beam was directed to the Fallopian tubes and to the uterine cavum. The ultrasound probe was held in place either manually or by a clamp fitted to a colposcope holder. After 2–5 min, oxytocin was administered either via nasal spray or i.v., at doses of 4 and 3 IU per application respectively, and the recording of Doppler signals was continued. The recording periods were documented on a video printer. A signal was defined as an increase to at least 10 cm/s for a duration of at least 1 s. The intensity and frequency of the signals on the printout were determined using mechanical calipers.

Hysterosalpingoscintigraphy - Classification of Results -

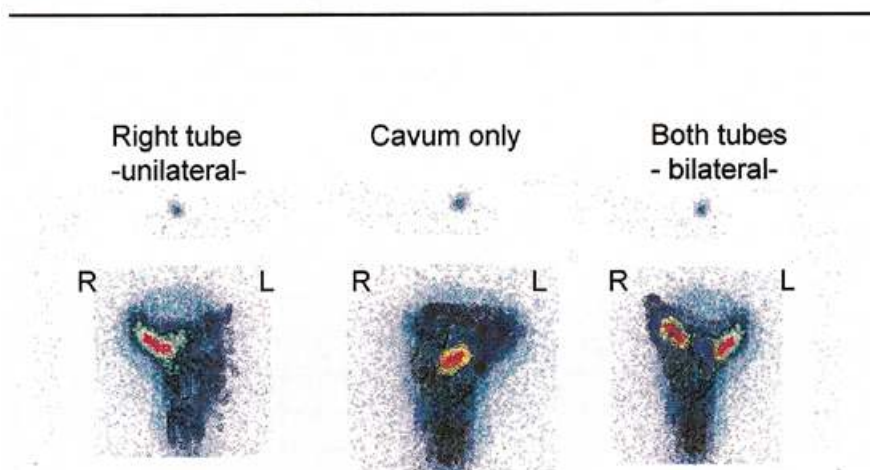


Figure 1. Typical examples of scans taken 10–20 min after application of 10–12 MBq ^{99m}Tc (radioactive Technetium)-labelled microspheres to the posterior vaginal fornix, demonstrating (from left to right) uptake into the uterus and unilateral transport to the right Fallopian tube, uptake into the uterus only and bilateral transport into the oviducts. A marker is placed at half distance between the pubic symphysis and umbilicus.

Clinical evaluation of tubal patency

For clinical evaluation of mechanical tubal patency, HSU, HSG and chromopertubation during laparoscopy were used. For HSU, a bladder catheter (Kinder-Ballon-Katheter 6 gauge; Uromed) was placed into the uterus and blocked; 2–4 ml of contrast medium for sonography (Echovist 300; Schering) was infused via the catheter into the uterus and the flow into the uterine cavity and the Fallopian tubes was monitored using vaginal sonography. HSG was performed using standardized procedures, with a Schultze apparatus applied to the cervix for instillation of contrast medium into the uterus. Chromopertubation during laparoscopy was performed by infusing a solution of Methylene Blue via a portio adapter into the uterus. Tubal patency was defined as the observation of flow into the abdomen revealed by one of these methods.

Statistical analysis

For statistical analysis, the SPSS software package version 6.1.3 was used. Analysis of variance followed by the Newman-Keuls test were used to compare means for multiple data sets. The limit of significance was set as $P \leq 0.05$. χ^2 analysis was used for testing distributions. Paired t -test was used when the effects of treatment were compared (Zar, 1984).

Particle distribution in the uterus

In all patients examined by HSS, labelled particles could be detected in the uterus at the time of the first scan as early as 2 min after intravaginal application, indicating rapid trans-

port of the microspheres from the vagina to the uterine cavity. Uptake into the uterus was observed during the follicular as well as during the luteal phase of the cycle in every patient examined. In 79% of the patients studied during the follicular phase, radioactivity did enter the Fallopian tubes either on both sides (15%) or on one side only (64%). In the remaining 21% of patients, radioactivity remained within the uterine cavity and did not migrate into the Fallopian tubes. Figure 1 shows typical examples of the scans (see also Table I). Significant radioactivity entering the pelvis was observed in 6% of patients only.

Table I. Results of hysterosalpingoscintigraphy. Values in parentheses are percentages

Uterine cavity only	Fallopian tubes	Bilateral	Unilateral	Activity within pelvis
116	434	82	352	33
(21)	(79)	(15)	(64)	(6)

In 10 patients examined accidentally during the early to mid-luteal phase of the cycle, with serum progesterone concentrations ranging from 2.5–12 ng/ml, the ascension of radioactive particles into the uterus appeared to be indistinguishable from that observed during the follicular phase. However, in none of the patients examined during the luteal phase transport into the oviducts could be observed. In addition, the pattern of distribution of radioactivity within the uterus appeared to be different from that observed during the follicular phase of the cycle: While during the follicular phase the area with the maximum of activity did

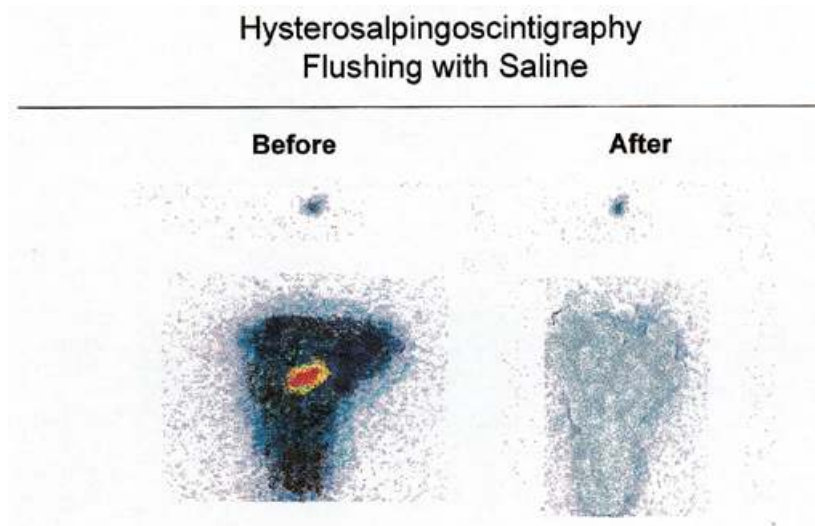


Figure 2. Scan of the uterus before and after flushing the uterine cavity with 3 ml saline via an intrauterine catheter. Most of the radioactivity has disappeared after flushing, demonstrating that it was located within the uterine cavum and not taken up by the lymphatic system. Precipitation with trichloroacetic acid indicated that the radioactivity was protein-bound.

exhibit an elongated shape, a rather broad area of radioactivity was observed during the luteal phase, as shown in Figure 2, giving the impression of a large cavum uteri.

Flushing of the uterus with a small volume of saline (~3 ml) did lead to an almost complete disappearance of radioactivity from the uterine cavity and the oviducts, as shown in Figure 3. In the fluid collected from the Pouch of Douglas >90% of radioactivity was found in the pellet after centrifugation and could be precipitated by trichloroacetic acid, indicating that most of the radioactivity was still protein-bound.

The relationship between ipsilateral or bilateral entry of radioactivity into the Fallopian tubes and the size of the dominant follicle is shown in Figure 4. With increasing diameter of the leading follicle, the frequency of ipsilateral transport of activity into the oviduct was found to increase from 10 to 75% when all patients were included into the analysis. When only those patients were considered who later became pregnant either spontaneously or after intrauterine insemination, the percentage of patients with ipsilateral transport was higher and increased from 25 to 95%.

The relationship between the asymmetrical distribution of radioactivity and the outcome of treatment of infertility is shown in Table II. The combined pregnancy rate for spontaneous pregnancies and pregnancies after timed intercourse or intrauterine insemination in women in whom radioactivity did enter the oviducts was 18%, in those exhibiting ipsilateral transport the rate was 24%. In contrast, the pregnancy rate in those women in whom no entry of radioactivity into the tubes was found, was only 6% ($P < 0.05$). When in-vitro fertilization (IVF) was performed, in

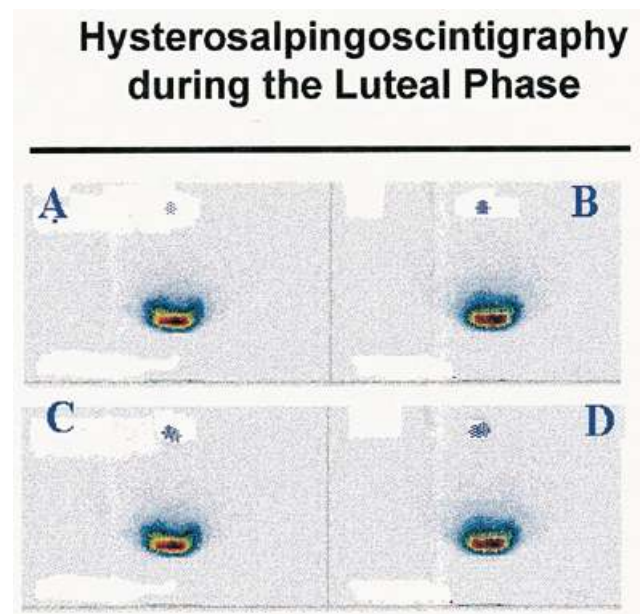


Figure 3. Uptake of labelled particles during the mid-luteal phase (progesterone serum concentrations: 14 ng/ml, onset of menstruation 7 days later) of the cycle by the uterus after application to the vagina. Uptake into the uterus occurred rapidly, within minutes as in the follicular phase. However, no further transport into the oviducts can be observed. The administration of oxytocin had no effect on distribution of radioactivity. Note the different pattern of distribution of radioactivity when compared with the follicular phase. (A) and (B) represent scans taken 2 and 10 min after application of activity; (C) and (D) represent scans taken before and 8–10 min after i.v. administration of 3 IU oxytocin.

contrast, no difference in pregnancy rate could be observed between both groups of patients.

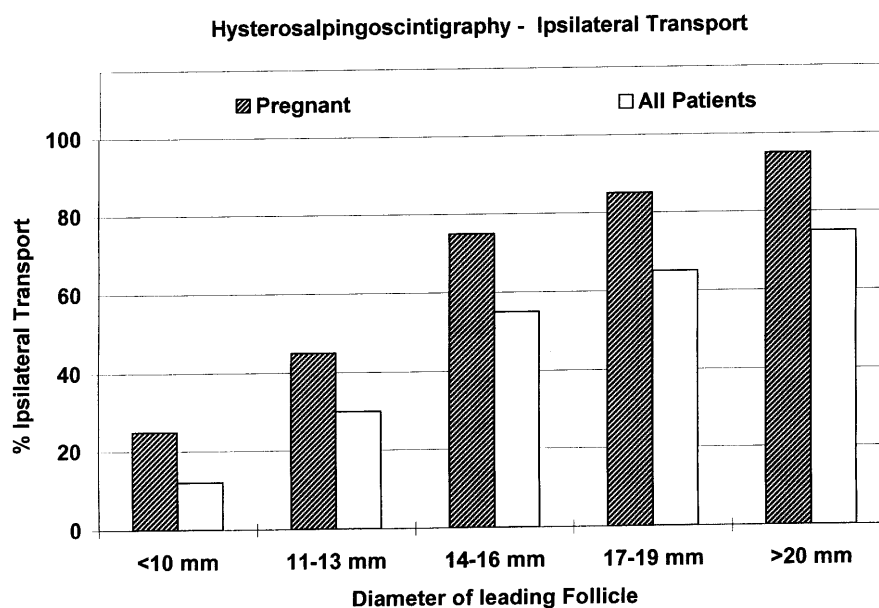


Figure 4. Lateralization of transport of labelled microspheres and size of the leading follicle. With increasing diameter of the dominant follicle, the proportion of patients exhibiting ipsilateral transport to the oviduct leading to the dominant follicle increased progressively. The proportion of patients with ipsilateral transport was higher in those who became pregnant after timed intercourse or intrauterine insemination than in those who did not conceive after this treatment (treatment duration lasting up to six cycles). Up to a follicle size of 13 mm, ipsilateral transport could be diagnosed only in retrospect, at the time when a dominant follicle did appear on the side where radioactivity was concentrated.

Table II. Result of hysterosalpingoscintigraphy and pregnancy rates (no. of pregnancies/no. of patients treated). Values in parentheses are percentages

	Ipsilateral transport	No transport
Pregnant ^a (Sp + IUI)	78/360 (21.7)	4/200 (2)
Pregnant ^b (IVF + ICSI)	25/110 (22.7)	48/196 (24.5)

^aIncludes pregnancy after normal and timed intercourse.

^bIncludes pregnancies after transfer of cryopreserved pro-nucleus cells.

IUI = intrauterine injection; ICSI = intracytoplasmic sperm injection; IVF = in-vitro fertilization.

The effects of oxytocin administration on transport of radioactivity is shown in Figures 5 and 6. As shown in Figure 5, radioactivity within the region of interest on the ipsilateral side did increase significantly immediately after oxytocin administration, suggesting an increase in the amount of particles transported as a consequence of the administration of the peptide. Radioactivity on the contralateral side, in contrast, did not exhibit dramatic changes. The data for all 50 patients studied are summarized in Figure 6. During the luteal phase, oxytocin had no effect on the distribution of radioactivity within the uterus.

Doppler sonography of the uterus and the oviduct filled with contrast medium resulted in characteristic signals, indicative for turbulent rather than laminar flow within the tubes. Oxytocin administration resulted in an increase of

turbulent flow, as shown on Figures 7 and 8, but only within the oviduct on the side of the dominant follicle. Only a few signals could be detected on the contralateral side before and after the administration of oxytocin.

Measurement of intrauterine pressure

The results of the recording of the intrauterine pressure before and after oxytocin administration are shown in Figures 9 and 10. Before oxytocin administration, contractions were observed with a frequency of 3/min and an amplitude of 10–20 mm HG respectively. Immediately following administration of oxytocin, basal pressure and amplitude of contractions did increase significantly ($P < 0.05$). Frequency of contractions, in contrast, did decrease. The decline of frequency was, however, not statistically significant. In addition, there were striking effects on the direction of pressure gradients caused by oxytocin. During the control period either no significant pressure gradients or small gradients with fundo-cervical direction were observed, oxytocin administration caused a significant increase of cervico-fundal pressure gradients, as shown in Figure 10.

The effects of oxytocin on electrical activity were similar to that on intrauterine pressure; the amplitude of the spikes increased, while the frequency declined immediately following oxytocin injection, as shown in Figure 11.

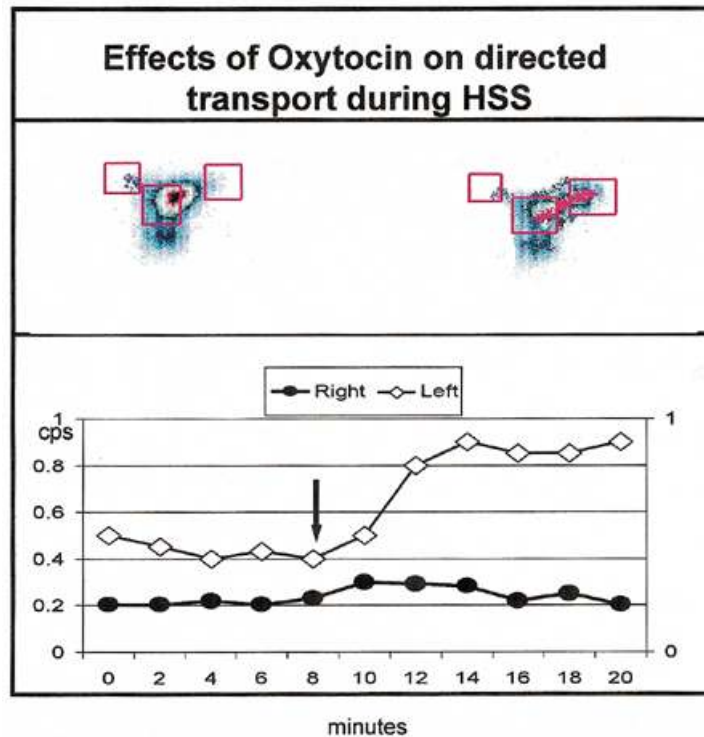


Figure 5. Administration (i.v.) of oxytocin (3 IU) in a patient during hysterosalpingoscintigraphy. The upper panel shows two scans taken 10 min apart, with the regions of interest (ROI) depicted as red boxes over the cavum and the left and right oviduct respectively. The lower panel shows radioactivity measured within the ROI over the left and right oviduct and expressed as counts per second. The dominant follicle in this patient was located in the left ovary. Activity on the left side is higher than on the right side. The arrow marks the time when oxytocin was administered; this was followed by an increase of radioactivity found within the ROI on the left side, indicating increased transport into the left oviduct.

Normal and disturbed function of the uterus and Fallopian tubes

To impregnate a fertilizable oocyte, male germ cells have to migrate from the place of their deposition in the posterior vaginal fornix to the pars ampullaris of the Fallopian tubes; the fertilized oocyte, in turn, has to be transported the opposite way to the uterine cavity for implantation. The timing of this process and the mechanisms controlling and coordinating this bidirectional travel are incompletely understood. In the present study the migration of radiolabelled immotile aggregates of serum albumin, used as surrogates for spermatozoa, from the vagina through the genital tract has been examined and some of the factors affecting this migration have been explored. The results of these studies suggest that upstream transport in the genital tract may be composed of two components: a rapid uptake by the uterus from the vagina and a directed transport from the uterus to the oviduct leading to the ovary bearing the dominant follicle. While the former is observed during follicular and luteal phase of the cycle, the latter is restricted to the follicular and preovulatory phase, becoming more predominant when the size of the leading follicle increases. These observations therefore strongly suggest that directed transport is controlled by the ovary.

Uptake of the radiolabelled aggregates by the uterus was found in all patients. It appears, therefore, that this part of the transport mechanism is relatively stable and that inhibition of uptake does not represent a major factor in infertility. The observation that uptake into the uterus occurred consistently even during the luteal phase of the cycle was rather unexpected because of the generally held belief that the cervical mucus becomes impenetrable to spermatozoa under the influence of elevated progesterone serum concentrations. However, this view may reflect a misinterpretation of data. It has been shown that spermatozoa become immotile in luteal mucus *in vivo* and *in vitro*, resulting in a failure to penetrate cervical mucus in in-vitro experiments. (Chretien *et al.*, 1980; Gaddum-Rosse *et al.*, 1980; Morales *et al.*, 1993). This does not necessarily imply that passive transport of spermatozoa will also be blocked during the luteal phase. Studies that examined directly the presence of spermatozoa in different compartments of the genital tract after intercourse have indeed shown that the numbers of motile spermatozoa found within the oviduct during the luteal phase are similar to those found in the early to mid-follicular phase of the cycle, although the highest number of spermatozoa can be detected in the Fallopian tube during the preovulatory phase

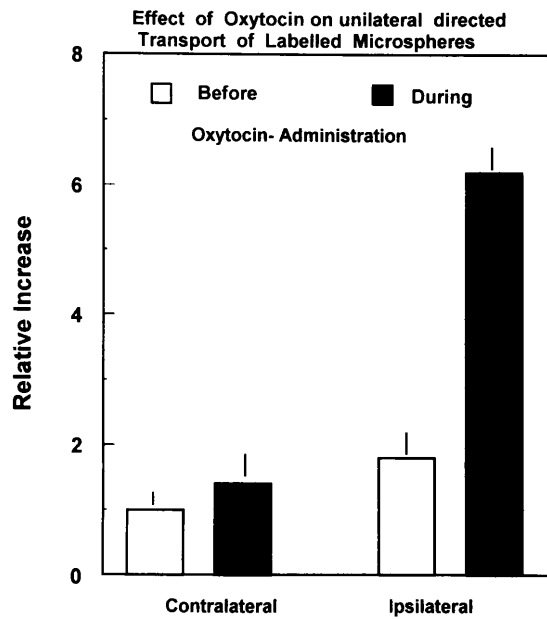


Figure 6. Relative increase of the radioactivity detected within the regions of interest (ROI) (see Figure 5) placed over uterus and the Fallopian tube leading to the dominant follicle. There is a significant ($P \leq 0.05$) increase in radioactivity immediately after oxytocin administration on the dominant, but not at the contralateral side. Data are presented as mean \pm SD of 50 observations.

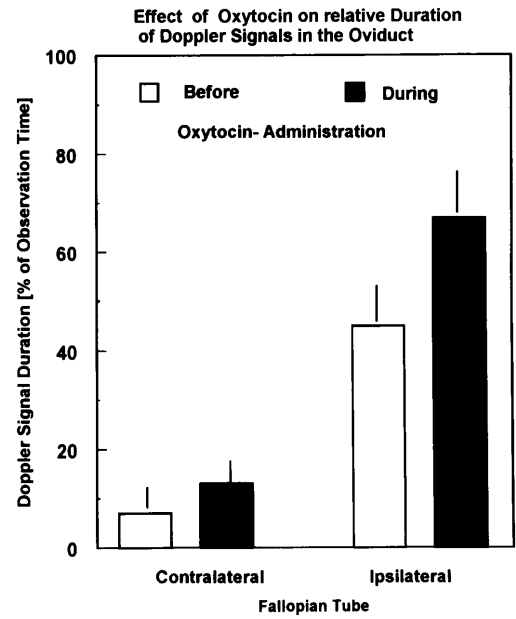


Figure 8. Doppler sonography of the left and right Fallopian tubes following instillation of echogenic contrast medium before and after oxytocin administration, demonstrating a significant increase ($P \leq 0.05$) in signal density and frequency after administration of the hormone. Data are presented as mean \pm SD of 30 observations.

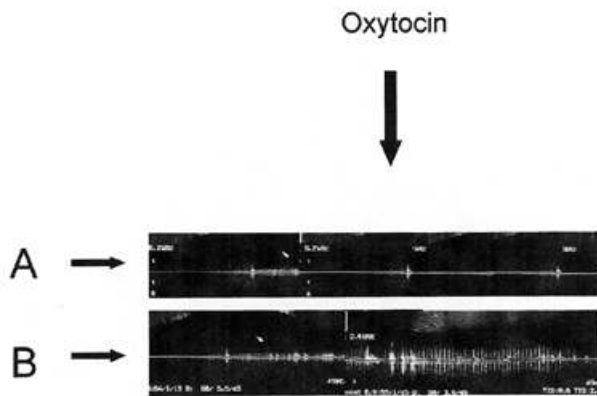


Figure 7. Doppler sonography of the Fallopian tubes after infusion of ultrasound contrast medium into the uterus. Panel A shows the signals on the side where no dominant follicle was found. Panel B depicts the signals within the Fallopian tube leading to the ovary with the dominant follicle. Time of oxytocin administration is indicated by the arrow. It was followed by a dramatic increase of signals within the Fallopian tube leading to the dominant follicle. The Doppler signals indicate turbulent flow.

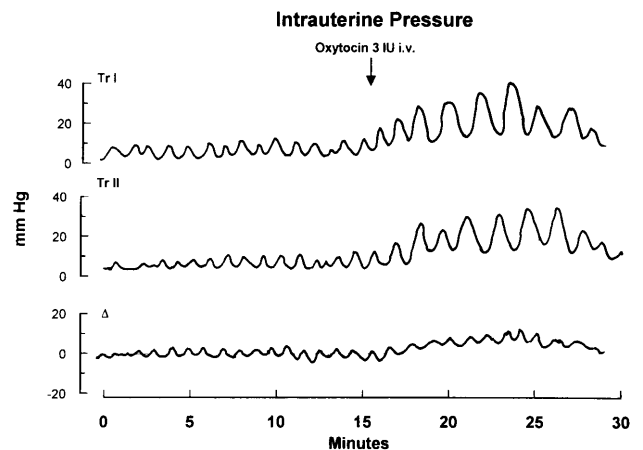


Figure 9. Intrauterine pressure recorded during the follicular phase of the cycle before and after the iv administration of 3 IU oxytocin. Transducer I (TrI) was placed in the fundal part, transducer II (TrII) near the internal cervical os. The arithmetic difference between pressure recorded in position II and the pressure recorded in position I is plotted in the lowest panel. Note the increase in basal tonus and the increase of the pressure difference between the two recording sites after oxytocin administration. The effect of oxytocin lasted for 20–40 min.

(Chretien *et al.*, 1980; Gaddum-Rosse *et al.*, 1980; Morales *et al.*, 1993; Vigil *et al.*, 1995).

The interpretation of the results of HSS with regard to sperm transport rests on the assumptions that the properties of the labelled material used for examination are similar to those of human spermatozoa and that there is no separation

of label from the carrier *in vivo*. For radionuclide imaging of the female genital tract that has been introduced more than 20 years ago, various radiolabelled compounds have been used, including radioactive inert gases, aggregates of human albumin and labelled spermatozoa (Ardran and

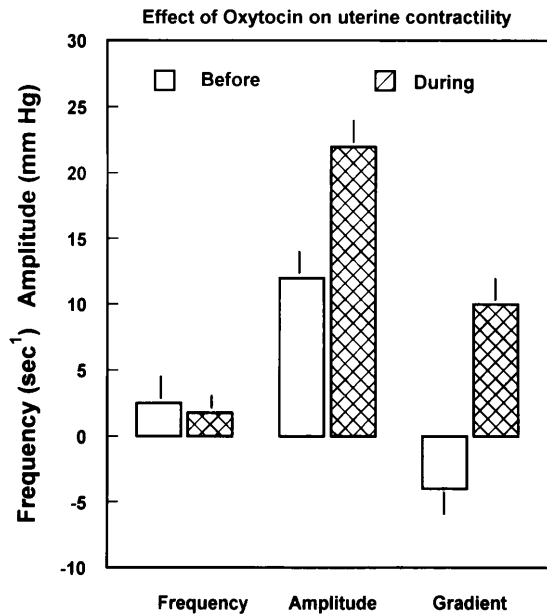


Figure 10. Effects of oxytocin administration on frequency and amplitude of uterine contractions and the pressure difference between cervix and fundus recorded during the late follicular phase of the cycle. The increase in amplitude and the changes in pressure gradient were statistically significant ($P \leq 0.05$). Data are presented as mean \pm SEM of 25 observations.

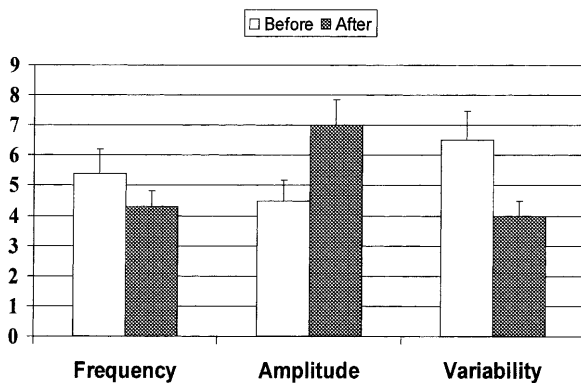


Figure 11. Effects of oxytocin on frequency, amplitude and variability of potential differences in electrical activity between fundus and cervix uteri of 20 women studied in the late follicular phase of the cycle. Recording duration was 5–10 min before and 5–10 min after administration of oxytocin. One electrode was positioned within the fundal part of the uterus, the second electrode were placed at the cervix. Data are presented as mean \pm SEM of 1 min observation periods before and after oxytocin administration. Frequency is expressed as spikes/minute, amplitude in μ V and variability as the point to point coefficient of variation in percentage.

Kemp, 1972; Alimov ShA *et al.*, 1973; Pertynski *et al.*, 1977; de Rossi *et al.*, 1981; Iturralde and Venter, 1981; Becker *et al.*, 1988; Brundin *et al.*, 1989; Ozgur *et al.*, 1997). In the present study, human serum albumin macroaggregates with Tc-99m (radioactive Technetium;

Amersham, Braunschweig, Germany) attached to the protein by non-covalent binding were used as surrogates for spermatozoa. Degradation of the labelled protein and uptake by the lymphatic system draining the uterus could be excluded by the demonstration that radioactivity disappeared from the uterus after flushing with saline and by the observation that the radioactivity collected from the Pouch of Douglas at laparoscopy could be precipitated completely by acid and still could be centrifuged down at low speed 4–7 h after application, suggesting that the majority of radioactivity was remained protein-bound.

Although HSS represents a technically very simple procedure, causing little discomfort to the patient when compared to hysterosalpingography, it has never been widely used. This may have been due to the apparent discrepancy between the results of HSS and those obtained with HSG or laparoscopy; in the majority of patients with proven patency of both Fallopian tubes, only one oviduct could be visualized by HSS. Although this was a disturbing finding initially, a detailed analysis of the results of HSS and their correlation with the results of ultrasonography and determination of endocrine parameters for follicular growth revealed that transport of the radiolabelled microspheres is physiologically restricted to the oviduct leading to the ovary bearing the dominant follicle while the contralateral Fallopian tube appears to be functionally closed (Becker *et al.*, 1992; Kissler *et al.*, 1995; (Kunz *et al.*, 1996, 1997). Data from the present study, collected in a large number of women, unequivocally demonstrate that ipsilateral transport is not the consequence of tubal pathology or an artefact of the method, but a reflection of the physiological function of the uterus and the oviduct. This view is further strengthened by the observation that the pregnancy rate after normal intercourse or intrauterine insemination was significantly higher in patients exhibiting ipsilateral transport than in those who failed to do so.

Our findings imply in addition that failure of transport, as demonstrated by HSS, in patients with mechanically patent Fallopian tubes may be considered as a cause of infertility. Most of the patients examined in this study would, in the absence of other causes of infertility, have been diagnosed as suffering from idiopathic sterility. We would like to propose instead the concept of 'tubal transport disorder (TTD)' as a more adequate description of the condition of these patients. Since pregnancy rate of patients with TTD, which is extremely low following insemination or timed intercourse, can be increased substantially by in-vitro-fertilization, the results of HSS may provide criteria for the choice of the adequate therapy in such women.

Transport from the uterus to the oviduct appears to depend upon ovarian function, more specifically on the func-

tion of the ovary bearing the dominant follicle. This view is based on the observation that the proportion of patients exhibiting ipsilateral transport did increase in parallel to the size of the dominant follicle, reaching up to 90% of those patients who became pregnant when the follicle diameter was ≥ 19 mm. The question then arises which forces are driving transport and which are the mechanisms directing this process. Motility of the spermatozoa can be excluded, since the particles used for HSS are protein aggregates devoid of motility. Movements of the ciliae within the oviduct seems also to be a very unlikely candidate, since the beat of ciliae is directed from the ampulla to the uterus in the opposite direction; in addition, the observation that women with Kartagener syndrome (congenital absence of ciliae), have no difficulty in becoming pregnant (Amsler and Pavic, 1985; McComb *et al.*, 1986; Halbert *et al.*, 1997) argues against the beat of ciliae as a major factor in rapid transport. Capillary forces generated within the mucus and a difference in hydrostatic pressure between the vagina and the peritoneal cavity have been described (Fox *et al.*, 1970); it is, however, unlikely that these factors account for the immediate uptake from the vagina and the directed transport. Therefore, peristaltic contractions of the uterus and of the muscular layers of the Fallopian tubes represent the most likely candidates responsible for the rapid transport phenomena. Peristaltic contractions of the non-pregnant uterus have been described in women during the normal menstrual cycle as well as in women suffering from primary dysmenorrhoea (Dawood, 1986; Csapo and Pinto Dantas, 1966) using direct measurement of intrauterine pressure, or in women with endometriosis using vaginal sonography combined with videocinematography (Kunz *et al.*, 1996; Leyendecker *et al.*, 1996) during the follicular phase of the cycle. In healthy women, the contractions seem to occur with a frequency of 2–5 per min and to exhibit a characteristic pattern of propagation, depending on the phase of the menstrual cycle. A fundocervical direction predominated in the early follicular phase, while a cervicofundal propagation of peristaltic waves was found during the preovulatory phase of the cycle.

Uterine contractions can be induced by a number of hormones and paracrine mediators such as prostaglandins, vasopressin, oxytocin and various peptides (Maggi *et al.*, 1994a,b). That oxytocin may be one of the critical mediators with respect to uterine contractions and transport is suggested by the observation that the administration of oxytocin during HSS was followed by an dramatic increase of transport into the oviduct ipsilateral to the dominant follicle, as reflected by the 5–7-fold increase in the radioactivity detected in the respective region of interest, as well as by the demonstration that systemic administration of oxytocin increased the amplitude

of contractions and reversed the pressure gradient from a fundocervical to a cervicofundal direction. A number of observations in the human female and in experimental animals suggest that oxytocin plays an important role in eliciting contractions of the non-pregnant uterus. Receptors for oxytocin have been demonstrated in the non-pregnant uterus of human females and laboratory animals (Fuchs *et al.*, 1985; Miller *et al.*, 1993; Ivell *et al.*, 1995). It has been shown that oxytocin is released from the posterior lobe of the pituitary gland in response to vaginal distension, in response to cervical stimulation and during intercourse in response to tactile as well as emotional stimuli (Fox *et al.*, 1970; Fox and Fox, 1971; Fox, 1973; Fox, 1976; Gilbert *et al.*, 1991; Murphy *et al.*, 1987). In addition to its classic hypothalamic site of production, synthesis of oxytocin has also been demonstrated within the endometrium and the ovary respectively (Garcia Villar *et al.*, 1983; Okuda *et al.*, 1992; Ivell *et al.*, 1995; Khan-Dawood *et al.*, 1995). Contractions of the non-pregnant human uterus in response to oxytocin were studied systematically >50 years ago by Knaus who showed that injections of posterior pituitary extract containing oxytocin promptly induced contractions during the follicular phase, but not after ovulation (Knaus, 1950). Our observations confirm and extend these findings by demonstrating a striking effect of oxytocin on uterine transport mechanisms. The absence of directed transport during the luteal phase and our failure to demonstrate effects of oxytocin at this stage of the cycle are in agreement with these early observations.

There are only few in-vivo studies on the electrical activity of the non-pregnant human uterus (Darconza *et al.*, 1990). In most instances, no direct relationship between contractions and electrical activity was found. Although no direct comparison between electrical activity and changes in intrauterine pressure were made in the present study, the changes in electrical activity in response to oxytocin administration did correspond with those of intrauterine pressure. Further studies are necessary to explore in more detail the correlation between electrical activity and intrauterine pressure and to examine the validity of recording electrical potentials for assessment of uterine contractions.

Ipsilateral transport into and within the oviduct could not only be observed using scintigraphy, but also more directly by Doppler sonography after administration of ultrasound contrast medium. An increase in signal density was consistently observed immediately after oxytocin administration, either i.v. or intranasally, indicating an increase in (turbulent) flow within the Fallopian tube. The increase of flow could only be detected within the oviduct leading to the dominant follicle, but not on the contralateral side, thus strengthening the view that transport occurred predominantly into this direction.

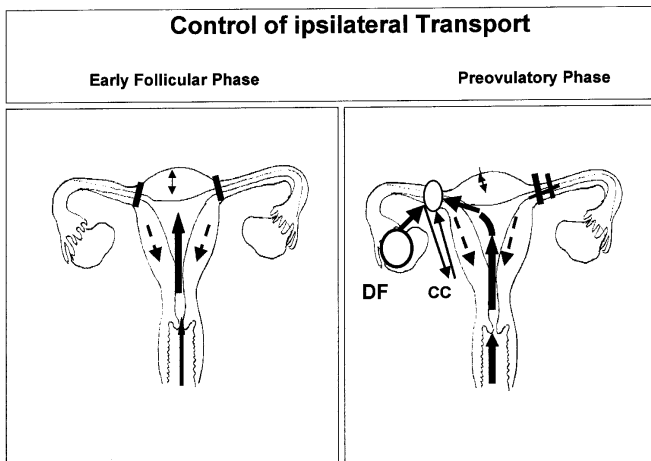


Figure 12. Schematic representation of the model of directed transport. During the early follicular phase (left panel) both Fallopian tubes are functionally closed, transport occurs from the vagina to the uterine cavity. Contractions of the myometrium, indicated by the broken arrows, that are followed by relaxation cause a negative pressure within the uterus when compared to the vagina. In the right panel, the dominant follicle has been selected (DF). Concentrations of progesterone, produced by the dominant follicle, are elevated at the utero-tubal junction due to a countercurrent (CC) system indicated by the arrows, causing relaxation of the musculature. Since the contralateral side remains functionally closed, transport is directed into the Fallopian tube at the side of the dominant follicle.

The overall increase in transport may be explained by the stimulatory action of oxytocin on myometrial contractions. An increase of myometrial contractions alone does not, however, explain unilateral transport. Additional mechanisms regulated at the levels of uterus and oviduct are required to account for this phenomenon. Asymmetric distribution of oxytocin receptors leading to an asymmetric contraction pattern of the uterus or changes in the resistance of the oviducts caused by the activation or relaxation of smooth muscle cells at the utero-tubal junction could represent such mechanisms. There are at present no experimental data available to answer this question. In the absence of such data we propose the hypothesis shown in Figure 12: (i) in the absence of ovarian hormones the Fallopian tubes are functionally closed; (ii) the ovary bearing the dominant follicle is producing hormones that cause relaxation of smooth muscle cells; (iii) unilateral transport is the consequence of active relaxation of the myometrium at the side of the ovary that is bearing the dominant follicle rather than the induction of a contraction at the contralateral side. This hypothesis is currently being tested experimentally.

There is ample of evidence that progesterone can induce relaxation of the myometrium. It has been shown that the

preovulatory follicle produces progesterone in increasing amounts, and that progesterone concentrations in the venous effluent from the ovary bearing the dominant follicle are higher than those from the contralateral ovary several days before ovulation (Baird and Fraser, 1975; Khan Dawood *et al.*, 1989). The arterio-venous counter-current exchange system that has been identified between the ovary and the uterus (Ginther, 1974; Czerkwinski, 1985; Einer Jensen, 1990; Krzymowski *et al.*, 1990), could serve as the anatomical substrate for the delivery of progesterone to the area of the utero-tubal junction.

In conclusion, our data demonstrate that the uterus and Fallopian tubes represent a functional unit with regard to transport of spermatozoa. The uterus seems to act as a peristaltic pump that provides the pressure gradients necessary to transport spermatozoa from the vagina to the Fallopian tubes. A functional sphincter mechanism located in the area of the utero-tubal junction that is actively relaxed by secretory products originating from the ovary bearing the dominant follicle allows further transport to the ampullary part of the tube on the side of the follicle destined to ovulate, while the contralateral oviduct remains functionally closed. As a consequence, the number of spermatozoa will be maximized at the site where the oocyte has to be expected, thereby increasing the probability for fertilization. Oxytocin may play a critical role in the control of this process by activation of pump mechanisms via contraction of uterine smooth muscles. Disturbance of these mechanisms seem to cause infertility by interfering with tubal transport, even in the presence of mechanically open Fallopian tubes. HSS appears to be a suitable method to diagnose this condition.

Acknowledgements

We thank D.Nollau and S.Schwemmer for assistance with the clinical studies and E.Stockhausen, U.Toborek and I.Hoffmann for the skilful performance of the assays.

References

- Adelusi, B., Al-Nuaim, L., Makanjuola, D. *et al.* (1995) Accuracy of hysterosalpingography and laparoscopic hydrotubation in diagnosis of tubal patency. *Fertil. Steril.*, **63**, 1016-1020.
- Alimov ShA, Kogan, A.A., Ginzburg, V.S., *et al.* (1973) Radioizotopnoe issledovanie prokhodimosti matochnykh trub. [Radioisotope study of uterine tubal patency.] *Akush. Ginekol. Mosk.*, **49**, 64-67.
- Amsler, P. and Pavic, N. (1985) Pregnancy in a patient with immotile cilia syndrome (Kartagener syndrome). *Geburtshilfe Frauenheilkd.*, **45**, 183-185.
- Ardran, G.M. and Kemp, F.H.M.8. (1972) Radiography of potentially pregnant females. *Br. Med. J.*, **4**, 422-423.
- Baird, D.T. and Fraser, I.S. (1975) Concentration of oestrone and oestradiol in follicular fluid and ovarian venous blood of women. *Clin. Endocrinol.*, **4**, 259-264.

- Becker, W., Steck, T., Albert, P. *et al.* (1988) Hysterosalpingoscintigraphy: a simple and accurate method of evaluating fallopian tube patency. *Nuklearmedizin*, **27**, 252–257.
- Becker, W., Wildt, L., Siebzehrübl, E. *et al.* (1992) Tubal patency regulated by the endocrine system- new concept based on hysterosalpingoscintigraphy. *Acta Endocrinol.*, **126** (Suppl. 4), 135–135.
- Brundin, J., Dahlborn, M., Ahlberg Ahre, E. *et al.* (1989) Radionuclide hysterosalpingography for measurement of human oviductal function. *Int. J. Gynaecol. Obstet.*, **28**, 53–59.
- Chretien, F.C., Sureau, C. and Neau, C. (1980) Experimental study of cervical blockage induced by continuous low-dose oral progestogens. *Contraception*, **22**, 445–456.
- Csapo, A.I. and Pinto Dantas, C.R. (1966) The cyclic activity of the nonpregnant human uterus. A new method for recording intrauterine pressure. *Fertil. Steril.*, **17**, 34–38.
- Czerkwinski, J. (1985) Selected problems of morphology of the venous system of the female internal genital organs. II. Morphology of the veins of the mesosalpinx. The venous system in cases of uterine myoma. Atypical anastomoses between ovarian and uterine venous trunks. *Ginekol. Pol.*, **56**, 293–299.
- Darconza, G., Paradiso, S., Trentadue, R. *et al.* (1990) Electrical activity of the human uterus *in vivo* in the phases of the menstrual cycle. *Clin. Exp. Obstet. Gynecol.*, **17**, 171–180.
- Dawood, M.Y. (1986) Current concepts in the etiology and treatment of primary dysmenorrhea. *Acta Obstet. Gynecol. Scand. Suppl.*, **138**, 7–10.
- de Rossi, G., Salvatori, M., Giordano, A. *et al.* (1981) Hysterosalpingoscintigraphy. About the possibility of fallopian tubes patency evaluations by means of ^{99m}Tc-pertechnetate and comparison of radiation loads due to radioisotopic and X-ray examinations. *Radiol. Diagn. Berl.*, **46**, 692–695.
- Einer Jensen, N. (1990) Functional and therapeutic aspects of counter current transfer in the female adnexa. *Med. Hypotheses*, **33**, 125–127.
- Fox, C.A. (1973) Recent studies in human coital physiology. *Clin. Endocrinol. Metab.*, **2**, 527–543.
- Fox, C.A. (1976) Some aspects and implications of coital physiology. *J. Sex. Marital Ther.*, **2**, 205–213.
- Fox, C.A. and Fox, B. (1971) A comparative study of coital physiology, with special reference to the sexual climax. *J. Reprod. Fertil.*, **24**, 319–336.
- Fox, C., Wolff, H.S. and Baker, J.A. (1970) Measurement of intra-vaginal and intra-uterine pressures during human coitus by radio-telemetry. *J. Reprod. Fertil.*, **22**, 243–255.
- Fuchs, A.R., Fuchs, F. and Soloff, M.S. (1985) Oxytocin receptors in nonpregnant human uterus. *J. Clin. Endocrinol. Metab.*, **60**, 37–41.
- Gaddum-Rosse, P., Blandau, R.J. and Lee, W.I. (1980) Sperm penetration into cervical mucus *in vitro*. II. Human spermatozoa in bovine mucus. *Fertil. Steril.*, **33**, 644–648.
- Garcia Villar, R., Toutain, P.L., Schams, D. *et al.* (1983) Are regular activity episodes of the genital tract controlled by pulsatile releases of oxytocin? *Biol. Reprod.*, **29**, 1183–1188.
- Gilbert, C.L., Jenkins, K. and Wathes, D.C. (1991) Pulsatile release of oxytocin into the circulation of the ewe during oestrus, mating and the early luteal phase. *J. Reprod. Fertil.*, **91**, 337–346.
- Ginther, O.J. (1974) Internal regulation of physiological processes through local venoarterial pathways. A review. *J. Anim. Sci.*, **39**, 550–564.
- Halbert, S.A., Patton, D.L., Zarutskie, P.W. *et al.* (1997) Function and structure of cilia in the fallopian tube of an infertile woman with Kartagener's syndrome. *Hum. Reprod.*, **12**, 55–58.
- Harper, M.J.K. (1994) Gamete and zygote transport. In: Knobil, E. and Neill, J.D. (eds), *The Physiology of Reproduction*. 2nd edn. Raven Press, New York, USA, pp. 123–187.
- Iturralde, M. and Venter, P.F. (1981) Hysterosalpingo-radionuclide scintigraphy (HERS). *Semin. Nucl. Med.*, **11**, 301–314.
- Ivell, R., Rust, W., Einspanier, A. *et al.* (1995) Oxytocin and oxytocin receptor gene expression in the reproductive tract of the pregnant cow: rescue of luteal oxytocin production at term. *Biol. Reprod.*, **53**, 553–560.
- Karande, V.C., Pratt, D.E., Rabin, D.S. *et al.* (1995) The limited value of hysterosalpingography in assessing tubal status and fertility potential. *Fertil. Steril.*, **63**, 1167–1171.
- Khan-Dawood, F.S., Yang, J. and Dawood, M.Y. (1995) Potential role of oxytocin in cell to cell communication in the corpus luteum. *Adv. Exp. Med. Biol.*, **395**, 507–516.
- Khan Dawood, F.S., Goldsmith, L.T., Weiss, G. *et al.* (1989) Human corpus luteum secretion of relaxin, oxytocin, and progesterone. *J. Clin. Endocrinol. Metab.*, **68**, 627–631.
- Kissler, S., Döinghaus, K., Becker, W. *et al.* (1995) Hysterosalpingoscintigraphic examination of the fallopian tube: a selective, unilateral transport mechanism. *Contracept., Fertil., Steril.*, **23**, OC-286.
- Knaus H. (1950) *Die Physiologie der Zeugung des Menschen*. 3rd edn. Wilhelm Maudlach Verlag. Vienna, Austria.
- Krzyszowski, T., Kotwica, J. and Stefanczyk Krzymowska, S. (1990) Uterine and ovarian countercurrent pathways in the control of ovarian function in the pig. *J. Reprod. Fertil.*, **40** (Suppl.), 179–191.
- Kunz, G., Beil, D., Deiniger, H. *et al.* (1997) The uterine peristaltic pump. Normal and impeded sperm transport within the female genital tract. *Adv. Exp. Med. Biol.*, **424**, 267–277.
- Kunz, G., Beil, D., Deiniger, H. *et al.* (1996) The dynamics of rapid sperm transport through the female genital tract: evidence from vaginal sonography of uterine peristalsis and hysterosalpingoscintigraphy. *Hum. Reprod.*, **11**, 627–632.
- Lang, E.K. (1991) Organic vs functional obstruction of the fallopian tubes: Differentiation with prostaglandin antagonist- and β_2 -agonist-mediated hysterosalpingography and selective ostial salpingography. *Am. J. Roentgenol.*, **157**, 77–80.
- Leyendecker, G., Kunz, G., Wildt, L. *et al.* (1996) Uterine hyperperistalsis and dysperistalsis as dysfunctions of the mechanism of rapid sperm transport in patients with endometriosis and infertility. *Hum. Reprod.*, **11**, 1542–1551.
- Maggi, M., Baldi, E. and Susini, T. (1994a) Hormonal and local regulation of uterine activity during parturition: Part I—The oxytocin system. *J. Endocrinol. Invest.*, **17**, 739–756.
- Maggi, M., Baldi, E., Susini, T. (1994b) Hormonal and local regulation of uterine activity during parturition: Part II—The prostaglandin and adrenergic systems. *J. Endocrinol. Invest.*, **17**, 757–770.
- McComb, P., Langley, L., Villalon, M. *et al.* (1986) The oviductal cilia and Kartagener's syndrome. *Fertil. Steril.*, **46**, 412–416.
- Merriam, G.R. and Wachter, K.W. (1982) Algorithms for the study of episodic hormone secretion. *Am. J. Physiol.*, **243**, 310–318.
- Miller, F.D., Chibbar, R. and Mitchell, B.F. (1993) Synthesis of oxytocin in amnion, chorion and decidua: a potential paracrine role for oxytocin in the onset of human parturition. *Regul. Pept.*, **45**, 247–251.
- Morales, P., Roco, M. and Vigil, P. (1993) Human cervical mucus: relationship between biochemical characteristics and ability to allow migration of spermatozoa. *Hum. Reprod.*, **8**, 78–83.
- Murphy, M.R., Seckl, J.R., Burton, S. *et al.* (1987) Changes in oxytocin and vasopressin secretion during sexual activity in men. *J. Clin. Endocrinol. Metab.*, **65**, 738–741.
- Okuda, K., Miyamoto, A., Sauerwein, H. *et al.* (1992) Evidence for oxytocin receptors in cultured bovine luteal cells. *Biol. Reprod.*, **46**, 1001–1006.
- Ozgun, K., Yildiz, A., Uner, M. *et al.* (1997) Radionuclide hysterosalpingography with radiolabeled spermatozoa. *Fertil. Steril.*, **67**, 751–755.
- Pertynski, T., Jakubowski, W., Stelmachow, J. *et al.* (1977) A scintigraphic method of examining the patency of oviducts using ¹³³Xe. *Eur. J. Nucl. Med.*, **2**, 159–164.
- Pulkkinen, M.O. (1995) Oviductal function is critical for very early human life. *Ann. Med.*, **27**, 307–310.
- Steck, T., Becker, W., Albert, P. *et al.* (1989) Initial experiences with hysterosalpingoscintigraphy in normal and pathologic fallopian tube passage. *Geburts. Frauenheilk.*, **49**, 889–893.
- Vigil, P., Riquelme, R. and Morales, P. (1995) Sperm binding to the human zona pellucida after migration through human cervical mucus. *Int. J. Androl.*, **18** (Suppl. 1), 7–11.
- Zar, J.H. (1984) *Biostatistical Analysis*. 2nd edn. Prentice Hall Inc, Englewood Cliffs, USA.