

# Spine Injuries in the Sport of Gymnastics

David Kruse<sup>1</sup> and Brooke Lemmen<sup>2</sup>

<sup>1</sup>Assistant Clinical Professor, Director, Primary Care Sports Medicine, Department of Family Medicine, University of California, Irvine, UC Irvine Healthcare Gottschalk Medical Plaza, Irvine, CA; <sup>2</sup>Third Year Resident, Family Medicine, Sparrow/MSU Family Medicine Residency, Lansing, MI

KRUSE, D. and B. LEMMEN. Spine injuries in the sport of gymnastics. *Curr. Sports Med. Rep.*, Vol. 8, No. 1, pp. 20–28, 2009. *Injury in gymnastics is not an uncommon occurrence, and an injury of the spine frequently is a source of pain in a gymnast. Because of the unique demands of this sport, which repetitively place significant forces across the spine, it becomes clear why the spine commonly is injured. Potential causes of back pain in a gymnast include spondylolysis, Scheuermann's disease, intervertebral disc pathology, and mechanical sources of pain. Much of the diagnostic workup and management of spondylolysis lesions remains controversial, but a successful management strategy can be developed for the safe return of a gymnast to the mat. Mechanical sources of pain are common and should be addressed. Psychosocial etiologies of back pain also exist in these athletes. Rehabilitation strategies should focus on improvement in the strength and function of the trunk and lumbar spine and the correction of biomechanical deficits with a goal of pain-free transition back to gymnastic-specific activities.*

## INTRODUCTION

The casual observer will note that the sport of gymnastics requires a level of flexibility, conditioning, and complete body recruitment that is matched infrequently by other sports. As a result, gymnasts present a unique diagnostic and treatment challenge to the medical practitioner. Injury rates in gymnastics have been well documented in multiple epidemiologic studies and literature reviews (4,12,13,17,20,28,36,39). Overall, an extensive and detailed review of the literature by Caine and Nassar reveals that lower extremity injuries, in particular ankle ligament sprains and internal knee derangements, are most common in women's gymnastics, while upper extremity wrist and shoulder injuries are most common for men. Exposure data show that injury rates are greatest during competition and for both women and men are highest during participation on the floor exercise event (4). Although not overall the highest in prevalence, the occurrence of back injury and pain in both women's and men's gymnastics is significantly high due to the unique physical challenges inherent in gymnastics (4,12,16,17,28,36,46,47).

Back pain has long been recognized as a major reason for doctor visits in the general population and is the most

common type of pain reported by adults. These visits result in medical costs amounting to billions of dollars annually (8,10). Recently, more attention has been brought to the high prevalence of back pain in children, more common than previously thought, with multiple studies showing back pain in 18%–70% of adolescents studied (24,42,49). With this recognition, also noted is a significant difference in the underlying pathology in adolescents with back pain compared with an adult population (9,15,32).

## THE PHYSICAL DEMANDS OF GYMNASTICS

The sport of gymnastics rises in popularity every 4 yrs during the Olympic games, and for most who watch the sport, a thorough understanding of the events, skills, equipment, and biomechanics of gymnastics is rare. A basic understanding of these, however, is important to understand the mechanism of injury in these athletes and their return to sport. Many factors make this difficult: rule changes occur every 4 yr, new skills are developed, there are multiple different events, and the dynamic activity and body positioning is unique, unlike any other sport.

There are many different body positions required in the sport of gymnastics that are relevant to back injury. During take-off from the ground, rebounding, and landing required for floor, vault, and dismounts, a large amount of force is translated along the axial spine (17,18). Biomechanical analyses of gymnastics have been performed and provide evidence of the forces generated during the participation of this sport (3). The amount of force generated will vary with the skill performed, the body part analyzed, and the

Address for correspondence: David Kruse, M.D., Assistant Clinical Professor, Director, Primary Care Sports Medicine, Department of Family Medicine, University of California, Irvine, UC Irvine Healthcare Gottschalk Medical Plaza, 2100 Medical Plaza Dr., Irvine, CA 92697 (E-mail: krused@uci.edu).

technique and skill level of the gymnast. During the take-off for a backward somersault skill, vertical forces through the foot have been measured at 3.4 to 5.6 times the body weight of the gymnast. More evident is the amount of force generated at the Achilles tendon during a back take-off, which has been measured at 16 times body weight (3).

Body positions for different skills and landing require a varied amount of hyperflexion, hyperextension, or vertical stability of the spine. Contrarily, "hanging" events, such as the uneven bars, horizontal bar and rings, place a traction force. Some trials have shown reaction forces of 6.5 to 9.2 times body weight during the downward ring swing (3). For proper execution of skills, certain spinal positioning is stressed and developed from a young age, one example among many being the "hollow" position. This position places an emphasis on scapular protraction and thoracic hyper-kyphosis, in combination with anterior pelvic tilt (Fig. 1). Other skills typically require extreme levels of hyperextension, and commonly hyperlordosis.

Female gymnasts train and compete on four events: the beam, uneven bars, floor, and vault. Beam requires repetitive hand, foot, and ankle impact in combination with a high level of proprioceptive control of the lower extremity. Floor and vault, like beam, require a combination of upper and lower extremity impact, possibly though with greater degrees of force. Floor also may involve many dance moves emphasizing hyperlordotic positioning. During uneven bars participation, there is a risk of spinal impact on the bar during release and regrasp skills.

Male gymnasts train and compete on six events: the floor, pommel horse, rings, vault, parallel bars, and horizontal bar. Stresses during floor and vault participation are similar to those seen in women's gymnastics. Other events such as pommel horse and parallel bars are particularly stressful on upper extremity structures. Additionally, impact on the lower extremity and the risk of acute spinal trauma are present during a parallel bar dismount. The horizontal bar and rings stress the stability of the spine, and both of these events require highly dynamic dismounts. On the horizontal bar, release and regrasp skills pose a risk for acute spinal trauma.

Rhythmic gymnasts also train and compete in multiple events. In general, stress is placed on the spine via skills that require extreme levels of flexion and extension of the vertebral column not seen in other sports.

Gymnastics for many is a year-round sport; therefore, rest and modification of activity becomes a time challenge when treating an injured gymnast. However, unlike a pitcher whose

rest from throwing is essentially complete rest from the sport, a gymnast has multiple events and skills that can be modified in order to facilitate uninterrupted participation while still avoiding exacerbation of the injury. As with any sport, a progressive and efficient return to training and competition is essential. The rehabilitative program must take into account the unique demands of the sport, provide sport-specific exercises, and also provide a maintenance program.

## GYMNASTICS AND BACK PAIN

Low back pain is highly prevalent in gymnasts and multiple epidemiologic studies and reviews have documented this with prevalences ranging from 25% to 85% (4,13,16,17,30,36,43,46,47). The prevalence of back pain varies depending upon the population studied and the definitions used. In female and male artistic gymnasts, rates of low back pain can be as high as 65% to 85%, respectively (46,47). For rhythmic gymnasts, one study published in 1999 showed reports of low back pain in 86% of the gymnasts studied (16). More recently, a review of the literature, done by Caine and Nassar, reveals additional studies showing a high prevalence of back pain and injury consistent with the previous data. Their review provides a percentage comparison of injury location from prospective and retrospective data showing spine/trunk percentages of 0% and 14% (24), respectively (4). Marshall et al. recently presented epidemiologic data on collegiate women's gymnastics injuries from the National Collegiate Athletic Association Injury Surveillance System (28). Data from the 1988/89 through 2003/04 academic years revealed that low back strains were the third most common practice and competition injury accounting for 6% and 3%, respectively, of those injuries behind the ankle and knee. These percentages are lower than previously described; however, this study reflects the percentage of acute injury, not taking into account the prevalence of chronic back pain in gymnastics. Katz and Scerpella demonstrated a case series of female gymnasts with anterior and middle column thoracolumbar spine injuries (20). The goal of this study was to highlight that in addition to the well known prevalence of posterior spine abnormalities and injury in gymnastics (i.e., spondylolysis), anterior and middle spinal injuries are common as well. These may include vertebral compression fractures, disc injuries, and growth plate abnormalities and should be considered during the evaluation of a gymnast with back pain. When compared with other sports, male gymnasts have a significantly higher frequency and severity of back pain (46).

## GYMNASTICS AND UNDERLYING SPINAL PATHOLOGY

A high rate of underlying spinal pathology is noted in the gymnastics population (13,16,17,35,36,46). When observing abnormalities on imaging studies in athletes, a common question is whether the pathology is the cause of the athlete's pain. With a high prevalence of radiologic abnormalities in the gymnast, answering this question becomes



**Figure 1.** Gymnastics hollow position. Requires scapular protraction, thoracic hyperkyphosis, and anterior pelvic tilt.

more difficult. An early study done by Jackson et al. showed that in 100 female gymnast volunteers, 11% had bilateral L5 pars interarticularis defects and 6% of those had Grade 1 spondylolisthesis, based on radiographic anteroposterior, lateral, and oblique films (17). Of those gymnasts with radiographic findings, 54% had a history of back pain. Goldstein et al. performed magnetic resonance imaging (MRI) studies on a population of 33 female gymnasts (13). Of the 33 athletes, 13 (39%) had evidence of spinal pathology, including either spondylolysis or an abnormal disk. Of these, 27% had no complaints of back pain. An additional study by Rossi and Dragoni inspected the clinical records of 3132 Italian athletes with low back pain, of which 417 were gymnasts (35). A total of 68, or 16%, of the 417 gymnasts had x-ray evidence of spondylolysis. A thorough study performed by Sward et al. of Swedish athletes involved 26 male gymnasts and 26 female gymnasts (46). Athletes were selected at random and underwent clinical and radiographic (thoracic and lumbar x-ray) study. Approximately 85% and 65% of male and female gymnasts, respectively, had complaints of back pain. Of the 52 gymnasts studied, 42% had radiologic changes of the thoracolumbar spine including spondylolysis, disc height reduction, and Schmorl's nodes. The same group of investigators performed a MRI analysis of 24 Swedish male gymnasts, selected without knowledge of prior or present back pain (47). When compared with non-athlete controls, the male gymnasts had a significantly higher incidence of disc degeneration in the thoracolumbar spine (75% compared with 31%). The male gymnasts also had a higher incidence of disc bulge, disc-height reduction, and Schmorl's nodes, but this difference was not statistically significant.

Because of the biomechanical forces present in the sport of gymnastics, certain etiologies of back injury and pain are more common in this sport and will be reviewed later in this article. Beyond these more common diagnoses, however, a gymnast still may present with other causes, such as inflammatory spondyloarthropathies, neoplasm, diskitis, osteomyelitis, or sickle cell disease, that should be explored if the clinical picture indicates. A detailed discussion of these will not take place in this article.

## CERVICAL SPINE FRACTURE

The risk of acute spinal trauma is real with gymnastics participation (37,40). Multiple flipping and twisting dismounts together with the possibility of slippage from grip events such as uneven bars, horizontal bar, and rings place these athletes at risk. With the utilization of supervision techniques and safety equipment, catastrophic spinal cord injury is a relatively rare occurrence (4). Improvements in safety equipment have included, among many, the development of improved foam landing and crash safety mats, foam pits for skill training, and more recently, a change in the structure of the vaulting horse to allow for improved and more consistent hand placement.

The most recently published data on spinal cord injury during gymnastics participation was presented by Schmitt and Gerner from the University of Heidelberg Department

of Orthopedics (37). Data analyzed from 1985-1997 revealed six gymnasts with acute spinal cord injuries. Earlier data from Silver et al. was presented in two papers and analyzed acute spinal injuries in sport in the United Kingdom (40,41). Among the main causes of sport accidents was gymnastics, and among those, 35 of 38 involved the cervical spine. Lack of supervision and a mismatch between the ability of the performer and the level of skill attempted were the most commonly attributed causes.

## SPONDYLOLYSIS

Spondylolysis is well known as a common cause of back pain in athletes and is defined as a fatigue fracture of the vertebral arch usually occurring at the pars interarticularis and rarely occurring at the pedicle. Since its recognition, there have been multiple case series and reviews showing the high prevalence of spondylolysis in some adolescent athletic populations, including gymnastics (2,4,6,13,15,17, 18,22,26,30,35,38,43,44,48). In a gymnast with spondylolysis, these lesions are related to mechanical stress via repetitive hyperextension and rotation of the lumbar spine. Standaert and Herring, in 2000, summarized accepted theories on the pathophysiology of these lesions (45). The pathology results from either an initial traumatic microfracture with subsequent progressive fracture from repetitive stress or begins as a fatigue fracture from repetitive overload. A subset of pars defects is congenital; however, post-mortem studies of infants and the typical age at onset of pain suggest congenital defects to be rare (15).

The clinical presentation in this subset of athletes will be similar to that of the general population. In general, this will consist of local low back pain and can be associated with radiation of pain to the buttock or proximal lower extremity (45). In the gymnastic population this pain can be chronic, dull, achy, and exacerbated by certain gymnastics maneuvers (17). Activity-related symptoms will occur during hyperextension and rotation. Common activities in gymnastics that might exacerbate this type of injury are: the back walkover, back handspring, and bridging (hyperextension); front walkover, front-handspring, and yurchenko vaulting skills (hyperextension and axial load); rebounding or punching skills and dismount landings (increased axial load); and backward twisting skills (rotation). Typically, dance moves performed on women's floor exercise and during rhythmic gymnastics also place a strain on the vertebral column.

The physical exam can often be nonspecific. A previously described finding is the reproduction of pain with a one-legged hyperextension maneuver. This test is typically referred to as the "Stork" test. A unilateral lesion may result in pain when standing on the ipsilateral leg (30). This test also may stress other spinal structures and therefore should not be considered specific for a spondylolysis lesion. Thus a positive finding should be interpreted using the remainder of the clinical presentation. The neurologic examination should be normal in an athlete with an isolated spondylolysis lesion (45).

As mentioned, much has been published on spondylolysis in gymnasts. Standaert did a comprehensive review of the

imaging and management strategies of spondylolysis in gymnasts in 2002 (43). Several possible choices for the diagnostic imaging of a spondylolysis lesion are available and include plain radiographs, nuclear planar bone scan, single photon emission computed topography (SPECT), computed topography (CT), and magnetic resonance imaging (MRI). Numerous studies have been published examining the use of all these modalities in the diagnosis of spondylolysis in athletes; however, only two comparative studies have been done in an attempt to reach a final consensus on a primary imaging modality (5,29).

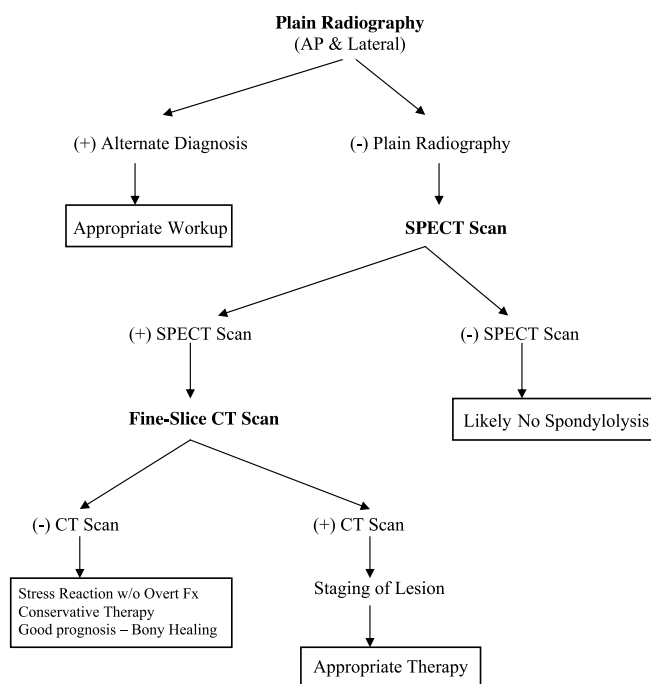
The main role of plain radiographs, AP and lateral views, should be to identify an associated spondylolisthesis lesion or other gross abnormality (43). Oblique plain radiographic images traditionally have been used as well to visualize a spondylolytic lesion. However, given the increased sensitivity and specificity of other imaging modalities and the subsequent increased use of these, some sports medicine practitioners choose to forgo the use of oblique images, using AP and lateral plain radiographs only as a tool to screen for spondylolisthesis or other abnormalities, as mentioned previously. Additionally, practitioners avoid oblique images in order to minimize gonadal exposure to ionizing radiation in athletes under the age of 18. SPECT scan has been shown to be more sensitive than both plain radiography and planar bone scan (14,22). The use of SPECT scan and plain radiography in combination together can be helpful. If oblique views are obtained and are negative but SPECT is positive, then the lesion is likely G1 yr old, and the prognosis for healing and success with conservative therapy is greater (15). Also of importance, a positive SPECT scan has been shown to correlate with painful pars lesions (44). Although SPECT scan is highly sensitive, CT has been shown to be more specific, and more recent data suggest the successful use of CT to predict the potential for bony healing (11,14). Fujii et al. noted multiple factors on CT that affect bony healing after conservative management including the stage of the defect, vertebral level, spondylolisthesis, and lumbar lordosis angle, among others (11). Therefore, it is recommended that a positive SPECT scan be followed by CT imaging to investigate further the source of the abnormality. Additionally, the reverse-angle gantry technique of CT imaging has been used to achieve images at a perpendicular angle to the plain of the suspected pars fracture (14). However, current CT technology allows for more fine-slice images and sagittal reconstructions, limiting the need for the reverse-angle gantry technique. A positive bone scan with normal CT imaging is another important combination of results that should be recognized during the workup of a suspected pars lesion. This may represent an early pars stress reaction without overt fracture that if caught early may result in good bony healing (44). An algorithmic approach to the use of plain radiography, SPECT scan, and CT is proposed in this article (Fig. 2). As consistent with above, oblique images are not included in this flow chart.

The use of MRI in athletes with suspected pars lesions is still unclear. Advantages may include the absence of ionizing radiation and the visualization of other potential etiologies of back pain. However, the literature still demonstrates limitations on the use of MRI in these patients.

Previously, MRI was thought to have a high false positive rate (14). More recently, comparative studies have been performed that show MRI's inability to identify pars lesions seen on SPECT scan and in those that were identified MRI lacked the ability to properly grade the lesions (5,29,44).

There are a number of different strategies for the management of spondylolysis available and still no clear consensus on which is the most efficacious. Controversy still surrounds the use of bracing. The controversy exists because of the lack of controlled trials, as well as multiple studies showing similar outcomes regardless of type of brace used as well as successful bony healing with brace therapy and without brace therapy (44). Adding to the confusion is the uncertainty of what constitutes a successful outcome. Theoretically, the ultimate goal is complete bony healing; however, multiple studies have shown decreased pain and return to sport despite nonunion (44). Overall, most would agree that after conservative management, the gymnast may return to the mat once he or she is pain-free and has met the goals of the management strategy regardless of whether there is evidence of radiographic healing (2). Management strategies should be directed individually and based upon the character and duration of the athlete's symptoms, radiologic workup, and his or her level of gymnastic participation and goals for the sport.

One comprehensive strategy presented in the 2002 Standard review contains a step-wise treatment algorithm for the management of spondylolysis in gymnasts (43). An initial rest phase is directed by clinical symptoms and the appearance of the lesion on CT. For acute or progressive lesions, bony



**Figure 2.** Radiologic workup for suspected spondylolysis lesion. AP, anteroposterior; (+), positive; (-), negative; SPECT, single photon emission computed topography; CT, computed topography; w/o, without; Fx, fracture.

healing should be attempted, and rest for 12 wk is suggested. As mentioned previously, if the SPECT scan is positive and the subsequent CT is normal, these gymnasts should be considered to have a high potential for bony healing and should enter a 12-wk period of rest as well. For terminal lesions, a period of rest until symptoms resolve is proposed. If resolution of pain is not achieved after 2 wk, bracing may be considered. The athlete then enters a phase of rehabilitation, progressing first through generalized range of motion and spine stabilization exercises to kinetic chain assessment, resistance training, and sport-specific retraining (43). A repeat CT scan, assessing for bony healing, may be obtained at 12 weeks if an athlete needs to be progressed more quickly through the initial rehabilitative phase (43,44). The progression of the gymnast back to the mat should account for the unique aspects and physical demand of gymnastics in order to direct a safe return and avoidance of recurrence.

After the athlete has achieved all goals of the rehabilitation program, can accomplish full and pain-free range of motion, has adequate strength and aerobic fitness, and is able to perform sport-specific skills without pain, successful return to the mat can be expected (43).

## SPONDYLOLISTHESIS

Spondylolisthesis is commonly discussed in concert with spondylolysis and is a potential cause of low back pain in the gymnast (4,17). This disorder is the translation of one vertebra on another and can occur in the anterior (anterolisthesis) or posterior (retrolisthesis) direction. There are two types: degenerative, which may result in anterolisthesis or retrolisthesis and results from intervertebral disc degeneration, and isthmic, an anterolisthesis resulting from bilateral spondylolysis lesions. Gymnasts are more likely to have an isthmic spondylolisthesis.

Spondylolisthesis is often noted on initial plain radiographs, but may also be diagnosed on CT scan (22). The concern for many sports medicine practitioners lies in the potential risk of progression of a spondylolysis lesion to spondylolisthesis or worsening of a low-grade spondylolisthesis during gymnastics participation. In general, the risk of progression of a low grade spondylolisthesis lesion is very low, between 4% or 5% of a general adolescent population in some studies, and the development of spondylolisthesis from spondylolysis is infrequent (26). It should be mentioned, though, that athletes at greatest risk for progression are those with baseline slippage of 950% and skeletal immaturity. Muschik et al. presented a study of 86 athletes (24 gymnasts), with spondylolysis or spondylolisthesis, 120 yr of age, followed over 5 yr, and noted in 38% of the athletes a development or progression of spondylolisthesis with an average increase of 10.5% (33). The remainder of athletes had no progression and a decrease in anterior translation was noted in seven athletes. All athletes were asymptomatic during the period of study and none of the athletes required surgical intervention. Low-grade symptomatic spondylolisthesis may be managed conservatively and management strategies may be similar to that for spondylolysis (2,6,26). In addition, skeletally immature gymnasts may be followed with standing

lateral radiographs every 12 months because of increased risk of progression (6,44).

## SCHEUERMANN'S DISEASE

Scheuermann's disease, also known as juvenile kyphosis, is defined by a constellation of radiographic findings which result in kyphosis of the thoracic or thoracolumbar spine and should be included in the differential for any adolescent gymnast with back pain. The thoracolumbar form of Scheuermann's disease, which encompasses both the thoracic and lumbar regions of the spine, is more common in athletes than nonathletes and also is considered to be associated more frequently with back pain (46,48). Among athletes, these radiographic changes are more prevalent among those sports that involve loading of the spine in flexion such as gymnastics (15).

Scheuermann's disease is characterized by anterior vertebral body wedging, endplate irregularity, disc space narrowing, and intravertebral disc herniations of the nucleus pulposus (Schmorl nodes) (22). Additional, more defined criteria used for diagnosis include: hyperkyphosis of greater than 40 degrees, wedging of 5 degrees or greater in 3 or more consecutive vertebrae, and irregular endplates with loss of disc space height (38) (Table). No definitive etiology of these findings has been identified, but one accepted cause is repeated or acute trauma of the immature spine, as is seen with adolescent athletes performing gymnastics (15).

With severe degrees of angulation, the presenting symptom is an associated cosmetic deformity in addition to pain. For a gymnast with back pain, however, pain may precede deformity. Pain is typically described as dull and achy, usually in the area of kyphosis, exacerbated by gymnastics activity and relieved with rest. Physical exam may or may not reveal a kyphotic deformity, depending on the severity of curvature, but will be more pronounced in forward flexion. Tenderness upon palpation usually is present above and below the apex of kyphosis. Neurologic exam is usually normal. An associated hyperlordosis below the level of involvement as well as a mild scoliosis can be seen (15). Plain radiographs will reveal the diagnostic criteria discussed previously. Bone scan

TABLE 1. Scheuermann's disease criteria.

Radiologic Characteristics	
	Anterior vertebral body wedging
	Endplate irregularity
	Disc space narrowing
	Schmorl's nodes
Diagnostic Criteria	
	Hyperkyphosis >40 degrees
	Wedging >5 degrees in three or more consecutive vertebral bodies
	Irregular endplates
	Disc space narrowing

is not necessary for diagnosis, but if performed will show increased uptake. MRI may be helpful to rule out diskitis if there is a concern. In addition, MRI will further evaluate Schmorl's nodes and disc prolapse beneath the vertebral apophyses (22).

Initial therapy with activity modification and back and core rehabilitation is similar to the recommended approach for spondylolysis. Bracing is typically indicated for kyphotic curves 95 degrees in the presence of skeletal immaturity (38). As with spondylolysis, rest and activity modification becomes the greatest challenge during the treatment of gymnasts. Skeletally immature gymnasts should be followed periodically to monitor for progression of kyphosis.

## SCOLIOSIS

Idiopathic scoliosis as a cause of back pain is still unclear. In one study, 30% of children with idiopathic scoliosis had back pain (34). Only 9% of those patients were found to have underlying pathology. Children in the study who had pain were usually older than 15 yr, had mature bones, had started their menstrual cycle and had a history of trauma. In the gymnastics population, this represents a smaller percentage of the cause of back pain. However, gymnastics is a very dynamic activity with the risk of trauma. Therefore, falls from the beam or high bar may unmask previously undiagnosed scoliosis. In general, gymnastics requires symmetrical development of the back musculature, as opposed to sports such as tennis, golf, or javelin with which the athlete may develop asymmetric hypertrophy of musculature leading to a false diagnosis of scoliosis (48). Therefore, similar exam techniques used for the general pediatric patient may be applied to the gymnastics population. One exception, however, does exist due to the common practice of twisting skills in gymnastics. During twisting maneuvers, a gymnast will always twist in one direction. This direction is established from early on in their participation in the sport and will not change. Repetitive, unidirectional twisting will result in asymmetric back musculature. Thus, asymmetry in a gymnast does not always correlate with the presence of scoliosis.

Scoliosis has been studied specifically in rhythmic gymnasts (50). Tanchev et al. studied 100 such gymnasts and found a 10-time higher incidence of scoliosis in this athletic population, 12% in this group compared with 1.1% in the control group. The authors propose a triad of generalized joint laxity, delayed maturity, and asymmetric spinal loading as a possible etiology. There have not been any follow-up studies to further examine scoliosis in this patient population. Whether rhythmic gymnastics should be considered a risk factor for the development of scoliosis needs further investigation; however, the proposed triad may be used to improve awareness of the potential increased prevalence in this population.

Standard radiologic workup with standing spinal films and Cobb angle measurements apply (22). If bracing is required, it is unclear whether pain-free participation in gymnastics while braced has a detrimental effect upon curvature progression. A case-to-case clinical decision given the

patient's degree of curvature, skeletal maturity, and gymnastics level is recommended.

## DISCOGENIC BACK PAIN

A high prevalence of disc degeneration has been noted in asymptomatic populations; therefore, it is difficult to predict disc disease as a pain generator (1). Lundinet al. reported a prospective study of back pain and radiologic changes in the thoracolumbar spine in athletes (27). They reported that reduction in disc-space height has the strongest correlation with the presence of low back pain and that the athlete was more likely to have low back pain the greater the number of levels involved. Gymnastics participation does appear to be a risk factor for development of disc disease. Swardet al. studied 24 male elite gymnasts and 16 male nonathletes with MRI imaging and found reduced disc signal intensity in 75% of the athletes compared with 31% in nonathletes (47). In addition, 11 of the 24 athletes had severe disc degeneration compared with 0 in the nonathlete group. This finding also correlated with a higher prevalence of back pain; however, there was also a correlation between reduced disc signal and the presence of other thoracolumbar abnormalities in the athlete group.

There can be a spectrum of disc injury and disease in gymnasts. Chronic mechanical loading has been shown to cause collagenous changes within the annulus fibrosis of the intervertebral disc. The lumbar spine of gymnasts is exposed to increased and repetitive mechanical loading. Subsequently, the disc abnormalities noted on MRI in gymnasts may represent this molecular change and a degenerative process of chronic mechanical stress (47). In addition to chronic degenerative change, gymnasts are at risk for acute disc injury. These injuries may range from acute annulus tears with little or no disc bulge to complete disc herniation with associated radiculopathy.

Disc disease has also been noted to have a higher prevalence in gymnasts when compared with athletes of other sports. Goldstein et al. performed an epidemiologic MRI study exploring the prevalence of disc abnormalities in the spines of gymnasts and swimmers (13). Five out of the eight national/Olympic caliber gymnasts had disc abnormalities compared with 2 out of 11 swimmers from a similar national level.

In a gymnast, the initial presentation can be similar to that seen in the general pediatric population. Pain may be subtle and only activity-related. Before pain, the first symptoms noted by the gymnast or coach may be loss of hamstring flexibility or inability to perform a pike stretch. Physical exam findings also may be minimal and isolated to a relative decrease in the ability to forward flex the spine with pain on reversal of motion. Weakness or changes in lower extremity reflexes are rare (30). Radiographic diagnosis is best made by MRI. A low signal intensity will be noted on T2-weighted images (22). On plain radiographs, the loss of disc-space height may be minimal.

A rehabilitation program developed by Cooke and Lutz, published in 2000, provides a comprehensive rehabilitation plan for the return to sport of an athlete with discogenic back

pain (7). The program consists of five stages. Stage I focuses on the initial stage of protected mobilization and therapeutic modalities to achieve return of lumbar and lower extremity range of motion. Stage II consists of opposing muscle contraction and isometric exercises involving the lumbar and abdominal musculature for dynamic spinal stabilization. The goal of Stage III is to achieve strength gains in lumbar muscles via neuromuscular recruitment. In Stage IV, the athlete returns to sport-specific activities once meeting three criteria: full and pain-free range of motion, the ability to maintain appropriate spinal posture during sport activity, and the return of pre-deficit strength and endurance. Stage V institutes a maintenance program for prevention or recurrence of pain.

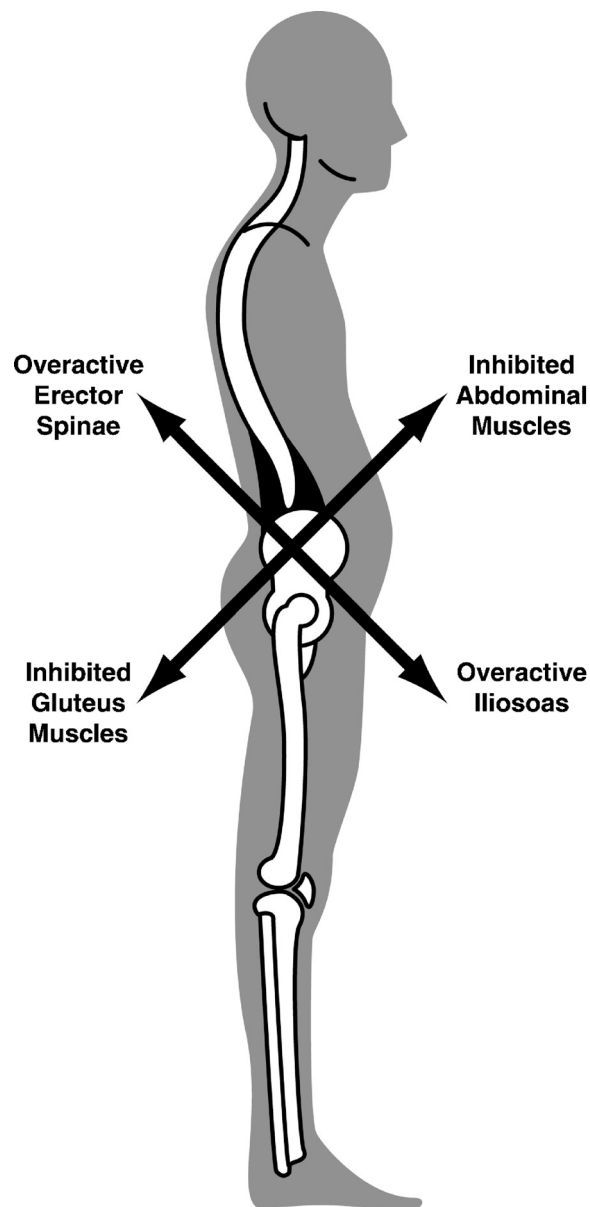
Beyond rehabilitation, bracing has been proposed in one study for the treatment of disc disease in adolescent athletes (31). In this study, Micheli et al. showed that the success rate for the treatment of disc disease with a brace was lower than brace therapy for spondylolysis. Future research is needed to investigate return to sport rates in athletes with disc disease following rehabilitation and bracing.

### NONSPECIFIC/MECHANICAL BACK PAIN

After a thorough history, physical, and radiographic workup has been performed, as directed by the clinical picture, a definitive diagnosis may still be unclear. This may be due to the complex interaction between the tissue structure and function of the low back, encompassing bone, muscle, fascia, nerve, etc. Injury to one of these tissues reflects upon the others and failure to evaluate fully each aspect can result in "treatment failure." Mechanical back pain often is considered secondary to a combination of structural imbalances, including but not limited to decreased mobility of the hips secondary to tight hip flexors, thoracic hyperkyphosis, lumbar hyperlordosis, tight hamstrings, and poor abdominal muscle strength (15). In addition to these, Micheli has noted a contribution to mechanical back pain from tight lumbodorsal fascia secondary to the adolescent growth spurt (30).

In comparison with many athletes, gymnasts require exceptional flexibility to perform the skills required in their sport. This flexibility, however, can result in a biomechanical imbalance within a given gymnast. This imbalance together with a thoracic hyperkyphotic and lumbar hyperlordotic posture noted in many gymnasts predisposes these athletes to mechanical back pain. In addition, gymnasts evaluated for back pain may exhibit a remarkable deficiency in core stabilization strength (primarily gluteal and transverse abdominus muscle groups) despite the overall level of strength required by their sport. As part of a thorough clinical back exam, the gymnast should undergo a comprehensive biomechanical examination to evaluate for underlying muscle weakness or inflexibility that may be contributing to the athlete's back pain. This identification can then be used to direct the athlete's rehabilitation.

Evaluation for the "Pelvic Crossed Syndrome" is an important part of the physical exam of mechanical low back pain (19) (Fig. 3). This syndrome is a "cross" between weak or inhibited gluteal and abdominal muscles and tight



**Figure 3.** Pelvic crossed syndrome. Depicts the relationship between biomechanical imbalances that can lead to mechanical back pain in a gymnast.

or over-activated erector spinae and iliopsoas muscles. This imbalance results in a cascade of other surrounding muscle imbalances including tight hamstrings, piriformis, and tensor fascia latae muscles. This combination of functional muscle changes results in biomechanical changes in sport performance, often leading to pain. Identification of these functional impairments rests in evaluation of both static strength and flexibility of the muscles as well as functional firing patterns and recruitment of the previously mentioned muscle groups. Evaluation of prone hip extension should elicit a muscle activation pattern, or firing pattern, with a predictable order. Variation or delay in this should prompt further evaluation. With a patient lying prone, active hip extension should result in progressive contraction of the

hamstring, gluteal, contralateral erector spinae then ipsilateral erector spinae muscles. Often, in patients with mechanical low back pain, the gluteal muscle is delayed, or never fires at all.

Important in assessment and treatment of the crossed pelvic syndrome is realization that the "weak" muscles are not weak because of disuse but instead because of inactivation secondary to the tight, hypertonic muscles. Merely "strengthening" the weak muscles will not result in adequate treatment, as the neural inhibition caused by the antagonistic tight muscles will not allow for full strengthening. In fact, spinal stabilization exercises, done without stretching, can worsen the problem. Instead, initial stretching of tight, hypertonic muscles often leads to the patient regaining full strength and normal recruitment patterns in the weak muscles.

As stated previously, gymnasts require extraordinary flexibility to perform in their sport. In the evaluation of flexibility, practitioners are encouraged to utilize input from the patient and coach about perceived "tightness." A gymnast may have decreased flexibility, yet show motion beyond the expected normal range. Determining and treating the tight muscles first, then addressing any residual weakness, can break the cycle of the pelvic crossed syndrome and allow for return of normal biomechanics to the back, thus eliminating pain.

Evaluation and treatment for osteopathic or chiropractic dysfunctions of the lumbar spine, sacrum, and innominate may also elicit diagnostic and treatment options to address mechanical low back pain. However, discussion of these topics is beyond the scope of this article.

## PSYCHOSOCIAL

The link between psychosocial factors and back pain in the general population as well as in children has been previously studied (25). The relationship between psychosocial stressors and athletic injury has also been explored. Kerr and Minden reported a positive relationship between the number of life stressors and the number and severity of injury in 41 elite female gymnasts over a 2-yr period of study (21). In their study, 83% of the gymnasts sustained injury, with 13% of these injuries involving the back. An additional study by Kolt and Kirkby out of Australia, included data from 162 competitive female gymnasts (23). They also showed the presence of life stressors to be a significant predictor of injury.

It is important to note that in gymnastics, the start of high-level competition, for most, begins in the adolescent years. Therefore, a health care provider must keep in mind the psychological stress this training and competition can place on these athletes and to be aware of the significance of psychosocial stress on the prevalence of injury in gymnastics. No study on the prevention of injury in gymnasts through life stressor intervention has been done and may be an area of future research.

## CONCLUSION

Back pain and the high rate of significant spinal pathology in the gymnastics population have been documented clearly in the medical literature and can present a diagnostic and

therapeutic challenge. Appropriate knowledge of the common causes of back pain and their subsequent workup and treatment are important to facilitate a safe and efficient return of a gymnast to their sport. Structural lesions, such as spondylolysis, spondylolisthesis, intervertebral disc pathology, and Scheuermann's disease, are among the potential causes of back pain in a gymnast, and knowledge of the biomechanics and demand of the sport of gymnastics helps to affirm the importance of recognizing these lesions. The workup and management of spondylolysis is still controversial, and more comparative studies are required to achieve a clear evidence-based strategy for the treatment of these lesions. Given that heavy training is required of skeletally immature and actively growing athletes in gymnastics, an adequate understanding of mechanical back pain and its treatment also is important. Additionally, in light of the high demand of the sport, psychosocial etiologies of pain also should be considered during the presentation of these athletes, commonly of adolescent age.

## References

1. Boden SD, Davis DO, Dina TS, et al. Abnormal magnetic resonance scans of the lumbar spine in asymptomatic subjects. A prospective investigation. *J. Bone Joint Surg. Am* 1990; 72:403Y8.
2. Bono CM. Current concepts review: low-back pain in athletes. *J. Bone Joint Surg* 2004; 86A:382 Y96.
3. Bruggeman GP. Biomechanics in gymnastics. *Med. Sport Sci* 1987; 25: 142Y76.
4. Caine D, Nassar L. Gymnastics Injuries. In: *Epidemiology of Pediatric Sports Injuries*. Caine DJ, Maffulli N, eds. Individual Sports. Med Sport Sci. Basel, Karger. 2005; 48:18 Y58.
5. Campbell RS, Grainger AJ, Hide IG, et al. Juvenile spondylolysis: a comparative analysis of CT, SPECT, and MRI. *Skeletal. Radiol* 2005; 34:63Y73.
6. Cavalier R, Herman MJ, Cheung EV, et al. Spondylolysis and spondylolisthesis in children and adolescents: I. Diagnosis, natural history, and nonsurgical management. *Am. Acad. Orthop. Surg* 2006; 14:417Y24.
7. Cooke PM, Lutz GE. Internal disc disruption and axial back pain in the athlete. *Phys. Med. Rehabil. Clin. N. Am.* 2000; 11:837Y65.
8. Deyo RA, Mirza SK, Martin BI. Back pain prevalence and visit rates. *Spine* 2006; 31:2724Y7.
9. Feldman DS, Hedden DM, Wright JG. The use of bone scan to investigate back pain in children and adolescents. *J. Pediatr. Orthop* 2000; 20:790Y5.
10. Frymoyer JW, Cats-Baril WL. An overview of the incidences and costs of low back pain. *Orthop. Clin. N. Am.* 1991; 22:263Y71.
11. Fujii K, Katoh S, Sairyo K, et al. Union of defects in the pars interarticularis of the lumbar spine in children and adolescents: the radiologic outcome after conservative treatment. *J. Bone Joint Surg. Br* 2004; 86:225Y31.
12. Goldberg MA. Gymnastic injuries. *Orthop. Clin North Am* 1980; 11: 717Y24.
13. Goldstein JD, Berger PE, Windler GE, et al. Spine injuries in gymnasts and swimmers. An epidemiologic investigation. *Am. J. Sports Med* 1991; 19:463Y73.
14. Harvey CJ, Richenberg JL, Saifuddin A, et al. Pictorial review: the radiological investigation of lumbar spondylolysis. *Clin. Radiol.* 1998; 53:723Y8.
15. Hollingworth P. Back pain in children. *Br. J. Rheumatol* 1996; 35: 1022Y8.
16. Hutchinson MR. Low back pain in elite rhythmic gymnasts. *Med. Sci. Sports Exer* 1999; 31:1686.
17. Jackson DW, Wiltse LL, Cirincione RJ. Spondylolysis in the female gymnast. *Clin. Orthop. Relat. Res.* 1976; 117:68Y73.
18. Jackson DW, Wiltse LL, Dingeman RD, et al. Stress reactions involving the pars interarticularis in young athletes. *Am. J. Sports Med* 1981; 9: 304Y12.



19. Jull G, Janda V. Muscles and motor control in low back pain. In: Physical Therapy for the Low Back: Clinics in Physical Therapy. Twomey and Taylor J.R., eds. New York, NY: Churchill Livingstone, 1987, pp. 253Y78.
20. Katz DA, Scerpella TA. Anterior and middle column thoracolumbar spine injuries in young female gymnasts. Report of seven cases and review of literature. *Am. J. Sports Med* 2003; 31:611Y6.
21. Kerr GA, Minden H. Psychological factors related to the occurrence of athletic injuries. *J. Sport Exer. Psych* 1988; 10:167Y73.
22. Khoury NJ, Hourani MH, Arabi MM, et al. Imaging of back pain in children and adolescents. *Curr. Probl. Diagn. Radiol* 2006; 35:224Y44.
23. Kolt G, Kirkby R. Injury in Australian competitive gymnasts: a psychological perspective. *Aust. J. Physiother* 1996; 42:121Y6.
24. Leboeuf-Yde C, Kyvik KO. At what age does low back pain become a common problem? A study of 29,424 individuals aged 11 years. *Spine* 1998; 23:228Y34.
25. Linton SJ. A review of psychological risk factors in back and neck pain. *Spine* 2000; 9:1148Y56.
26. Lonstein JE. Spondylolisthesis in children: cause, natural history, and management. *Spine* 1999; 24:2640Y8.
27. Lundin O, Hellstrom M, Nilsson I, et al. Back pain and radiologic changes in the thoraco-lumbar spine of athletes: a long-term follow-up. *Scand. J. Med. Sci. Sports* 2001; 11:103Y9.
28. Marshall SW, Covassin T, Dick R, et al. Descriptive epidemiology of collegiate women's gymnastics injuries: National Collegiate Athletic Association Injury Surveillance System, 1988Y1989 Through 2003Y2004. *J. Athl. Train.* 2007; 42:234Y40.
29. Masci L, Pike J, Malara F, et al. Use of the one-legged hyperextension test and magnetic resonance imaging in the diagnosis of active spondylolysis. *Br. J. Sports Med* 2006; 40:940Y6.
30. Micheli LJ. Back injuries in gymnastics. *Clin. Sport Med* 1985; 4:85Y92.
31. Micheli LJ, Hall JF, Miller ME. Use of the modified Boston brace for back injuries in athletes. *Am. J. Sports Med* 1980; 8:351Y6.
32. Micheli LJ, Wood R. Back pain in young athletes: significant differences from adults in causes and pattern. *Arch. Pediatr. Adolesc. Med* 1995; 149:15Y8.
33. Muschik M, Hahnel H, Robinson PN, et al. Competitive sports and the progression of spondylolisthesis. *Pediatr. Orthop* 1996; 16:364Y9.
34. Ramirez N, Johnston CE, Browne RH, et al. The prevalence of back pain in children who have idiopathic scoliosis. *J. Bone Joint Surg* 1997; 79A:364Y8.
35. Rossi F, Dragoni S. Lumbar spondylolysis: occurrence in competitive athletes. Updated achievements in a series of 390 cases. *Sports Med. Phys. Fitness* 1990; 30:450Y2.
36. Sands WA, Shultz BB, Newman AP. Women's gymnastics injuries. A 5-year study. *Am. J. Sports Med* 1993; 21:271Y6.
37. Schmitt H, Gerner HJ. Paralysis from sport and diving accidents. *Clin. J. Sport Med* 2001; 11:17Y22.
38. Shilt JS, Barnett TM. Evaluating and managing back pain in children. *J. Musculoskeletal Med* 2007; 24:73Y86.
39. Singh S, Smith GA, Fields SK, et al. Gymnastics-related injuries to children treated in emergency departments in the United States, 1990Y2005. *Pediatrics* 2008; 121:e954Y60.
40. Silver JR. Spinal injuries in sports in the UK. *Br. J. Sports Med* 1993; 27:115Y20.
41. Silver JR, Silver DD, Godfrey JJ. Injuries of the spine sustained during gymnastic activities. *Br. Med. J. (Clin. Res. Ed.)* 1986; 293:861Y3.
42. Skaggs DL, Early SD, D'Ambra P, et al. Back pain and backpacks in school children. *J. Pediatr. Orthop* 2006; 26:358Y63.
43. Standaert CJ. New strategies in the management of low back injuries in gymnasts. *Curr. Sports Med. Rep* 2002; 1:293Y300.
44. Standaert CJ, Herring SA. Expert opinion and controversies in sports and musculoskeletal medicine: the diagnosis and treatment of spondylolysis in adolescent athletes. *Arch. Phys. Med. Rehabil* 2007; 88:537Y40.
45. Standaert CJ, Herring SA. Spondylolysis: a critical review. *Br. J. Sports Med* 2000; 34:415Y22.
46. Sward L, Hellstrom M, Jacobsson B, et al. Back pain and radiologic changes in the thoraco-lumbar spine of athletes. *Spine* 1990; 15:124Y9.
47. Sward L, Hellstrom M, Jacobsson B, et al. Disc degeneration and associated abnormalities of the spine in elite gymnasts. A magnetic resonance imaging study. *Spine* 1991; 16:437Y43.
48. Sward L. The thoracolumbar spine in young elite athletes: current concepts on the effects of physical training. *Sports Med* 1992; 13:357Y64.
49. Taimela S, Kujala UM, Salminen JJ, et al. The prevalence of low back pain among children and adolescents: a nationwide, cohort-based questionnaire survey in Finland. *Spine* 1997; 22:1132Y6.
50. Tanchev PI, Dzherov AD, Parushev AD, et al. Scoliosis in rhythmic gymnasts. *Spine* 2000; 25:1367Y72.