

- comparison with medical health states. *Ophthalmology* 2003; 110: 1076–81.
48. Chia EM, Wang JJ, Rochtchina E, Smith W, Cumming RR, Mitchell P. Impact of bilateral visual impairment on health-related quality of life: the Blue Mountains Eye Study. *Invest Ophthalmol Vis Sci* 2004; 45: 71–6.
49. West CG, Gildengorin G, Haegerstrom-Portney G, Schneck ME, Lott L, Brabyn JA. Is vision function related to physical functional ability in older adults? *J Am Geriatr Soc* 2002; 50: 136–45.
50. Gallagher M, Yip B, Viridi M, Martin BJ. Retinal screening in patients attending a fast track TIA clinic. *Age Aging* 2004; 33 (Suppl. 2): ii44.
51. Carey S. The care of elderly people in hospital – the orthoptist's role. *Br Orthopt J* 1993; 50: 51–3.

Received 6 December 2005; accepted in revised form 23 May 2006

Age and Ageing 2006; 35: 565–571 © The Author 2006. Published by Oxford University Press on behalf of the British Geriatrics Society. doi:10.1093/ageing/af1108 All rights reserved. For Permissions, please email: journals.permissions@oxfordjournals.org
Published electronically 18 September 2006

Sporadic cerebral amyloid angiopathy—an important cause of cerebral haemorrhage in older people

BHOMRAJ THANVI, TOM ROBINSON

Leicester General Hospital, Medicine for the Care of Older People, Leicester, UK

Address correspondence to: B. Thanvi. Email: bthanvi@hotmail.com

Abstract

Cerebral amyloid angiopathy (CAA) is an important cause of primary intracerebral haemorrhage (PICH) in older people, accounting for ~10% of all types of PICH. The amount of amyloid deposition in the vessels and vasculopathic changes determine the propensity to PICH. The risk factors of CAA include advanced age and the presence of certain alleles of apolipoprotein E. There are no specific clinical features of CAA-related PICH, although lobar, recurrent or multiple simultaneous haemorrhages in older patients should raise suspicion of its diagnosis. A definitive diagnosis of CAA requires pathological examination of the affected tissue. However, with modern imaging techniques, it is possible to make a diagnosis of 'probable CAA' in patients presenting with PICH. Gradient-echo magnetic resonance imaging is a sensitive, non-invasive technique for identifying small haemorrhages in life. Currently, there is no specific treatment available for CAA. Recent advances in the immunopathology and pathogenesis of CAA are expected to help in developing specific anti-amyloid therapy.

Keywords: cerebral amyloid angiopathy, primary intracerebral haemorrhage, older people, elderly

Introduction

Cerebral amyloid angiopathy (CAA) is a clinicopathological condition resulting from the extracellular deposition of an amorphous eosinophilic substance (a fibrillar protein, amyloid) in the walls of small- and medium-sized arteries. When stained with Congo red and viewed under polarising microscope, this substance gives a yellow–green birefringence, and therefore, this entity is also known as congophilic angiopathy. The earlier reports emphasised the association of cerebral amyloid with Alzheimer's disease. It is now clear that CAA may occur in the absence of clinical and/or path-

ological evidence (e.g. amyloid plaques) of dementia. Although CAA can manifest in several ways, the most serious manifestation of CAA in older people is the rupture of cerebral vessels, leading to primary intracerebral haemorrhage (PICH). PICH account for ~10% of all strokes in the United Kingdom [1], but there are racial and geographical variations across the globe as it is more common in some parts of Asia, e.g. Japan [2], and in blacks [3]. The incidence of PICH increases with age [3].

CAA mostly occurs in the sporadic form. Rare familial forms occur in younger age and include hereditary cerebral haemorrhage with amyloid—Icelandic, Dutch and Finnish

types (HCHWA-I, HCHWA-D and HCHWA-F), familial amyloid angiopathy with deafness and ocular haemorrhage and familial British dementia with amyloid angiopathy.

It is difficult to make a definitive diagnosis of CAA in life, as it requires pathological examination of the brain tissue. Recent developments in brain imaging techniques have greatly helped in allowing a diagnosis of ‘probable CAA’ to be made. Our understanding of the biology of cerebral amyloid has also greatly improved. Unfortunately, specific therapy for CAA is currently unavailable.

Epidemiology and risk factors

The accurate prevalence and incidence rates for CAA are difficult to ascertain due to the difficulties in making a definitive diagnosis in life. The prevalence of CAA increases with age, and it is rare under the age of 55 years. It affects both sexes equally. In a post-mortem study of 84 brains removed from patients aged 60–97 years, some degree of CAA was found in 36% of all brains examined, with increasing proportion of patients affected in each successive decade of life [4]. In unselected autopsies, CAA has been reported in up to 60% of older people >90 years of age [5]. CAA is responsible for ~10% of all types of PICH [6]. However, this proportion rises up to 30% in lobar type of PICH [7]. In a recent study of consecutively encountered patients, CAA accounted for 74% cases of lobar PICH [8]. The authors of the study suggest that a higher proportion of CAA-related PICH as compared with the hypertension-related PICH could be due to the improved management of hypertension with modern antihypertensive therapy. CAA may play an important role in warfarin-related PICH [9].

In a pathological study of 117 brains from patients with Alzheimer’s disease, moderate to severe CAA was noted in 25.6% and CAA-related PICH in 5% [10]. Although Alzheimer’s disease and CAA have a close molecular relationship and frequently co-exist, majority of patients with CAA-related PICH do not show clinical evidence of dementia prior to the initial bleed [11].

Hypertension, the most important risk factor for PICH caused by the rupture of the deep penetrating arteries, has not been shown to predispose to CAA-related PICH [12]. There are no data to suggest diabetes mellitus and ischaemic heart disease as risk factors for CAA-related PICH. Although epidemiological studies suggest a link between low serum cholesterol and increased incidence of PICH [13], they have not specifically analysed CAA-related PICH.

The role of apolipoprotein E (APOE) as a risk factor for CAA is discussed below.

Pathology and pathogenesis

In CAA, there is a localised deposition of amyloid in the media and adventitia of the small arteries, arterioles, veins and capillaries of the cortex and leptomeninges. The haemorrhages in CAA are mostly ‘lobar’ (in the subcortical white matter of the cortical lobes with a tendency to extend parallel to the overlying cortex) [4]. In the post-mortem examination, the frontal and parietal lobes are most commonly affected sites in CAA [12], although a recent study using gradient-echo magnetic resonance imaging (MRI) in probable CAA reported preferential distribution in the temporal and occipital lobes [14].

The characterisation of cerebral microvascular amyloid from patients with Alzheimer’s disease and Down’s syndrome by Glenner and Wong [15] was a major advance in our understanding of the molecular biology of CAA. This protein, subsequently termed as Aβ peptide, is the main constituent of both vascular amyloid and the amyloid seen in plaques of Alzheimer’s disease. Aβ peptides are 39–43 amino acid fragments derived from a much larger molecule of 695–770 amino acid sequence, amyloid precursor protein (APP). Aβ peptides with carboxyl termini extending to position 42 or 43 (known as Aβ 42) are presumably the initial trigger for amyloid aggregation in both vessels and plaques [16]. Aβ 40 (Aβ peptides with carboxyl termini extending to position 39 or 40) is found in more severely involved vessels [17].

Amyloid deposition in the cerebral blood vessels is known to occur in normal older people with no evidence of PICH. It is proposed that the combination of a greater amount of amyloid and vasculopathic changes (cracking and fibrinoid necrosis) in the amyloid-laden vessel walls is indicative of a high risk of haemorrhages in CAA [18]. Table 1 describes the grades of vasculopathic changes in the order of severity as proposed by Greenberg and Vonsattel [18].

The source of Aβ in CAA is primarily neuronal [10], although vascular smooth-muscle cells (VSMCs) are another possible source [19]. It is possible that locally produced Aβ simply accumulates in the vessel walls, leading to injury to the VSMCs. With neuronal origin, the vascular deposition of Aβ could result from the reduced solubility or interference with the drainage of Aβ peptides along periarterial interstitial fluid pathways [20].

In CAA, amyloid is deposited close to the regions of the basement membrane. The adjacent VSMCs show degeneration in CAA. It is suggested that amyloid can decrease VSMC viability by disrupting VSMC–extracellular matrix

Table 1. Pathological grading of cerebral amyloid angiopathy (CAA) [18]

Grade	Description
0	Denotes the absence of congophilic staining in vessels
1	Amyloid deposits present in the otherwise normal artery as a congophilic rim around muscle fibres
2	The media of the vessel is fully replaced by amyloid, and the wall is thickened
3	The blood vessel shows total congophilic replacement of the media and cracking of the vessel wall that creates a ‘vessel-within-vessel’ appearance affecting at least 50% of the circumference of the vessel
4	The vessel develops scarring and fibrinoid necrosis

adhesion [21]. Head injury [22] and the use of thrombolytics or anticoagulants [9] may act as triggers in some cases.

Sporadic CAA and CAA-related haemorrhages (CAAHs) have been associated with several gene polymorphisms, including APOE, presenilin 1 and alpha1-antichymotrypsin [23]. The importance of APOE in the pathology of CAA has been well demonstrated in animal experiments using transgenic mice [24].

As for the APOE, the ε4 allele is associated with CAA [25] and the ε2 with CAAH [26]. The relationship between Aβ length and the APOE ε2 allele may be important in the pathogenesis of CAAH [26]. A high Aβ 40:42 ratio favours vascular over parenchymal amyloidosis [10]. APOE ε2 increases Aβ40 seeding of cortical blood vessels [27]. This causes microvascular damage leading to PICH [28]. The blood vessels in such cases exhibit severe luminal compromise secondary to Aβ 40 deposition and fibrinoid necrosis [17].

Interestingly, the incidence of ε4 allele was found to negatively correlate with age in CAA with or without PICH [29]. Lower age at death was significantly associated with ε4. In the authors' view, the possession of ε4 does not by itself confer an increased risk of CAA but may be associated with reduced longevity even in the absence of dementia or cerebral haemorrhage.

The abnormalities in the composition of vascular basement membrane (VBM) can lead to microvascular injury and cerebral haemorrhage. The mutations in a gene encoding for type IV collagen alpha-1 (COL4A1), a basement membrane protein, have been described in mouse models and in a human family with small-vessel disease [30]. These abnormalities could account for some familial forms of intracerebral haemorrhage and white matter lesions. Similar abnormalities of VBM have not been reported in the sporadic form of CAA.

The association of advancing age with CAA suggests that cerebrovascular disease may play a role in its pathogenesis. There is some evidence that cerebrovascular disease impedes the elimination of amyloid protein along perivascular pathways and contributes to the pathogenesis of CAA [31]. The pathogenesis of CAA-related PICH could be schematised as follows (Figure 1).

Clinical features

CAA is a disease of older people. Although PICH and dementia are the most well-recognised manifestations, CAA can present in several ways (Table 2). Progressive dementia can be found in 10–30% of patients, and pathological evidence of neuritic plaques is observed in ~50% of cases with CAA. Cerebral infarcts, particularly on the background of cognitive impairment, although less common than PICH, are well recognised. Episodes of transient focal neurological deficit suggestive of transient ischaemic attacks or partial seizure can also occur. These may occur days to weeks before the major haemorrhage and may be related to small haemorrhages on multiple sites seen on gradient-echo MRI sequences [32].

PICH due to CAA tend to be lobar (due to the involvement of superficial cortical and leptomeningeal vessels) and

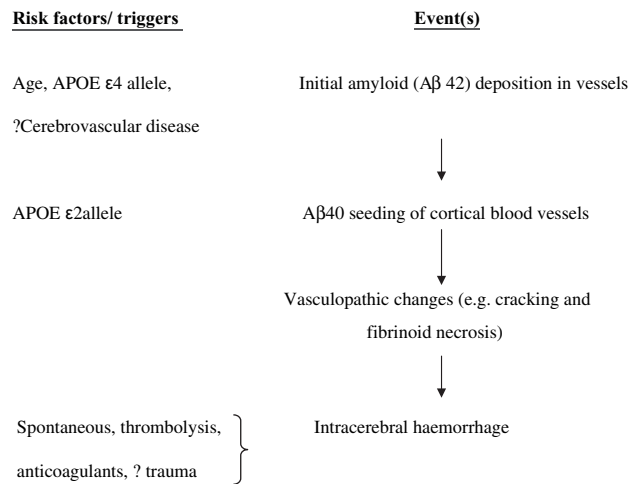


Figure 1. Schematic representation of steps in the pathogenesis of cerebral amyloid angiopathy-related cerebral haemorrhage.

Table 2. Recognised clinical manifestations of cerebral amyloid angiopathy (CAA)

Primary intracerebral haemorrhage
Dementia
Cerebral infarcts
Transient ischaemic attacks
Seizures
Subarachnoid haemorrhage
CAA-related central nervous system vasculitis

recurrent or multiple simultaneous (widespread nature of the angiopathy). Hypertension is less commonly associated with lobar haemorrhages [33].

There is no pathognomonic clinical feature of CAAH. Headache, focal neurological deficit, seizures and altered level of consciousness occur depending on the size and location of haemorrhage, although headache and seizures are more common in lobar than in deep haemorrhages. The coma on admission is less frequent—probably related to the peripheral location of the haematoma [33] and cerebral atrophy in older people. PICH due to CAA can be small and asymptomatic.

The following criteria have been proposed to diagnose CAA-associated PICH [see the table Appendix 1 in the supplementary data on the journal website (<http://www.ageing.oxfordjournals.org>)] [34]. They have recently been validated in a clinicopathological study [8]. In this study, 13 subjects were diagnosed clinically with probable CAA from among 39 patients with available pathologic tissue in a prospective cohort of older patients with primary lobar haemorrhage. All 13 individuals were confirmed neuropathologically as having CAA.

In a study that compared the clinical features of PICH due to CAA and those due to hypertension, the features of CAA-related PICH included lobar distribution affecting mainly lobar superficial areas, multiplicity of haemorrhage (defined as

two or more separate haematomas in multiple lobes), bilaterality, and repeated episodes, lobulated appearance, rupture into the subarachnoid space, and secondary intraventricular haemorrhage from the lobar haemorrhage [35].

A recent review on the pathophysiology of PICH describes interesting differences in the pathophysiological mechanisms underlying CAA-related lobar bleeds and hypertensive deep bleeds [36]. According to the authors, CAA results from the failure of egress of A β peptides after APP cleavage within brain parenchyma. The lobar distribution of changes reflects an impairment of amyloid removal from brain interstitial fluid and Virchow–Robin spaces due to the lower pulse pressure and bulk flow. On the contrary, the high pulse pressure and brisk interstitial fluid pumping in Virchow–Robin spaces deep within the brain protects against amyloidosis while leaving basal arterioles vulnerable to hypertensive damage.

An important manifestation of CAA is PICH caused by therapy with anticoagulants or thrombolytic agents. In a recent study, most of the warfarin-related PICH (76%) occurred with an international normalised ratio of ≤ 3.0 , and APOE $\epsilon 2$ allele was over-represented among patients with warfarin-associated lobar haemorrhage [9]. As these bleeds tend to occur commonly in older people, it raises an interesting question whether individual's risk of CAA should be included in the decision making while using anticoagulants or thrombolysis.

Imaging studies in CAA-associated PICH

Computerised tomography (CT) and MRI of brain are commonly used to diagnose PICH. CT scan is often the initial investigation as it is widely available, is relatively inexpensive and can be used in emergency situations. In a study to review the CT features of intracerebral haemorrhage pathologically proven to be associated with CAA, the haemorrhages appeared large, lobar, often extended through the cortex to the subarachnoid space or into the ventricles, and were multiple and recurrent in patients who survived the initial bleed [37]. In anticoagulation-related haemorrhage, a blood–fluid level can be seen caused by the sedimentation of red blood cells in a haematoma that does not clot in the presence of the anticoagulation. Although useful in diagnosing PICH, CT provides limited information regarding the underlying cause. Moreover, it may be difficult to differentiate PICH from a haemorrhagic transformation of an ischaemic infarct on CT.

MRI is useful to diagnose underlying cause, e.g. arteriovenous malformations, tumour, microangiomas and even saccular aneurysms. Multiple haemorrhages, either simultaneous or separated by days to weeks, are quite typical of CAA-related PICH [38]. However, multiple intracerebral haemorrhages are not unique to CAA and can be caused by several other pathologies (Table 3). Gradient-echo (also called susceptibility-weighted) MRI is a sensitive, non-invasive technique for identifying small chronic haemorrhagic lesions. Small asymptomatic cerebral haemorrhages detectable by gradient-echo MRI are common, and their number may predict the risk of future haemorrhage [39]. PICH have also been associated with the white matter

Table 3. Causes of multiple intracerebral haemorrhages

Cerebral amyloid angiopathy
Thrombolytic therapy
Cerebral metastases: most typically from melanoma but also from lung, choriocarcinoma, hypernephroma, etc.
Cerebral venous thrombosis
Coagulation disorders
Cerebral vasculitis

lesions on MRI scans, suggesting the presence of an underlying small-vessel vasculopathy in these patients [40].

CAA may present as a space-occupying lesion (pseudotumour) on the brain imaging, and the real nature of this inflammatory granuloma may become obvious only after histological examination [41].

Functional imaging with positron emission tomography and single photon emission computerised tomography have recently been employed to identify and quantify A β *in vivo* in neurodegenerative diseases, e.g. Alzheimer's disease [42]. This has great potential implications for the accuracy in diagnosis, for the detection of pre-symptomatic stage and for monitoring the effect of putative anti-amyloid drugs in the future [42].

The demonstration of amyloid using special immunohistochemical tests on specimens obtained at neurosurgery is the only confirmatory test currently available to diagnose CAA in life [18].

Treatment and prevention of CAA-related PICH

Acute management

There is no specific therapy available for treating CAA. Acute PICH caused by CAA should be treated in the same way as PICH due to any other aetiology. There is no evidence to suggest a higher rebleeding risk with the surgical treatment of CAA-related PICH [43]. A recently reported randomised trial comparing early surgery versus initial conservative treatment in patients with spontaneous supratentorial intracerebral haematomas did not show a significant difference in the outcomes [44]. If surgery is undertaken, the specimen should be sent for histopathological and immunochemical examination. In anticoagulation-related PICH, appropriate therapy should be commenced to reverse anticoagulation. The prothrombin complex concentrates and recombinant activated factor VII have been shown to be effective in preventing haematoma expansion [45] but are associated with significant thrombotic risk.

Secondary prevention

Although hypertension does not appear to play a direct role in CAA-related PICH, it is sensible to treat high blood pressures for cardiovascular risk reduction. Advice on moderation of alcohol consumption is similarly important.

It appears prudent to avoid anticoagulation therapy after CAA-related PICH unless absolutely indicated, and survivors of lobar ICH with atrial fibrillation should not be

offered long-term anticoagulation [46]. The decision on the use of antiplatelet therapy should be individualised taking into consideration the patient's cardiovascular risk profile. Some authors have suggested routine use of gradient-echo MRI sequences to detect microbleeds in older people to avoid potentially dangerous anticoagulant or antiplatelet therapy [47]. In an observational study of survivors of intracerebral haemorrhage, antiplatelet use (mostly for ischaemic heart disease) was not associated with an excessive risk of haemorrhage recurrence [48].

Recently, there has been a great deal of interest in the development of putative anti-amyloid drugs. One such drug (Cerebril) has shown a good safety profile in phase 2 trials [49]. Cerebril is a small molecule designed to compete with glycosaminoglycans for binding to A β . The ongoing phase 3 trial should provide efficacy data.

Unfortunately, the trial of active immunisation with a vaccine including A β 1–42 fibrils had to be suspended due to the occurrence of meningoencephalitis in a subset of patients [50]. Most of the patients who had post-mortem examination showed severe CAA, suggesting that the mobilisation of A β from the parenchyma may cause at least a temporary increase in its deposition in the cerebral vasculature. A gene gun-mediated A β 42 gene vaccination has recently been developed that showed a high titre of anti-A β 42 antibodies, leading to a significant reduction of A β 42 deposition in mouse experiments [51]. Although shown to have beneficial effects on cognitive functions in transgenic mice, passive immunotherapy with anti-A β antibody did not show useful effects on CAA and rather had a negative effect [52].

Prognosis

As with PICH due to any cause, outcome depends on the size and site of bleeding, patient's age [53] and the level of consciousness. APOE ϵ 4 allele has also been associated with a higher mortality [49]. An in-hospital mortality of 24% was reported in patients >55 years with lobar PICH [54]. In the same study, mortality at 6 months rose to 32%.

White matter damage in lobar ICH is common and is associated with cognitive impairment [41]. It is possible that CAA can cause clinically important vascular dysfunction.

Major concern in the survivors of CAA-related PICH is the recurrent bleeding. A recurrence rate of 10% per year has been reported [21], which is much higher than for non-lobar haemorrhage. The burden of small asymptomatic cerebral haemorrhages detectable by gradient-echo MRI in patients with lobar PICH related to CAA is a good predictor of haemorrhage recurrence [39].

The recurrence of haemorrhage carries particularly poor prognosis with in-hospital mortality of up to 42% [52]. This highlights the importance of secondary prevention in CAA-related PICH.

Conclusions

CAA is an important cause of PICH in older people. Recent advances in immunopathology and pathogenesis of CAA are expected to help in developing specific anti-amyloid

therapy. Gradient-echo MRI is a sensitive, non-invasive technique for identifying small chronic haemorrhagic lesions in life. In a recent study, increased plasma A β 40 concentration was found to be independently associated with the extent of white matter hyperintensity in subjects with Alzheimer's disease, mild cognitive impairment or CAA. This opens an exciting possibility of circulating A β peptide serving as a novel biomarker or risk factor for these diseases in older people [55]. Recent phase 2 trials of Cerebril, a putative anti-amyloid agent, have given encouraging safety data. However, the data for clinical efficacy are still awaited. Until specific therapy for CAA is developed, treatment for CAA-related PICH remains similar to that for the other aetiologies.

Key points

- Sporadic CAA accounts for ~10% of all PICH in older people.
- The lobar, recurrent or multiple simultaneous haemorrhages in older patients should raise suspicion of its diagnosis.
- Although definitive diagnosis requires pathological examination of the affected tissue, with modern imaging techniques, it is possible to make a diagnosis of 'probable CAA' in patients presenting with PICH.
- Currently, specific therapy is not available to treat CAA-associated cerebral haemorrhage.

Conflicts of interest

None to declare.

References

1. Bamford J, Sandercock P, Dennis M, Burn J, Warlow C. A prospective study of acute cerebrovascular disease in the community: the Oxfordshire Community Stroke Project – 1981–86. 2. Incidence, case fatality rates and overall outcome at one year of cerebral infarction, primary intracerebral and subarachnoid haemorrhage. *J Neurol Neurosurg Psychiatry* 1990; 53:16–22.
2. Tanaka H, Ueda Y, Date C *et al.* Incidence of stroke in Shibata, Japan: 1976–1978. *Stroke* 1981; 12: 460–6.
3. Broderick JP, Brott T, Tomsick T, Huster G, Miller R. The risk of subarachnoid and intracerebral hemorrhages in blacks as compared with whites. *N Engl J Med* 1992; 326: 733–6.
4. Vinters HV, Gilbert JJ. Cerebral amyloid angiopathy: incidence and complications in the aging brain. II. The distribution of amyloid vascular changes. *Stroke* 1983; 14: 924–8.
5. Masuda J, Tanaka K, Ueda K, Omae T. Autopsy study of incidence and distribution of cerebral amyloid angiopathy in Hisayama, Japan. *Stroke* 1988; 19: 205–10.
6. Ishii N, Nishihara Y, Horie A. Amyloid angiopathy and lobar cerebral haemorrhage. *J Neurol Neurosurg Psychiatry* 1984; 47: 1203–10.
7. Itoh Y, Yamada M, Hayakawa M, Otomo E, Miyatake T. Cerebral amyloid angiopathy: a significant cause of cerebellar as well as lobar cerebral haemorrhage in the elderly. *J Neurol Sci* 1993; 116: 135–41.

8. Knudsen KA, Rosand J, Karluk D, Greenberg SM. Clinical diagnosis of cerebral amyloid angiopathy: validation of the Boston Criteria. *Neurology* 2001; 56: 537–9.
9. Rosand J, Hylek EM, O'Donnell HC, Greenberg SM. Warfarin-associated haemorrhage and cerebral amyloid angiopathy: a genetic and pathologic study. *Neurology* 2000; 55: 947–95.
10. Herzig MC, Van Nostrand WE, Jucker M. Mechanism of cerebral beta-amyloid angiopathy: murine and cellular models. *Brain Pathol* 2006; 16: 40–54.
11. Mandybur TI. Cerebral amyloid angiopathy: the vascular pathology and complications. *J Neuropathol Exp Neurol* 1986; 45: 79.
12. Vinters HV. Cerebral amyloid angiopathy. A critical review. *Stroke* 1987; 18: 311.
13. Segal AZ, Chiu RI, Eggleston-Sexton PM, Beiser A, Greenberg SM. Low cholesterol as a risk factor for primary intracerebral hemorrhage: a case-control study. *Neuroepidemiology* 1999; 18: 185–93.
14. Rosand J, Muzikansky A, Kumar A *et al.* Spatial clustering of hemorrhages in cerebral amyloid angiopathy. *Ann Neurol* 2005; 58: 459–62.
15. Glenner CG, Wong CW. Alzheimer's disease: initial report of the purification and characterization of a novel cerebrovascular amyloid protein. *Biochem Biophys Res Commun* 1984; 120: 885.
16. Jarrett JT, Berger EP, Lansbury PT. The carboxy terminus of the beta amyloid protein is critical for the seeding of amyloid formation: implications for the pathogenesis of Alzheimer's disease. *Biochemistry* 1993; 32: 4693–7.
17. Alonzo NC, Hyman BT, Rebeck GW, Greenberg SM. Progression of cerebral amyloid angiopathy: accumulation of amyloid-beta40 in affected vessels. *J Neuropathol Exp Neurol* 1998; 57: 353–9.
18. Greenberg SM, Vonsattel JG. Diagnosis of cerebral amyloid angiopathy sensitivity and specificity of cortical biopsy. *Stroke* 1997; 28: 1418–22.
19. Attems J. Sporadic cerebral amyloid angiopathy: pathology, clinical implications, and possible pathomechanisms. *Acta Neuropathol (Berl)* 2005; 110: 345–59 (Epub 17 September 2005).
20. Weller RO, Massey A, Kuo YM, Roher AE. Cerebral amyloid angiopathy: accumulation of A beta in interstitial fluid drainage pathways in Alzheimer's disease. *Ann N Y Acad Sci* 2000; 903: 110–7.
21. Mok SS, Losic D, Barrow CJ *et al.* The beta-amyloid peptide of Alzheimer's disease decreases adhesion of vascular smooth muscle cells to the basement membrane. *J Neurochem* 2006; 96: 53–64.
22. Kalyan-Raman UP, Kalyan-Raman K. Cerebral amyloid angiopathy causing intracranial haemorrhage. *Ann Neurol* 1984; 16: 321–9.
23. Yamada M. Cerebral amyloid angiopathy and gene polymorphisms. *J Neurol Sci* 2004; 226: 41–4.
24. Holtzman DM, Fagan AM, Mackey B *et al.* Apolipoprotein E facilitates neuritic and cerebrovascular plaque formation in an Alzheimer's disease model. *Ann Neurol* 2000; 47: 739–47.
25. Greenberg SM, Rebeck GW, Vonsattel JP, Gomez-Isla T, Hyman BT. Apolipoprotein E epsilon 4 and cerebral hemorrhage associated with amyloid angiopathy. *Ann Neurol* 1995; 38: 254–9.
26. McCarron MO, Nicoll JA. High frequency of apolipoprotein E epsilon 2 allele is specific for patients with cerebral amyloid angiopathy-related haemorrhage. *Neurosci Lett* 1998; 247: 45–8.
27. McCarron MO, Nicoll JA, Stewart J *et al.* Amyloid beta-protein length and cerebral amyloid angiopathy-related haemorrhage. *Neuroreport* 2000; 11: 937–40.
28. McCarron MO, Nicoll JA, Stewart J *et al.* The apolipoprotein E epsilon2 allele and the pathological features in cerebral amyloid angiopathy-related haemorrhage. *J Neuropathol Exp Neurol* 1999; 58: 711.
29. Love S, Nicoll JA, Hughes A, Wilcock GK. APOE and cerebral amyloid angiopathy in the elderly. *Neuroreport* 2003; 14: 1535–6.
30. Gould DB, Phalan FC, van Mil SE *et al.* Role of COL4A1 in small-vessel disease and hemorrhagic stroke. *N Engl J Med* 2006; 354: 1489–96.
31. Roher AE, Esh C, Kokjohn TA *et al.* Circle of Willis atherosclerosis is a risk factor for sporadic Alzheimer's disease. *Arterioscler Thromb Vasc Biol* 2003; 23: 2055–62.
32. Roch JA, Nighoghossian N, Hermier M *et al.* Transient neurologic symptoms related to cerebral amyloid angiopathy: usefulness of t(2)*-weighted imaging. *Cerebrovasc Dis* 2005; 20: 412–4 (Epub 28 May 2004).
33. Ropper AH, Davis KR. Lobar cerebral haemorrhages: acute clinical syndromes in 26 cases. *Ann Neurol* 1980; 8: 141–7.
34. Greenberg SM, Kunz DP, Hedley-Whyte ET *et al.* Weekly clinicopathological exercises. Case: 22-1996. *N Engl J Med* 1996; 335: 189.
35. Zhan RY, Tong Y, Shen JF *et al.* Study of clinical features of amyloid angiopathy hemorrhage and hypertensive intracerebral hemorrhage. *J Zhejiang Univ Sci* 2004; 5: 1262–9.
36. Auer RN, Sutherland GR. Primary intracerebral hemorrhage: pathophysiology. *Can J Neurol Sci* 2005; 32 (Suppl 2): S3–12.
37. Miller JH, Wardlaw JM, Lammie GA. Intracerebral haemorrhage and cerebral amyloid angiopathy: CT features with pathological correlation. *Clin Radiol* 1999; 54: 422–9.
38. Passero S, Burgalassi L, D'Andrea P, Battistini N. Recurrence of bleeding in patients with primary intracerebral haemorrhage. *Stroke* 1995; 26: 1189–92.
39. Greenberg SM, Eng JA, Ning M, Smith EE, Rosand J. Hemorrhage burden predicts recurrent intracerebral hemorrhage after lobar hemorrhage. *Stroke* 2004; 35: 1415–20.
40. Smith EE, Rosand J, Knudsen KA, Hylek EM, Greenberg SM. Leukoaraiosis is associated with warfarin-related hemorrhage following ischemic stroke. *Neurology* 2002; 59: 193–7.
41. Polivka M, Vallat AV, Woimant F *et al.* Cerebral amyloid angiopathy (CAA) with presentation as a brain inflammatory pseudo-tumour. *Clin Exp Pathol* 1999; 47: 303–10.
42. Mathis CA, Klunk WE, Price JC, DeKosky ST. Imaging technology for neurodegenerative diseases. Progress toward detection of specific pathologies. *Arch Neurol* 2005; 62: 196–200.
43. Izumihara A, Ishihara T, Iwamoto N, Yamashita K, Ito H. Postoperative outcome of 37 patients with lobar intracerebral hemorrhage related to cerebral amyloid angiopathy. *Stroke* 1999; 30: 29–33.
44. Mendelow AD, Gregson BA, Fernandes HM *et al.* 2005. Early surgery versus initial conservative treatment in patients with spontaneous supratentorial intracerebral haematomas in the International Surgical Trial in Intracerebral Haemorrhage (STICH): a randomised trial. *Lancet* 2005; 365: 387–97.
45. Mayer SA, Brun NC, Broderick J *et al.* Safety and feasibility of recombinant factor VIIa for acute intracerebral hemorrhage. *Stroke* 2005; 36: 74–9 (Epub 29 November 2004).
46. Eckman MH, Rosand J, Knudsen KA, Singer DE, Greenberg SM. Can patients be anticoagulated after intracerebral hemorrhage?

- A decision analysis. *Stroke* 2003; 34: 1710–6 (Epub 12 June 2003).
47. Walker DA, Broderick DF, Kotsenas AL, Rubino FA. Routine use of gradient-echo MRI to screen for cerebral amyloid angiopathy in elderly patients. *AJR Am J Roentgenol* 2004; 182: 1547–50.
 48. Viswanathan A, Rakich SM, Engel C *et al.* Antiplatelet use after intracerebral hemorrhage. *Neurology* 2006; 66: 206–9.
 49. Safety Data Presented for Cerebril at Neurology Meeting. Biotechnology Healthcare February 2005; Volume 2, No. 1.
 50. Orgogozo JM, Gilman S, Dartigues JF *et al.* Subacute meningoencephalitis in a subset of patients with AD after Abeta42 immunization. *Neurology* 2003; 61: 46–54.
 51. Qu B, Boyer PJ, Johnston SA, Hynan LS, Rosenberg RN. Abeta(42) gene vaccination reduces brain amyloid plaque burden in transgenic mice. *J Neurol Sci* 2006; 244: 151–8 (Epub 6 March 2006).
 52. Wilcock DM, Rojiani A, Rosenthal A *et al.* Passive immunotherapy against Abeta in aged APP-transgenic mice reverses cognitive deficits and depletes parenchymal amyloid deposits in spite of increased vascular amyloid and microhemorrhage. *J Neuroinflammation* 2004; 1: 24.
 53. Hemphill JC 3rd, Bonovich DC, Besmertis L *et al.* The ICH score: a simple reliable grading scale for intracerebral hemorrhage. *Stroke* 2001; 32: 891.
 54. O'Donnell HC, Rosand J, Knudsen KA *et al.* Apolipoprotein E genotype and the risk of recurrent lobar intracerebral hemorrhage. *N Engl J Med* 2000; 342: 240.
 55. Gurol ME, Irizarry MC, Smith EE *et al.* Plasma beta-amyloid and white matter lesions in AD, MCI, and cerebral amyloid angiopathy. *Neurology* 2006; 66: 23–9.

Received 12 January 2006; accepted in revised form 11 August 2006