

Sports Concussions and Aging: A Neuroimaging Investigation

Sebastien Tremblay¹, Louis De Beaumont^{2,6}, Luke C. Henry¹, Yvan Boulanger³, Alan C. Evans⁷, Pierre Bourgoïn⁴, Judes Poirier⁸, Hugo Théoret^{1,5} and Maryse Lassonde^{1,5}

¹Centre de Recherche en Neuropsychologie et Cognition, ²Montreal Sacré-Cœur Hospital Research Center, ³Department of Radiology, CHUM Hospital Saint-Luc, ⁴Department of Radiology and ⁵Sainte-Justine Hospital Research Center, University of Montreal, Montreal, Canada ⁶Department of Psychology, Université du Québec à Trois-Rivières, Trois-Rivières, Canada ⁷McConnell Brain Imaging Centre, Montreal Neurological Institute and ⁸Douglas Mental Health University Institute, McGill University, Montreal, Canada

Address correspondence to Maryse Lassonde, Department of Psychology, University of Montreal, C.P. 6128, Succ. Centre-Ville, Montreal, Quebec, Canada H3C 3J7. Email: maryse.lassonde@umontreal.ca

Recent epidemiological and experimental studies suggest a link between cognitive decline in late adulthood and sports concussions sustained in early adulthood. In order to provide the first in vivo neuroanatomical evidence of this relation, the present study probes the neuroimaging profile of former athletes with concussions in relation to cognition. Former athletes who sustained their last sports concussion >3 decades prior to testing were compared with those with no history of traumatic brain injury. Participants underwent quantitative neuroimaging (optimized voxel-based morphometry [VBM], hippocampal volume, and cortical thickness), proton magnetic resonance spectroscopy (¹H MRS; medial temporal lobes and prefrontal cortices), and neuropsychological testing, and they were genotyped for APOE polymorphisms. Relative to controls, former athletes with concussions exhibited: 1) Abnormal enlargement of the lateral ventricles, 2) cortical thinning in regions more vulnerable to the aging process, 3) various neurometabolic anomalies found across regions of interest, 4) episodic memory and verbal fluency decline. The cognitive deficits correlated with neuroimaging findings in concussed participants. This study unveiled brain anomalies in otherwise healthy former athletes with concussions and associated those manifestations to the long-term detrimental effects of sports concussion on cognitive function. Findings from this study highlight patterns of decline often associated with abnormal aging.

Keywords: aging, neuroimaging, sports concussion

Introduction

Sports-related concussions have received growing scientific and public attention over recent years. For one, the rapid increase of their reported incidence, now estimated to an annual occurrence of 1.6–3.8 million in the United States of America alone (Langlois et al. 2006), make them the most significant contributor to the silent epidemic of traumatic brain injuries (TBIs) affecting the global population (Kelly, 1999; Cassidy et al. 2004). Research conducted in young concussed athletes has also revealed diverse chronic alterations of brain function affecting the cognitive (Gaetz et al. 2000; Gosselin et al. 2006; De Beaumont, Brisson, et al. 2007; Theriault et al. 2011), affective (Chen et al. 2008), and motor domains (Cavanaugh et al. 2005; De Beaumont, Lassonde, et al. 2007; De Beaumont et al. 2011), regardless of time since injury. Attempts to explain these chronic perturbations metabolically have failed, in part because most brain metabolites, following an initial imbalance (Giza and Hovda, 2001; Henry et al.

2010; Vagnozzi et al. 2010), return to a normal equilibrium 30 days postinjury (Vagnozzi et al. 2010). Very recently, young asymptomatic concussed athletes were shown to exhibit impaired synaptic plasticity in the primary motor cortex that correlated with motor learning decline (De Beaumont et al. 2011), a finding suggesting that disrupted cellular mechanisms may relate to persistent brain function anomalies.

Sports-related concussions have also received a widespread media coverage because of the recent uncovering of important neuropathological and histological findings in the brains of deceased professional American football and ice hockey players (Miller, 2009). This emerging syndrome, known as chronic traumatic encephalopathy (CTE), is grossly characterized by an atrophy of the cerebral hemispheres, including the medial temporal lobes (MTLs), combined with the lateral ventricle volume expansion (McKee et al. 2009; Costanza et al. 2011; Gavett et al. 2011; Omalu et al. 2011). Microscopically, extensive tau-immunoreactive neurofibrillary tangles affect the superficial cortical layers of the frontal and temporal lobes. Although this pathology, initially termed *dementia pugilistica*, has been known to affect professional boxers for decades (Martland, 1928; Roberts et al. 1990), it has also been documented only recently in athletes with lower exposure to concussive and subconcussive blows to the head (McKee et al. 2009; Omalu et al. 2011). CTE is currently thought to result from multiple concussive impacts to the brain, although no experimental evidence thus far has established a causal relationship between the postmortem observations and mild TBIs.

Further, the growing interest in the long-term effects of sports concussion is partly based on the observation of clinically relevant cognitive and motor decline in aging concussed athletes (De Beaumont et al. 2009). While brain function anomalies detected in young asymptomatic athletes are not related to clinically significant impairments, those same anomalies found in the brains of retired athletes who sustained sports concussions >30 years ago were shown to relate to the insidious installation of measurable memory and motor system dysfunctions (De Beaumont et al. 2009). This interaction between the aging process and the persistent subclinical effects of concussions is substantiated by an epidemiological study that reported a 5-fold increased prevalence of diagnosis of a mild cognitive impairment (MCI) in retired professional American football players who sustained 3 concussions or more during their career (Guskiewicz et al. 2005). MCI is a clinical condition where patients exhibit cognitive decline without showing any impairment on activities

of daily living, which subsequently converts at an approximate rate of 10–20% annually into dementia (Petersen et al. 1999; Morris et al. 2001).

The recent emergence of these converging scientific findings on the long-term effects of sports concussion is currently fueling an important social debate regarding the safety of athletes and regulations over violent contact in sports, particularly for head shots. Unfortunately, this debate is hindered by a lack of controlled experimental studies demonstrating a causal relation between sports concussions and long-term deleterious consequences on brain tissue. Since most structural evidence of brain tissue damage comes from postmortem neuropathological studies, the latter anomalies have not yet been directly related to cognitive symptoms documented in retired concussed athletes.

Therefore, this study purports 2 main objectives: 1) To document possible structural anomalies of a brain tissue in vivo in retired athletes who sustained sports concussions in early adulthood and 2) to establish neurocognitive links between hypothesized structural and neurometabolic anomalies in retired concussed athletes with cognitive decline.

With prior postmortem investigations suggesting that deceased American football athletes exhibit abnormal ventricular enlargement combined with cortical thinning of the frontal, temporal, and parietal lobes (McKee et al. 2009; Omalu et al. 2011), it was hypothesized that retired concussed athletes would feature the same pattern of anomalies, although quantitatively lesser, on magnetic resonance imaging (MRI)-based measures of cerebral atrophy and cortical thickness. In addition, since former athletes with concussions were shown to exhibit decrements on episodic memory function, in which hippocampal structures are centrally implicated (De Beaumont et al. 2009), ^1H MRS was used to quantify the neurometabolite concentration in this region of interest (ROI). Finally, knowing that former athletes with concussions exhibited a reduced performance on a selective attention/executive task in association with the attenuated P3a electrophysiological component (De Beaumont et al. 2009), which is thought to reflect a frontal lobe dysfunction in allocating attentional resources to novel stimuli (Comerchero and Polich, 1999; Kopp et al. 2006), frontal lobe neurochemical composition was also investigated using ^1H MRS. This neuroimaging technique has proven to be sensitive to age (Haga et al. 2009), TBI (Brooks et al. 2001), as well as MCI (Chantal et al. 2004; Kantarci et al. 2007, 2008), showing neurochemical modifications of the brain parenchyma under all 3 conditions.

The second objective of the study was to establish neurocognitive links between hypothesized structural and neurometabolic anomalies in retired concussed athletes and their cognitive performance. Knowing that a previous study reported the episodic memory decline on standard neuropsychological examination in this population (De Beaumont et al. 2009), we attempted to replicate and detail those results using a neuropsychological test battery designed to preferentially assess memory function. As the CTE, the clinical profile also indicates various cognitive symptoms (McKee et al. 2009), tests of verbal fluency, attention, and information processing speed were added to the battery. Associations between the cognitive decline of retired concussed athletes and uncovered brain structural anomalies were then explored using correlational analyses. Finally, as age is considered to

be the primary risk factor of Alzheimer's disease (AD) (Lindsay et al. 2002), and an important factor of clinically significant cognitive decline in retired concussed athletes (Guskiewicz et al. 2005; De Beaumont et al. 2009), its effects on neurocognitive measures were modeled.

Materials and Methods

Participants

All 30 male participants included in this study were former university-level athletes between the ages of 51 and 75 recruited with the help of university athletics organizations. All participants played for their respective college or university ice hockey (70%) or American football (30%) team at the time they were students. Participants were included if they met all of the following criteria: No history of alcohol abuse and/or substance abuse; no medical condition requiring daily medication or radiotherapy (malignant cancers, diabetes, hypertension, and/or other cardiovascular diseases); no previous history of psychiatric illness, learning disability, neurological history (seizure or brain tumour), or TBI unrelated to contact sports. Participants included in the present study had no history of concussion after their university years. To better control for data contamination due to the protective properties of regular physical activity on the development of AD (Lindsay et al. 2002), participants had to report engaging regularly in physical activity at least 3 times a week at the time of testing and have maintained this level of activity since the end of their athletic career. In addition, all participants had a body mass index <30 kg/m², according to the criteria for obesity of the World Health Organization.

Participants were divided into 2 groups. The experimental group consisted of 15 former university-level athletes with a mean age of 60.87 years (standard deviation [SD] 7.51) and a mean level of education of 16.67 years (SD 4.07) who sustained their last sports concussion in early adulthood (mean 24.00 and SD 4.55). A standardized concussion history questionnaire (Collins et al. 2002) was administered in an interview setting by a sports physician to obtain detailed information about the number of previous concussions, their approximate date, the description of the accident, and the nature and duration of on-field postconcussion severity markers (confusion and/or disorientation, retrograde and/or anterograde amnesia, and loss of consciousness [LOC]). Concussion was defined according to the latest definition provided by the 2009 Consensus Statement on Concussion in Sports (McCrory et al. 2009) as "a complex pathophysiological process affecting the brain, induced by traumatic biomechanical forces, that results in the rapid onset of short-lived impairment of neurologic function that may or may not include loss of consciousness (LOC)." Using this methodology, we sought to retrospectively diagnose concussions that might have gone unnoticed by some participants who played their sport at a time where LOC was considered a necessary condition for the diagnosis. Two participants who could not recollect sufficient information about their concussion history to enable the group classification were excluded from the study. The number of reported concussions sustained ranged from 1 to 5 (mean 2.08 and SD 1.31) and the time elapsed since the last concussion spanned from 29 to 53 years (mean 37.08 and SD 7.10). All brain injuries classified as "mild" on the Glasgow Coma Scale (scores ranging from 13 to 15).

The control group included 15 former university-level athletes with a mean age of 58.13 (SD 5.28) and a mean level of education of 17.27 (SD 3.45) who had no prior history of concussion. The 2 groups did not differ according to the age ($t(28) = 1.15$, $P = 0.259$), level of education ($t(28) = 0.44$, $P = 0.666$), or frequency of APOE ϵ -4 (Fisher's exact test $P = 1.00$). The study was approved by the local ethics committees and all participants provided written informed consent prior to testing in accordance with the Declaration of Helsinki.

Procedures

All participants underwent 2 testing sessions. Session 1 included the administration of the general health questionnaire to screen for

medical exclusion criteria (De Beaumont et al. 2009), the concussion history questionnaire, and a neuropsychological test battery aiming to assess age-related cognitive function changes. Session 2 was entirely dedicated to neuroimaging.

The neuropsychological assessment included tests of general cognitive function, verbal fluency, verbal and visual episodic memory, visual attention, along with a depression symptom inventory. The mini-mental status examination (MMSE) was administered as a rapid screening tool for cognitive impairment (Folstein et al. 1975). Given the presumed association between concussion and depressive symptoms (Chen et al. 2008), the Beck depression inventory II (BDI-II) was used to control for symptoms of depression. The Taylor complex figure test (TCFT) was administered to assess incidental learning and visual memory. To evaluate verbal memory, the Rey auditory verbal learning test (RAVLT) was administered. Both these tests were followed by a 20-min delayed recall condition as well as a recognition test. Verbal fluency over 60 s was assessed with letters "F," "A," "S" (phonemic condition) and with categories "animals," "fruits," and "furniture" (semantic condition). Visual attention and inhibition was assessed with the symbol-digit modalities test (SDMT) and the color trails test (A and B). This neuropsychological test battery was administered by a trained neuropsychologist blinded to participants' concussion history.

DNA extraction from saliva samples was performed using Oragene OG-250s kits (DNA Genotek, Ottawa, Canada) and participants were genotyped for APOE 112 (rs429358)-158 (rs7412) polymorphisms. Polymerase chain reaction amplification was carried out as previously described (Petersen et al. 2005). APOE polymorphisms were subsequently determined via an established pyrosequencing protocol (Petersen et al. 2005).

All MR examinations were performed on a Siemens 3T Magnetom TIM TRIO scanner with a 12-channel head coil (Siemens, Erlangen, Germany). Three-dimensional high-resolution T_1 -weighted images of the brain were acquired using a sagittal MP-RAGE sequence (repetition time (TR)=2300 ms; echo time (TE)=2.91 ms; number of slices=176) with a 1-mm³ resolution. T_2 -weighted images were obtained using a turbo spin-echo sequence (TR=3000 ms; TE=78 ms; number of slices=48) for neuroradiological diagnostic purposes. All scans were interpreted by an experienced neuroradiologist who was blinded to the subject group. ¹H MR spectra were obtained from the voxels localized in the bilateral MTL and bilateral prefrontal cortices (PFC) (Fig. 1). All voxels contained a mixture of gray and white matter, while avoiding potential signal artifacts from ventricles, fatty tissues, and bones. Proton signal detection using the point-resolved spectroscopy pulse sequence (PRESS) was performed after suppression of the water signal with the chemical shift-selective sequence. PRESS spectra were also acquired without water suppression in order to use the H₂O signal as an internal reference (Christiansen et al. 1993). Acquisition parameters were the following: TR=1200 ms, TE=30 ms, and 128 averages. Free induction decays were transferred to a Silicon Graphics workstation and processed with the LCModel software version 6.1 (Provencher 1993). The following metabolites were

quantified: *N*-acetylaspartate (NAA), *myo*-inositol (mI), choline-containing compounds (Cho), as well as H₂O for an internal reference.

High-resolution T_1 -weighted images were analyzed with FSL-VBM, a VBM style analysis (Good et al. 2001) carried out with FSL tools (Smith et al. 2004). Modulated and segmented images were smoothed with a 4-mm isotropic Gaussian kernel and fitted to the general linear model using permutation-based non-parametric testing, correcting for multiple comparisons across space. Additionally, brain tissue volumes (including gray matter volume, white matter volume, and ventricular cerebral spinal fluid), normalized for subject head size, were estimated using SIENAX (Smith et al. 2002) from the FSL toolbox. Lastly, cortical thickness analyses were executed using the CIVET pipeline of the Brain Imaging Center (McGill University, Montreal, Canada) (Lytelton et al. 2007). All of the above-mentioned tools for structural data analysis are fully automated and user-independent.

Statistical analysis

All values are expressed as means (SDs). Data were analyzed with SPSS 16 (SPSS, Chicago, IL, USA) unless otherwise specified. The significance level was set at $\alpha=0.05$, bilaterally. The effect sizes for mean differences were estimated with Cohen's *d*. MMSE and BDI-II scores collected for screening purposes were not subjected to statistical analyses. The group mean differences for the TCFT, SDMT, RAVLT, verbal fluency (phonemic and semantic), and Color trails test were tested using Student's *t*-tests for independent samples.

To limit the number of statistical comparisons, the group mean differences for ¹H MRS data were conducted with Student's *t*-tests only for metabolites known to be affected by aging, TBI, or MCI, in our selected ROIs. These included NAA, mI, and Cho in the MTL, and NAA and Cho in the PFC. Two-tailed Pearson correlations, corrected for multiple comparisons with false discovery rate (FDR), were computed between neuropsychological tests and ¹H MRS variables that both significantly discriminated groups. Using the SurfStat toolbox (<http://www.math.mcgill.ca/keith/surfstat/>), the cortical thickness data were tested for the main effects of group, age, and their interaction, corrected with FDR. FDR correction was selected over more conservative but less powerful methods because of the exploratory nature of the current investigation (Perneger, 1998; Genovese et al. 2002).

Results

All participants had MMSE scores ≥ 27 and BDI-II scores ≤ 9 . The demographic data and neuropsychological assessment test results are summarized in Table 1. Neuroradiological examination found no gross anatomical anomaly across samples. Relative to controls, former athletes with concussion (s) showed a reduced semantic verbal fluency ($t(28)=2.16$,

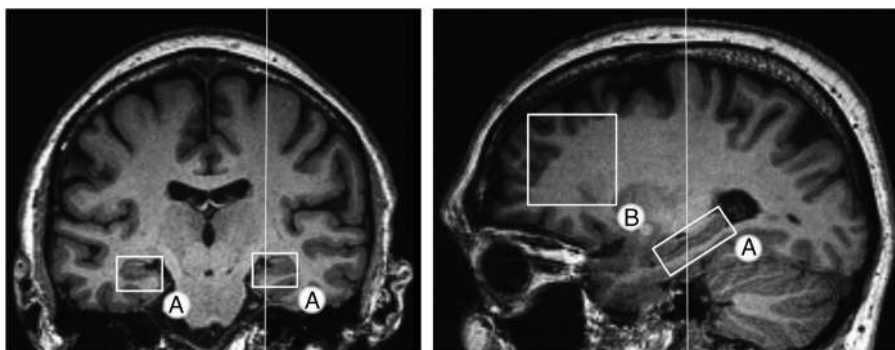


Figure 1. Regions of interest for ¹H MRS examination. T_1 -weighted image of a brain showing approximate locations of the voxels used for MRS. (A) Medial temporal lobes (hippocampus, part of subiculum, entorhinal cortex, and parahippocampal gyrus) ($1.5 \times 1.8 \times 3.6$ cm³). (B) PFC ($3.5 \times 3.5 \times 2$ cm³). PFC voxels were positioned to enclose the maximal amount of gray matter.

$P=0.040$, $d=0.79$) and altered episodic memory on both delayed recall ($t(27)=2.36$, $P=0.026$, $d=0.86$) and recognition ($t(27)=2.61$, $P=0.015$, $d=0.95$) conditions of the TCFT, while performance on the copy trial was not different across groups ($t(27)=1.46$, $P>0.15$). They also exhibited higher retroactive interference on the RAVLT ($t(28)=2.20$, $P=0.039$, $d=0.80$).

^1H MRS examination detected a significant elevation of $\text{mI}/\text{H}_2\text{O}$ in the left MTL of formerly concussed participants ($t(23)=-2.54$, $P=0.037$, $d=0.89$) that correlated strongly with the TCFT delayed recall score ($r=-0.72$, $P=0.008$), after FDR correction for multiple comparisons. The same ROI also exhibited an abnormal reduction in Cho ($t(25)=2.15$, $P=0.041$, $d=0.84$), while the right PFC presented a significant increase in the same metabolite ($t(26)=-2.54$, $P=0.017$, $d=0.96$), when referenced to H_2O .

The structural images of the brain processed by an optimized VBM revealed no gray matter density differences

Table 1
Demographic and neuropsychological data

Measures	Controls, mean (SD)	Concussed, mean (SD)	<i>P</i> -values
<i>N</i>	15	15	
Age	58.13 (5.28)	60.87 (7.51)	0.26
Hockey players (%)	70	70	
Education (years)	17.27 (3.45)	16.67 (4.06)	0.67
APOE ϵ -4 (% positive)	2 (13.33)	2 (13.33)	1.00 ^a
MMSE	29.40 (1.12)	29.20 (0.86)	0.31 ^b
BDI-II	2.93 (3.08)	3.43 (3.29)	0.67 ^b
TCFT (# of items drawn)			
Copy	35.86 (0.36)	35.33 (1.29)	0.16
Immediate recall	30.14 (2.58)	27.80 (3.95)	0.07
Delayed recall	30.18 (2.47)	27.33 (3.83)	0.03
Recognition	20.36 (1.28)	18.60 (2.19)	0.02
RAVLT (# of words)			
Trials 1–5 total	54.87 (7.83)	52.33 (5.79)	0.32
Delayed recall	12.20 (2.01)	11.00 (2.67)	0.18
Recognition	13.07 (1.91)	12.67 (1.99)	0.58
Proactive interference	1.00 (1.36)	0.93 (1.44)	0.90
Retroactive interference	0.93 (1.03)	2.13 (1.85)	0.04
SDMT (# of correct digits)	54.00 (8.60)	49.53 (7.43)	0.14
Color trails test (s)			
Form A	35.13 (10.61)	32.43 (6.43)	0.42
Form B	74.13 (26.86)	73.00 (16.58)	0.89
Verbal fluency (words)			
Phonemic	46.00 (7.80)	49.67 (11.31)	0.31
Semantic	52.93 (8.67)	46.40 (7.69)	0.04

Note: APOE ϵ -4, proportion of participants with a ϵ -4 allele; MMSE, mini-mental state examination; BDI-II, Beck depression inventory II; TCFT, Taylor complex figure test; RAVLT, Rey auditory verbal learning test; SDMT, symbol-digit modalities test.

^aFisher's exact test.

^bMann–Whitney *U* test.

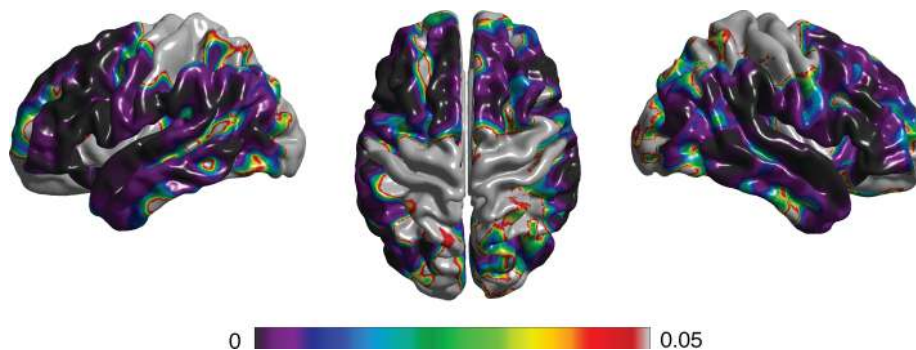


Figure 2. Age effect on cortical thickness. The main effect of age on cortical thickness over the entire sample. Colors encode the *P*-value, FDR corrected.

between groups after correction with permutation-based statistics. In contrast, SIENAX analysis revealed a significant enlargement of the lateral ventricles of concussed participants ($t(28)=-2.44$, $P=0.023$, $d=0.89$) that correlated positively with episodic memory performance deficits at the TCFT delayed recall condition ($r=0.55$, $P=0.033$). In the same analysis, when the age variable was introduced in addition to the group, lateral ventricular volume presented a significant age \times group interaction, suggesting that ventricular volume expansion was further exacerbated with the advancing age in the concussed group ($F(1, 28)=9.20$, $P=0.005$).

As expected, cortical thickness analysis revealed a detrimental main effect of age when the 2 groups were combined (Fig. 2). Indeed, MRI-based cortical thickness of the frontal, temporal, and parietal lobes presented a diffuse thinning with the advancing age. However, this adverse age effect was again exacerbated in the former concussed athletes group, as revealed by the significant age \times group interaction in various ROIs (Fig. 3). In addition, these clusters of abnormal thinning correlated markedly with the episodic memory decline detected in formerly concussed participants at the TCFT delayed recall condition (Fig. 3).

Discussion

The present study investigated the effects of sports concussion and aging using multimodal neuroimaging in conjunction with the cognitive assessment. This research reveals: 1) the episodic memory decline in former athletes with concussion; 2) a significant decline on measures of semantic verbal fluency; 3) a significant enlargement of the lateral ventricles that correlates with episodic memory decrements; 4) a combined effect of age and concussion on cortical thickness measures in various ROIs that correlates with the episodic memory decline; 5) abnormally elevated mI relative concentration in the left MTL that correlates with the episodic memory decline; and 6) perturbations of Cho concentrations in both the left MTL and right PFC.

The enlarged ventricles found in retired concussed participants relative to unconcussed counterparts are particularly salient neuroanatomical findings. The lateral ventricle enlargement has consistently been found in deceased athletes with pathologically verified CTE (McKee et al. 2009; Omalu et al. 2011). The lateral ventricle expansion is also reported in various neurological conditions, including AD and, to a lesser extent, MCI (Jack et al. 2005; Fleisher et al. 2008; Chou et al.

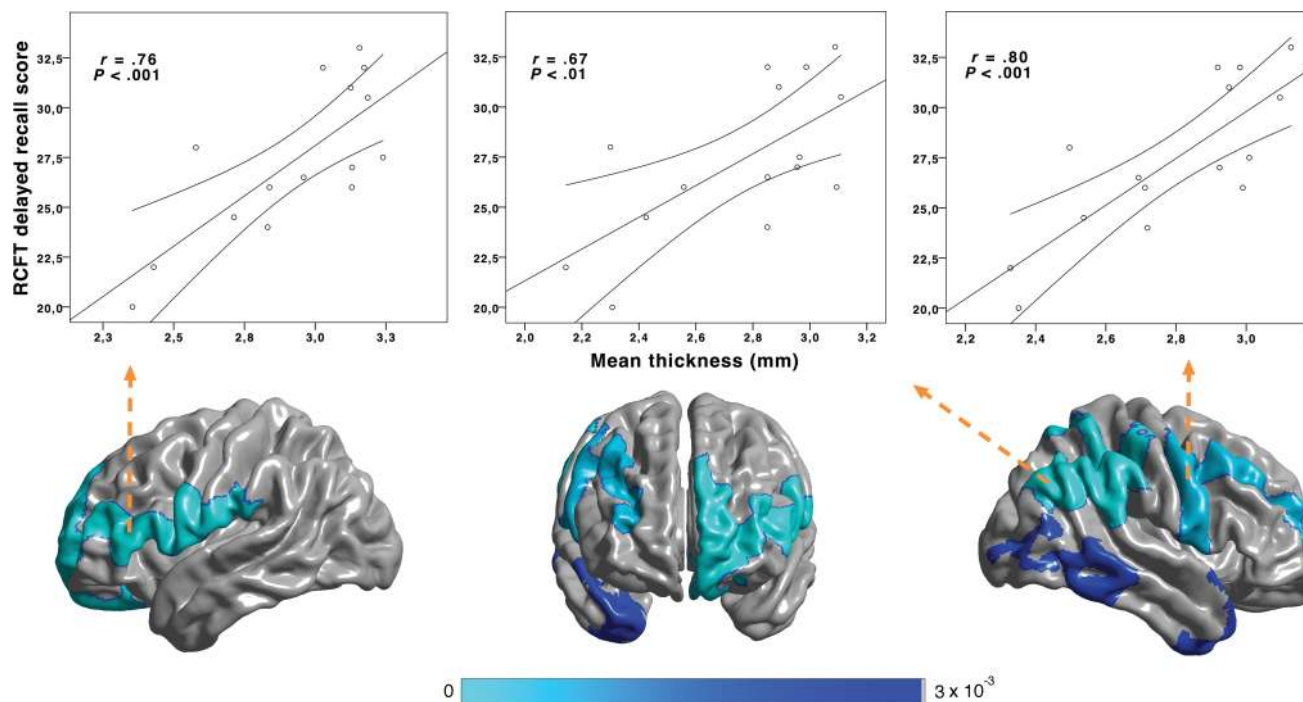


Figure 3. Synergistic effect of concussion and aging. Clusters of significant interaction between concussion history (groups) and aging effect on cortical thickness. Concussed participants exhibited a pronounced detrimental effect of aging in 4 clusters: Left frontal, right frontal, right temporo-parietal, and right temporal cortices. Colors encode P -value, FDR corrected. In concussed participants, abnormal cortical thinning in all clusters but the right temporal one correlates with the episodic memory decline on TCFT.

2010). Aside from being considered a significant predictor of conversion from amnesic MCI to AD (Fleisher et al. 2008), the annual ventricular enlargement rate is found to be predictive of conversion from normal aging to an MCI (Jack et al. 2005). In agreement with the majority of previous quantitative MRI studies conducted with TBI patients, the ventricular enlargement found in concussed athletes may predominantly reflect white matter losses consequent to diffuse axonal injury (Bigler 2001; Bendlin et al. 2008). Diffuse axonal injury preferentially affecting the corpus callosum in addition to other major fiber bundles is reported in TBI patients with or even without gross anatomical lesions (Gale et al. 1995; Nakayama et al. 2006). This is consistent with recent diffusion tensor imaging studies conducted with concussed athletes (Cubon et al. 2011; Henry et al. 2011) and military personnel with a blast-related mild traumatic brain injury (Mac Donald et al. 2011) reporting evidence of diffuse white matter injury in this population of young adults. It remains to be seen, using diffusion-weighted imaging in retired athletes with concussions, whether these white matter anomalies are still present with the advancing age and if they relate to the ventricular enlargement and/or cognitive decline. Although the cause of this ventricular enlargement in our sample remains uncertain with regards to diffuse axonal injury, the clinical significance of this finding in former athletes with concussion is substantiated by the significant relation found with episodic visual memory decline, a correlation also observed in patients with remote TBI of much greater severity (Himanen et al. 2005).

The detrimental effect of normal aging on MRI-based cortical thickness measurement is well documented (Allen et al. 2005; Fotenos et al. 2005; Walhovd et al. 2005; Fjell et al. 2009). The presence of this same relation over the entire study sample is in agreement with this notion (Fig. 2). More

importantly, when concussion history was included as an additional factor to aging, a significant interaction indicated accentuated cortical thinning in concussed athletes over various ROIs known to be particularly vulnerable to the aging process (Fig. 3) (Fjell et al. 2009). These clusters of accentuated thinning also relate to the cortical regions subjected to neuronal loss in former contact sports athletes posthumously diagnosed with CTE (McKee et al. 2009). However, one technical limitation is that MRI-based cortical thickness reduction does not necessarily imply neuronal loss in our concussed sample; the MRI measurement being insensitive to the variety of cellular types constituting the cerebral cortex. Further neuroanatomical studies need to address the cellular underpinnings of cortical thinning specific to older former concussed athletes. Of clinical relevance, clusters of cortical thinning resulting from the interaction of aging and concussion were found to correlate with the episodic memory decline in concussed participants. Taken together, these findings are indicative of abnormal aging in the former concussed athletes group not only affecting cognitive functions but also cortical tissue integrity.

Further evidence of the long-term effects of concussions on brain integrity was found using *in vivo* $^1\text{H-MRS}$. Indeed, Cho, for which the $^1\text{H-MRS}$ signal is mainly composed of cytosolic glycerophosphocholine and phosphocholine (Miller et al. 1996; Klein 2000), were found to be imbalanced in the left MTL and right PFC of concussed participants. In the MCI and AD literature, Cho present an inconsistent pattern of alterations, partly explained by a moderate test–retest reliability across different methodologies (Valenzuela and Sachdev 2001). However, using precisely the same methodology, a previous study from our group conducted with an MCI population (Chantal et al. 2004) found choline alterations similar to

those uncovered in concussed athletes from the current study. Although various explanations have been proposed to account for this neurometabolic imbalance, increased membrane turnover due to neuronal degeneration is perhaps most consistently reported in the TBI and AD literature (Garnett et al. 2000; Klein 2000). In parallel, the left MTL mI increase found in concussed athletes is compellingly supported by the MCI literature (Kantarci et al. 2008; Wang et al. 2009; Chao et al. 2010) and is also found to correlate with neurofibrillary tangle count (NFT) in postmortem AD brains (Klunk et al. 1996). Converging evidence indicates that early NFT deposition over the perirhinal cortex seems to be linked to early visual memory impairments in MCI patients (Barbeau et al. 2004), a finding also consistent with the chronic effects of concussions reported herein. This excess of mI, which is known as a marker of glial proliferation (Fisher et al. 2002), is also in line with the recent neuropathological uncovering of hippocampal NFT deposition in deceased professional football players with pathologically verified CTE (Omalu et al. 2006; McKee et al. 2009). The strong correlation between the elevated mI and episodic memory decline found in former concussed athletes emphasizes the clinical relevance of this novel finding.

Finally, this study replicates previous findings of the episodic memory decline in formerly concussed athletes (De Beaumont et al. 2009) in addition to uncovering increased retroactive interference as well as semantic verbal fluency decrements for the first time in this population. Semantic verbal fluency tests have proven to be more sensitive to the early effects of AD on executive functions than their phonemic counterparts (Monsch et al. 1992), a peculiarity also reported in our concussed group. Interestingly, a concomitant decline in semantic verbal fluency and non-verbal episodic memory was identified as a key predictor of AD conversion in a population of very mildly impaired individuals (MMSE ≥ 24) (Salmon et al. 2002). Further, evidence of executive function decline in our sample comes from significantly increased retroactive interference on verbal memory examination. When combined with recognition memory scores, which are abnormally low in our concussed group, retroactive interference scores have been reported to distinguish MCI patients from normal elderly individuals with great sensitivity and specificity (both $>85\%$) (Loewenstein et al. 2004). Although no neuropsychological studies have been conducted in patients who were posthumously diagnosed with CTE, memory loss is the most frequently reported initial symptoms in the literature (McKee et al. 2009). In spite of the fact that these neurocognitive measures statistically differentiated the groups, it is important to mention that none of the concussed participants exhibited clinically significant cognitive deficits, and that all participants were well functioning in their daily living activities at the time of testing. These positive results should not overshadow the other cognitive domains where concussed participants performed at the control group level. The clinical cognitive profile of this population has yet to be fully characterized in a larger sample with a more exhaustive neuropsychological examination, preferentially using a prospective approach.

Anatomo-functional correlations found in this study by no means reflect a direct relationship between structural damage and a specific cognitive function decline. Results from this study rather point to a wider neuropathology involving

multiple brain regions to account for cognitive performance decrements found in former concussed athletes relative to un-concussed counterparts. This notion is supported by an episodic memory decline being related to the ventricular enlargement, cortical thinning, and hippocampal neurochemical anomalies in our concussed samples. As documented in both the CTE and amnesic MCI literatures (Petersen et al. 1999; McKee et al. 2009), episodic memory decrements might be the first cognitive function to be affected by the underlying neuropathology in the current sample, which may explain why the above-mentioned neurocognitive correlations have yet to implicate other cognitive functions.

In conclusion, the current study unveils multifaceted brain anomalies in retired athletes who sustained sports-related concussions in early adulthood. Anatomical and neurometabolic findings resemble the patterns of abnormal aging reflected in pathological conditions such as MCI and CTE. Of clinical significance, the anatomical findings uncovered in otherwise healthy former athletes with concussions were correlated with cognitive decline, preferentially affecting episodic memory, which is the first clinical symptom of both amnesic MCI and CTE. Despite these similarities, motor system alterations specifically affecting young athletes with concussions that persist up to their late adulthood (De Beaumont et al. 2009, 2011) distinguish the natural history of MCI from one of the current syndromes. The present study also raises alarming concerns regarding the minimal severity of brain injury involved to induce long-term brain tissue damage. Indeed, this study was conducted with participants who played for their university athletic team in their young adulthood, who sustained on average 2 concussions, and who took on a successful professional career outside the world of contact sports after their graduation. This study shows that uncomplicated concussion history is related to the abnormal aging pattern in otherwise healthy former concussed athletes. Considering that this study sample was also highly educated, both physically and mentally active, and was on average 10 years younger than the typical MCI age of onset, this neurobiological and cognitive profile may well underestimate the more typical pattern of brain decline to be found in the general population aging with a prior history of sports concussions. For similar reasons, the neuropsychological test performance of the concussed sample should not be interpreted with respect to the normative data, which would otherwise suggest that its performance is more or less normal, but should rather be compared with the performance of the control group that presents the exact same life profile as the concussed group, except for the concussion history.

The limitations of this study include small sample size and retrospective classification based on self-reported information. The impact of these 2 methodological limitations were minimized by assuring a stringent equivalency between samples on biologically and psychologically relevant variables, and by combining a standardized concussion diagnostic procedure with a conservative classification strategy. Having to include such a stringent set of inclusion criteria also compromises the generalizability of our findings to a small subset of former athletes with a history of concussions. Despite our efforts to reliably reconstruct concussion histories according to modern guidelines, our sample probably underrepresents athletes who exclusively sustained very mild concussions in their athletic career. Nevertheless, this study highlights disquieting

information about the chronic effects of remote concussions on late-life cognitive decline and calls for replication studies conducted with a broader sample of former athletes that present with more diverse medical history characteristics. The current findings, if replicated, could have practical implications with regard to the enforcement of safety measures and regulations that should not be restricted to professional sports associations but should rather apply to all individuals, including children, playing contact sports. Large-scale longitudinal studies are urgently needed to validate these novel findings and to investigate the incidence of MCI or CTE in the general population with remote sports-related concussions.

Funding

This work was supported by the Canadian Institutes of Health Research, the Fonds de la Recherche en Sante du Quebec, the Canadian Foundation for Innovation, the Natural Sciences and Engineering Research Council of Canada, and the Canada Research Chair program. *Conflict of Interest:* none declared.

References

- Allen JS, Bruss J, Brown CK, Damasio H. 2005. Normal neuroanatomical variation due to age: the major lobes and a parcellation of the temporal region. *Neurobiol Aging*. 26:1245–1260; discussion 79–82.
- Barbeau E, Didic M, Tramon E, Felician O, Joubert S, Sontheimer A, Ceccaldi M, Poncet M. 2004. Evaluation of visual recognition memory in MCI patients. *Neurology*. 62:1317–1322.
- Bendlin BB, Ries ML, Lazar M, Alexander AL, Dempsey RJ, Rowley HA, Sherman JE, Johnson SC. 2008. Longitudinal changes in patients with traumatic brain injury assessed with diffusion-tensor and volumetric imaging. *Neuroimage*. 42:503–514.
- Bigler ED. 2001. Quantitative magnetic resonance imaging in traumatic brain injury. *J Head Trauma Rehabil*. 16:117–134.
- Brooks WM, Friedman SD, Gasparovic C. 2001. Magnetic resonance spectroscopy in traumatic brain injury. *J Head Trauma Rehabil*. 16:149–164.
- Cassidy JD, Carroll LJ, Peloso PM, Borg J, von Holst H, Holm L, Kraus J, Coronado VG. 2004. Incidence, risk factors and prevention of mild traumatic brain injury: results of the WHO Collaborating Centre Task Force on Mild Traumatic Brain Injury. *J Rehabil Med*. 43:28–60.
- Cavanaugh JT, Guskiewicz KM, Stergiou N. 2005. A nonlinear dynamic approach for evaluating postural control: new directions for the management of sport-related cerebral concussion. *Sports Med*. 35:935–950.
- Chantal S, Braun CMJ, Bouchard RW, Labelle M, Boulanger Y. 2004. Similar 1H magnetic resonance spectroscopic metabolic pattern in the medial temporal lobes of patients with mild cognitive impairment and Alzheimer disease. *Brain Res*. 1003:26–35.
- Chao LL, Mueller SG, Buckley ST, Peek K, Raptentsetseng S, Elman J, Yaffe K, Miller BL, Kramer JH, Madison C. 2010. Evidence of neurodegeneration in brains of older adults who do not yet fulfill MCI criteria. *Neurobiol Aging*. 31:368–377.
- Chen J-K, Johnston KM, Petrides M, Ptito A. 2008. Neural substrates of symptoms of depression following concussion in male athletes with persisting postconcussion symptoms. *Arch Gen Psychiatry*. 65:81–89.
- Chou YY, Lepore N, Saharan P, Madsen SK, Hua X, Jack CR, Shaw LM, Trojanowski JQ, Weiner MW, Toga AW *et al*. 2010. Ventricular maps in 804 ADNI subjects: correlations with CSF biomarkers and clinical decline. *Neurobiol Aging*. 31:1386–1400.
- Christiansen P, Henriksen O, Stubgaard M, Gideon P, Larsson HB. 1993. In vivo quantification of brain metabolites by ¹H-MRS using water as an internal standard. *Magn Reson Imaging*. 11:107–118.
- Collins MW, Lovell MR, Iverson GL, Cantu RC, Maroon JC, Field M. 2002. Cumulative effects of concussion in high school athletes. *Neurosurgery*. 51:1175–1179; discussion 80–81.
- Comerchero MD, Polich J. 1999. P3a and P3b from typical auditory and visual stimuli. *Clin Neurophysiol*. 110:24–30.
- Costanza A, Weber K, Gandy S, Bouras C, Hof PR, Giannakopoulos P, Canuto A. 2011. Review: contact sport-related chronic traumatic encephalopathy in the elderly: clinical expression and structural substrates. *Neuropathol Appl Neurobiol*. 37:570–584.
- Cubon VA, Putukian M, Boyer C, Dettwiler A. 2011. A diffusion tensor imaging study on the white matter skeleton in individuals with sports-related concussion. *J Neurotrauma*. 28:189–201.
- De Beaumont L, Brisson B, Lassonde M, Jolicoeur P. 2007. Long-term electrophysiological changes in athletes with a history of multiple concussions. *Brain Inj*. 21:631–644.
- De Beaumont L, Lassonde M, Leclerc S, Theoret H. 2007. Long-term and cumulative effects of sports concussion on motor cortex inhibition. *Neurosurgery*. 61:329–336; discussion 36–37.
- De Beaumont L, Théoret H, Mongeon D, Messier J, Leclerc S, Tremblay S, Ellemberg D, Lassonde M. 2009. Brain function decline in healthy retired athletes who sustained their last sports concussion in early adulthood. *Brain*. 132:695–708.
- De Beaumont L, Tremblay S, Poirier J, Lassonde M, Theoret H. 2011. Altered bidirectional plasticity and reduced implicit motor learning in concussed athletes. *Cereb Cortex*. 22:112–121.
- Fisher SK, Novak JE, Agranoff BW. 2002. Inositol and higher inositol phosphates in neural tissues: homeostasis, metabolism and functional significance. *J Neurochem*. 82:736–754.
- Fjell AM, Westlye LT, Amlien I, Espeseth I, Reinvang I, Raz N, Agartz I, Salat DH, Greve DN, Fischl B *et al*. 2009. High consistency of regional cortical thinning in aging across multiple samples. *Cereb Cortex*. 19:2001–2012.
- Fleisher AS, Sun S, Taylor C, Ward CP, Gamst AC, Petersen RC, Jack CR, Aisen PS, Thal LJ. 2008. Volumetric MRI vs clinical predictors of Alzheimer disease in mild cognitive impairment. *Neurology*. 70:191–199.
- Folstein MF, Folstein SE, McHugh PR. 1975. “Mini-mental state”. A practical method for grading the cognitive state of patients for the clinician. *J Psychiatr Res*. 12:189–198.
- Fotinos AF, Snyder AZ, Girton LE, Morris JC, Buckner RL. 2005. Normative estimates of cross-sectional and longitudinal brain volume decline in aging and AD. *Neurology*. 64:1032–1039.
- Gaetz M, Goodman D, Weinberg H. 2000. Electrophysiological evidence for the cumulative effects of concussion. *Brain Inj*. 14:1077–1088.
- Gale SD, Johnson SC, Bigler ED, Blatter DD. 1995. Nonspecific white matter degeneration following traumatic brain injury. *J Int Neuropsychol Soc*. 1:17–28.
- Garnett MR, Blamire AM, Corkill RG, Cadoux-Hudson TA, Rajagopalan B, Styles P. 2000. Early proton magnetic resonance spectroscopy in normal-appearing brain correlates with outcome in patients following traumatic brain injury. *Brain*. 123(Pt 10):2046–2054.
- Gavett BE, Cantu RC, Shenton M, Lin AP, Nowinski CJ, McKee AC, Stern RA. 2011. Clinical appraisal of chronic traumatic encephalopathy: current perspectives and future directions. *Curr Opin Neurol*. 24:525–531.
- Genovese CR, Lazar NA, Nichols T. 2002. Thresholding of statistical maps in functional neuroimaging using the false discovery rate. *Neuroimage*. 15:870–878.
- Giza CC, Hovda DA. 2001. The neurometabolic cascade of concussion. *J Athl Train*. 36:228–235.
- Good CD, Johnsrude IS, Ashburner J, Henson RN, Friston KJ, Frackowiak RS. 2001. A voxel-based morphometric study of ageing in 465 normal adult human brains. *Neuroimage*. 14:21–36.
- Gosselin N, Theriault M, Leclerc S, Montplaisir J, Lassonde M. 2006. Neurophysiological anomalies in symptomatic and asymptomatic concussed athletes. *Neurosurgery*. 58:1151–1161; discussion 51–61.
- Guskiewicz KM, Marshall SW, Bailes J, Mccrea M, Cantu RC, Randolph C, Jordan BD. 2005. Association between recurrent concussion

- and late-life cognitive impairment in retired professional football players. *Neurosurgery*. 57:719–726; discussion 19–26.
- Haga KK, Khor YP, Farrall A, Wardlaw JM. 2009. A systematic review of brain metabolite changes, measured with ¹H magnetic resonance spectroscopy, in healthy aging. *Neurobiol Aging*. 30:353–363.
- Henry LC, Tremblay S, Boulanger Y, Ellemberg D, Lassonde M. 2010. Neurometabolic changes in the acute phase after sports concussions correlate with symptom severity. *J Neurotrauma*. 27:65–76.
- Henry LC, Tremblay J, Tremblay S, Lee A, Brun C, Lepore N, Theoret H, Ellemberg D, Lassonde M. 2011. Acute and chronic changes in diffusivity measures after sports concussion. *J Neurotrauma*. 28:2049–2059.
- Himanan L, Portin R, Isoniemi H, Helenius H, Kurki T, Tenovuo O. 2005. Cognitive functions in relation to MRI findings 30 years after traumatic brain injury. *Brain Inj*. 19:93–100.
- Jack CR, Shiung MM, Weigand SD, O'Brien PC, Gunter JL, Boeve BF, Knopman DS, Smith GE, Ivnik RJ, Tangalos EG. 2005. Brain atrophy rates predict subsequent clinical conversion in normal elderly and amnesic MCI. *Neurology*. 65:1227–1231.
- Kantarci K, Petersen RC, Przybelski SA, Weigand SD, Shiung MM, Whitwell JL, Negash S, Ivnik RJ, Boeve BF, Knopman DS *et al*. 2008. Hippocampal volumes, proton magnetic resonance spectroscopy metabolites, and cerebrovascular disease in mild cognitive impairment subtypes. *Arch Neurol*. 65:1621–1628.
- Kantarci K, Weigand SD, Petersen RC, Boeve BF, Knopman DS, Gunter J, Reyes D, Shiung M, O'Brien PC, Smith GE *et al*. 2007. Longitudinal ¹H MRS changes in mild cognitive impairment and Alzheimer's disease. *Neurobiol Aging*. 28:1330–1339.
- Kelly JP. 1999. Traumatic brain injury and concussion in sports. *JAMA*. 282:989–991.
- Klein J. 2000. Membrane breakdown in acute and chronic neurodegeneration: focus on choline-containing phospholipids. *J Neural Transm*. 107:1027–1063.
- Klunk WE, Xu C, Panchalingam K, McClure RJ, Pettegrew JW. 1996. Quantitative ¹H and ³¹P MRS of PCA extracts of postmortem Alzheimer's disease brain. *Neurobiol Aging*. 17:349–357.
- Kopp B, Tabeling S, Moschner C, Wessel K. 2006. Fractionating the neural mechanisms of cognitive control. *J Cogn Neurosci*. 18:949–965.
- Langlois JA, Rutland-Brown W, Wald MM. 2006. The epidemiology and impact of traumatic brain injury: a brief overview. *J Head Trauma Rehabil*. 21:375–378.
- Lindsay J, Laurin D, Verreault R, Hébert R, Helliwell B, Hill GB, McDowell I. 2002. Risk factors for Alzheimer's disease: a prospective analysis from the Canadian Study of Health and Aging. *Am J Epidemiol*. 156:445–453.
- Loewenstein DA, Acevedo A, Luis C, Crum T, Barker WW, Duara R. 2004. Semantic interference deficits and the detection of mild Alzheimer's disease and mild cognitive impairment without dementia. *J Int Neuropsychol Soc*. 10:91–100.
- Lyttelton O, Boucher M, Robbins S, Evans A. 2007. An unbiased iterative group registration template for cortical surface analysis. *Neuroimage*. 34:1535–1544.
- Mac Donald CL, Johnson AM, Cooper D, Nelson EC, Werner NJ, Shimony JS, Snyder AZ, Raichle ME, Witherow JR, Fang R *et al*. 2011. Detection of blast-related traumatic brain injury in U.S. military personnel. *N Engl J Med*. 364:2091–2100.
- Martland HS. 1928. Punch drunk. *J Am Med Assoc*. 91:1103–1107.
- Mccrory P, Meeuwisse W, Johnston K, Dvorak J, Aubry M, Molloy M, Cantu R. 2009. Consensus statement on concussion in sport: the 3rd International Conference on Concussion in Sport held in Zurich, November 2008. *Br J Sports Med*. 43:i76–i84.
- McKee AC, Cantu RC, Nowinski CJ, Hedley-Whyte ET, Gavett BE, Budson AE, Santini VE, Lee HS, Kubilus CA, Stern RA. 2009. Chronic traumatic encephalopathy in athletes: progressive tauopathy after repetitive head injury. *J Neuropathol Exp Neurol*. 68:709–735.
- Miller BL, Chang L, Booth R, Ernst T, Cornford M, Nikas D, McBride D, Jenden DJ. 1996. In vivo ¹H MRS choline: correlation with in vitro chemistry/histology. *Life Sci*. 58:1929–1935.
- Miller G. 2009. Neuropathology. A late hit for pro football players. *Science*. 325:670–672.
- Monsch AU, Bondi MW, Butters N, Salmon DP, Katzman R, Thal LJ. 1992. Comparisons of verbal fluency tasks in the detection of dementia of the Alzheimer type. *Arch Neurol*. 49:1253–1258.
- Morris JC, Storandt M, Miller JP, McKeel DW, Price JL, Rubin EH, Berg L. 2001. Mild cognitive impairment represents early-stage Alzheimer disease. *Arch Neurol*. 58:397–405.
- Nakayama N, Okumura A, Shinoda J, Yasokawa YT, Miwa K, Yoshimura SI, Iwama T. 2006. Evidence for white matter disruption in traumatic brain injury without macroscopic lesions. *J Neurol Neurosurg Psychiatry*. 77:850–855.
- Omalu B, Bailes J, Hamilton RL, Kambh MI, Hammers J, Case M, Fitzsimmons R. 2011. Emerging histomorphologic phenotypes of chronic traumatic encephalopathy in American athletes. *Neurosurgery*. 69:173–183; discussion 83.
- Omalu BI, DeKosky ST, Hamilton RL, Minster RL, Kambh MI, Shaker AM, Wecht CH. 2006. Chronic traumatic encephalopathy in a national football league player: part II. *Neurosurgery*. 59:1086–1092; discussion 92–93.
- Perneger TV. 1998. What's wrong with Bonferroni adjustments. *BMJ*. 316:1236–1238.
- Petersen RC, Smith GE, Waring SC, Ivnik RJ, Tangalos EG, Kokmen E. 1999. Mild cognitive impairment: clinical characterization and outcome. *Arch Neurol*. 56:303–308.
- Petersen RC, Thomas RG, Grundman M, Bennett D, Doody R, Ferris S, Galasko D, Jin S, Kaye J, Levey A *et al*. 2005. Vitamin E and donepezil for the treatment of mild cognitive impairment. *N Engl J Med*. 352:2379–2388.
- Provencher SW. 1993. Estimation of metabolite concentrations from localized in vivo proton NMR spectra. *Magn Reson Med*. 30:672–679.
- Roberts GW, Allsop D, Bruton C. 1990. The occult aftermath of boxing. *J Neurol Neurosurg Psychiatry*. 53:373–378.
- Salmon DP, Thomas RG, Pay MM, Booth A, Hofstetter CR, Thal LJ, Katzman R. 2002. Alzheimer's disease can be accurately diagnosed in very mildly impaired individuals. *Neurology*. 59:1022–1028.
- Smith SM, Jenkinson M, Woolrich MW, Beckmann CF, Behrens TEJ, Johansen-Berg H, Bannister PR, De Luca M, Drobnjak I, Flitney DE *et al*. 2004. Advances in functional and structural MR image analysis and implementation as FSL. *Neuroimage*. 23(Suppl 1):S208–S219.
- Smith SM, Zhang Y, Jenkinson M, Chen J, Matthews PM, Federico A, De Stefano N. 2002. Accurate, robust, and automated longitudinal and cross-sectional brain change analysis. *Neuroimage*. 17:479–489.
- Theriault M, De Beaumont L, Tremblay S, Lassonde M, Jolicoeur P. 2011. Cumulative effects of concussions in athletes revealed by electrophysiological abnormalities on visual working memory. *J Clin Exp Neuropsychol*. 33:30–41.
- Vagnozzi R, Signoretti S, Cristofori L, Alessandrini F, Floris R, Isgrò E, Ria A, Marziale S, Zoccatelli G, Tavazzi B *et al*. 2010. Assessment of metabolic brain damage and recovery following mild traumatic brain injury: a multicentre, proton magnetic resonance spectroscopic study in concussed patients. *Brain*. 133:3232–3242.
- Valenzuela MJ, Sachdev P. 2001. Magnetic resonance spectroscopy in AD. *Neurology*. 56:592–598.
- Walhovd KB, Fjell AM, Reinvang I, Lundervold A, Dale AM, Eilertsen DE, Quinn BT, Salat D, Makris N, Fischl B. 2005. Effects of age on volumes of cortex, white matter and subcortical structures. *Neurobiol Aging*. 26:1261–1270; discussion 75–78.
- Wang Z, Zhao C, Yu L, Zhou W, Li K. 2009. Regional metabolic changes in the hippocampus and posterior cingulate area detected with 3-Tesla magnetic resonance spectroscopy in patients with mild cognitive impairment and Alzheimer disease. *Acta Radiol*. 50:312–319.