

# Stereotaxic Radiofrequency Hypophysectomy for Disseminated Breast and Prostate Cancer — Transseptal Transsphenoidal Approach —

Sang Sup Chung, Hun Jae Lee, Kyu Sung Lee, Kyu Chang Lee and Joong Uhn Choi

*Department of Neurosurgery, Yonsei University College of Medicine  
Seoul, Korea*

The authors performed three consecutive cases of stereotaxic radiofrequency hypophysectomies for patients with disseminated cancer from breast or prostate at Severance Hospital, Yonsei University. The procedures were essentially the same, in large part, as the technique first introduced by Zervas. The authors modified the original technique to reduce the known risks of cerebrospinal fluid rhinorrhea and meningitis. Surgical details and clinical cases are presented.

**Key Word:** Stereotaxic hypophysectomy  
Disseminated cancer  
Breast  
Prostate  
Trans-septal trans-sphenoidal  
Cerebrospinal fluid rhinorrhea

Hypophysectomy for palliation of malignant disease was first reported in 1952 (Shimkin *et al*). In the same year, Huggins and Bergenstal demonstrated that adrenalectomy could produce remission in certain patients with metastatic cancer of the breast. In 1953, Luft and Olivercrona reported regression of breast and prostatic carcinoma after pituitary ablation. Since these reports, hypophysectomy became a useful palliative operation for either disseminated cancer of the breast or prostate. Section of the pituitary stalk (Ehni and Eckles, 1959) or transfrontal extirpation of the pituitary (Ray, 1960) were effective methods with satisfactory results, but these major procedures were not practiced widely for the patients with

advanced cancer in poor condition. Hardy (1971) introduced transsphenoidal hypophysectomy which had few complications, little discomfort and low morbidity.

Talairach (1956) reported stereotaxic transnasal hypophysectomy with radioactive gold, which was performed with minimum operative stress and postoperative discomfort. Rand introduced the cryosurgical stereotaxic method in 1964. In the following year, Zervas published the technique of radiofrequency hypophysectomy. The radiofrequency method is relatively safe and can easily be performed in patients with disseminated cancer as a palliative treatment.

## SUMMARY OF CASES

**Case 1.** A 47-year-old woman had a right radical mastectomy and radiation therapy for an adenocarcinoma in 1978. She was free of symptoms until a palpable mass of the left neck with intractable pain developed in 1980. The mass had grown to egg size and was confirmed as metastatic adenocarcinoma. The intractable pain spread to the left shoulder, arm and anterior chest wall. Radiofrequency hypophysectomy was performed in October, 1980. After the operation, she felt about 70% regression of the pain.

**Case 2.** A 63-year-old male patient underwent prostatectomy for an adenocarcinoma of the prostate in 1977. He began to experience severe pain in the back two years later. Osteolytic metastases were noted and estrogen therapy was started. The pain subsided for about six months. Hematuria developed and severe back pain recurred. Biopsy of the prostate and a left supraclavicular node revealed recurrent adenocarcinoma with metastasis. The bone scan showed multiple skeletal metastases in the thoracolumbar spine and the pelvis. Stereotaxic radiofrequency hypophysectomy was performed and the pain was reduced about 60% immediately after the operation.

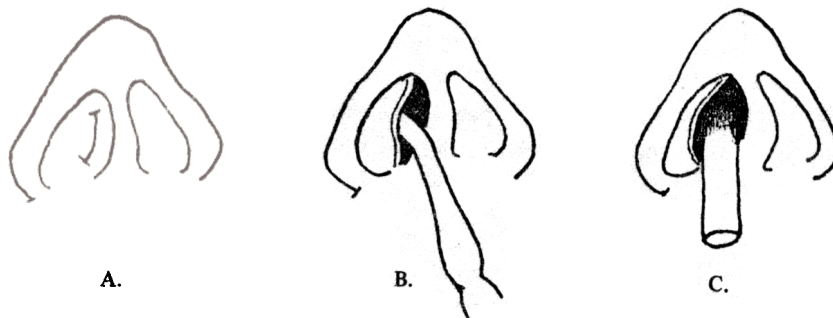
**Case 3.** A 76-year-old male patient was admitted due to hematuria and low back pain. He had had a prostatectomy and suprapubic cystostomy in 1979 due to advanced prostatic carcinoma. One year after the surgery, low back pain developed and the bone scan showed spinal metastases. Stereotaxic hypophysectomy was performed and the bone pain was reduced by about 90%. The patient showed symptoms of panhypopituitarism and diabetes insipidus after the surgery. Hormonal replacement therapy was started and the diabetes insipidus

was controlled by treatment with chlorothiazide for about two weeks.

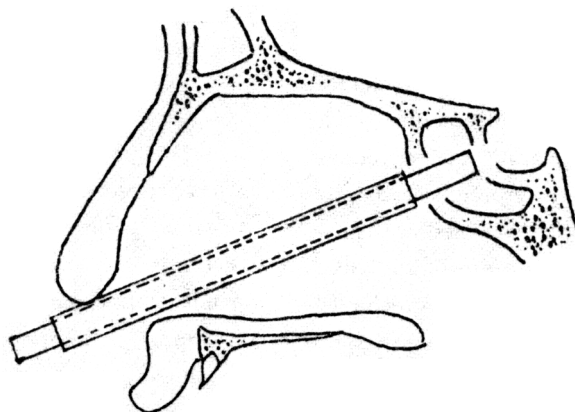
## TECHNIQUE

Under general endotracheal anesthesia, the patient is placed in the supine position, with the head fixed securely in the Todd-Wells stereotaxic frame. The electrode holder is centered on the anterior wall of the sella turcica as close to the midline as possible. The target point is the midline sella, not more than 4 mm above the floor. The nasal cavity is prepared with betadine solution. Submucosal infiltration of 1% lidocaine with diluted epinephrine (1:200,000) facilitate the submucosal dissection as in the transsphenoidal hypophysectomy. The unilateral submucosal dissection is performed from the right side nostril, after making a small incision at the mucocutaneous junction. A cannula is inserted through the submucosal tunnel just anterior to the sphenoid sinus. Under the fluoroscopic control with a portable image intensifier, a 4 mm drill hole is made in the anterior wall of the sphenoid sinus. A 2.2 mm drill hole is made in the anterior wall of the sella turcica through an inner cannula. Care is taken so that the head of the drill is not extended more than 1 or 2 mm into the sella turcica to prevent stripping the dura from the bone. The dura is then punctured with a sharp pointed stylet. The 2.1 mm electrode (Hypophysectomy Thermocouple Spring Electrode\*) is advanced to 4 mm short of the dorsum sellae. The electrode has a side outlet 1 mm short of the tip, through which a spring electrode can be projected. After protrusion, the thermocouple spring electrode becomes semicircular in shape. A thermocouple within the spring electrode monitors the temperature at the tip.

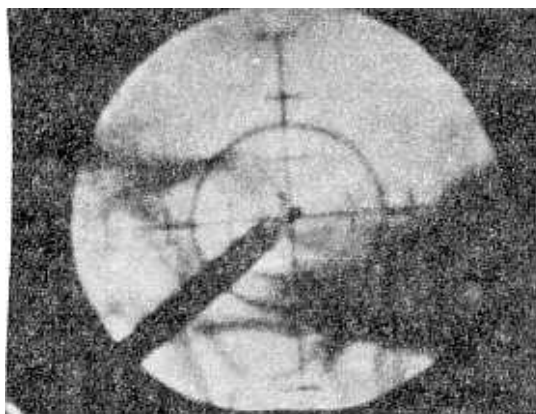
\*Radionics, INC. 76 Cambridge Street, Burlington, Massachusetts, U.S.A.



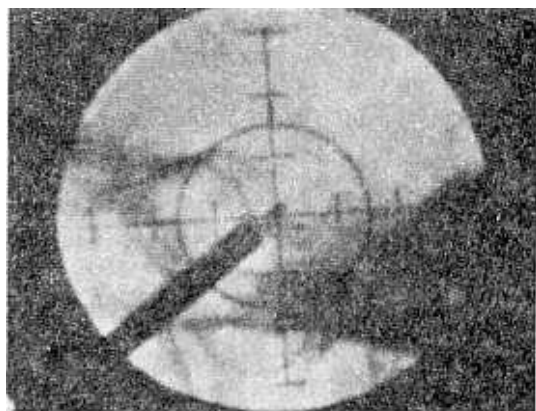
**Fig. 1.** A : A small incision at the mucocutaneous junction.  
 B : Submucosal dissection of the mucoperichondrium.  
 C : Insertion of the cannula through the submucosal pathway along the nasal septum.



**Fig. 2.** Lateral view of midline of the nasal cavity showing the transseptal transsphenoidal approach.



A.



B.

**Fig. 3.** Fluoroscopic images show the upward(A) and downward(B) direction of the thermocouple spring electrode.

Resistance can be felt as the spring electrode reaches the diaphragma sellae or the floor or the lateral dura, depending on the angle of rotation. The anterior dorsum sellae is palpated with the electrode tip, and the electrode is withdrawn 1 or 2 mm.

Total destruction of the gland can be done by series of lesions in various quadrants—alternately retracting and extending the spring electrode after the electrode has been turned into a new angle. It is very important to confirm the actual position of the electrode tip with fluoroscopic monitoring.

Before making a lesion, stimulation with 60Hz, 2 msec, less than 2 V is carried out at each position of the spring electrode to detect the possible abnormal eye movements which can be elicited by stimulating the surrounding cranial nerves. The ground needle is implanted in the deltoid. Each lesion is produced by bringing the temperature of the electrode tip as monitored by the thermocouple to 80° to 90°C for 120 seconds. A series of lesions is made by turning the outer cannula 30 degree after each lesion. After the lesions are completed, the electrode can be removed and the cannula is withdrawn just beneath the sellar floor. Small pieces of gelfoam are inserted through the cannula directly into the anterior wall of the sella. Then the cannula is removed back a little further, and the coating material

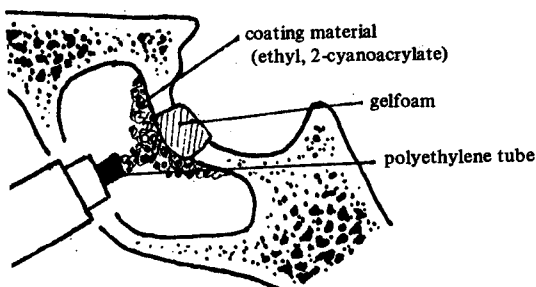


Fig. 4. Reconstruction of the sellar floor with gelfoam and coating material.

(ethyl, 2-cyanoacrylate) is spread over the gelfoam through a polyethylene tube, which is inserted into the cannula. The cannula is then totally removed and a vaseline gauze pack is placed in the nasal cavity. The incision of the mucocutaneous junction is closed with 1 or 2 stitches. Following operation the patient is in good condition and has few restrictions.

## DISCUSSION

Objective remission rate following hypophysectomy in patients with metastatic carcinoma of the prostate ranges from 19 to 37% (Tindall *et al.*, 1979). The remission probably results from the removal of pituitary gonadotrophins and adrenocorticotrophic hormone. Huggins and Hódges (1941) contended that androgens stimulate growth of prostatic cancer, and thus respond to the hormonal therapy and hypophysectomy. In the same manner, estrogen dependent disseminated carcinoma of the breast responds to hypophysectomy (Ray, 1967). In our cases, the patients showed subjective remission by disappearance of intractable pain. Such objective evidence of response as decreased frequency of hematuria and urinary retention in the patients with prostatic cancer were observed, though the follow-up period was not long. Postoperative hormonal studies showed decreased function of the pituitary gland. One patient showed profound panhypopituitarism and is still receiving hormonal replacement therapy.

Pain relief in disseminated cancer following hypophysectomy is one of the major benefits of the operation and was observed in our cases. It is speculated that the loss of shortloop feedback control due to pituitary ablation is followed by the release of one or more peptide (endorphine, enkephalin) that act to alleviate pain (Tindall *et al.*, 1977, 1979).

Operative approaches for performing the hypophysectomy have changed considerably, and the effective and relatively safe procedures are stereotaxic thermal hypophysectomy (Zervas, 1965), stereotaxic cryohypophysectomy (Rand, 1964), and transsphenoidal microsurgery (Hardy, 1971). In experienced hands, any one of these procedures yields good results.

Considering the stereotaxic hypophysectomy, the radiofrequency technique of Zervas and other methods caused the not-so-uncommon serious obstacle—cerebrospinal fluid rhinorrhea. The use of silicon rubber plug decreased the CSF rhinorrhea remarkably (Zervas, 1969). The authors modified the procedure to reduce the CSF rhinorrhea, using coating material and operating through the submucosal pathway. Compared with the direct transnasal approach, the authors' transseptal method prevents the direct exposure to the nasal bacterial flora by operating through a relatively long and aseptic submucosal tunnel, which in turn decreases the chance of infection. Our method seems to be a good alternative to the silicon rubber plug technique.

### CONCLUSION

Stereotaxic radiofrequency hypophysectomy is a simple and effective palliative treatment for disseminated carcinoma of the prostate and breast. This paper illustrated a new method of stereotaxic radiofrequency hypophysectomy which minimize the occurrence of cerebrospinal fluid rhinorrhea and ascending infection.

### ACKNOWLEDGEMENTS

The authors wish to express their gratitude to Professor J.M. Lee, Department of Urology and Professor B.S. Kim, Cancer Center, Severance Hospital, Yonsei University College of Medicine, for referring the patients.

### REFERENCES

- Ehni G, Eckles NE: *Interruption of the pituitary stalk in the patient with mammary cancer. J Neurosurg* 16:628-651, 1959
- Hardy J: *Transsphenoidal hypophysectomy. J Neurosurg* 34:582-594, 1971
- Huggins C, Bergenstal DD: *Inhibition of human cancers by adrenalectomy. Cancer Res* 12:134-141, 1952
- Huggins C, Hodges CV: *Studies on prostatic cancer. 1. The effect of castration, of estrogen and of androgen injection on serum phosphatases in metastatic carcinoma of the prostate. Cancer Res* 1:293-297, 1941
- Luft R, Olivecrona H: *Experiences with hypophysectomy in man. J Neurosurg* 10:301-316, 1953
- Rand RW: *Stereotaxic transsphenoidal cryohypophysectomy. Bull Los Angeles Neurol Soc* 29:40-48, 1964
- Ray BS: *Some inferences from hypophysectomy on 450 human patients. Arch Neurol* 3:121-126, 1960
- Ray BS: *Hypophysectomy as palliative treatment. JAMA* 200:974-975, 1967
- Shimkin MB, Boldrey EB, Kelly KH: *Effects of surgical hypophysectomy in man with malignant melanoma. J Clin Endocrinol* 12:439-453, 1952
- Talairach J, Aboulker J, Tournoux P, David M: *Technique stereotaxique de la chirurgie hypophysaire par voie nasale. Neurochirurgie* 2:3-20, 1956
- Tindall GT, Nilson DW, Christy JH, Neil JD: *Pain relief in metastatic cancer other than breast and prostate gland following transsphenoidal hypophysectomy. J Neurosurg* 47:659-662, 1977
- Tindall GT, Payne NS, Nixon DW: *Transsphenoidal hypophysectomy for disseminated carcinoma of the prostate gland. J Neurosurg* 50:275-282, 1979
- Zervas NT: *Technique of radiofrequency hypophysectomy. Confin Neurol* 26:157-160, 1965
- Zervas NT, Gordy PD: *Radiofrequency hypophysectomy for metastatic breast and prostatic carcinoma. Surg Clin North Am* 47:1279-1285, 1967
- Zervas NT: *Stereotaxic radiofrequency surgery of the normal and abnormal pituitary gland. New Engl J Med* 280:429-437, 1969