

Stickler Syndrome: Clinical Characteristics and Diagnostic Criteria

Peter S. Rose,¹ Howard P. Levy,² Ruth M. Liberfarb,^{3,4*} Joie Davis,⁵ Y. Szymko-Bennett,⁶ Benjamin I. Rubin,⁷ Ekaterini Tsilou,⁷ Andrew J. Griffith,⁶ and Clair A. Francomano⁴

¹Department of Orthopedic Surgery, Mayo Clinic, Rochester, Minnesota

²Johns Hopkins University, Baltimore, Maryland

³Genetics and Teratology Unit, Massachusetts General Hospital, Boston, Massachusetts

⁴Laboratory of Genetics, National Institute on Aging, National Institutes of Health, Baltimore, Maryland

⁵National Human Genome Research Institute, National Institutes of Health, Bethesda, Maryland

⁶National Institute on Deafness and Other Communication Disorders, National Institutes of Health, Bethesda, Maryland

⁷National Eye Institute, National Institutes of Health, Bethesda, Maryland

The purpose of this study was to establish diagnostic criteria for Stickler syndrome. Ninety patients from 38 families had complete evaluations for possible Stickler syndrome. Molecular confirmation of *COL2A1* mutation status (type I Stickler syndrome) was available on 25 patients from six families. In the remaining 65 patients, 47 from 25 families were affected with Stickler syndrome and 18 from seven families were unaffected with Stickler syndrome. A diagnostic nosology based on type I Stickler patients with known *COL2A1* mutations was applied to clinically affected and unaffected patients. A diagnostic scale of 9 points evaluated molecular data or family history data and characteristic ocular, orofacial, auditory, and musculoskeletal findings. A score of ≥ 5 was diagnostic of Stickler syndrome. These criteria demonstrate 100% sensitivity when applied to type I Stickler syndrome patients with known *COL2A1* mutations, 98% sensitivity when applied to clinically affected Stickler patients, and 86% specificity when applied to patients unaffected based on clinical and/or molecular analysis. We conclude that diagnostic criteria based on type I Stickler patients with molecularly confirmed *COL2A1* mutations appear to be sensitive and specific for the diagnosis of this syndrome and should be helpful to clinicians when making the diagnosis. © 2005 Wiley-Liss, Inc.

KEY WORDS: Stickler syndrome; diagnostic criteria; nosology

The study was conducted at the Warren Magnuson Grant Clinical Center of the National Institutes of Health.

Grant sponsor: National Human Genome Research Institute (Intramural Research Programs); Grant sponsor: National Institute on Deafness and Other Communication Disorders; Grant sponsor: National Institute on Aging.

*Correspondence to: Ruth M. Liberfarb, Genetics and Teratology Unit, Massachusetts General Hospital, Warren 801, Boston, MA 02114. E-mail: rml@massmed.org

Received 28 April 2005; Accepted 14 July 2005

DOI 10.1002/ajmg.a.30955

Published online 00 Month 2005 in Wiley InterScience (www.interscience.wiley.com)

INTRODUCTION

Stickler syndrome (hereditary arthro-ophthalmopathy) first recognized by Stickler et al. [1965] in a family with ocular, orofacial, auditory, and musculoskeletal abnormalities [Stickler and Pugh, 1967] is thought to be one of the most common autosomal dominant connective tissue disorders [Herrmann et al., 1975]. Subsequently over 100 reports including more than a dozen review articles on this syndrome have expanded the details of the phenotype affecting the ocular, craniofacial, auditory, and musculoskeletal systems and the heart, and highlighted the intra- and inter-familial variability [Liberfarb et al., 1981, 2003; Lucarini et al., 1987; Spallone, 1987; Seery et al., 1990; Snead et al., 1994, 1996; Wilkin et al., 1998; Martin et al., 1999; Snead and Yates, 1999; Richards et al., 2000a,b; Stickler et al., 2001; Szymko-Bennett et al., 2001; Rose et al., 2001a,b; Donoso et al., 2003; Poulson et al., 2004].

Molecular studies have demonstrated linkage to and subsequently mutations in the *COL2A1*, *COL11A1*, and *COL11A2* procollagen genes, and further loci are likely, as linkage to these three genes has been excluded in some affected families [Francomano et al., 1987, 1988; Ahmad et al., 1991, 1993; Brown et al., 1992; Brunner et al., 1994; Vikkula et al., 1995; van Steensel et al., 1997; Sirko-Osadsa et al., 1998]. A-2 → G transition at the 3' acceptor splice site of IVS 17 in *COL2A1* was found to be the mutation in the original Stickler family [Williams et al., 1996].

The molecular causes of the Stickler syndromes are mutations in type II or type XI collagen. Type II collagen is a homotrimer of three *COL2A1* gene products, while type XI collagen is a heterotrimer containing one each of the *COL2A1*, *COL11A1*, and *COL11A2* gene products [Byers, 1995]. Both are fibrillar collagens expressed primarily in cartilage, the vitreous, and nucleus pulposus. Type II and XI collagen are among the most abundant proteins in the middle and inner ear [Shpargel et al., 2004]. In type XI collagen found in the vitreous, the gene product of *COL5A2* replaces that of *COL11A2*.

The Stickler syndrome is now subclassified into three types based on ocular phenotype and molecular linkage [Online Mendelian Inheritance in Man, Johns Hopkins University, 1999, MIM Number 184840; Online Mendelian Inheritance in Man, Johns Hopkins University, 2000, MIM Number 108300, MIM Number 60481]. Most patients have characteristic congenital vitreous abnormalities with an apparently vestigial vitreous gel bordered by a folded membrane occupying the retrolental space. This membranous vitreous phenotype, type 1, has been linked to abnormalities in *COL2A1* and is associated with type I Stickler syndrome [Online Mendelian

Inheritance in Man, Johns Hopkins University, 2000, MIM Number 108300). In a clinical variant of type I, families with mutations in exon 2 of *COL2A1* present with the Stickler phenotype in the eye with minimal or absent extraocular findings [Donoso et al., 2003]. In another clinical variant of type I Stickler syndrome, a large family with linkage to the *COL2A1* gene has a unique L467F mutation in the X position of the type II collagen Gly-X-Y triple helix producing a novel “afibrillar” vitreous gel devoid of all lamellar structure, extending the mutation spectrum of the *COL2A1* gene and helping to explain the basis for different vitreous phenotypes seen in the Stickler syndromes [Richards et al., 2000^{Q1}].

The type 2 “beaded” vitreous phenotype, manifesting sparse, and irregular thickened bundles of fibers throughout the vitreous cavity, is linked to *COL11A1*, and is described as type II Stickler syndrome [Online Mendelian Inheritance in Man, Johns Hopkins University, 2000, MIM Number 60481].

Most recent publications confirm that vitreous slit-lamp biomicroscopy can be helpful in distinguishing between patients with *COL2A1* and *COL11A1* mutations based on the vitreous phenotype [Snead et al., 1994, 1996, 1999^{Q2}; Martin et al., 1999]. However in three recent reports there appears not to be a correlation between the gene mutation and vitreous phenotype. In one family, Parentin et al. [2002] reported that the type 1 or membranous vitreous was linked to *COL11A1*. By way of explanation, McLeod et al. [2002] hypothesized that an apparent conversion of the type 2 vitreous phenotype to a type 1-like appearance had occurred after the development of a posterior vitreous detachment (PVD) in a family followed by their group, and that the same phenomenon had occurred in Parentin et al.’s family prenatally. In reply, Parentin [2002] reported that the latest clinical history of one of his patients refutes the hypothesis of conversion from type 2 to type 1 after PVD; that patient had the same type 1 vitreous phenotype in both eyes prior to and following PVD in one eye. Parentin [2002] indicates that confusion still exists when trying to correlate vitreous phenotype with genotype and underlines the need to do further genetic studies involving greater size and number of pedigrees to better explain the correlation or lack of it between gene mutations and vitreous phenotypes.

In type III Stickler syndrome, patients whose phenotype manifests systemic features of Stickler syndrome with no ocular involvement have mutations in the *COL11A2* gene [Online Mendelian Inheritance in Man, Johns Hopkins University, 1999, MIM Number 184840].

Clinical manifestations of both Stickler syndromes type I and type II involve the ocular, orofacial, auditory, and musculoskeletal systems. Patients may develop myopia at a young age with vitreous abnormalities and predisposition to retinal lattice formation, holes, tears, and/or detachments and premature cataracts [Niffenegger et al., 1993]. Approximately one quarter have cleft palate, and another third have more subtle palatal abnormalities including submucous clefts or bifid uvulas [Stickler et al., 2001; Liberfarb et al., 2003]. Facial abnormalities include malar hypoplasia, flattening, or widening of the nasal bridge, and micro/retrognathia (Fig. 1). In our experience, the facial characteristics usually are less prominent in older individuals. High frequency sensorineural hearing loss progresses with age, and many patients have hypermobile tympanic membranes (Fig. 2) [Szymko-Bennett et al., 2001]. Nearly all patients have evidence of mild spondyloepiphyseal dysplasia [Herrmann et al., 1975; Liberfarb and Hirose, 1982] with frequent spinal abnormalities (scoliosis, Scheuermann-like kyphotic deformities, and spondylolisthesis) [Letts et al., 1999; Rose et al., 2001a]. Premature osteoarthritis is common, and there appears to be a predisposition to femoral head complications (Legg-Perthes like disease or slipped epiphysis) [Rose et al., 2001b].

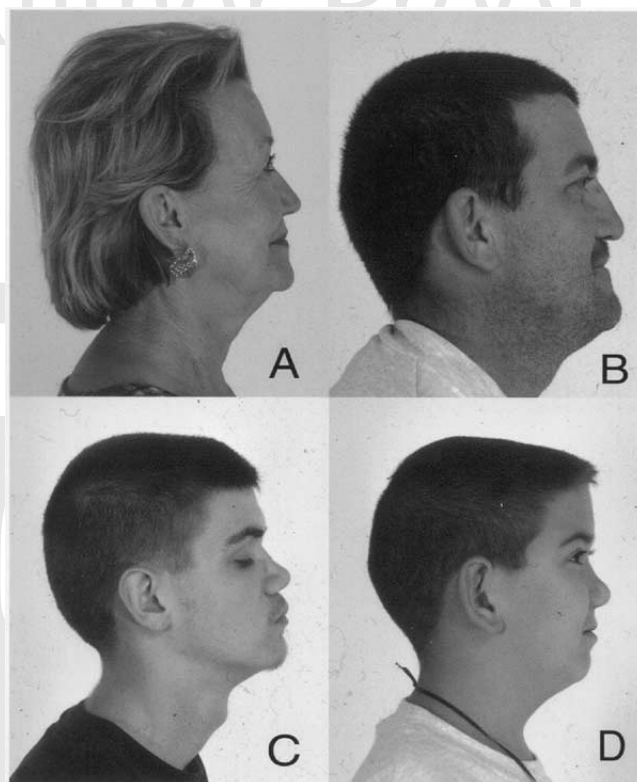


Fig. 1. Profiles of three generations of affected relatives with type I Stickler syndrome and known *COL2A1* mutation demonstrate characteristic face (short midface, micro/retrognathia, and depressed nasal bridge): (a) grandmother, age 55; (b) son, age 37; (c) grandson, age 13; and (d) grandson, age 9 years.

Previous authors have proposed diagnostic criteria for Stickler syndrome based on vitreous phenotype (for which a slit lamp examination is needed) and requiring involvement in various organ systems (e.g., congenital vitreous anomaly plus any three of the following: myopia with onset before 6 years; rhegmatogenous retinal detachment or perivascular pigmented lattice degeneration; joint hypermobility with an abnormal

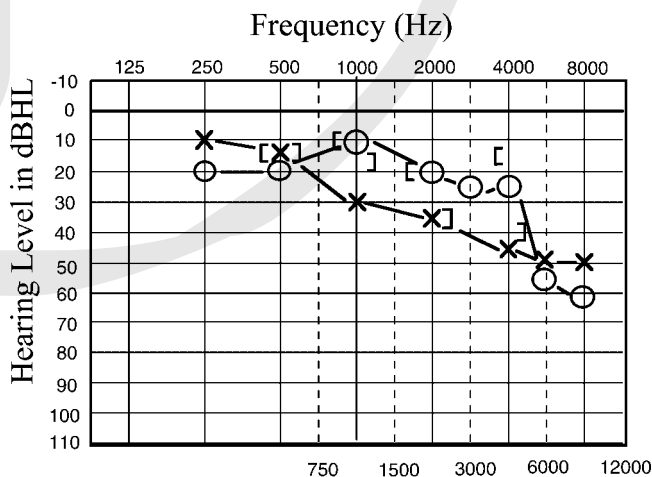


Fig. 2. Audiogram of patient with type I Stickler syndrome and a known *COL2A1* mutation. Hearing thresholds for right ear indicated by ○, left ear by ×; brackets indicate masked bone conduction thresholds for each ear.

Beighton score with or without radiological evidence of joint degeneration; audiometric confirmation of sensorineural hearing defect; and midline clefting) [Snead et al., 1994, 1996; Snead and Yates, 1999]. Unfortunately, it is not always possible to determine vitreous phenotype using slit-lamp biomicroscopy in children 4 years and younger (unless an examination under anesthesia is performed) or in patients with prior retinal surgeries (following retinal detachment, vitrectomy is often performed and prevents subsequent distinction between the type I and II phenotypes).

We propose diagnostic criteria for Stickler syndrome based on involvement in ocular, orofacial, auditory, and musculoskeletal systems. The diagnostic criteria were developed from clinical data on 22 patients from six families diagnosed because of clinical manifestations of type I Stickler syndrome, and then confirmed by molecular analysis demonstrating mutations in *COL2A1*. We further report the application of these criteria to a larger cohort of 47 patients from 25 families clinically diagnosed with Stickler syndrome (44 patients with type I or II Stickler syndrome, two with type II and one with type III without ocular problems and a negative family history) in whom molecular confirmation is not yet available.

MATERIALS AND METHODS

We reviewed clinical and molecular data on 90 patients from 38 families evaluated for Stickler syndrome at the National Institutes of Health Medical Genetics Clinic. All patients were enrolled (with written informed consent) in a natural history and molecular etiology study approved by the National Human Genome Research Institute Institutional Review Board (NIH protocol 97-HG-0089). Patients under age 5 years were excluded from analysis because of the difficulty in obtaining complete ocular, auditory, and radiographic data.

All patients age 5 years and older were examined by one or more medical geneticists experienced in diagnosing Stickler syndrome and related connective tissue disorders (CAF, HPL, RML). All underwent eye examination by ophthalmologists experienced in evaluating connective tissue disorders (BIR, ET); otorhinolaryngological examination (AJG), and audiological evaluation (YMS-B) by specialists experienced in evaluating Stickler syndrome patients; and all had musculoskeletal evaluations including determination of the Beighton score and skeletal radiology of the spine and long bones (PR). Retinal detachment was ascertained by history and vitreous changes were observed by ophthalmologic examination. High frequency sensorineural hearing loss was evaluated by audiologic examination with deficits defined by age specific thresholds at or greater than the 95th centile for normal values at 4 kHz [Morrell et al., 1996; Szymko-Bennett et al., 2001]. Palatal abnormalities were defined by otorhinolaryngologist examination. Hypermobile tympanic membranes were defined by tympanometry. Scoliosis was defined as sagittal curvature of the spine $>10^\circ$ as measured by the technique of Cobb [1948]. Scheuermann-like kyphosis was defined as a focal kyphosis with 5° or greater vertebral body wedging across three consecutive vertebral bodies (for a minimum 15° focal kyphosis) [Fon et al., 1980; Freeman, 2003]. Osteoarthritis was defined as articular pain in conjunction with joint space narrowing, osteophytes, or subchondral sclerosis or cysts. Characteristic facial changes were defined as the triad of malar hypoplasia, a broadened or flat nasal bridge, and micro/retrognathia. Family history was considered contributory if a 1st degree relative independently met diagnostic criteria. Designation as clinically affected or unaffected was determined prior to development or application of the diagnostic criteria proposed herein.

Initially, 40 families were screened for mutations in the type II collagen gene locus *COL2A1*. Five mutations were found in multiple members of eight families by polymerase chain

reaction amplification of sequences containing in-frame CGA codons in *COL2A1* (which are mutable to TGA stop codons via a methylation-deamination mechanism) [Wilkin et al., 2000]. In addition, frameshift mutations in two families were detected using denaturing high performance liquid chromatography (DHPLC) to analyze PCR fragments including intron/exon boundaries amplified from genomic DNA. Products showing a shift on DHPLC were then sequenced for mutation analysis. As a result of the screening procedure, a total of seven mutations in the type II collagen gene locus *COL2A1* were found in 47 individuals from 10 families [Liberfarb et al., 2003]. In two families, the proband was a child with a de novo mutation. All 10 families were invited to the NIH genetics clinic for a comprehensive clinical evaluation. Individuals from six of the families exhibiting five different mutations accepted our invitation and had complete evaluations at NIH. The other four families allowed us to review medical records. Affected members of the 10 families with confirmed mutations had similar phenotypes, though both inter- and intra-familial variability was apparent and extensive [Liberfarb et al., 2003]. In addition, individuals from 31 families with the clinical diagnosis of type I and type II Stickler syndrome and one individual with type III (non-ocular Stickler syndrome) had comprehensive evaluations at NIH. Molecular analysis of these families is planned.

Patients pictured in Figure 1 provided written consent for publication of unmasked facial photographs.

RESULTS

Ninety patients over age 5 years from 38 families had complete evaluations for possible Stickler syndrome (M:F 34:56; age range from 5 to 69 years). Of these, molecular confirmation of *COL2A1* mutation status (type I Stickler syndrome) was available on 25 patients from six families (22 affected and three unaffected by mutation analysis). In the remaining 65 patients from 32 families, 47 from 25 families were affected and 18 from seven families were unaffected with Stickler syndrome. Of the 47 affected patients, on the basis of eye findings, 16 have type I Stickler syndrome, two have type II, and one has type III. In the remaining affected individuals, the ocular phenotype was either overlapping or too severe to distinguish type I from type II Stickler syndrome, or could not be determined due to prior surgery.

Molecular data on 22 patients from six families with known *COL2A1* mutations are presented in Table I. All had ocular, orofacial, auditory, and musculoskeletal abnormalities characteristic of type I Stickler syndrome. The clinical data on these 22 patients with known *COL2A1* mutations is shown in Table II. All patients who could have vitreous examinations had type I vitreous findings.

Proposed diagnostic criteria based on analysis of 22 patients with type I Stickler syndrome with known *COL2A1* mutations are presented in Table III. These criteria evaluate the major manifestations of the disorder and are structured similarly to the Ghent criteria for the diagnosis of Marfan syndrome [De Paepe et al., 1996]. Patients are classified as affected if they have a diagnostic score of five or more points (of nine maximum) and have at least one "major" (2 point) orofacial, ocular, or auditory manifestation (cleft palate, submucous cleft palate, and/or bifid uvula, characteristic vitreous changes or retinal abnormalities, high frequency sensorineural hearing loss) and do not have findings of a more severe skeletal dysplasia or other syndrome.

All 22 Stickler type I patients with molecular confirmation of *COL2A1* mutations (average age = 38.8 years) satisfied these diagnostic criteria (average score 7.4; range 5–9). Additionally, 47 patients diagnosed with Stickler syndrome on whom molecular data were not available (average age = 34.8 years)

TABLE I. Molecular Data on 22 Patients With Type I Stickler Syndrome and Known *COL2A1* Mutations

Family	Number seen at NIH/number affected	Patient	Exon	Nucleotide ^a	Amino acid ^b
2	7/8	1–7	12	883delC	L95fsX107
3	2/11	8, 9	15	625C > T	R9X
4	4/8	10–13	22	1563del5	G322fsX345
5	3/4	14–16	23	1597C > T	R333X
6	3/5	17–19	23	1597C > T	R333X
9	3/3	20–22	40	2794C > T	R732X

^aNucleotide position is from ATG of variant 1 mRNA (GenBank reference number NM_001844).

^bAmino acid position is from the start of the triple helical domain.

satisfied these criteria (average score 7.5; range 4–9). One 35 years old woman considered to be clinically affected (ocular phenotype too severe to distinguish type I from type II) with characteristic vitreous changes, retinal detachment, premature osteoarthritis, and spinal deformity but without a family history of Stickler syndrome, orofacial or significant auditory abnormalities scored 4 of 9 on our criteria. High frequency sensorineural hearing loss was present in this patient but had not yet reached the threshold used in this study.

A clinical summary of all patients evaluated in this study is presented in Table IV. There was no difference in the clinical severity of the 22 patients with molecular confirmation of affected status and the 47 patients diagnosed on clinical grounds. The diagnostic scores of all patients evaluated in this study is presented in Figure 3A (molecularly confirmed and excluded) and Figure 3B (clinically confirmed and excluded).

Three molecularly excluded patients (average age = 36.6 years) had scores of 0, 1, and 1 with an average of 0.6. Fifteen of the unaffected patients evaluated (average age = 27 years) had scores ranging from 0 to 4 with an average of 1.33. Four patients are completely unaffected and had a diagnostic score of zero. Three relatives of Stickler patients had diagnostic scores of one point for positive family history because they had an affected relative. Seven patients had minimal findings suggestive of a possible non-specific connective tissue disorder, not Stickler syndrome. Two sibs had type I vitreous changes without extra ocular involvement. Each had a diagnostic score of 2. They might be considered examples of the variant of type I Stickler syndrome caused by a mutation in exon 2 of *COL2A1*. However, the parents' normal eyes make the diagnosis of autosomal dominant Stickler syndrome unlikely. Their mother had a diagnostic score of one for Scheuermann-like kyphosis. Another patient, a woman 30 years old and with no family history of Stickler syndrome, was referred for evaluation with non-specific vitreous degeneration associated with mild myopia, mitral valve prolapse, early onset degenerative arthritis and scoliosis. Her diagnostic score was 4. Three other related patients had no eye involvement and minimal extraocular manifestations such as bifid uvula and hypermobile tympanic membrane in a father, bifid uvula in one daughter and significant sensorineural hearing loss in another daughter. The father had a diagnostic score of 3 and each daughter had a diagnostic score of 2. Another patient with an affected brother had a diagnostic score of 3, one point for family history of Stickler syndrome and two points for a retinal detachment that occurred after a cataract extraction. The other three clinically excluded patients (average age = 9.6 years) had diagnostic scores of 6, 7, and 8 and would have been diagnosed under these criteria. However, each of these had a clinically distinct phenotype (unique unnamed syndrome, Kniest syndrome, and spondyloepimetaphyseal dysplasia, or SEMD, respectively) easily differentiated from Stickler syndrome.

DISCUSSION

The difficulties in obtaining molecular analysis on patients diagnosed as having Stickler syndrome can be explained because of the size, complexity, and number of genes involved. Where the service is available, it is costly and not generally covered by insurance. Molecular analysis of the 47 clinically diagnosed patients is planned. In the meantime, we decided that it would be useful for clinicians not familiar with Stickler syndrome to develop diagnostic criteria based on our 22 patients with molecular confirmation of type I Stickler syndrome.

These proposed diagnostic criteria for type I Stickler syndrome are centered on four sets of manifestations (orofacial, ocular, auditory, and musculoskeletal). Although mitral valve prolapse (MVP) had been reported as common in Stickler syndrome [Liberfarb and Goldblatt, 1986], we did not include it for two reasons. First, this finding lacks specificity among heritable disorders of connective tissue. Second, the criteria for echocardiographic diagnosis of MVP have undergone revision since its report as a common manifestation in Stickler syndrome. Using current criteria, MVP is a relatively uncommon finding in Stickler syndrome patients [Ahmad et al., 2003; Liberfarb et al., 2003].

Our proposed diagnostic criteria demonstrate 100% sensitivity when applied to a population of Stickler patients with ocular and systemic changes and known *COL2A1* mutations, which is expected since the criteria were developed based on findings in these 22 patients. More importantly, the diagnostic criteria demonstrate 98% sensitivity when applied to a larger cohort of patients clinically diagnosed as having Stickler syndrome on the basis of the four commonly affected systems. In this group, molecular analysis is not yet available. The single patient considered to be clinically affected who was not diagnosed under these criteria scored only 4 points, she has hearing loss which has not yet reached the threshold in our criteria but may do so in the future. Thus, these diagnostic criteria demonstrate a high sensitivity for patients with type I Stickler syndrome.

Of the 47 Stickler patients without molecular confirmation, only two were diagnosed as having type II Stickler syndrome and only one as having type III Stickler syndrome. These three met the diagnostic criteria as well. The numbers in our study were too small for statistical analysis; however, the only published clinical distinctions between the three Stickler types have been the presence/absence of ocular findings and specific type of vitreous change. Therefore one might logically suspect that these criteria would prove equally sensitive and specific for type II, and only slightly less sensitive for the non-ocular type III.

There were no patients in the study with only ocular findings as in the variant of type I with mutation in exon 2 of *COL2A1*. We did not intend these diagnostic criteria to be applied to any ocular-only phenotype(s), but rather to multi-system

TABLE II. Clinical Data on Type I Stickler Syndrome Patients With Known COL2A1 Mutations

Family	Patient	Age at last exam (years)	Sex	Face	Orofacial			Ocular		Auditory			Skeletal					
					Open cleft	Submucous cleft	Bifid uvula	Vitreous changes	Retinal changes ^b	High frequency hearing loss	Hypermobile TMJs	Femoral head failure	Osteoarthritis ^c	Scoliosis	Spondylolisthesis	Scheuermann kyphosis	Score ^d	
2	1 ^e	7	F	-	+	-	+	-	+	-	-	-	-	-	-	-	-	7
	2	11	M	+	-	-	+	+	+	-	-	-	-	-	-	-	-	7
	3	15	M	-	-	-	+	+	+	+	+	+	+	+	+	+	+	6
	4	31	F	+	-	-	+	+	+	+	+	+	+	+	+	+	+	9
	5	37	M	-	-	-	+	+	+	+	+	+	+	+	+	+	+	9
	6	56	F	-	+	-	+	+	+	+	+	+	+	+	+	+	+	9
	7	57	M	-	+	-	+	+	+	+	+	+	+	+	+	+	+	9
3	8	26	F	-	-	+	+	+	+	+	+	+	+	+	+	+	+	5
	9	49	F	-	+	-	+	+	+	+	+	+	+	+	+	+	+	9
	10	20	F	+	+	-	+	+	+	+	+	+	+	+	+	+	+	5
4	11	35	M	+	-	-	+	+	+	+	+	+	+	+	+	+	+	9
	12	36	F	+	+	+	+	+	+	+	+	+	+	+	+	+	+	9
	13	58	F	+	-	-	+	+	+	+	+	+	+	+	+	+	+	8
	14 ^a	23	F	+	-	-	+	+	+	+	+	+	+	+	+	+	+	5
	15	26	M	-	-	-	+	+	+	+	+	+	+	+	+	+	+	5
	16	53	M	+	-	-	+	+	+	+	+	+	+	+	+	+	+	6
6	17	30	F	+	-	-	+	+	+	+	+	+	+	+	+	+	+	9
	18	55	F	+	-	-	+	+	+	+	+	+	+	+	+	+	+	7
	19	57	F	-	-	-	+	+	+	+	+	+	+	+	+	+	+	6
	20 ^a	6	M	-	+	-	+	+	+	+	+	+	+	+	+	+	+	6
9	21	M	-	+	-	+	+	+	+	+	+	+	+	+	+	+	+	9
	22	70	M	+	-	-	+	+	+	+	+	+	+	+	+	+	+	8

^aVitreous changes were noted in the medical history but prior surgery prevented vitreous examination at NIH.

^bRetinal changes includes detachment, tear, holes or lattice degeneration.

^cPremature osteoarthritis could not be assessed on patients who were over age 40 at time of first evaluation.

^dScore on diagnostic criteria presented in Table III.

^eProband.

TABLE III. Diagnostic Criteria for Type I Stickler Syndrome

Orofacial abnormalities (2 points maximum)	Cleft palate (open cleft, submucous cleft, or bifid uvula) (major)
2 points	Characteristic face (malar hypoplasia, broad or flat nasal bridge, and micro/retrognathia)
1 point	
Ocular abnormalities (2 points maximum)	Characteristic vitreous changes or retinal abnormalities (lattice degeneration, retinal hole, retinal detachment or retinal tear) (major)
2 points	
Auditory abnormalities (2 points maximum)	High frequency sensorineural hearing loss (major)
2 points	Age < 20: threshold ≥ 20 dB at 4–8 kHz
	Age 20–40: threshold ≥ 30 dB at 4–8 kHz
	Age > 40: threshold ≥ 40 dB at 4–8 kHz
1 point	Hypermobility tympanic membranes
Skeletal abnormalities (2 points maximum)	Femoral head failure (slipped epiphysis or Legg–Perthes-like disease)
1 point	Radiographically demonstrated osteoarthritis before age 40
1 point	Scoliosis, spondylolisthesis, or Scheuermann-like kyphotic deformity
1 point	
Family history/molecular data	Independently affected 1st degree relative in a pattern consistent with autosomal dominant inheritance or presence of <i>COL2A1</i> , <i>COL11A1</i> , or <i>COL11A2</i> mutation associated with Stickler syndrome
1 point	
Diagnosis requires	5 or more points
	At least one major 2-point manifestation
	Absence of features suggestive of a more severe skeletal dysplasia or other syndrome (e.g., stature < 5th percentile)

connective tissue disorders. To change the diagnostic criteria to pick up the ocular-only phenotype would dilute the specificity so that the clinical utility would be lost. While it is important to make the diagnosis of the ocular-only variant of type I Stickler syndrome, it was not the goal of this work to do that. The diagnosis of the type I variant must depend on the clinical suspicion of the examining ophthalmologist and molecular confirmation of the mutation in exon 2 of *COL2A1*.

The specificity of the diagnostic criteria for type I Stickler syndrome cannot be directly ascertained unless there is comparison to a control population with complete medical history and physical, ophthalmologic, audiologic, and radiographic examinations. We are able to report these findings on a group of 21 patients referred for evaluation of possible Stickler syndrome. Eighteen of these patients failed to meet our proposed diagnostic criteria. Three scored 5 or more on these diagnostic criteria. However, each of the three “false positives” had a distinctive clinical phenotype allowing for easy differentiation from the Stickler syndrome.

Additionally, the background prevalence of the components of our diagnostic criteria suggests that these criteria will display a high specificity when applied to a larger population.

The incidence of retinal detachment and similar abnormalities is estimated at 10.1 per 100,000 person-years [Wilkes et al., 1982]. Cleft palate (including submucous cleft and bifid uvula) occurs in less than one in 100 patients [Schurter and Letterman, 1966; Weatherley-White et al., 1972]. The proposed audiology criteria identify only those individuals beyond the 95th centile in hearing loss and tympanic membrane mobility [Szymko-Bennett et al., 2001]. Idiopathic scoliosis occurs in approximately 2% of adolescents, and other spinal abnormalities have similar frequencies [Rogala et al., 1978]. Symptomatic osteoarthritis before age 40 and femoral head failure in youth are very rare events, well beyond two standard deviations from normal [Barker and Hall, 1986; Carney et al., 1991; Tepper and Hochberg, 1993]. Taken in combination, it is unlikely that patients without Stickler syndrome or a closely related disorder will fulfill these diagnostic criteria by random chance.

Patients with Marshall syndrome are also expected to satisfy the diagnostic criteria for Stickler syndrome but in spite of some clinical overlap with the types of Stickler syndrome as shown in Table V, they differ [Ayme and Preus, 1984; Annunen et al., 1999]. Marshall syndrome patients have: short stature;

TABLE IV. Clinical Summary of Patients Evaluated for Type I Stickler Syndrome

	Number	Orofacial system		Ocular system		Auditory system		Skeletal system			Score
		Face	Palate	Vitreous ^a	Retina	Hearing loss	Hyper-mobile TM ^c	Premature osteoarthritis ^d	Spine	Femoral head failure	
Molecularly Confirmed	229 M: 13 F	10	13	22	17	16	8	14	15	4	7.4
Molecularly Excluded	33 F	0	0	0	0	0	1	0	1	0	0.6
Clinically Confirmed	4719 M: 28 F	34	30	46	30	38	20	35	28	9	7.7
Clinically Excluded	186 M: 12 F	1	5	3	1 ^b	1	4	1	2	0	2.5

^aVitreous changes in some patients could not be determined because of previous surgeries.

^bRetinal detachment post cataract surgery.

^cTM = tympanic membrane.

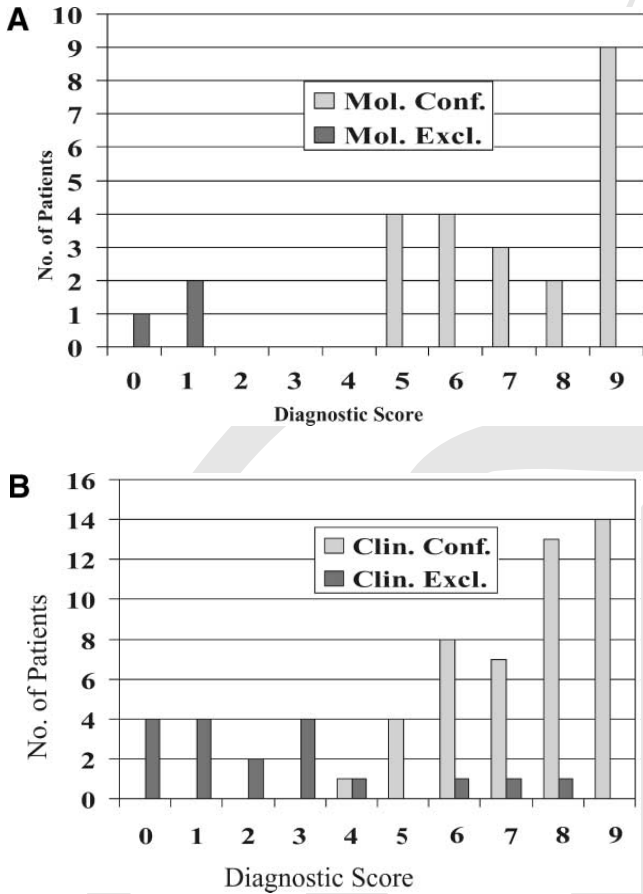


Fig. 3. **A:** Summary of diagnostic scores of affected patients with type I Stickler syndrome, molecularly confirmed (mol. conf.) and unaffected relatives molecularly excluded (mol. excl.); and **(B)** summary of diagnostic scores of clinically confirmed Stickler patients (clin. conf.) and others clinically excluded (clin. excl.).

more pronounced dysmorphic facial features (a flat, retracted midface, a short nose, anteverted nostrils, and shallow orbits) not lessened with age; abnormalities in cranial ossifications; less frequent vitreoretinal degeneration and retinal detachments; congenital and juvenile cataracts; and moderate to severe congenital or early onset hearing loss. Thus, it is unlikely that syndromic overlap will lead to misclassification of patients using these diagnostic criteria for Stickler syndrome.

Molecular studies have indicated that patients with a splicing mutation in a 54-bp exon or with a mutation causing a 54-bp deletion in the C-terminal half of the *COL11A1* gene frequently have findings related to Marshall syndrome [Annunen et al., 1999]. However, other mutations in the *COL11A1* gene resulted in overlapping phenotypes of Marshall and type I Stickler syndrome, possibly explaining the conflicting reports of whether Stickler and Marshall syndromes are separate entities [Annunen et al., 1999].

Stickler syndrome is among the most common autosomal dominant connective tissue disorders but is often unrecognized and therefore not diagnosed by clinicians. Ten percent of patients with isolated cleft palate and 12% with the Pierre-Robin sequence were found to have undiagnosed Stickler syndrome in recent studies [Sheffield et al., 1987; Kronwith et al., 1990]. In a small series of children with an assortment of non-specified disorders causing visual loss attending a pre-school for the visually impaired, examiners found 10% to be affected with Stickler syndrome [Printzlau and Anderson,

TABLE V. Comparison of Clinical Features in Stickler Syndromes and Marshall Syndrome

Chromosome/gene	Stickler syndrome type I ^a	Stickler syndrome type I variant ^b	Stickler syndrome type II ^c	Stickler syndrome type III ^d	Marshall syndrome ^e
	12q13.1-q13.2/ <i>COL2A1</i> 52 (exons 1, 3-53)	12q13.1-q13.2/ <i>COL2A1</i> 1 (exon 2)	1p21/ <i>COL11A1</i>	6p21.3/ <i>COL11A2</i>	1p21/ <i>COL11A1</i>
Number of exons	52 (exons 1, 3-53)	1 (exon 2)	66	68	68
Vitreoretinal degeneration	100%	100%	100%	0%	33.3%
Retinal detachment	68%	57%-91%	42%-53%	0%	10%
Cataract	40% (late onset)	78%	64%	NR	40% (congenital or early onset)
Myopia	100%	83%	81%-100%	0%	100%
Cranial abnormalities	0%	NR	43%	NR	66%
Midfacial hypoplasia	72%	0%-41%	Mild, if at all	100%	100%
Palatal abnormalities	64%	23%	12.5%-33.3%	55%	80%
Hearing loss	76% (mild-moderate)	47%	75%-80%	100%	100% (moderate-severe)
Early onset osteoarthritis	60%	NR	50%	55%	NR
Short stature	Rare	NR	NR	44%	60%
Joint hypermobility	52%	12%	12.5%-33%	NR	NR
Ectodermal dysplasia	NR	NR	0%	NR	100%
Mitral valve prolapse	4%	NR	0%	NR	NR

^aLiberfarb et al. [2003].
^bRichards et al. [2000]; Donoso et al. [2003]; Poulson et al. [2004].
^cRichards et al. [1996].
^dVikkula et al. [1995]; Sirko-Osadsa et al. [1998].
^eAnnunen et al. [1999].
 NR, none reported.

2004]. It is likely that some patients presenting with retinal detachment or skeletal abnormalities such as scoliosis or Legg–Perthes disease have unrecognized Stickler syndrome.

Recognition of Stickler syndrome has important medical and personal consequences for patients and their families. Early identification of ocular and auditory abnormalities allows surveillance for and early treatment of complications. Similarly, correct diagnosis allows prognosis of and surveillance for skeletal complications and genetic counseling for affected families. Of equal value, exclusion of the Stickler syndrome can provide reassurance or lead to further evaluation to establish the correct diagnosis.

ACKNOWLEDGMENTS

The authors thank the patients for their participation in this research with special gratitude for those who gave permission to use their photographs in the publication. The authors also thank Joan Z. Balog, R.N., M.S.N., for her invaluable support to the clinical investigators and for her excellent assistance in coordinating the patients' appointment scheduling at NIH and travel to NIH and home.

REFERENCES

- Ahmad NN, Ala-Kokko L, Knowlton RG, Jimenez SA, Weaver EJ, Maguire JL, Tasman W, Prokop DJ. 1991. Stop codon in the procollagen gene II (*COL2A1*) in a family with the Stickler syndrome (arthro-ophthalmopathy). *Proc Natl Acad Sci USA* 88:6624–6627.
- Ahmad NN, McDonald-McGinn DM, Zackai EH, Knowlton RG, La Rossa D, DiMascio J, Prokop DJ. 1993. A second mutation in type II procollagen gene (*COL2A1*) causing Stickler syndrome is also a premature termination codon. *Am J Hum Genet* 52:39–45.
- Ahmad N, Richards AJ, Murfett HC, Shapiro L, Scott JD, Yates JR, Norton J, Snead MP. 2003. Prevalence of mitral valve prolapse in Stickler syndrome. *Am J Med Genet* 116A:234–237.
- Annunen S, Korkko J, Czarny M, Warman ML, Brunner HG, Kaarianen H, Mulliken JB, Tranebjærg L, Brooks DJ, Cox GF, Cruysberg JR, Curtis MA, Davenport SLH, Friedrich CA, Kaitila I, Krawczynski MR, Latos-Bielenska A, Mukai S, Olsen BR, Shinno N, Somer M, Vikkula M, Zlotgora J, Prokop DJ, Ala-kokko L. 1999. Splicing mutations of 54-bp exons in the *COL11A1* gene cause Marshall syndrome, but other mutations cause overlapping Marshall/Stickler phenotypes. *Am J Hum Genet* 65:974–983.
- Ayme S, Preus M. 1984. The Marshall and Stickler syndromes: Objective rejection of lumping. *J Med Genet* 21:34–38.
- Barker DJ, Hall AJ. 1986. The epidemiology of Perthes' disease. *Clin Orthop* 209:89–94.
- Brown DM, Nichols BE, Weingest TA, Sheffield VC, Kimura AE, Stone EM. 1992. Procollagen II gene mutation in Stickler syndrome. *Arch Ophthalmol* 110:1593.
- Brunner HG, van Beersum SEC, Warman ML, Olsen BR, Ropers H-H, Mariman ECM. 1994. A Stickler syndrome gene is linked to chromosome 6 near *COL11A2* gene. *Hum Mol Genet* 3:1561–1564.
- Byers PH. 1995. Disorders of collagen biosynthesis and structure. In: Scriver CR., Beaudet AL, Sly WS, Valle D, editors. *The metabolic and molecular basis of inherited diseases*. New York: McGraw-Hill. pp4029–4077.
- Carney BT, Weinstein SL, Noble J. 1991. Long-term follow-up of slipped capital femoral epiphysis. *J Bone Joint Surg Am* 73:667–674.
- Cobb JR. 1948. Outline for the study of scoliosis. *Instr Course Lect* 5:261–275.
- Freeman BL III. 2003. Scoliosis and kyphosis. In: Canale ST, editor. *Campbell's operative orthopaedics*. New York: Mosby. p 1877.
- De Paepe A, Devereux RB, Dietz HC, Hennekam RC, Pyeritz RE. 1996. Revised diagnostic criteria for the Marfan syndrome. *Am J Med Genet* 62:417–426.
- Donoso LA, Edwards AO, Frost AT, Ritter R III, Ahmad N, Vrabec T, Rogers J, Meyer D, Parma S. 2003. Clinical variability of Stickler syndrome: Role of exon 2 of the collagen *COL2A1* Gene. *Surv Ophthalmol* 48:191–199.
- Fon GT, Pitt MJ, Theis AC. 1980. Thoracic kyphosis: Range in normal subjects. *Am J Roentgenol* 134:979–983.
- Francomano CA, Liberfarb RM, Hirose T, Maumenee IH, Streeten EA, Myers DA, Pyeritz RE. 1987. The Stickler syndrome: Evidence for close linkage to the structural gene for type II collagen. *Genomics* 1:293–296.
- Francomano CA, Liberfarb RM, Maumenee IH, Streeten EA, Myers DA, Pyeritz DA. 1988. The Stickler syndrome is closely linked to *COL2A1*, the structural gene for type II collagen. *Pathol Immunopathol* 7:104–106.
- Herrmann J, France TD, Spranger JW, Opitz JM, Wiffler C. 1975. The Stickler syndrome (hereditary arthroophthalmopathy). *Birth Defects Orig Artic Ser* 11:76–103.
- Kronwith SD, Quinn G, McDonald DM, Cardonick E, Onyx P, LaRossa D, Borns P, Stambolian DF, Zackai EH. 1990. Stickler's syndrome in the cleft palate clinic. *J Pediatr Ophthalmol Strabismus* 27:265–267.
- Letts M, Kabir A, Davidson D. 1999. The spinal manifestations of Stickler's syndrome. *Spine* 24:1260–1264.
- Liberfarb RM, Goldblatt A. 1986. Prevalence of mitral valve prolapse in the Stickler syndrome. *Am J Med Genet* 24:387–393.
- Liberfarb RM, Hirose T. 1982. The Wagner–Stickler syndrome. *Birth Defects Orig Artic Ser* 18:525–538.
- Liberfarb RM, Hirose T, Holmes LB. 1981. The Wagner–Stickler syndrome. *J Pediatr* 99:394–399.
- Liberfarb RM, Levy H, Rose PS, Wilkin DJ, Davis J, Balog JZ, Griffith AJ, Szymko-Bennett YM. 2003. The Stickler syndrome: Genotype/phenotype correlation in 10 families with Stickler syndrome resulting from seven mutations in the type II collagen gene locus *COL2A1*. *Genet Med* 5:21–27.
- Lucarini JW, Liberfarb RM, Eavey RD. 1987. Otolaryngological manifestations of the Stickler syndrome. *Int J Pediatr Otolaryngol* 14:215–222.
- Martin S, Richards AJ, Yates JR, Scott JD, Pope M, Snead MP. 1999. Stickler syndrome: Further mutations in *COL11A1* and evidence for additional locus heterogeneity. *Eur J Hum Genet* 7:807–814.
- McLeod D, Black GCM, Bishop PN. 2002. Vitreous phenotype: Genotype correlation in Stickler syndrome. *Graefes Arch Clin Exp Ophthalmol* 240:63–65.
- Morrell CH, Gordon-Salant S, Pearson JD, Brant LJ, Fozard JL. 1996. Age- and gender-specific reference ranges for hearing level and longitudinal changes in hearing level. *J Acoust Soc Am* 100:1949–1967.
- Niffenegger JH, Topping TM, Mukai S. 1993. Stickler's syndrome. *Int Ophthalmol* 33:271–280.
- Online Mendelian Inheritance in Man, Johns Hopkins University. 1999. Stickler syndrome, Type III; MIM Number 184840: 7/12/99. World Wide Web URL: <http://www.ncbi.nlm.nih.gov/omim/>
- Online Mendelian Inheritance in Man, Johns Hopkins University. 2000. Stickler syndrome, Type I; MIM Number 108300: 2/25/00. World Wide Web URL: <http://www.ncbi.nlm.nih.gov/omim/>
- Online Mendelian Inheritance in Man, Johns Hopkins University. 2000. Stickler syndrome, Type II; MIM Number 60481: 4/16/00. World Wide Web URL: <http://www.ncbi.nlm.nih.gov/omim/>
- Parentin F. 2002. Reply to McLeod et al.: Vitreous phenotype genotype correlation in Stickler syndrome. *Graefes Arch Clin Exp Ophthalmol* 66: p 240.
- Parentin F, Sangalli A, Mottes M, Perissutti P. 2002. Stickler syndrome and vitreoretinal degeneration: Correlation between locus mutation and vitreous phenotype. A propos of a case. *Graefes Arch Clin Exp Ophthalmol* 239:316–319.
- Poulson AV, Hooymans JMM, Richards AJ, Bearcroft P, Murphy R, Baguley DM, Scott DJ, Snead MP. 2004. Clinical features of type 2 Stickler syndrome. *J Med Genet* 41:e107.
- Printzlau A, Anderson M. 2004. Pierre–Robin sequence in Denmark: A retrospective study. *Cleft Palate Craniofac J* 41:47–52.
- Richards AJ, Baguley DM, Yates JR, Lane C, Nicol M, Harper PS, Scott JD, Snead MP. 2000a. Variation in the vitreous phenotype of Stickler syndrome can be caused by different amino acid substitutions in the X position of the type II collagen Gly–X–Y triple helix. *Am J Hum Genet* 67:1083–1094.
- Richards AJ, Martin S, Yates JRW, Scott JD, Baguley DM, Pope FM, Snead MP. 2000b. *COL2A1* exon 2 mutations: Relevance to the Stickler and Wagner syndromes. *Br J Ophthalmol* 84:364–371.

- Rogala EJ, Drummond DS, Gurr J. 1978. Scoliosis: Incidence and natural history. A prospective epidemiological study. *J Bone Joint Surg Am* 60:173–176.
- Rose P, Ahn N, Levy H, Ahn U, Davis J, Liberfarb R, Sponseller PD, Francomano CA. 2001a. The hip in the Stickler syndrome. *J Pediatr Orthop* 21:657–663.
- Rose P, Ahn N, Levy HP, Davis J, Liberfarb RM, Nallamshetty L, Sponseller PD, Francomano CA. 2001b. Thoracolumbar spinal abnormalities in Stickler syndrome. *Spine* 26:403–409.
- Schurter M, Letterman G. 1966. The incidence of cleft lip and cleft palate. An analysis of the literature with the addition of statistics. *J Am Med Womens Assoc* 21:915–920.
- Seery P, Pruett RC, Liberfarb RM, Cohen BZ. 1990. Distinctive cataract in the Stickler syndrome. *Am J Ophthalmol* 110:143–148.
- Sheffield LJ, Reiss JA, Strohm K, Gilding M. 1987. A genetic follow-up study of 64 patients with the Pierre Robin complex. *Am J Med Genet*^{Q8} 28:25–36.
- Shpargel KB, Makishima T, Griffith AJ. 2004. *COL11A1* and *COL11A2*mRNA expression in the developing mouse cochlea: Implications for the correlation of hearing loss phenotype with mutant type XI collagen genotype. *Acta Laryngol* 124:242–248.
- Sirko-Osadsa DA, Murray MA, Scott JA, Lavery MA, Warman ML, Robin NH. 1998. Stickler syndrome without eye involvement is caused by mutations in *COL11A2*, the gene encoding the alpha2(XI) chain of type XI collagen. *J Pediatr* 132:368–371.
- Snead MP, Yates JR. 1999. Clinical and molecular genetics of Stickler syndrome. *J Med Genet* 36:353–359.
- Snead MP, Payne SJ, Barton DE, Yates JRW, Al-Imara L, Pope FM, Scott JD. 1994. Stickler syndrome: Correlation between vitreoretinal phenotypes and linkage to *COL2A1*. *Eye* 8:609–614.
- Snead MP, Yates JR, Williams R, Payne SJ, Pope FM, Scott JD. 1996. Stickler syndrome type 2 and linkage to the *COL11A1* gene. *Ann NY Acad Sci* 785:331–332.
- Spallone A. 1987. Stickler's syndrome: A study of 12 families. *Br J Ophthalmol* 71:504–509.
- Stickler GB, Pugh DG. 1967. Hereditary progressive arthroophthalmopathy II. Additional observations on vertebral abnormalities: A hearing defect, and a report of a similar case. *Mayo Clin Proc* 42:495–500.
- Stickler GB, Belau PG, Farrell FJ, Jones JD, Pugh DG, Steinberg AG, Ward LE. 1965. Hereditary progressive arthroophthalmopathy. *Mayo Clin Proc* 40:433–455.
- Stickler GB, Hughes W, Houchin P. 2001. Clinical features of hereditary arthroophthalmopathy (Stickler syndrome): A survey. *Genet Med* 3:192–196.
- Szymko-Bennett YM, Mastroianni MA, Shottland LI, Davis J, Ondrey FG, Balog JZ, Rudy SF, McCullagh L, Levy HP, Liberfarb RM, Francomano CA. 2001. Auditory dysfunction in Stickler syndrome. *Arch Otolaryngol Head Neck Surg* 127:1061–1068.
- Tepper S, Hochberg MC. 1993. Factors associated with hip osteoarthritis: Data from the First National Health and Nutrition Examination Survey (NHANES-I). *Am J Epidemiol* 137:1081–1088.
- van Steensel MA, Buma P, Waal Malefijt MC, van den Hoogen FH, Brunner HG. 1997. Oto-spondylo-megaepiphyseal dysplasia (OSMED): Clinical description of three patients homozygous for a missense mutation in the *COL11A2* gene. *Am J Med Genet*^{Q9} 70:315–323.
- Vikkula M, Mariman EC, Lui VC. 1995. Autosomal dominant and recessive osteochondrodysplasias associated with the *COL11A2*locus. *Cell* 80:431–437.
- Weatherley-White RC, Sakura CY Jr, Brenner LD, Stewart JM, Ott JE. 1972. Submucous cleft palate. Its incidence, natural history, and indications for treatment. *Plast Reconstr Surg* 49:297–304.
- Wilkes SR, Beard CM, Kurland LT, Robertson DM, O'Fallon WM. 1982. The incidence of retinal detachment in Rochester, Minnesota, 1970–1978. *Am J Ophthalmol* 94:670–673.
- Wilkin DJ, Mortier GR, Johnson CL, Joues MC, De Paepe A, Shohat M, Wildin RS, Falk RE, Cohn DH. 1998. Correlation of linkage data with phenotype in eight families with Stickler syndrome. *Am J Med Genet*^{Q10} 80:121–127.
- Wilkin DJ, Liberfarb R, Davis J, Levy HP, Cole WG, Francomano CA, Cone DH. 2000. Rapid determination of *COL2A1* mutations in individuals with Stickler syndrome: Analysis of potential premature termination codons. *Am J Med Genet*^{Q11} 94:141–148.
- Williams CJ, Ganguly A, Considine E, Mc Carron S, Prokop DJ, Walsh-Vockley C, Michels VV. 1996. A 2 → G transition at the 3' acceptor splice site of IVS 17 characterizes the *COL2A1*gene mutation in the original Stickler syndrome kindred. *Am J Med Genet*^{Q12} 63:461–467.

Q1: Au: Please specify 2000a or 2000b throughout.

Q2: Au: Reference not given in references list.

Q3: Au: Please provide the footnote legend.

Q4: Au: Reference not given in reference list.

Q5: Au: Please specify Part A, B, or C.

Q6: Au: Please specify Part A, B, or C.

Q7: Au: Please specify Part A, B, or C.

Q8: Au: Please specify Part A, B, or C.


Q9: Au: Please specify Part A, B, or C.

Q10: Au: Please specify Part A, B, or C.

Q11: Au: Please specify Part A, B, or C.

Q12: Au: Please specify Part A, B, or C.

AJMA, e-proof:
C1/Wiley-Liss



WILEY

Publishers Since 1807

111 RIVER STREET, HOBOKEN, NJ 07030

*****IMMEDIATE RESPONSE REQUIRED*****

Your article will be published online via Wiley's EarlyView® service (www.interscience.wiley.com) shortly after receipt of corrections. EarlyView® is Wiley's online publication of individual articles in full text HTML and/or pdf format before release of the compiled print issue of the journal. Articles posted online in EarlyView® are peer-reviewed, copyedited, author corrected, and fully citable. EarlyView® means you benefit from the best of two worlds--fast online availability as well as traditional, issue-based archiving.

READ PROOFS CAREFULLY

- This will be your only chance to review these proofs.
- Please note that the volume and page numbers shown on the proofs are for position only.

ANSWER ALL QUERIES ON PROOFS (Queries for you to answer are attached as the last page of your proof.)

- Mark all corrections directly on the proofs. Note that excessive author alterations may ultimately result in delay of publication and extra costs may be charged to you.

CHECK FIGURES AND TABLES CAREFULLY (Color figures will be sent under separate cover.)

- Check size, numbering, and orientation of figures.
- All images in the PDF are downsampled (reduced to lower resolution and file size) to facilitate Internet delivery. These images will appear at higher resolution and sharpness in the printed article.
- Review figure legends to ensure that they are complete.
- Check all tables. Review layout, title, and footnotes.

COMPLETE REPRINT ORDER FORM

- Fill out the attached reprint order form. It is important to return the form even if you are not ordering reprints. You may, if you wish, pay for the reprints with a credit card. Reprints will be mailed only after your article appears in print. This is the most opportune time to order reprints. If you wait until after your article comes off press, the reprints will be considerably more expensive.

RETURN

- PROOFS**
 REPRINT ORDER FORM
 CTA (If you have not already signed one)

RETURN IMMEDIATELY AS YOUR ARTICLE WILL BE POSTED IN ORDER OF RECEIPT.

QUESTIONS?

Christopher Sannella, Production Editor
Phone: 201-748-5949
E-mail: csannell@wiley.com
Refer to journal acronym and article production number
(i.e., AJMA 00-0001 for *American Journal of Medical Genetics* ms 00-0001).

COPYRIGHT TRANSFER AGREEMENT

Date:

Production/Contribution

ID# _____

To:

Publisher/Editorial office use only

Re: Manuscript entitled _____
_____ (the "Contribution")
for publication in _____ (the "Journal")
published by Wiley-Liss, Inc., a subsidiary of John Wiley & Sons, Inc. ("Wiley").

Dear Contributor(s):

Thank you for submitting your Contribution for publication. In order to expedite the publishing process and enable Wiley to disseminate your work to the fullest extent, we need to have this Copyright Transfer Agreement signed and returned to us as soon as possible. If the Contribution is not accepted for publication this Agreement shall be null and void.

A. COPYRIGHT

1. The Contributor assigns to Wiley, during the full term of copyright and any extensions or renewals of that term, all copyright in and to the Contribution, including but not limited to the right to publish, republish, transmit, sell, distribute and otherwise use the Contribution and the material contained therein in electronic and print editions of the Journal and in derivative works throughout the world, in all languages and in all media of expression now known or later developed, and to license or permit others to do so.
2. Reproduction, posting, transmission or other distribution or use of the Contribution or any material contained therein, in any medium as permitted hereunder, requires a citation to the Journal and an appropriate credit to Wiley as Publisher, suitable in form and content as follows: (Title of Article, Author, Journal Title and Volume/Issue Copyright © [year] Wiley-Liss, Inc. or copyright owner as specified in the Journal.)

B. RETAINED RIGHTS

Notwithstanding the above, the Contributor or, if applicable, the Contributor's Employer, retains all proprietary rights other than copyright, such as patent rights, in any process, procedure or article of manufacture described in the Contribution, and the right to make oral presentations of material from the Contribution.

C. OTHER RIGHTS OF CONTRIBUTOR

Wiley grants back to the Contributor the following:

1. The right to share with colleagues print or electronic "preprints" of the unpublished Contribution, in form and content as accepted by Wiley for publication in the Journal. Such preprints may be posted as electronic files on the Contributor's own website for personal or professional use, or on the Contributor's internal university or corporate networks/intranet, or secure external website at the Contributor's institution, but not for commercial sale or for any systematic external distribution by a third party (e.g., a listserve or database connected to a public access server). Prior to publication, the Contributor must include the following notice on the preprint: "This is a preprint of an article accepted for publication in [Journal title] © copyright (year) (copyright owner as specified in the Journal)". After publication of the Contribution by Wiley, the preprint notice should be amended to read as follows: "This is a preprint of an article published in [include the complete citation information for the final version of the Contribution as published in the print edition of the Journal]", and should provide an electronic link to the Journal's WWW site, located at the following Wiley URL: <http://www.interscience.Wiley.com/>. The Contributor agrees not to update the preprint or replace it with the published version of the Contribution.
2. The right, without charge, to photocopy or to transmit online or to download, print out and distribute to a colleague a copy of the published Contribution in whole or in part, for the Contributor's personal or professional use, for the

advancement of scholarly or scientific research or study, or for corporate informational purposes in accordance with Paragraph D.2 below.

3. The right to republish, without charge, in print format, all or part of the material from the published Contribution in a book written or edited by the Contributor.
4. The right to use selected figures and tables, and selected text (up to 250 words, exclusive of the abstract) from the Contribution, for the Contributor's own teaching purposes, or for incorporation within another work by the Contributor that is made part of an edited work published (in print or electronic format) by a third party, or for presentation in electronic format on an internal computer network or external website of the Contributor or the Contributor's employer.
5. The right to include the Contribution in a compilation for classroom use (course packs) to be distributed to students at the Contributor's institution free of charge or to be stored in electronic format in datarooms for access by students at the Contributor's institution as part of their course work (sometimes called "electronic reserve rooms") and for in-house training programs at the Contributor's employer.

D. CONTRIBUTIONS OWNED BY EMPLOYER

1. If the Contribution was written by the Contributor in the course of the Contributor's employment (as a "work-made-for-hire" in the course of employment), the Contribution is owned by the company/employer which must sign this Agreement (in addition to the Contributor's signature), in the space provided below. In such case, the company/employer hereby assigns to Wiley, during the full term of copyright, all copyright in and to the Contribution for the full term of copyright throughout the world as specified in paragraph A above.
2. In addition to the rights specified as retained in paragraph B above and the rights granted back to the Contributor pursuant to paragraph C above, Wiley hereby grants back, without charge, to such company/employer, its subsidiaries and divisions, the right to make copies of and distribute the published Contribution internally in print format or electronically on the Company's internal network. Upon payment of the Publisher's reprint fee, the institution may distribute (but not resell) print copies of the published Contribution externally. Although copies so made shall not be available for individual re-sale, they may be included by the company/employer as part of an information package included with software or other products offered for sale or license. Posting of the published Contribution by the institution on a public access website may only be done with Wiley's written permission, and payment of any applicable fee(s).

E. GOVERNMENT CONTRACTS

In the case of a Contribution prepared under U.S. Government contract or grant, the U.S. Government may reproduce, without charge, all or portions of the Contribution and may authorize others to do so, for official U.S. Government purposes only, if the U.S. Government contract or grant so requires. (U.S. Government Employees: see note at end).

F. COPYRIGHT NOTICE

The Contributor and the company/employer agree that any and all copies of the Contribution or any part thereof distributed or posted by them in print or electronic format as permitted herein will include the notice of copyright as stipulated in the Journal and a full citation to the Journal as published by Wiley.

G. CONTRIBUTOR'S REPRESENTATIONS

The Contributor represents that the Contribution is the Contributor's original work. If the Contribution was prepared jointly, the Contributor agrees to inform the co-Contributors of the terms of this Agreement and to obtain their signature to this Agreement or their written permission to sign on their behalf. The Contribution is submitted only to this Journal and has not been published before, except for "preprints" as permitted above. (If excerpts from copyrighted works owned by third parties are included, the Contributor will obtain written permission from the copyright owners for all uses as set forth in Wiley's permissions form or in the Journal's Instructions for Contributors, and show credit to the sources in the Contribution.) The Contributor also warrants that the Contribution contains no libelous or unlawful statements, does not infringe on the rights or privacy of others, or contain material or instructions that might cause harm or injury.

CHECK ONE:

Contributor-owned work

Contributor's signature

Date

Type or print name and title

Co-contributor's signature

Date

Type or print name and title

ATTACHED ADDITIONAL SIGNATURE PAGE AS NECESSARY

Company/Institution-owned work
(made-for-hire in the
course of employment)

Company or Institution (Employer-for-Hire)

Date

Authorized signature of Employer

Date

U.S. Government work

Note to U.S. Government Employees

A Contribution prepared by a U.S. federal government employee as part of the employee's official duties, or which is an official U.S. Government publication is called a "U.S. Government work," and is in the public domain in the United States. In such case, the employee may cross out Paragraph A.1 but must sign and return this Agreement. If the Contribution was not prepared as part of the employee's duties or is not an official U.S. Government publication, it is not a U.S. Government work.

U.K. Government work (Crown Copyright)

Note to U.K. Government Employees

The rights in a Contribution prepared by an employee of a U.K. government department, agency or other Crown body as part of his/her official duties, or which is an official government publication, belong to the Crown. In such case, the Publisher will forward the relevant form to the Employee for signature.



WILEY

Publishers Since 1807

111 RIVER STREET, HOBOKEN, NJ 07030

To: Mr. Christopher Sannella

Phone: 201-748-5949

Fax: 201-748-6281

From: _____

Date: _____

Pages including
this cover page: _____

Comments:



REPRINT BILLING DEPARTMENT - 111 RIVER STREET, HOBOKEN, NJ 07030

PHONE: (201) 748-8789; FAX: (201) 748-6281

E-MAIL: reprints@wiley.com

PREPUBLICATION REPRINT ORDER FORM

Please complete this form even if you are not ordering reprints. This form **MUST** be returned with your corrected proofs and original manuscript. Your reprints will be shipped approximately 4 weeks after publication. Reprints ordered after printing will be substantially more expensive.

JOURNAL _____ VOLUME _____ ISSUE _____

TITLE OF MANUSCRIPT _____

MS. NO. _____ NO. OF PAGES _____ AUTHOR(S) _____

No. of Pages	100 Reprints	200 Reprints	300 Reprints	400 Reprints	500 Reprints
	\$	\$	\$	\$	\$
1-4	336	501	694	890	1052
5-8	469	703	987	1251	1477
9-12	594	923	1234	1565	1850
13-16	714	1156	1527	1901	2273
17-20	794	1340	1775	2212	2648
21-24	911	1529	2031	2536	3037
25-28	1004	1707	2267	2828	3388
29-32	1108	1894	2515	3135	3755
33-36	1219	2092	2773	3456	4143
37-40	1329	2290	3033	3776	4528

****REPRINTS ARE ONLY AVAILABLE IN LOTS OF 100. IF YOU WISH TO ORDER MORE THAN 500 REPRINTS, PLEASE CONTACT OUR REPRINTS DEPARTMENT AT (201) 748-8891 FOR A PRICE QUOTE.**

Please send me _____ reprints of the above article at \$ _____

Please add appropriate State and Local Tax (Tax Exempt No. _____) \$ _____
for United States orders only.

Please add 5% Postage and Handling \$ _____

TOTAL AMOUNT OF ORDER** \$ _____

***International orders must be paid in currency and drawn on a U.S. bank*

Please check one: Check enclosed Bill me Credit Card

If credit card order, charge to: American Express Visa MasterCard

Credit Card No _____ Signature _____ Exp. Date _____

BILL TO:

Name _____

Institution _____

Address _____

SHIP TO:

(Please, no P.O. Box numbers)

Name _____

Institution _____

Address _____

Purchase Order No. _____

Phone _____ Fax _____

E-mail _____

Softproofing for advanced Adobe Acrobat Users - NOTES tool

NOTE: ADOBE READER FROM THE INTERNET DOES NOT CONTAIN THE NOTES TOOL USED IN THIS PROCEDURE.

Acrobat annotation tools can be very useful for indicating changes to the PDF proof of your article. By using Acrobat annotation tools, a full digital pathway can be maintained for your page proofs.

The NOTES annotation tool can be used with either Adobe Acrobat 4.0, 5.0 or 6.0. Other annotation tools are also available in Acrobat 4.0, but this instruction sheet will concentrate on how to use the NOTES tool. Acrobat Reader, the free Internet download software from Adobe, DOES NOT contain the NOTES tool. In order to softproof using the NOTES tool you must have the full software suite Adobe Acrobat 4.0, 5.0 or 6.0 installed on your computer.

Steps for Softproofing using Adobe Acrobat NOTES tool:

1. Open the PDF page proof of your article using either Adobe Acrobat 4.0, 5.0 or 6.0. Proof your article on-screen or print a copy for markup of changes.
2. Go to File/Preferences/Annotations (in Acrobat 4.0) or Document/Add a Comment (in Acrobat 6.0) and enter your name into the "default user" or "author" field. Also, set the font size at 9 or 10 point.
3. When you have decided on the corrections to your article, select the NOTES tool from the Acrobat toolbox and click in the margin next to the text to be changed.
4. Enter your corrections into the NOTES text box window. Be sure to clearly indicate where the correction is to be placed and what text it will effect. If necessary to avoid confusion, you can use your TEXT SELECTION tool to copy the text to be corrected and paste it into the NOTES text box window. At this point, you can type the corrections directly into the NOTES text box window. **DO NOT correct the text by typing directly on the PDF page.**
5. Go through your entire article using the NOTES tool as described in Step 4.
6. When you have completed the corrections to your article, go to File/Export/Annotations (in Acrobat 4.0) or Document/Add a Comment (in Acrobat 6.0).
7. **When closing your article PDF be sure NOT to save changes to original file.**
8. To make changes to a NOTES file you have exported, simply re-open the original PDF proof file, go to File/Import/Notes and import the NOTES file you saved. Make changes and re-export NOTES file keeping the same file name.
9. When complete, attach your NOTES file to a reply e-mail message. Be sure to include your name, the date, and the title of the journal your article will be printed in.