

Review Article

Strategies of Spinal Fusion on Osteoporotic Spine

Sung Bae Park, M.D.,¹ Chun Kee Chung, M.D.²*Department of Neurosurgery,¹ Inje University College of Medicine, Seoul Paik Hospital, Seoul, Korea**Department of Neurosurgery,² Seoul National University College of Medicine, Clinical Research Institute, Seoul National University Hospital, Seoul, Korea*

The prevalence of osteoporosis has been increasing globally. Recently surgical indications for elderly patients with osteoporosis have been increasing. However, only few strategies are available for osteoporotic patients who need spinal fusion. Osteoporosis is a result of negative bone remodeling from enhanced function of the osteoclasts. Because bone formation is the result of coupling between osteoblasts and osteoclasts, anti-resorptive agents that induce osteoclast apoptosis may not be effective in spinal fusion surgery, necessitating new bone formation. Therefore, anabolic agents may be more suitable for osteoporotic patients who undergo spinal fusion surgery. The instrumentations and techniques with increased pull-out strength may increase fusion rate through rigid fixation. Studies on new osteoinductive materials, methods to increase osteogenic cells, strengthened and biocompatible osteoconductive scaffolds are necessary to enable osteoporotic patients to undergo spinal fusion. When osteoporotic patients undergo spinal fusion, surgeons should consider appropriate osteoporosis medication, instrumentation and technique.

Key Words : Osteoporosis · Spine · Fusion · Osteoblast · Osteoclast.

INTRODUCTION

Because the degenerative changes in the intervertebral discs and spinal facet joint capsules in people over 50 years of age are associated with spinal instability and there are the increased life expectancy, improved quality of life and the elderly desire to remain physically active, surgical indications for degenerative spinal conditions in elderly patients have been increased^{2,21,28,33,37}. The surgical outcome and perioperative complication of spinal fusion in elderly patients can be negatively affected by co-morbidities, such as cardiopulmonary disease, renal disease, diabetes mellitus, nutritional disorders and osteoporosis¹⁸. Because osteoporosis is strongly associated with poor fusion rate and bone stability, it is crucial to understand the pathophysiology of osteoporosis and its treatment, in order to enhance spinal fusion and preserve bone stability. Spinal surgeons must be informed of the appropriate treatment plan for osteoporosis, and formulate appropriate strategies for osteoporotic patients who need to undergo spinal fusion surgery. The objective of this article was to review the prevalence and pathophysiology of osteoporosis, and strategies to facilitate spinal fusion.

PREVALENCE OF OSTEOPOROSIS AND SPINAL FUSION IN ELDERLY PATIENTS

Osteoporosis is a major global problem, because over 10 million people are currently diagnosed with osteoporosis³⁴. Although 80% of osteoporotic patients are women, a considerable number of men are also affected^{19,25}. The age matched prevalence of osteoporosis is 17-20% of women over 50 years old, 26% over 65 years old and 50% over 85 years old in the United States. In the Republic of Korea, the prevalences of osteoporosis in the lumbar spine in women between 50 and 59, 60 and 69 and 70 and 79 years old are 32.8%, 62.2%, 88.9%, respectively^{34,42,48}. In addition, the prevalence of osteoporosis in male and female patients over 50 years old who underwent spinal surgery were 14.5% and 51.3%, respectively²¹. Due to increasing life expectancy, the number of elderly patients with osteoporosis will increase even further.

Due to an increasingly aged population, degenerative spinal stenosis and spondylolisthesis have become more frequently diagnosed^{67,72}. Up to 10% of women over 60 years may be affected by degenerative spondylolisthesis and one study presented the rates of male and female patients with spondylolisthesis (degenerative or spondylolytic types) at 14.8% and 66.1%, respectively^{21,34}. In elderly patients, iatrogenic cause of instability following spinal surgery may occur because of pre-existing degenerative changes in the facet joints and intervertebral disc. If instability of the spine at the index level is confirmed by preop-

• Received : February 2, 2011 • Revised : April 25, 2011
 • Accepted : May 30, 2011
 • Address for reprints : Chun Kee Chung, M.D.
 Department of Neurosurgery, Seoul National University Hospital,
 101 Daehak-ro, Jongno-gu, Seoul 110-744, Korea
 Tel : +82-2-2072-2352, Fax : +82-2-744-8459
 E-mail : chungc@snu.ac.kr

erative radiological evaluations or when iatrogenic instability occurs, fusion operation should be considered in elderly patients^{40,67,72}. Several reports claimed that decompression and additional fusions in elderly patients who experienced spinal stenosis and instability, such as spondylolisthesis, produced favorable outcomes, because lumbar arthrodesis with spinal instrumentation produce satisfactory outcome in elderly patients^{20,32,40,65,72}. Many studies demonstrated fusion failure which negatively impact on clinical outcomes, and fusion rates ranged from 56% to 100%^{13,56,71}. There exist reports on the outcome of lumbar arthrodesis following instrumentation in patients over 60 years of age, which indicated the prevalence of delayed and collapsed fusion in elderly patients to be higher than that in younger patients. The fusion rates of elderly patients reported were over 90%^{32,57}. In elderly osteoporotic patients who underwent lumbar arthrodesis with instrumentation, the fusion rates were 89.7%, 95.8%^{20,43}. In other words, old age and osteoporosis are not contraindication in spinal arthrodesis. The number of elderly patients who needs spinal surgery will increase and the prevalence of osteoporosis in elderly patients is high. The existence and severity of osteoporosis should be preoperatively assessed in elderly patients, and appropriate strategy to facilitate spinal fusion should be formulated.

PATHOGENESIS OF POSTMENOPAUSAL OSTEOPOROSIS

Although the skeletal system appears to be a static structure macroscopically, the bone is a collection of dynamic tissues microscopically. In other words, remodeling, including bone absorption and formation in the microcracks of bone occurs continuously^{41,50}. Bone remodeling is performed by basic multicellular unit (BMU) within the bone remodeling cavity, and the BMU is composed of osteoclasts, osteoblasts, bone lining cells and osteocytes (Fig. 1)⁶⁰. Complete regeneration of adult skeleton through remodeling takes 10 years and remodeling serves to repair damage and prevent aging and fracture⁴¹. Remodeling with positive balance occurs in the growing skeleton, and negative remodeling causes reduced bone mineral density (BMD) and osteoporosis. Among several etiologies of osteoporosis,

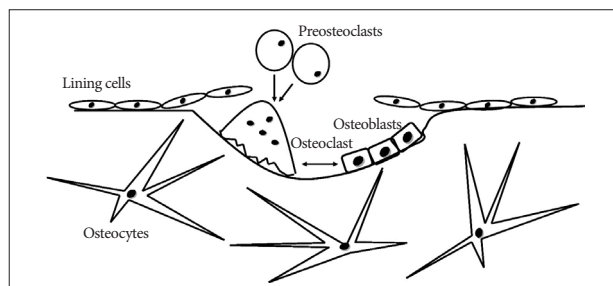


Fig. 1. This scheme shows the basic multicellular units (BMU) in resorption cavity. After the lining cells prepare the damaged bone surface, osteoclasts as fused cell preosteoclasts absorb the bone in a BMU and release several growth factors that promote osteoblasts.

menopause is the most common cause. Bone loss in both women and men begins in the 40s and rapid bone loss in women occurs during the first 5-10 years after menopause⁴⁶. In addition, women accumulate less bone mass than men during the developmental period. Therefore, the incidence of fracture is higher in women than in men⁵⁸.

After the loss of estrogen (menopause), several events occur. In terms of molecular changes, several cytokines such as IL-1, IL-6, macrophage colony stimulating factor and tumor necrosis factor increase and these cytokines stimulate osteoclast development⁵⁰. Osteoprotegerin stimulated by estrogen has very potent inhibitory effects on osteoclastogenesis through blocking receptor activation of nuclear factor- κ B (RANK) ligand/RANK interaction - the main stimulator involved in osteoclast differentiation and activation^{50,64}. In terms of cellular changes, although the formation of osteoblast and osteoclast in the bone marrow is up-regulated initially after menopause, the first event as the mesenchyme differentiates toward osteoblasts has decreased and the increased osteoclast formation persists⁵¹. In addition, estrogen deficiency leads to shorter osteoblast and osteocytes lifespan, and prolongation of osteoclast lifespan^{52,60}. The longer lifespan of osteoclasts is responsible for deeper absorption cavities^{27,60}. In addition, increase in osteocyte apoptosis may impair the osteocytes-canalicular mechanoreceptor as the skeletal signals of detection of microdamage and repair. Bone loss through negative bone remodeling may be the downstream consequence of these changes (Table 1).

BIOLOGY OF SPINAL FUSION

Although instrumentation and technique have been improving, non-union still occurs in 5 to 35% of patients who undergo spinal fusion^{9,14}. Non-union in spinal surgery frequently leads to unsatisfactory clinical outcomes^{23,30}. Therefore, understanding of the histological and biologic events in spinal fusion is crucial to spinal surgeons who treat patients with and without osteoporosis. Clinically relevant lumbar fusion animal model provide information on the methods that facilitate fusion in several articles. Non-decortication of the transverse process did not result in arthrodesis and primary vascular supply to the fu-

Table 1. The cellular and molecular changes after loss of estrogen

Cellular changes	Osteoblastogenesis ↓ (initial ↑)
	Osteoclastogenesis ↑
	Life span of osteoblasts and osteocytes ↓
Molecular changes	Life span of osteoclasts ↑
	IL-1, IL-6, M-CSF, TNF ↑
	OPG ↓
	RANK ligand/RANK interaction ↓

IL : interleukin, M-CSF : macrophage-colony stimulating factor, TNF : tumor necrosis factor increase, OPG : Osteoprotegerin, RANK : receptor activator of nuclear factor- κ B

sion mass originated from decorticated bone, not from the adjacent muscle^{10,69}. Intra-membranous bone formation occurs in the area near the transverse processes, and endochondral bone formation which involves bone formation through a cartilage intermediate occurs centrally at the interface between the upper and lower halves of the bridging bone⁷³. Cartilage formed through endochondral ossification has poor vascular supply and low oxygen saturation. However, in the mid and late stages of bone formation, extension of bone formation towards the central zone occurs and disappearance of cartilage and bone formation occurs in the central area (Fig. 2)^{10,11,69}. The transient cartilaginous area may explain why many non-unions are found to occur in the central zone of a fusion mass. Considering the previous description and three factors for bone formation as osteoconductive scaffold, osteogenic cell and osteoinductive materials, the characteristics of host bed such as vascularity and quality of bone marrow, the distance of fusion site and the quality of bone graft should be assessed by the surgeon. Although there is no publication that discusses the histological difference between osteoporosis and non-osteoporosis animal models with spinal fusion, reduced osteoblast ability, poor vascularity and lower bone marrow quality in the host bed may contribute to non-union in elderly osteoporotic patients. Therefore, surgeons must consider bone graft quality, proper osteoinductive materials (for example, bone morphogenetic proteins (BMPs) and other growth factors), increasing the ability of osteoblasts [for example, with intermittent administration of parathyroid hormone (PTH)] and preventing factors that may hinder fusion, including long-term use of non-steroidal anti-inflammatory agents and smoking, before performing spinal fusion on elderly osteoporotic patients.

STRATEGIES FOR OSTEOPOROTIC PATIENTS WITH SPINAL FUSION

Osteoporosis reduces bone quality through negative bone remodeling. Low bone quality can reduce the pull-out strength of pedicle screw, and negative bone remodeling can cause delayed bone fusion^{3,22}. Therefore, before performing spinal fusion surgery on osteoporotic patients, we should pursue effective strate-

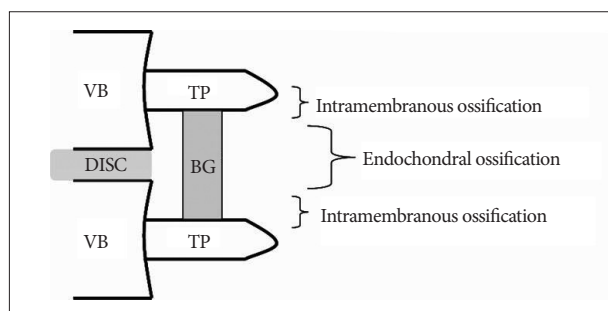


Fig. 2. The scheme shows the different ossifications in center posterolateral fusion. VB : vertebral body, TP : transverse process, BG : bone graft.

gies to increase the pull-out strength and facilitate positive bone remodeling.

Pharmacotherapeutic strategies

Osteoporosis secondary to loss of estrogen is the cause of negative bone remodeling through reduced function and life span of osteoblasts, and the reverse for osteoclasts. In addition, bone remodeling depends on communication between the osteoblast lineage, including lining cell, preosteoblasts, osteocytes and the osteoclast lineage⁶⁶. Thus, in order to obtain good fusion rate in osteoporotic patients, we should be aware of the antiresorptive and anabolic agents.

Bisphosphonates

Bisphosphonates are typical anti-resorptive agents that include alendronate, ibandronate, etidronate and pamidronate. The mechanism of bisphosphonate is to promote apoptosis of mature osteoclasts and result in slow rate of bone remodeling^{38,50,60}. Many animal studies presented the effects of bisphosphonates on the skeletal system. In animal studies that investigated fracture healing and pull-out strength of implants, bisphosphonates did not adversely affect the skeletal system^{55,61}. However, according to recent studies, bisphosphonates inhibit or delay spinal fusion through reduced incorporation between grafted bone and host bone^{37,45,68}. In other words, the anti-fracture effect of bisphosphonates is not proportional to their efficacy on bone fusion. Therefore, when osteoporotic patients are scheduled to undergo spinal fusion, surgeons must consider the need of using other antiresorptive or anabolic agents postoperatively.

Other classes of anti-absorptive agents

There are many studies on new treatment targets of osteoclasts, except bisphosphonate that acts chiefly by inducing the osteoclast apoptosis. The targets of new resorption inhibitors are RANKL, cathepsin K, vacuolar type H⁺ATPase (V-ATPases) and integrin $\alpha\beta 3$ ⁶⁴. RANKL is a main stimulator of osteoclast differentiation. The anti-RANKL antibody, denosumab (AMG 162) was evaluated in Phase I, II and III trials and the effect of denosumab on BMD was superior to that of alendronate^{6,15,53}. Cathepsin K is a cysteine protease expressed by osteoclasts and degrades bone matrix protein. A human cathepsin K inhibitor, odanacatib (MK-0822) is well-tolerated and increases lumbar spine and total-hip BMD of postmenopausal women in Phase I and II studies^{12,31}. V-ATPases acts as a proton pump in the resorptive cavity under osteoclasts and integrin $\alpha\beta 3$ is the main integrin on osteoclasts. Research on V-ATPases inhibitor and $\alpha\beta 3$ antagonist is ongoing^{54,64}.

PTH

Only one drug acts as anabolic agent to osteoporosis - recombinant human PTH, teriparatide. Although high levels of PTH cause decreased BMD through increased bone resorption, low and intermittent PTH elevation increases bone formation sec-

ondary to its anti-apoptotic effect on osteoblasts^{35,38,39,64}. Prior studies concluded that PTH treatment did not increase the incidence of bone tumor, such as osteosarcoma^{36,59,70}. It must be emphasized that the experience of PTH use is so far limited in the United States and Europe to 2 years and 18 months, respectively. If PTH treatment is not followed by antiresorptive therapy, the increased BMD would be lost^{7,26}. Therefore, it needs to develop additional anabolic agents that can be continuously used in osteoporotic patients. The results of animal studies suggested that PTH enhanced the healing of bone fracture, BMD, mechanical strength and arthrodesis of the spine^{1,4}. As concurrent use of alendronate for increasing positive remodeling reduced the anabolic effect of PTH, the use of PTH on osteoporotic patients taking bisphosphonates may be refrained after spine arthrodesis⁸).

Other anabolic agents

Other targets for anabolic agents are Wnt signaling pathway and activin. The Wnt signaling pathway has a critical role on bone formation, and sclerostin and Dickkopf (DKK)-1 are the inhibitors of the Wnt signaling pathway^{26,64}. The efficacy of sclerostin and DKK-1 antagonists have been examined in several animal studies and these results are related to clinical studies for osteoporosis patients^{47,64}. Activin is a member of the TGF- β superfamily and activin receptor is one of the BMP receptors⁶⁴. Activation of BMP receptors causes differentiation of osteoblasts and increased bone formation²⁶. Although there is no clinical report on the outcome of BMP therapy in osteoporotic patients who have undergone lumbar spinal fusion, BMPs increased fusion rate for non-osteoporotic patients with spine arthrodesis according to recent articles. In an animal study using osteoporotic rats, higher dose of BMP-7 increased spinal fusion rate^{16,49,63}. Therefore, agents that exert effects on the BMP pathway, such as BMPs and activin, are promising anabolic agents for osteoporotic patients with or without spine fusion.

Implant based strategies

Cancellous bone is more affected by osteoporosis than cortical bone, therefore lower BMD has been a major factor in poor screw fixation, screw loosening and fixation failure²². Many techniques have been employed to enhance the pullout strength of the pedicle screw²⁹. The preparation for screw hole or minimization of tapping hole can affect the pullout strength in osteoporotic bone and, although the anatomical constraints vary with patients, bigger and longer screws may provide good solution for fragile bones²⁴. The angulation of two screws and screw positioning in areas of higher BMD in the vertebrae may increase pullout strength^{62,69}. Also, to improve the fixation and fatigue strength of instrumentation, screw augmentation with polymethyl methacrylate has yielded favorable outcomes^{5,17,43}. These techniques may enhance bone fusion through stabilization of fusion segments.

Other strategies

Mesenchymal cells differentiate to osteoblasts are critical for increasing fusion rate. Although the fusion rate achieved by using bone marrow aspiration (BMA) with collagen was inferior to that in autologous iliac crest bone for posterior lumbar interbody fusion, the fusion rate of posterolateral lumbar fusion was comparable to that of autologous bone⁴⁴. However, as there is low concentration of osteogenic cell in the BMA, it is ineffective as a bone graft substitute. Therefore, investigations for methods of stimulating osteoblast differentiation, expanding the number of osteoblast and new osteoconductive scaffold with structural strength are needed.

CONCLUSION

Osteoporosis results in fragile bone through negative bone remodeling. As such, prior to performing spinal fusion on osteoporosis patients, surgeons should consider multidisciplinary strategies, including the use of the antiresorptive and anabolic agents, proper instrumentations and BMA. Perioperative strategies in osteoporotic patients may affect the radiological and clinical outcomes.

References

1. Abe Y, Takahata M, Ito M, Irie K, Abumi K, Minami A : Enhancement of graft bone healing by intermittent administration of human parathyroid hormone (1-34) in a rat spinal arthrodesis model. *Bone* 41 : 775-785, 2007
2. Aebi M : The scoliosis. *Eur Spine J* 14 : 925-948, 2005
3. Aldini NN, Fini M, Giavaresi G, Giardino R, Greggi T, Parisini P : Pedicular fixation in the osteoporotic spine : a pilot in vivo study on long-term ovariectomized sheep. *J Orthop Res* 20 : 1217-1224, 2002
4. Alkhiary YM, Gerstenfeld LC, Krall E, Westmore M, Sato M, Mitlak BH, et al. : Enhancement of experimental fracture-healing by systemic administration of recombinant human parathyroid hormone (PTH 1-34). *J Bone Joint Surg Am* 87 : 731-734, 2005
5. Aydogan M, Ozturk C, Karatoprak O, Tezer M, Aksu N, Hamzaoglu A : The pedicle screw fixation with vertebroplasty augmentation in the surgical treatment of the severe osteoporotic spines. *J Spinal Disord Tech* 22 : 444-447, 2009
6. Bekker PJ, Holloway DL, Rasmussen AS, Murphy R, Martin SW, Leese PT, et al. : A single-dose placebo-controlled study of AMG 162, a fully human monoclonal antibody to RANKL, in postmenopausal women. *J Bone Miner Res* 20 : 2275-2282, 2005
7. Black DM, Bilezikian JP, Ensrud KE, Greenspan SL, Palermo L, Hue T, et al. : PaTH Study Investigators. One year of alendronate after one year of parathyroid hormone (1-84) for osteoporosis. *N Engl J Med* 353 : 555-565, 2005
8. Black DM, Greenspan SL, Ensrud KE, Palermo L, McGowan JA, Lang TE, et al. : PaTH Study Investigators. The effects of parathyroid hormone and alendronate alone or in combination in postmenopausal osteoporosis. *N Engl J Med* 349 : 1207-1215, 2003
9. Boden SD : Overview of the biology of lumbar spine fusion and principles for selecting a bone graft substitute. *Spine (Phila Pa 1976)* 15 : S26-S31, 2002
10. Boden SD : The biology of posterolateral lumbar spinal fusion. *Orthop Clin North Am* 29 : 603-619, 1998
11. Boden SD, Schimandle JH, Hutton WC, Chen MI : The use of an osteo-

- inductive growth factor for lumbar spinal fusion. Part I : Biology of spine fusion. *Spine (Phila Pa 1976)* **20** : 2626-2632, 1995
12. Bone HG, McClung MR, Roux C, Recker RR, Eisman JA, Verbruggen N, et al. : Odanacatib, a cathepsin-K inhibitor for osteoporosis : a two-year study in postmenopausal women with low bone density. *J Bone Miner Res* **25** : 937-947, 2010
 13. Brantigan JW, Steffee AD : A carbon fiber implant to aid interbody lumbar fusion. Two-year clinical results in the first 26 patients. *Spine (Phila Pa 1976)* **18** : 2106-2107, 1991
 14. Bridwell KH, Sedgewick TA, O'Brien MF, Lenke LG, Baldus C : The role of fusion and instrumentation in the treatment of degenerative spondylolisthesis with spinal stenosis. *J Spinal Disord* **6** : 461-472, 1993
 15. Brown JP, Prince RL, Deal C, Recker RR, Kiel DP, de Gregorio LH, et al. : Comparison of the effect of denosumab and alendronate on bone mineral density and biochemical markers of bone turnover in postmenopausal women with low bone mass : a randomized, blinded, phase 3 trial. *J Bone Miner Res* **14** : 1-34, 2009
 16. Burkus JK, Gornet MF, Schuler TC, Kleeman TJ, Zdeblick TA : Six-year outcomes of anterior lumbar interbody arthrodesis with use of interbody fusion cages and recombinant human bone morphogenetic protein-2. *J Bone Joint Surg Am* **91** : 1181-1189, 2009
 17. Burval DJ, McLain RF, Milks R, Inceoglu S : Primary pedicle screw augmentation in osteoporotic lumbar vertebrae : biomechanical analysis of pedicle fixation strength. *Spine (Phila Pa 1976)* **32** : 1077-1083, 2007
 18. Carreon LY, Puno RM, Dimar JR 2nd, Glassman SD, Johnson JR : Perioperative complications of posterior lumbar decompression and arthrodesis in older adults. *J Bone Joint Surg Am* **85** : 2089-2092, 2003
 19. Cauley JA, Fullman RL, Stone KL, Zmuda JM, Bauer DC, Barrett-Connor E, et al. : Factors associated with the lumbar spine and proximal femur bone mineral density in older men. *Osteoporos Int* **16** : 1525-1537, 2005
 20. Cavagna R, Tournier C, Aunoble S, Bouler JM, Antonietti P, Ronai M, et al. : Lumbar decompression and fusion in elderly osteoporotic patients : a prospective study using less rigid titanium rod fixation. *J Spinal Disord Tech* **21** : 86-91, 2008
 21. Chin DK, Park JY, Yoon YS, Kuh SU, Jin BH, Kim KS, et al. : Prevalence of osteoporosis in patients requiring spine surgery : incidence and significance of osteoporosis in spine disease. *Osteoporos Int* **18** : 1219-1224, 2007
 22. Coe JD, Warden KE, Herzig MA, McAfee PC : Influence of bone mineral density on the fixation of thoracolumbar implants. A comparative study of transpedicular screws, laminar hooks, and spinous process wires. *Spine (Phila Pa 1976)* **15** : 902-907, 1990
 23. Conaty JP, Mongan ES : Cervical fusion in rheumatoid arthritis. *J Bone Joint Surg Am* **63** : 1218-1227, 1981
 24. Cook SD, Barbera J, Rubi M, Salkeld SL, Whitecloud TS 3rd : Lumbosacral fixation using expandable pedicle screws : an alternative in reoperation and osteoporosis. *Spine J* **11** : 109-114, 2001
 25. Cummings SR, Melton LJ : Epidemiology and outcomes of osteoporotic fractures. *Lancet* **359** : 1761-1767, 2002
 26. Deal C : Future therapeutic targets in osteoporosis. *Curr Opin Rheumatol* **21** : 380-385, 2009
 27. Eriksen EF, Landgdahl B, Vesterby A, Rungby J, Kassem M : Hormone replacement therapy prevents osteoclastic hyperactivity : a histomorphometric study in early postmenopausal women. *J Bone Miner Res* **14** : 1217-1221, 1999
 28. Fraizer DD, Lipson SJ, Fossel AH, Katz JN : Associations between spinal deformity and outcomes after decompression for spinal stenosis. *Spine (Phila Pa 1976)* **22** : 2025-2029, 1997
 29. Ferguson SJ, Winkler F, Nolte LP : Anterior fixation in the osteoporotic spine : cut-out and pullout characteristics of implant. *Eur Spine J* **11** : 527-534, 2002
 30. Farey ID, McAfee PC, Gurr KR, Randolph MA : Quantitative histologic study of the influence of spinal instrumentation on lumbar fusions : a canine model. *J Orthop Res* **7** : 709-722, 1989
 31. Gauthier JY, Chauret N, Cromlish W, Desmarais S, Duong le T, Falgueyret JP, et al. : The discovery of odanacatib (MK-0822), a selective inhibitor of cathepsin K. *Bioorg Med Chem Lett* **18** : 923-928, 2008
 32. Glassman SD, Polly DW, Bono CM, Burkus K, Dimar JR : Outcome of lumbar arthrodesis in patients sixty-five years of age or older. *J Bone Joint Surg Am* **91** : 783-790, 2009
 33. Greenfield RT 3rd, Capen DA, Thomas JC Jr, Nelson R, Nagelberg S, Rimoldi RL, et al. : Pedicle screw fixation for arthrodesis of the lumbosacral spine in the elderly : an outcome study. *Spine (Phila Pa 1976)* **23** : 1470-1475, 1998
 34. Hart RA, Prendergast MA : Spine surgery for lumbar degenerative disease in elderly and osteoporotic patients. *Instr Course Lect* **56** : 257-272, 2007
 35. Hodsman AB, Bauer DC, Dempster DW, Dian L, Hanley DA, Harris ST, et al. : Parathyroid hormone and teriparatide for the treatment of osteoporosis : a review of the evidence and suggested guidelines for its use. *Endocr Rev* **26** : 688-703, 2005
 36. Horwitz M, Stewart A, Greenspan SL : Sequential parathyroid hormone/alendronate therapy for osteoporosis-robbing Peter to pay Paul? *J Clin Endocrinol Metab* **85** : 2127-2128, 2000
 37. Huang RC, Khan SN, Sandhu HS, Metz JA, Cammisa FP Jr, Zheng F, et al. : Alendronate inhibits spine fusion in a rat model. *Spine (Phila Pa 1976)* **30** : 2516-2522, 2005
 38. Hughes DE, Wright KR, Uy HL, Sasaki A, Yoneda T, Roodman GD, et al. : Bisphosphonates promote apoptosis in murine osteoclasts in vitro and in vivo. *J Bone Miner Res* **10** : 1478-1487, 1995
 39. Jilka RL, Weinstein RS, Bellido T, Roberson P, Parfitt AM, Manolagas SC : Increased bone formation by prevention of osteoblast apoptosis with PTH. *J Clin Invest* **104** : 439-446, 1999
 40. Johnsson KE, Willner S, Johnsson K : Postoperative instability after decompression for lumbar spinal stenosis. *Spine (Phila Pa 1976)* **11** : 107-110, 1986
 41. Khosla S, Westendorf JJ, Oursler MJ : Building bone to reverse osteoporosis and repair fracture. *J Clin Invest* **118** : 421-428, 2008
 42. Kim CH, Kim YI, Choi CS, Park JY, Lee MS, Lee SI, et al. : Prevalence and risk factors of low quantitative ultrasound values of calcaneus in Korean elderly women. *Ultrasound Med Biol* **26** : 35-40, 2000
 43. Kim KH, Lee SH, Lee DY, Shim CS, Maeng DH : Anterior bone cement augmentation in anterior lumbar interbody fusion and percutaneous pedicle screw fixation in patients with osteoporosis. *J Neurosurg Spine* **12** : 525-532, 2010
 44. Kitchel SH : A preliminary comparative study of radiographic results using mineralized collagen and bone marrow aspirate versus autologous bone in the same patients undergoing posterior lumbar interbody fusion with instrumented posterolateral lumbar fusion. *Spine J* **6** : 405-411, 2006
 45. Lehman RA Jr, Kuklo TR, Freedman BA, Cowart JR, Mense MG, Riew KD : The effect of alendronate sodium on spinal fusion : a rabbit model. *Spine J* **4** : 36-43, 2004
 46. Lindsay R : Sex steroids in the pathogenesis and prevention of osteoporosis in Riggs BL (ed) : *Osteoporosis : Etiology, Diagnosis and Management*. New York : Raven Press, 1988, pp333-358
 47. Li X, Ominsky MS, Warmington KS, Morony S, Gong J, Cao J, et al. : Sclerostin antibody treatment increases bone formation, bone mass, and bone strength in a rat model of postmenopausal osteoporosis. *J Bone Miner Res* **24** : 578-588, 2009
 48. Looker AC, Johnston CC Jr, Wahner HW, Dunn WL, Calvo MS, Harris TB, et al. : Prevalence of low femoral bone density in older U.S. women from NHANES III. *J Bone Miner Res* **10** : 796-802, 1995

49. Lu J, Bhargav D, Wei AQ, Diwan A : Posterolateral intertransverse spinal fusion possible in osteoporotic rats with BMP-7 in a higher dose delivered on a composite carrier. *Spine (Phila Pa 1976)* 33 : 242-249, 2008
50. Manolagas SC : Birth and death of bone cells : basic regulatory mechanisms and implications for the pathogenesis and treatment of osteoporosis. *Endocr Rev* 21 : 115-137, 2000
51. Manolagas SC, Jilka RL : Bone marrow, cytokines, and bone remodeling-emerging insights into the pathophysiology of osteoporosis. *N Engl J Med* 332 : 305-311, 1995
52. Manolagas SC, Weinstein RS, Bellido T, Bodenner DL : Opposite effects of estrogen on the life span of osteoblasts / osteocytes vs. osteoclasts in vivo and in vitro : an explanation of the imbalance between formation and resorption in estrogen deficiency. *J Bone Miner Res* 14 : S169, 1999
53. Miller PD, Bolognese MA, Lewiecki EM, McClung MR, Ding B, Austin M, et al. : Effect of denosumab on bone density and turnover in postmenopausal women with low bone mass after long-term continued, discontinued, and restarting of therapy : a randomized blinded phase 2 clinical trial. *Bone* 43 : 222-229, 2008
54. Murphy MG, Cerchio K, Stoch SA, Gottesdiener K, Wu M, Recker R : Effect of L-000845704, an alphaVbeta3 integrin antagonist, on markers of bone turnover and bone mineral density in postmenopausal osteoporotic women. *J Clin Endocrinol Metab* 90 : 2022-2028, 2005
55. Nakamura Y, Hayashi K, Abu-Ali S, Naito M, Fotovati A : Effect of preoperative combined treatment with alendronate and calcitriol on fixation of hydroxyapatite-coated implants in ovariectomized rat. *J Bone Joint Surg Am* 90 : 824-832, 2008
56. Okuda S, Miyauchi A, Oda T, Haku T, Yamamoto T, Iwasaki M : Surgical complications of posterior lumbar interbody fusion with total laminectomy in 251 patients. *J Neurosurg Spine* 4 : 304-309, 2006
57. Okuda S, Oda T, Miyauchi A, Haku T, Yamamoto T, Iwasaki M : Surgical outcomes of posterior lumbar interbody fusion in elderly patients. *J Bone Joint Surg Am* 88 : 2714-2720, 2006
58. Orwoll ES, Klein RF : Osteoporosis in men. *Endocr Rev* 16 : 87-116, 1995
59. Palmer M, Adami HO, Krusem UB, Ljunghall S : Increased risk of malignant disease after surgery for primary hyperparathyroidism : a nation-wide cohort study. *Am J Epidemiol* 127 : 1031-1040, 1988
60. Parfitt AM, Mundy GR, Roodman GD, Hughes DE, Boyce BF : A new model for the regulation of bone resorption, with particular reference to the effects of bisphosphonates. *J Bone Miner Res* 11 : 150-159, 1996
61. Peter CP, Cook WO, Nunamaker DM, Provost MT, Seedor JG, Rodan GA : Effect of alendronate on fracture healing and bone remodeling in dogs. *J Orthop Res* 14 : 74-79, 1996
62. Reinhold M, Schwieger K, Goldhahn J, Linke B, Knop C, Blauth M : Influence of screw positioning in a new anterior spine fixator on implant loosening in osteoporotic vertebrae. *Spine (Phila Pa 1976)* 31 : 406-413, 2006
63. Rihn JA, Makda J, Hong J, Patel R, Hilibrand AS, Anderson DG, et al. : The use of RhBMP-2 in single-level transforaminal lumbar interbody fusion : a clinical and radiographic analysis. *Eur Spine J* 18 : 1629-1636, 2009
64. Roux B : New treatment targets in osteoporosis. *Joint Bone Spine* 77 : 222-228, 2010
65. Sienkiewicz PJ, Flatley TJ : Postoperative spondylolisthesis. *Clin Orthop Relat Res* 221 : 172-180, 1987
66. Sims NA, Gooi JH : Bone remodeling : multiple cellular interactions required for coupling of bone formation and resorption. *Semin Cell Dev Biol* 19 : 444-451, 2008
67. Szpalski M, Gunzburg R : Lumbar spinal stenosis in the elderly : an overview. *Eur Spine J* 12 : S170-S175, 2003
68. Takahata M, Ito M, Abe Y, Abumi K, Minami A : The effect of anti-resorptive therapies on bone graft healing in an ovariectomized rat spinal arthrodesis model. *Bone* 43 : 1057-1066, 2008
69. Toribatake Y, Hutton WC, Tomita K, Boden SD : Vascularization of the fusion mass in a posterolateral intertransverse process fusion. *Spine (Phila Pa 1976)* 23 : 1149-1154, 1998
70. Wermers RA, Khosla S, Atkinson EJ, Grant CS, Hodgson SF, O'Fallon WM, et al. : Survival after the diagnosis of hyperparathyroidism : a population-based study. *Am J Med* 104 : 115-122, 1998
71. Yamamoto T, Ohkohchi T, Ohwada T, Kotoku H, Harada N : Clinical and radiological results of PLIF for degenerative spondylolisthesis. *J Musculoskelet Res* 2 : 181-195, 1998
72. Yone K, Sakou T, Kawauchi Y, Yamaguchi M, Yanase M : Indication of fusion for lumbar spinal stenosis in elderly patients and its significance. *Spine (Phila Pa 1976)* 15 : 242-248, 1996
73. Zipfel GJ, Guiot BH, Fessler RG : Bone grafting. *Neurosurg Focus* 14 : e8, 2003