

Case Report

***Streptomyces* bacteremia in a patient with actinomycotic mycetoma**

Noyal Mariya Joseph¹, Belgode Narasimha Harish¹, Sujatha Sistla¹, Devinder Mohan Thappa², Subhash Chandra Parija¹

Departments of ¹Microbiology and ²Dermatology and Sexually Transmitted Diseases, Jawaharlal Institute of Postgraduate Medical Education and Research (JIPMER), Pondicherry, India

Abstract

A 29-year-old woman presented with multiple painful swelling with discharging sinuses over the scalp. Histopathological examination of the biopsy tissue was suggestive of actinomycotic mycetoma. *Streptomyces* spp. was isolated from blood culture. The patient was successfully treated with trimethoprim-sulfamethoxazole and crystalline penicillin. This case is reported because of the rare occurrence of bacteremia by *Streptomyces* spp. secondary to subcutaneous actinomycotic mycetoma. Moreover, an interesting association between successive two pregnancies and occurrence of mycetoma of the scalp was observed in this case.

Key words: *Streptomyces*, bacteremia, actinomycetoma, mycetoma of scalp

J Infect Dev Ctries 2011; 4(4):249-252.

(Received 3 November 2009 – Accepted 17 January 2010)

Copyright © 2010 Joseph *et al.* This is an open-access article distributed under the Creative Commons Attribution License, which permits unrestricted use, distribution, and reproduction in any medium, provided the original work is properly cited.

Introduction

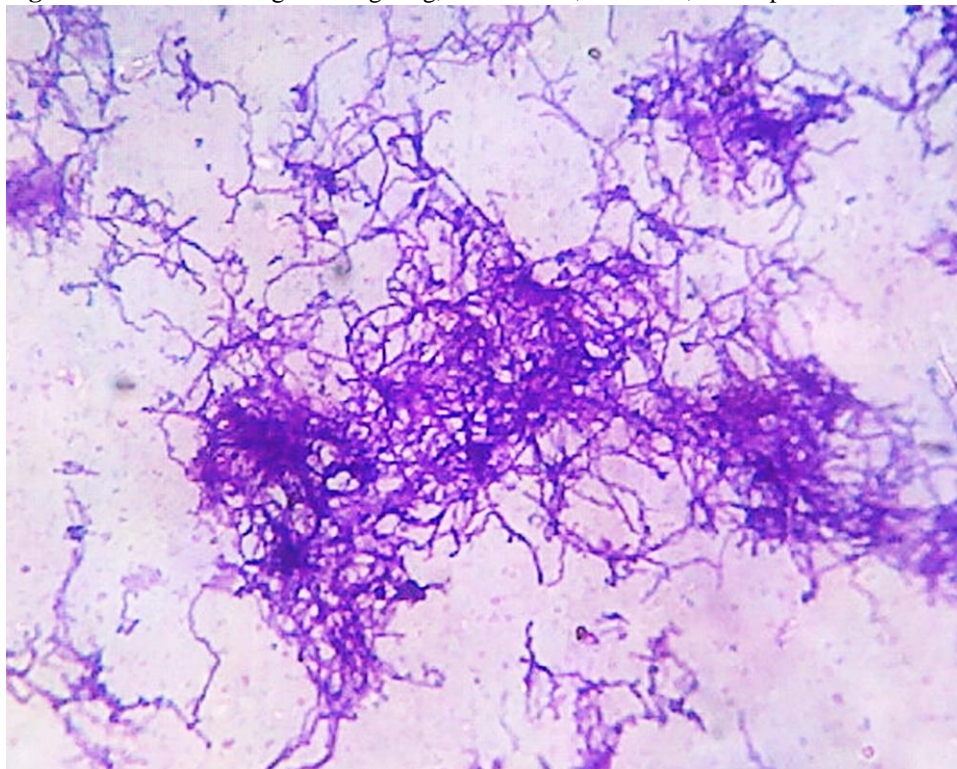
The aerobic actinomycetes (order Actinomycetales) are a large, diverse group of obligately aerobic and relatively slow-growing Gram-positive bacilli with a tendency to form chains or filaments [1]. They are closely related to members of the genera *Corynebacterium* and *Mycobacterium*. They are found as saprophytes in soil and other natural habitats. Members of the aerobic actinomycetes can be categorized based on their acid fastness. *Nocardia* and *Rhodococcus* are weakly acid fast, while *Streptomyces* and *Actinomadura* are non-acid fast [1].

The aerobic actinomycetes cause a localized, slowly progressive, chronic infection that begins in subcutaneous tissue and spreads to adjacent tissues known as actinomycotic mycetoma. The causative agent is implanted into the subcutaneous tissue by minor trauma. The actinomycotic lesions occur commonly in the lower extremities, while the hand, face and neck can also be involved [1]. *Streptomyces* is a common cause of mycetoma, particularly mycetomas affecting the head and neck [1,2]. *Streptomyces* spp. are only rarely associated with invasive systemic infections [3]. We report a case of actinomycotic mycetoma of the scalp caused by *Streptomyces* spp. which has invaded locally and spread to the bloodstream.

Case report

A 29-year-old woman presented with multiple painful swellings with discharging sinuses over the scalp for the past one year. She was apparently normal one year back when she developed a single, soft, swelling over the forehead, which was associated with pain and itching. There was no apparent history of trauma. The swelling softened and discharged pus with yellow to pale brown granules. The number of swellings gradually increased with time involving the entire scalp. The patient also had difficulty opening her mouth for the past six months. She also gave history of blackouts whenever she stood up from a lying down position. There was no history of tinnitus, vertigo or nasal obstruction. She gave history of pain and redness of the eyes. She was pregnant with a gestational age of seven months at the onset of these lesions and had also given birth to a child nine months back. She had taken local treatment for three months and had partial response.

There was past history of similar lesions in the scalp seven years back during her first pregnancy and the biopsy taken from those lesions was suggestive of actinomycotic mycetoma. She was successfully treated with trimethoprim-sulfamethoxazole and underwent medical termination of the pregnancy to avoid any teratogenic effects in the foetus.

Figure 1. Gram's staining showing long, filamentous, branched, Gram-positive bacilli.

On examination, she was febrile, but her general condition was stable. Her blood pressure was 100/70 mmHg and pulse rate was 84/minute. There were multiple soft erythematous nodules, varying in size from 1 to 3 cm in size, over the scalp and face. The surface of the swellings showed partially healed sinuses with minimal discharge. There was enlargement of the bilateral frontal and parietal bones. Both the eyes were puckered with sinuses at the superolateral region. Mouth opening was grossly restricted.

The hemoglobin level was 9.4 g/ dl, the total leucocyte count was 6700/ mm³, and the platelet count was 508,000/ mm³. The CT scan revealed soft tissue accentuating lesions involving the scalp. There was asymmetrical thickening of the left nasopharynx with obliteration of the Eustachian tube. There was bilateral frontal sinus opacity and osteosclerotic thickening of the inner and outer layer of calvarium. Soft tissue accentuating lesions of the mastoid were seen. The orbits, maxillary sinus, ethymoids and nasal cavity were normal.

As the lesions were partially healed and there were no discharging sinuses, pus or granules were not obtained. Blood collected with sterile aseptic precautions was inoculated into brain heart infusion

biphasic medium. The blood culture medium revealed turbidity and showed dry, pitted colonies on the slope after three days of incubation at 37°C. Gram's staining showed long, filamentous, extensively branched, Gram-positive bacilli with irregular staining (Figure1). The Gram-positive branching bacillus did not break up into bacillary forms, was catalase positive, and modified acid-fast staining negative. The isolate was subcultured on blood agar, Lowenstein Jensen (LJ) medium and Sabouraud's dextrose agar (SDA). The isolate grew on blood agar revealing folded, glabrous colonies, with earthy odour and aerial mycelia. It grew on LJ medium, but not on SDA. It did not reduce nitrate or hydrolyse urea. Acid was formed oxidatively only from glucose and maltose, but not from trehalose and other sugars. The organism was identified as a *Streptomyces* spp. based on the morphological appearance, growth properties and other reactions. The isolate was susceptible to penicillin, trimethoprim-sulfamethoxazole, ceftriaxone, and amikacin but was resistant to tetracycline and erythromycin.

Histopathological examination of the biopsy tissue obtained from the subcutaneous lesions revealed chronic nonspecific granulomatous

inflammation, with a central focus of acute inflammatory reaction surrounding the grains, suggestive of actinomycotic mycetoma.

The discharge from the lesions, where biopsy was taken, was plated on blood agar, chocolate agar, MacConkey's medium and Sabouraud's dextrose agar, but these cultures grew only *Staphylococcus aureus*. The patient was negative for HIV by HIV ELISA and she was not on immunosuppressive agents.

The patient was treated with trimethoprim-sulfamethoxazole and crystalline penicillin (4 million units, four times daily). Paracetamol and antihistaminics were also given to alleviate the symptoms. After two weeks, the patient was discharged as she became afebrile, repeat blood cultures were negative, and her swellings started regressing. She was advised to complete a six-month course of trimethoprim-sulfamethoxazole and come for follow-up.

Discussion

Actinomycotic mycetoma is commonly caused by *Actinomyces* spp., *Streptomyces* spp., and *Nocardia* spp. Mycetoma commonly occurs in the lower extremities, while the head and neck may be rarely involved. Lesions on the head and neck are usually caused by *Streptomyces somaliensis* [1,2].

Mycetoma caused by *S. somaliensis*, which is common in India, East Africa, including Somalia, Sudan, and Kenya, as well as in Yemen, is known as Bouffardi's white mycetoma. This condition is characterised by destruction of muscles, tendons, and bones with numerous draining sinuses discharging yellowish grains [1,4]. In a study from Senegal, bone lesions were observed in 68 of the 130 cases of mycetoma [5]. Our patient also showed bone involvement with osteosclerotic thickening of the layers of calvarium. Mycetoma of the cranium is most often associated with osteosclerotic rather than osteolytic changes in CT scan [2].

Invasive *Streptomyces* infections are relatively rare [3]. Our report is one such rare occurrence, wherein *Streptomyces* spp. causing mycetoma of the scalp invaded locally and then spread to the bloodstream. Other reported cases of invasive *Streptomyces* infections include endocarditis of the prosthetic valve, catheter-related bacteremia in a patient receiving holistic infusions, bacteremia with thrombosis, pneumonia, pericarditis, peritonitis, arthritis, cervical lymphadenitis, brain abscess, and intraspinal mycetoma [6,7]. There is also a report of

Streptomyces bikiniensis causing bacteremia without overt clinical symptoms in a young girl with osteosarcoma [8]. In all the reported cases of bacteremia due to *Streptomyces*, the source was a catheter, prosthetic valve, intravenous infusion or a primary lesion in internal organs such as the lung. But to the best of our knowledge there is no report of bacteremia secondary to subcutaneous actinomycetoma of the scalp or other parts of the body, emphasising the uniqueness of our case. However, due to certain practical difficulties, we could not show the histopathological image of the mycetoma, which would have been useful in illustrating the identical nature of the organisms observed in the tissue and blood. Our failure to demonstrate the similarity of the organisms observed at both these sites is a limitation of our report.

Invasive *Streptomyces* infections most often occur in immunocompromised patients with human immunodeficiency virus infection, malignancy, and those treated with immunosuppressive agents such as corticosteroids and cancer chemotherapy [6,9]. Our patient did not have any of these underlying immunosuppressive conditions; however, an interesting association between pregnancy and occurrence of mycetoma of the scalp was noted in her. Pregnancy is a known physiological immunosuppressive state and probably that could have predisposed for the recurrence of actinomycetoma with bacteremia in our patient.

There are no standard guidelines for optimal therapy of invasive *Streptomyces* infection [7]. Amikacin, linezolid, amoxicillin-clavulanate, clarithromycin, minocycline, imipenem, penicillin, cephalosporins, ciprofloxacin, and sulfonamides can be used for treatment of the condition [7,9]; however, the selection of antibiotic for the treatment of individual cases should be based on the *in vitro* antibiotic susceptibility of the isolate. Our patient responded well to treatment with trimethoprim-sulfamethoxazole and crystalline penicillin, but most often the *Streptomyces* isolates are not susceptible to sulfa drugs which are traditionally used for treatment of *Nocardia* infection [9]. Even though our patient had responded well to the initial treatment, she is more prone to subsequent relapses such as the recent occurrence. Successful treatment of *Streptomyces* infection requires a minimum of one year's treatment with trimethoprim-sulfamethoxazole [10]. Because of such a long treatment period, the patients are more prone to discontinuing the treatment [10]. Relapses are known to occur in actinomycotic mycetoma,

especially in non-compliant individuals [11]. Though relapses or treatment failures have been well documented with Nocardiosis, there is paucity of data on the relapse of *Streptomyces* infections [1]; however, there is a report of probable asymptomatic relapse of *Streptomyces* infection in a young man with Burkitt lymphoma [3]. The failure to isolate *Streptomyces* from the discharge collected after a week from the subcutaneous lesions could be explained by the fact that the patient had received appropriate antibiotic therapy before collection of the specimen. To conclude, this is an unusual case report of bacteremia by *Streptomyces* spp. secondary to subcutaneous actinomycotic mycetoma. Furthermore, an interesting association between pregnancy and recurrence of mycetoma of the scalp was noted.

References

1. McNeil MM, Brown JM (1994) The medically important aerobic actinomycetes: epidemiology and microbiology. *Clin Microbiol Rev* 7: 357-417.
2. Arbab MA, Idris MN, Sokrab TE, Saeed ES, Ali GM, Tariq MY, Ahmed AE (1998) Clinical presentation and CAT scan findings in mycetoma of the head. *East Afr Med J* 75: 246-248.
3. Kapadia M, Rolston KV, Han XY (2007) Invasive *Streptomyces* infections: six cases and literature review. *Am J Clin Pathol* 127: 619-624.
4. Mossad SB, Tomford JW, Stewart R, Ratliff NB, Hall GS (1995) Case report of *Streptomyces* endocarditis of a prosthetic aortic valve. *J Clin Microbiol* 33: 3335-3337.
5. Dieng MT, Sy MH, Diop BM, Niang SO, Ndiaye B (2003) Mycetoma: 130 cases. *Ann Dermatol Venereol* 130: 16-19.
6. Carey J, Motyl M, Perlman DC (2001) Catheter-related bacteremia due to *Streptomyces* in a patient receiving holistic infusions. *Emerg Infect Dis* 7: 1043-1045.
7. Ghanem G, Adachi J, Han XY, Raad I (2007) Central venous catheter-related *Streptomyces* septic thrombosis. *Infect Control Hosp Epidemiol* 28: 599-601.
8. Moss WJ, Sager JA, Dick JD, Ruff A (2003) *Streptomyces bikiniensis* bacteremia. *Emerg Infect Dis* 9: 273-274.
9. Rose CE, III, Brown JM, Fisher JF (2008) Brain abscess caused by *Streptomyces* infection following penetration trauma: case report and results of susceptibility analysis of 92 isolates of *Streptomyces* species submitted to the CDC from 2000 to 2004. *J Clin Microbiol* 46: 821-823.
10. Ameen M, Arenas R (2009) Developments in the management of mycetomas. *Clin Exp Dermatol* 34: 1-7.
11. Joshi R (2008) Treatment of actinomycetoma with combination of rifampicin and co-trimoxazole. *Indian J Dermatol Venereol Leprol* 74: 166-168.

Corresponding author

Dr. Noyal Mariya Joseph
 Department of Microbiology
 Mahatma Gandhi Medical College and Research Institute
 Pillaiyarkuppam, Pondicherry – 607 402
 India
 Telephone: 9843094673
 Email address: noyaljoseph@yahoo.com

Conflict of interest: No conflict of interest is declared.